MFDS PART 2
60 OSCE Stations

Johno Breeze
Eiling Wu

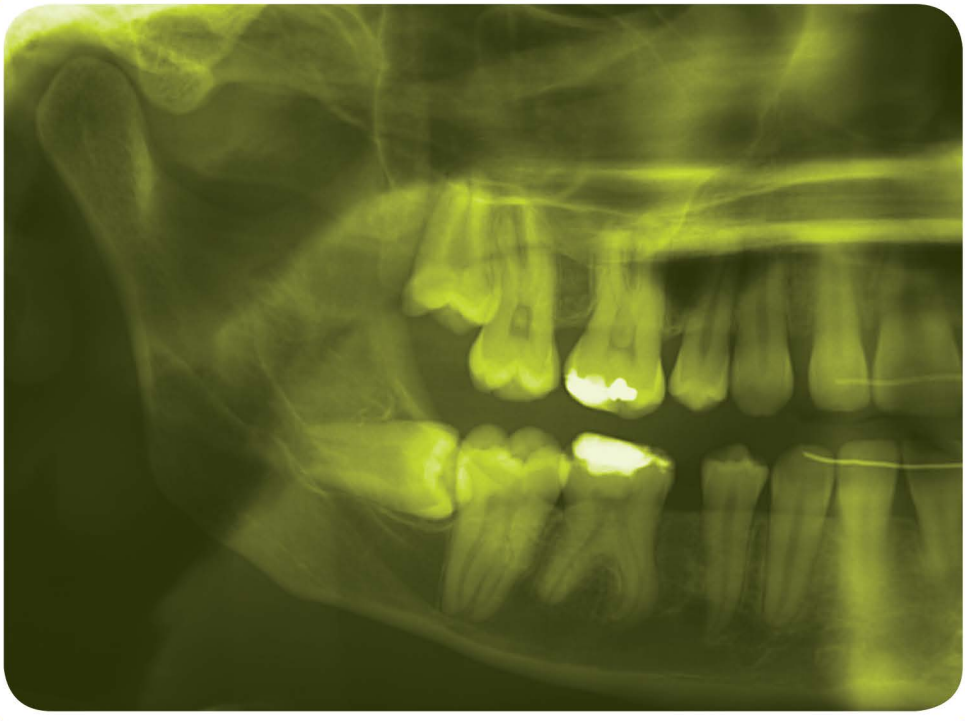

Contents

Preface		v
Contributors		xi
Map of scenarios to curriculum		xii
Acknowledgements		xvi
About the MFDS part 2 examination and the role of this book		xvii
Scenario 1	A dental patient with a dry mouth	1
Scenario 2	Management of a white patch in the mouth	5
Scenario 3	Temporomandibular joint dysfunction	9
Scenario 4	Facial pain	13
Scenario 5	Recurrent oral ulceration	17
Scenario 6	A suspicious ulcer necessitating urgent referral	21
Scenario 7	Cemento-osseous dysplasia	25
Scenario 8	Cranial nerves examination	29
Scenario 9	Management of anaphylaxis in dental practice	31
Scenario 10	Management of angina in dental practice	35
Scenario 11	Management of asthma in dental practice	39
Scenario 12	Management of epilepsy in dental practice	43
Scenario 13	Management of hypoglycaemia in dental practice	47
Scenario 14	Basic life support in dental practice	49
Scenario 15	Immediate options for an extracted tooth	53
Scenario 16	Long-term options for a missing tooth	57
Scenario 17	Partial denture design	61
Scenario 18	Implant management	65

Scenario 19	A child with a cleft lip presenting to dental practice	69
Scenario 20	Referral for advanced periodontal disease	73
Scenario 21	Trauma to an adult incisor tooth	77
Scenario 22	A mandible fracture presenting to dental practice	81
Scenario 23	Repair of a facial laceration	85
Scenario 24	Special needs children requiring sedation	89
Scenario 25	Amelogenesis imperfecta	93
Scenario 26	Management of childhood caries	97
Scenario 27	Unerupted maxillary canines	101
Scenario 28	Management of infraoccluded primary molars	105
Scenario 29	Orthodontic appliances	109
Scenario 30	Periodontal disease and recession in an orthodontic patient	113
Scenario 31	Failed tooth extraction	117
Scenario 32	Coronectomy for a third molar tooth	121
Scenario 33	Dental treatment of patients on bisphosphonates	125
Scenario 34	Intravenous sedation for dental extractions	129
Scenario 35	Oroantral fistula	133
Scenario 36	Management of an unrestorable tooth in a patient with a replacement heart valve	137
Scenario 37	Management of lichen planus in dental practice	141
Scenario 38	Previously undiagnosed periodontal disease	145
Scenario 39	Failed tooth extraction with retained root	149
Scenario 40	Tongue numbness after tooth extraction	151

Scenario 41	A lump in the palate	155
Scenario 42	Management of an avulsed tooth in a child	159
Scenario 43	Incisional biopsy of a suspicious lesion	163
Scenario 44	Suturing of a bleeding socket	167
Scenario 45	Raising a flap for a surgical tooth extraction	171
Scenario 46	Interpretation of apical radiolucent lesion	175
Scenario 47	Adequacy of root canal filling for apicectomy	179
Scenario 48	Third molar assessment	183
Scenario 49	Salivary gland swellings	187
Scenario 50	X-ray machine malfunction	191
Scenario 51	Extractions of teeth for patients on warfarin	195
Scenario 52	Correctly writing a prescription for antibiotics	199
Scenario 53	Antibiotics for a dental infection following tooth extraction	203
Scenario 54	Spreading infection from a lower molar tooth	207
Scenario 55	Communication of national health service eligibility for orthodontic treatment	211
Scenario 56	Mental capacity and consent for dental treatment	215
Scenario 57	Alcohol misuse by a dentist	219
Scenario 58	General dental council standards	223
Scenario 59	Missing money from the work place staff room	227
Scenario 60	Management of a sharps injury in dental practice	231

Scenario 4

Facial pain

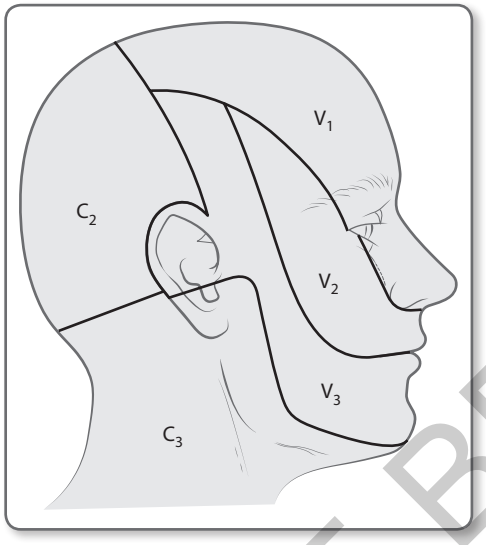

Figure 1 Distribution of the three branches of the trigeminal nerve, crainal nerve V.

A 55-year-old woman presents with a history of excruciating right-sided facial pain. She had a tooth restored approximately 2 years ago but does not feel this is like any toothache she has ever had before. When you gently retract her lower lip, she recoils reporting a severe sharp pain (**Figure 1**).

Questions

1. What is the sensory innervation to the mouth and face?
2. Describe the typical presentations of odontogenic pain.
3. Describe causes of dental pain other than caries.
4. Who is typically affected by trigeminal neuralgia?
5. What is trigeminal neuralgia and how does it present?
6. What other diagnoses should be considered for this type of facial pain?
7. How is trigeminal neuralgia typically managed?
8. Why does lip retraction in this patient elicit pain?

JAYPEE BROTHERS

Answers

1. The sensory innervation to the face and dentition is provided by the trigeminal nerve, which is the fifth cranial nerve. It has three principal divisions:
   i. *The ophthalmic branch (V_1):* This is a sensory nerve supplying the skin of the eye, upper eyelids, upper face, and forehead
   ii. *The maxillary branch (V_2):* This is a sensory nerve that exits the orbit via the superior orbital fissure and emerges from the floor of the orbit via the infraorbital foramen to supply the skin of the cheek and nose
   iii. *The mandibular branch (V_3):* This is the largest of the three divisions. The most important sensory branches are the inferior alveolar nerve supplying sensation to the teeth and lip, and the lingual nerve supplying the tongue. The motor branch supplies the muscles of mastication
2. Patients with odontogenic pain typically present in following manner:
   - *Reversible pulpitis:* The initial presentation where the pulp responds to an irritant and bacterial ingress may not yet have reached the pulp. Pain is typically short lasting and often triggered by hot or cold stimuli. It is poorly localisable
   - *Irreversible pulpitis:* This occurs as bacterial invasion of the pulp progresses. Patients develop pain which is severe, long lasting, and spontaneous, if untreated
   - *Apical periodontitis:* The periodontal ligament becomes involved and the inflammatory process above progresses, producing characteristic tenderness on percussion of the tooth. Abscess formation may result, leading to swelling or sinus formation as pus seeks to escape via the most direct route
3. There are a number of potential causes of dental pain other than caries:
   - *Cracked cusp syndrome:* This is when a fracture has propagated through the tooth but is yet to manifest in a loss of tooth structure. Patients present with sharp pain, which is characteristically worse on the "release" of bite. The diagnosis is primarily by clinical examination. Relief of symptoms may occur by using full coverage restorations such as onlays or crowns
   - *Dentinal hypersensitivity:* Tooth wear or gingival recession can expose dentinal tubules, causing sensitivity to hot and cold stimuli. This is generally managed by specialised toothpastes that act to occlude the dentinal tubules
4. Trigeminal neuralgia is a relatively rare condition. It is estimated to have an incidence of 12 new cases per 100,000 people per year.[1] The condition more frequently occurs in females and in those aged over fifty. Where younger people experience symptoms, it is important to exclude a diagnosis of multiple sclerosis.
5. Trigeminal neuralgia is a type of neuropathic pain, and is generally associated with a nerve injury or lesion.[2]
   - It affects the trigeminal cranial nerve and is of unknown aetiology. One or more branches of the nerve can be affected, with the maxillary and mandibular branches most commonly involved
   - A subset of patients may experience pain bilaterally at different times. Even more rarely, in bilateral trigeminal neuralgia, both sides of the face may be affected simultaneously
   - Trigeminal neuralgia manifests as excruciating pain in the face and jaw, often described as a "stabbing" or "electric shock" sensation. Two broad subtypes of

JAYPEE BROTHERS

trigeminal neuralgia exist. In Type I or "classic" trigeminal neuralgia, definitive periods of remission are present where symptoms are absent. In Type II or "atypical" trigeminal neuralgia, pain is often a constant burning sensation affecting a widespread area

6. Cluster headaches and temporal arteritis are other differential diagnosis of facial pain.
   - *Cluster headaches:* Patients experience excruciating pain on a single side of the face and around the eye. Headaches begin without warning, with a sharp piercing sensation. Watering of the eye is sometimes present, as is drooping of the eyelid (ptosis), facial sweating, or a runny nose (rhinorrhea). Attacks are long lasting and occur multiple times a day
   - *Temporal arteritis:* This is also known as giant cell arteritis. Symptoms include severe headache with pain over the temporal region, jaw claudication, and alteration of vision. Management involves titration of a systemic steroid dose until symptom control is achieved. A diagnosis is confirmed by temporal artery biopsy, where a small portion of the superficial temporal artery is removed and sent for histopathological analysis
7. Measures for managing trigeminal neuralgia include the following:
   - *Analgesia:* Pain should be managed using the World Health Organization "analgesia ladder". This recommends starting with nonopioid medications such as nonsteroidal anti-inflammatory drugs (NSAIDs) and paracetamol, prior to progressing to mild opioids such as codeine. Where pain has not been effectively controlled, strong opioids such as morphine may be indicated
   - *Anticonvulsant medications:* These are used to gain both symptom control and confirm diagnosis. The recommended first line drug is carbamazepine, with the dose titrated to response. Blood tests are recommended as anticonvulsants can affect liver function[3]
   - *Percutaneous procedures:* A needle can be inserted into the trigeminal ganglion under radiological guidance and either glycerol injected or the needle is used to apply heat. Alternatively, a balloon can be inserted through the needle to compress the trigeminal ganglion and later removed
   - *Microvascular decompression (MVD):* This is where a neurosurgeon relieves the pressure placed on the trigeminal nerve by surrounding blood vessels. This provides long-lasting relief but is a major surgical intervention
8. Lip retraction may act as a trigger for trigeminal neuralgia. Others triggers include touching the face, cold wind, or even shaving the face can bring on painful episodes. Where pain affects the mandibular division of the trigeminal nerve, an inferior alveolar nerve block may provide some short-term relief to facilitate more thorough clinical examination.

References

1. Jones, MR, Ehrhardt, KP, Cefalu JN, et al. A comprehensive review of trigeminal neuralgia. Current Pain Headache Rep 2019; 23:1599.
2. British association of oral and maxillofacial surgeons. Trigeminal neuralgia. https://www.baoms.org.uk/patients/conditions/8/trigeminal_neuralgia (Last accessed 07 June, 2020).
3. Scottish Dental Clinical Effectiveness Programme. Drug prescribing for dentistry. 2016. http://www.sdcep.org.uk/published-guidance/drug-prescribing/ (Last accessed 07 June 2020).

JAYPEE BROTHERS

MFDS PART 2
60 OSCE Stations

The Membership of the Faculty of Dental Surgery (MFDS) examination can rightly be regarded as a key milestone in the career of any dental graduate. This book aims to help trainees to focus knowledge acquired in simulated patient encounters in the setting of the clinical examination. In making the leap to applying the theory, the trainee is directed through likely questions and pearls of current thinking that may distinguish the excellent trainee from the merely satisfactory one. Sometimes there are no clear answers and understanding the evidence base forms an important foundation onto which you can build your knowledge and shape your own opinions.

Throughout we aim to direct the reader to pivotal research papers and further reading for a deeper understanding in areas that they may wish to explore more thoroughly. Read this as a standalone work, use it as the springboard to wider reading or simulate the examination with colleagues. Above all, rehearse saying the knowledge you already have out loud and believe in yourself, you have made it this far.

Eiling Wu is a dual-degreed specialist trainee in Oral and Maxillofacial Surgery in the West Midlands deanery. She gained her medical degree from St. Bartholomew's and The Royal London in 2002 and her dental degree from King's College London in 2013 including an Associate King College degree in Philosophy and Theology. Since her appointment as a research and teaching fellow in 2008 she has been a medical school examiner and completed a PGCE. She has travelled as part of a Mercy Ships humanitarian mission through a series of hospitals in Cameroon. This involved leading the on-shore Medical Capacity Building team which was responsible for the teaching and integration of surgical safety measures in support of the Cameroon Government. Her work as a voluntary medic, including working in Tanzania and Ghana, has led her around the world and up mountains.

Johno Breeze is a Lieutenant Colonel in the Royal Army Medical Corps and Consultant Oral and Maxillofacial Surgeon at the Royal Centre for Defence Medicine and University Hospitals Birmingham NHS Foundation Trust. He has deployed to Bosnia, Oman, Northern Ireland and three times to Afghanistan. He completed his medical and dental degrees in London, and his PhD in Birmingham, UK. He completed "higher surgical training" in the West Midlands and a year post-CCT fellowship in Craniomaxillofacial Trauma at Duke University Medical Centre, North Carolina, United States of America. He was awarded military healthcare person of the year in 2013 for developing a new design of body armour worn by all UK military personnel. In 2015, he was presented by Her Majesty The Queen the civil service prize for innovation. He is the editor-in-chief of BMJ Military Health. His research interests centre around the optimisation of body armour, emergency preparedness, and protection of the national infrastructure against ballistic threats.

JP medical publishers

www.jpmedpub.com

ISBN 978-1-78779-114-5

9 781787 791145