SECOND EDITION

Short and OSCE Cases in INTERNAL MEDICINE Clinical Exams

for PACES, MRCPI, Arab Board and Similar Exams









Wanis H Ibrahim

Foreword
Rayaz A Malik

Part 3

Respiratory cases

How to examine the respiratory system?

- Wash your hands.
- Shake hands with the patient, introduce yourself, and take permission.
- Position the patient at a 45° angle and request him/her to remove the upper clothes.
- Inform the patient to alert you in case you cause any discomfort or pain to him/her during the examination.
- Start by inspecting the patient and the surrounding:
  - *Surrounding*:
    - Pay particular attention to the use of oxygen, noninvasive ventilation machines, ongoing intravenous infusion, and sputum pot.
  - *Careful inspection of the patient for*:
    - Signs of respiratory distress and use of accessory muscles of respiration.
    - Observe for the presence of cachexia [malignancy, chronic obstructive pulmonary disease (COPD), or tuberculosis (TB)].
    - Features of Cushing's syndrome due to chronic steroid use for chronic lung diseases such as interstitial lung diseases (ILDs) and severe asthma are frequently missed by candidates in clinical examinations.
    - Facial features of scleroderma, systemic lupus erythematosus (SLE), or sarcoid lesions.
    - A patient who cannot move his/her neck during examination might have ankylosing spondylitis with apical lung fibrosis.
- Presence of hoarseness of voice while talking to the patient or Horner's syndrome when looking at the patient's face can be easily missed during chest examination. These two signs can point to lung cancer as the underlying diagnosis.
- Hold the patient's hand, put your fingers over the radial pulse, and pretend to count the pulse while counting the respiratory rate to distract the patient's attention.
- *Hand examination can provide important clues about the underlying diagnosis*:
  - Nicotine stains may suggest COPD or cancer lung.
  - Finger clubbing may point to lung cancer, bronchiectasis, or interstitial lung disease (ILD).
  - Palmar erythema and flapping tremor may suggest CO_2 retention.
  - The presence of rheumatoid hand deformities suggests rheumatoid lung disease.
  - Tight skin and fingertip ulcerations suggest scleroderma lung disease.
  - Asymmetric wasting of the small muscles of one hand may suggest a Pancoast tumour compressing the brachial plexus (**Figure 3.1**).
- During the eye examination, look for the following features:
  - Horner's syndrome such as ptosis, meiosis, and enophthalmos that may suggest a Pancoast lesion.
  - Conjunctival pallor.
  - Presence of episcleritis (may suggest rheumatoid) or uveitis (ankylosing spondylitis).



Figure 3.1 Unilateral small muscle wasting in the hand may suggest a Pancoast lesion.

- Examine the mouth for cyanosis (remember that the best place to look for cyanosis is the ventral aspect of the tongue – some examiners may become irritated, if the candidate does not ask the patient to lift the tongue up when looking for cyanosis).
- Examine the neck for lymphadenopathy.
- Examine the jugular venous pressure (JVP) (cor pulmonale).
- Examine the legs for pitting oedema (can be left till the end but should not be forgotten). Remember when examining for pitting oedema to enquire from the patient about leg pain before pressing over the legs and to direct your face towards the patient for tenderness rather than towards the examiner.
- Move to the chest and follow the four steps of chest examination – inspection, palpation, percussion, and auscultation.
- *Inspection*:
  - Look for chest deformities such as pectus excavatum and carinatum or kyphoscoliosis (**Figures 2.3** and **2.4: Part 2**).
  - Asymmetry of the chest is an important sign that is easily missed by candidates and may suggest an underlying collapse, fibrosis, a large effusion or lung surgery (**Figure 3.2**).
  - The intercostal recession during inspiration and use of accessory muscles.
  - Some patients with cystic fibrosis (CF) or lung cancer may have long-lasting venous catheters (Hickman's line, PICC, Port, etc.) for repeated administration of antibiotics or chemotherapy (**Figure 3.3**).
  - The presence of dilated veins over the chest may suggest superior vena cava (SVC) obstruction.
  - Scars in the chest wall can give an important clue about the diagnosis. A thoracotomy scar may suggest a prior lung resection. A scar of chest drain may suggest pleural effusion as a possible diagnosis (**Figure 3.4**).
  - The presence of radiation-related skin changes may point to lung cancer as a diagnostic possibility.
- There are four things you need to palpate for during chest examination:
  1. Chest expansion.
  2. Tactile vocal fremitus.

JAYPEE BROTHERS



Figure 3.2 Asymmetry of the chest and left thoracotomy scar from a previous lobectomy of the left lung.



Figure 3.3 Port line used for chemotherapy or prolonged antibiotic administration.

3. Position of the trachea.
4. Apex beat.

- During percussion of the chest, always compare the right and left side at the same level and listen to any difference in the note (**Figures 3.5a** and **b**).
- If you find dullness at one lung base, do not forget to perform tidal percussion.
- During auscultation, concentrate on the following:
  - Type and intensity of breath sounds. They should be of equal intensity on both sides and should be vesicular over the lungs.
  - Next, listen for any adventitial sounds such as crackles, rhonchi, or pleural rub. If you find crackles, ask the patient to cough and notice the change in the quality of crackles.
  - Do not forget to listen for vocal resonance; it is more reliable than vocal fremitus.
  - If you find a dull percussion note (particularly with bronchial breathing), check for aegophony and whispering pectoriloquy to make sure you do not miss consolidation.

JAYPEE BROTHERS



Figure 3.4 Left thoracotomy scar with chest drain scars.

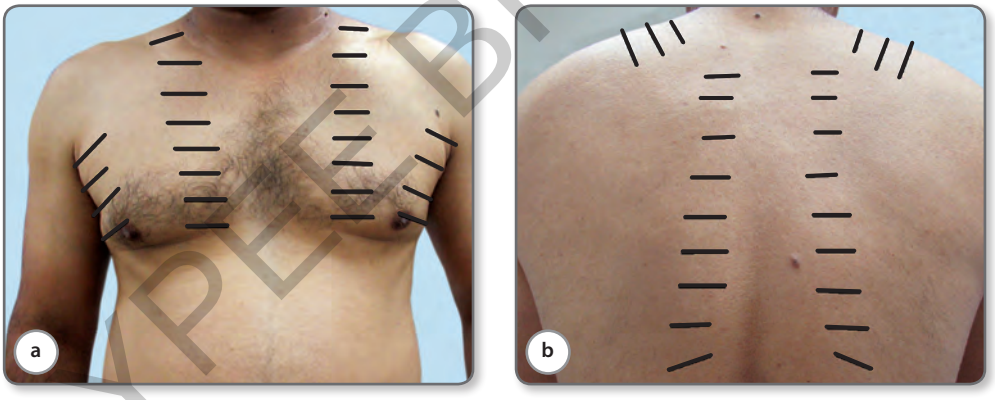

Figures 3.5a and b Sites for chest percussion.

JAYPEE BROTHERS

- It is important to make the patient feels comfortable during chest examination from the back. A good candidate may provide his/her patient with a pillow to rest arms on while examining the back of the chest.
- Do not forget to percuss and auscultate the lateral sides of the chest and make sure you know the surface anatomy of the lung lobes (**Figures 3.6a to c**).

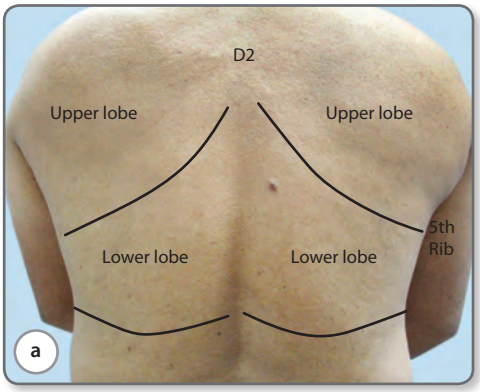

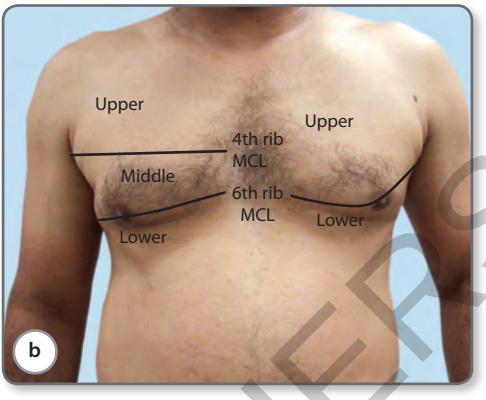

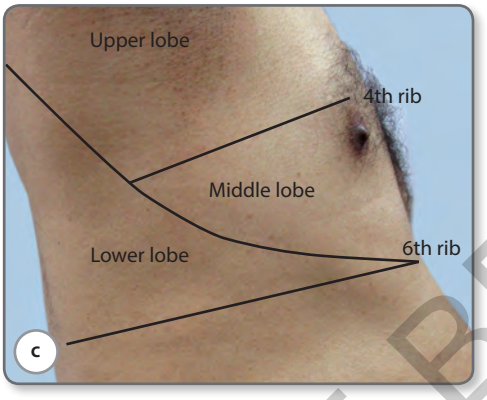

Figures 3.6a to c Surface anatomy of the lung lobes.

Bilateral basal crackles with or without finger clubbing

- Bilateral basal crackles and finger clubbing are one of the most common respiratory cases encountered in both under- and postgraduate clinical examinations. The most common scenarios are:
  - *Bronchiectasis*:
    In bronchiectasis, the crackles are coarse and altered by coughing. Finger clubbing is typically present but may not be found in all cases. The type of crackles is the most important differentiating sign from ILD. (If the patient is young, think of causes of bronchiectasis in young people such as CF, hypogammaglobulinaemia, childhood infections, and Kartagener's syndrome.).
  - *Interstitial lung diseases*:
    The crackles are typically fine and have a Velcro character (some candidates may misdiagnose the cause as heart failure). You must know the causes of ILD in older individuals and young individuals. Many candidates wrongly mention idiopathic pulmonary fibrosis (IPF) as an initial diagnosis in young patients with ILD.
- Bilateral fine crackles with clubbing in an older patient are commonly due to idiopathic pulmonary fibrosis (consider also chronic hypersensitivity pneumonitis).
- *Bilateral fine crackles with hand deformities*: Pulmonary fibrosis secondary to rheumatoid arthritis (RA).
- *Bilateral crackles with signs of scleroderma*: Scleroderma lung disease.

JAYPEE BROTHERS

A patient with interstitial lung disease

Common instructions

- This 65-year-old gentleman complains of cough and exertional breathlessness. Please examine his respiratory system.
- This 30-year-old gentleman complains of cough and exertional breathlessness. Please examine his respiratory system.

Common pitfalls

- Misdiagnosing ILD as bronchiectasis.
- Failure to see Hickman line/implanted ports for long-term antibiotic administration in cystic fibrosis (CF).
- Diagnosing IPF in a young patient.
- Forgetting the causes of ILD in young patients.
- Failure to spot clinical features suggestive of scleroderma or RA in patients with ILD.

The typical presentations of the findings

Candidate 1: This gentleman appears comfortable and not in distress. He appears thin and has finger clubbing and bilateral basal fine inspiratory crackles of the Velcro type. The crackles are not altered by coughing. The most likely diagnosis is ILD. The most common cause at this age is IPF.

Candidate 2: This young gentleman has finger clubbing and bilateral fine inspiratory crackles. The most likely diagnosis is ILD. At this younger age, I will think of hypersensitivity pneumonitis, connective tissue diseases, drugs, etc. (see below).

Examiner: Can you name some of the causes of ILD?

Candidate:
- *IPF/cryptogenic fibrosing alveolitis*: The most common in the older age group (**Figure 3.7**).
- Chronic hypersensitivity pneumonitis (extrinsic allergic alveolitis).
- Connective tissue disease-related ILD (systemic sclerosis, ILD, Sjögren's disease, etc.).
- *Medications*: Methotrexate, nitrofurantoin, some of the chemotherapeutic agents.
- *Occupational lung diseases*: Asbestosis, silicosis, pneumoconiosis, etc.
- Sarcoidosis.
- Smoking-related ILD.

Examiner: How would you differentiate crackles in bronchiectasis, lung fibrosis, and pulmonary oedema?

Candidate:
- *In bronchiectasis*:
  - The crackles are coarse, low-pitched, and loud.
  - Characteristically change with or altered by cough.

JAYPEE BROTHERS



Figure 3.7 Computed tomography (CT) scan of the lungs in a patient with idiopathic pulmonary fibrosis (IPF) (observe the sub-pleural fibrosis and honeycombing).

- *In pulmonary oedema*:
  - In early cases of pulmonary oedema, the crackles can be fine.
  - In severe pulmonary oedema, the crackles can be coarse.
  - They are mid-to-late (end) inspiratory and do not change with the cough.
- *In lung fibrosis*:
  - The crackles are fine and high pitched.
  - They are late (end) inspiratory.
  - They do not change with the cough.
  - Usually described as a 'Velcro' type of crackles – (Velcro sound is the sound produced by the hook-and-loop fasteners when the strips are separated).

Examiner: Which crackles are heard during early inspiration?

Candidate: Crackles heard during early inspiration are indicative of airway diseases, such as chronic bronchitis and emphysema.

Crackles heard during late inspiration are indicative of parenchymal disorders, such as pulmonary fibrosis, interstitial pneumonitis, and pneumonia.

Examiner: What are pulmonary squawks (or squeaks) and when do you hear them?

Candidate: Squawks/squeaks are short inspiratory wheezes of very short duration that are heard late in inspiration (end-inspiratory). Common causes of squawks are:
- Pulmonary fibrosis of various causes (particularly in hypersensitivity pneumonitis).
- Pneumonia.
- Bronchiolitis obliterans.

Examiner: What are the causes of predominantly upper lobe fibrosis?

Candidate: 'SARA-HAS-TO-BE-SICK-FROM-CHRONIC-ANKLE PAIN'—
- Sarcoidosis.
- Histoplasmosis.
- Tuberculosis.
- Berylliosis.
- Silicosis.
- Cystic fibrosis.
- Chronic hypersensitivity pneumonitis.
- Ankylosing spondylitis.
- Progressive massive fibrosis.

JAYPEE BROTHERS

Examiner: What are the causes of predominantly lower lobe fibrosis?

Candidate: 'DRUGS-CANNOT-CURE-ASBESTOSIS'—
- Drugs (busulfan, bleomycin, nitrofurantoin, hydralazine, methotrexate, and amiodarone).
- Connective tissue diseases (scleroderma and RA).
- Cryptogenic fibrosing alveolitis (IPF).
- Asbestosis.

Examiner: What important questions would you like to ask this patient?

Candidate:
- Keeping birds.
- Farming.
- Recent and past occupations (asbestosis usually develops many years after asbestos exposure).
- Use of drugs.
- *Symptoms suggestive of connective tissue disease*: Joint pain, Raynaud's phenomenon, dysphagia, dry mouth and eyes, skin rash, etc.).
- *Extra-pulmonary features that suggest sarcoidosis*: Uveitis, skin rash, etc.

Examiner: What is the type of immune reaction that happens in hypersensitivity pneumonitis?

Candidate: Acute hypersensitivity pneumonitis is a type III immune reaction; whereas, subacute and chronic forms are type IV immune reactions.

Examiner: Can you name some examples of hypersensitivity pneumonitis?

Candidate: Many substances can cause hypersensitivity pneumonitis. Some of the famous examples include:
- Farmer's lung – caused by inhalation of *Saccharopolyspora rectivirgula* in mouldy hay and straw.
- Bird fancier's lung (pigeon breeder's disease) – caused by inhalation of avian or animal proteins in feathers or droppings of birds.
- Humidifier lung – caused by inhalation of fungi growing in humidifiers, air conditioners, and heating systems.
- Hot tub lung – caused by inhalation of *Mycobacterium avium* complex in the water vapour coming from hot tubs.

Examiner: Where do you examine for a right middle lobe abnormality?

Candidate: The right middle lobe is represented in the right mid-chest anteriorly and laterally (between 4th and 6th ribs) but not posteriorly. When you examine the chest posteriorly, you examine for abnormalities in upper and lower lobes only (**Figures 3.6a to c**).

Examiner: How would you manage this patient?

Candidate:
Investigations:
- High-resolution computed tomography (HRCT) chest.
- Pulmonary function tests (PFTs) and arterial blood gas (ABG).
- Six-minute walk test.
- Bronchoscopy with bronchoalveolar lavage (BAL).

JAYPEE BROTHERS

- Autoimmune workup [rheumatoid factor (RF), anti-cyclic citrullinated peptide antibodies (ACCP), anti-SCL-70, and extractable nuclear antigen antibodies (ENA)].
- Hypersensitivity pneumonitis panel (serum precipitins).
- Surgical lung biopsy.

Treatment:

- Stop smoking.
- Home oxygen therapy.
- Vaccination.
- Treat the underlying cause – steroids for hypersensitivity pneumonitis.

Idiopathic pulmonary fibrosis and interstitial lung disease

Examiner: What is the most common cause of ILD in older age groups?

Candidate: IPF is the most common cause.

Examiner: What are the diagnostic criteria for IPF?

Candidate: The three main diagnostic criteria are:

1. Exclusion of a known cause of ILD.
2. HRCT scan criteria.
3. Pathologic criteria (lung biopsy).

Examiner: What do you know about the HRCT findings in IPF?

Candidate:

- Honeycombing.
- Bilateral, predominantly subpleural basal fibrosis.
- Absence on HRCT of features that point to other aetiology.

Examiner: What is the name given to the histopathologic appearance of a lung biopsy in IPF?

Candidate: Usual interstitial pneumonia (UIP).

Examiner: What are the causes of pulmonary fibrosis with honeycombing (UIP pattern) on a CT scan of the chest? Or what diseases may mimic IPF?

Candidate:

- Idiopathic pulmonary fibrosis.
- Chronic hypersensitivity pneumonitis (extrinsic allergic alveolitis).
- Connective tissue diseases such as RA and scleroderma.
- Drug-induced – methotrexate used in the treatment of RA.
- Sarcoidosis.
- Asbestosis.

Examiner: In a patient with RA treated with methotrexate, how would you differentiate pulmonary fibrosis due to methotrexate from that due to RA?

Candidate: This may be difficult to differentiate, but the presence of lymphocytes in the BAL fluid, granuloma in the lung biopsy specimens, and peripheral eosinophilia can suggest it is methotrexate rather than RA-related ILD. The presence of active RA and neutrophilic BAL suggests RA-related ILD.

JAYPEE BROTHERS

Examiner: Can you name some new drugs for the treatment of IPF?

Candidate:
- Pirfenidone.
- Nintedanib.

Examiner: What are the complications or comorbidities associated with IPF?

Candidate:
- Pulmonary hypertension.
- Lung cancer.
- Coronary artery disease.
- Pulmonary embolism.
- Respiratory failure.

Examiner: How would you manage this patient?

Candidate:
Investigations:
- HRCT chest.
- PFTs and ABG
- Six-minute walk test.
- Bronchoscopy with BAL.
- Autoimmune workup (RF, ACCP, ASCL-70, and ENA).
- Hypersensitivity pneumonitis panel (serum precipitins).
- Surgical lung biopsy.

Treatment:
- Stop smoking.
- Home oxygen therapy.
- Vaccination.
- *Drugs*: Pirfenidone and nintedanib.
- Referral for lung transplantation (should be done early).
- Pulmonary rehabilitation.

Examiner: What is the prognosis of IPF?

Candidate: The prognosis of IPF is poor with a median survival of 2.5–3.5 years.

Bronchiectasis

Common instructions

- This gentleman is under follow-up in the urology clinic for infertility. He complains of cough. Please examine his respiratory system.
- This young gentleman has cough since childhood. Please examine his respiratory system.

Common pitfalls

- Misdiagnosing bronchiectasis as ILD despite the presence of coarse crackles.
- Failure to ask the patient to cough to appreciate the changes in the quality of coarse crackles.

JAYPEE BROTHERS

The typical presentation of the findings

This gentleman appears comfortable and not in distress. He has finger clubbing. Chest examination revealed bilateral coarse crackles that are altered by coughing. The most likely diagnosis is bilateral bronchiectasis. Given the history of infertility, Kartagener's syndrome is the likely cause. I would like to complete my examination by examining the cardiovascular system to check for dextrocardia (**Figure 3.8**).

Examiner: What are the causes of bronchiectasis?

Candidate: 'OK CHAPS'—

1. **O:** Obstruction of the bronchus (tumour and foreign body).
2. **K:** Kartagener's syndrome.
3. **C:** Cystic fibrosis.
4. **H:** Hypogammaglobulinaemia.
5. **A:** Allergic bronchopulmonary aspergillosis.
6. **P:** Pneumonia and previous chest infections (whooping cough and measles).
7. **S:** Sjögren's syndrome and connective diseases.

Examiner: Which other systems would you like to examine in this patient?

Candidate: I would like to examine the cardiovascular system for the presence of dextrocardia (Kartagener's syndrome).

Examiner: What is Kartagener's syndrome?

Candidate: This is an autosomal recessive disorder, which results in dextrocardia, sinusitis, and bronchiectasis. It is caused by defective ciliary function in the airways 'ciliary dyskinesia' leading to defective mucus clearing and repeated infections and bronchiectasis. The main diagnostic method is nasal and bronchial brushings or biopsy.

Examiner: What do you think about the cause of his infertility?

Candidate: Most men with primary ciliary dyskinesia/Kartagener's syndrome are infertile because of immotile sperms (the sperms are viable but immotile). Almost half of women with this disease have reduced fertility because of a lack of ciliary function of the fallopian tubes.

Examiner: If a patient with bronchiectasis has recurrent cough since childhood, what comes to your mind as the possible aetiology?

Candidate:

- Cystic fibrosis.

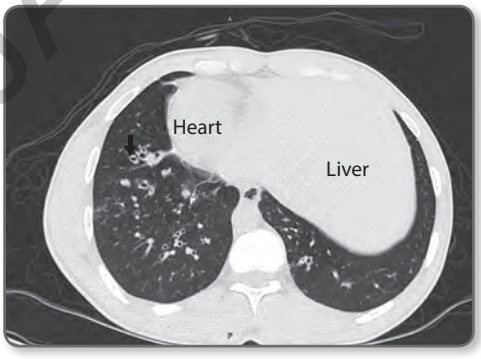

Figure 3.8 Computed tomography (CT) scan chest of a patient with Kartagener's syndrome (observe the presence of situs inversus and the bronchiectasis).

JAYPEE BROTHERS

- Bronchiectasis complicating viral/bacterial pneumonia.
- Hypogammaglobulinaemia.

Examiner: If this patient comes with nephrotic syndrome, what is the possible aetiology?

Candidate: Systemic amyloidosis complicating chronic bronchiectasis.

Examiner: What are the complications of bronchiectasis?

Candidate:
- Massive haemoptysis.
- Repeated chest infections.
- Lung abscess.
- Cor-pulmonale.
- Systemic amyloidosis.

Examiner: How do you investigate this patient?

Candidate:
- Complete blood count (CBC).
- Sputum gram stain and culture.
- Chest X-ray.
- HRCT lungs.
- Serum immunoglobulin levels.
- Work-up for CF (including sweat chloride and genetic testing).
- Skin prick test for *Aspergillus* and *Aspergillus*-specific IgE level.
- Bronchoscopy and BAL.
- Pulmonary function test.

Examiner: How would you treat this patient?

Candidate:
- Antibiotics.
- Bronchodilator therapy.
- Mucolytic therapy.
- Saline nebulisation.
- Treat the underlying cause.
- Vaccination.
- Chest physiotherapy.
- Surgery for localised bronchiectasis or massive haemoptysis.

Cystic fibrosis

Examiner: How would you diagnose CF?

Candidate:
- Clinical features, PFT, sputum culture, and HRCT chest.
- Two samples of sweat chloride >60 mmol/L.
- *Genetic testing*: Indications:
  - Intermediate results of the sweat chloride test (40–60).
  - Family history of CF.
  - Pre-pregnancy.

Examiner: What is the basic abnormality in CF?

JAYPEE BROTHERS

Short and OSCE Cases in

INTERNAL MEDICINE

Clinical Exams

Key Features

- A comprehensive and up-to-date book from the examiner's perspective intended to help postgraduate and undergraduate candidates pass their clinical exams.
- The first edition of the book was very well-received and was a resounding success. The book has gained wide popularity among international candidates, particularly those preparing for MRCP (UK) PACES, MRCPI, Arab Board, and other clinical exams that use the OSCE format.
- The second edition keeps the same basic theme of conversational style of the book (an examiner asks a question and a candidate provides the typical answer), which recreates the conditions encountered in the real clinical exams.
- The approach to each case in the book has been standardised into a unified format that includes the common examiner's instructions, the common mistakes (pitfalls) committed by candidates and the typical style of presentation of findings. This is followed by a succinct summary of diagnosis, differential diagnosis, management, and further information usually required in clinical exams.
- Particular emphasis has been placed on a highly professional approach to the case, a competent and relevant examination technique according to examiner's instruction, and a concise, professional presentation. This is followed by the questions that are commonly asked by the examiners on each case along with their standard answers, encompassing all aspects of the case.
- A "how to examine" paragraph precedes each case in this book, which emphasises and explains the most competent and professional manner of examination for that case.
- A paragraph containing the important rules/clues for each case has been added and updated to help candidates understand common practical facts about that case.
- The list of cases has been expanded to include cases recently encountered by candidates in international clinical exams.
- All the sections have been thoroughly reviewed and updated based on new information and advancements in the medical field since the publication of the first edition.
- A section entitled "how to prepare for and pass your clinical exams" has been added to explain important practical tips that help candidates plan and prepare for their clinical exams.
- The number of photos and illustrations has been expanded in this edition to include about 150 photos in order to improve the candidate's visual learning experience.
- Considering how a candidate's working memory is negatively affected by examination-provoked stress, some mnemonics to help recall long lists have been included in various pages of the book.

JP medical publishers

www.jpmedpub.com

ISBN 978-1-78779-124-4

9 781787 791244