MRCOG Part 1:
400 SBAs

THIRD EDITION

Editors-in-Chief
Katherine Andersen • Tara Woodward

Editors
Ariadne L'Heveder • Laura van der Krogt

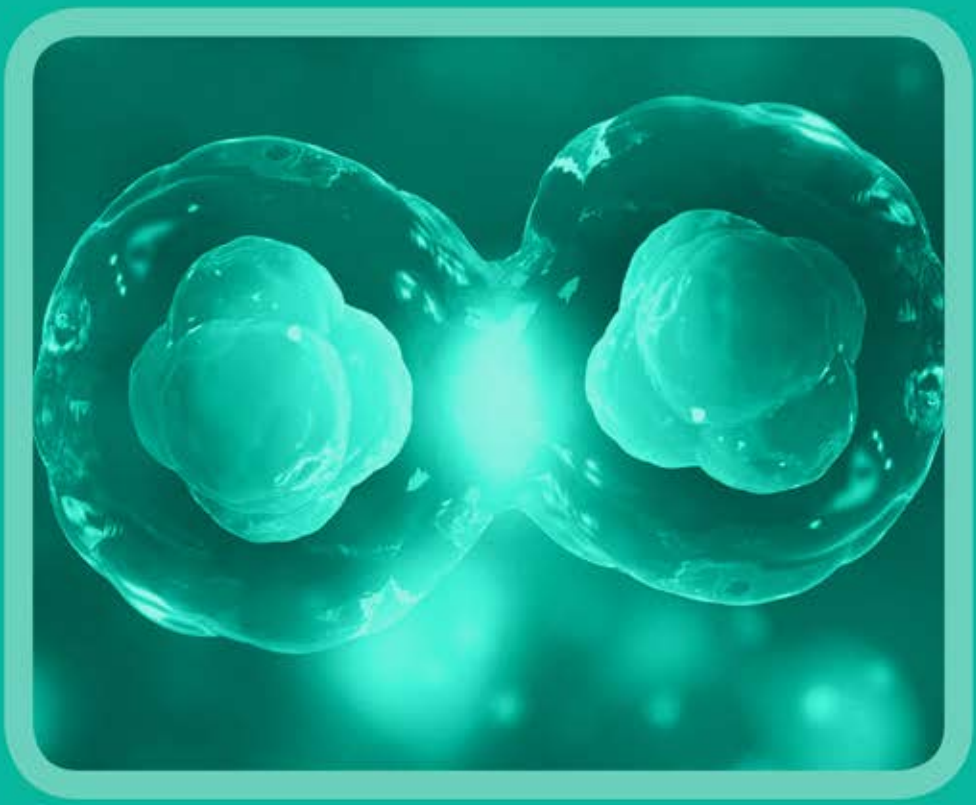

MRCOG Part 1

400 SBAs

THIRD EDITION

Editors-in-Chief

Katherine Andersen **MBBS BSc MRCOG**
Consultant Obstetrician and Gynaecologist
Royal Free London NHS Foundation Trust, London, UK

Tara Woodward **MBBS BSc (Hons) DRCOG PgDip Journalism, PgCert Healthcare Practice**
General Practitioner
London, UK

Editors

Ariadne L'Heveder **MBChB (Hons) BMedSci (Hons)**
Specialty Trainee in Obstetrics and Gynaecology
North Central & East London Deanery, London, UK

Laura van der Krogt **MBBS, BSc (Hons)**
Specialty Trainee in Obstetrics and Gynaecology
North Central & East London Deanery, London, UK

JAYPEE BROTHERS

JP medical publishers

London • New Delhi

Contents

Preface *v*
Dedication *vi*
Exam revision advice *vii*
Acknowledgements *viii*

Chapter 1 **Anatomy** 1

Chapter 2 **Biochemistry** 17

Chapter 3 **Embryology** 25

Chapter 4 **Endocrinology** 31

Chapter 5 **Statistics and epidemiology** 45

Chapter 6 **Genetics** 53

Chapter 7 **Physiology** 59

Chapter 8 **Biophysics** 73

Chapter 9 **Clinical management** 81

Chapter 10 **Data interpretation** 95

Chapter 11 **Immunology** 109

Chapter 12 **Microbiology** 115

Chapter 13 **Pathology** 125

Chapter 14 **Pharmacology** 137

Chapter 15 **Mock Paper 1** 145

Chapter 16 **Mock Paper 2** 203

JAYPEE BROTHERS

Chapter 1

Anatomy

Questions

For each question, select the single best answer from the five options listed.

1. An 82-year-old woman attends her general practitioner's surgery complaining of a painful lump in the groin.

Which of the following does not form a boundary of the femoral triangle?

A Adductor longus
B Inguinal ligament
C Obturator internus
D Pectineus
E Sartorius

2. Identify the structure labelled B.

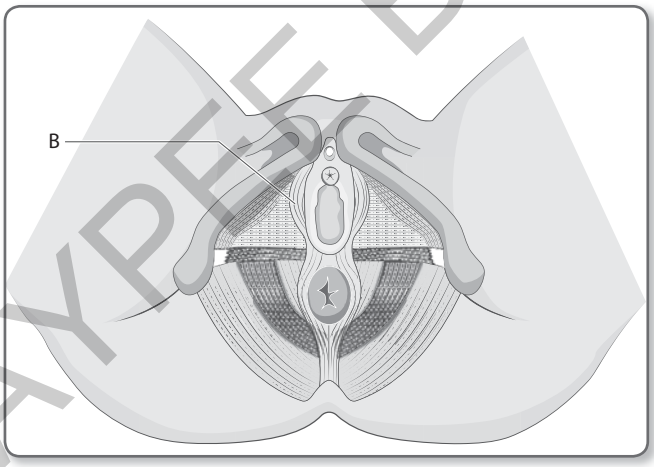

A Bulbocavernosus muscle
B Ischiocavernosus muscle
C Transverse perineal muscles
D Urethral sphincter
E Urogenital diaphragm

JAYPEE BROTHERS

3. Following a routine elective caesarean section, the rectus sheath is being sutured.

With regard to the rectus sheath, which of the following is correct?

A Arcuate line demarcates the upper limit of the posterior layer of rectus sheath
B External oblique aponeurosis forms the posterior aspect of the sheath
C Internal oblique aponeurosis always passes in front of rectus abdominis
D Scarpa's fascia is superficial to Camper's fascia and the external oblique
E Transversalis fascia lies directly below the rectus sheath

4. A 47-year-old woman undergoes a routine total abdominal hysterectomy to remove a large fibroid uterus. She is found to have a fibroid in the broad ligament and there is concern that her ureter may have been damaged during the operation.

With regard to the path of the ureter, which of the following is correct?

A Both ureters pass over their respective uterine artery in the broad ligament
B Ovarian vessels enter the pelvis posterior to the ureters
C The upper one-third of the ureters lies in the abdomen
D The ureter runs lateral to the internal iliac artery
E Ureters cross close to the bifurcation of the common iliac vessels

5. What structure does the right ovarian vein empty into?

A Azygos vein
B Inferior vena cava
C Internal iliac vein
D Right pudendal vein
E Right renal vein

6. A 27-year-old woman has a forceps delivery under regional block. She suffers a significant tear, whereby approximately 70% of the external anal sphincter is torn; the internal anal sphincter remains intact.

How would this tear be classified?

A Episiotomy
B Second-degree tear
C 3a tear
D 3b tear
E 3c tear

7. The median umbilical ligament is derived from which embryological structure?

A Gubernaculum
B Ligamentum teres
C Umbilical artery
D Umbilical vein
E Urachus

JAYPEE BROTHERS

8. Which nerve innervates the anterior third of labia majora?

A Clitoral branch of pudendal nerve
B Iliohypogastric
C Ilioinguinal nerve
D Obturator nerve
E Perineal branch of pudendal nerve

9. During a laparoscopic assisted vaginal hysterectomy the surgeon accidentally damages the ovarian artery. Regarding the left ovarian vein vasculature, which of the following is correct?

A Follows the course of the left ureter
B It anastomoses with the vaginal artery
C Is it a branch of the abdominal aorta?
D Lies inferiorly to the inferior mesenteric artery
E The left ovarian vein is supplied by the inferior vena cava

10. Which of the following arteries is a terminal branch (not paired) of the abdominal aorta?

A Gonadal
B Median sacral
C Phrenic
D Renal
E Suprarenal

11. A 32-year-old woman has an episiotomy repaired following a forceps delivery.

Which of the following does not insert into the perineal body?

A Bulbocavernosus
B External anal sphincter
C Ischiocavernosus
D Levator ani
E Transverse perineal

12. A woman undergoes an emergency caesarean section at full dilatation following a failed trial of instrumental delivery. There is a lateral extension to the lower segment transverse uterine incision which is bleeding and needs repairing.

Identify which of the following gives the correct pairing of the artery and its origin.

	Artery	**Origin**
A	Internal pudendal	Posterior division of internal iliac
B	Ovarian artery	Common iliac
C	Testicular artery	Pudendal
D	Uterine artery	Abdominal aorta
E	Uterine artery	Anterior division of the internal iliac

JAYPEE BROTHERS

13. What is the structure labelled C below?

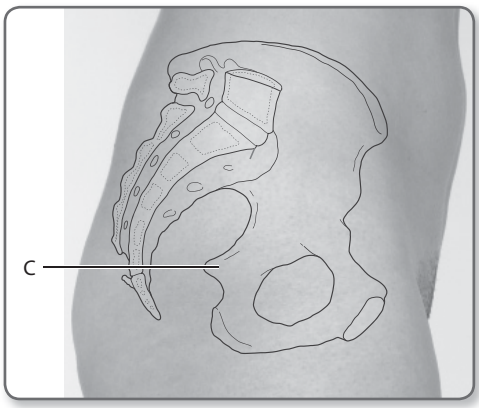

A Anterior superior iliac spine
B Iliac crest
C Ischial spine
D Ischial tubercle
E Pubic tubercle

14. Which of the following describes the anatomy of the inguinal region?

A The deep inguinal ring lies at the lateral two-thirds of the inguinal ligament
B The deep inguinal ring transmits the ilioinguinal nerve
C The superficial inguinal ring lies below the pubic tubercle
D The superficial inguinal ring transmits the genitofemoral nerve
E The superficial inguinal ring transmits the round ligament

15. Which of the following nerves is transmitted by the superficial inguinal ring?

A Femoral nerve
B Genitofemoral nerve
C Ilioinguinal nerve
D Peroneal nerve
E Sciatic nerve

16. A 24-year-old primiparous woman has been pushing in second stage of labour for 90 minutes. A decision is made for a forceps delivery as there is a bradycardia. She does not have an epidural and therefore a pudendal block is given for analgesia for the delivery. On examination, the presenting part is in a direct occipito anterior position at +1 station.

Which of the following statements is most accurate regarding the pudendal nerve?

A It arises from the posterior rami of S2, S3 and S4
B It crosses over the ischial tuberosity, lateral to the internal pudendal artery
C It gives rise to the dorsal nerve of the clitoris

JAYPEE BROTHERS

D It leaves the pelvis through the lesser sciatic foramen
E It supplies the piriformis muscle

17. A 28-year-old woman suffers a fourth-degree tear following a water birth. This is repaired in theatre. The medical student on attachment on the 'labour ward' asks you about the anatomy of the anal canal. Which of the following statements would you choose to describe the anal canal?

A Hilton's line indicates the junction between keratinised and non-keratinised stratified squamous epithelium
B The dentate line lies at the border of the upper one-third and lower two-thirds of the anal canal
C The fibres of ischiococcygeus form part of the internal anal sphincter
D The lower half is lined with keratinised stratified squamous epithelium
E The upper half is lined with cuboidal epithelium

18. Identify which of these is the correct pairing regarding the anatomical structure and its epithelial lining.

	Structure	Lining
A	Vagina	Cuboidal epithelium
B	Ectocervix	Stratified squamous epithelium
C	Uterus	Squamous epithelium
D	Ovary	Columnar epithelium
E	Fallopian tube	Ciliated squamous epithelium

19. Which of the following statements is correct regarding the femoral triangle?

A Its contents include the femoral nerve, the ilioinguinal nerve and the deep inguinal nodes
B Its posterior border forms the inguinal ligament
C The adductor longus forms the medial margin of the femoral triangle
D The femoral sheath includes the femoral artery, vein and nerve
E The femoral vein is medial to the femoral ring

20. A woman is taking oral steroids daily as part of treatment for an acute flare of inflammatory bowel disease throughout the third trimester of her pregnancy. She is admitted to labour ward at 37 weeks' gestation in active labour and is commenced on IV steroids as there is concern about adrenal insufficiency.

Considering the adrenal glands; they can best be described by which of the following?

A The left adrenal gland is triangular-shaped
B The adrenal cortex consists of chromaffin cells
C The right adrenal vein drains into the right renal vein
D The adrenal glands have three sources of arterial blood supply
E The left adrenal gland is in contact with the descending colon

JAYPEE BROTHERS

21. A 28-year-old woman is taken to the operating theatre for a trial of instrumental delivery as she has been pushing for 90 minutes and the presenting part is at the ischial spines station. This is her first baby. She is Caucasian and her height is 152 cm. The baby seems to be a normal size clinically; however, you are concerned about the adequacy of the pelvis.

Which is the most accurate description of the diameters of the pelvis?

A The anatomical antero-posterior diameter (true conjugate) is approximately 11 cm
B The anatomical transverse diameter forms the largest pelvic diameter (~15 cm)
C The antero-posterior diameter bisects the true conjugate
D The coccyx forms an important bony landmark in measurement of the pelvic outlet
E The obstetric conjugate is larger than the true conjugate

22. A 38-year-old woman undergoes a diagnostic laparoscopy for chronic pelvic pain. During the operation, there is a discussion about the condition of pelvic venous congestion, and whether this is a potential cause of the pain.

Which is the best description of the veins of the pelvis?

A The left ovarian vein drains directly into the inferior vena cava
B The external pudendal vein passes through the pudendal canal
C The uterine venous plexus lies medially to the broad ligament
D The internal pudendal vein drains into the great saphenous vein
E The rectal venous plexus is a site of portocaval anastomosis

23. During a hysterectomy for a large multi-fibroid uterus causing pressure symptoms and menorrhagia, you suspect that the right ureter may have been injured while tying the uterine pedicle.

The ureters are muscular tubular structures and:

A Lie in front of the peritoneum
B Are 35 cm long
C Cross in front of the uterine arteries
D Originate embryonically from the ureteric buds
E Insert into the bladder postero-medially

JAYPEE BROTHERS

Answers

1. C Obturator internus

The femoral triangle (**Figure 1.1**) is an anatomical area in the upper thigh. The borders of the femoral triangle can be remembered by the mnemonic, **SAIL**:

- **S**artorius (laterally)
- **A**dductor longus (medially)
- **I**nguinal
- **L**igament (superiorly)

The floor of the femoral triangle is formed by the iliopsoas laterally and pectineus medially. Important structures passing through the femoral triangle include the femoral nerve, artery and vein.

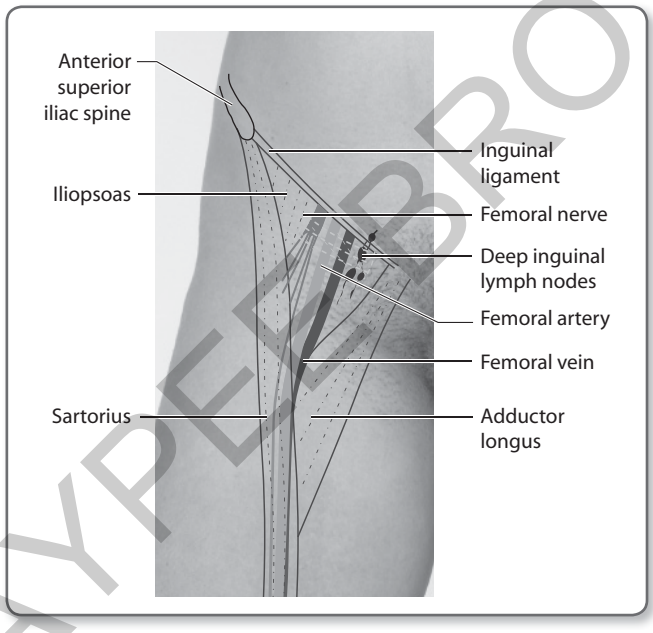

Figure 1.1 Anatomy of the femoral triangle. Reproduced from Tunstall R and Shah N. Pocket Tutor Surface Anatomy. London: JP Medical Ltd, 2012 and courtesy of Sam Scott-Hunter, London.

2. A Bulbocavernosus muscle

See the diagram given in the question for the anatomy of the perineum, including the origins and insertions of the muscles of the perineum.

3. E Transversalis fascia lies directly below the rectus sheath

The rectus sheath is formed from the aponeuroses of three muscles: (1) transversus abdominis, external and internal oblique muscles. Above the arcuate line, the aponeurosis of the external oblique passes in front of the rectus abdominis and

JAYPEE BROTHERS

the transversus abdominis passes behind; the aponeurosis of the internal oblique divides into two at the lateral margin, with the anterior lamellae passing in front of the rectus abdominis and the posterior lamellae passing behind. Scarpa's fascia is deep to the Camper's fascia and superficial to external oblique muscle. The transversalis fascia forms the layer below the rectus sheath (**Figure 1.2**).

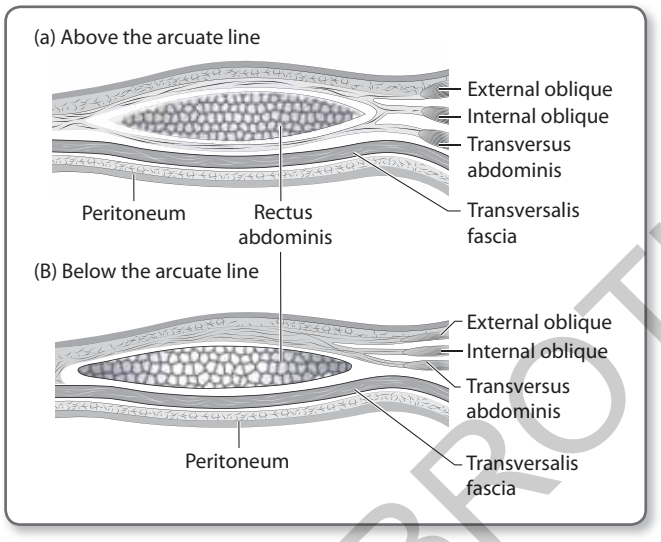

Figure 1.2 Anatomy of the rectus sheath.

4. E Ureters cross close to the bifurcation of the common iliac vessels

The ureters leave the kidney and travel inferiorly and medially along the psoas muscle. They run along the posterior pelvic brim and cross anteriorly to the bifurcation of the common iliac vessels. They run anterior to the internal iliac arteries. They continue postero-inferiorly and turn medially at the ischial spines. They then run in the base of the broad ligament where they are crossed by the uterine artery (water under the bridge). The ureter passes the lateral vaginal fornix and enters the bladder.

5. B Inferior vena cava

The right ovarian vein empties directly into the inferior vena cava. The left ovarian vein empties into the left renal vein before reaching the inferior vena cava.

6. D 3b tear

The Royal College of Obstetricians and Gynaecologists (RCOG) classify perineal tears as follows:

- First-degree tear: Injury to perineal skin and/or vaginal mucosa

JAYPEE BROTHERS

MRCOG Part 1:
400 SBAs

THIRD EDITION

MRCOG Part 1: 400 SBAs, Third Edition builds on the success of the previous editions, ensuring its place as a 'must have' revision text for those preparing for the MRCOG Part 1 computer-based test.

With 400 single best answers (SBAs) covering the basic and clinical science key to passing the MRCOG Part 1 examination, this edition includes more clinical images than ever before and features updated clinical guidance together with numerous new questions to aid candidates with their preparation.

- Comprehensive guidance on how to approach the examination and how to maximise your revision
- 400 SBAs reflecting the current examination format, covering the broad subject base of the examination curriculum
- New material accurately reflects the question style of the examination
- Every question has an in-depth answer to help consolidate learning
- Includes two complete 'Mock Papers' to allow you to practise and refine your examination technique

JP medical publishers

www.jpmedpub.com

ISBN 978-1-78779-163-3