nation on obstetrics and gynecology books, visit our website www.jaypeebrothers.com, for detailed information on obstetrics and gynecology books, visit our website www.jaypeebrothers.com







Aesthetic Regenerative and Cosmetic Gynecology

Editor
Preeti Jindal

Contents

1. **Aesthetic and Regenerative Gynecology: An Overview** 1
   Preeti Jindal
2. **Tracing the History of Aesthetic Gynecology** 4
   Tanuja Uchil
3. **The Mechanisms of Aging** 10
   Narendra Malhotra, Neharika Malhotra, Jaideep Malhotra, Keshav Malhotra, Gurkiran Kaur
4. **Anatomy and Physiology: In Relation to Aesthetic and Regenerative Gynecology** 21
   Prerna Keshan
5. **Counseling and Consenting in Cosmetic Gynecology** 27
   Bela Shah Jain, Naval Milind Shah
6. **Laser and Its Role in Aesthetic and Regenerative Gynecology** 31
   Preeti Jindal, Vivek Malhotra, Cherry Malhi
7. **Diode Laser in Cosmetic Gynecology** 34
   Molina Patel, Nayana Patel, Niket Patel
8. **Radio Frequency in Cosmetic Gynecology** 38
   Shradha Goel
9. **High Intensity Focused Ultrasound** 43
   Rachana Kaveri
10. **High Intensity Focused Electromagnetic Technology** 48
    Preeti Jindal, Ridhi Kalra
11. **Carboxy Therapy in Cosmetic Gynecology** 52
    Poonam Mishra
12. **Intimate Thread Lifting** 54
    Doaa Saleh, Salwa Bahkali
13. **Liposuction and Its Use in Cosmetic Gynecology** 60
    Mohan Thomas, James Dsilva
14. **Botulinum Toxin for Vaginismus** 70
    Ayman El Attar
15. **Genitourinary Syndrome of Menopause: Novel Treatment Modalities** 78
    Ragini Agrawal

16. **Labiaplasty and Clitoroplasty: A Comprehensive Review** 84
Preeti Jindal, Pragati Tandon

17. **Female Orgasmic Disorder and Treatment** 93
Kanika Singh

18. **Vulvodynia and Vaginismus** 96
Shahad Saeed Alzaabi, Amel Ibrahim Almaeeni

19. **Cosmetic Breast Surgery in Gynecology** 107
Mohan Thomas, James Dsilva

20. **Overactive Bladder Syndrome** 115
Indranil Banerjee, Ami Shukla

21. **Body Dysmorphic Disorder and Its Implications in Cosmetic Gynecology** 128
Manvi Verma

22. **Platelet-rich Plasma for Ovarian Rejuvenation** 132
Preeti Jindal, Sumitu Sahdev, Muskaan Mittal

23. **Dermatological Changes in Pregnancy** 137
Nutan Upadhaya

24. **Sexual Pain in Women** 144
Anita Shyam, AV Raveendran, Avinash Desousa

25. **Understanding Varicose Veins: Causes, Management, and Complications** 155
Ravul Jindal, Piyush Chaudhary, Muneer Ahmad Para, Taranvir Kaur, Shabjot Dhillon

26. **The Anatomy of a Smile: An Introduction to the Art and Science of Teeth Brightening** 161
Shivani Jain, Gauri Sachdeva

27. **Designer Smiles** 170
Renu Datta, Tarika Datta

28. **Anesthesia for Cosmetic Gynecological Procedures** 178
Jasmeet Kaur, Akashdeep Singh

29. **Extraperitoneal Laser Applications** 181
Preeti Jindal, Cherry Malhi

Index *187*

CHAPTER 4

Anatomy and Physiology: In Relation to Aesthetic and Regenerative Gynecology

Prerna Keshan

JAYPEE BROTHERS

INTRODUCTION

A thorough knowledge of the anatomy and physiology of the vulvovaginal complex is a must to understand the physiology of aging and the anatomical changes associated with the same. Aesthetic, functional, and regenerative gynecology call for an in-depth dive into the very basics of the anatomical and physiological preview of the female genitalia. The motive of this chapter is to enhance the basics of functional anatomy for all clinicians delving into this field of aesthetics.

VULVOVAGINAL COMPLEX

The vulvovaginal complex **(Fig. 1)** classically comprises in a sequential manner of the following structures:

- The upper most part is called the mons pubis which is also known as the "Venus Mount".
- Thereafter, it is the clitoral hood underneath which lies the most sensitive organ of sexual arousal—the clitoris.
- Bilaterally, there are two pads of fat tissue known as the "labium majus".

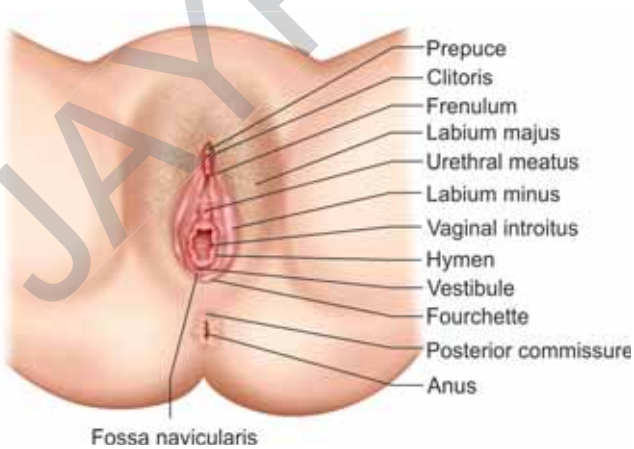

Fig. 1: Vulvovaginal complex.

- Besides the labium majus, bilaterally there lies the two thin leaf-like structures called the "labia minora".
  1. Hymen
  2. Vestibule
- At the central alignment below the clitoral body, there lies the urethral meatus.
- Bilaterally, there are the two Bartholin's glands, they are also known as the "greater vestibular glands".
- Beside the Bartholin's glands, there lie the minor vestibular glands which are of not much functional significance.
- The glands lying alongside the urethra are known as the "paraurethral glands".
- Vagina

Mons Pubis

Gross anatomy—under the bony prominence of the symphysis pubis lies this dense pad of fat which serves as a protective cushion. This mound is a triangle in shape and comprises adipose connective tissue in the subcutaneous strata.

Changes

- The mons pubis is subjective to alter during various phases of aging. It becomes considerably less elevated with the onset of menopause. On the contrary, it becomes more elevated during the onset of puberty. This mound also alters with weight gain and significant weight loss wherein the elevation can increase or decrease respectively.
- Coarse and thick hair cover the pubic mound which is also called the "escutcheon". This escutcheon has the tendency to decrease as age advances more so during the postmenopausal phase of life.
- It is of utmost importance to understand that the deviance of the degree of angulation of the pubic rami also determines the elevation of the mons pubis. This is in addition to the amount of adipose connective tissue in the mons pubis.

Labium Majus

- Starting from the pubic mound anteriorly and extending uptill the perineal body, the two labium majus runs bilaterally as pad of dense skin folds. Posteriorly, there lies the commissure which is of great functional and applied anatomical significance.
- The exterior part of the outer lips (labia majora) bilaterally is covered with hair and the interior portion comprises abundant apocrine and eccrine sweat glands lacking hair.
- It is covered by squamous epithelium.
- Both the outer lips comprise dense subcutaneous tissue and fibrofatty tissue. The labia majora are highly vascular with intricate supply of veins.
- Labia majora do not consist any macular tissue.

Changes

The variations in the labia majora extend in the following manner—they can be full/tight/lax/baggy. The documentation per se can be labeled to be empty or redundant labia.

Labia Minora

- These are the two leaf-like thin structures running alongside the labium majus medially and bilaterally.
- At the upper end of the labia minora there is a division into two lamellae, the frenulum of the clitoris is formed by the inferior portion whereas the superior portion runs into the prepuce.
- In the most inferior part, it is the fourchette which is formed by the fusion at the central alignment.

Structurally

- The labia minora are composed of connective tissue with many vessels, elastin fibers, and some smooth muscle fibers.
- There are numerous sweat glands in labia minora, but they are devoid of any hair cuticles.
- The labia minora bilaterally have loose connective tissue thereby imparting free cutaneous movement during the act of coitus.

Hart Line of the Labia Minora (Fig. 2)

- This is a linear demarcation of the outer aspect of the interior portion of the labia minora in which the epithelium is stratified squamous.

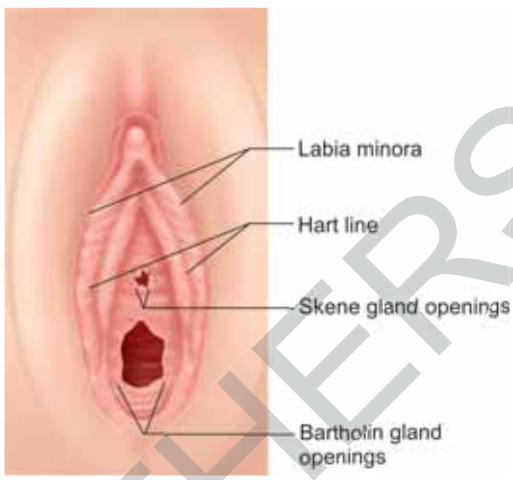

Fig. 2: Hart line of the labia minora.

- On the medial aspect of the Hart line, each labium has nonkeratinized squamous epithelium.

Variations

- A well-defined deep sulcus separates the labia majora from the labia minora. However in few subjects, it is seen that occasionally the sulcus has tendinous segmental insertions and sometimes it is even not seen. This leads to an ill-defined separation between the outer and the inner lips.
- Appearance and shape of the labia minora has many anatomic variations, asymmetrics being the most common.
- The skin quality may vary from tight to loose and rugose.

Clitoris (Fig. 3)

- It is the principal female erogenous organ. At the upper end, the clitoris is situated beneath the hood of the clitoris. This arrangement can however vary widely. This particular knowledge of the wide variation in the shape and size of the clitoral hood has significant applied anatomical value in the practice of aesthetics.
- The entire clitoris is not what it looks like from the exterior. The internal structure is homologous to the male penis and comprises the following—the glans clitoris, the body of the clitoris, and bilaterally the crura.

Glans Clitoris

- The glans clitoris comprises a magnanimous nerve supply which is the basis of its being the most sensitive structure for human sexual arousal reflex.

JAYPEE BROTHERS

- Usually the hood of the clitoris merges with the upper part of the labia minora.

Variations

- Clitoral hood may be small. In this, the frenulum continues with the labia minora.

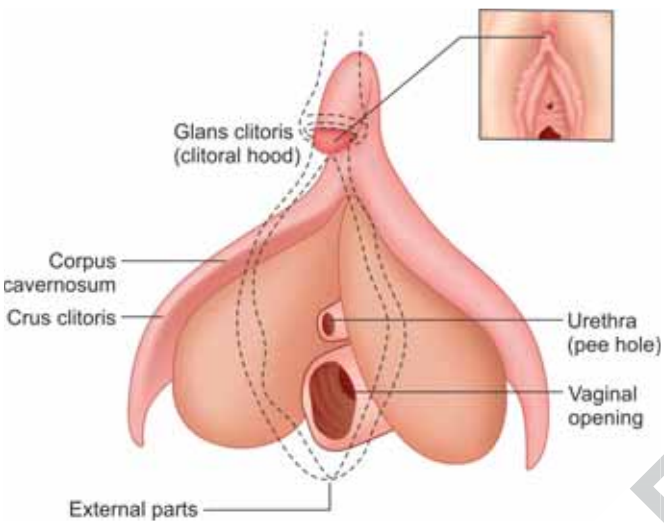

Fig. 3: The clitoris: Inside the body.

- Clitoral hood may be heavy.
- At times the clitoris is laterally divided and that looks like a double-folded clitoris at the lateral end.
- There may also be the presence of many folds in the clitoris laterally rather than only two.
- An important structural change of applied aesthetic significance is that the body of the clitoris which is bigger in size has a much heavier covering hood. Clitoral hood reduction surgery is a very commonly done surgery in this field of aesthetic and functional gynecology.

Body of the Clitoris

- From the hood of the clitoris bilaterally radiates the corpora cavernosa.
- The divergence bilaterally from the clitoral body creates a narrow area called crura.

VASCULAR ANATOMY (FIG. 4)

- Beneath the perineal membrane there lies the internal pudendal artery. The parent arterial supply is from this internal pudendal artery. The outer and the inner

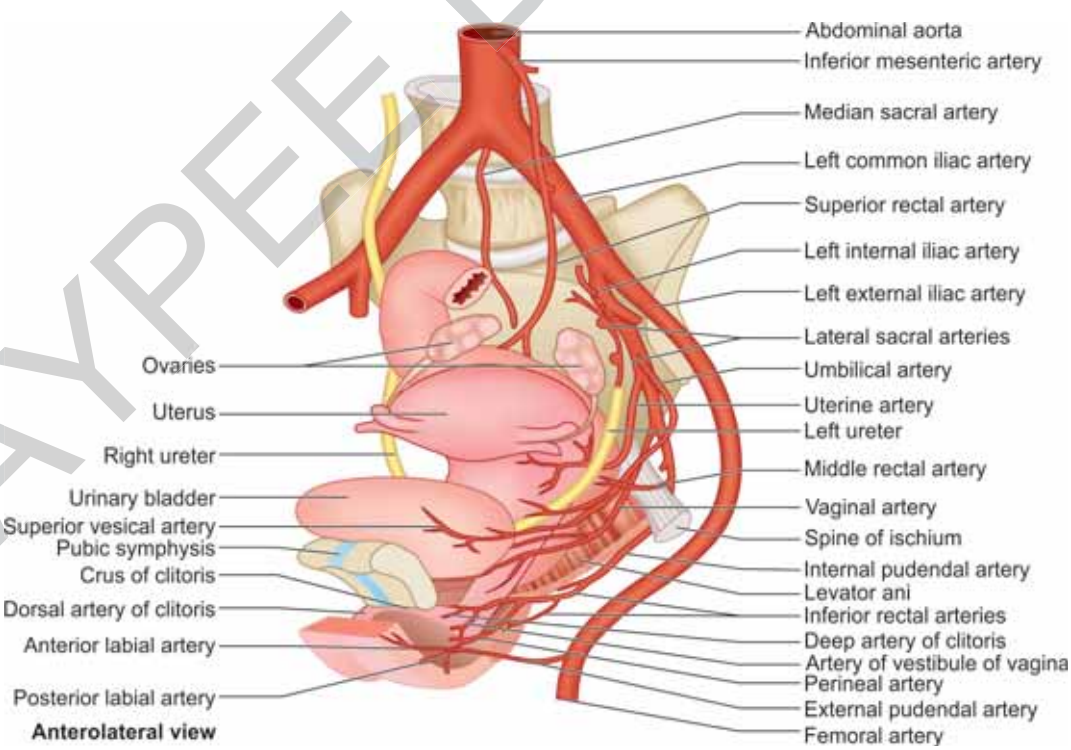

Fig. 4: Vascular anatomy.

JAYPEE BROTHERS

lips have the vascular supply from the posterior labial artery and the perineal artery respectively.

- The clitoris and its entire length is supplied by the dorsal artery of clitoris.
- Georgiou et al. have reported the following in the vascular supply of the vulvovaginal complex. There is one artery that is dominant and is identified at the center, two arteries coming from the posterior end and one small artery at the anterior end.

Nerve Supply (Fig. 5)

- The primary nerve supply of the vulvovaginal complex is via the pudendal nerve.
- The branches of the pudendal nerve namely the superficial and the deep perineal nerves supply the entire extent starting at the juncture of the superficial perineal muscle.
- Later in its course, the posterior labial nerve arises from the superficial branch and the dorsal nerve to the clitoris arises from the deep branch of the perineal nerves.

Vestibule (Fig. 6)

- The boundaries of the vestibule comprises the following structures—on the lateral aspect is the Hart line, on the medial aspect is the outer surface of the hymen, on the anterior aspect is the frenulum of the clitoris, and on the posterior aspect is the juncture of the fourchette. This gives an almond shape to the vestibular area.
- There are six openings which perforate the vestibule namely the urethral meatus, the vagina, bilaterally the vestibular gland ducts, and the glands of Skene.
- The area between the fourchette and the vagina is termed as the fossa navicularis which lies at the most posterior aspect of the vestibule.

Vaginal Opening and the Hymen

- The most important organ of the external genitalia is the vaginal opening which is located at the posterior most aspect of the vestibule.
- The distal end of the vagina is lined with the hymen or at times only the hymenal remnants. This knowledge has a huge implication in applied aesthetic anatomy for procedures like hymenoplasty.
- Vagina comprises both collagenous and elastic connective tissues. This knowledge is of importance in aesthetic procedures as maximum vaginal rejuvenative procedures are based on collagen remodeling and neovascularization. The epithelial lining is of stratified squamous type in both the inner and outer aspects of the vaginal wall.

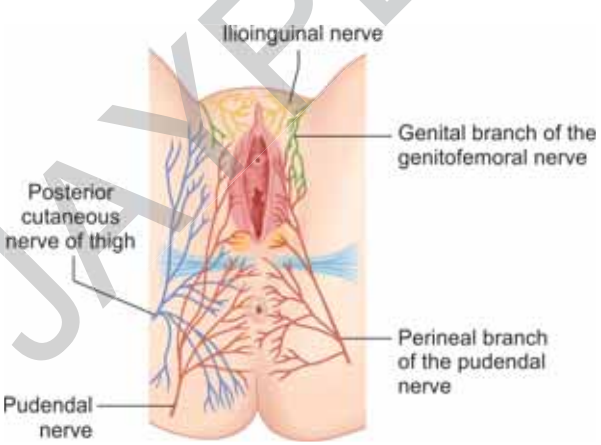

Fig. 5: Nerve supply.

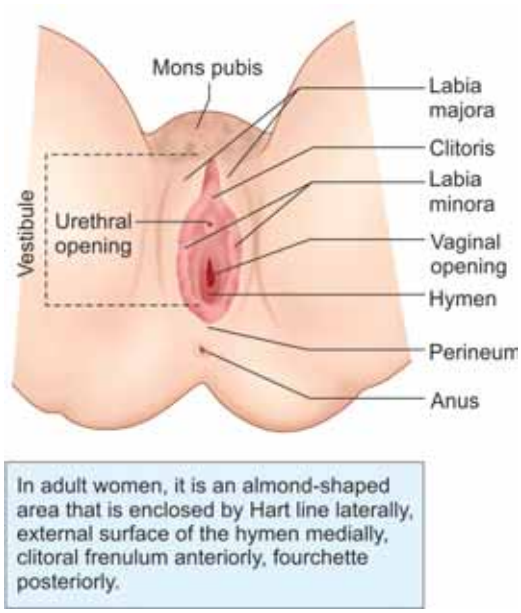

Fig. 6: Vestibule.

JAYPEE BROTHERS

Various Types of Hymen (Fig. 7)

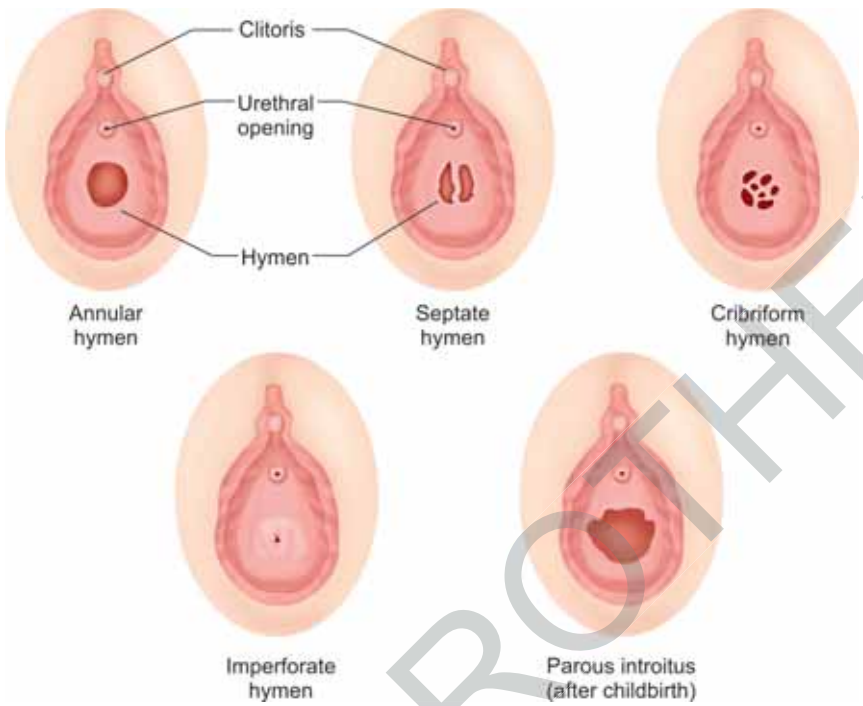

Fig. 7: Various types of hymens.

Vagina

- The lining of the vagina has a weak inner coat of circular fibers and a stronger outer longitudinal fiber coat.
- Vaginal pH is strongly acidic; pH is 4–5, due to Döderlein's bacillus.

Changes

- The characteristics of the vagina change during intercourse, throughout menstrual cycle, pregnancy, and with age.
- With increasing age the walls become lax and dry due to estrogen deficiency.

CLASSIFICATION OF FEMALE GENITAL ANATOMY FOR AID IN AESTHETIC AND REGENERATIVE PROCEDURES

For better understanding of the variation in the labial anatomy and correction of the same in required population, Motakef classified the degree of labial (labia minora) protrusion.[1] This classification is based on the length of the labia minora that extends beyond the anterior aspect of the labia majora. Based on this, the following are the degrees of labial (labia minora) protrusions. This knowledge is of utmost importance for all practicing aesthetic gynecologists because labioplasty is one of the most commonly done procedures in this field and it requires an apt knowledge of the degree of protrusion because undercorrection is always better than overcorrection in cases of hanging labia or labial hypertrophies. Labial hypertrophies may act as hindrance in pleasurable coitus as well as other cosmetic and functional issues revolving around the vagina.[2]

- *Class I:* 0–2 cm
- *Class II:* 2–4 cm
- *Class III:* More than 4 cm

Later, FRANCO AND FRANCO 8 in 1993, also classified labia minora hypertrophy into various types:

- Less than 2 cm enlargement is termed as type I hypertrophy.
- 2–4 cm enlargement is termed as type II hypertrophy.
- 4–6 cm enlargement is termed as type III hypertrophy.
- More than 6 cm enlargement is termed as type IV hypertrophy.

Later based on the position of enlargement of the labia minora in its length depending on whether there upper, middle or lower third enlargement, Banwell classified labia minora hypertrophy as the following:

- Enlargement of the upper one-third of the labia minora is termed as type I hypertrophy.

JAYPEE BROTHERS

- Enlargement of the middle one-third of the labia minora is termed as the type II hypertrophy.
- Enlargement of the lower one-third of the labia minora is termed as the type III hypertrophy.

This classification further includes symmetrical or asymmetrical hypertrophy depending on the symmetry of enlargement of the labia minora beyond the labia majora.

The takeoff between the labia minora and the perineum is also known as the labial perineal takeoff.

This emphasizes upon the distance between the posterior attachment of the labia minora and the perineum. This measurement can vary through a wide range and its proximity to the perineum can be classified as the following:

- If the posterior attachment of the labia is closest to the perineum, it is called *low* "labial perineal takeoff".
- If the posterior attachment of the labia is little farther from the perineum, it is called *medium* "labial perineal takeoff".
- If the posterior attachment of the labia is very far from the perineum, it is called *high* "labial perineal takeoff".

The aesthetic and functional implication of the low perineal takeoff is that it might be connected to the posterior fourchette, the knowledge of which is important for labioplasty procedures.

In addition to this, there may also be asymmetrical perineal takeoff.

Clitoral Labial Complex

- The clitoral labial complex is subjected to a wide variety of anatomic differences.
- Traditionally, the body of the clitoris and the clitoral hood should be small.
- The body of the clitoris and the hood might be hyperplastic and even disproportionate to the labia minora.
- There can be a vestigial clitoral hood, the significance of which is very pertinent in aesthetic procedure commonly done that is clitoral hood reduction.

Sexual Response Cycle

Understanding of the sexual response cycle is of importance to understand the changes associated with it to further treat functional and anatomic aberrancies of the same. It is divided into four phases:

1. Excitement or the arousal phase
2. Plateau phase
3. Orgasm
4. Resolution phase

Aesthetic Ideals

- Ideally there is no standard anatomic appearance or standard aesthetic appearance of the female genitalia or the intimate organs.
- An individual's body has its own standard based on her functional and aesthetic requirements. The desirable appearance and improvement of functionality in terms of comfort and self-esteem is to be regarded as the basis of aesthetic ideal. Proportionate rectifications more preferably undercorrection than overcorrection is the mainstay of vulvovaginal aesthetic, functional, and regenerative gynecology.

Applied Anatomy

- Prior to aesthetic treatment of the female genitalia, a thorough anatomical knowledge of the standards and the wide anatomic variations of the vulval complex is a must.
- Careful documentation of the anatomy prior to aesthetic treatment is mandatory.

CONCLUSION

It is of paramount importance that a thorough anatomical and physiological knowledge should be considered the basis of any aesthetic management. With the wide range of normal anatomic variations it is the responsibility of the care provider to reassure a client about her physiological variations and the need of correction only when functional or aesthetic concern arises. Undercorrection is always better than overcorrection and that is possible only with the perfect eye to the vulvovaginal anatomy. The procedural learning curve associated with this stream of aesthetic, functional and regenerative gynecology may be short but in depth anatomical knowledge of the female genitalia is the very basic of a successful outcome of any treatment revolving around the very sensitive vulvovaginal and urogenital complex.

REFERENCES

1. Motakef S, Rodriguez-Feliz J, Chung MT, Ingargiola MJ, Wong VW, Patel A. Vaginal labiaplasty: current practices and a simplified classification system for labial protrusion. Plast Reconstr Surg. 2015;135(3):774-88.
2. Banwell PE. Anatomy and classification of the female genitalia: implications for surgical management. In: Hamori CA, Banwell PE, Alinsod R (Eds). Female Cosmetic Genital Surgery: Concepts, Classification, and Techniques. New York: Thieme Publishers; 2017. pp. 14-7.

JAYPEE BROTHERS

for detailed information on obstetrics and gynecology books, visit our website www.jaypeebrothers.com, for detailed information on obstetrics and gynecology books, visit our website www.jaypeeb

Aesthetic, Regenerative and Cosmetic Gynecology

Salient Features

- Comprehensive overview of cosmetic, aesthetic, and regenerative gynecology
- Surgical and nonsurgical procedures done in this field
- Latest developments in technology such as energy-based devices (EBDs), mesotherapy, carboxytherapy, platelet-rich plasma (PRP), etc., explained in details
- Medicolegal aspects and how to setup your aesthetic practice described in easy language.



Preeti Jindal MD DNB MRCOG (UK) FICOG is a Senior Gynecologist, practicing since the last 30 years. She is an in vitro fertilization (IVF) specialist, recurrent miscarriage expert, high-risk pregnancy expert, and robotic surgeon with special interest in cosmetic, aesthetic, and regenerative gynecology. She is the Director of The Touch Clinic, Mohali, and Senior Consultant Gynecologist, Fortis Hospital, Mohali, Punjab, India. She is one of the pioneers of aesthetic gynecology in India. She introduced high-intensity focus electromagnetic (HIFEM) chair (Emsella) for the first time in India. She opened the unique clinic for stress urinary incontinence (SUI) treatment by noninvasive methods such as energy-based devices and platelet-rich plasma. She is a core academician and has written many books for adolescents, pregnant mothers, and menopausal women. She founded Mohali Obstetrics and Gynaecology Society. She is a Founder Member and General Secretary of Indian Society of Aesthetic and Reconstructive Gynecology (INSARG) which was formed for spreading awareness in the field of cosmetic gynecology to every clinician. She does many academic courses for inspiring doctors in the field of cosmetic gynecology, IVF, and intracytoplasmic sperm injection (ICSI).

JP medical publishers

www.jpmedpub.com

ISBN 978-1-78779-184-8

9 781787 791848