

HANDBOOK OF ENDOMETRIAL PATHOLOGY

Debra S Heller

Handbook of

Endometrial Pathology

JAYPEE BROTHERS

Debra S Heller
Professor of Pathology and Laboratory Medicine
Joint Professor of Obstetrics, Gynecology and Women's Health
University of Medicine and Dentistry of New Jersey, Newark, USA

JP medical publishers

London • Panama City • New Delhi

Contents

Preface		v
Abbreviations		x
Chapter 1	**Interpreting pathology results – the value of communication**	1
	Introduction	1
	Some gynecology for the pathologist	1
	Some pathology for the clinician	3
Chapter 2	**The normal endometrial cycle**	13
	Menstrual/early proliferative endometrium (day 1–5)	13
	Mid- to late proliferative endometrium (days 6–14)	16
	Interval endometrium (day 15–16, postovulatory day (POD) 2–3)	20
	Secretory endometrium (day 17–28, POD 4–14)	20
	Atrophic endometrium	25
	Luteal phase defects	25
Chapter 3	**Pregnancy-related findings in normal and abnormal pregnancies**	29
	First trimester intrauterine products of conception	29
	Endometrium associated with ectopic pregnancy	37
	Third trimester endometrial findings	37
	Gestational trophoblastic neoplasia (GTN)	39
	Trophoblastic lesions that may be confused with GTN	48
	Persistent gestational trophoblastic disease	49

JAYPEE BROTHERS

Chapter 4	**Organic lesions of the endometrium**	53
	Endometrial polyps	53
	Endometritis	58
	Leiomyomas	64
	Adenomyosis	64
	Atrophy	65
Chapter 5	**Hormonally related abnormal uterine bleeding: dysfunctional uterine bleeding and exogenous hormone effects**	69
	Dysfunctional uterine bleeding	69
	Exogenous hormonal causes of bleeding	72
Chapter 6	**Endometrial hyperplasia and preinvasive disease**	81
	Precursors of type 1 endometrioid adenocarcinoma	81
	Precursors of type 2 uterine serous carcinoma	90
	Superimposed therapeutic effects on endometrial hyperplasia	90
Chapter 7	**Endometrial malignancies**	95
	Biologic and molecular classification	95
	Histopathologic classification of endometrial carcinoma	95
	Mixed epithelial and mesenchymal malignancies	112
	Sarcomas of the uterus	114
	Metastatic carcinoma	118
	Problems with artifacts	120
Chapter 8	**Pitfalls in diagnosis**	123
	Artifacts	123
	Metaplasias	133
	Lack of history	140

JAYPEE BROTHERS

Chapter 9	**Molecular aspects of endometrial disease**	147
	Molecular mechanisms of endometrial disease	147
	Mechanism of bleeding	147
	Mechanisms of carcinogenesis	147
	New diagnostic techniques	149
Appendix	**Glossary of terms**	153
Index		155

JAYPEE BROTHERS

6 Endometrial hyperplasia and preinvasive disease

- Precursors of type 1 endometrioid adenocarcinoma: page 81
- Precursors of type 2 uterine serous carcinoma: page 90
- Superimposed therapeutic effects on endometrial hyperplasia: page 90

There are two different terminologies currently in use for endometrial hyperplasia. The World Health Organization (WHO) terminology, which is based on architectural complexity and degree of nuclear atypia, uses the diagnoses of simple hyperplasia, complex hyperplasia, and atypical hyperplasia. It is in widespread use, but has been shown to have poor reproducibility.[1,2] This lack of reproducibility, as well as a variety of more recent molecular insights, has led to a newer terminology, the endometrial intraepithelial neoplasia (EIN) terminology, which has its advocates as well as its opponents. It divides endometrium into categories of risk of developing carcinoma, using the term "endometrial hyperplasia" for lesions not thought to be at risk and "EIN" for those thought to be at risk. This chapter discusses both terminologies.

Precursors of type 1 endometrioid adenocarcinoma

Endometrial hyperplasia is seen in the setting of unopposed estrogenic stimulation, and is thought to be the precursor pathway for the type I estrogen-dependent endometrioid adenocarcinomas. There is reportedly a 5–10% overall risk of progression to endometrial carcinoma from hyperplasia.[3] There is, of course, a huge difference in potential risk between the lower risk lesions and the higher risk lesions, however where to make this distinction histopathologically is an ongoing area of diagnostic difficulty. Inconsistent prior terminologies (mild, moderate or severe hyperplasia, cystic or adenomatous hyperplasia) led to the 1994 WHO terminology, which reflects the significance of nuclear atypia as the main risk factor for carcinoma, demonstrated in an earlier study by Kurman et al.[4] That study had outcome data for women who did not have surgery for their hyperplasia for at least a year after diagnosis.[4]

WHO terminology

The WHO classification, which is in widespread usage, rests on the degree of glandular crowding (simple for less versus complex hyperplasia for more crowding) and the presence or absence of nuclear atypia (simple or complex hyperplasia either with or without atypia). The thinking behind this terminology is that nuclear atypia is the main feature indicating malignant potential, with a 29% risk of progression from atypical hyperplasia to carcinoma in the series reported by Kurman et al.[4]

JAYPEE BROTHERS

Simple hyperplasia without atypia (simple hyperplasia)

Simple hyperplasia is characterized by a mildly increased gland-to-stroma ratio. This is what distinguishes it from disordered proliferation, which also has occasionally cystic or outpouching glands but has no increase in gland-to-stroma ratio. In simple hyperplasia, the increased numbers of glands may show cystic dilatation or outpouchings ("rabbit ears"). The epithelium lining the glands is similar to that seen in proliferative endometrium, with oval nuclei without atypia. Mitotic activity is present (**Figures 6.1** and **6.2**).

A finding that should not be confused with simple hyperplasia is cystic atrophy (**Figure 6.3**). Cystic atrophy is a normal variant of atrophic endometrium, with flattened nonproliferating epithelium lining the cystic glands.

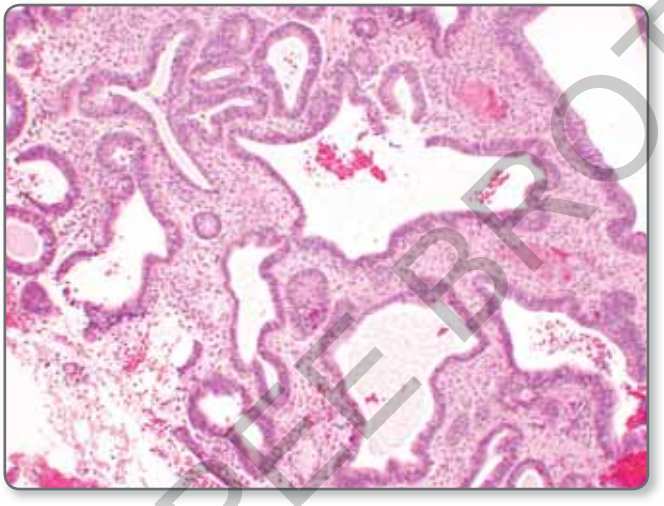

Figure 6.1 Simple hyperplasia, showing mild glandular crowding, with cystic dilatation and outpouchings of glands.

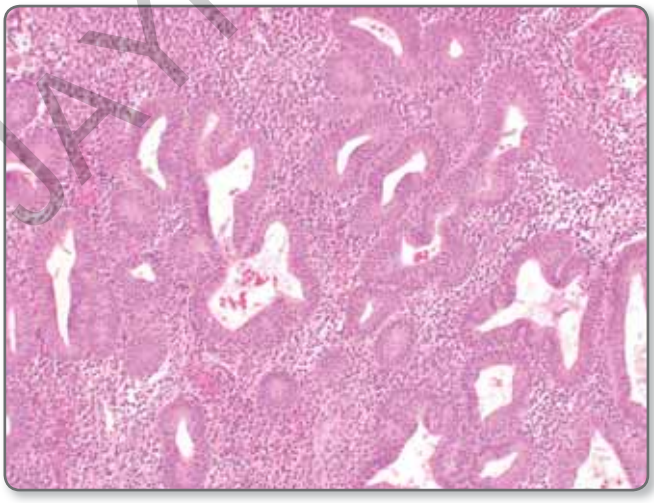

Figure 6.2 Simple hyperplasia. The epithelium is pseudostratified, with no nuclear atypia.

JAYPEE BROTHERS

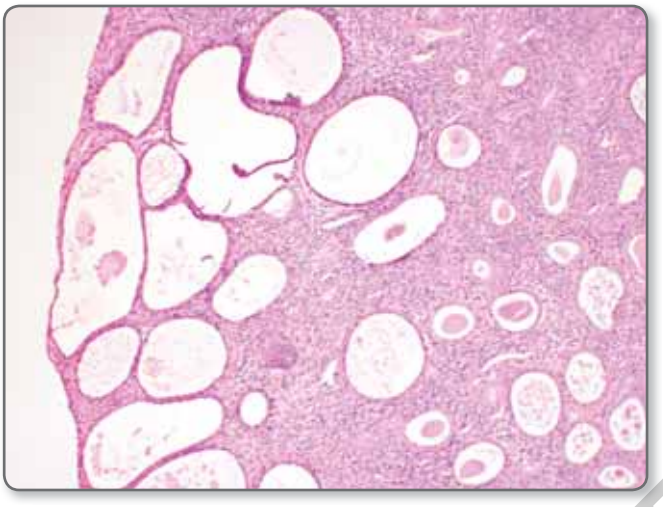

Figure 6.3 Cystic atrophy. Cystic glands show inactive epithelium.

Simple and other degrees of hyperplasia may also be noted within nests of adenomyosis, having no additional clinical significance beyond the diagnosis of hyperplasia of the lining (**Figure 6.4**).

The risk of simple hyperplasia progressing to carcinoma over 20 years in patients treated according to community standards was less than 5% in one study.[5] Simple hyperplasia is most often treated with progestational agents. Biopsies may be obtained as part of follow-up, and familiarity with superimposed progestational effect is important, particularly as a treatment history may not be provided (see p. 90).

Simple hyperplasia with atypia

Simple atypical hyperplasia is probably the least common pattern seen, and it is often not even mentioned in the classification, which is shortened to simple/complex/atypical. In simple hyperplasia with

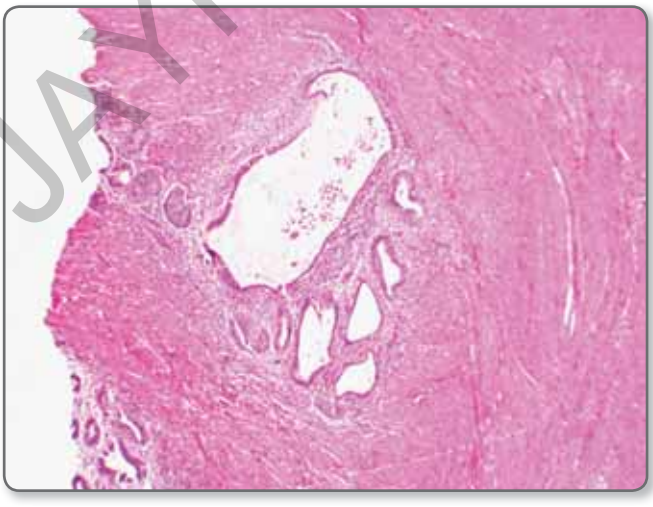

Figure 6.4 Simple hyperplasia within adenomyosis.

JAYPEE BROTHERS

atypia, the architecture is the same as in simple nonatypical hyperplasia, but nuclear atypia is present. Atypical nuclei are enlarged and round rather than oval, with margination of the chromatin and clearing of the nucleus. Nucleoli may be seen. Nuclear pleomorphism and loss of polarity may be seen as well (**Figures 6.5** and **6.6**). Progression to carcinoma was seen in 8% (one patient) in the series reported by Kurman et al,[4] but this diagnosis occurs too uncommonly to conduct large studies.

Complex hyperplasia without atypia (complex hyperplasia)

Complex hyperplasia shows a greater degree of glandular crowding than simple hyperplasia (**Figures 6.7–6.10**). A range of changes may be seen in a single specimen, including areas of less crowding or simple hyperplasia, and accompanying metaplasias are often present. In the

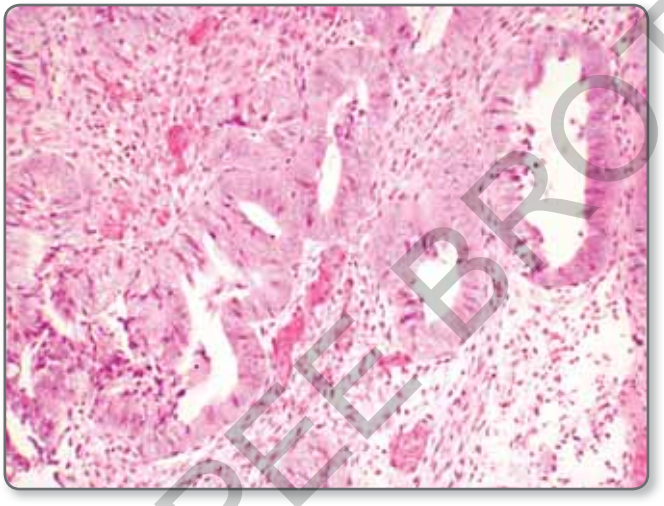

Figure 6.5 Simple hyperplasia with atypia. The architecture is only mildly crowded, but there is nuclear atypia.

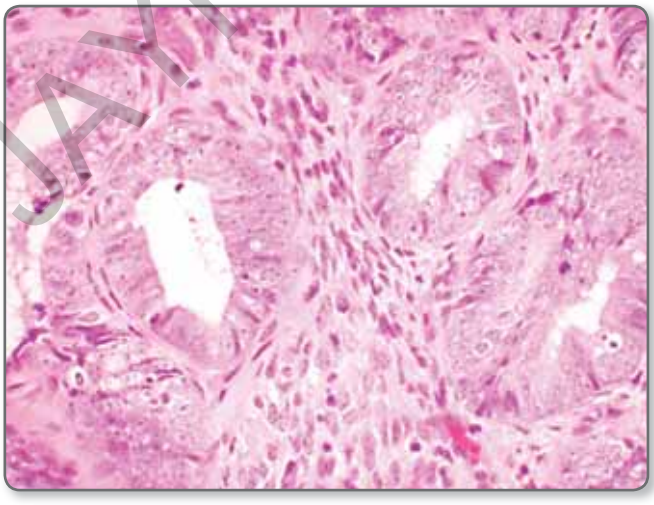

Figure 6.6 Simple hyperplasia with atypia. Nuclear atypia, with rounded nuclei, marginated chromatin with vesicular nuclei, with nucleoli seen.

JAYPEE BROTHERS

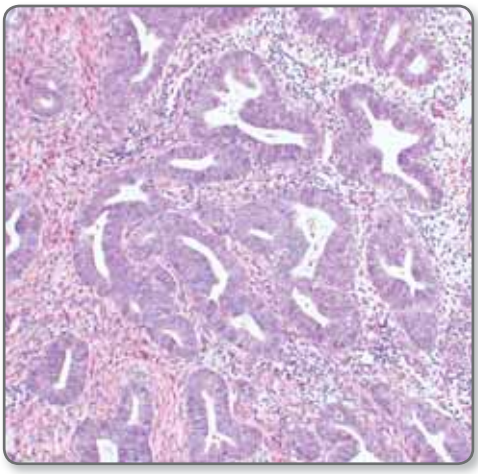

Figure 6.7 Complex hyperplasia showing increased gland-to-stromal ratio; however, stroma still intervenes.

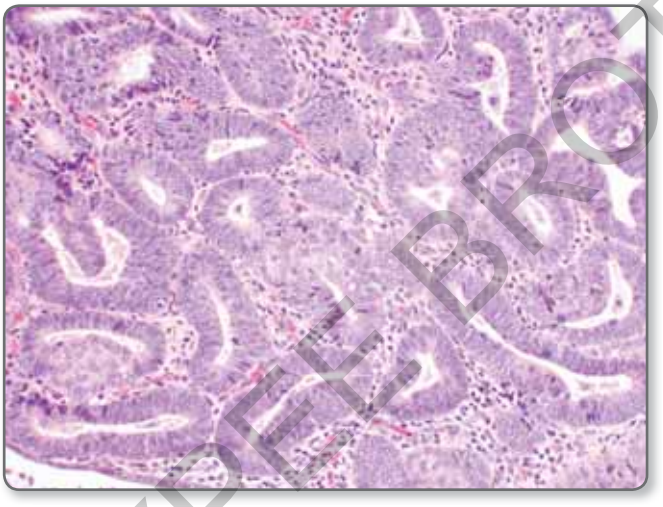

Figure 6.8 Complex hyperplasia showing increased gland-to-stromal ratio; however, stroma still intervenes.

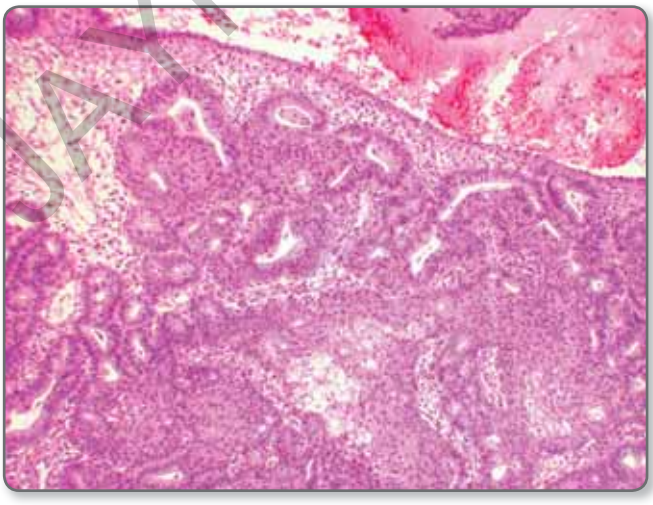

Figure 6.9 Complex hyperplasia with squamous metaplasia making the lesion appear more solid.

JAYPEE BROTHERS

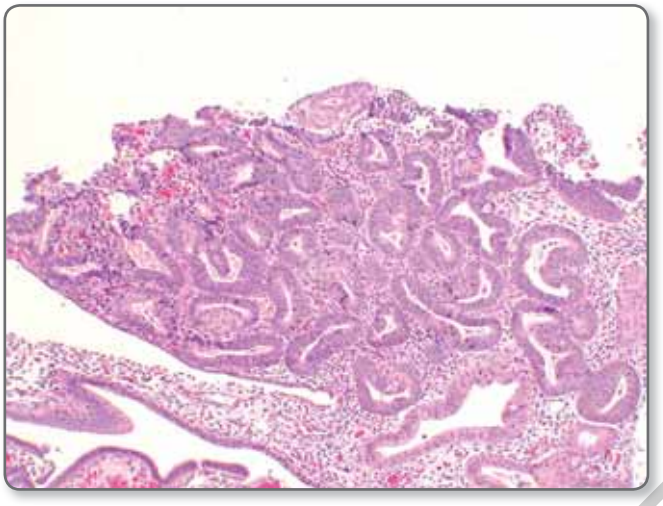

Figure 6.10 Range of types of hyperplasia, from simple on the bottom, to complex on the top. Squamous metaplasia is also seen.

absence of nuclear atypia, the risk of carcinoma is still low, with a 3% risk in the series reported by Kurman et al,[4] and less than 5% in the study by Lacey et al.[5]

The presence of squamous metaplasia may make the distinction of complex hyperplasia from well-differentiated adenocarcinoma difficult, particularly if there is minimal nuclear atypia in the carcinoma. Carcinoma by definition shows stromal invasion, as evidenced by stromal response, cribriforming, possible papillary configurations, and large masses of squamous epithelium. The last three criteria must be at least 2.1 mm in size, according to the criteria in the 1982 report by Kurman and Norris.[6] Often many fields have to be examined to make the distinction. Although the terminology is not in widespread use, Mittal et al have called lesions less than 2.1 mm but otherwise meeting the Kurman & Norris criteria as "adenocarcinoma in situ", and have found a greater likelihood of carcinoma and myometrial invasion by the carcinoma, in subsequent hysterectomies, after a biopsy diagnosis of adenocarcinoma in situ as they defined it.[7]

Atypical hyperplasia (complex hyperplasia with atypia)

Complex hyperplasia with atypia, or atypical hyperplasia, combines significant glandular crowding with nuclear atypia (**Figures 6.11–6.14**); although glands are crowded, some stroma remains. It may be difficult to distinguish from carcinoma if there is extensive squamous metaplasia.

Atypical hyperplasia has a high risk of either progression to carcinoma or concomitant carcinoma being present at hysterectomy after a diagnosis of atypical hyperplasia on biopsy. While most studies have estimated a risk of approximately 25%, one recent study estimated as high as 45.9%. [8] This being so, hysterectomy remains the treatment

JAYPEE BROTHERS

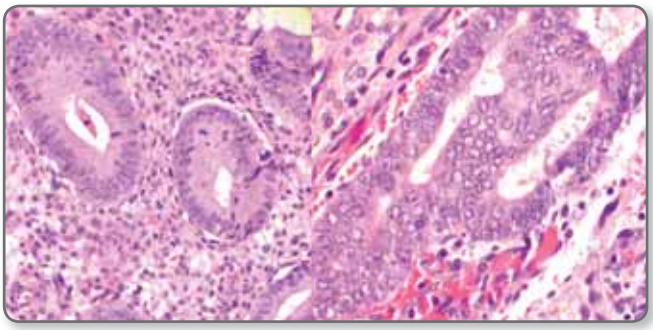

Figure 6.11 Nonatypical vs atypical nuclei. The nonatypical nuclei on the left are oval, with well-distributed chromatin. The larger rounder atypical nuclei on the right show vesiculation with margination of chromatin, loss of polarity, and occasional nucleoli.

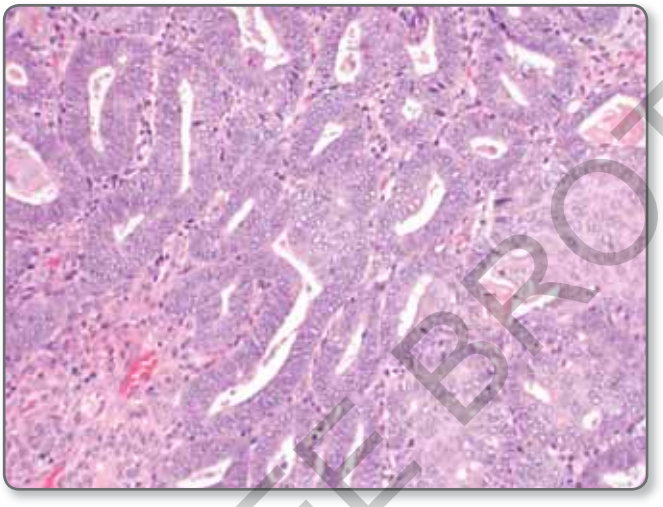

Figure 6.12 Atypical hyperplasia. Marked glandular crowding and nuclear atypia. Squamous metaplasia is also present.

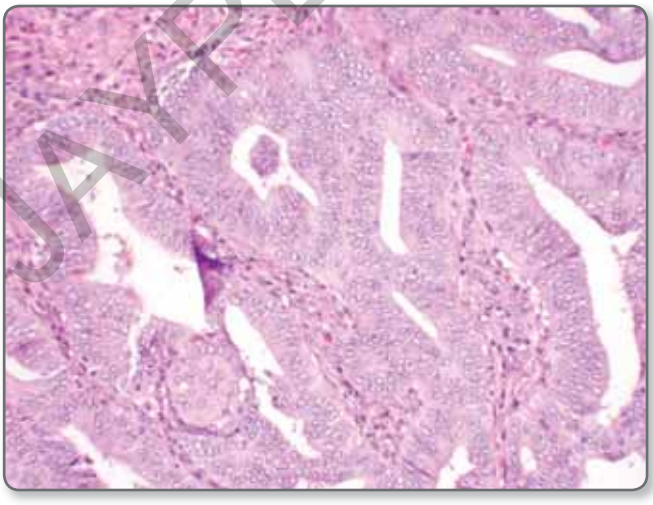

Figure 6.13 Atypical hyperplasia. Marked glandular crowding and nuclear atypia.

JAYPEE BROTHERS

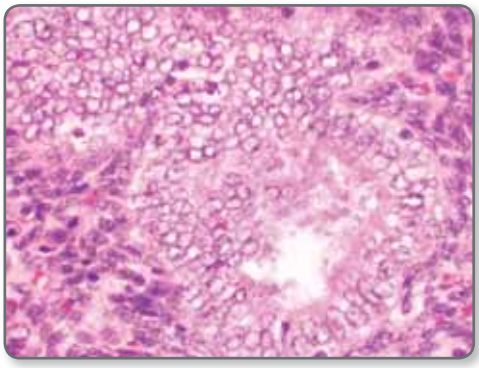

Figure 6.14 Atypical hyperplasia. Nuclei show marked vesiculation.

of choice for these lesions; however in extenuating circumstances, for example where medical therapy is chosen to preserve fertility, close follow-up is required. In a 20 year follow-up of patients, the risk associated with atypical hyperplasia progressing to carcinoma was one in eight at 10 years, and one in three at 20 years.[5]

EIN (endometrial intraepithelial neoplasia) terminology

The more recent EIN terminology was devised to incorporate genetic aspects of endometrial carcinogenesis as well as clinicopathologic aspects. While the original studies were performed morphometrically, the classification made available by Mutter and colleagues[3,11,13] for routine use is based on histology, and has been embraced by some as a more accurate way of predicting which lesions are at high risk of progressing to cancer.

While there does not seem to be major dispute that the WHO 94 classification is fraught with difficulty, the problem with the adoption of the EIN terminology on a widespread basis is concern that the original morphometric studies assigning risk do not reliably translate into day-to-day practice for the community pathologist. Most institutions would not find it practical to conduct morphometric diagnosis, due to cost and time restraints. There is also the issue of whether the H&E attempts at diagnosing EIN will be any more reproducible than WHO among working pathologists.[3,9] One study[10] suggested that in the hands of an experienced pathologist the WHO and EIN classifications have similar sensitivities and negative predictive values for coexistent endometrial cancer, but opined that the EIN system is more concrete, and hence may be preferable if an experienced pathologist is not available.[10] Sivridis et al[9] concluded that the EIN concept is impractical, but noted that both classifications focus on the recognition of cytologic atypia. Follow-up of at least 1 year in women with biopsy diagnosed atypical hyperplasia or EIN had similarly increased risks of progression to carcinoma in one study.[11] The debate continues, and at this juncture, both systems have their advocates.

In an attempt to educate pathologists on the use of the EIN system, Mutter and colleagues have set up a website with tutorials

JAYPEE BROTHERS

(www.endometrium.org). In an editorial on whether or not it is time to make the leap to this classification, Zaino has stated that this educational site is valuable in that in order to be useful, the terminology needs to be reproducible at the community pathologist level.[12] The terminology of the EIN classification is

- benign hyperplasia,
- EIN, and
- carcinoma.

Benign hyperplasia

Benign hyperplasia is defined as a polyclonal diffuse process which is hormonally dependent and not considered to be a significant risk for progressing to carcinoma.[3] It is thought of as a reactive process amenable to hormonal therapy.

EIN

EIN is a monoclonal proliferation, initially localized, which can progress to a more diffuse distribution. It is a neoplastic proliferation.[3] The morphologic correlate of the morphometric EIN (based on a D-score) is defined predominantly by the volume percent stroma (VPS). Lesions with less than 55% VPS are often monoclonal and thus may represent EIN, while lesions with over 55% VPS are usually polyclonal[3] and hence represent endometrial hyperplasia. While phosphatase and tensin homolog (PTEN) inactivation (and immunonegativity), is the molecular pathway of endometrioid carcinoma, and is seen in two-thirds of cases of EIN, it often precedes any recognizable histologic changes, and is often focally present in normal endometrium, as well as being present in some EIN cases, making it a very nonspecific test.[3] The other criteria for the histologic diagnosis of EIN besides VPS less than 55% are that in the same lesional area the cytology of the crowded focus differs from the background, the maximum linear aspect of the lesion exceeds 1 mm, and benign mimics and cancer have been ruled out.[3] Applying EIN criteria was felt to outperform the WHO classification, and it showed good interobserver agreement between three gynecologic pathologists in one study.[13] EIN is thought to be best treated with hysterectomy, however hormonal therapy with follow-up is an option (**Figure 6.15**).

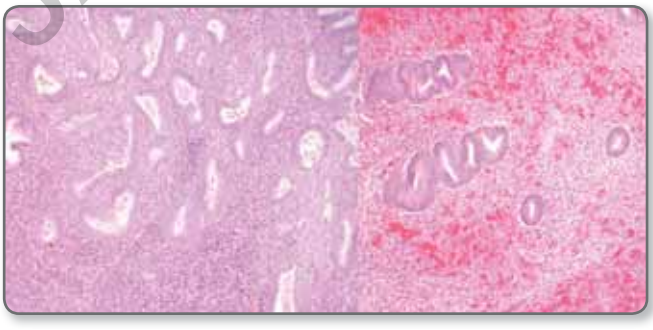

Figure 6.15 Intraepithelial neoplasia (EIN). Both fields are from the same biopsy. The focus of EIN on the left was present in a biopsy dominated by the proliferative endometrium on the right.

JAYPEE BROTHERS

Precursors of type 2 uterine serous carcinoma

Endometrial intraepithelial carcinoma (EIC)

EIC had originally been thought to be the precursor lesion of serous adenocarcinoma of the endometrium, often seen in association with invasive serous carcinoma.[14] However, more recently some authors have stated that EIC actually represents early serous carcinoma, since it doesn't behave as a precancer. EIC is defined as cells identical to serous carcinoma, arising on the surface of the endometrium and devoid of stromal or myometrial invasion (**Figure 6.16a**). However, as extrauterine disease is the major prognostic factor for these early lesions, and disseminated disease has been found with EIC, Wheeler et al now call EIC "minimal uterine serous carcinoma" and combine it with serous carcinomas measuring ≤ 1 cm.[15]

Proposed as a better candidate precursor lesion for serous carcinoma is an entity called "endometrial glandular dysplasia",[16] which shows a p53 staining pattern and Ki-67 index intermediate between normal endometrium (p53 negative and Ki-67 low) and EIC (p53 staining strong and diffusely present, and Ki-67 index elevated), and has a lesser degree of nuclear atypia.[17] It is a surface lesion, often only occupying a gland or two, and it may have some papillary or cribriform architecture, and some nuclear atypia with loss of polarity and presence of nucleoli, but less than EIC. As such, this may be a difficult lesion to diagnose (**Figure 6.16b** and **c**). This lesion has been found in retrospective biopsy material from serous carcinomas, consistent with a precursor lesion.[18]

Superimposed therapeutic effects on endometrial hyperplasia

Secretory hyperplasia, the presence of secretory glands in a crowded configuration with markedly increased gland-to-stromal ratio, is thought to be a transient progestational effect on hyperplasia, either endogenously from ovulation, or exogenously (**Figure 6.17**)

Progestin effect on hyperplasia may show the remnants of the architecture, with inactive or secretory glands in a decidualized stroma (**Figure 6.18**). In a study of treated atypical hyperplasia and well-differentiated carcinoma, Wheeler et al[19] noted decrease in the gland-to-stroma ratio, decreased or absent mitotic activity, and loss of atypia, and they confirmed that the architectural abnormalities persisted longer. Eosinophilic, secretory, squamous, and mucinous metaplasia were seen after therapy. In some cases, treatment induced papillary or cribriform architecture, mimicking progression.

JAYPEE BROTHERS

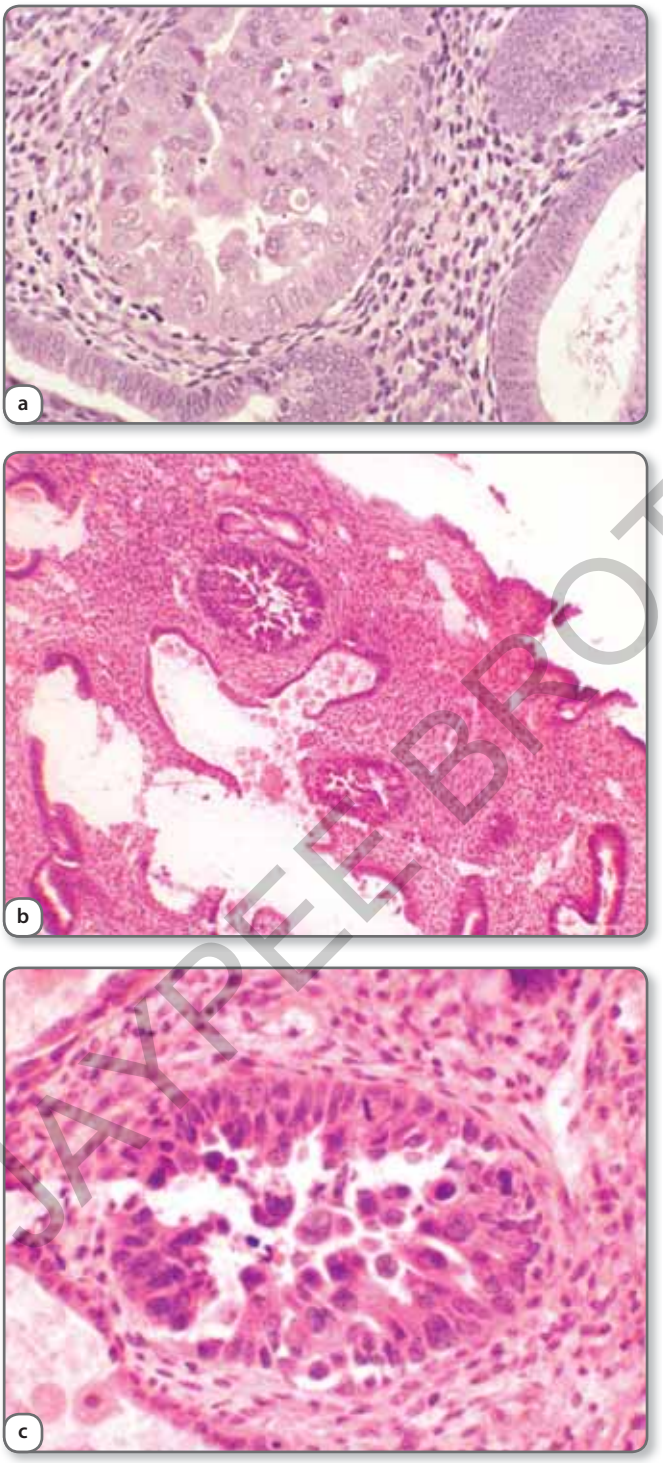

Figure 6.16 Endometrial intraepithelial carcinoma showing marked cytologic atypia. (a) Endometrial glandular dysplasia showing single dysplastic glands. (b) Admixed with nondysplastic glands, with cytologic atypia less than seen in EIC (c).

JAYPEE BROTHERS

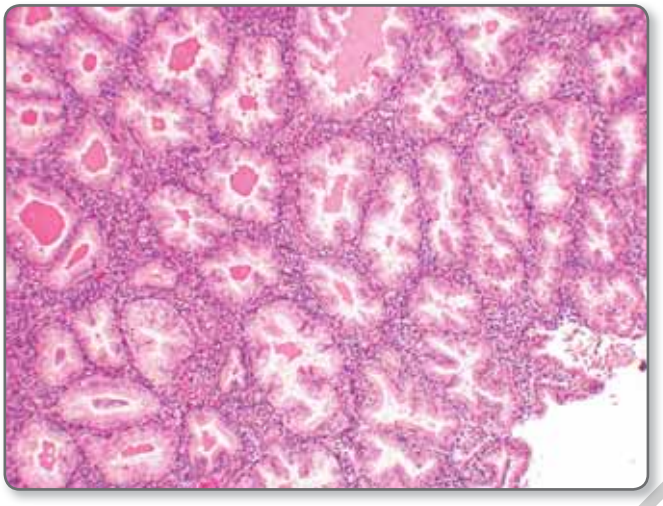

Figure 6.17 Secretory hyperplasia. There is marked crowding of secretory glands

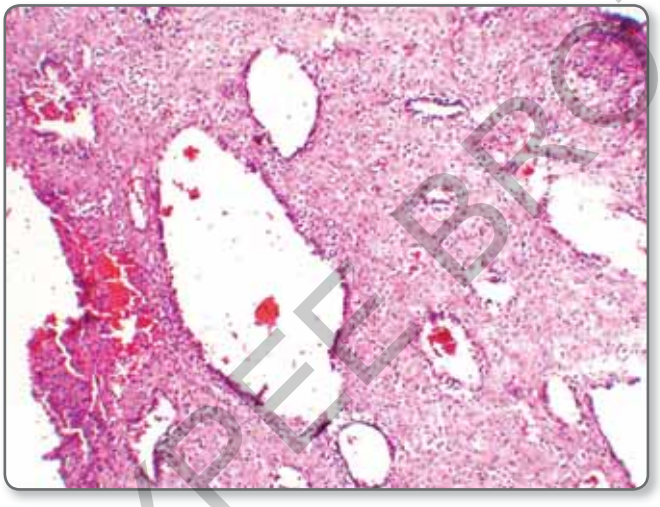

Figure 6.18 Simple hyperplasia after progesterone therapy, showing preservation of the architectural abnormality in a decidualized stroma.

JAYPEE BROTHERS

References

1. Allison KH, Reed SD, Voigt LF, Jordan CD, Newton KM, Garcia RL. Diagnosing endometrial hyperplasia: why is it so difficult to agree? Am J Surg Pathol 2008;32:691–98.
2. Sherman ME, Ronnett BM, Ioffe OB, Richesson DA, Rush BB, et al. Reproducibility of biopsy diagnoses of endometrial hyperplasia: evidence supporting a simplified classification. Int J Gynecol Pathol 2008;27:318–25.
3. Baak JP, Mutter GL. EIN and WHO94. J Clin Pathol 2005;58:1–6.
4. Kurman RJ, Kaminski PF, Norris HJ. The behavior of endometrial hyperplasia. A long-term study of "untreated" hyperplasia in 170 patients. Cancer 1985;56:403–12.
5. Lacey JV Jr, Sherman ME, Rush BB, Ronnett BM, Ioffe OB, Duggan MA, et. al. Absolute risk of endometrial carcinoma during 20-year follow-up among women with endometrial hyperplasia. J Clin Oncol 2010;28: 788–92.
6. Kurman RJ, Norris HJ. Evaluation of criteria for distinguishing atypical endometrial hyperplasia from well-differentiated carcinoma. Cancer 1982;49:2547–59.

7. Mittal K, Sebenik M, Irwin C, Yan Z, Popiolek D, et al. Presence of endometrial adenocarcinoma in situ in complex atypical endometrial hyperplasia is associated with increased incidence of endometrial carcinoma in subsequent hysterectomy. Mod Pathol 2009;22:37–42.
8. Pennant S, Manek S, Kehoe S. Endometrial atypical hyperplasia and subsequent diagnosis of endometrial cancer: a retrospective audit and literature review. J Obstet Gynaecol 2008;28:632–33.
9. Sivridis E, Giatromanolaki A. The endometrial hyperplasias revisited. Virchows Arch 2008;453:223–31.
10. Salman MC, Usubutun A, Boynukalin K, Yuce K. Comparison of WHO and endometrial intraepithelial neoplasia classifications in predicting the presence of coexistent malignancy in endometrial hyperplasia. J Gynecol Oncol 2010;21:97–101.
11. Lacey JV, Mutter GL, Nucci MR, Ronnett BM, Ioffe OB, et al. Risk of subsequent endometrial carcinoma associated with endometrial intraepithelial neoplasia (EIN) classification of endometrial biopsies. Cancer 2008;113:2073–81.
12. Zaino RJ. Endometrial hyperplasia: is it time for a quantum leap to a new classification? Int J Gynecol Pathol 2000;19:314–21.
13. Hecht JL, Ince TA, Baak JPA, Baker HE, Ogden MW, Mutter GL. Prediction of endometrial carcinoma by subjective EIN diagnosis. Mod Pathol 2005;18:324–30.
14. Ambros RA, Sherman ME, Zahn CM, Bitterman P, Kurman RJ. Endometrial intraepithelial carcinoma: a distinctive lesion specifically associated with tumors displaying serous differentiation. Hum Pathol 1995;26:1260–67.
15. Wheeler DT, Bell KA, Kurman RJ, Sherman ME. Minimal uterine serous carcinoma: diagnosis and clinicopathologic correlation. Am J Surg Pathol 2000;24:797–806.
16. Zheng W, Liang SX, Yu H, Rutherford T, Chambers SK, Schwartz PE. Endometrial glandular dysplasia: a newly defined precursor lesion of uterine papillary serous carcinoma. Part I: morphologic features. Int J Surg Pathol 2004;12:207–23.
17. Yi X, Zheng W. Endometrial glandular dysplasia and endometrial intraepithelial neoplasia.Curr Opin Obstet Gynecol 2008;20:20–25.
18. Zheng W, Liang SX, Yi X, Ulukus EC, Davis JR, Chambers SK. Occurrence of endometrial glandular dysplasia precedes uterine papillary serous carcinoma. Int J Gynecol Pathol 2007;26:38–52.
19. Wheeler T, Bristow RE, Kurman RJ. Histologic alterations in endometrial hyperplasia and well-differentiated carcinoma treated with progestins. Am J Surg Pathol 2007;31:988–98.

JAYPEE BROTHERS

HANDBOOK OF ENDOMETRIAL PATHOLOGY

Handbook of Endometrial Pathology is a practical, clinically oriented reference, detailed enough for pathologists yet with a clinical focus that ensures its relevance and appeal to gynecologists.

The book discusses the clinical aspects of evaluating the endometrium and describes the pathology of endometrial diseases. Differential diagnoses are included where appropriate. There is a chapter on the histologic pitfalls associated with diagnosis and a chapter that summarises the latest information on molecular mechanisms and immunohistochemical tests.

- Practical reference for the evaluation and diagnosis of endometrial disorders, for both gynaecologists and pathologists
- Clinically focussed, with practical guidance on avoiding diagnostic pitfalls
- Full color histopathology sections throughout

JP medical publishers
www.jpmedpub.com
ISBN 978-1-907816-10-9
9 781907 816109