

HANDBOOK OF COLORECTAL SURGERY

THIRD EDITION

David E Beck

Contents

Foreword to the third edition v
Foreword to the second edition vi
Preface vii
Contributors xiii

Section 1: Basic principles and skills

Chapter 1 **Anatomy** 3
Macroscopic anatomy 3
Vascular anatomy 8
Nervous supply 10
Bowel wall 11

Chapter 2 **Pathophysiology** 13
Colonic motility 13
Colonic motility disorders 15
Water and electrolyte transport 17
Bacterial barrier 19
Intestinal gas 19
Anorectal physiology 19
Defecation 24

Chapter 3 **History and physical examination** 29
History 29
Physical examination 31

Chapter 4 **Diagnostic imaging** 39
Plain radiographs 39
Barium enema 44
Small bowel examination 47
Ultrasonography 49
Computed tomography 52
Magnetic resonance imaging 55
Positron emission tomography 55
Colography and wireless capsule 57
Angiography 58
Nuclear medicine/scintigraphy 61
Physiologic examinations 62

Chapter 5	**Endoscopy**	67
	Proctoscopy	67
	Flexible fiberoptic sigmoidoscopy	71
	Colonoscopy	76
	Scope cleaning and disinfection	81
Chapter 6	**Minimally invasive surgery**	83
	Equipment	83
	Patient selection and indications	88
	Procedures	88
	Complications	99
	Current and future role	104
Chapter 7	**Intestinal stomas**	107
	Selecting the stoma site	107
	Ileostomy	108
	Continent ileostomy	115
	Colostomy	118
	Enterostomal therapy	122

Section 2: Perioperative management

Chapter 8	**Preoperative preparation**	131
	Nutrition and fluid management	131
	Bowel preparation	136
	Summary of trials and meta-analyses	140
	Miscellaneous preoperative evaluations and management	142
	Informed consent	145
Chapter 9	**Anesthetic management**	149
	Preoperative evaluation	149
	Risk factors	150
	Choice of anesthesia	151
	Additional considerations	158
Chapter 10	**Postoperative management**	163
	General care	163
	Drains	168
	Wound care	169
	Intravenous fluids	170

Transfusions 170
Antibiotics 175

Section 3: Disease processes

Chapter 11 **Hirschsprung disease, colorectal anomalies, and pediatric colorectal conditions** 181
Hirschsprung disease 181
Imperforate anus 190
Duplications 197
Neonatal small left colon syndrome 198
Necrotizing enterocolitis 199
Colonic atresia 200

Chapter 12 **Functional colorectal disorders** 205
Constipation 205
Anal incontinence 211

Chapter 13 **Diverticular disease** 223
Pathophysiology 223
Diagnosis and treatment 225
Conclusion 236

Chapter 14 **Inflammatory bowel disease: ulcerative colitis and Crohn's disease** 239
Ulcerative colitis 239
Crohn's disease 259
Pregnancy and inflammatory bowel disease 268
Surveillance 269
Future directions 271

Chapter 15 **Rectal prolapse and intussusception** 277
Pathophysiology 277
Evaluation 278
Treatment 281
Conclusion 293

Chapter 16 **Hemorrhoids** 299
Anatomy 299
Pathophysiology 299

	Evaluation and treatment	301
	Summary	314
Chapter 17	**Anorectal abscess and fistula-in-ano**	317
	Anorectal abscess	317
	Fistula-in-ano	324
Chapter 18	**Pruritus ani and fissure-in-ano**	337
	Pruritus ani	337
	Fissure-in-ano	341
Chapter 19	**Pilonidal disease**	357
	Etiologic factors	357
	Incidence	358
	Microbiology	358
	Classification and physical findings	358
	Management	359
	Conclusion	366
Chapter 20	**Sexually transmitted diseases and colorectal infections**	369
	Viral diseases	369
	Bacterial diseases	380
	Parasitic diseases	385
Chapter 21	**Polyps**	389
	Histopathology	389
	Management of colorectal polyps	396
	Polyp follow-up	402
Chapter 22	**Malignancy of the colon, rectum, and anus**	407
	Colon and rectum	407
	Anus	431
Chapter 23	**Other conditions: colonic volvulus, ischemia, radiation injury and trauma**	441
	Colonic volvulus	441
	Ischemic colitis	447
	Radiation injury	452
	Colorectal trauma	455

Contributors to the 3rd edition

Kevin P Lally, MD, FACS
University of Texas Health Science Center at Houston, Houston, Texas, USA

Francis R Rodwig, Jr, MD, MPH
Ochsner Clinic Foundation, New Orleans, Louisiana, USA

Shinil K Shah, DO
University of Texas Health Science Center at Houston, Houston, Texas, USA

Barbara Siede
Director of Ochsner Medical Illustrations, Louisiana, USA

Steven D Wexner, MD, FACS, FASCRS
Cleveland Clinic Florida, Weston, Florida, USA

Contributors to 1st and 2nd editions

Chapter 2
First and second edition chapters:
Thomas E Read, MD and Patricia L Roberts, MD

Chapter 3
First and second edition chapters:
Dr W Brian Perry

Chapter 13
Second edition chapter coauthored by:
Frank G Opelka, MD

Chapter 14
Second edition chapter
Steven D Wexner, MD

Chapter 15
Second edition chapter coauthored by:
Charles B Whitlow, MD

Chapter 17
First edition chapter:
Carol-Ann Vasilevsky, MD

Chapter 18
First edition chapter:
Alan E. Timmcke, MD

Chapter 19
First edition chapter:
Richard E Karulf, MD

Chapter 23
First edition chapter :
Terry C Hicks, MD

JAYPEE BROTHERS

4 Diagnostic imaging

In recent years there have been numerous technologic developments in radiology that help physicians in their evaluations of colorectal patients [1]. Radiologic studies include plain and contrast radiographs, ultrasonography, computed tomography, magnetic resonance imaging and nuclear medicine studies. With all this diversity of choice, an understanding of the benefits and limitations of the varying radiologic procedures is helpful in determining which is the most useful examination for a particular problem. This chapter presents a brief analysis of the strengths and weaknesses of the various radiologic procedures so that, in consultation with a diagnostic radiologist, one can select the appropriate imaging study and interpret the findings.

Plain radiographs

In the setting of acute abdominal pain, plain films of the abdomen remain an important radiographic imaging study [2–5]. These examinations are relatively inexpensive, can be performed on virtually all patients (since they can be obtained with portable equipment) and can be evaluated with relative ease by both radiologists and non-radiologists. The standard views for a patient with acute abdominal pain consist of a supine and erect film of the abdomen and an erect film of the chest, centering on the hemidiaphragms. Primarily in this acute abdominal series the physician will be attempting to exclude the presence of free air, evaluating for the presence of radiopaque densities (including gallstones and kidney stones), looking for masses and for deformity of the normal viscous structures (such as the kidney and the liver) and, in particular, assessing the bowel pattern to see whether there is any distention.

As little as 1 or 2 mL of free air can be appreciated on an upright chest or lateral decubitus film (**Figure 4.1a and b**). Larger quantities of free air can be identified on supine films as air inside and outside the bowel produces a 'double lumen' sign (**Figure 4.1c**). Free intra-abdominal air is frequently seen in the initial postoperative films of a laparotomy patient. This usually resolves in 5–7 days. Serial postoperative films should show a reduction in free air. Cholelithiasis and urolithiasis as well as other calcified masses and radiopaque foreign bodies may be visible on a plain film of the abdomen (**Figure 4.2**). However, other imaging modalities such as ultrasonography, computed tomography (CT) or an intravenous urogram (IVU) are often needed for definitive evaluation [6]. The bony structures of the lumbosacral spine, lower

JAYPEE BROTHERS

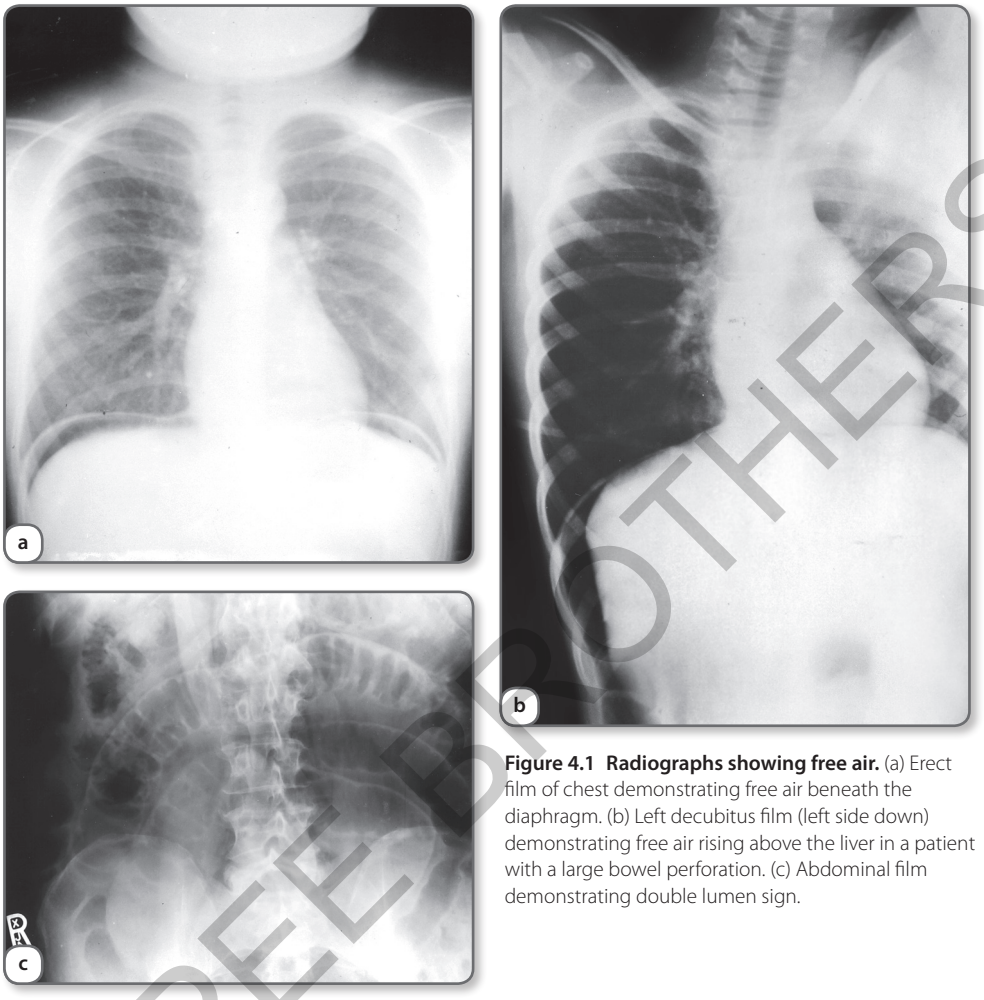

Figure 4.1 Radiographs showing free air. (a) Erect film of chest demonstrating free air beneath the diaphragm. (b) Left decubitus film (left side down) demonstrating free air rising above the liver in a patient with a large bowel perforation. (c) Abdominal film demonstrating double lumen sign.

thoracic spine, the ribs, pelvis, and femoral head are also visualized on these plain films and should be carefully evaluated for sclerotic as well as lytic lesions. Fractures and lesions of the bony structures may frequently present with abdominal pain when ileus is a secondary complicating factor.

Radio-opaque foreign bodies can also be demonstrated on plain films (**Figure 4.3**). In addition to identifying and localizing the foreign body, an acute abdominal series can exclude free air, which suggests a bowel perforation.

Plain films of the abdomen also allow the examiner to evaluate the visceral structures of the liver, spleen, kidneys, and bladder. The outlines of these structures should be assessed for deformity or displacement. The sensitivity of this examination will vary, depending on the patient's body habitus, ability to cooperate, hold his breath,

JAYPEE BROTHERS

and remain still. Of particular interest to those concerned with colorectal surgery is evaluation of the bowel gas pattern. Gas, which is a product of both swallowed air and bacteria production, is normally seen within the colon and stomach and, to a lesser extent, within the small bowel. The small bowel is considered abnormal if it measures more than 3 cm in diameter and the wall abnormal if it is greater than 3 mm. The transverse colon is considered abnormal if it measures more than 5.5 cm in diameter. The extent and pattern of the bowel gas is important as well. If there is distention both of the small bowel and large bowel, including the rectum, then consideration should be given that an ileus may be present. Similarly, if the patient has recently undergone surgery, the possibility of an ileus must be considered as well. Clinical setting and change over time are important factors that help determine the significance of radiographic findings. Serial films at

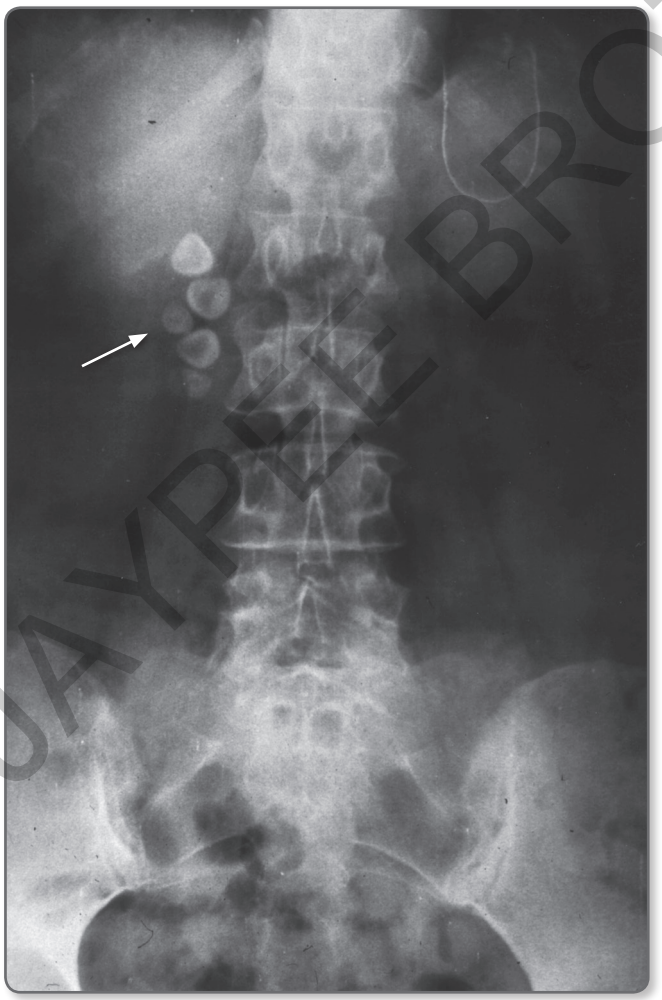

Figure 4.2 Plain film of the abdomen reveals four calcified masses in the right upper quadrant, representing cholelithiasis (white arrow).

JAYPEE BROTHERS

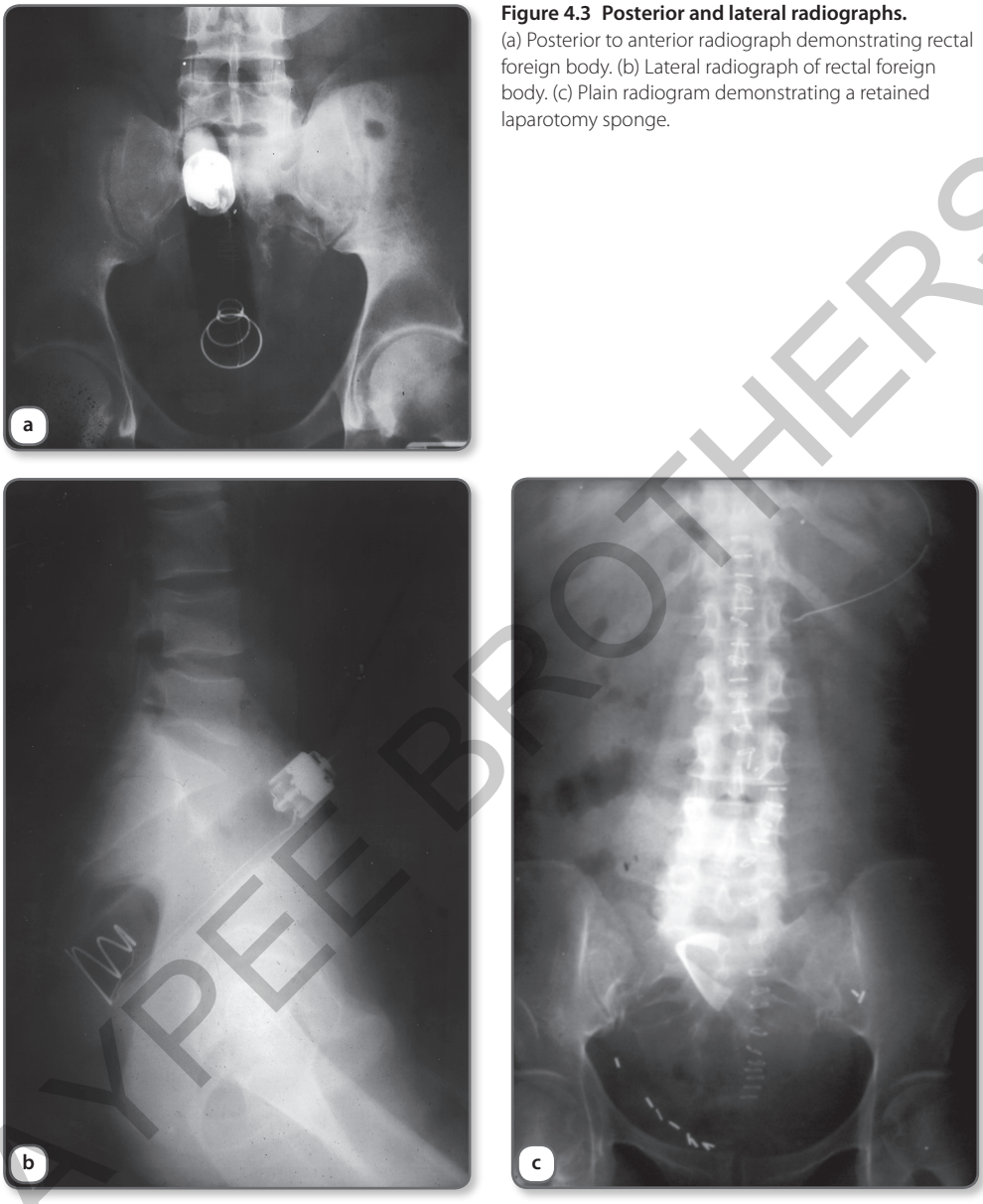

Figure 4.3 Posterior and lateral radiographs.
(a) Posterior to anterior radiograph demonstrating rectal foreign body. (b) Lateral radiograph of rectal foreign body. (c) Plain radiogram demonstrating a retained laparotomy sponge.

JAYPEE BROTHERS

regular intervals provide important clinical information and help the examiner determine the significance of radiographic findings.

Volvulus or twisting of the large bowel can be identified on plain films (**Figures 4.4** and **4.5**, and see Figures 23.1 and 23.2). In some circumstances a contrast study as described below may assist in confirming the location of the volvulus. This study may also reduce the volvulus and excludes other colonic pathology.

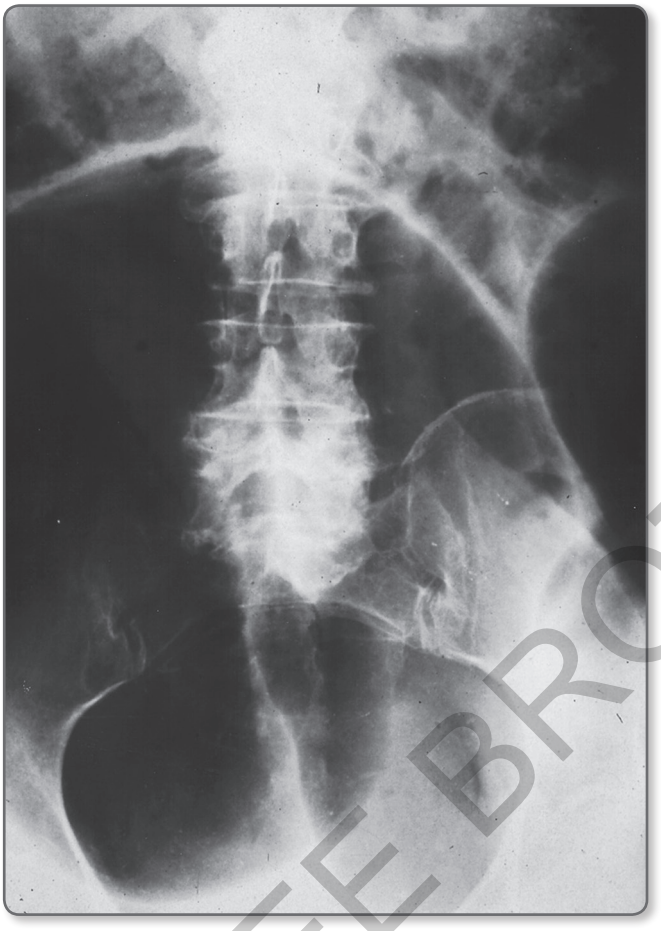

Figure 4.4 Radiograph of sigmoid volvulus.

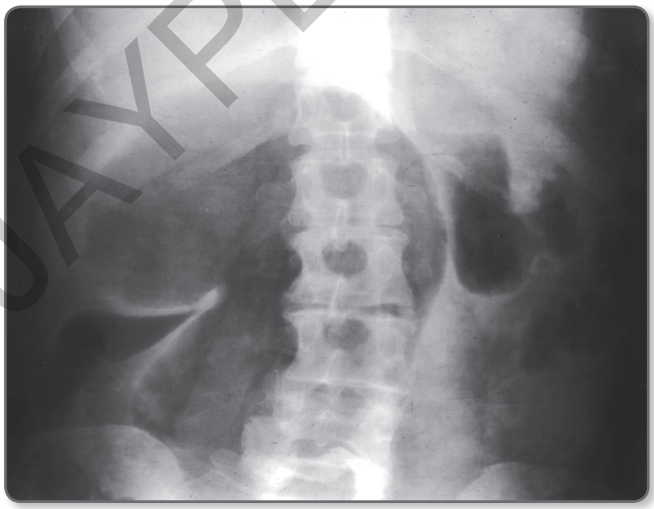

Figure 4.5 Radiograph of cecal volvulus.

JAYPEE BROTHERS

Barium enema

Barium enemas are performed to evaluate patients with heme-positive stools, a family history of colon carcinoma, inflammatory bowel disease, change in bowel habits, and abdominal pain [7, 8]. Contrast enemas employ a single- or double-contrast technique. The indications for single- versus double-contrast barium enema are controversial. Double-contrast studies are generally considered superior, particularly for the detection of small polyps and the mucosal changes of inflammatory bowel disease.

In a **single-contrast barium enema,** the colon is slowly filled with barium and compressed manually or mechanically. The examination is monitored by live fluoroscopy. 'Spot' images are acquired in multiple projections as the colon is being distended. Each portion of the colon must be examined free from overlapping bowel. Once the colon is completely filled, as demonstrated by visualization of the terminal ileum, appendix, or ileocecal valve, films of the entire colon are obtained (**Figures 4.6** and **4.7**).

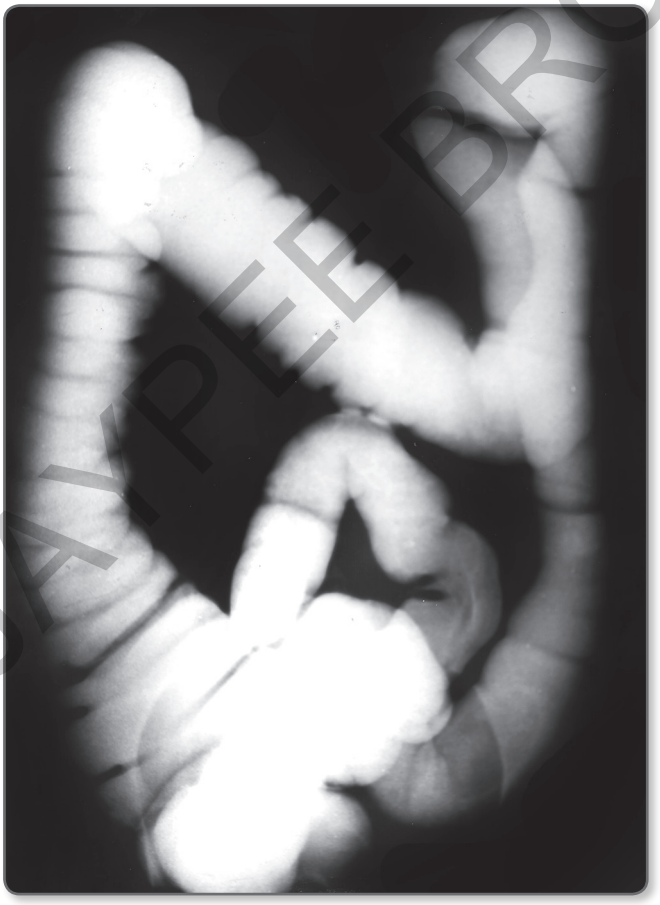

Figure 4.6 Single-contrast barium overhead film demonstrating a normal 'filled' colon.

JAYPEE BROTHERS

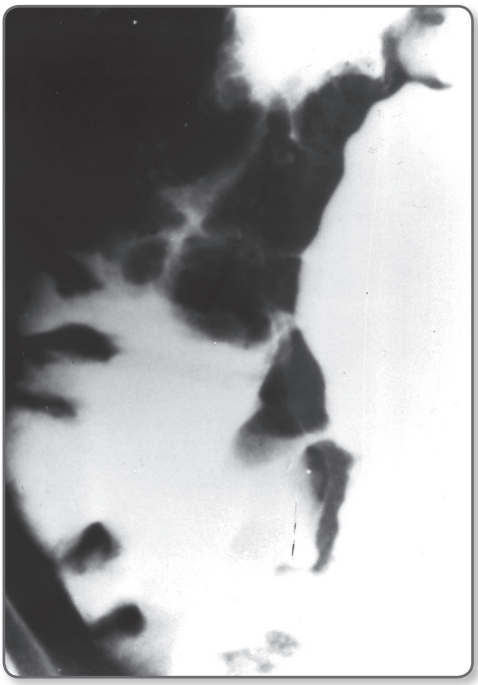

Figure 4.7 Constricting lesion (adenocarcinoma) of the ascending colon on a single-contrast barium enema spot film.

With a **double-contrast barium enema,** a higher viscosity, more dense barium suspension is introduced into the colon, then the colon is distended by air insufflation. Fluoroscopic examination is performed as the colon fills and then a series of overhead films is taken (**Figures 4.8** and **4.9**). The patient must retain the barium and air during these overhead films**.** A double-contrast barium enema is more time consuming and often not as well tolerated by the patient. Contrast enemas have a sensitivity of 50–80% for lesions <1 cm and 70–90% for lesions >1 cm [2]. A contrast study tends to be less accurate in the rectosigmoid area.

Rigorous cleansing of the colon is required before a barium enema, especially with the double-contrast technique. Even a small amount of retained stool can obscure mucosal detail, leading to inconclusive results or even misinterpretation. Regimens to prepare the colon often include clear liquid diet and laxatives the day before the examination and a suppository the morning of the study. An additional 24-hour preparation or stronger laxatives are necessary in a small number of patients (see Chapter 8).

Incompetence of the ileocecal valve can also degrade the quality of barium enemas by preventing full colonic distention and obscuring segments of colon. An incompetent ileocecal valve causes greater difficulty in a double-contrast barium enema, where there is less control of the contrast column. Colonic spasm can interfere with single- and double-contrast barium enemas. Spasm causes patient discomfort and

JAYPEE BROTHERS



Figure 4.8 Left lateral decubitus overhead film of a normal double-contrast barium enema.



Figure 4.9 Diffuse colonic ulceration, best seen in the transverse colon (arrows) from a double-contrast barium enema in a patient with ulcerative colitis.

JAYPEE BROTHERS

makes full distention of the colon impossible. Intravenous glucagon is commonly administered to combat spasm. In some institutions, glucagon is given prophylactically before all double-contrast barium enemas.

Because of its imaging characteristics, barium is the agent of choice for most contrast enemas. If intestinal perforation is suspected or emergency surgery is anticipated, water-soluble, iodine-based, single-column contrast agents (Gastrografin, Oral Hypaque) are often preferred. These types of contrast medium are considerably more expensive and can have a high osmolality. These high-osmolar agents may cause fluid shifts and act as cathartics.

Small bowel examination

Effective examination of the small bowel requires a thorough knowledge of the disease processes that can affect it. Methods of study include standard barium small bowel follow-through and enteroclysis [9]. Standard barium **small bowel follow-through (SBFT)** is usually combined with an upper gastrointestinal (UGI) barium examination (**Figure 4.10**). 480–600 mL of medium-density barium is given orally at a delivery speed that depends on patient toleration and gut and small bowel motility as observed by fluoroscopy. Intermittent supine abdominal radiographs are taken at intervals, depending on observed



Figure 4.10 Overhead film from a small bowel follow-through shows a normal small-bowel loop and mucosal fold patterns. External compression device (white ring) helps to isolate single loops of small bowel.

JAYPEE BROTHERS

small bowel motility (usually every 30 minutes) until barium reaches the large bowel. During the course of the examination, manual examination of the small bowel is performed, paying careful attention to small bowel caliber and mucosal pattern. When the terminal ileum is reached, it is thoroughly examined manually using compression and spot images taken fluoroscopically. Several films are necessary for a complete examination to image the small bowel in various stages of the passage of the barium meal.

Standard **enteroclysis** examination can provide increased sensitivity to the barium examination of the small bowel; however, it is more expensive, more invasive and less tolerated by patients (**Figure 4.11**) [10]. Medium-density barium followed by methylcellulose is injected through a nasal-intestinal tube at a rapid rate (100 mL/min), either manually or with an infusion device. This provides excellent distention of the small bowel and a double-contrast effect that may show partially obstructing lesions that might have been less well seen by conventional SBFT. The examination is monitored fluoroscopically with intermittent manual examination and supine abdomen filming. Various disease states can change the mucosal fold pattern, cause complete or partial obstruction through mass effect, stricture, or kinking of small bowel loops. Small bowel studies can characterize these clinically suspected lesions or show the likely location of lesions, allowing directed surgical exploration for diagnosis and therapy. Differential diagnosis is then offered by the radiologist after carefully correlating the radiologic data with the clinical data provided by the referring physician.

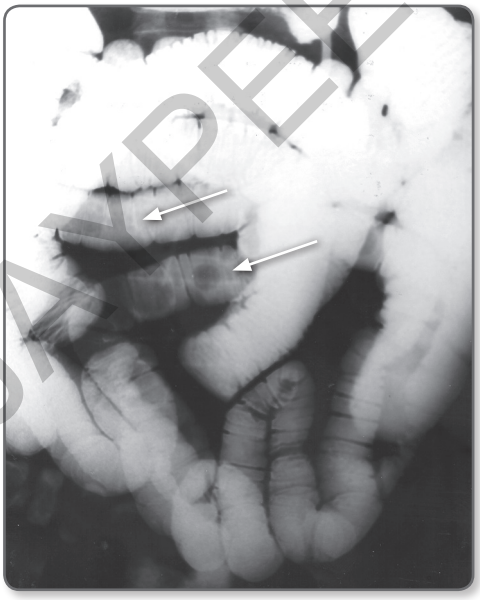

Figure 4.11 Overhead film from normal enteroclysis reveals multiple nonpersistent filling defects (arrows), which are air bubbles.

JAYPEE BROTHERS

Ultrasonography

Diagnostic

Diagnostic ultrasonography is of great value in diagnosing abnormalities of the gastrointestinal tract [11]. This modality is not invasive and uses sound waves to provide rapid and inexpensive multiplanar images of the major abdominal organs [12,13]. Examinations can be performed at the patient's bedside, and therefore virtually all patients can undergo evaluation. The structures that can be studied include the liver, spleen, pancreas, kidneys, aorta and periaortic areas, and pelvis. Abnormal loops of bowel can be identified as well. Persistent loops of noncompressible bowel, similar to the sonographic appearance of the kidney, have been called the **pseudokidney** and indicate bowel wall thickening [14]. These abnormalities can be seen in conditions that produce bowel wall thickening, including neoplasms, inflammatory bowel disease, inflammatory processes such as diverticulitis, infectious processes such as tuberculosis, and acute appendicitis (**Figure 4.12**) [15–17].

Inflammatory processes such as abscesses can be visualized and separated from normal structures. Under ultrasound guidance, these can also be percutaneously aspirated and drained.

Masses, particularly in the liver, can be appropriately visualized with ultrasonography. Although CT portography has a greater sensitivity and specificity than diagnostic ultrasound, most sensitive of all appears to be intraoperative ultrasound in identifying focal liver lesions. Patients with mucinous adenocarcinoma metastatic to the liver frequently have a characteristic pattern of calcified liver masses causing posterior shadowing. Once a liver mass is identified with ultrasound, a diagnostic

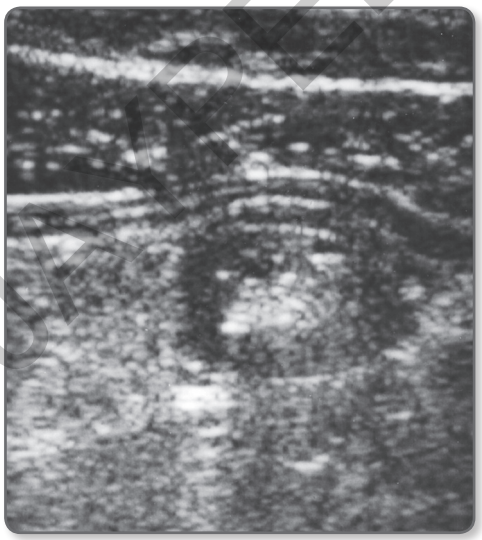

Figure 4.12 Ultrasound showing 'pseudokidney' sign in the right lower quadrant, indicating acute appendicitis.

JAYPEE BROTHERS

percutaneous biopsy can be performed. Ultrasonography is also helpful intraoperatively when segmental resections of the liver are being planned.

Intraluminal

Ultrasonography is also of increasing value in evaluating the extent of anal and rectal cancer [18–20]. Intra-anal ultrasound is extremely helpful in evaluating the anal sphincter to confirm defects in the incontinent patient (**Figures 4.13** and **4.14**) [21]. It can be helpful in evaluating complex anorectal fistulas or abscesses. Hydrogen peroxide injected into the fistula serves as an ecogenic contrast. Rectal cancers can be staged using **transrectal ultrasound**, not only to determine the extent of wall penetration (**Figure 4.15**), but also to visualize the presence of nodal enlargement. Intrarectal ultrasound of the normal rectum produces five rings, three hyperecoic (white) and two hypoecoic (black), which correspond to the interfaces demonstrated in **Figure 4.16**. An ultrasound staging system is described in **Table 4.1**. Intra-anal ultrasonography produces images slightly different from those taken in the rectum. In the upper anal canal the puborectalis

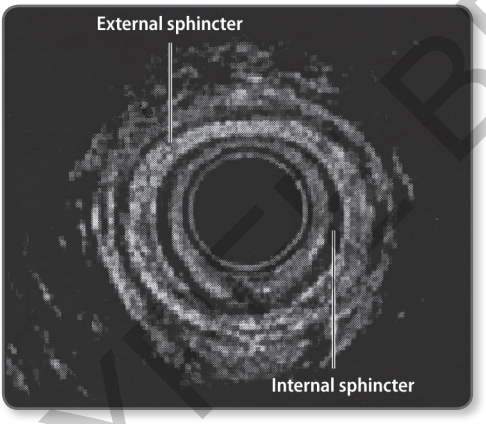

Figure 4.13 Normal intra-anal ultrasound.

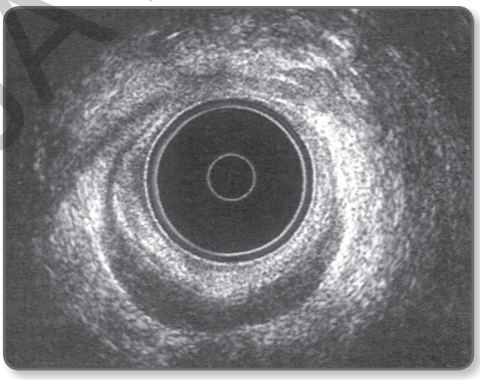

Figure 4.14 Intra-anal ultrasound demonstrating sphincter defect.

JAYPEE BROTHERS

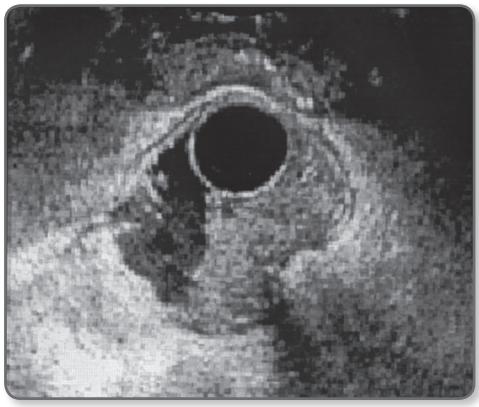

Figure 4.15 Intrarectal ultrasound demonstrating a uT3 lesion.

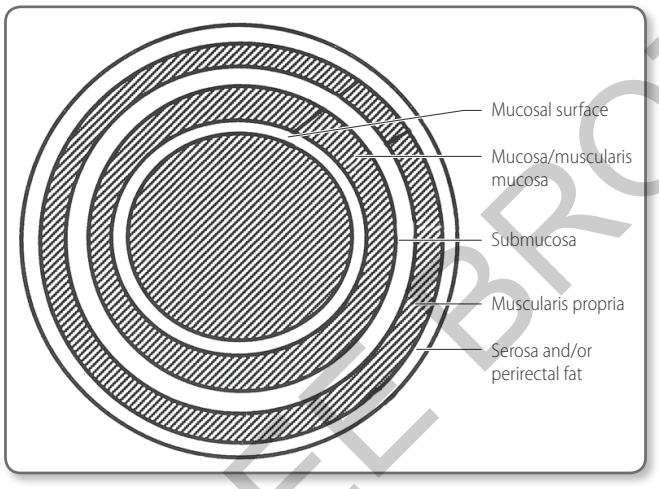

Figure 4.16 Graphic representation of intrarectal ultrasound.

Table 4.1 Intrarectal ultrasound staging system

Level	Description
uT1	Malignant lesion confined to mucosa and submucosa
uT2	Invasion into, but not through, the muscularis propria
uT3	Invasion into perirectal fat
uT4	Invasion into adjacent organ (e.g. prostrate, vagina, bladder)
N0	No evidence of regional nodal metastases
N1	Involvement of perirectal nodes with metastatic disease

muscle appears as a U-shaped structure with the open anterior end (**Figure 4.17**). The lower anal canal is presented in **Figure 4.18**.

Retained stool in the rectum will degrade or produce false images. Patient preparation includes enemas and a proctoscopic examination

JAYPEE BROTHERS

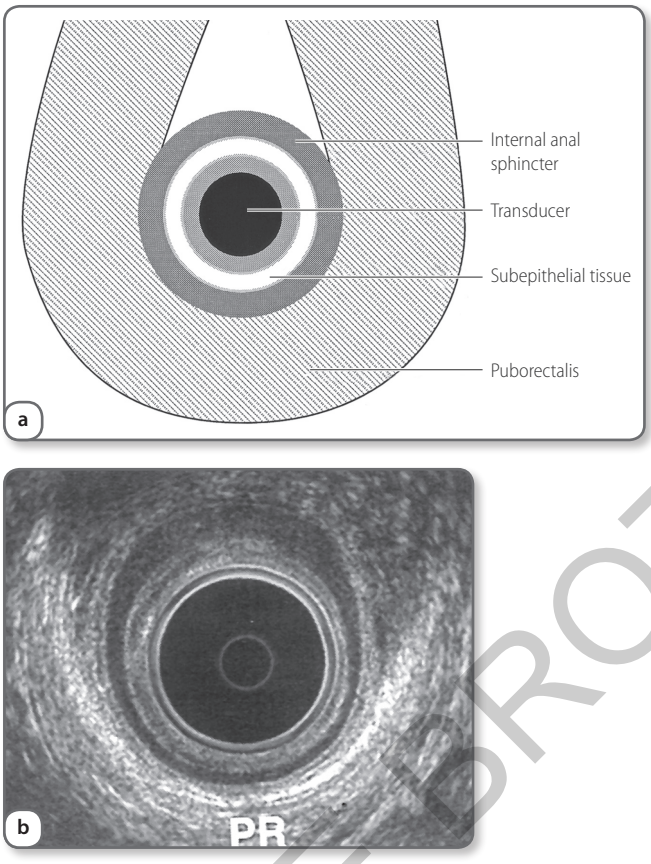

Figure 4.17 Anatomy of the upper anal canal. (a) Diagramatic representation of normal anatomy of the upper anal canal. (b) Corresponding endoanal ultrasound image demonstrating the hypsechoic internal anal sphincter and the hyperechoic 'U' shaped puborectalis as denoted by PR. From Wong DW. Endosconography of the anal canal. Persp Colon Rectal Surg 1998;10:1–21. With permission.

to confirm the adequacy of the preparation and if necessary to suction any residual stool. This need for proctoscopy along with a superior knowledge of anorectal anatomy explains the superior results obtained by colorectal surgeons performing intraluminal ultrasound. Impediments to abdominal ultrasound include bowel gas as well as barium. Preparation for abdominal ultrasonographic examination requires that the patient be NPO for at least 4–8 hours before the examination. Since this examination is operator dependent, it is absolutely necessary to have highly qualified individuals performing and interpreting these examinations.

Computed tomography

Computed tomography imaging is a useful modality for the evaluation of pathologic conditions of the abdomen, including colon carcinoma (**Figure 4.19**) [22]. As X-rays course through the patient, they are attenuated. The CT scanner's detectors sum up the transmitted attenuated X-ray energies and use a computer to process the information to produce an image. The original concept for CT was introduced in 1972 by G.N.

JAYPEE BROTHERS

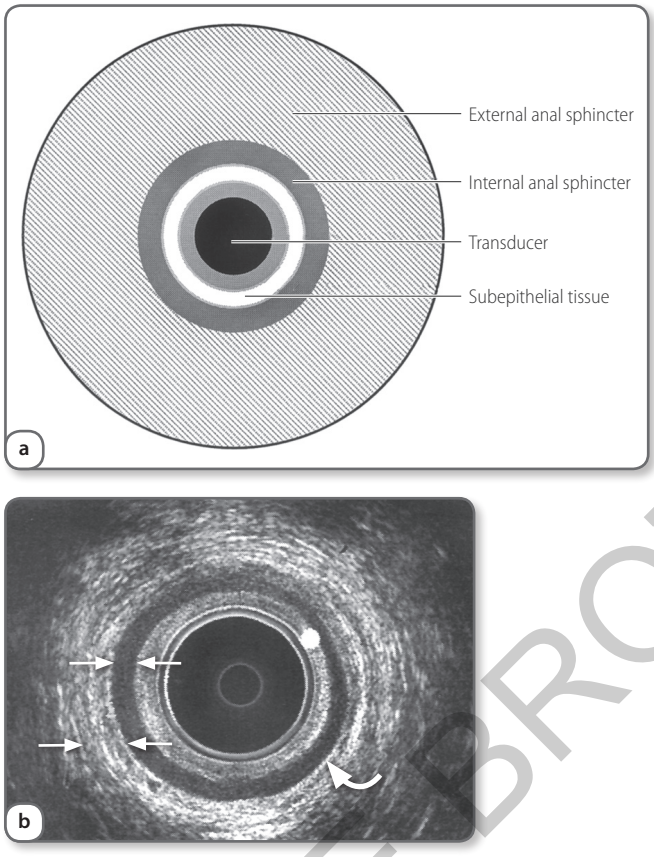

Figure 4.18 Anatomy of the mid anal canal. (a) Diagramatic representation of normal anatomy of the mid anal canal. (b) Corresponding endoanal ultrasound image demonstrating the inner hyperechoic subepithelial tissues (white dot), the thin circular hypoechoic ring of the internal anal sphincter marked by the two opposing solid arrows, a portion of the thin longitudinal muscle denoted by the curved arrow, and the mixed echogenicity ring of the external anal sphincter seen between the two opposing open arrows. From Wong DW. Endoscongraphy of the anal canal. Persp Colon Rectal Surg 1998;10:1-21. With permission.

Hounsfield. Today, higher heat capacity tubes have made CT scanning much faster. The modern spiral multi-detector CT units have increased resolution, reduced radiation exposure and dramatically decreased scan time.

Patient preparation before CT imaging should be discussed with the consulting radiologist. In general, the use of an oral gastrointestinal contrast medium is crucial, whereas intravenous contrast is not. Oral contrast medium is administered to outline the intestinal wall, which should not exceed 5 mm in thickness (includes large and small bowel). An oral suspension of 2% barium sulfate or 2% water-soluble contrast medium (Hypaque or Gastrografin) should be given before any scanning. The use of barium should be avoided if one suspects a bowel perforation. If this is a concern, then Hypaque (less expensive) or Gastrografin (more expensive) can be given. Water-soluble contrast should be avoided in patients with intestinal obstruction. Intravenous contrast medium should be administered when details of vascular structures or vascular lesions are needed unless contraindicated by prior allergic reaction or renal insufficiency. Rectal contrast allows better

JAYPEE BROTHERS