




ESSENTIALS OF HAND SURGERY

Kevin C Chung

Contents

Preface v

Acknowledgements vii

Contributors xiii

SECTION 1 BASIC PRINCIPLES

Chapter 1
Anatomy of the upper limb 3
Shady A. Rehim, Kevin C. Chung

Chapter 2
Objective evaluation of hand function 17
Jeanne M. Riggs, Kevin C. Chung

Chapter 3
Radiologic studies used in evaluation of the upper extremity 21
Aviram M. Giladi, Yirong Wang, Kevin C. Chung

Chapter 4
Electrodiagnostic studies and peripheral nerve ultrasound 33
Kay WP. Ng, Aravinda K. Therimadasamy, Li Sihui Eileen, Einar P. Wilder-Smith

Chapter 5
Use of locoregional anesthesia and tourniquet in the upper limb 45
Shady A. Rehim, Kevin C. Chung

Chapter 6
Surgical instrumentation and magnification 53
Keming Wang, Evan J. Kowalski, Kevin C. Chung

Chapter 7
Rehabilitation 59
Jeanne M. Riggs, Kevin C. Chung

SECTION 2 EMERGENCY HAND SURGERY

Chapter 8
Examination of the traumatized hand 69
Shady A. Rehim, Kevin C. Chung

Chapter 9
Compartment syndrome 77
Matthew D. Chetta, Kevin C. Chung

Chapter 10
Acute hand infections 83
Jennifer F. Waljee, Kevin C. Chung

Chapter 11
Nail bed injuries 93
Aviram M. Giladi, Sandeep J. Sebastin, Kevin C. Chung

Chapter 12
Tendon injuries 99
12.1 Flexor tendon injuries
Alphonsus Chong
12.2 Extensor tendon injuries
Teemu Karjalainen
12.3 Rehabilitation of tendon injuries
Erika D. Sears, Kevin C. Chung

Chapter 13
Fractures and dislocations 117
13.1 Principles of skeletal fixation for the hand
Amitabha Lahiri
13.2 Phalangeal fractures and interphalangeal joint dislocations
Maneesh Singhal, Kevin C. Chung
13.3 Metacarpal fractures
Keming Wang, Evan J. Kowalski, Kevin C. Chung
13.4 Ligamentous instability and carpal fractures
Yeong-Pin Peng
13.5 Fractures and dislocations of the distal radius and the distal radioulnar joint
Yeong-Pin Peng
13.6 Therapy for fractures and dislocations in the hand
Kris Tong DL

Chapter 14
Burns 163
Keming Wang, Evan J. Kowalski, Kevin C. Chung

Chapter 15
High-pressure jet injection injuries 175
Keming Wang, Evan J. Kowalski, Kevin C. Chung

Chapter 16
Fundamental principles of microsurgery and replantation 179
Aaron WT. Gan, Yeong-Pin Peng

Chapter 17
Soft tissue coverage and thumb reconstruction 185
Keming Wang, Evan J. Kowalski, Kevin C. Chung

Chapter 18
Approach to complex hand trauma 209
Amitabha Lahiri

SECTION 3 ELECTIVE HAND SURGERY

Chapter 19
System-specific examination of the hand 217
Shady A. Rehim, Kevin C. Chung

Chapter 20
Congenital disorders 227
Alphonsus Chong

Chapter 21
Chronic infections of the hand and upper extremity 235
Oluseyi Aliu, Kevin C. Chung

Chapter 22
Tendinopathy and work-related upper-limb disorders 245
Yirong Wang, Evan J. Kowalski, Kevin C. Chung

Chapter 23
Nerve disorders 255
23.1 Nerve injury and repair
Ellen Y. Lee, Aymeric Lim
23.2 Nerve compression syndromes
Ellen Y. Lee, Aymeric Lim
23.3 Nerve palsy
Ellen Y. Lee, Aymeric Lim
23.4 Neonatal brachial plexus palsy
Ellen Y. Lee, Sandeep J. Sebastin, Aymeric Lim
23.5 The spastic upper limb and tetraplegia
Ter Chyan Tan
23.6 Thoracic outlet syndrome
Martins Kapickis

Chapter 24
Vascular disorders of the hand 293
Yirong Wang, Evan J. Kowalski, Kevin C. Chung

Chapter 25
Degenerative osteoarthritis and inflammatory arthritis of the hand and wrist 305
Jennifer F. Waljee, Kevin C. Chung

Chapter 26
Hand tumors 325
Mark Puhaindran

Chapter 27
Contracture 331
27.1 The stiff digit
Shady A. Rehim, Kevin C. Chung
27.2 Volkmann ischemic contracture
Hari Venkatramani, Praveen Bhardwaj
27.3 Dupuytren contracture
Teemu Karjalainen

Chapter 28
Complex regional pain syndrome 349
Sandeep J. Sebastin

Index **355**

Chapter 4 Electrodiagnostic studies and peripheral nerve ultrasound

Kay WP. Ng, Aravinda K. Therimadasamy, Li Sihui Eileen, Einar P. Wilder-Smith

JAYPEE BROTHERS

Nerve conduction studies (NCS) and needle electromyography (EMG) are investigations used to assess patients with neuromuscular conditions. These investigations are valuable in peripheral nervous system (PNS) disorders because they help in

- Localizing the lesion
- Determining underlying pathophysiology
- Following the temporal course
- Assessing severity and prognosis

Ultrasound (US) and magnetic resonance imaging (MRI) are also increasingly used to assess the PNS. These tools are useful to

- Provide supportive evidence of clinical diagnosis
  - E.g. focal nerve enlargement in nerve entrapment
- Help in precise localization of nerve and nerve lesions
- Detect anatomic variations prior to surgical intervention
- Suggest etiology
  - E.g. ganglion, neuroma, and luxation
- Provide information on surrounding structures
  - E.g. muscle, tendon, ligaments, and artery
- Provide information on blood flow to the nerve
  - E.g. to detect inflammation
- Help in guided intervention
  - E.g. nerve blocks

ANATOMY OF THE PNS

The PNS includes the motor, the sensory, and the autonomic systems. The sensory and motor roots combine to form a mixed spinal nerve (**Figure 4.1**). The mixed spinal nerve then divides to form the dorsal and the ventral ramus. The dorsal rami supply the paraspinal muscles, and sensation to the overlying skin. The ventral rami continue as the intercostal nerves in the thoracic region, and in all other regions the ventral rami fuse to form a plexus. The brachial plexus is formed by the ventral rami of the C_5-T_1 roots, whereas the lumbosacral plexus is formed by the ventral rami of the L_4-S_1 roots. Peripheral nerves arise from the plexus to supply different muscles and areas of sensation. These areas can be classified as

- Myotomes (all muscles innervated by individual nerve roots)
- Dermatomes (areas of cutaneous innervation by individual nerve roots)

The autonomic system (sympathetic and parasympathetic) is not under voluntary control. Sympathetic preganglionic cell bodies lie in the lateral horns of the spinal segments T_1-L_2 where these fibers travel a short distance in the mixed spinal nerve. They then exit to enter the sympathetic ganglionic chains that lie paravertebrally from the cervical to sacral region. The parasympathetic preganglionic cell bodies lie in the brain stem in the motor nuclei of cranial nerves III, VII, IX and X, and in the sacral segments of the spinal cord (S_2-S_4), spreading out fibers that synapse near the innervated organ.

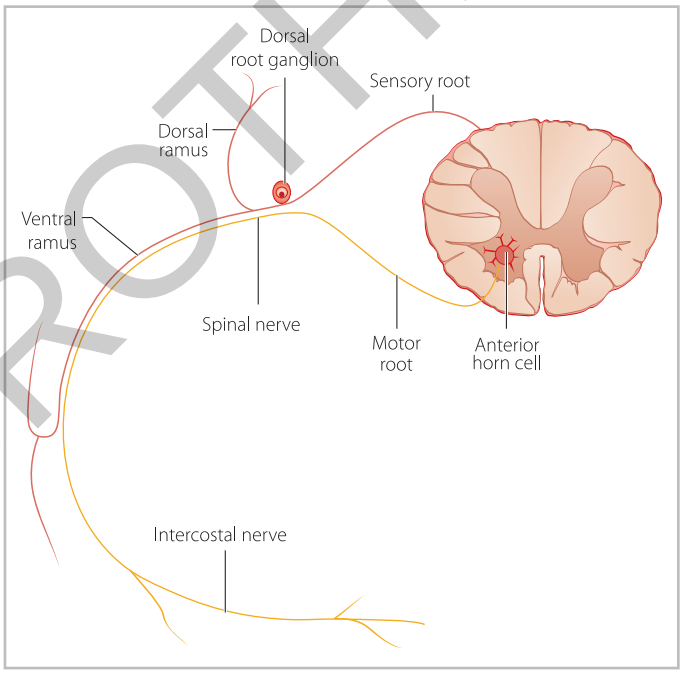

Figure 4.1 The sensory root leaves the cord dorsally, whereas the motor root arises from the anterior horn cells and leaves the cord ventrally. Both combine to form a mixed spinal nerve, which divide to form the dorsal and ventral ramus. The dorsal rami supply the paraspinal muscles, while the ventral rami continue as either intercostal nerves, or fuse to form the brachial or lumbosacral plexus.

PHYSIOLOGY

Each axon has a resting membrane potential (threshold). The membrane is negatively charged internally compared with externally, due to membrane properties and the Na^+/K^+ pump, leading to higher sodium concentrations outside of the membrane. When a current passes through the axon, the axon becomes more positive internally (depolarization) via opening of voltage-gated sodium channels that line the membrane, allowing sodium influx, creating an action potential. Sodium channels are then inactivated, and the threshold re-established.

Propagation of this action potential is very slow without the presence of myelin and the nodes of Ranvier. Conduction velocity is increased substantially by saltatory conduction, which involves action potentials jumping from node to node (**Figure 4.2a**). When the nerve action potential reaches the presynaptic side of the neuromuscular junction, voltage-gated calcium channels open, allowing calcium to enter and triggering the release of acetylcholine across the synapse. Acetylcholine then binds to receptors on the muscle membrane, allowing sodium to enter and depolarizing the muscle fiber. The motor axon, its anterior horn cell, and all of the connecting muscle fibers form a motor unit. A motor unit action potential (MUAP) is created when all of the muscle fibers of one motor unit are depolarized (**Figure 4.2b**). NCS measure mainly the large diameter fibers that have the most myelin, and hence the fastest conduction velocities. Needle EMG studies, on the other hand, analyze the MUAPs.

NERVE CONDUCTION STUDIES

A depolarizing electrical impulse is applied to the skin to stimulate the underlying peripheral nerve, and an electrode records the resultant action potential. NCS may be used for motor, sensory, or mixed nerves.

Motor NCS

The recording electrode is placed over a distal muscle, recording the summation of the individual activated muscle fiber action potentials as a compound muscle action potential (CMAP). The parameters studied in a motor NCS (**Figure 4.3a**) have been summarized in **Table 4.1**.

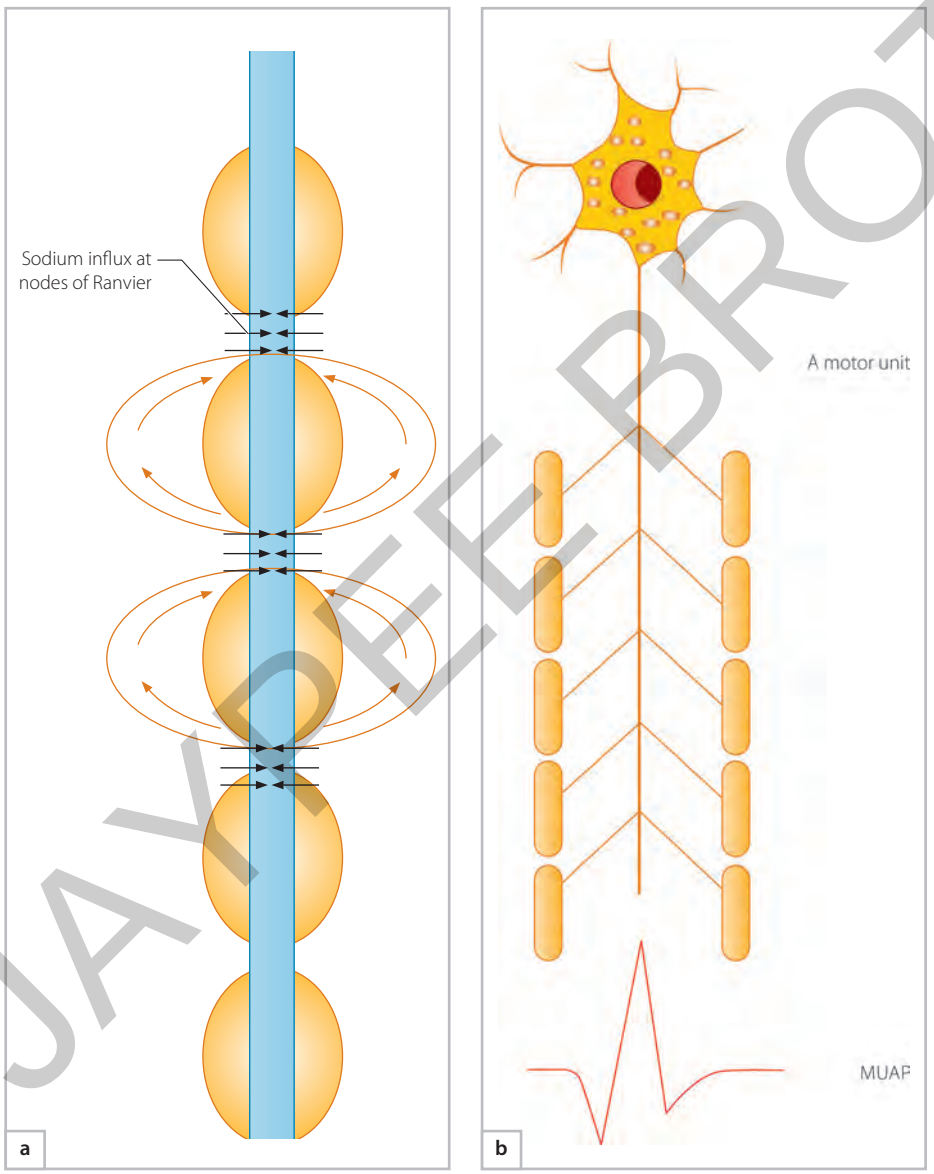

Figure 4.2 (a) Action potentials are created at the unmyelinated areas of the nerve (nodes of Ranvier), and jump over the myelinated portions from node to node, thus increasing conduction velocity. (b) A motor unit action potential is created when all the muscle fibers of one motor unit are depolarized.

JAYPEE BROTHERS

Table 4.1 Parameters studied in a motor NCS

Parameter	Description	Significance
dML	Time from the most distal stimulus to initial CMAP deflection from the baseline	Time taken for fastest nerve fibers to conduct. Includes time for neuromuscular transmission and muscle depolarization and activation
Amplitude	From baseline to 'negative' peak (by convention, the upward deflection)	Number of muscle fibers that depolarize, representing the number of conducting axons
Duration	From initial deflection from baseline to first baseline crossing	Extent of synchrony of muscle fiber activation
CV	Calculated by distance between two stimulation sites/difference in latencies between both sites (hence excludes neuromuscular transmission and muscle activation time)	Speed of the fastest conducting motor axons

NCS, nerve conduction studies; dML, distal motor latency; CV, conduction velocity; CMAP, compound muscle action potential.

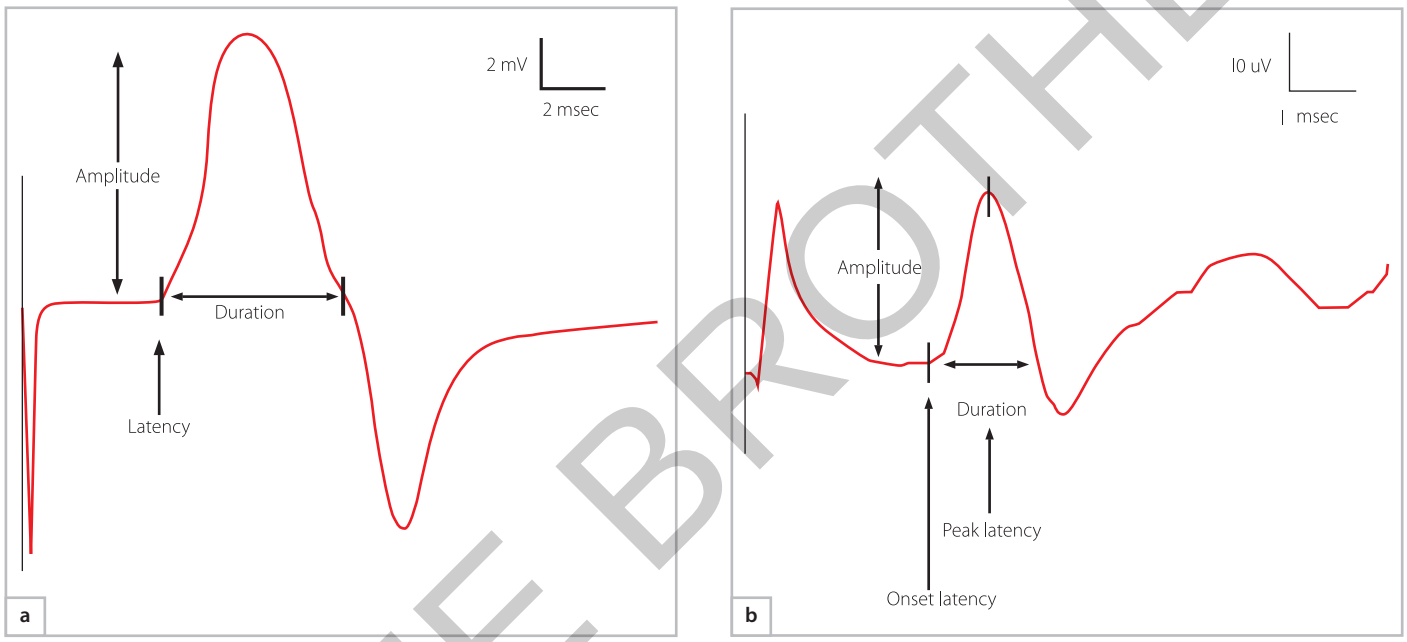

Figure 4.3 (a) Schematic of a compound muscle action potential (CMAP) – Latency (msec): time from stimulus to initial upward deflection of CMAP from baseline. Amplitude (mV): from baseline to peak. Duration (msec): from initial deflection to first baseline crossing. (b) Schematic of a sensory nerve action potential: Peak latency (msec): time from stimulus to first upward peak. Amplitude (μV): from negative peak to positive peak. Duration (msec): from initial baseline deflection to first baseline crossing.

Sensory NCS

Sensory fibers are stimulated and the sensory nerve action potential (SNAP) is recorded with the recording electrode placed either proximally (or orthodromic – direction in which physiologic sensory conduction occurs) or distally (or antidromic – in the reverse direction) to stimulus. The parameters studied in a sensory NCS (**Figure 4.3b**) have been summarized in **Table 4.2**.

Mixed NCS

A mixed nerve action potential (MNAP) reflects the summation of both motor and sensory nerve fiber action potentials. This study assesses the largest and fastest fibers that are the sensory muscle afferents supplying the muscle spindles. For example, MNAP can be used to test the stimulation of the ulnar nerve before the cubital tunnel with a measurement of the nerve potential after the cubital tunnel.

F waves

An action potential is propagated in both directions from the site of stimulus of a motor axon. The proximal impulse conducts to the anterior horn cell, depolarizes the axon hillock, and returns to create a late muscle depolarization (F wave). It is useful in the testing of proximal segments of nerves, is a sensitive indicator of pathology, and tests longer segments of nerves.

Parameters affecting NCS

They include

- Temperature: conduction velocity is slower in lower temperatures
- Age: conduction velocity is slower with increasing age
- Limb length: conduction velocity is slower with increasing length

JAYPEE BROTHERS

Table 4.2 Parameters studied in sensory NCS

Parameter	Description	Significance
Peak latency	Time from stimulus to midpoint of first negative peak	Nerve conduction time from stimulus to recording electrodes. Peak latencies preferred over onset latencies as peak more easily identified in sensory studies, due to small amplitudes
Amplitude	From first negative peak to next positive peak	Number of depolarized sensory fibers
Duration	From initial deflection from baseline to first baseline crossing	Extent of synchrony of firing individual fibers (larger fibers conduct faster than smaller ones)
CV	Distance divided by latency	Velocity of 20% largest diameter and fastest conducting fibers that mainly convey fine touch, vibration, proprioception

NCS, nerve conduction studies; CV, conduction velocity.

Interpretation of NCS

Laboratory-specific age-matched 'normal' values are available. The aim of NCS is to determine if the nerve pathology is focal or generalized and if it is axonal or demyelinating. An entrapment neuropathy, e.g. ulnar neuropathy at the elbow from a focal neuropraxia, resulting in demyelination, has a better prognosis than if axonal loss has occurred. The NCS characteristics of axonal and demyelinating lesions have been summarized in **Table 4.3**.

ELECTROMYOGRAPHY

This involves insertion of a needle electrode into muscles selected by an electromyographer based on history and physical examination. This study is used to analyze spontaneous activity (electrical discharge while the muscle is at rest) and MUAPs (when the patient contracts the muscle). The common spontaneous activity and MUAP have been summarized in **Tables 4.4** and **4.5,** respectively.

Table 4.3 NCS characteristics of axonal and demyelinating lesions

Study	Axonal loss	Demyelinating	Apparently normal despite pathology present
Motor studies	Reduced amplitudes Near-normal CV and dML	Reduced CV Prolonged dML Variable amplitude changes Temporal dispersion† Conduction block‡	Hyperacute axonal lesions, e.g. acute nerve transections*
Sensory studies	Reduced amplitudes Near-normal CV and dML	Reduced CV Prolonged dML More prominent temporal dispersion and conduction block	1. Lesion is proximal to the dorsal root ganglion, e.g. radiculopathies 2. Affects only small, unmyelinated, slower conducting fibers

*Stimulating distal to the lesion before Wallerian degeneration has occurred (3–10 days) can yield normal results.
†Temporal dispersion is due to phase cancellation, and is more prominent in sensory nerve action potentials **(Figure 4-4a)**.
‡Where there is conduction failure in some or all of the motor axons, the compound muscle action potential (CMAP) from a proximal stimulation has a reduced amplitude and area compared with the CMAP recorded from a stimulus distal to the lesion. This is called conduction block (more than 50% reduction, without more than 20% increase in duration) **(Figure 4-4b)**.
NCS, nerve conduction studies; dML, distal motor latency; CV, conduction velocity.

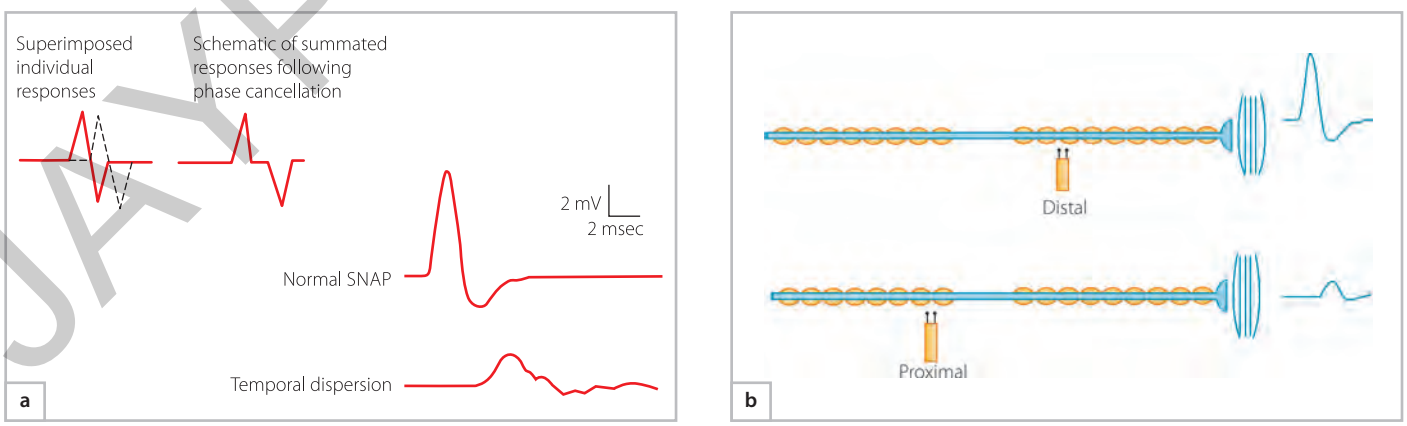

Figure 4.4 (a) In each nerve, fibers conduct at varying speeds, some slower, some faster. With proximal stimulation, as the slower fibers lag further behind the faster fibers, the resulting action potentials created cancel each other out (phase cancellation), resulting in decreased amplitude and increased duration (temporal dispersion). (b) When stimulated across an area of demyelination, the compound muscle action potential (CMAP) of the distal stimulation is normal, whereas the CMAP of the proximal stimulation has reduced amplitude and area due to failure of axonal conduction (conduction block).

JAYPEE BROTHERS

Table 4.4 Common abnormal spontaneous activity

Terminology	Description	Significance
Increased insertional activity	Waveforms resulting from needle movement in the muscle that last >300 ms due to depolarization of muscle fibers	Neuropathic disorders Myopathic (mainly inflammatory) disorders
Fibrillation potentials	Spontaneous depolarization of single muscle fibers	Active denervation in neuropathic disorders (3 weeks–3 months post-injury) Inflammatory myopathies/dystrophies
Positive sharp waves	Spontaneous depolarization of single muscle fibers	Active denervation in neuropathic disorders (3 weeks–3 months post-injury) Inflammatory myopathies/dystrophies
Complex repetitive discharges	Depolarization of single muscle fiber with spread to adjacent denervated fibers	Chronic neuropathic and myopathic disorders
Myotonic discharges	Depolarization of muscle fiber but with waxing and waning of amplitude and frequency	Myotonic dystrophy Myotonia congenita Paramyotonia congenita Myopathies (acid maltase deficiency), polymyositis, and myotubular myopathy Hyperkalemic periodic paralysis
Fasciculations	Spontaneous depolarization of individual motor unit	Amyotrophic lateral sclerosis Radiculopathies Polyneuropathies Entrapment neuropathies Benign fasciculations
Myokymia	Grouped spontaneous repetitive discharges of same motor unit	Radiation injury Hypocalcemia Nerve entrapments Radiculopathy

Table 4.5 Common MUAP terminology

Terminology	Description	Significance
Polyphasic	Increased number of baseline crossings of the MUAP	Neuropathic or myopathic disorders
Satellite potentials	Time-locked potential trailing main MUAP	Early reinnervation*
Recruitment	Addition of more motor units with increasing firing rate (normal ratio of 5:1 for firing frequency: number of firing motor units)	Reduced in neuropathic disorders and end-stage myopathies

*By collateral sprouting from adjacent intact motor units.
MUAP, motor unit action potential.

Interpretation of EMG

The EMG provides information that helps in differentiating between neuropathic versus myopathic disorders, localization of a lesion, determining axonal or demyelinating pathology, chronicity, and presence of re-innervation. In a neuropathic disorder (**Figure 4.5**), the recruitment is reduced (due to loss of MUAPs from axonal loss or conduction block). It may be preserved, if demyelination affects only conduction velocity and the number of MUAPs are preserved. Additionally, there is increased fast-firing of MUAPs (reduced number of MUAPs fire at increased rate to exert same force) and altered MUAP morphology in reinnervation (adjacent intact motor units produce collateral sprouts to denervated muscle fibers, leading to fewer, larger motor units). The EMG differentiation between axonal and demyelinating disorders based on chronicity has been summarized in **Table 4.6**.

ELECTROPHYSIOLOGIC FINDINGS (NCS AND EMG)

The electrophysiologic findings in some common upper limb conditions have been summarized below. In all of these conditions, neurophysiology allows localization of the lesion and helps exclude other PNS disorders mimicking the clinical syndrome. It is important to consider the timing from onset of symptoms when interpreting the NCS and EMG findings (**Table 4.7**).

Carpal tunnel syndrome

Carpal tunnel syndrome (CTS) is diagnosed when a patient has the typical clinical symptoms and signs, associated with median nerve entrapment at the wrist. The compression at the carpal tunnel leads to local ischemia and myelin dysfunction, with resultant slowed conduction velocity (CV) and prolonged latencies on NCS, especially on sensory studies, where sensory fibers have a higher proportion of large myelinated fibers. This may be followed by axonal loss. The PNS differential diagnoses to be considered include proximal median neuropathy (e.g. at elbow), brachial plexopathy (upper trunk), cervical radiculopathy (C_6/$_7$), and polyneuropathy. The NCS findings (**Figure 4.6a** and **4.6b**) in CTS include

- Prolonged sensory and motor latencies
- Slow CVs
- Amplitudes decreased if axonal loss or conduction block present
- Prolonged median F wave latencies

JAYPEE BROTHERS

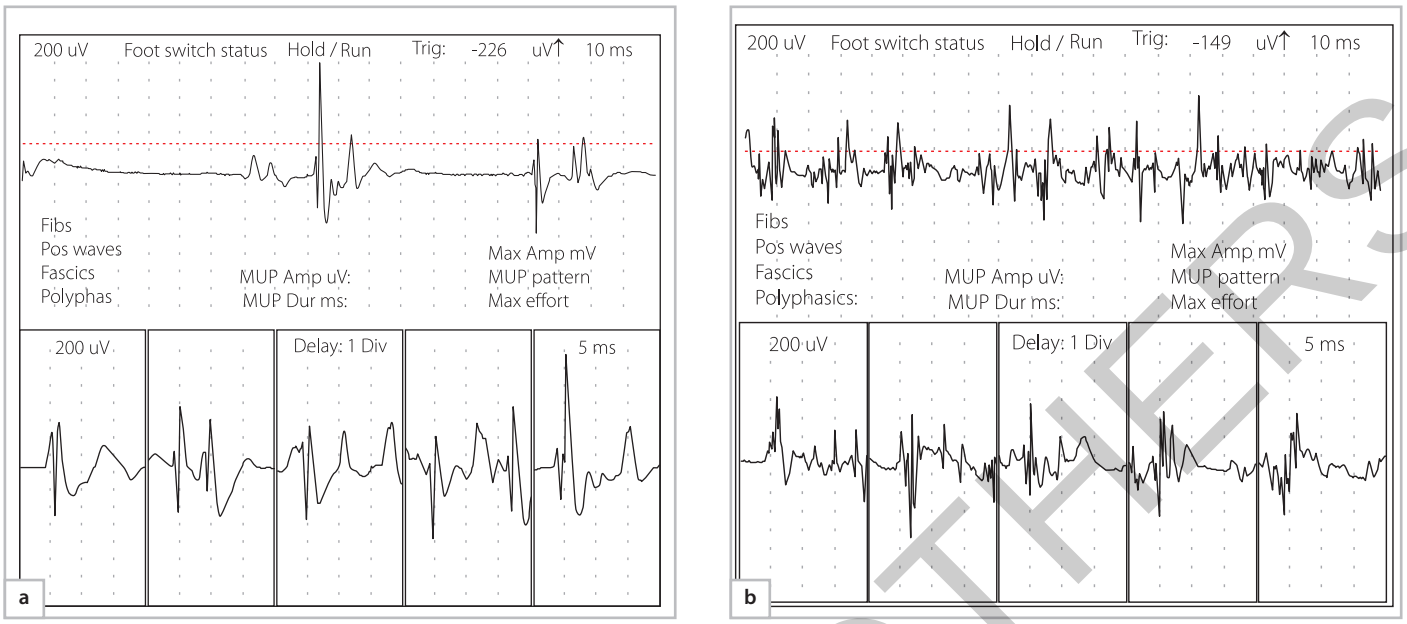

Figure 4.5 (a) Decreased recruitment of motor unit action potentials (MUAPs) due to a neurogenic condition, such as acute nerve damage or neuropraxia. (b) Increased recruitment of MUAPs due to a muscle disease such as myopathy.

Table 4.6 EMG differentiation between axonal and demyelinating disorders

Temporal relationship	Axonal	Demyelinating
Acute	Normal morphology Reduced recruitment Fibrillations, positive sharp waves	Normal morphology (±reduced recruitment)
Chronic with reinnervation	Increased MUAP duration Increased MUAP amplitude Polyphasic Reduced recruitment Satellite potentials Nil spontaneous activity, or complex repetitive discharges	Normal morphology (±reduced recruitment)

MUAP, motor unit action potential; EMG, electromyography.

Table 4.7 The effect of timing on interpretation of electrophysiologic studies

Post-injury/symptoms onset days	Pathological impact on electrophysiologic studies	Interpretation/action
1–10	Wallerian degeneration is still not yet established: be aware that NCS and EMG may be normal	Consider repeat studies, or delaying study till a more suitable time
11–14	Wallerian degeneration established – NCS may be abnormal, or still normal depending on fascicular susceptibility EMG may not show evidence of acute denervation activity, i.e. spontaneous activity of positive sharp waves and fibrillations	May have to repeat studies for conclusive localization
>14	Sufficient time evolved for NCS and EMG abnormalities to manifest	Most accurate information for diagnosis and prognosis

NCS, nerve conduction studies; EMG, electromyography.

- Normal ulnar studies, lateral, and medial antebrachial cutaneous nerve SNAPs, otherwise consider differentials

Additional NCS studies that may be considered in CTS include

- Comparison of median nerve with another nerve – usually median-versus-ulnar comparison
  - Compares the difference in latencies with the recording electrodes equidistant from the stimulating electrodes for both median and ulnar nerves
  - E.g. 2L-INT study (records at the 2nd lumbrical (2L) on stimulating the median nerve, compared with the recording at the interossei (INT) on stimulating the ulnar nerve) (**Figure 4.6c**)
- Inching studies (**Figure 4.6d**)
  - Motor or sensory inching across the wrist at 1-cm intervals to look for an abrupt change in latency or amplitude

The EMG findings in CTS include

- Denervation changes in the abductor pollicis brevis (APB) in more severe cases

JAYPEE BROTHERS

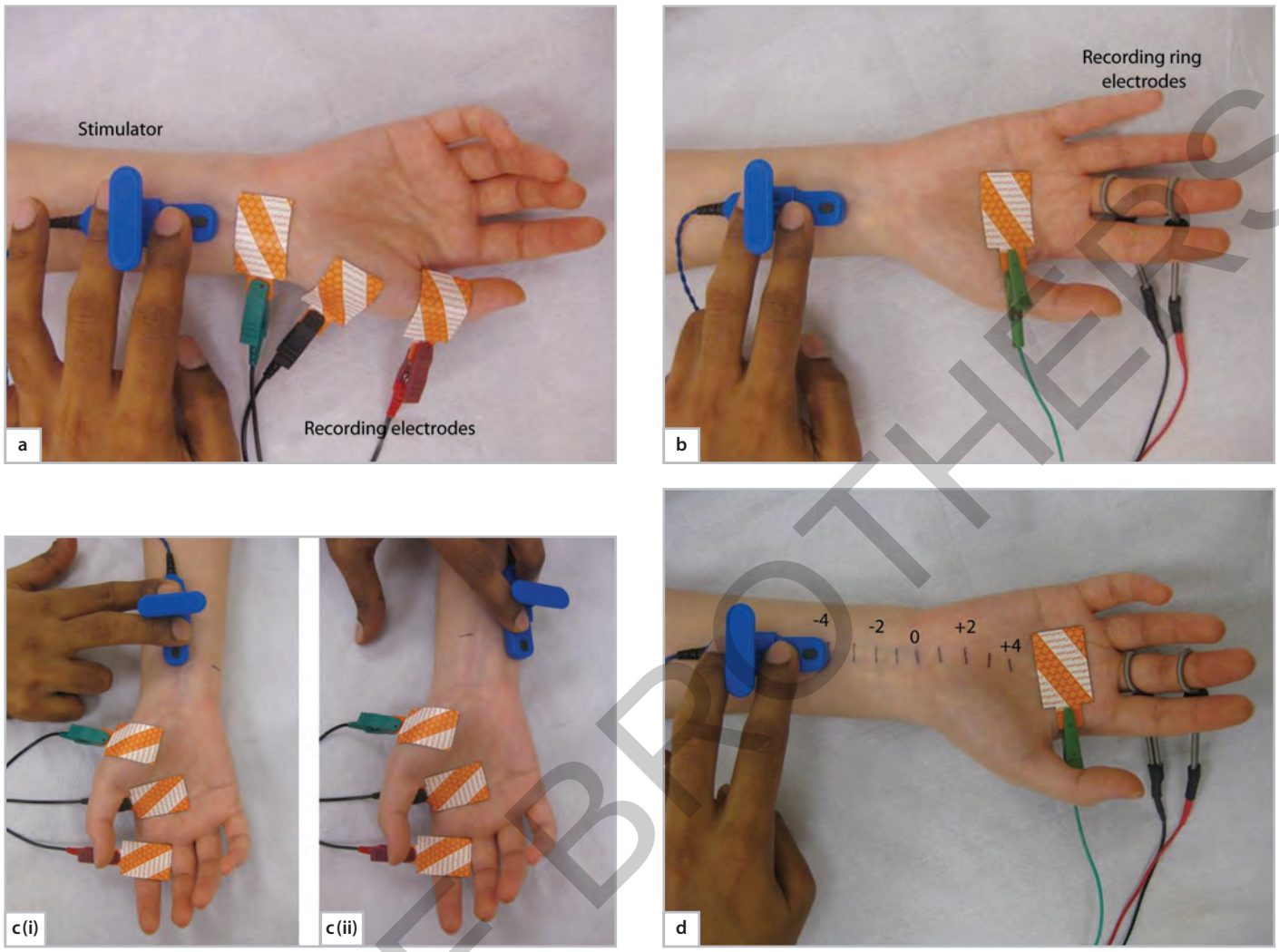

Figure 4.6 (a) Median motor study for carpal tunnel syndrome, stimulating median nerve at wrist, recording electrode over abductor pollicis brevis. (b) Median sensory antidromic study, stimulating over median nerve, recording over middle finger. (c) 2L-INT study, comparing the latencies of (i) (stimulating the median nerve, recording over the 2nd lumbrical, '2L') versus (ii) (stimulating the ulnar nerve, recording over the interossei, 'INT'). (d) Inching studies, stimulating the median nerve at 1 cm intervals looking for an abrupt change in latency or amplitude from the sensory nerve action potential recorded at the middle finger.

- Normal studies in muscles supplied by the median nerve more proximally [flexor carpi radialis (FCR) and pronator teres (PT)]
- Normal studies in C_6/C_7-innervated muscles (PT, triceps, extensor digitorum communis, paraspinal muscles)
- Normal studies in C_8/T_1-innervated muscles [first dorsal interosseous (FDI), extensor indicis pollicis (EIP), paraspinal muscles]

A 7-point scale based on NCS and EMG findings by Bland has been proposed for grading CTS severity. A simplified version is in **Table 4.8**. This scale has been found to correlate with surgical outcomes.

Ulnar neuropathy at the elbow

It is a result of compression or mechanical forces on the ulnar nerve as it passes from the arm to the forearm through the cubital tunnel. Once axonal loss has occurred, it is difficult to localize with NCS alone, and EMG studies are required. The PNS disorder differentials to be considered include ulnar neuropathy at other sites (wrist, rarely forearm), brachial plexopathy (lower trunk or medial cord), cervical radiculopathy (C_8/T_1), and polyneuropathy. The NCS is conducted with the arm in a flexed position (approximately 100°), to stretch out the nerve to its maximal length with stimulation above and below the elbow. The NCS findings in ulnar nerve neuropathy at the elbow (**Figure 4.7a** and **4.7b**) include

- Focal demyelinating lesion:
  - Conduction block: drop in amplitude of the CMAP below the elbow compared with above
  - Reduction of CV: Slowing across the elbow compared with the forearm segment
- Axonal loss: unable to localize – small CMAP amplitudes throughout

Additional NCS studies that may be considered in ulnar nerve neuropathy at the elbow include

- Recording from the FDI, which can increase diagnostic yield due to different fascicle bundles within the same nerve being affected to different degrees (differential fascicular susceptibility)
- Record dorsal cutaneous ulnar nerve SNAP: This sensory branch arises proximal to the wrist, so its absence denotes a lesion above the wrist

JAYPEE BROTHERS

Table 4.8 Grading of the severity of CTS based on electrophysiologic studies

Grade	NCS findings	EMG findings
Mild	Isolated prolonged sensory latencies Normal motor studies	Normal
Moderate	Isolated prolonged sensory latencies Isolated prolonged distal motor latency	Normal
Severe (evidence of axonal loss)	Absent/low amplitude SNAP Absent/low amplitude CMAP	Fibrillations Altered MUAP morphology

CTS, carpal tunnel syndrome; NCS, nerve conduction studies; SNAP, sensory nerve action potential; MUAP, motor unit action potential; CMAP, compound muscle action potential; EMG, electromyography.

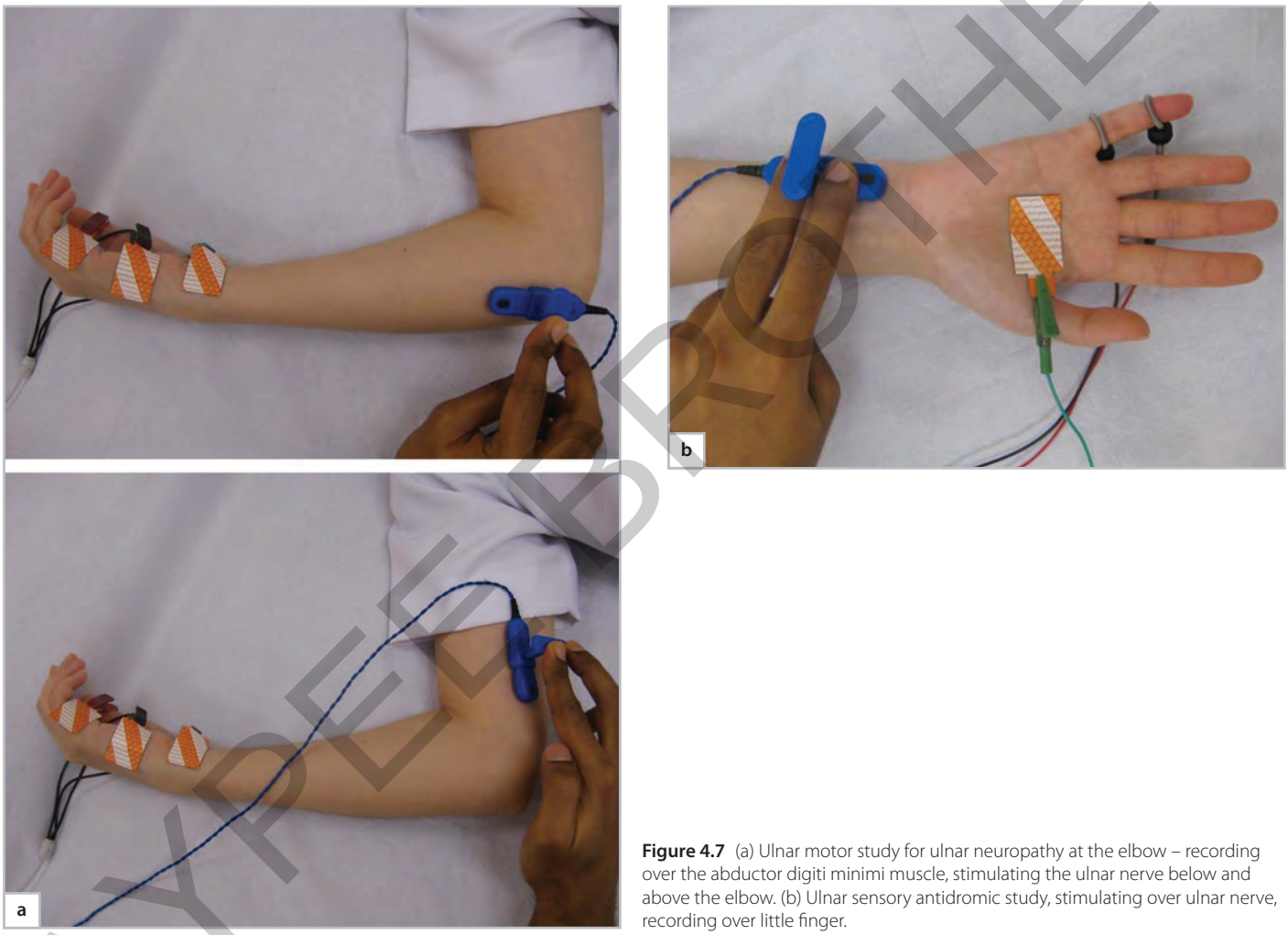

Figure 4.7 (a) Ulnar motor study for ulnar neuropathy at the elbow – recording over the abductor digiti minimi muscle, stimulating the ulnar nerve below and above the elbow. (b) Ulnar sensory antidromic study, stimulating over ulnar nerve, recording over little finger.

The EMG findings in ulnar neuropathy at the elbow include

- Abnormal study in ulnar-innervated muscles: FDI, flexor digitorum profundus to digit 4 and 5, abductor digiti minimi
  - Flexor carpi ulnaris may be normal due to differential fascicular susceptibility
- Normal C8/T1-innervated muscles: APB, flexor pollicis longus, EIP, paraspinal muscles

Radial nerve palsy at the spiral groove

It is the most common site of radial neuropathy and usually results from compression against the humerus from immobilization, e.g. arm hanging over the chair while asleep or drunk! ('Saturday night palsy'). This can also be caused by a fracture of the humerus. The PNS disorder

JAYPEE BROTHERS

differentials include radial neuropathy at other sites (i.e. axilla), posterior interosseous neuropathy (distal to the lateral epicondyle), brachial plexopathy (posterior cord), cervical radiculopathy ($C_7/_8$), and polyneuropathy. The radial nerve is stimulated above and below the spiral groove and recording is taken from the extensor indicis proprius. NCS findings (**Figure 4.8a** and **4.8b**) include

- Demyelinating lesion: temporal dispersion, conduction block across the spiral groove
- Axonal loss: diminished CMAP amplitudes throughout – will need EMG studies for further localization

Additional NCS studies that may be considered

- Superficial radial sensory nerve study: stimulating nerve over the radius, recording over the extensor tendons to the thumb
  - If absent: axonal loss has occurred
  - If present:
    - Wallerian degeneration has not yet occurred OR
    - Demyelinating pathology OR
    - Posterior interosseous neuropathy

The EMG findings in radial nerve palsy at the spiral groove include

- Abnormal study of muscles supplied by the posterior interosseous nerve: extensor indicis proprius, extensor carpi ulnaris, extensor digitorum communis
- Abnormal study of muscles supplied by nerve distal to the spiral groove: brachioradialis, long head of extensor carpi radialis, supinator muscle
- Normal study of muscles proximal to the spiral groove: triceps
- Normal study of posterior-cord innervated muscles: deltoid, latissimus dorsi
- Normal study of C_7-innervated muscles: FCR, PT, flexor digitorum sublimis, paraspinal muscles

PERIPHERAL NERVE US

US waves are sound waves of a high frequency (>20,000 Hz). The frequency ranges used in medical US range from 2 to 20 MHz. The increasing frequency of US transducers provides better image resolution, but with reduced penetrative ability. For imaging the PNS, US requires frequencies anywhere from 10 to 18 MHz. A generous amount of acoustic coupling gel is required to minimize artifacts from air–skin interface during this study. The advantages of US include easy accessibility, low cost, real time images, and better resolution (than MRI) of peripheral nerves. The main disadvantage is that there is poorer image resolution with deeper imaging, e.g. sciatic nerve.

US imaging technique

In US, B-mode imaging and color Doppler flow imaging are commonly used. In B-mode imaging, transverse and longitudinal images are obtained, allowing assessment of the cross-sectional area (CSA) or diameter, fascicular structure (presence of disruption),

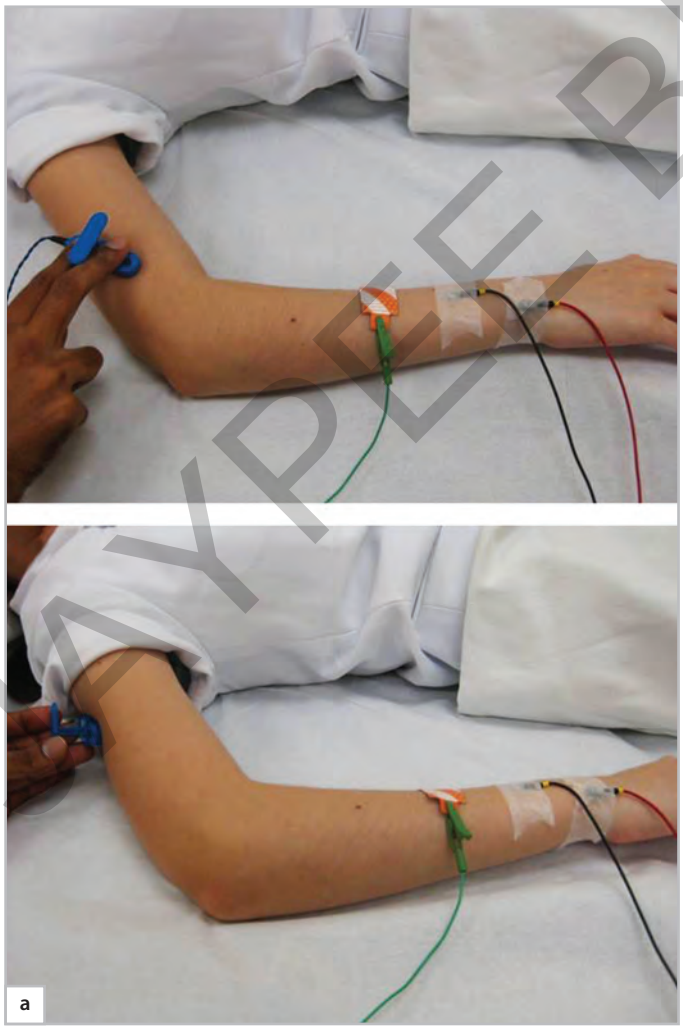

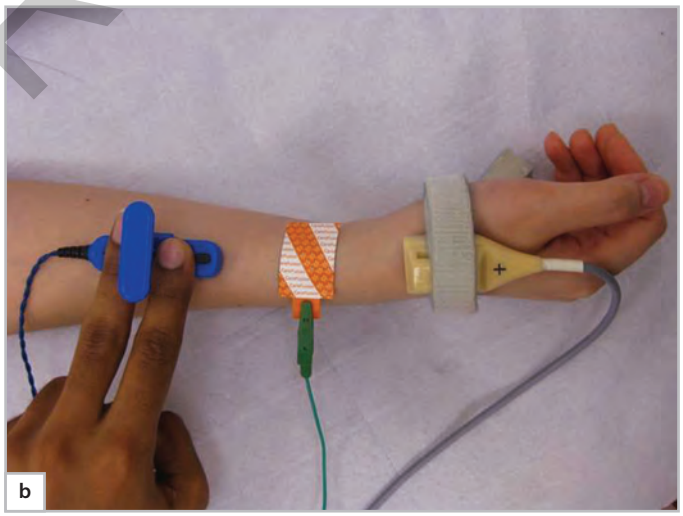

Figure 4.8 (a) Radial motor study across sulcus spiralis, stimulating below and above (b) the spiral groove, recording over extensor indicis proprius. Radial sensory study, stimulating radial nerve over the radius, recording over the radial sensory nerve that is over the thumb extensor tendons.

JAYPEE BROTHERS

and echotexture (hypo/hyperintensity). In color Doppler flow imaging, blood flow to the nerve and the surrounding tissues is assessed. In general, transverse imaging is better in identifying focal swelling of nerve fascicles, whereas longitudinal imaging looks for sudden change in diameter of nerve. Doppler flow can be useful in diagnosis of entrapments, inflammatory lesions, postoperative states, and tumors. The findings are compared against the unaffected contralateral side and laboratory-specific normal values (population norms). The features of normal peripheral nerves include (**Figure 4.9a** and **4.9b**)

- More echogenicity than muscles but less so than tendons
- Honeycomb appearance (fascicular structures seen on transverse view)
- Less mobility than tendons

US findings

The US features that suggest nerve anomalies/entrapment include

- Change in CSA:
  - Just proximal to entrapment: increased CSA
  - At entrapment: nerve is flattened
- Change in echotexture:
  - Loss of fascicular discrimination due to nerve edema
- Color Doppler flow
  - Increased nerve blood flow, usually just proximal to entrapment

Carpal tunnel syndrome

US position: transverse and longitudinal scans over the wrist, with arm supinated (**Figure 4.10**).

Sonographic features:

- Enlarged nerve proximal to entrapment (cut-off of 10 mm^2 CSA)
- Loss of median nerve fascicular discrimination (**Figure 4.11**)
- Abrupt change of median nerve caliber (notch sign) (**Figure 4.12**)
- Increased intra- and perineural vascularization (**Figure 4.13**)

Additional US features:

- Detects secondary causes of CTS, e.g. tumors and ganglia
- Detects persistent median artery, which may accompany anatomical variants of median nerve, e.g. bifid nerve

Overall, sensitivity of US for CTS is 77.6%, specificity 86.8%.

Cubital tunnel syndrome

US position: arm extended, to limit traction on ulnar nerve during flexion resulting in nerve flattening in normal subjects (**Figure 4.14**). The nerve is adjacent to the medial epicondyle at level of ulnar groove.

Sonographic features (**Figure 4.15**):

- Increased CSA anywhere along ulnar nerve segment from 4 cm proximal to 4 cm distal to the medial epicondyle (cut-off of 10 mm^2 CSA)
- Thickened cubital tunnel retinaculum
- Loss of fascicular discrimination

Additional useful US features:

- Edema in surrounding soft tissue
- Luxation or subluxation of nerve: during elbow flexion, the ulnar nerve either moves to the tip of the medial epicondyle (subluxation); or over the epicondyle (luxation). This recurrent movement results in wear and tear to the nerve causing ulnar neuropathy at the elbow. Presence of luxation/subluxation affects surgical approach. Note that subluxation or luxation also occurs in healthy controls, so this finding needs clinical interpretation

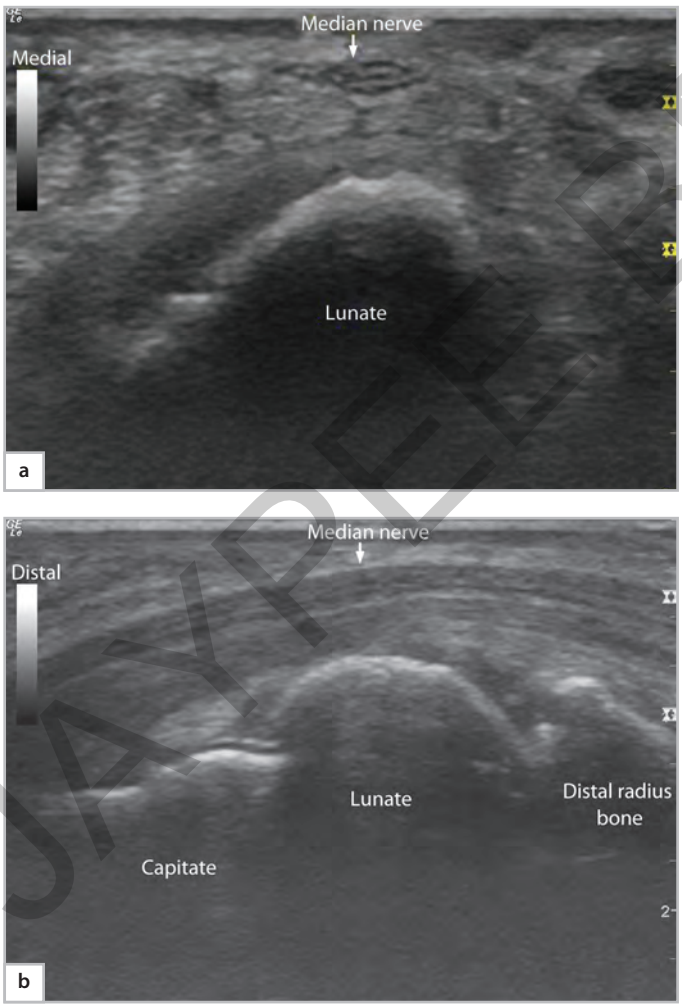

Figure 4.9 (a) Transverse image of a normal median nerve. Note the honeycomb appearance of the fascicles within the nerve. (b) Longitudinal image of a normal median nerve.

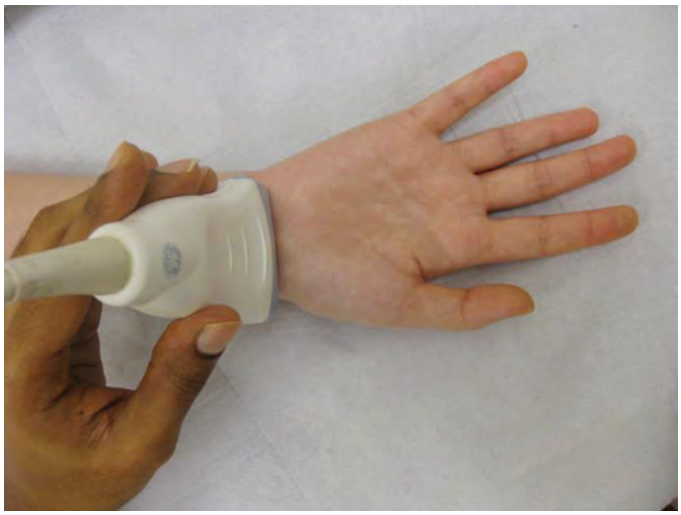

Figure 4.10 Imaging for carpal tunnel syndrome – transverse imaging over patient's wrist, arm supinated.

JAYPEE BROTHERS

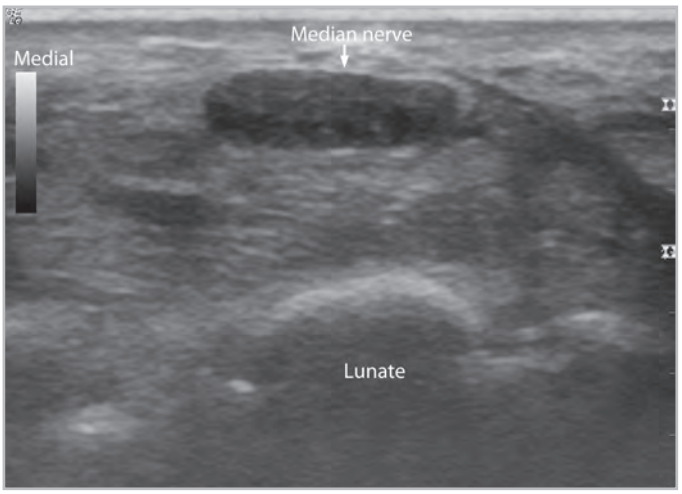

Figure 4.11 Sonographic appearance of median nerve at the wrist in a patient with carpal tunnel syndrome. Note the enlarged nerve, with loss of fascicular discrimination.

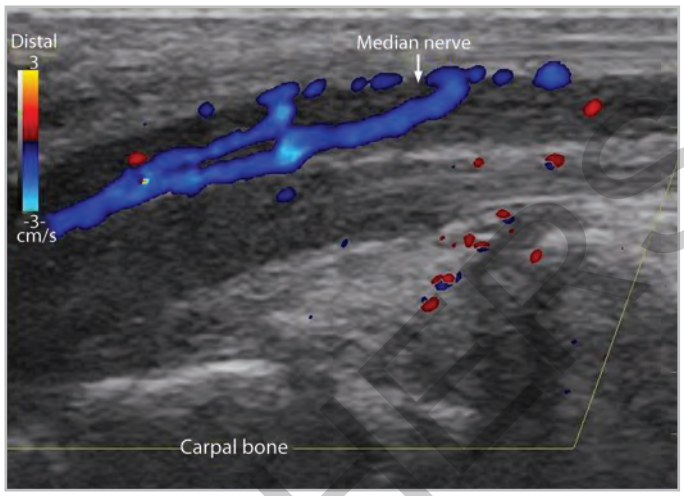

Figure 4.13 Longitudinal image of the median nerve with color Doppler flow imaging showing increase in intra- and perineural vascularization.

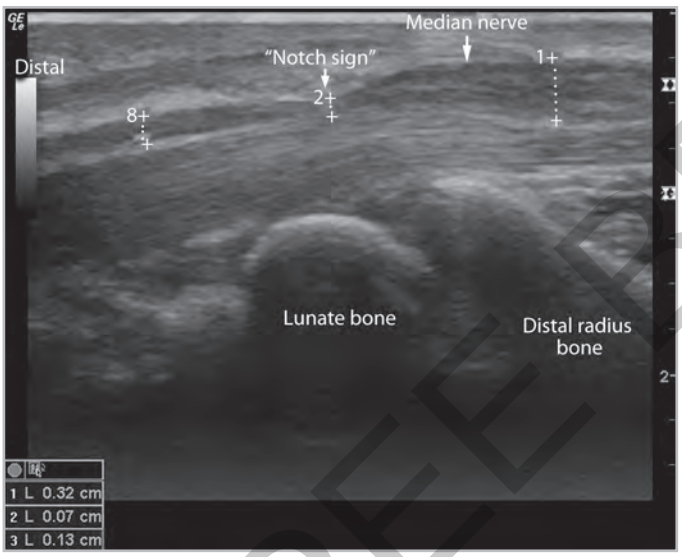

Figure 4.12 Longitudinal image of the median nerve showing the 'notch sign' where there is an abrupt change in caliber.



Figure 4.14 Sonography of ulnar nerve at cubital tunnel, with arm in extended position.

- Masses like ganglia, osteophytes, tumors, and rare reports of lymphoma, intraneural perineurioma, etc.

The sensitivity of US for the diagnosis of ulnar nerve compression at the elbow is generally >80%.

Radial neuropathy at the spiral groove

US position: The nerve is detected at mid-humerus level and color Doppler is used to identify the deep brachial artery as a guide.

Sonographic features of radial neuropathy are relatively less well-studied, with laboratory-specific CSA cut-offs. The features include:

- Swelling proximal to compression site
- Hypoechogenicity with loss of fascicular discrimination
- Increased epineural vascularity

Additional US features:

- Etiology – neuroma, etc.
- Assesses continuity of nerve, e.g. for nerve trauma

Nerve trauma

The sonographic features suggesting nerve trauma include

- Axonal swelling
- Nerve discontinuity
- Neuroma formation (**Figure 4.16**)

US is used as a complementary investigation with electrodiagnostic studies:

- Aids in differentiating complete nerve transection versus partial discontinuity

JAYPEE BROTHERS

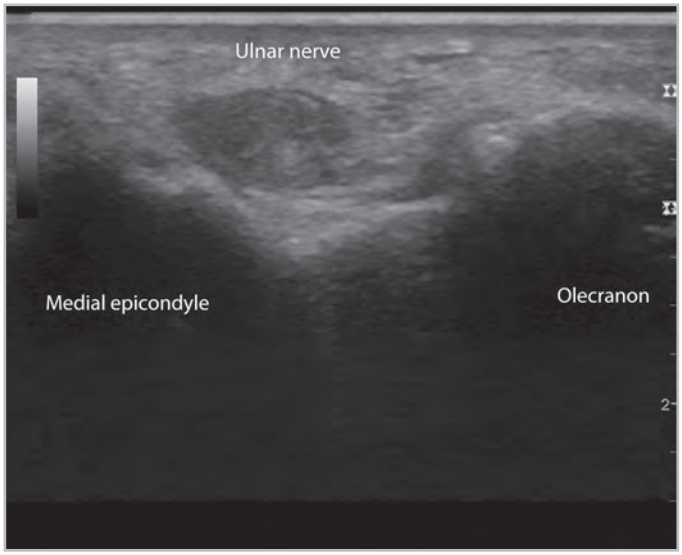

Figure 4.15 Sonography of the ulnar nerve at the cubital tunnel in a patient with cubital tunnel syndrome. Note the enlarged nerve with loss of fascicular discrimination.

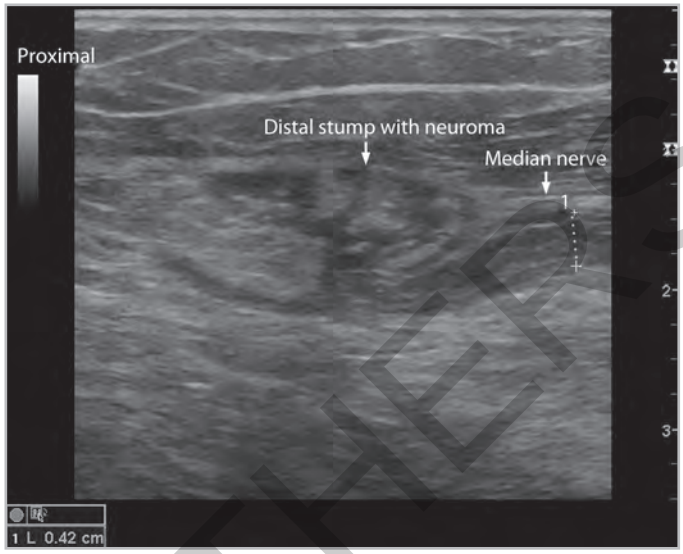

Figure 4.16 Nerve discontinuity and neuroma formation of the median nerve in the forearm following nerve trauma.

- Obtains information immediately and considerably earlier than electrodiagnostic studies (EDx), due to time lag required for visible changes in the NCS and EMG
- Aids in early decision for surgical versus conservative treatment
- Aids in localizing lesion

Nerve tumors

Some of the common nerve tumors that have been described using US include schwannomas and neurofibromas. US determines the location of the tumor (intra versus extra-neural), extent of vascularity, and consistency (cystic or solid).

Nerve inflammation

Well described in chronic demyelinating neuropathies, e.g. Charcot–Marie–Tooth 1A, chronic inflammatory demyelinating polyneuropathy (CIDP), and multifocal motor neuropathy. US shows a marked increase in nerve size from inflammatory cells and edema outside typical sites of nerve entrapment. In Hansens disease (leprosy), a multifocal inflammatory disease, the nerves appear focally enlarged, with increased vascularity.

Role of US in comparison with electrodiagnostic studies for assessing nerve diseases

US has a complementary role and can impact diagnostic and therapeutic decisions in approximately 40% of cases, with confirmatory role in 40%. It enhances diagnostic information and follow-up provided by EDx by providing information on nerve morphology and surrounding structures.

SUGGESTED READING

Beekman R, van der Plas JP, Uitdehaag BM, et al. Clinical, electrodiagnostic, and sonographic studies in ulnar neuropathy at the elbow. Muscle Nerve 2004; 30:202–208.
Good review of what is known (and not known) in the evaluation of ulnar neuropathy.

Daube JR, Rubin DI. Needle electromyography. Muscle Nerve 2009; 39:244–270.
Excellent and detailed review on the principles and uses of EMG in peripheral nerve and muscle disorders.

Fowler JR, Gaughan JP, Ilyas AM. The sensitivity and specificity of ultrasound for the diagnosis of carpal tunnel syndrome: a meta-analysis. *Clin Orthop Relat Res* 2011; 469:1089–1094.
Timely meta-analysis of the value of ultrasound in the evaluation of CTS. The paper emphasizes the need for a structured approach to ultrasound investigation of entrapments.

Padua L, Liotta G, Di Pasquale A, et al. Contribution of ultrasound in the assessment of nerve diseases. Eur J Neurol 2012; 19:47–54.
In this article, the authors assess the practical value of adding ultrasound to the routine neurophysiological examination of peripheral nerve disorders.

Werber RA, Andaray M. Electrodiagnostic evaluation of carpal tunnel syndrome. Muscle Nerve 2011; 44:597–607.
All you need to know in the evaluation of CTS using nerve conductions.

JAYPEE BROTHERS

ESSENTIALS OF HAND SURGERY

Essentials of Hand Surgery is a practical, comprehensive manual for the diagnosis and surgical management of hand and upper limb disorders. It covers the core knowledge required by trainee surgeons, delivered in an easy-to-understand format and with an emphasis on modern treatments that will yield optimal outcomes.

The first section of the book reviews the relevant functional anatomy, imaging studies and principles of treatment that underpin the practice of hand surgery. The subsequent two sections give a comprehensive overview of examination and surgical techniques, organized by timing: eleven chapters on trauma management and ten on elective surgery. The emphasis throughout is on the provision of a clear, authoritative guide to the management of the more common hand and upper limb conditions that affect hand function.

- Provides trainee hand, orthopaedic and plastic surgeons with a lavishly illustrated guide to the diagnosis and management of hand and upper limb conditions requiring emergency or elective surgery
- Includes core principles of anatomy, imaging and therapeutics as well as practical, step-by-step guidance on a wide range of surgical techniques
- Easy-access information, written in a concise style with high-quality clinical photographs and descriptive artworks

JAYPEE BROTHERS

JP medical publishers
www.jpmedpub.com

ISBN 978-1-907816-32-1
9 781907 816321