


THE DIABETIC FOOT

Robert J Hinchliffe
Nicolaas C Schaper
Matt M Thompson
Ramesh K Tripathi
Carlos H Timaran

JP

Contents

Preface v

Contributors xi

Introduction xvii
Karel Bakker

SECTION 1: GENERAL ASPECTS

Chapter 1
Epidemiology of diabetic foot disease and etiology of ulceration 3
Jan Apelqvist

Chapter 2
Diabetic foot assessment and classification of risk 11
David G. Armstrong, Nicholas A. Giovinco, Magdiel Trinidad-Hernandez

Chapter 3
Setting up a diabetic foot service 21
Abdul Basit

Chapter 4
Economic aspects of foot care 27
Marion Kerr

Chapter 5
Medical therapy and metabolic control to optimize cardiovascular risk and reduce overall mortality 33
Jack R. W. Brownrigg, Kausik K. Ray

Chapter 6
Psychological aspects of diabetes-related foot disease 39
George Peach, Robert J. Hinchliffe

Chapter 7
Diabetes self-management education for the preservation of patient and foot health and the prevention of foot ulcers and amputations 45
Kristien Van Acker, Neil Baker

SECTION 2: INFECTION

Chapter 8
Managing infection in the diabetic foot 57
Edgar J. G. Peters, Benjamin A. Lipsky

Chapter 9
Diabetic foot osteomyelitis: diagnosis and classification 69
Eric M. Senneville

Chapter 10
Osteomyelitis: medical management 75
John M. A. Embil, Elly Trepman

Chapter 11
Osteomyelitis: surgical management 79
F. Javier Aragón Sánchez

SECTION 3: ISCHEMIA

Chapter 12
Peripheral arterial disease in diabetes 95
Carlos H. Timaran, David E. Timaran

Chapter 13
Microvascular disease 101
Sanjeev Sharma, Gerry Rayman

Chapter 14
The diagnosis of peripheral arterial disease 111
Patrick Coughlin

Chapter 15
Imaging of peripheral arterial disease 117
Gerard S. Goh

Chapter 16
Angiosomes 129
Neil C. Wright, Robert Fitridge

Chapter 17
Distal bypass techniques 137
Himanshu Verma, Robbie K. George, Ramesh K. Tripathi

Chapter 18
Angioplasty techniques 153
Ezio Faglia, Giacomo Clerici, Flavio Airoldi

Chapter 19
Outcomes of angioplasty and bypass in diabetes 171
Robert J. Hinchliffe, Keith G. Jones, Rachael O. Forsythe

SECTION 4: NEUROPATHY

Chapter 20
Pathobiology of neuropathy 183
Ketan Dhatariya

Chapter 21
The diagnosis and clinical impact of diabetic distal symmetrical polyneuropathy 193
Nicolaas C. Schaper, Solomon Tesfaye

Chapter 22
Surgical treatment of diabetic neuropathy 201
A. Lee Dellon

SECTION 5: WOUNDS AND ULCERATION

Chapter 23
Acute and chronic wound healing biology in diabetes 209
Michelle Griffin, Ardeshir Bayat

Chapter 24
Scoring systems and assessment of the ulcerated foot 223
Fran Game

Chapter 25
Wound dressings and debridement 231
Elizabeth J. Mudge, Alastair J. Richards, Keith G. Harding

Chapter 26
Adjuncts to wound healing 243
Magnus Löndahl

Chapter 27
Standardization of outcomes and end points of wound healing in everyday practice and clinical trials 251
Finn Gottrup

SECTION 6: SURGICAL INTERVENTION

Chapter 28
Surgical anatomy of the foot 259
Adam Ajis

Chapter 29
Surgical debridement 267
Peter Vowden, Soroush Sohrabi

Chapter 30
Skin and local tissue flaps 273
Crystal L. Ramanujam, John J. Stapleton, Thomas Zgonis

Chapter 31
Free tissue transfer 283
Joon Pio Hong

SECTION 7: CHARCOT

Chapter 32
The causes and diagnosis of acute Charcot foot in diabetes 297
William Jeffcoate

Chapter 33
Charcot osteoarthropathy: medical management and off-loading 303
Valeria Ruotolo, Luigi Uccioli

Chapter 34
Charcot osteoarthropathy: surgical management and off-loading 311
Katherine M. Raspovic, Dane K. Wukich

SECTION 8: AMPUTATION

Chapter 35
Minor amputation and major amputation 321
Yiu-Che Chan, Stephen W. Cheng

Chapter 36
Rehabilitation post-amputation 333
S. Sooriakumaran

SECTION 9: BIOMECHANICS AND PREVENTION

Chapter 37
Off-loading 345
Martin C. Berli, Thomas Böni

Chapter 38
Prevention of ulcer recurrence 353
Sicco A. Bus

Chapter 39
Preventive foot care programs 361
Zulfiqarali G. Abbas

Index 369

Chapter 2 Diabetic foot assessment and classification of risk

David G. Armstrong, Nicholas A. Giovinco, Magdiel Trinidad-Hernandez

SUMMARY

- The risk of foot ulceration may be stratified by simple clinical examination
- Always examine the patient standing and walking
- Regular clinical assessment (screening) of the foot is important
- The 10G monofilament is a simple tool to reliably identify neuropathy
- Any patient with diabetes attending hospital requires a clinical foot examination

BACKGROUND AND HISTORY

Despite, and in many ways because of, advances in public health, diabetes has continued to increase over the past 90 years. According to the United States' Centers for Disease Control and Prevention, nearly 8% of the US population alone has some form of diabetes. The rate of new diagnoses tops 1.6 million annually (Centers for Disease Control & Prevention- National Diabetes Fact Sheet 2008, World Health Organization 2009). In 2009, the leading cause of death became, for the first time, noncommunicable disease, of which diabetes is a significant proportion. Diabetes alone accounts for 6.8% of global all-cause mortality in persons between 20 and 79 years of age. It appears that this number is climbing (Unwin et al. 2010).

Many common complications of diabetes manifest in the periphery. This is particularly true of the lower extremity. Indeed, the lifetime risk of developing a wound on the foot may be conservatively placed at 25% (Singh et al. 2005). This is part of what might be considered a 'stairway' to amputation, which begins with development of diabetes, leading to loss of protective sensation (LOPS) (neuropathy), loss of integument (ulcer), loss of ability to protect against infection, frequent loss of sufficient outflow, and loss of limb. This is graphically illustrated in **Figure 2.1**.

PATHOPHYSIOLOGY

Mechanically and functionally, the human foot is a multitissue composite structure. It is remarkably unique and serves a variety of roles, predominantly sensory and locomotory. Because of this complexity of function and potential for pathological dysfunction or imbalance, initial evaluation of the human foot should consist of a thorough, multicomponent examination in order to isolate specific elements of a patient in order to prevent and treat diabetic foot complications. While it is not necessary for this thorough evaluation to be burdensome or extensively time consuming, it should cover a variety of key areas. These include assessment of blood flow, assessment for LOPS, assessment of the integument, and assessment of the musculoskeletal system and, as necessary, shoe gear. Before addressing this, we will address frequent patterns of pathology prevalent in people with diabetes that may lead to amputation.

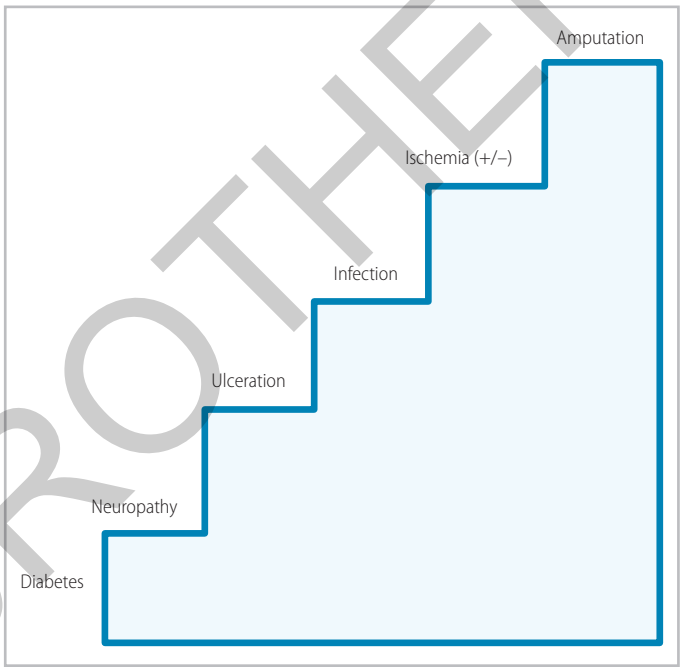

Figure 2.1 Stairway to amputation. From Rogers et al. (2010).

ANGIOPATHY

In combination with the risk factors for ulceration discussed above, the presence of vascular occlusive disease increases the risk of potential amputation. Vascular disease is a common finding in individuals with long-standing diabetes. While vascular insufficiency alone is not usually the primary cause of ulceration, inadequate perfusion can inhibit ulcer healing, leading to further tissue necrosis and the inability to clear infection. **Table 2.1** provides a list of other potential risk factors for amputation. Most cases of vascular disease in individuals with diabetes, interestingly, affect the infrapopliteal vessels with relative sparing of the pedal vessels. In many instances, this allows for a distal bypass to a pedal target artery in order to increase the blood flow to the foot. The vascular examination is addressed in further detail later in this chapter.

NEUROPATHY

Neuropathy, which results in a LOPS of the lower extremity, is the predominant etiology for diabetic foot ulceration. The 'gift of pain' is a natural, nociceptor mediated, defense against tissue trauma

JAYPEE BROTHERS

Table 2.1 Risk factors for amputation

Peripheral neuropathy (LOPS)
Vascular insufficiency (PAD)
Infection
Structural foot deformity
Trauma
History of prior foot ulcer or amputation
Charcot foot
Poor glycemic control
Older age
Male gender
Ethnicity (higher in Hispanics and African-Americans)

LOPS, loss of protective sensation; PAD, peripheral arterial disease.

and sensation of a hazardous environment (Yancey & Brand 1997). Without protective sensation, the patient is at a markedly increased risk of serious complications, which may result in loss of limb or life. Peripheral neuropathy can be evaluated as distinct subcategories, such as sensory, motor, and autonomic, but are often witnessed in concert with varying extent of functional compromise. Sensory neuropathy is a symmetric loss of temperature, vibration, pressure, and/or light touch sensation. This often begins distally in the toes and forefoot region, and will progress toward the hindfoot or ankle. More advanced losses will progress toward the proximal lower leg and beyond. The earlier stages of this condition within the foot will resemble a 'stocking and glove' distribution, whereby patients will report numbness or dysthesthesia (abnormal and frequently painful sensations) comparable with a low riding stocking over the foot.

Motor neuropathy is the progressive loss of motor function and control with an eventual imbalance of biomechanical stability and foot posture. Distal, intrinsic foot muscle will lose muscle mass and contractile strength first, which will lead to recruitment and compensation of extrinsic muscles of the leg during ambulation. This, combined with tissue tightness at the joints, will result in several common architectural misalignments such as hammertoe, claw toe, and plantar flexion deformities of the metatarsals. These deformities can cause an increase in focal pressure at the areas of the interphalangeal joints of the digits and beneath the metatarsal heads, respectively, increasing the probability of an ulcer formation from these bony prominences.

Autonomic neuropathy is associated with pathology of the sympathetic nervous system. In the lower extremity, this usually results in the absence of sweat production, inappropriate temperature regulation, and eventual dermatological complications such as drying and scaling of the skin, which increase the likelihood of cracking and fissuring. These cracks or fissures, especially in the heel, may then serve as a portal of entry for bacteria, increasing the chances of developing an infection. Other factors precipitating diabetic foot ulcers have been identified and are listed in (**Table 2.2**) (Boulton et al. 2008).

Table 2.2 Risk factors for ulceration

General or systemic factors	Local factors
Uncontrolled hyperglycemia	Peripheral neuropathy
Duration of diabetes	Structural foot deformity
Peripheral arterial disease	Limited joint range of motion
Older age	Trauma
Chronic renal disease	Improperly fitted shoes
Blindness or visual loss	Callus
	Prolonged elevated focal pressure
	History of previous ulcer or amputation

STRUCTURAL ABNORMALITIES/ GAIT ABNORMALITIES

Through a variety of means, structural derangements of the foot and ankle can be a potential cause of increased pressure and subsequent skin breakdown. The development of foot ulceration is often based on a biomechanical etiology (Frykberg et al. 2000, Lavery et al. 2006). It is important to evaluate both feet and shoe gear, of a patient when possible. As described earlier, motor neuropathy can lead to the loss of functional intrinsic foot musculature causing a deformity (and subsequent overpowering of the intrinsic muscles by the larger extrinsic lower leg muscles). Identification of any of the following contractures will assist in prevention of a potential ulceration: hammertoe (**Figure 2.2**), claw toe, bunion, tailor's bunion (bunionette), hallux limitus/rigidus, flat feet, high arched feet, Charcot deformities, or any postsurgical deformities such as amputations and subsequent further muscular imbalance.

Limited joint and soft tissue mobility should also be evaluated as it can cause an increase in vertical and shear force in certain areas, such as the plantar hallux (**Figure 2.3**), and lead to hypertrophic callosities, preulcerative changes, and tissue breakdown. The Achilles tendon should be evaluated for any type of functional contracture causing equinus deformity (**Figure 2.4**). It is common to find an increase in



Figure 2.2 Hammertoe.



Figure 2.3 Plantar hallux.

JAYPEE BROTHERS



Figure 2.4 Equinus deformity.

glycosylation of soft tissues and tendons causing contracture of the muscles in the posterior compartment of the leg (Armstrong et al. 1999, Giacomozzi et al. 2005, Grant et al. 2005). This, along with a relatively high body mass index (BMI) will cause an increase in plantar pressures in the forefoot and heel, making these areas more prone to breakdown.

Gait evaluation and muscle testing should also be conducted to evaluate any potential abnormality with ambulation and muscle strength. Thorough evaluation of the muscles in the lower extremity should be done both actively and passively, weight bearing and nonweight bearing in order to gain a more accurate perception of the patient's condition. Plantar foot pressures can also be assessed with the use of a variety of pressure sensitive and pressure recording devices, such as a Harris ink mat. Although these may not always be available, a careful inspection of wear patterns of the inner and outer soles of the patient's footwear can illustrate a great deal of information to the observer.

SCREENING

History and visual screening

A thorough history and physical examination of each patient who presents with a diabetic foot complication are important and should always be obtained at initial patient visit or at the time of a significant change in status. The touchstone datum to consider when obtaining a history includes previous pedal wounds, history of prior amputations, and lower extremity vascular interventions (Boulton et al. 2008, Rogers & Armstrong 2009). A physical examination should always include assessment in at least four of the following categories: biomechanical position and function, neurological status, vascular status, and dermatological presentation.

It is important to remove both shoes and socks for adequate examination. A systematic approach should be taken in order to avoid missing any important aspects of the examination. All surfaces of the foot and ankle should be evaluated including the nails, digits, interdigital webspaces, subdigital sulci, the soles, and the heels, inspecting for cracks, blisters or bullae, hyper/hypopigmentation, fissuring, calluses, macerations, and ulcers. **Figure 2.5** demonstrates an interdigital examination, with significant maceration and secondary infection. The shoe gear should also be inspected for signs



Figure 2.5 An interdigital examination, with significant maceration and secondary infection.

of wear patterns, foreign bodies, and any irregularities. In addition to any gross deformities as described above, malodor, debris, and drainage can be identified during this rapid visual screening (Boulton et al. 2008).

Neurological examination

As stated earlier, peripheral sensory neuropathy and the subsequent LOPS are major risk factors for the development of a diabetic foot complication. Several noninvasive examinations that can be performed to assess the neurological status of a patient, starting with historian, account for neuropathic symptoms such as tingling, burning, numbness, and the feeling of insects crawling on the feet (formication). This may help to identify the onset and progression of neuropathy in those patients at risk of developing foot ulceration (Armstrong & Quebedeaux 1998).

Monofilament testing

One of the most inexpensive and ubiquitous methods used to assess neuropathy is the use of the 10-g Semmes–Weinstein monofilament (Armstrong et al. 1998, Boulton et al. 2008) This technique employs the use of a nylon monofilament, which is placed on 10 different predetermined locations on the foot and pressed down manually until there is a slight bend in the wire. The patient is instructed to say 'yes' if he or she thinks they feel slight pressure or sensation. Loss of accurate sensation to two or more of these 10 locations is clinically positive for neuropathic LOPS.

Vibration testing

Vibratory perception testing can be assessed utilizing several different modalities. The more traditional method of testing is by the use of a 128-Hz tuning fork. The tuning fork is struck and then placed on a prominent bony surface of the foot, such as the great toe or metatarsal head, malleoli or tibial tuberosity. The patient is instructed to identify when the vibration stops. Loss of vibratory sensation at one distal location merits evaluation at the next proximal surface in order to evaluate the locality of compromised sensation.

Alternatively, a vibratory perception threshold monitor (**Figure 2.6**) can be used to test for vibration perception, by means of threshold detection range. The instrument consists of a hand piece with a testing probe on the end, a motor, rheostat, and voltmeter. The probe is held gently on the distal aspect of each hallux, or distal most prominent area. The rheostat is slowly increased until the patient senses the vibration. Once the patient identifies the sensation, the rheostat is then decreased until the sensation is no longer detected. The average value of the two numerical readings is taken and the level of sensation

JAYPEE BROTHERS

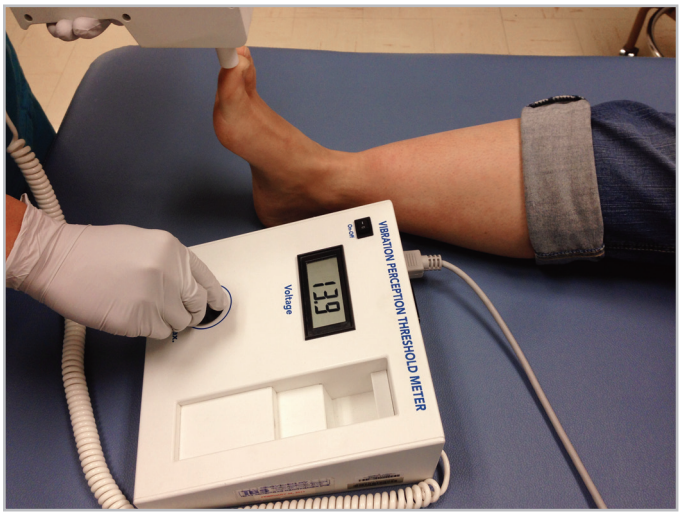

Figure 2.6 Vibratory perception threshold monitor.

is documented to the location where the numbers were obtained. Average values above 25 Volts are considered positive for neuropathic changes (Boulton et al. 2008).

Neurological examinations traditionally require additional hardware or technology. This is not only costly but requires additional maintenance, electrical power resources, and overhead. Recent study and product designs have made advances in providing reliable and accurate testing modalities for identifying neurological capacity without the expense of burdening carrying capacity (Bowling et al. 2012). This has benefits for underprivileged and underserved regions of the world.

Where no medical instrumentation is present, an Ipswich Touch Test (IpTT) may be utilized. This involves a light touch with the index finger of the examiner for 1–2 seconds to various sites on the patient's foot, as demonstrated by **Figure 2.7** (Rayman et al. 2011). Although not considered as reliable enough to rival standard practices, it does provide care teams a fast and easy means of evaluating a patient's risk of ulceration within a care facility.

Dermatological examination

Following assessment for any loss of sensation, evaluation of the integument is often an important part of the foot screening. The skin can be evaluated for color, texture, turgor, quality, and presence of any areas of moisture, maceration, dryness or fissures, as well as malodor or drainage. This can frequently manifest itself in the interspaces (**Figure 2.5**). Calluses, if present, can be problematic as they indicate areas of increased pressure and an 'at risk' status of preulceration. Wounds can form under the hyperkeratotic lesion, which may cause hemorrhage beneath the callus. **Figure 2.8** shows a hypertrophic rim, encircling the ulceration at the distal aspect of a hammertoe. Debridement of these lesions is recommended in order to increase pressure dispersal (Pataky et al. 2002, Pitei et al. 1999).

Appearance and integrity of the nails should also be noted. If there are nails that are ingrowing, elongated, or there is incurvation of the nails, this could represent a potential area for skin trauma, abscess, and possible infection. Other nail issues to be aware of are onychomycosis (fungal nails), paronychia (ingrown nails with infection and an abscess in the nail fold), dystrophic, atrophic, or hypertrophic growth. Evaluation of any ulceration to the foot or lower leg should be assessed.



Figure 2.7 Ipswich touch test.



Figure 2.8 Hypertrophic rim encircling ulceration at the distal aspect of a hammertoe.

Important characteristics of ulcers are depth, size, presence of fibrotic or granulation tissue, location, and whether or not the area appears to be infected, malodorous, or draining.

Vascular examination

A complete vascular examination is mandatory in any patient who has symptoms consistent with claudication or ischemic rest pain.

JAYPEE BROTHERS

However, due to neuropathy some patients will present with limb-threatening ischemia without the aforementioned complaints. Other patients will present with nonhealing wounds following minor elective or urgent operations. Theses patients may or may not have associated gangrene or infection. The initial physical examination should focus on the pulse examination from the inguinal ligament to the dorsalis pedis and posterior tibial arterial pulses. Nonetheless, perception of the pedal pulses is subjective and there is great variability between examiners who describe its presence and quality (Mowlavi et al. 2002). The ankle-brachial index (ABI) provides an objective measure to screen patients with arterial obstructive disease. Generally, patients with severe ischemia will have an ABI <0.4.

Many patients with diabetes, however, have falsely elevated ankle pressures due to calcification of the arterial wall. This renders some tibial vessels less compressible and others incompressible (pressures >250 mmHg) and the resulting ABI underestimates the severity of the disease (Weitz et al. 1996). In these instances pulse volume recordings (PVR) are helpful to obtain some measure of the degree of arterial occlusive disease involved. PVR are obtained with partially inflated segmental blood pressure cuffs that detect volume changes sequentially down a limb. Volume changes beneath the cuffs during the cardiac cycle cause discrete pressure changes within the cuffs, which can be displayed as arterial waveforms by specific transducers. A normal PVR waveform has a sharp systolic upstroke and peak and a prominent dicrotic notch on the downward portion of the curve. Such a waveform reflects normal arterial inflow to the portion of the extremity under the cuff. With increasing proximal arterial stenosis, the dicrotic notch shrinks and the peak wave becomes rounded with loss of amplitude. With proximal occlusion, the pulse wave may be absent. Pulse volume waveforms are evaluated qualitatively based on the shape of the curve.

Flat and dampened curves are considered severely abnormal. The paucity of reproducible data in PVR limits the utility of air plethysmography (Strandness 1969). An alternative to PVR is the evaluation of digital pressures and waveforms. These noninvasive tests are particularly useful in patients with pedal artery occlusive disease or highly calcified vessels, in whom ankle blood pressures do not accurately reflect real arterial pressure due to incompressibility of the calcified arterial walls. The presence of normal digital waveforms indicates minimal restriction to blood flow despite the calcific arterial disease. In contradistinction, a flat and dampened digital waveform in the presence of normal ankle pulses often indicates pedal artery occlusive disease.

When perfusion cannot be assessed from the indirect noninvasive tests mentioned above, arterial duplex scanning can provide detailed anatomic and hemodynamic information. Duplex scanning combines B-mode ultrasound and pulsed Doppler ultrasound. The combination of color Doppler and B-mode ultrasound can determine anatomical and hemodynamic abnormalities. B-mode imaging alone cannot differentiate hemodynamically significant soft plaque and thrombus from blood. B-mode ultrasound visualizes calcified plaque and enables one to focus on the arterial segment of interest. Doppler ultrasound can demonstrate abnormal flow patterns caused by intra-arterial luminal defects. Blood flow velocities are calculated to determine the degree of stenosis in the artery. Arterial duplex scanning has been compared prospectively with angiography to define standard criteria for normal and diseased arteries. The sensitivity of duplex examination for detecting the presence of a hemodynamically significant lesion (>50% stenosis) ranges from 89% at the iliac artery to 68% at the popliteal artery. Overall sensitivities for predicting interruption of patency are 90% for the anterior tibial, 90% for the posterior tibial, and 82% for the peroneal artery. The sensitivity of arterial duplex ultrasound is not significantly influenced by the severity of atherosclerosis (Moneta et al. 1992).

Intra-arterial digital subtraction angiography continues to be the most accurate method to evaluate arterial circulation of the lower extremity. Nonetheless, it is an invasive procedure that can be associated with complications in up to 2.9% of patients (Balduf et al. 2002). A detailed angiogram must include the inflow vessels and the runoff. Careful selective catheterization of the superficial femoral or popliteal artery allows for detailed visualization of the tibial and pedal vessels with a reduced contrast load. This is important because patients with diabetes despite having a normal creatinine level are at increased risk of contrast-induced nephropathy (Toprak et al. 2007).

RISK CLASSIFICATION

Diabetes mellitus foot risk classification (risk of ulceration and subsequent amputation)

Based on a thorough history and physical examination, each patient should then be classified and assigned to a specific foot risk category as outlined in **Table 2.3** (Boulton et al. 2008). These categories were designed to direct and expedite the referral process to the necessary specialist and should also serve as a guide for subsequent follow-up visits. Increased categorical levels are associated with increasing risk of ulceration, hospitalization, and amputation.

Wound classification systems (risk of nonhealing and subsequent amputation)

Multispecialty teams and hospital facilities employ a variety of specialists and caregivers for the treatment of diabetic foot complications. Wound classification systems are a useful appliance for documentation and peer interaction within a caregiving community. Several wound classification systems have emerged, which are actively in use. Members of the multidisciplinary team should use standard language and descriptions, which include accepted wound classifications. Each of these classifications offers a common descriptor of a clinical scenario, and can be used in addition to the specific details and specific patient evaluation.

Wagner classification for foot ulcers

This classification is primarily based on vascular integrity and depth of involvement within the foot (Wagner 1981). A Grade 0 scenario describes a preulcerative condition overlying an 'at risk' area of skin. A Grade 1 wound describes a partial thickness loss of skin. A Grade 2 wound details a deeper skin or soft tissue involvement, not involving bone. Grade 3 describes a deep wound or abscess involving bone or joint. Grade 4 describes a localized focal gangrenous wound, whereby Grade 5 describes a global foot gangrenous scenario.

University of Texas wound classification system

While many wound classification systems exist, The University of Texas (UT) ulcer classification system was developed to provide a

JAYPEE BROTHERS

Table 2.3 American Diabetes Association risk classification for the diabetic foot (Boulton et al. 2008, Lavery et al. 2007)

Risk category	Definition	Yearly ulcer incidence/odds ratio (compared with risk category 0)	Treatment recommendations	Suggested follow-up
0	No LOPS, no PAD, no deformity	2.0%	Patient education including advice on appropriate footwear	Annually (by generalist and/or specialist)
1	LOPS ± deformity	4.5%/2.4	Consider prescriptive or accommodative footwear Consider prophylactic surgery if deformity cannot be safely accommodated in shoes Continue patient education	Every 3–6 months (by generalist and/or specialist)
2	PAD ± LOPS	13.8%/9.3	Consider prescriptive or accommodative footwear Consider vascular consultation for combined follow-up	Every 2–3 months (by specialist)
3	History of ulcer or amputation	32.2%/52.2	Same as category 1 Consider vascular consultation for combined follow-up if PAD present	Every 1–2 months (by specialist)

LOPS, loss of protective sensation; PAD, peripheral arterial disease.

more uniform evaluation of diabetic foot wounds (Armstrong et al. 1998). Like other classification systems, the UT wound classification system builds on the depth-ischemia classification; however, the UT system also considers infection. The presence of infection and ischemia has been found to be more strongly predictive of outcome than the wound depth alone (Oyibo et al. 2001). The UT system uses a 4 by 4 matrix (classes A to D, wound depths 0–3) and evaluates 3 factors of ulceration, which include depth, infection, and peripheral arterial disease (PAD) (Andros 2010). The frequency and level of amputation increases in deeper wounds and in the presence of infection and PAD (Armstrong et al. 1998). Regardless of which specific classification is used, the key factors of depth, infection, and ischemia should generally be communicated in some form. This classification is listed in **Table 2.4**.

PEDIS system

The International Working Group of Diabetic Foot, in an effort to standardize wound classification across research studies, developed and proposed the PEDIS system. Building on previous systems, it also includes wound size and the presence of neuropathy. It also includes these in ordinal variables, which may allow for more precision (Schaper 2004) (**Table 2.5**).

As discussed, classifications are useful to multispecialty care teams for communicating varying descriptions of acuity, benefiting not only clinical dialogue, but also research stratification and investigation. While the use of a specific system is not important, it is important, when patient care involves a number of different specialties and the treatment of both acute and chronic conditions, to agree a common 'language' of risk and description among members of the team. If a specific classification is preferred, then it is appropriate to define which nomenclature is being applied. Assessment and management of wounds will be discussed in subsequent chapters.

Table 2.4 The University of Texas (UT) wound classification system

Grade	Description	Stage
1	Pre- or postulcerative lesion	A–D
2	Superficial	A–D
3	Penetrated to tendon or joint capsule	A–D
4	Penetrates to bone	A–D

Stages: A, no infection or ischemia; B, infection; C, ischemia; D, infection and ischemia.

Management of tissue loss, infection, and ischemia: the importance of team

Diabetic foot care demands an interdisciplinary team approach given the multifactorial components and progressive nature of the disease in the foot and the whole patient. If a patient presents with a wound, infection, ischemia, or a combination of these three, then recent evidence as it exists continues to consistently point to a reduction in major amputation rates following the development of an interdisciplinary team (Armstrong et al. 2012, Rogers et al. 2010). The components of a limb salvage team are predicated on the pathology at presentation. The core of the team typically starts with clinicians caring for the structural and surgical aspects of the foot along with clinicians caring for the vascular integrity of the lower extremity. Other specialties of the team, to add a more comprehensive care model, may include Internal Medicine, Diabetology, Infectious Disease, Physical Therapy, Plastic Surgery, Nursing, Emergency Medicine, Endocrinology, Nutrition, and Prosthetics.

Both vasculopathy and neuropathy are two major contributors to diabetic foot disease and subsequent ulceration. In order to reduce amputations, it is proposed that a diabetic rapid response acute foot team would combine the knowledge of certain specialties to promote limb salvage (Fitzgerald et al. 2009). Rather than pointing to specific team members, one may focus on 'skill sets' that transcend borders and specific specialties. We have listed seven important skill sets that can help to define the core of a 'diabetic rapid response foot team (DRRAFT)' (**Box 2.1**) (Rogers et al. 2010). These align well with the National Minimum Skills Framework developed in the UK (Diabetes UK 2011).

JAYPEE BROTHERS

Table 2.5 PEDIS wound classification

Perfusion	Extent/size	Depth/tissue loss	Infection	Sensation
Grade 1 No symptoms or signs of PAD in the affected foot, in combination with: Palpable dorsal pedal and posterior tibial artery pulse or Ankle-brachial index 0.9 to 1.10 or Toe-brachial index >0.6 or Transcutaneous oxygen pressure ($tcpO_2$) >60 mmHg **Grade 2** Symptoms or signs of PAD, but not of critical limb ischemia (CLI): Presence of intermittent claudication (in case of claudication, additional non-invasive assessment should be performed), as defined in the document of the International Consensus on the Diabetic Foot [8] or Ankle-brachial index < 0.9, but with ankle pressure >50 mmHg or Toe-brachial index < 0.6, but systolic toe blood pressure >30 mmHg or $tcpO_2$ 30–60 mmHg or Other abnormalities on non-invasive testing, compatible with PAD (but not with CLI). Note: if tests other than ankle or toe pressure or $tcpO_2$ are performed, they should be specified in each study **Grade 3** CLI, as defined by: Systolic ankle blood pressure <50 mmHg or Systolic toe blood pressure <30 mmHg or $tcpO_2$ <30 mmHg	Various means of planimetric analysis have been described in literature from circumference to perpendicular diameter approximations	**Grade 1** Superficial full-thickness ulcer, not penetrating any structure deeper than the dermis **Grade 2** Deep ulcer, penetrating below the dermis to subcutaneous structures, involving fascia, muscle or tendon **Grade 3** All subsequent layers of the foot involved, including bone and/or joint (exposed bone, probing to bone)	**Grade 1** No symptoms or signs of infection **Grade 2** Infection involving the skin and the subcutaneous tissue only (without involvement of deeper tissues and without systemic signs, as described below). At least two of the following items are present: Local swelling or induration Erythema >0.5–2 cm around the ulcer Local tenderness or pain Local warmth Purulent discharge (thick, opaque to white or sanguineous secretion) Other causes of an inflammatory response of the skin should be excluded (e.g. trauma, gout, acute Charcot neuroarthropathy, fracture, thrombosis, venous stasis) **Grade 3** Erythema >2 cm plus one of the items described above (swelling, tenderness, warmth, discharge) or infection involving structures deeper than skin and subcutaneous tissues such as abscess, osteomyelitis, septic arthritis, fasciitis. No systemic inflammatory response signs, as described below **Grade 4** Any foot infection with the following signs of a systemic inflammatory response syndrome. This response is manifested by two or more of the following conditions: Temperature >38 or <36°C Heart rate >90 beats/min Respiratory rate >20 breaths/min *P*aCO_2 <32-mmHg White blood cell count >12.000 or <4.000/cu mm 10% immature (band) forms	**Grade 1** No loss of protective sensation on the affected foot detected, defined as the presence of sensory modalities described below **Grade 2** Loss of protective sensation on the affected foot is defined as the absence of perception of the one of the following tests in the affected foot: Absent pressure sensation, determined with a 10G monofilament, on two out of three sites on the plantar side of the foot, as described in the International Consensus on the Diabetic Foot Absent vibration sensation (determined with a 128-Hz tuning fork) or vibration threshold >25 V (using semiquantitative techniques), both tested on the hallux

PAD, peripheral arterial disease.

JAYPEE BROTHERS

CONCLUSION

Diabetic foot complications are common, complicated, and costly to patients and their communities alike. This makes identification of risk factors through consistent screening and triage very important. Through systematic screening and stratification, patients can be triaged according to risk. Care may thus be standardized with the benefit being a reduction in morbidity and a better quality of life for our patients and their families.

Box 2.1 Seven essential skills of a diabetic rapid response acute foot care team

- Ability to perform hemodynamic and anatomic vascular assessment with revascularization
- Ability to perform a neurological assessment
- Ability to perform site-appropriate culture technique
- Ability to perform wound assessment and staging/grading of infection and ischemia
- Ability to perform site-specific bedside and intraoperative incision and debridement
- Ability to initiate and modify culture-specific and patient-appropriate antibiotic therapy
- Ability to perform appropriate postoperative monitoring to reduce risks of re-ulceration and infection

IMPORTANT FURTHER READING

Boulton AJ, Armstrong DG, Albert SF, et al. Comprehensive foot examination and risk assessment: a report of the task force of the foot care interest group of the American Diabetes Association, with endorsement by the American Association of Clinical Endocrinologists. Diabetes Care 2008; 31:1679–1685.

Chang CH, Peng YS, Chang CC, Chen MY. Useful screening tools for preventing foot problems of diabetics in rural areas: a cross-sectional study. BMC Public Health 2013; 13:612.

Feng Y, Schlösser FJ, Sumpio BE. The Semmes Weinstein monofilament examination as a screening tool for diabetic peripheral neuropathy. J Vasc Surg 2009; 50:675–682.

National Institute for Health and Care Excellence. Clinical guidelines: type 2 diabetes – footcare (CG10. http://guidance.nice.org.uk/CG10.

Rayman G, Vas PR, Baker N, et al. The Ipswich Touch Test: a simple and novel method to identify inpatients with diabetes at risk of foot ulceration. Diabetes Care 2011; 34:1517–1518.

Singh N, Armstrong DG, Lipsky BA. Preventing foot ulcers in patients with diabetes. JAMA 2005; 293:217–228.

REFERENCES

Andros GL, Lavery LA. Diabetic foot ulcers. In: Cronenwett J, Johnston KW (eds), Rutherford's Vascular Surgery, vol. 2, 7th edn. Saunders Elsevier, 2010:1735–1746.

Armstrong DG, Bharara M, White M, et al. The impact and outcomes of establishing an integrated interdisciplinary surgical team to care for the diabetic foot. Diabetes Metab Res Rev 2012:n/a-n/a.

Armstrong DG, Lavery LA, Harkless LB. Validation of a diabetic wound classification system. The contribution of depth, infection, and ischemia to risk of amputation [see comments]. Diabetes Care 1998; 21:855–859.

Armstrong DG, Lavery LA, Vela SA, et al. Choosing a practical screening instrument to identify patients at risk for diabetic foot ulceration. Arch Intern Med 1998: 289–292.

Armstrong DG, Stacpoole-Shea S, Nguyen HC, Harkless LB. Lengthening of the Achilles tendon in diabetic patients who are at high risk for ulceration of the foot. J Bone Joint Surg (Am) 1999; 81A:535–538.

Balduf LM, Langsfeld M, Marek JM, et al. Complication rates of diagnostic angiography performed by vascular surgeons. Vasc Endovascular Surg 2002; 36:439–445.

Boulton AJ, Armstrong DG, Albert SF, et al. Comprehensive foot examination and risk assessment: a report of the task force of the foot care interest group of the American Diabetes Association, with endorsement by the American Association of Clinical Endocrinologists. Diabetes Care 2008; 31:1679–1685.

Bowling FL, Abbott CA, Harris WE, et al. A pocket-sized disposable device for testing the integrity of sensation in the outpatient setting. Diabet Med 2012; 29:1550–1552.

Centers for Disease Control & Prevention – National Diabetes Fact Sheet: General Information & National Estimates on Diabetes in the United States. Atlanta, GA: Centers for Disease Control & Prevention, 2008.

Diabetes UK. Putting feet first: national minimum skills framework. The national minimum skills framework for commissioning of footcare services for people with diabetes. Revised March 2011. http://www.diabetes.org.uk/About_us/What-we-say/Improving-services--standards/National-Minimum-Skills-Framework-for-commissioning-of-foot-care-services-for-people-with-diabetes-March--2011/

Fitzgerald RH, Mills JL, Joseph W, Armstrong DG. The diabetic rapid response acute foot team: 7 essential skills for targeted limb salvage. Eplasty 2009; 9:15.

Frykberg RG, Armstrong DG, Giurini J, et al. Diabetic foot disorders: a clinical practice guideline. American College of Foot and Ankle Surgeons. J Foot Ankle Surg 2000; 39:S1–60.

Giacomozzi C, D'Ambrogi E, Uccioli L, Macellari V. Does the thickening of Achilles tendon and plantar fascia contribute to the alteration of diabetic foot loading? Clin Biomech (Bristol, Avon) 2005; 20:532–539.

Grant WP, Foreman EJ, Wilson AS, Jacobus DA, Kukla RM. Evaluation of Young's modulus in Achilles tendons with diabetic neuroarthropathy. J Am Podiatr Med Assoc 2005; 95:242–246.

Lavery LA, Armstrong DG, Wunderlich RP, et al. Risk factors for foot infections in individuals with diabetes. Diabetes Care 2006; 29:1288–1293.

Lavery LA, Peters EJ, Williams JR et al., International Working Group on the Diabetic Foot. Reevaluating the way we classify the diabetic foot: restructuring the diabetic foot risk classification system of the International Working Group on the Diabetic Foot. Diabetes Care 2008; 31:154–156.

Moneta GL, Yeager RA, Antonovic R, et al. Accuracy of lower extremity arterial duplex mapping. J Vasc Surg 1992; 15:275–283; discussion 283–274.

Mowlavi A, Whiteman J, Wilhelmi BJ, Neumeister MW, McLafferty R. Dorsalis pedis arterial pulse: palpation using a bony landmark. Postgrad Med J 2002; 78:746–747.

Oyibo SO, Jude EB, Tarawneh I, et al. A comparison of two diabetic foot ulcer classification systems: the Wagner and the University of Texas wound classification systems. Diabetes Care 2001; 24:84–88.

Pataky Z, Golay A, Faravel L, et al. The impact of callosities on the magnitude and duration of plantar pressure in patients with diabetes mellitus. A callus may cause 18,600 kilograms of excess plantar pressure per day. Diabetes Metab 2002; 28:356–361.

Pitei DL, Foster A, Edmonds M. The effect of regular callus removal on foot pressures. J Foot Ankle Surg 1999; 38:251–255; discussion 306.

Rayman G, Vas PR, Baker N, et al. The Ipswich Touch Test: a simple and novel method to identify inpatients with diabetes at risk of foot ulceration. Diabetes Care 2011; 34:1517–1518.

JAYPEE BROTHERS

Rogers LC, Andros G, Caporusso J, et al. Toe and flow: essential components and structure of the amputation prevention team. J Vasc Surg 2010; 52:23S–27S.
Rogers LC, Armstrong DG. Diabetic foot ulcers: podiatry care. In: Cronenwitt J (ed.), Rutherford vascular surgery, 7th edn. Amsterdam: Elsevier, 2009.
Schaper NC. Diabetic foot ulcer classification system for research purposes: a progress report on criteria for including patients in research studies. Diabetes Metab Res Rev 2004; 20:S90–95.
Singh N, Armstrong DG, Lipsky BA. Preventing foot ulcers in patients with diabetes. JAMA 2005; 293:217–228.
Strandness DE. Peripheral arterial disease: a physiologic approach. Boston: Little, Brown, 1969.
Toprak O, Cirit M, Yesil M, et al. Impact of diabetic and pre-diabetic state on development of contrast-induced nephropathy in patients with chronic kidney disease. Nephrol Dial Transplant: Official publication of the European Dialysis and Transplant Association – European Renal Association 2007; 22:819–826.
Unwin N, Gan D, Whiting D. The IDF Diabetes Atlas: providing evidence, raising awareness and promoting action. Diabetes Res Clin Pract 2010; 87:2–3.
Wagner FW. The dysvascular foot: a system for diagnosis and treatment. Foot Ankle 1981; 2:64–122.
Weitz JI, Byrne J, Clagett GP, et al. Diagnosis and treatment of chronic arterial insufficiency of the lower extremities: a critical review. Circulation 1996; 94:3026–3049.
World Health Organization Diabetes Fact Sheet, No 312. Geneva: World Health Organization, 2009.
Yancey P, Brand P. The gift of pain. Grand Rapids: Zondervan, 1997.

JAYPEE BROTHERS

JAYPEE BROTHERS

THE DIABETIC FOOT

Diabetes is reaching epidemic proportions worldwide and foot disease is one of its most challenging complications which, if not managed in a timely and expert fashion, can result in foot ulceration and amputation.

Reflecting the multi-system nature of the disease and the benefits of a multidisciplinary approach, *The Diabetic Foot* brings together a group of leading experts who summarize the best available evidence and provide authoritative guidance on the clinical management of diabetic foot disease.

The book starts with sections on epidemiology, infection, ischemia and neuropathy before moving on to discuss wound healing, surgical intervention, Charcot disease and biomechanics. Written with the information needs of both specialists and generalists in mind, *The Diabetic Foot* provides an accessible, comprehensive and evidence-based review of the management of diabetes-related complications of the lower extremity.

- Provides a definitive 'go-to' reference for trainee and practicing vascular specialists, diabetologists, endocrinologists, podiatrists, surgeons and all other health professionals involved in the management of diabetic foot problems
- Multidisciplinary editor and author team provides expert advice from all participating disciplines
- Summarizes current evidence and highlights controversies and areas of research

JP medical publishers

www.jpmedpub.com

ISBN 978-1-907816-62-8

9 781907 816628