Recent Advances in Gastroenterology



Edited by **Chris Probert**

Contents

Preface		v
Acknowledgements		ix
Chapter 1	Ulcerative colitis	1
Chapter 2	Crohn's disease	11
Chapter 3	Coeliac disease: how should we diagnose it?	23
Chapter 4	*Helicobacter pylori* and its complications	35
Chapter 5	Advances in luminal imaging	47
Chapter 6	Advances in gastrointestinal endoscopy	57
Chapter 7	Microscopic colitis	77
Chapter 8	IgG4-related disease	93
Chapter 9	Recent advances in upper GI haemorrhage	113
Chapter 10	Viral hepatitis	125
Chapter 11	Alcoholic liver disease	137
Index		149

Chapter 3

Coeliac disease: how should we diagnose it?

Steve Hughes, Joe Unsworth

JAYPEE BROTHERS

INTRODUCTION

Coeliac disease (CD) is an autoimmune small bowel disorder characterised by inflammation, villous atrophy and crypt hyperplasia caused by exposure to gluten, which is fully reversible after withdrawing gluten from the diet. CD affects up to one in a hundred people in certain populations (e.g. European) though it is much less common in other populations (e.g. Chinese and Africans). Despite this high prevalence, many cases remain undiagnosed as they have few or no symptoms. In addition CD exists in a number of different forms. The 'Classical' form of CD presents with typical features of malabsorption but 'Atypical' cases, which are more common, have milder clinical features or mainly extra-intestinal symptoms. Patients with the 'Silent' form are asymptomatic and those with 'Potential' CD have the immunological abnormalities but not the biopsy changes. 'Latent' CD refers to those with normal mucosa who will go on to develop CD or have not redeveloped mucosal damage after reintroduction of gluten.

If there are many patients with undiagnosed CD, but little in the way of symptoms, does it matter? Is it necessary to pursue these patients and impose a major lifelong dietary restriction, particularly as asymptomatic patients may be less likely to comply with a gluten-free diet (GFD)? As justification, it has been suggested that patients with undiagnosed CD may experience an improved well-being after starting a GFD even if they felt well beforehand and subclinical nutritional problems can be corrected. Furthermore, the risk of, admittedly very rare, complications such as malignancy, ulceration and refractory CD may be increased in those diagnosed late.

WHO SHOULD BE TESTED?

Despite the high prevalence of CD, population screening is not recommended. Recent NICE guidance is available on who to test [1], but currently primary care requesting seems poorly focused, achieving detection rates no better than would be achieved by random

Steve Hughes MD, FRCP, Frenchay Hospital, Frenchay Park Road, Bristol, UK

Email: Stephen.Hughes@nbt.nhs.uk (for correspondence)

D Joe Unsworth PhD, FRCP, FRCPath, Southmead Hospital, Bristol, UK

population screening [2]. Tests for CD should be done in anyone where the diagnosis is suspected from the patient's symptoms and in those with less typical symptoms but who have a high risk of CD (e.g. first-degree relatives, patients with type 1 diabetes mellitus).

Clinical presentation of 'classical' coeliac disease

In childhood, CD classically presents with failure to thrive, steatorrhoea, anorexia, wasting and abdominal distension. Often, however, children manifest non-specific or mild symptoms. Adults and children may present with malabsorption; the stools are pale, floaty, offensive, greasy and difficult to flush. The stools may contain obvious undigested food and fatty droplets. Fat malabsorption may lead to deficiencies of fat-soluble vitamins, weakness and weight loss. Calcium and vitamin D deficiency may lead to osteomalacia, fractures and rarely tetany. Bruising may occur due to hypoprothrombinaemia and even hyperkeratosis from vitamin A deficiency. Occasionally low albumin, electrolyte disturbances and dehydration may develop. None of these features is specific to CD but may be seen in any patient with small bowel malabsorption. CD will be one of several possible diagnoses in patients presenting in this way. It is interesting that such symptoms can be precipitated by procedures that increase gastric emptying (e.g. gastrectomy or pyloroplasty) in patients with previously unapparent CD. The onset of symptomatic CD can also be 'triggered' by gastroenteritis, pregnancy and childbirth.

Clinical presentations of 'atypical' coeliac disease

Increasingly CD is being identified, especially in adults, with a wide variety of symptoms. Coeliacs may have a range of gastrointestinal symptoms including bloating and abdominal discomfort or no gastrointestinal symptoms whatsoever. Significant abdominal pain is rare. In adults, typical features of malabsorption are much less common than in children. Adult coeliacs can sometimes present with constipation, and a high proportion of patients are overweight.

Presentation with extra-intestinal features includes anaemia, particularly recurrent iron deficiency or folate deficiency; however, vitamin B_{12} deficiency is not expected as CD affects the terminal ileum much less often than the upper small bowel, where iron and folic acid are absorbed [3]. Aphthous ulcers occur in up to 25% of coeliacs and resolve with gluten withdrawal. Arthritis occurs in 40% of untreated and 25% of treated coeliacs.

Neuropsychiatric symptoms are well recognised. Depression is common. Peripheral neuropathy, demyelination affecting the spinal cord, myopathy, encephalopathy and cerebellar ataxia have also been reported. Fatigue (without anaemia) is a reported feature of untreated CD, but patients presenting with chronic fatigue syndrome very rarely have CD in the absence of other suggestive symptoms or blood abnormalities. Dermatitis herpetiformis (DH) is a skin lesion strongly associated with CD and reversible with diet, and although the small bowel mucosal changes may be patchy, a gluten-sensitive enteropathy (GSE) is almost universally confirmed. Some authors believe that small bowel biopsy is therefore unnecessary in DH. Hypogonadism, amenorrhoea and infertility are all seen in CD and may improve with a GFD. There is debate as to whether patients attending fertility clinics and those with recurrent fetal loss should be tested for CD.

On occasions, incidental abnormalities which suggest CD are seen on blood tests performed for unrelated symptoms. Hyposplenism with Howell-Jolly bodies and target cells, abnormal liver tests (raised ALT) and macrocytosis due to folate deficiency may all be chance

JAYPEE BROTHERS

findings in undiagnosed coeliacs. Dental enamel defects in both children and adults may indicate underlying CD as may metabolic bone disease (osteomalacia and osteoporosis).

Patients at high risk of coeliac disease

CD develops in those with a genetic predisposition, and in some studies CD affects 10% or more of first-degree relatives of patients with coeliac. Despite this, screening of relatives is no longer recommended unless they have symptoms suggestive of CD. A variety of other conditions, particularly autoimmune diseases, are associated with CD, and patients with these conditions and symptoms which could be due to CD should be tested. These conditions include type 1 diabetes mellitus, Down's syndrome, Turner syndrome, William's syndrome, autoimmune liver disease, Addison's disease, vitiligo and autoimmune thyroid disease.

The associations between other gastrointestinal diseases and CD are less clear, and the presence of diarrhoeal symptoms may mask the coexistence of CD. Patients with CD may be misdiagnosed as having irritable bowel syndrome (IBS) [4]. IBS-type symptoms occur more frequently in patients with CD and may be reduced by adherence to a GFD [5]. Patients with diarrhoea-predominant IBS should be tested for CD according to the American College of Gastroenterology and NICE. Patients with IBS may be intolerant of wheat and respond to gluten withdrawal, but this is different from, and lacks the autoimmune serology and classical histology diagnostic of, CD. Indeed the concept of non-coeliac 'gluten sensitivity' is an emerging, contentious area with no diagnostic tests [6]. One study suggests a response to gluten withdrawal may be predicted by the presence of immunoglobulin G (IgG) wheat protein antibodies and expression of HLA-DQ2 in diarrhoea-predominant IBS [7], but critics point out that 15% of the healthy population also have these non-specific antibodies (see later).

A link between inflammatory bowel disease (IBD) and CD has been proposed. A study of the incidence of IBD in first-degree relatives of coeliac patients showed a five times greater risk of ulcerative colitis compared with the normal population [8]. Although this increase in IBD in patients with coeliac has been confirmed by others, there was no increase in CD in patients with IBD compared with controls [9]. In contrast, the much rarer microscopic colitis is associated with CD. CD can also be associated with a variety of liver conditions including primary biliary cirrhosis, autoimmune hepatitis and primary sclerosing cholangitis.

TESTS

Non-diagnostic tests

A variety of tests have been used in the past which, whilst suggestive of CD, are not truly diagnostic tests. The blood abnormalities already mentioned may suggest CD but are not diagnostic. Serum citrulline, a non-protein amino acid, may be a marker of enterocyte mass. Levels are low in CD compared with normal, and increase on GFD, but it cannot be considered a diagnostic test. Low levels of citrulline are also seen in other gastrointestinal conditions such as Crohn's disease and short bowel syndrome. D-Xylose absorption testing has been used to indicate malabsorption, as have tests of small bowel permeability, but these tests are not specific for CD.

HLA typing is not a diagnostic test for CD. Ninety-five per cent of patients are positive for HLA-DQ2, and most of the remainder are positive for DQ8, but 30% of the normal

JAYPEE BROTHERS

population is also positive for DQ2. In very rare circumstances, knowing the patient is negative for both DQ2 and DQ8 helps indicate that CD is highly unlikely [10].

Small bowel radiology in untreated CD is abnormal in 90% of cases. It shows features of malabsorption such as flocculation of barium, a coarse mucosal pattern and distension of the lumen. Abnormalities are maximal in the jejunum and spread distally with increasing severity of the disease. These changes are all non-specific and are not diagnostic of CD.

Immunopathology

The evidence suggesting that CD is autoimmune is compelling [11]. Firstly, there are strong HLA association (DQ2 or DQ8, see above). Secondly, IgA autoantibodies directed against tissue transglutaminase (TT) – a normal, ubiquitous tissue repair enzyme, not confined to the gut – are effectively pathognomonic. However, CD has been reported in an immunodeficient, pan-hypogammaglobulinaemic patient, lacking detectable autoantibody, suggesting that autoantibodies may be secondary epiphenomenae, rather than being directly pathogenic in their own right. Wheat proteins including gliadins and other glutamine-rich proteins are readily accepted substrates for the TT enzyme, and bind with high affinity. Gliadin peptides processed and altered by the TT enzyme are preferentially recognised by T lymphocytes derived from CD small bowel. GSE features increased numbers of intra-epithelial T lymphocytes. There is a close association between CD and DH, where IgA deposits in the skin are pathognomonic, and skin lesions improve on a GFD. In vitro disease models have demonstrated that auto-reactive T lymphocytes can cause severe villous atrophy; in patients with coeliac crisis, immunosuppression is the treatment of choice.

This particular autoimmune disease is gluten dependent. All the abnormal immunological markers (autoantibodies, intra-epithelial T lymphocytes etc.) return to normal on a strict GFD, and relapse when gluten is reintroduced. However, many unanswered questions remain, including

1. Why is CD relatively uncommon (only 1% of population affected) when approximately one-third of the UK population carry the associated HLA types. Family studies suggest there are many other relevant disease-related genes yet to be identified.
2. Genetic analyses have failed to find differences between the TT enzyme expressed in CD and non-CD patients, so it is not clear why high titre IgA anti-TT antibodies are so closely associated with CD. Indeed their relative disease specificity makes them indispensable diagnostic tools. Confirmatory biopsy remains the diagnostic gold standard and is advised by NICE, but there has been debate as to whether symptomatic, serologically positive cases which respond to gluten withdrawal always need to have a biopsy.

Coeliac disease-associated antibodies

Food antibodies including anti-gliadin

Wheat gluten-related antibodies (e.g. anti-gliadin and others), but also other food antibodies particularly of IgG class, are present in the majority of patients with untreated CD but seem to be associated with small bowel damage rather than CD per se. They are not disease specific and cannot be used for diagnosis or routine monitoring. Various (non-cereal) food antibodies (anti-ovalbumin, anti-casein, anti-B lactoglobulin and others) non-specifically tend to accompany wheat antibodies when present, especially IgG isotype.

JAYPEE BROTHERS

All these food antibodies are non-specifically associated with gut mucosal damage whether it is CD or other (Crohn's disease, for example). Wheat and other (non-wheat) food antibodies in CD will, in most patients, all disappear after 3–6 months on a GFD. Although IgG wheat antibodies are not disease specific, being also found in around 15% of normal healthy individuals and disease controls, titres may be higher in untreated CD [12,13].

IgA wheat antibodies, by contrast, are far more closely associated with GSE. Historically IgA (rather than IgG) anti-gliadin antibody tests were used to assist CD diagnosis. However, these tests have been superseded by the far more reliable IgA anti-TT tests (see below).

There are several clinical scenarios (e.g. IgA nephropathy and some patients with idiopathic neurological disease), where anti-gliadin antibodies (IgA and or IgG) are found in the absence of GSE. Some regard gluten antibodies in these circumstances as non-specific epiphenomenae, but others argue that they indicate 'gluten sensitivity,' and particularly in the context of putative gluten-sensitive neuropathies, trial of GFD has been advocated by some authors. This area remains controversial.

Tissue reactive autoantibodies: anti-TT and anti-endomysium

These are not food antibodies. They are highly disease specific, especially when the tests are designed to detect high titre IgA antibodies only. The autoantigen is a normal tissue repair factor called TT type II. Although TT was not identified as the autoantigen until 1997 [14], autoantibodies were first detected in 1971 by indirect immunofluorescence using rat tissue sections as substrate. Initially they were described as 'anti-reticulin' (a connective tissue pattern of staining). Subsequently, depending on the substrate used, they have alternatively been referred to as anti-jejunum (human small bowel), or anti-endomysial (human umbilicus or monkey oesophagus substrates). Lock, et al. [15] used monoclonal antibodies and other techniques to demonstrate that IgA anti-endomysium, IgA anti-TT and IgA anti-reticulin are all one and the same. Over the years, it has become clear that best results (in terms of disease specificity) are obtained by designing tests which only detect IgA anti-TT. These antibodies are closely associated with GSE and not other forms of gut damage. Our data [16] confirms an association between IgA anti-TTG and CD, but no clear relationship with other forms of increased gut permeability [17].

Diagnostic tests

IgA anti-TT is now easily and cheaply detected by the use of solid phase (Elisa or other) assays [17-19]). Human recombinant TT is widely used. A variety of different assay kits are available, but the majority give similar results (see UK national quality assurance data). These solid phase assays are more sensitive than indirect immunofluorescence tests for IgA anti-endomysial antibody (AEA). Positive results in high-throughput solid phase assays, used as first line, can then be confirmed by indirect immunofluorescence testing for IgA AEA. When both tests are positive, (effectively selecting high titre IgA anti-TT), CD is highly likely. Combining these two tests, sensitivity, specificity, positive predictive value and negative predictive value of 95%, 95%, 75% and 95% is achieved, respectively. In a newly referred case, small bowel biopsy is advisable to confirm CD, and justify lifelong GFD. The positive predictive value for IgA anti-TT (solid phase, highly sensitive assay) alone is much lower (<50%) because low titre IgA anti-TT is less disease specific.

Serology can be extremely useful in selecting cases for confirmatory small bowel biopsy. We suggest the algorithm in **Figure 3.1**, which is similar to that recommended in the NICE

JAYPEE BROTHERS

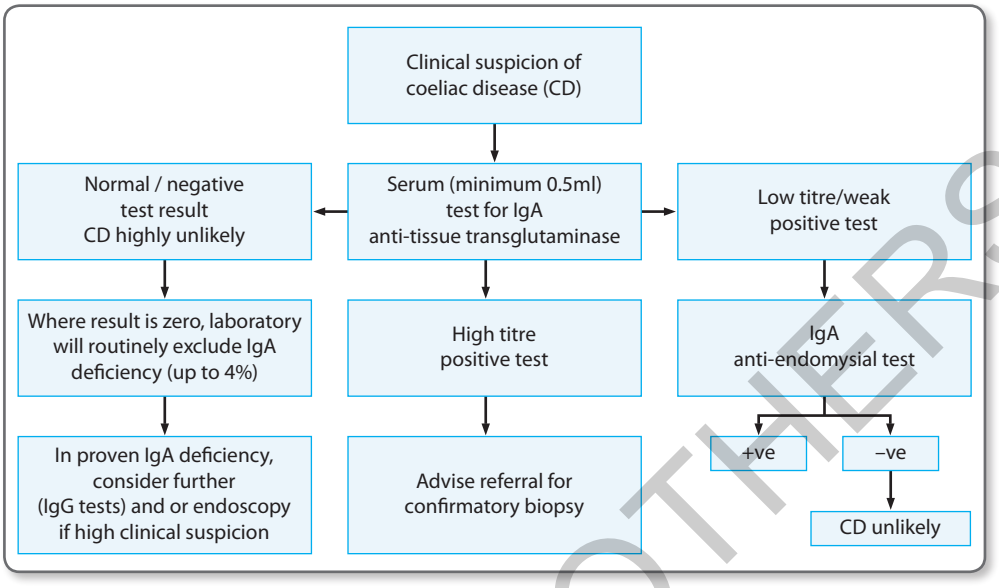

Figure 3.1 Algorithm for the investigation of suspected coeliac disease by serology and biopsy.

guidelines, for using CD serology to help select possible CD cases for endoscopy. Negative results in a sensitive IgA-based anti-TT solid phase assay confidently excludes untreated CD (unless the patient is IgA deficient – see below).

False-positive serology and latency Dual positivity (IgA anti-TT and anti-endomysial), in a patient who is found to have a normal small bowel biopsy, may well be a predictor of future GSE, especially if the patient has a family history of CD, and/or where HLA-DQ2 or DQ8 is carried. These patients merit regular follow-up, and are suspected of having evolving or 'latent' CD. True false-positive results almost certainly are encountered (as with most other autoantibody tests) but they are uncommon.

False-negative serology IgA deficiency in the general population occurs with a frequency of approximately 1/500 in adults. In CD, IgA deficiency is 10 times more common (1/50 cases). Hence, around 2% of adult CD cases are predictably missed by routine IgA-based CD serology. The situation is more complicated in children whose IgA levels are often slow to mature before 7 years of age. NICE recommends that IgA-deficient cases, who are negative in routine IgA-based serological tests for CD, be repeat tested for IgG for anti-gliadin or anti-TT. However, as discussed above, these IgG antibodies are poorly disease specific, and further tests may not prove reliable [20]. It may therefore be simpler to perform endoscopy in seronegative cases where the clinical suspicion is highest (family history, anaemia, other indicators of malabsorption etc.). Finally, studies report up to 2.5% or so of CD cases are seronegative, without IgA deficiency [18].

Serology and monitoring of GFD

IgA anti-TT generally takes 3–6 months to disappear once a complete GFD has been established. However, in cases that become seronegative, anti-TT are not reliable indicators

JAYPEE BROTHERS

of dietary indiscretion. Thus, continuing seronegativity may be seen in cases whose diet is not entirely gluten free, and who show degrees of histological relapse [21].

CD serology and targeted screening

Global population screening is of debatable value, but targeted screening is accepted, justified and clinically useful. For example, serological studies have shown that around 5% of patents with type 1 diabetes mellitus have occult CD. Indeed repeat testing of the anti-TT seronegative cases in subsequent years reveals further cases of CD on top of the initial 5% yield. Another example is in patients with iron deficiency or folate deficiency-associated anaemia, where again around 5% have occult CD and associated malabsorption.

Histology

The mainstay of the diagnosis of CD in clinical practice is histological examination of small bowel mucosa in appropriate patients. Ever since Paulley demonstrated the abnormalities on surgical specimens, biopsy has been the gold standard. The Marsh Classification [22] is usually used to define gluten enteropathy:

- Type 0 – normal
- Type I – increased intra-epithelial lymphocytes (>30 per 100 enterocytes)
- Type II – intra-epithelial lymphocytes plus crypt hyperplasia
- Type III – above plus villous atrophy
- Type IV – villous atrophy without lymphocytes (gland atrophy)

In an appropriate setting, these changes (as demonstrated in **Figure 3.2**) are diagnostic of CD and treatment with a GFD could be started. Historically, especially in children, a second biopsy showing resolution of the histological changes on a GFD was advised, and even a third biopsy showing recurrent histological damage after gluten challenge had its advocates. However, the consensus view now is that the presence of positive serology, typical biopsy changes and a good clinical response to gluten withdrawal is sufficient to make a firm diagnosis.

Various methods have been used to obtain tissue over the years. Techniques using capsules and suction tubes to obtain biopsies are all of historical interest only, having been superseded by endoscopic mucosal biopsies.

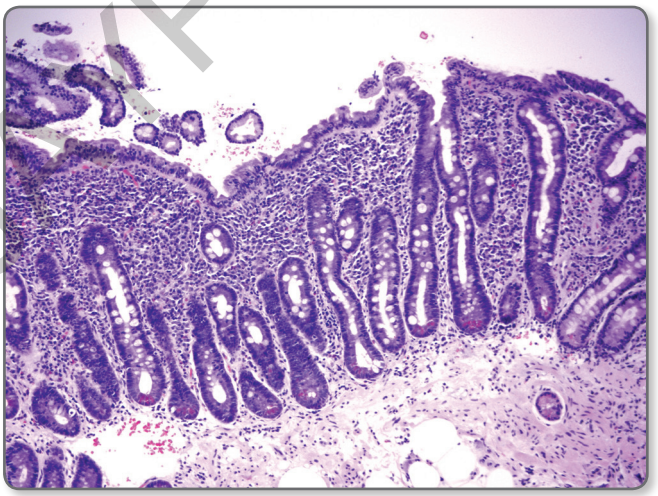

Figure 3.2 Histological appearances of type III coeliac disease. By courtesy of Dr N Rooney, Bristol, UK.

JAYPEE BROTHERS

Endoscopy in CD

With modern video endoscopes, it is often possible to see villi in the distal duodenum, especially after the instillation of some water. A variety of endoscopic appearances are seen in patients with CD. A reduction in the number of circular folds, scalloping of the ridges of the duodenal folds (as shown in **Figure 3.3**), a mosaic pattern or nodularity of the mucosa is suggestive of CD. Visible submucosal blood vessels and multiple erosions in the second part of the duodenum have also been described [23]. These appearances are not, however, pathognomonic of CD [24] neither are they sensitive enough to identify who to biopsy [25]. Whilst not capable of diagnosing CD, endoscopy is essential for obtaining biopsies for histological examination.

There are however a number of issues regarding endoscopic biopsy which may be important. When patients coeliac adopt a GFD, symptoms usually improve and the mucosal abnormalities may resolve. This improvement first appears in the distal small bowel, and it may take many months for the proximal damage to resolve and in some patients it may never go back to normal completely. However, given this tendency to improve, it is important that biopsies for the diagnosis of CD are taken whilst the patient is on a gluten containing diet. If they have already started a GFD, a false normal result may be obtained. If on a GFD, the patient should return to a normal diet or alternatively remain on the GFD and be subjected to a gluten challenge with added gluten. Some patients prefer to avoid disrupting the GFD and giving a set amount of gluten ensures an adequate dose is taken, as patients may choose foods with low gluten content out of habit or in a subconscious effort to avoid symptoms. A dose of 10 gm of gluten (or 4 slices of bread) daily, taken for 4–6 weeks is recommended.

The maximum impact of ingested gluten is where the largest concentration of gluten makes contact with the first villi (i.e. the second part of the duodenum). It has generally been accepted that biopsies from the duodenal cap are less helpful, as this area is normally flat with abundant Brunner's glands. Recently, however, it has been shown that biopsies of the duodenal bulb always show histological abnormalities in CD, and sometimes this specific site is the only one affected [26]. The villous atrophy in CD may be patchy, and therefore multiple biopsies must be taken. The optimal number of biopsies has not been identified. In one retrospective study, CD could be confirmed with two biopsies in 90% of

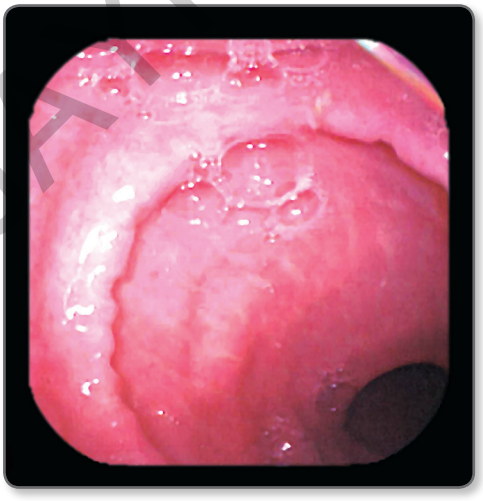

Figure 3.3 Scalloping in untreated coeliac disease. By courtesy of Dr S Hughes, Bristol, UK.

JAYPEE BROTHERS

cases. With three biopsies, 95% were confirmed, but four biopsies were required to confirm CD in all cases [27]. In a prospective trial, nine biopsies were taken from various areas and graded according to Marsh criteria. All cases with CD could be confirmed on three biopsies but to detect the most severe degree of villous atrophy in all cases required five biopsies [28]. It is clear that at least three biopsies are the minimum necessary and more may be preferable. Some groups have shown good results from distal duodenal and jejunal biopsies taken at push enteroscopy where initial duodenal biopsies were equivocal.

It is possible that, in future, endoscopic techniques will be used to enable the endoscopist to target abnormal areas for biopsy. Encouraging results have been obtained using high magnification endoscopy [29]. Confocal laser endomicroscopy is an endoscopic technique which allows an almost microscopic view of mucosa through an endoscope, and hence can show features of CD such as villous atrophy [30]. Whether this technique can diagnose CD accurately remains to be seen.

Wireless capsule endoscopy

Wireless capsule endoscopy (WCE) has been a significant step forward in the investigation of small bowel disease. It has an excellent pick up rate for the causes of obscure bleeding, tumours and other pathology. The villous pattern can be seen clearly at least in some areas of the small bowel using this technology. Several studies have looked at its use in diagnosing CD. In one study, 21 endomysial antibody positive patients underwent both WCE and duodenal biopsy; villous atrophy was identified by a blinded observer in 17 of the 20 patients who were proven to have CD on duodenal biopsy [31]. In a multicentre study, WCE was shown to have good sensitivity and excellent specificity for detecting villous atrophy in 32 cases of CD with reasonable inter-observer agreement [32]. When WCE was used in biopsy-proven CD, it identified villous atrophy in 35 of the 38 cases (92%) with good inter-observer agreement [33]. It is clear that WCE can detect CD, and although it falls short of the gold standard of duodenal biopsy, it could have a role where patients are unwilling or unable to undergo endoscopy.

However, WCE has shown itself to be extremely useful in complicated CD as it can visualise the whole length of the small bowel and identify not only persistent villous atrophy but also ulceration, tumours and strictures. In type 2 refractory CD, it may identify lymphoma not picked up by other forms of imaging [34].

Double balloon enteroscopy

Double balloon enteroscopy allows visualisation of the whole small bowel, usually by intubation from above and below in separate examinations. It is a time consuming and invasive procedure but allows biopsy and therapeutic interventions at all levels of the small intestine. It would be inappropriate to use it as a routine tool to diagnose CD, but it may be a useful technique to rule out complications in symptomatic CD and for identifying lymphoma in refractory CD [35].

CONCLUSION

GSE is a common (1% UK population) reversible autoimmune condition, cured by GFD. Presentation may be with severe malabsorption, but many cases with severe enteropathy on biopsy are asymptomatic and lack malabsorptive complications. Detection of autoantibodies, especially IgA anti-TT, is a convenient inexpensive tool, to select likely cases for confirmatory small bowel biopsy.

JAYPEE BROTHERS

Key points for clinical practice

- Diagnosing CD is easy in most patients if you suspect and look for it.
- Test all patients with typical symptoms, and consider testing in any patient with atypical symptoms, but who also has a high risk of CD.
- Always test on a gluten containing diet or after a gluten challenge.
- IgA deficiency can lead to false-negative serology, but this is rare.
- A therapeutic trial of GFD is not an alternative to testing.
- Histology remains the gold standard for diagnosing CD.
- Always take multiple biopsies from distal duodenum (at least three).
- If there is a strong clinical suspicion, biopsy even if serology is negative.

REFERENCES

1. NICE. Coeliac disease: recognition and assessment of coeliac disease. NICE Clinical Guidelines, No. 86. London: NICE, 2009.
2. Unsworth DJ, Smith F, Lock RJ. Targeting coeliac disease. BMJ 2012; 345:e8120.
3. Hopper AD, Hurlestone DP, Leeds JS, et al. The occurrence of terminal ileal histological abnormalities in patients with coeliac disease. Dig Liver Dis 2006; 38:815–819.
4. Sanders DS, Carter MJ, Hurlestone DP, et al. Association of adult coeliac disease with irritable bowel syndrome: a case-control study in patients fulfilling ROME II criteria referred to secondary care. Lancet 2001; 358:1504–1508.
5. Sainsbury A, Sanders DS, Ford AC. Prevalence of irritable bowel syndrome-type symptoms in patients with celiac disease: a meta-analysis. Clin Gastroenterol Hepatol 2013; 11:359–365.
6. Elli L. The challenge of non-coeliac gluten sensitivity. BMJ 2012; 345:29.
7. Wahnschaffe U, Schulzke JD, Zeitz M, Ullrich R. Predictors of clinical response to gluten-free diet in patients diagnosed with diarrhoea-predominant irritable bowel syndrome. Clin Gastroenterol Hepatol. 2007; 5:844.
8. Shah A, Mayberry JF, Williams G, et al. Epidemiological survey of coeliac disease and inflammatory bowel disease in first-degree relatives of coeliac patients. Q J Med 1990; 74:283–288.
9. Leeds JS, Horoldt BS, Sidhu R, et al. Is there an association between coeliac disease and inflammatory bowel disease? A study of relative prevalence in comparison with population controls. Scand J Gastroenterol 2007; 42:1214–1220.
10. Kaukinen K, Partanen J, Maki M, Collin P. HLA-DQ typing in the diagnosis of celiac disease. Am J Gastroenterol 2002; 97:695.
11. Green PH, Cellier C. Celiac disease. (Review). N Eng J Med 2007; 357:1731–1743.
12. Unsworth DJ, Walker-Smith JA, Holborow EJ. Gliadin and anti-reticulin antibodies in childhood coeliac disease. Lancet 1983; 321: 874–875.
13. Unsworth DJ. Serological diagnosis of gluten-sensitivity enteropathy. J Clin Pathol 1996; 49:704–711.
14. Dieterich W, Ehnis T, Bauer M, et al. Identification of tissue transglutaminase as the autoantigen in celiac disease. Nat Med 1997; 3:797–801.
15. Lock RJ, Gilmour JEM, Unsworth DJ. Anti-tissue transglutaminase, anti-endomysium and anti-R1-reticulin autoantibodies – the antibody trinity of coeliac disease. Clin Exp Immunol 1999; 116:258–262.
16. Lock RJ, Stevens S, Pitcher MCL, Unsworth DJ. Is IgA anti-tissue transglutaminase antibody a reliable serological marker of celiac disease? Eur J Gasroenterol Hepatol 2004; 16:467–470.
17. Lock RJ, Pitcher MCL, Unsworth DJ. IgA anti-tissue transglutaminase as a diagnostic marker of gluten sensitive enteropathy. J Clin Pathol 1999; 52:274–276.
18. Dickey W, McMillan SA, Hughes DF. Sensitivity of serum tissue transglutaminase antibodies for endomysial antibody positive and negative coeliac disease. Scand J Gastroenterol 2001; 36:511–514.
19. Hopper AD, Hadjivassiliou M, Hurlestone DP, et al. What is the role of serologic testing in celiac disease? A prospective, biopsy-confirmed study with economic analysis. Clin Gastroenterol Hepatol 2008; 6:314–320.

JAYPEE BROTHERS

20. Lock RJ, Unsworth DJ. Identifying IgA deficient children and adults does not necessarily help the serological diagnosis of coeliac disease. J Paediatr Gastroenterol Nutr 1999; 28:81–83.
21. Vahedi K, Mascart F, Mary JY, et al. Reliability of anti-transglutaminase antibodies as predictors of gluten free diet compliance in adult celiac disease. Am J Gastroenterol 2003; 98:1079–1087.
22. Marsh MN. Gluten, major histocompatibility complex, and the small intestine. Gastroenterology 1992; 102:330–354.
23. Dickey W, Hughes D. Disappointing sensitivity of endoscopic markers for villous atrophy in a high risk population: implications for celiac disease diagnosis during routine endoscopy. Am J Gastroenterol 2001; 96:2126–2128.
24. Shah VH, Rotterdam H, Kotler DP, et al. All that scallops is not celiac disease. Gastrointest Endosc 2000; 51:717.
25. Lecleire S, Di Fiore F, Antonietti M, et al. Endoscopic markers of villous atrophy are not useful for the detection of celiac disease in patients with dyspeptic symptoms. Endoscopy 2006; 38:696–701.
26. Bonamico M, Thanasi E, Mariani P, et al. Duodenal bulb biopsies in celiac disease: a multicenter study. J Paediatr Gastroenterol Nutr 2008; 47:618–622.
27. Pais WP, Duerksen DR, Pettigrew NM, Bernstein CN. How many duodenal biopsy specimens are required to make a diagnosis of celiac disease? Gastrointest Endosc 2008; 67:1082–1087.
28. Hopper AD, Cross SS, Sanders DS. Patchy villous atrophy in adult patients with suspected gluten-sensitive enteropathy: is a multiple duodenal biopsy strategy appropriate? Endoscopy 2008; 40:219–224.
29. Lo A, Guelrud M, Essenfeld H, Bonis P. Classification of villous atrophy with enhanced magnification endoscopy in patients with celiac disease and tropical sprue. Gastrointest Endosc 2007; 66:377.
30. Zambelli A, Villanacci V, Buscarini E, et al. Confocal laser endomicroscopy in celiac disease: description of findings in two cases. Endoscopy 2007; 39:1018–1020.
31. Hopper AD, Sidhu R, Hurlestone DP, et al. Capsule endoscopy: an alternative to duodenal biopsy for the recognition of villous atrophy in coeliac disease? Dig Liver Dis 2007; 39:145–147.
32. Rondonotti E, Spada C, Cave D, et al. Video capsule enteroscopy in the diagnosis of celiac disease: a multicenter study. Am J Gastroenterol 2007; 102:1624–1631.
33. Murray JA, Rubio-Tapia A, Van Dyke CT, et al. Mucosal atrophy in celiac disease: extent of involvement, correlation with clinical presentation, and response to treatment. Clin Gastroenterol Hepatol 2008; 6:186–193.
34. Daum S, Wahnschaffe U, Glasenapp R, et al. Capsule endoscopy in refractory celiac disease. Endoscopy 2007; 39:455–458.
35. Hadithi M, Al-toma A, Oudejans J, et al. The value of double-balloon enteroscopy in patients with refractory celiac disease. Am J Gastroenterol 2007; 102:987–996.

JAYPEE BROTHERS

Recent Advances in Gastroenterology 12

Recent Advances in Gastroenterology 12 is the ideal resource for keeping abreast of new developments in this fast-moving field. Written by expert authors and featuring topics such as IgG4 syndrome, ulcerative colitis and luminal imaging, each chapter highlights latest developments of relevance to clinical practice. This book is also an invaluable revision tool for trainees preparing for postgraduate examinations.

- Practical and clinically relevant content, enhanced by *Key Points for Clinical Practice* at the end of each chapter
- Chapters focus on important recent developments in the field of gastroenterology
- Effective exam revision tool for the gastroenterology portion of the MRCP(UK) and the SCE in Gastroenterology

JP medical publishers

www.jpmedpub.com

ISBN 978-1-907816-76-5