Recent Advances in Otolaryngology



Edited by
Holger Sudhoff • Mahmood Bhutta

Contents

Preface		v
Chapter 1	Optical diagnostics in head and neck cancer *Taranjit S Tatla, Adrian Gh Podoleanu, Daniel S Elson*	1
Chapter 2	Stem cells in head and neck cancer *Mark Prince*	21
Chapter 3	PET-CT in head and neck cancer *Wai Lup Wong, Bal Sanghera, Peter Ross*	31
Chapter 4	Middle ear implants *Ingo Todt*	43
Chapter 5	Tissue hypoxia in chronic otitis media *Mahmood F Bhutta, Michael T Cheeseman*	51
Chapter 6	Balloon dilation Eustachian tuboplasty *Holger Sudhoff, Jörg Ebmeyer, Stefanie Schröder, Martin Lehmann*	61
Chapter 7	Superior canal dehiscence syndrome *Rupan Banga, Richard Irving*	73
Chapter 8	Regeneration of hair cells in the inner ear: possibilities and challenges *Jonathan E Gale, Stephanie Juniat, Ruth R Taylor, Andrew Forge*	81
Chapter 9	Vestibular implants *Richard F Lewis, Daniel M Merfeld*	99
Chapter 10	The medical treatment of vascular anomalies *Oren Cavel, Julie Powell, Josée Dubois, Patrick Froehlich*	113
Index		131

Chapter 4

Middle ear implants

Ingo Todt

HISTORICAL ASPECTS

Whilst early attempts of active middle ear implants go back to the 1930 of the last century, the current motivation for the development of middle ear implant systems should consider the context of hearing aids and other implantable hearing systems.

In the early times of hearing aids, there was a limited ability to offer the patient sufficient energy to reach a proper gain to improve the understanding of speech. Therefore, active middle ear implants were in the 90s assumed to close the audiological gap between cochlear implants (CIs) and hearing aids. The disadvantage of ear moulds which close the external auditory canal and potentially cause eczema, chronic otitis externa should be overcome by active middle ear systems, which allowed the external auditory canal to remain open. This was a great advantage in terms of clinical indications [1]. The problem of limited functional gain obtained by hearing aids in the high-frequency range seemed to be resolved by active middle ear implants.

On one hand, current developments of hearing aids with modern high-frequency algorithms (sound recovery, frequency transposition) and expanding indication criteria for CIs by excellent results in patients with residual hearing limit the group of patients with classical audiological indications. On the other hand, recent developments of extended audiological indication criteria for those with conductive or mixed hearing loss originating from 'alternative coupling' of actors (e.g. to ossicle residues) the round/oval window (RW/OW) or third window will include new patient groups, which were the domain of bone – anchored hearing systems or hearing aids so far. Choosing the right hearing system is – in a fast developing and changing field of hearing systems, overlapping indications and country-specific economic limitations – a demanding task.

PRINCIPLES

With the exception of anomalies, active middle ear implants are a second-line treatment option. Before deciding for an active middle ear implant, modern hearing aids have to be sufficiently tried. Before choosing an active middle ear system in cases of conductive or mixed hearing loss, additional middle ear surgeries should have made the outer ear canal dry and ready to use hearing aids.

Ingo Todt MD, Associate Professor, Department of Otolaryngology, Head and Neck Surgery, Unfallkrankenhaus, Berlin, Germany. E-mail: todt@gmx.net (for correspondence)

JAYPEE BROTHERS

INDICATIONS AND DIFFERENTIAL INDICATIONS

Currently, we can differentiate between an audiological and a clinical indication for middle ear implant systems. The middle ear implant systems should be taken into consideration if other less invasive systems do not cover the audiological indication criteria to provide an acceptable speech understanding. The audiological indication for a 'classical' incus coupling of the Vibrant Soundbridge (VSB) as given by the manufacturer can be seen in **Figure 4.1**. The one for the middle ear transducer (MET) is described in **Figure 4.2**.

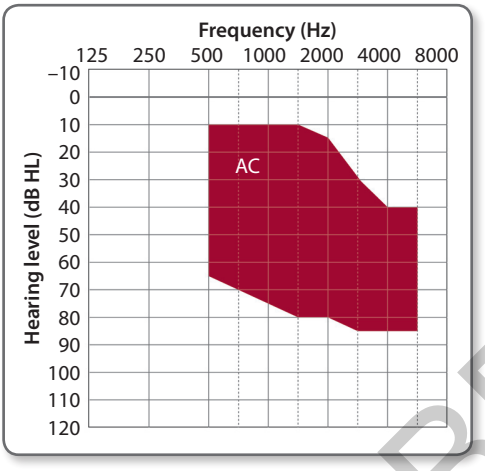

Figure 4.1 Audiological indication criteria for the Vibrant Soundbridge and pure sensorineural hearing loss.

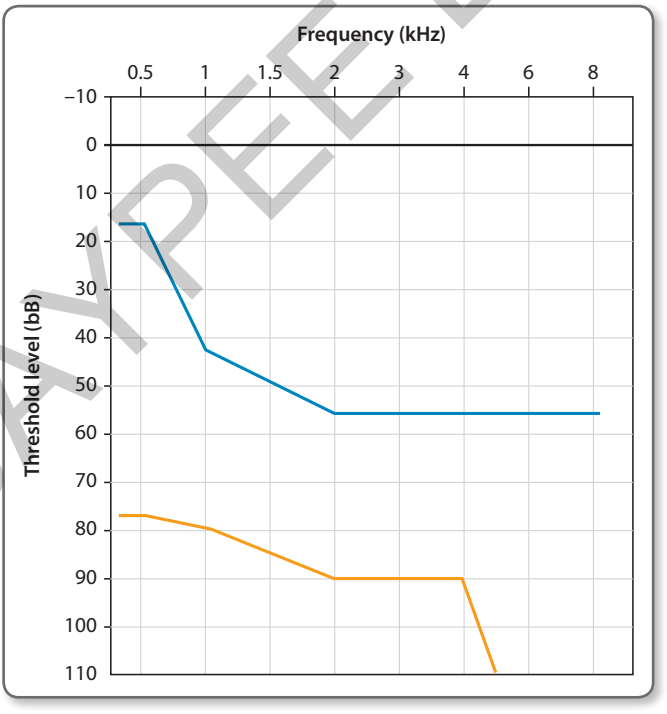

Figure 4.2 Audiological indication criteria for the middle ear transducer and pure sensorineural hearing loss.

JAYPEE BROTHERS

The audiological indication criteria for a conductive and mixed hearing loss for the VSB are given in **Figure 4.3**. Since the development of other, competing hearing systems is fast ongoing, a permanent comparison of the indications of the different systems should be attempted.

Looking at the pure sensorineural hearing loss (SNHL) indication, hearing aid systems with frequency compression or transposition algorithms are trying to cover the audiological indication field of high-frequency SNHL or 'ski-slope' hearing loss (Phonak Sound Recovery, Widek Frequency Transposition) which is overlapping with the recommended indication for the VSB. Therefore, a sufficient testing period (minimum 2 weeks) of current hearing aids should be preferred in those cases. Since the indication corridor for the MET covers even more the low-frequency range, other specific power hearing aids should be tested prior to surgery.

If the hearing loss exceeds 60–70 dB, an overlap with CI systems can occur (e.g. a hybrid or electric and acoustic stimulation). Looking at those pure conductive hearing losses, a fitting with a bone conductive system should be kept in mind. The transcutaneous systems (BAHA, Cochlear, Sydney, Australia; Ponto, Oticon, Denmark) and even the percutaneous systems (Vibrant Bonebridge, Medel, Innsbruck, Austria) offer in some cases a better solution for the patient (i.e. less risky) than the active middle ear implants. However, those bone conductive systems have only the audiological ability to close an air-bone gap. This limits their indication corridor to cases of <35 dB bone conduction (BC) SNHL. Additionally, a time and disease-related progressive threshold shift can be seen and should be kept in mind.

Looking at combined hearing losses on average, hearing aids can overcome an air-bone gap of 30–35 dB. In cases of larger air-bone gaps (ABGs), a middle ear implant can be indicated. In general, even in those cases a hearing aid should be tested before the possible implantation of an active middle ear system. Although a medical indication cannot be completely separated from the audiological indication, there are specific constellations where an active middle ear systems is the only medical solution for a patient.

In cases of chronic otitis externa in combination with a SNHL after multiple tests with ear moulds, only an active middle ear system can help the patient. Hearing losses in cases of radical cavities ('canal- wall- down') caused by cholesteatoma surgeries can often only be treated by an active middle ear system since fitting with hearing aids leads in many cases to an otorrhoea.

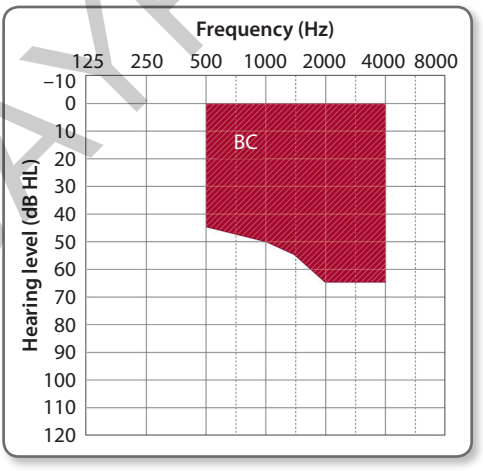

Figure 4.3 Audiological indication criteria for the Vibrant Soundbridge for the inner ear function in cases of mixed hearing loss.

JAYPEE BROTHERS

Anomalies especially in children are described to be treated by active middle ear systems, but in those cases a critical comparison with bone conductive systems should be done. Although described as a one-step treatment in cases of otosclerosis, the indication for an active middle ear implant system should be critically considered. A regular indication for an active middle ear implant system is an ear with chronic otitis media, which, after multiple middle ear surgeries, has become dry, but with persisting mixed hearing loss.

SYSTEMS

There are currently five different middle ear systems on the European market. The VSB system (Medel, Austria, Innsbruck) consists of an implanted receiver with a magnet, demodulator and a cable attached to an electromagnetic actor called floating mass transducer (FMT). This actor has an attached clip, which allows the fixation to the long process of the incus. The FMT can be fixed to the stapes head or after removal of the clip attached to the RW. The addition of coupler elements offers a standardised attachment to the RW, the OW or the stapes suprastructure.

The audioprocessor is in the fifth generation and has a 16 canal processor and two directional microphones. The system has a conformity marking of the European community market (CE) and is currently FDA approved for an incus attachment application. The MET systems (Boulder, Colorado, USA) consist of an implant with a magnet and a spoil with an electromagnetically driven actor which is attached to the head of the incus, the RW or to the stapes head. The system is fixed in the mastoid cavity by a plating system. The system has a CE mark. The Carina system consists of the same ossicular actor and fixation system in the mastoid. In contrast to the MET, a fully implantable microphone and a reloadable battery are attached. The system has a CE mark.

The direct acoustic cochlear stimulation (DACS) system consists of a magnet and a receiver. The receiver is fixed in the mastoid cavity by a plating system. The actor is electromagnetically driven. The actor contains a rod with an element for the fixation for a stapes prosthesis. The audioprocessor is the known cochlear freedom audioprocessor with specific modifications. The system has recently reached the CE mark.

The Esteem system (Envoy Medical, St. Paul, Minnesota, USA) is a fully implantable system and consists of a magnet and a receiver. A sensor which is attached to the malleolus catches the natural sound and transmits the signal to the receiver, which converts the signals and sends them to a piezo actor which is connected to the stapes. The ossicular chain has to be interrupted to prevent feedback. The system is FDA approved and has the CE mark.

The Maxum system (Ototronix, Texas, USA) is similar to the previously known Soundtec system. It consists of a stapes joint attached magnet and a specific ear canal device. The ear canal device steers the magnet by the application of a magnetic field. The device has the FDA approval and the CE mark.

SURGERIES

The different systems follow – with the exception of the Maxum system – a transmastoidal route for implantation. The usual surgical approach for the attachment of the VSB system at the long process of the incus consists of a mastoidectomy and a posterior tympanotomy. The FMT-clip is pushed onto the incus and crimped. Additional fixation to minimise

JAYPEE BROTHERS

surgical variations in the quality of attachment has been performed by the addition of bone cement or the push over of a Soft-Clip stapes prosthesis head. Surgical approaches without a mastoidectomy, but burying a canal through the external auditory canal, have been described.

In cases of pure conductive or mixed hearing loss, the FMT can be attached to different structures. Besides, the previously described surgical approach via a posterior tympanotomy can be performed in cases of canal-wall-down surgeries. For those cases, a two-step procedure consisting of a partial obliteration with cartilage, Palva flap, bone pate… and secondly a FMT attachment is recommended. In this way, the risk of a cable extrusion is minimised, and in addition, a revision without risking the implant is possible.

The attachment to the RW was performed for the first time by Colletti [2] in 2005. The RW attachment has been described in different ways. Whilst a cartilage support behind the FMT is commonly used, the contact between RW and FMT can vary. Whilst Colletti used Tutopatch, others place the FMT directly on the RW. Alternatively fascia, cartilage, Ivalon or a Kurz (Dusslingen, Germany) coupler is used. Common sense is that the RW should be well visualised after removal of the promontorial lip before placing the FMT. The frequently found differences in diameter between RW and the FMT have to be considered.

If persisting, an attachment on the stapes can be performed by a direct crimping of the FMT-clip onto it. The introduction of Kurz couplers (Clip, Bell, OW) allowed a more standardised attachment of the FMT to middle ear structures. The attachment on the OW has been described by the positioning of a cartilage piece with perichondrium on the footplate and wrapping it around the FMT. Newer developments allow the attachment on the OW with a specific total ossicular replacement prosthesis (TORP)-like coupler. The coupler is stabilised in the OW niche with a cartilage shoe [3].

A general recommendation for a coupling site of the FMT cannot be given. Since the audiological aim of an aided hearing threshold at 25–35 dB can be reached with all kinds of coupling, the chosen coupling site depends on the anatomic situation, the experience and preference of the surgeon and can easily be modified throughout surgery. In cases of occluded RW, high jugular bulb and fixed OW, the burring of an artificial third window and the attachment of the FMT directly on the endosteum has been described.

Even the fixation of the FMT additional to a stapes prosthesis on the long process of the incus called ‘Power-Stapes’ is known. Alternatively to stapes surgery, the direct insertion of a specific FMT coupler in a stapedotomy hole was successfully performed [4].

The MET surgery consists of a mastoidectomy. Mastoid size needs to be confirmed preoperatively to verify a proper ability to place the plating system for the actor inside the cavity and to exclude a low middle fossa obliterating the access to the short process of the incus. The actor and its transmission rod are attached to the incus for cases of SNHL. The actors load on the short process of the incus needs to be determined. In cases of conductive or mixed hearing loss, the coupling element of the actor can be positioned through a posterior tympanotomy on the RW with added fascia or with a specific coupling element on the stapes head [5]. A solution in cases of nonpersisting external canal wall is so far to our knowledge not described. In cases of Carina surgeries, the position of the microphone needs to be considered. It is recommended to be placed the microphone not under the temporalis muscle to minimise secondary noise by chewing.

The DACS systems actor position is even determined by a plating system. The actor is directed through a posterior tympanotomy over the OW. After a stapedotomy, a stapes prosthesis is inserted and fixed on the specific rod element of the actor. The vibration of the

JAYPEE BROTHERS

actor drives the stapes prosthesis. So far the indication of the system is limited to stapes surgery cases.

The Esteem surgery consists of a mastoidectomy and a very exact laser Doppler vibrometric controlled positioning of the sensor and the actor on the malleolus and the stapes head. The Maxum surgery can be performed, in contrast to the previous surgeries, in local anaesthesia. The surgery consists of a regular elevation of the tympanic membrane followed by an opening of the incudostapedial joint. Then the magnet is placed through the joint and the joint is closed. Disadvantage is a mandatory device in the ear canal.

RESULTS

The published results of the different systems depend very much on the included number of patients and the specific audiologic criteria. Therefore, a direct comparison of the systems is difficult to achieve.

The audiological result with the VSB system in cases of pure SNHL described a functional gain (aided hearing threshold over BC) of up to 30 dB [6]. The hearing gain (aided hearing threshold over AC) in cases of pure conductive and mixed hearing loss is described to be between 30 and 65 dB [3]. A difference between the different coupling options at the stapes showed no significant advantage of one over another [7]. All applications offer a sufficient gain to reach the target hearing threshold of 25–35 dB.

This holds true for all systems. The MET systems data described a functional gain between 15–20 and 39 dB [8,9]. The DACS system offers a functional gain of 17 dB and a hearing gain of 46 dB [10]. Data of the Esteem system showed a functional gain of 12 dB [11]. Maxum data showed a functional gain of 26 dB [12]. A subjective advantage in comparison to conventional hearing aids with its ear moulds has been described for all systems.

SPECIAL CONSIDERATIONS

The MRI compatibility of active middle ear implants is an important topic nowadays since the number of scans/lifetime is rising, as well as the number of implants and the tesla magnetic strength. Although only for the VSB system and the Maxum/Soundtec system described, a defined 'magnet shadow' (i.e. blackening) artefact was reported for both [13,14] and can be assumed for all systems.

Complications due to MRI scanning were described, but without serious medical complications (pain, dislocation of FMT) reported for the VSB at 1.5 T. Hearing losses or dislocations of the ossicular chain were not found when systematically investigating this subject [15]. The Maxum system is approved for 0.3 T scans [14], but no experiences exist beyond this limit.

Key points for clinical practice

- The number of patients who are candidates for active middle ear implants is highly limited in SNHL [16]. Those patients with mixed hearing loss are considered as the main patient population to be supplied with active middle ear implants.
- The treatment with active middle ear implants is a second-line treatment with the exception of anomalies.
- A trial with modern digital hearing aids is mandatory.

JAYPEE BROTHERS

REFERENCES

1. Lenarz T, Weber BP, Mack KF, Battmer RD, Gnadeberg D. The Vibrant Soundbridge System: a new kind of hearing aid for sensorineural hearing loss. 1: function and initial clinical experiences. Laryngorhinootologie 1998; 77:247–255.
2. Colletti V, Soli SD, Carner M, Colletti L. Treatment of mixed hearing losses via implantation of a vibratory transducer on the round window. Int J Audiol 2006; 45(10):600-608.
3. Luers JC, Hüttenbrink KB, Zahnert T, Bornitz M, Beutner D. Vibroplasty for mixed and conductive hearing loss. Otol Neurotol 2013; 34:1005–1012.
4. Arauz SL, Mercandino EC, Campo E, Arauz SA. Vibrant Soundbridge-ubucacion en ventana oval utilizando proteseis-ad hoc. Otorinolaringologica 2007; 4:10–15.
5. Martin C, Deveze A, Richard C, et al. European results with totally implantable carina placed on the round window: 2-year follow-up. Otol Neurotol 2009; 30:1196–1203.
6. Todt I, Seidl RO, Ernst A. Hearing benefit of patients after Vibrant Soundbridge implantation. ORL J Otorhinolaryngol Relat Spec 2005; 67:203–206.
7. Coordes A, Ernst A, Todt I. Assessment of VSB attachments for the stapes head coupling. Int CI, Baltimore,3-5 May 2012, Abstract #237802.
8. Jenkins HA, Niparko JK, Slattery WH, Neely JG, Fredrickson JM. Otologics Middle Ear Transducer Ossicular Stimulator: performance results with varying degrees of sensorineural hearing loss. Acta Otolaryngol. 2004; 124:391–394.
9. Tringali S, Perrot X, Berger P, et al. Otologics middle ear transducer with contralateral conventional hearing aid in severe sensorineural hearing loss: evolution during the first 24 months. Otol Neurotol 2010; 31:630–636.
10. Lenarz T, Zwartenkot JW, Stieger C, et al. Multicenter study with a direct acoustic cochlear implant. Otol Neurotol 2013; 34:1215–1225.
11. Chen DA, Backous DD, Arriaga MA, et al. Phase 1 clinical trial results of the Envoy System: a totally implantable middle ear device for sensorineural hearing loss. Otolaryngol Head Neck Surg 2004; 131:904–916.
12. Silverstein H, Atkins J, Thompson JH Jr, Gilman N. Experience with the SOUNDTEC implantable hearing aid. Otol Neurotol 2005; 26:211–217.
13. Todt I, Seidl RO, Mutze S, Ernst A. MRI scanning and incus fixation in vibrant soundbridge implantation. Otol Neurotol 2004; 25:969–972.
14. Dyer RK Jr, Nakmali D, Dormer KJ. Magnetic resonance imaging compatibility and safety of the SOUNDTEC Direct System. Laryngoscope 2006; 116:1321–1333.
15. Todt I, Wagner J, Goetze R, et al. MRI scanning in patients implanted with a Vibrant Soundbridge. Laryngoscope 2011; 121:1532.
16. Junker R, Gross M, Todt I, Ernst A. Functional gain of already implanted hearing devices in patients with sensorineural hearing loss of varied origin and extent: Berlin experience. Otol Neurotol 2002; 23:452–456.

JAYPEE BROTHERS

Recent Advances in Otolaryngology 9

Recent Advances in Otolaryngology 9 is the ideal resource for keeping abreast of new developments in this constantly changing field. Written by experts and featuring topics such as stem cells in head and neck cancer and balloon dilation Eustachian tuboplasty, each chapter highlights the latest developments of relevance to clinical practice. This book is an invaluable update and revision tool for trainees preparing for postgraduate examinations.

- Practical and clinically relevant content, enhanced by Key Points for Clinical Practice at the end of each chapter
- Chapters focus on significant recent developments in the field of otolaryngology
- Effective revision tool for candidates preparing for postgraduate examinations

JP medical publishers

www.jpmedpub.com

ISBN 978-1-907816-89-5