

HANDBOOK OF DIRECT IMMUNOFLUORESCENCE

A PATTERN-BASED APPROACH TO SKIN AND MUCOSAL BIOPSIES

Douglas R Fullen
May P Chan
Aleodor A Andea
David P Arps

JP

Contents

Preface		v
Acknowledgements		x
Introduction	Immunofluorescence techniques and protocols *Aleodor A Andea*	xi

Section I: EPITHELIAL INTERCELLULAR STAINING PATTERN

Chapter 1	Pemphigus vulgaris *Douglas R Fullen*	3
Chapter 2	Pemphigus vegetans *Douglas R Fullen*	9
Chapter 3	Pemphigus foliaceus *Douglas R Fullen*	15
Chapter 4	Pemphigus herpetiformis *Douglas R Fullen*	21
Chapter 5	IgA pemphigus *May P Chan*	25
Chapter 6	IgG/IgA pemphigus *Douglas R Fullen*	31

Section II: EPITHELIAL NUCLEAR STAINING PATTERN

Chapter 7	Connective tissue diseases *May P Chan*	39
Chapter 8	Chronic ulcerative stomatitis *May P Chan, Douglas R Fullen*	45

Section III: EPITHELIAL INTERCELLULAR AND BASEMENT MEMBRANE ZONE STAINING PATTERN

Chapter 9	Paraneoplastic pemphigus *May P Chan*	51
Chapter 10	Pemphigus erythematosus *May P Chan*	57

Section IV: LINEAR BASEMENT MEMBRANE ZONE STAINING PATTERN

Chapter 11 Bullous pemphigoid 65
Aleodor A Andea

Chapter 12 Mucous membrane pemphigoid (cicatricial pemphigoid) 75
Aleodor A Andea

Chapter 13 Epidermolysis bullosa acquisita 81
Aleodor A Andea

Chapter 14 Bullous lupus erythematosus 87
May P Chan

Chapter 15 Linear IgA bullous dermatosis 93
Aleodor A Andea

Chapter 16 Pemphigoid gestationis (herpes gestationis) 97
Aleodor A Andea

Chapter 17 Lichen planus pemphigoides 101
May P Chan

Chapter 18 Anti-p200 pemphigoid 107
Aleodor A Andea

Section V: GRANULAR BASEMENT MEMBRANE ZONE STAINING PATTERN

Chapter 19 Dermatitis herpetiformis 113
David P Arps

Chapter 20 Lupus erythematosus 119
May P Chan

Chapter 21 Nonspecific granular dermoepidermal junction staining 127
May P Chan

Section VI: FIBRILLAR BASEMENT MEMBRANE ZONE STAINING PATTERN

Chapter 22 Lichen planus 133
David P Arps

Section VII: CYTOID BODIES

Chapter 23 Interface dermatitis/mucositis 141
David P Arps

Section VIII: GRANULAR VASCULAR STAINING PATTERN

Chapter 24 Leukocytoclastic vasculitis 149
David P Arps

Chapter 25 Henoch–Schönlein purpura 155
David P Arps

Chapter 26 Nonspecific granular vascular staining 161
David P Arps

Section IX: SMOOTH VASCULAR STAINING PATTERN

Chapter 27 Porphyria cutanea tarda 167
Douglas R Fullen

Chapter 28 Pseudoporphyria 173
Douglas R Fullen

Chapter 29 Nonspecific smooth vascular staining 177
Douglas R Fullen

Index 183

Section I

Epithelial intercellular staining pattern

Chapter 1 Pemphigus vulgaris
Chapter 2 Pemphigus vegetans
Chapter 3 Pemphigus foliaceus
Chapter 4 Pemphigus herpetiformis
Chapter 5 IgA pemphigus
Chapter 6 IgG/IgA pemphigus

JAYPEE BROTHERS

1 Pemphigus vulgaris

Clinical presentation

Pemphigus vulgaris (PV), the most common type of pemphigus, is a rare, chronic autoimmune blistering disease that involves skin and mucosal epithelium. The incidence of PV is estimated at 1–5 individuals per million residents with a higher incidence in individuals of Japanese and Ashkenazi Jewish descent.[1] Onset of disease is usually in the 4th to 6th decade of life, although very rare cases occur in children. Men and women are affected equally.[2]

Most patients initially develop painful erosions on mucous membranes with prominent involvement of the oral cavity. Involvement of mucosa of the genital tract, anus, rectum, pharynx, larynx, and esophagus may ensue. Skin involvement usually follows mucosal disease and presents as flaccid bullae that are prone to spread peripherally, corresponding to a positive Nikolsky sign, and rupture easily resulting in erosions and large denuded areas. These skin lesions have a predilection for the scalp, face, sternum, extremities and groin.

The mortality rate is approximately 5–10% and is primarily the result of infections in the setting of immunosuppressive therapy. Approximately 40% of patients in remission after therapy for the initial flare have no further exacerbations. Another 30% of patients experience a relapsing and remitting disease requiring chronic maintenance immunosuppression.[2] Patients with longstanding disease may transition from clinical features of PV to pemphigus foliaceus (PF).

Pathogenesis

The pathogenesis of PV involves a complex interaction of genetic, immunologic and environmental factors. The primary autoantibody responsible for the clinical manifestations of PV targets desmoglein 3 (Dsg3), a member of the cadherin superfamily, within stratified epithelium.[3–5] However, more than 50% of patients will also have circulating antibody against desmoglein 1 (Dsg1). Patients with only anti-Dsg3 have mucosal disease with little to no skin manifestation (mucosal dominant), whereas patients with mucocutaneous disease have circulating anti-Dsg1 and anti-Dsg3.[5] Recently, a strong association between HLA class II haplotypes HLA-DR4 and HLA-DR6 and PV has been reported with over 95% of patients carrying one of the alleles. The two alleles most associated with PV in the non-Jewish population are DRB1*0402 and DQB1*0503, whereas DRB1*0402 is the sole allele responsible for increased susceptibility in the Ashkenazi Jewish population.[6] Environmental factors, such as medications, pesticides, ultraviolet radiation, malignancy and stress, may incite a flare of PV.[7]

Antigen mimicry and epitope spreading are key factors that determine the clinical features manifested and therefore the type of pemphigus. Exogenous antigens, such as bacterial or viral proteins or medications, may closely mimic endogenous structural proteins of the desmosomal plaque leading to the generation of various autoantibodies. Autoimmune response can spread to different epitopes on the same structural protein or similar proteins resulting in a shift from mucosal dominant PV to mucocutaneous PV, PV to PF, or vice versa over time.[8]

Histopathology

Early lesions may show eosinophilic spongiosis or spongiosis and acantholysis. Acantholysis subsequently results in cleft formation and eventually bullae with suprabasal localization in the epidermis (**Figure 1.1**). Acantholytic cells within the blister cavity are discohesive and appear rounded up (**Figure 1.2**). A Tzanck smear has been used to evaluate for these acantholytic keratinocytes in patients suspected of having PV. The basal keratinocytes remain attached to the dermis and form a single layer along the floor of the bulla likened to a 'row of tombstones' (**Figure 1.3**). Extension of acantholysis and cleft formation down hair follicle and sebaceous epithelium

JAYPEE BROTHERS

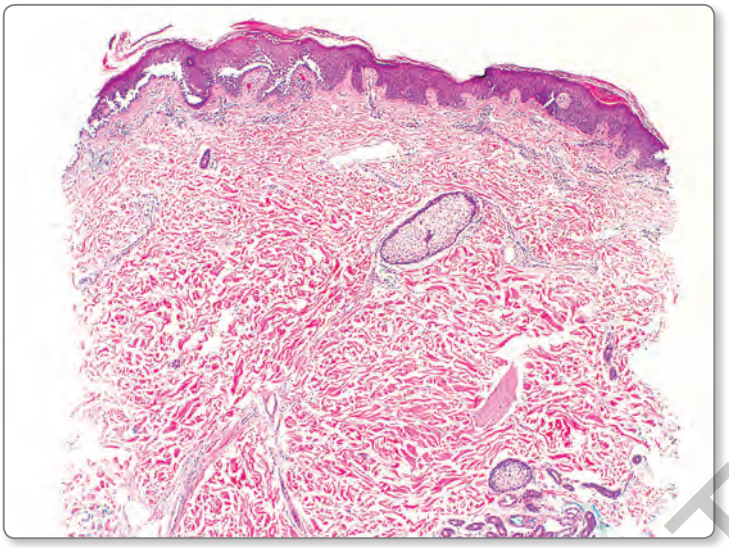

Figure 1.1 Pemphigus vulgaris (histopathology). An intraepidermal split is seen on the left-hand side of this punch biopsy.

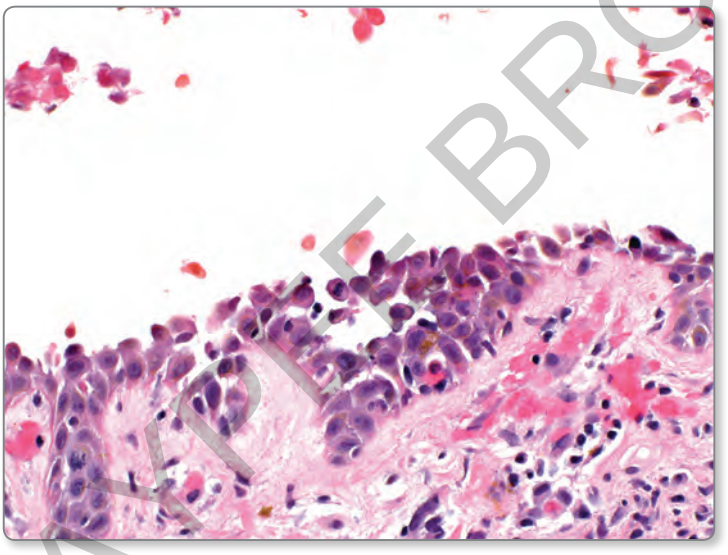

Figure 1.2 Pemphigus vulgaris (histopathology). Acantholytic keratinocytes appear discohesive and rounded up within the blister cavity.

JAYPEE BROTHERS

is often observed (**Figure 1.4**). Identical histopathologic features are seen in mucosal epithelium.

Direct immunofluorescence

Direct immunofluorescence examination of perilesional skin biopsies from patients with PV show cell surface (intercellular) deposition of IgG and C3 in a linear, lace-like or 'chicken wire' pattern within the epidermis or mucosal epithelium (**Figures 1.5** and **1.6**). Preferential staining in the lower layers of the epidermis or mucosa may be seen in some cases (**Figure 1.7**). More frequently, however, the staining pattern is present through all levels of the epidermis or mucosal epithelium (**Figure 1.8**). A punctate or dot-like pattern of deposits may be seen as the sole pattern or admixed with the 'chicken wire' pattern (**Figure 1.9**).[9]

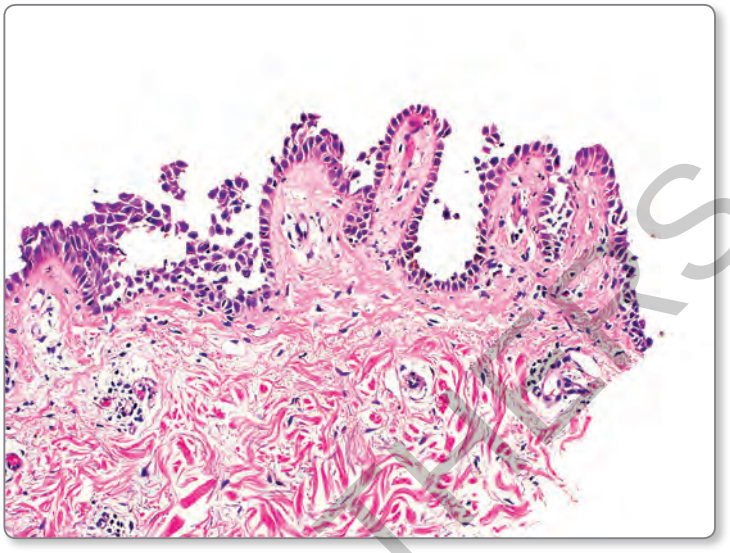

Figure 1.3 Pemphigus vulgaris (histopathology). Basal layer keratinocytes remain attached to the basement membrane and form a 'row of tombstones' along the floor of the bulla.

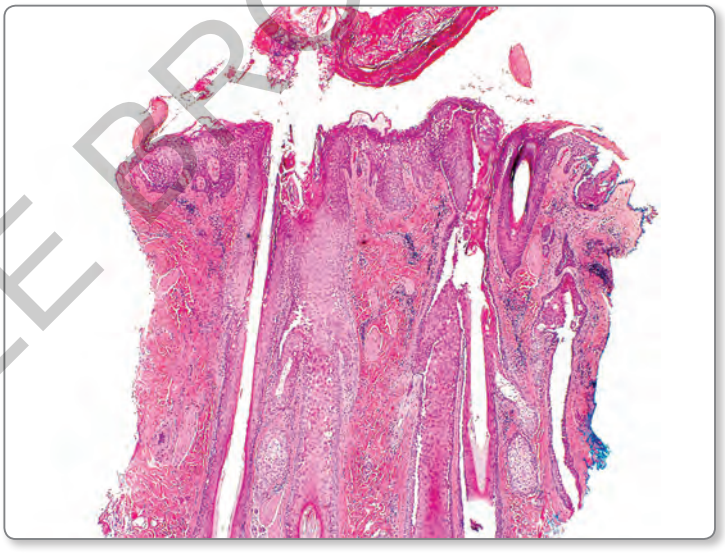

Figure 1.4 Pemphigus vulgaris (histopathology). Intraepithelial clefts with acantholysis often extend down hair follicles and sebaceous glands.

JAYPEE BROTHERS

Indirect immunofluorescence

Anti-Dsg3 and, to a lesser extent, anti-Dsg1 can be detected using monkey esophagus or normal human skin substrate in the sera of approximately 90% of PV patients. The titer of circulating antibody correlates with severity of disease and can be used to monitor disease activity.[10,11]

ELISA

Enzyme-linked immunosorbent assay (ELISA) is the most sensitive and specific method for detecting circulating anti-Dsg3 and anti-Dsg1 in patients with pemphigus. The reported sensitivity exceeds 90% and the specificity is approximately 95%.[12,13]

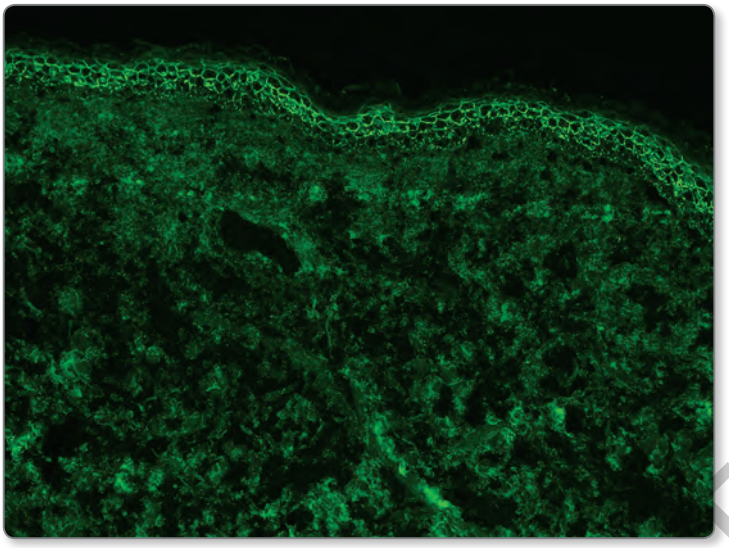

Figure 1.5 Pemphigus vulgaris [direct immunofluorescence (IgG)]. A lace-like or 'chicken wire' pattern of immune deposition is evident within the epidermis.

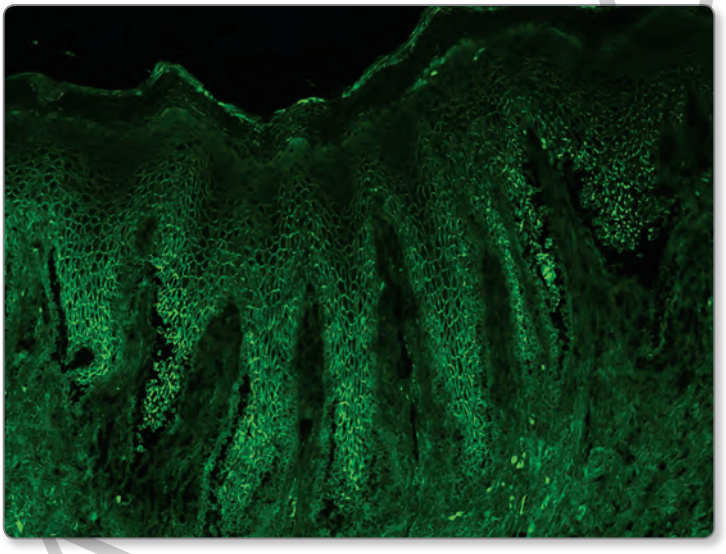

Figure 1.6 Pemphigus vulgaris [direct immunofluorescence (IgG)]. An intercellular 'chicken wire' pattern of deposition is present in the oral mucosa of this patient with desquamative mucositis.

JAYPEE BROTHERS

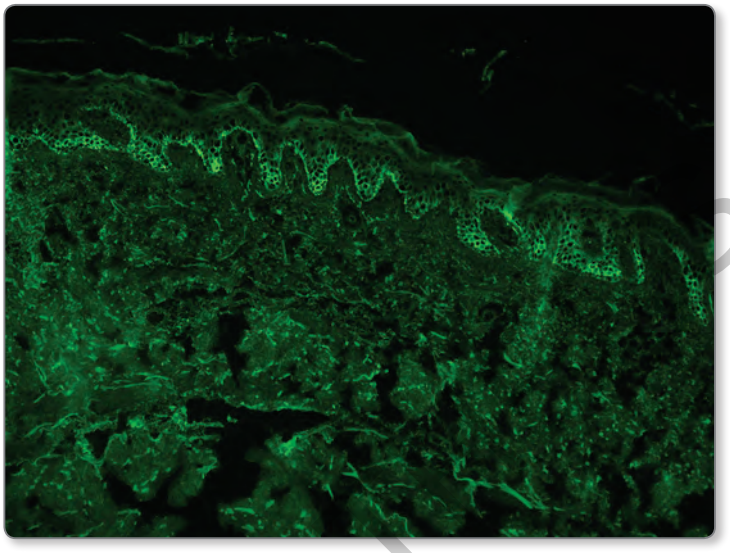

Figure 1.7 Pemphigus vulgaris [direct immunofluorescence (C3)]. Preferential staining of the lower epidermis in a lace-like or 'chicken wire' pattern in a patient with PV.

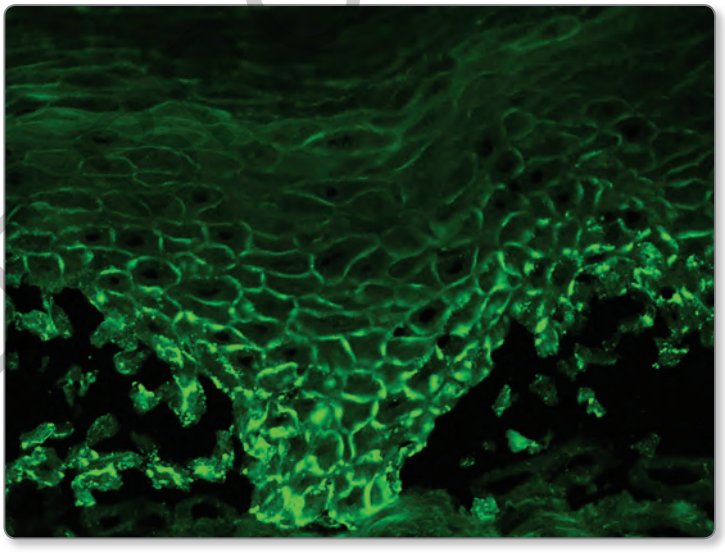

Figure 1.8 Pemphigus vulgaris [direct immunofluorescence (IgG)]. Immune deposition of IgG throughout the epidermis in a predominantly continuous 'chicken wire' pattern. Acantholysis is present in the lower epidermis.

JAYPEE

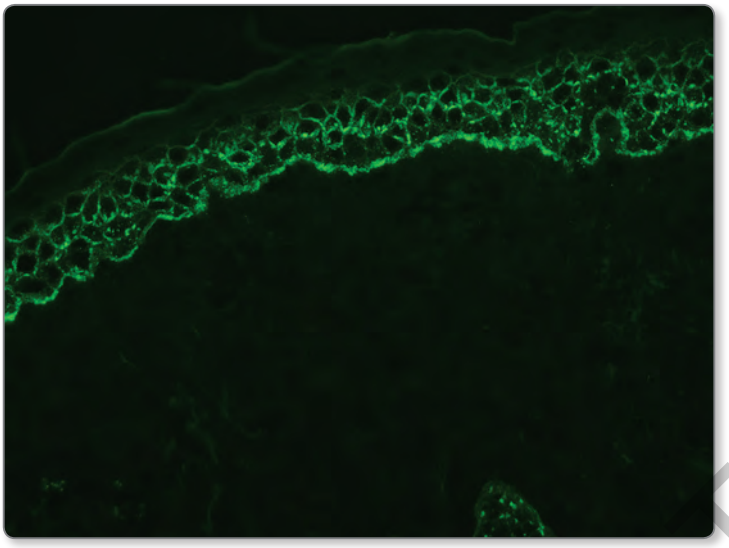

Figure 1.9 Pemphigus vulgaris [direct immunofluorescence (IgG)]. A mixed pattern of 'chicken wire' pattern primarily in the superficial epidermis and punctate pattern in the lower epidermis is present in this case.

JAYPEE BROTHERS

References

1. Joly P, Litrowski N. Pemphigus group (vulgaris, vegetans, foliaceus, herpetiformis, brasiliensis). Clin Dermatol 2011; 29:432–436.
2. Ahmed AR. Clinical features of pemphigus. Clin Dermatol 1983; 1:13–21.
3. Shimuzu A, Ishiko A, Ota T, et al. IgG binds to desmoglein 3 in desmosomes and causes a desmosomal split without keratin retraction in a pemphigus mouse model. J Invest Dermatol 2004; 122:1145–1153.
4. Amagai M. Autoantibodies against cell adhesion molecules in pemphigus. J Dermatol 1994; 21:833–837.
5. Amagai M, Tsunoda K, Zillikens D, et al. The clinical phenotype of pemphigus is defined by the anti-desmoglein autoantibody profile. J Am Acad Dermatol 1999; 40:167–170.
6. Sinha AA. The genetics of pemphigus. Dermatol Clin 2011; 35:381–391.
7. Venugopal SS, Murrell DF. Diagnosis and clinical features of pemphigus vulgaris. Dermatol Clin 2011; 29:373–380.
8. Tchernev G, Orfanos CE. Antigen mimicry, epitope spreading and the pathogenesis of pemphigus. Tissue Antigens 2006; 68:280–286.
9. Ko CJ, McNiff JM. Punctate pemphigus: an underreported direct immunofluorescence pattern. J Cutan Pathol 2014; 41:293–296.
10. Weissman V, Feverman FJ, Joshua H, Hazaz B. The correlation between antibody titers in sera of patients with pemphigus vulgaris and their clinical state. J Invest Dermatol 1978; 71:107–113.
11. Kanitakis J. Indirect immunofluorescence microscopy for the serological diagnosis of autoimmune blistering skin diseases: a review. Clin Dermatol 2001; 19:614–621.
12. Amagai M, Komai A, Hashimoto T, et al. Usefulness of enzyme-linked immunosorbent assay using recombinant desmogleins 1 and 3 for serodiagnosis of pemphigus. Br J Dermatol 1999; 140:351–357.
13. Ng PP, Thng ST, Mohamed K, Tan SH. Comparison of desmoglein ELISA and indirect immunofluorescence using two substrates (monkey esophagus and normal human skin) in the diagnosis of pemphigus. Australas J Dermatol 2005; 46:239–241.

HANDBOOK OF DIRECT IMMUNOFLUORESCENCE

A PATTERN-BASED APPROACH TO SKIN AND MUCOSAL BIOPSIES

Immunofluorescence is a key tool in the dermatopathologic diagnosis of vesiculobullous and connective tissue diseases, vasculitis and other cutaneous disorders. Interpreting its results and correlating these with the histopathology is a skill required of dermatopathologists and, increasingly, of dermatologists.

Handbook of Direct Immunofluorescence is divided into sections according to immunofluorescence pattern. Within sections, each chapter is dedicated to one of the diseases likely to be encountered by the clinician.

Chapters are highly structured, opening with essential information on clinical presentation and pathogenesis, followed by illustrated discussion of the histopathology and interpretation of direct and indirect immunofluorescence. Special guidance is provided on recognizing nonspecific findings and avoiding diagnostic pitfalls.

- Practical, clinically oriented resource for dermatopathologists, oral and general pathologists, and dermatologists
- Multiple images showing the range of histopathologic and immunofluorescence findings associated with each disease
- Pattern-based approach, as a framework for understanding disorders, reaching diagnoses and recognizing when to order further tests

Also available from JP Medical



Diagnostic Dermatopathology
Gregory A Hosler

Handbook of Dermatology Treatments
Michael Ardern-Jones
Philip Hampton
Ruth Ann Vleugels

JP medical publishers

www.jpmedpub.com

ISBN 978-1-907816-90-1
9 781907 816901