

AESTHETIC FACIAL RECONSTRUCTION AFTER MOHS SURGERY



Salvatore J Pacella
Mark A Codner

Contents

Preface v

Acknowledgements vi

Contributors xi

Dedications xii

Chapter 1
A primer on Mohs surgery technique 1
Hubert (Hugh) T. Greenway, Salman M. S. Alsaad, Brent R. Taylor, Ashley Wysong

Chapter 2
Histologic review of common skin cancers 11
Kelly L. Harms, Paul W. Harms, Timothy M. Johnson

Chapter 3
Aesthetic concepts in facial soft tissue reconstruction 23
Salvatore J. Pacella, Mark A. Codner

Chapter 4
Wound closure: physiology, techniques and aftercare 33
Salvatore J. Pacella, Mark A. Codner

Chapter 5
Approach to defects of the forehead, eyebrow and temporal region 49
Salvatore J. Pacella, Mark A. Codner

Chapter 6
Reconstruction of the auricle 61
Salvatore J. Pacella, Mark A. Codner

Chapter 7
Approach to defects of the upper eyelid and medial canthus 81
Kunaal Jindal, Salvatore J. Pacella, Mark A. Codner

Chapter 8
Approach to defects of the lower eyelid and lateral canthus 99
Salvatore J. Pacella, Kunaal Jindal, Mark A. Codner

Chapter 9
Aesthetic concepts in nasal reconstruction 137
Salvatore J. Pacella, Mark A. Codner

Chapter 10
Reconstruction of the midcheek 179
Salvatore J. Pacella, Mark A. Codner

Chapter 11
Reconstruction of the lateral cheek 193
Salvatore J. Pacella, Mark A. Codner

Chapter 12
Approach to defects of the lips and perioral region 201
Kunaal Jindal, Salvatore J. Pacella, Mark A. Codner

Chapter 13
Scar physiology and non-surgical scar management 221
Peter R. Shumaker, Leah K. Spring, Douglas A. Winstanley

Chapter 14
Aesthetic surgical treatment of scar deformities 235
Mark A. Codner, Salvatore J. Pacella

Index 249

DVD-ROM contents

Supplementary videos are cited in the relevant chapter with the symbol.

Video 1
Instruments and suture techniques (Chapter 4)
Salvatore J. Pacella

Video 2
Design of transpositional flap for nasal tip defect (Chapter 4)
Mohammed Alghoul

Video 3
Design of rotational advancement flap for nasal tip defect (Chapter 4)
Mohammed Alghoul

Video 4
Design of bilateral advancement flaps for forehead defect (Chapter 4)
Mohammed Alghoul

Video 5
Reconstruction of central forehead defect with bilateral O-to-H advancement flaps (Chapter 5)
Salvatore J. Pacella

Video 6
Closure of large forehead and scalp defect with bilobed flap and scalp advancement (Chapter 5)
Salvatore J. Pacella

Video 7
Reconstruction of Mohs helical rim defect with Antia-Buch flap (Chapter 6)
Salvatore J. Pacella

Video 8
Upper eyelid reconstruction with direct closure and canthotomy (Chapter 7)
Salvatore J. Pacella

Video 9
Repair of upper eyelid Mohs defect with two-stage Cutler-Beard bridge flap (Chapter 7)
Salvatore J. Pacella

Video 10
Anterior lamellar reconstruction with acellular dermal matrix and paramedian forehead flap (Chapter 7)
Salvatore J. Pacella

Video 11
Direct closure of lower eyelid defect (Chapter 8)
Mohammed Alghoul

Video 12
Reconstruction of lower eyelid defect with periosteal flap and Tenzel flap (Chapter 8)
W. Thomas McClellan, Mohammed Alghoul

Video 13
Reconstruction of lower eyelid defect with Hughes flap and Tripier flap (Chapter 8)
Mark A. Codner, Mohammed Alghoul

Video 14
Reconstruction of lower eyelid defect with ear cartilage and myocutaneous flap (Chapter 8)
Mark A. Codner, Mohammed Alghoul

Video 15
Reconstruction of nasal alar defect with full thickness skin graft (Chapter 9)
Mohammed Alghoul

Video 16
External nasal valve reconstruction with ear cartilage graft and nasolabial flap (Chapter 9)
Salvatore J. Pacella

Video 17
Aesthetic reconstruction of Mohs alar defect with multiple, staged flaps and ear cartilage graft (Chapter 9)
Salvatore J. Pacella

Video 18
Reconstruction of lower eyelid and midcheek defect with cervicofacial rotational flap (Chapter 10)
Mohammed Alghoul

Video 19
Reconstruction of lateral cheek defect with rhombic transposition flap (Chapter 11)
Mohammed Alghoul

Video 20
Reconstruction of total lip defect with Karapandzic flaps (Chapter 12)
Mohammed Alghoul

Video 21
Aesthetic scar revision: nasal alar contraction (Chapter 14)
Salvatore J. Pacella

Systems requirements

Operating systems: Mac OS, Windows Vista or later. Recommended web browsers: Google Chrome, Mozilla Firefox. Java and Flash Player plug-ins required.
For use only on personal computer, not on DVD player.

Chapter 3 Aesthetic concepts in facial soft tissue reconstruction

Salvatore J. Pacella, Mark A. Codner

JAYPEE BROTHERS

LEARNING POINTS

- To understand the importance of the initial patient consultation with regard to surgical planning, patient expectation and long term outcome
- To appreciate the midface skeleton in relation to the aesthetics of facial soft tissue
- To understand the effect of facial aging and fat atrophy with planning aesthetic facial reconstruction

INTRODUCTION

In this chapter, we discuss the approach to evaluation and planning soft tissue reconstruction of facial defects. Much like any other surgical problem, a successful outcome relies not only on the execution of a strategic surgical plan, but in patient education and management of patient expectations.

THE PATIENT EXPERIENCE

Although repairing facial defects is, in essence, reconstructive surgery, many lessons can be applied from caring for aesthetic or cosmetic surgery patients. Traditionally in plastic surgery, many successful cosmetic practices which demonstrate patient value are those which pride themselves on a rewarding customer service experience. This is evident from the initial patient phone call to the final outcome of the surgery. In fact, data has indicated that a successful patient experience is often not dictated by a successful surgical outcome, but by a satisfactory experience with communication and service. This experience can be quite different from, for example, a busy university or county hospital experience that may be understaffed or underfunded. The diagnosis of skin cancer can be very frightening for any patient, therefore a patient experience based on attention, communication, guidance and empathy (in addition to a successful surgical outcome) will often be a rewarding one.

When reconstructive surgery is performed on a visible part of the body, patients often see no distinction between 'cosmetic surgery' and 'plastic surgery'. In other words, many skin cancer patients expect a perfect result with minimal-to- no scarring regardless of the size or extent of the defect. While this seems counter-intuitive, it is not without reason. In today's environment of healthcare outcomes transparency and information technology, patient satisfaction can have a significant effect on reimbursement from many health insurers and hospital systems. In addition, a poor patient encounter (which can easily be documented on websites or chatrooms) can have a devastating effect on physician reputation and patient referrals.

A successful patient outcome starts at the initial phone call. In our practices, skin cancer patients are given the highest priority and usually seen within several days. We attempt to work closely with the extirpative or Mohs surgeon to align consultation and coordinated repairs in a convenient and timely fashion. Cooperative, engaging and dedicated patient coordinators (from both physicians) is paramount.

It is our strong feeling that any reconstructive patient should be seen in consultation prior to their Mohs surgery. This allows the patient and surgeon ample opportunity to discuss the clinical problem, the potential defect and the reconstructive plan. While skin cancer is a very common problem, the familiarity of the disease also can result in misinformation and a pre-conceived expectation of treatment or outcomes. Sometimes patient and surgeon expectations are divergent. **Table 3.1** illustrates some common 'disconnects' between patient and

Table 3.1 Common disconnects between patient and surgeon expectation

Patient expectation	Surgeon expectation
The doctor will just 'sew me up'	A successful reconstruction is more complex than just simply closing a defect by its current dimensions
I would like the skin cancer removed but I don't want a scar	Scars are a necessity for any repair; however, appropriate planning can make scars very inconspicuous
The spot on my nose was so small, why is this 'hole' so big?	Non-melanoma skin cancers, particularly aggressive ones, can have microscopic extensions that often travel beyond a visual border
The 'hole' was so small, why is my scar so big?	In order to distribute tension and plan scars in a contoured line, scars may often need to be extended
The Mohs doctor already 'numbed' me. Why do you have to do it again?	Reconstructive flaps often are much larger than the initial defect. Anesthetic can have a very short half-life
Can't you just put me to sleep right now for this?	Patient safety is paramount. General anesthetic requires an anesthetist, which must be planned in advance of the repair
My nose repair was yesterday, my nostril is very distorted	Volume of anesthetic, swelling and skin tension can often distort cartilage. Patience, time, massage and skin care will significantly improve any distortion
It's been several months now and my scar is so red	The natural progression of wound healing dictates the appearance of scars. Scars often fade and usually appear at their best after about a year

surgeon expectation. The preoperative consultation allows the first opportunity to educate, ensures clear communication of expected outcome and provides a chance to assuage patients' potential fears of disfigurement.

The initial consultation provides an opportunity for the surgeon to discuss the details of why Mohs Surgery is necessary and the logistics of how it is performed. In addition, this visit provides a venue to illustrate incision extent and placement, swelling and long term character of scarring in general. Many patients expect an outcome without any perceivable scar. Although this is usually not possible, this consultation provides an opportunity for a clear discussion of how the scar will look weeks, months, and even years after the reconstruction.

Most importantly, the initial consultation provides an opportunity for the reconstructive surgeon to discuss the absolute worst case scenario. For example, Mohs defects on the nasal tip can most often be reconstructed with local or bilobed flaps under local anesthesia. Nonetheless, a predictably small defect may sometimes become a larger wound especially if the Mohs resection involves a perineural, morpheoform or infiltrative basal cell carcinoma. In these larger defects, the patient who may have expected a small flap reconstruction under local anesthesia will often become upset when a multi-staged, forehead flap under general anesthetic is required. In our experience, a patient who is educated on potential scenarios (and subsequently relieved they will require only local anesthesia) is often much more satisfied than a patient who expects only a small defect and is surprised by a larger scar or the need for a general anesthetic.

AESTHETIC CONCEPTS

Facial proportion

It has long been said that 'beauty is in the eye of the beholder'. The aesthetics of facial proportion certainly vary by race, culture and age. Classic observational studies, from the times of the ancient Greeks to modern-day cephalometrics have popularized the standard of the Golden Ratio (phi) of 1:1.618. Commonly held beliefs illustrate that from nature, to architecture, to facial proportion that objects which are rectangular or non-symmetric in appearance will appear 'aesthetically pleasing' if the ratio of the shorter side of the construct is in a 1 : 1.618 proportion to the larger side of the construct. **Figure 3.1** provides an illustration of these concepts in relation to facial beauty and symmetry.

While 'aesthetically pleasing' may represent differing ideals, in general, this proportion can be looked upon as a standard 'rule-of-thumb' in planning cosmetic plastic surgery procedures. On the contrary, when evaluating the reconstructive plastic surgery patient to repair a facial defect, the surgeon must weigh this ideal in relation to overall facial balance and symmetry. Most importantly, the ideal concepts of planning an aesthetic repair involve matching appropriate facial contour, balancing facial symmetry, avoidance of tension and anticipation of long-term cicatricial deformity.

Anatomically, the approach to reconstruction of the face can be aesthetically de-constructed into the following region or zones: The forehead and temporal area, the auricle, the upper eyelid and medial canthus, the lower eyelid and lateral canthus, the nose, the midcheek, the lateral cheek and the lips and mouth, and the auricle (**Figure 3.2**). Whereas the majority of borders between these zones represent a distinct aesthetic unit, the region of the midcheek represents a unique zone. As discussed in Chapter 10, the medial border (between the midcheek and nasal sidewall) as well as the lateral border (between the midcheek and lateral cheek) have relatively indistinct borders. This has significant implications for incisional planning. Whereas most incisions can be planned as a contoured scar at the junction of the two zones (e.g. the border between the midcheek and lower eyelid), the indistinct medial and lateral border of the midcheek most often benefit aesthetically from a blended or 'zig-zag' scar which can prevent dIvoting or scar contracture.

Although all regions are important from an aesthetic standpoint, the area of the eyes and nose represents a focal point in human conversation. The focal point of these regions can be described as the 'golden triangle' of the face (**Figure 3.3**). Because of this focal point, at conversational distance, most people will notice the most miniscule of scars or contour deformity. While careful attention to aesthetic contour and incision placement is important throughout the face, incision design and scar appearance is of critical importance in these central zones.

An overwhelming majority of defects can be consistently reconstructed aesthetically utilizing the concepts as illustrated in the remainder of this textbook. While these anatomic zones are mostly consistent, there are several concepts than can be variable which



Figure 3.1 Golden proportions in facial aesthetics. In general, ideals of facial balance and symmetry can be approximated in faces which have an approximate ratio of phi (1:1.618). (a, b) Examples of 'aesthetic' or 'beautiful' faces. The ratio of balance appears throughout the face. Examples include the ratio of the lower face (i.e. eyes to chin) to the entire face (hairline) and the ratio of the horizontal width of the mouth to the eyes. While these ideals are challenging to obtain, planning an aesthetic facial soft tissue repair involves attempting to approximate balance in facial proportion.

JAYPEE BROTHERS



Figure 3.2 Aesthetic zones for reconstruction of facial defects. The following diagrams illustrate the aesthetic zones for reconstruction of facial defects. These include the forehead and eyebrow region, the upper lid and medial canthus, the lower lid and lateral canthus, the nose, the lips and mouth, the auricle, the lateral cheek and the midcheek. The medial and lateral border of the midcheek represents a fairly indistinct border which has implications for incisional design.



Figure 3.3 The 'golden triangle' of the face. This photograph illustrates the concept of the 'golden triangle'. At standard conversational distance, the primary concentration for focus on a conversant lies in a triangle bordered by the eyes and nose. This concept illustrates that nasal and eyelid scars can be easily noticed as a point of focus. Adjacent areas of scar donor sites for regional flaps such as the forehead or cheek are usually of secondary focus.

can affect the aesthetic result. These are related to aesthetic contour related to underlying variance in midface facial skeletal structure and fat atrophy and facial descent as it relates to facial aging.

Facial skeleton

Soft tissue reconstruction of the face relies on a platform of skeleton in order to provide support for secondary scar healing. As we will further discuss in the upcoming chapters, regions of the face that have thin soft tissue with close bony support (such as the lateral temporal region or chin) tend to have less scar contracture and deformity than those areas of the face that possess skeletal support at a distance (such as the eyelids or lips). For example, incisional placement involving lip tissue is notorious for causing scar hypertrophy. In repose, the lips are positioned anteriorly and in poor proximity to the teeth, maxilla and mandible to provide a substrate to counteract scar contracture. Conversely, anatomic locations such as the nasal root or medial canthus have a very adherent soft tissue structure in relation to bone, which provides a structural 'stretch' to counteract scar contracture.

It is not without surprise that the 'golden triangle' of the face possesses a skeletal structure that can be highly variable. Most specifically, this relates to the aesthetic appearance of the globe in relation to the midface skeleton. Patients who have prominent eyes, by definition, possess a midface skeleton that appears underprojected. Patients with 'high cheekbones' or deep-set eyes, possess a midface structure that is very prominent in relation to eyes (**Figure 3.4**).

This variance in structure has a significant effect on postoperative appearance and scar maturation after soft tissue reconstruction. Patients with prominent midface or zygomaticomaxillary complex structure possess a solid foundation to counteract the effects of scar contracture. In addition, the lateral canthal attachments in these patients (in general) tend to be more adherent. It is our experience that this results in less scarring and a lesser tendency toward secondary lid malposition. In contrast, patients with prominent eyes and a recessed midface skeletal appear to have less support, which can result in deeper scar contracture and a greater tendency toward lower eyelid malposition.

As will be discussed in upcoming chapters, special attention must be paid to evaluation of defects around the periorbital and upper midcheek region. This is particular important in older patients, patients who have had previous eyelid surgery or in patients that have pre-existing weakness in canthal support (**Figure 3.5**). In these scenarios, canthal support maneuvers such as canthopexy, canthoplasty or drill-hole fixation should be liberally employed (by an experienced surgeon) to prevent postoperative lid malposition and/or ectropion.

JAYPEE BROTHERS

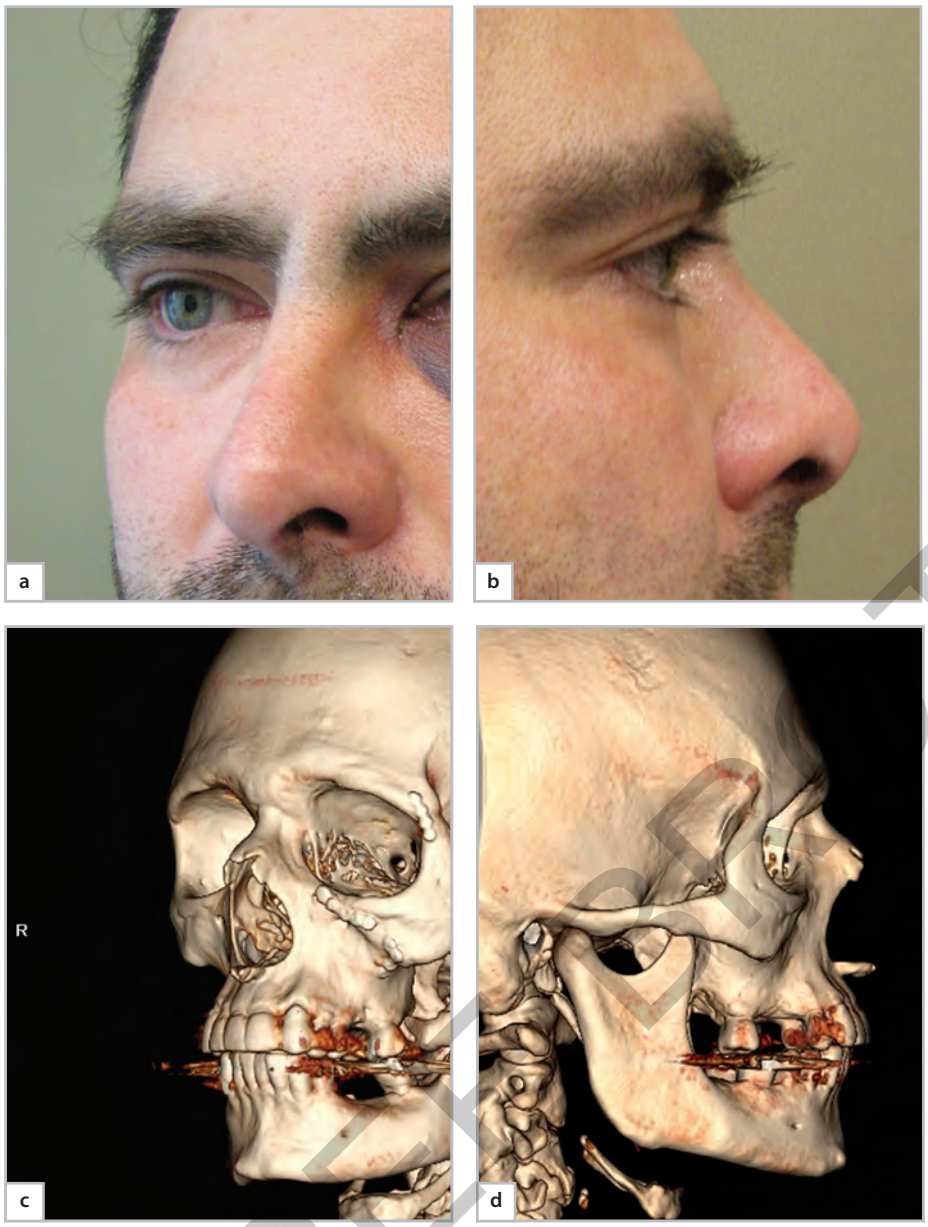

Figure 3.4 *(continues opposite)*

The remainder of the facial skeleton, such as the mandible, frontal and temporal regions, possess very limited variability among patients. In our experience, scar contracture in these anatomic zones does not predictably vary based on skeletal structure.

Facial aging

Traditionally in plastic surgery teaching, surgeons are instructed to attempt to design incisions and repairs with the longest extent of the incision to be situated with Langer's lines or relaxed skin tension lines (RSTLs). This basic teaching is certainly fundamental to planning an aesthetic repair. It is interesting to note that as we age, RSTLs become more distinct and well defined. In fact, these lines are directly complimentary to commonly appearing facial rhtyids (**Figure 3.6**).

As we age, there are predictable changes that occur in facial skin. The dermis thins and the collagen and elastin content reduce. This gives the appearance of skin becoming loose and descending. While this certainly is true, there is a deeper layer of complexity as it relates to facial fat. The anatomic relationship of midface fat in relation to skin is illustrated in **Figure 3.7**.

As we age, natural collections of fat in the face reduce in size and atrophy. This changes the appearance of a youthful face from a round and triangular shape to a rectangular appearance. The most pronounced areas of the face that exhibit atrophy are the mid-cheek region, the temporal region, the lips and the lateral face. By way of illustration, a child's face appears round and full, whereas many elderly patients have an appearance of appearing 'skeletonized' (**Figure 3.8**).

JAYPEE BROTHERS

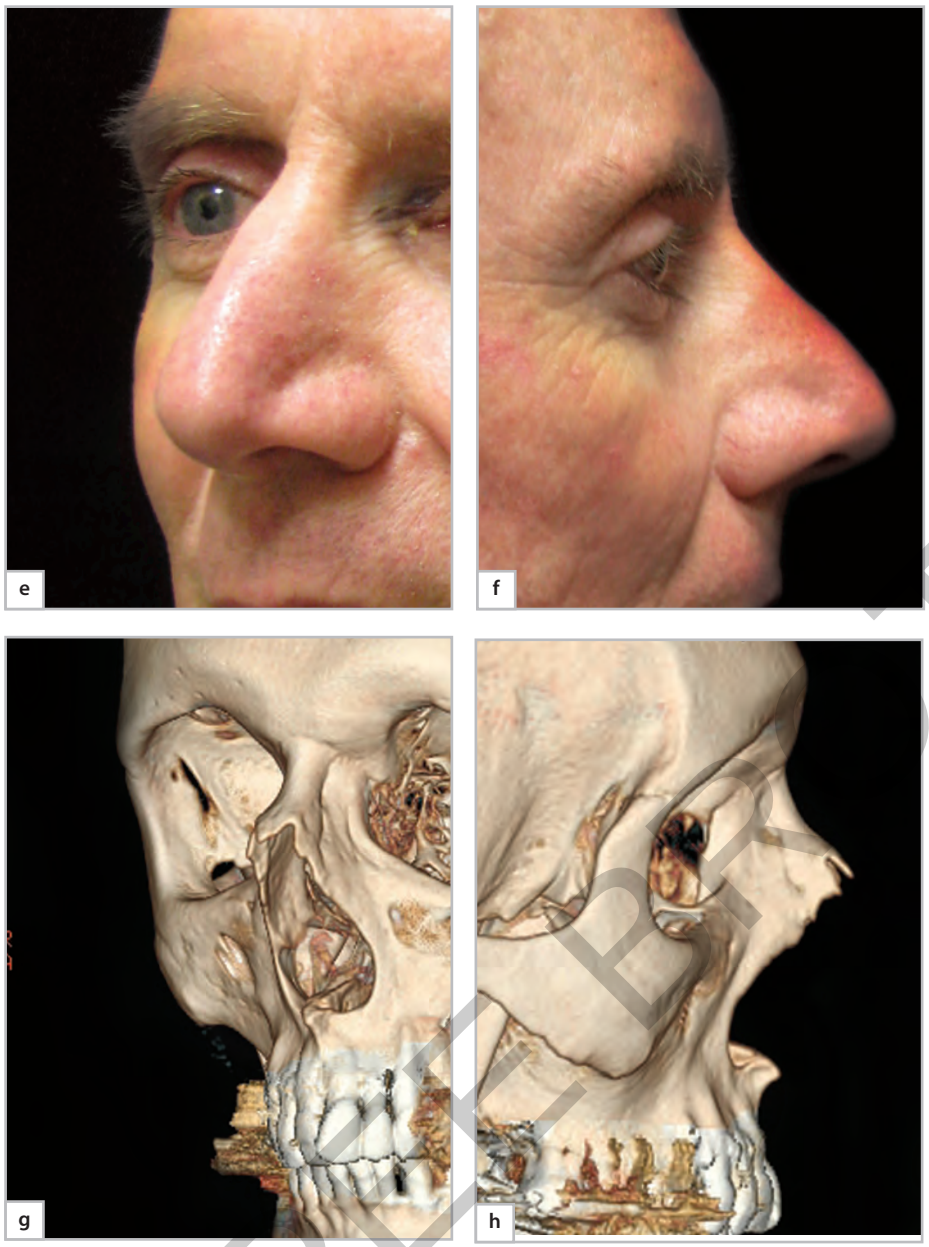

Figure 3.4 *continued.* Facial skeletal structure and globe prominence. The position of the anterior surface of the globe in relation to the zygomaticomaxillary skeleton has important ramifications with relation to the tendency for postoperative midface scarring after facial soft tissue repair. Facial trauma patients are often evaluated with a three-dimensional CT which can provide insightful analysis into the relation of the facial skeleton and soft tissue. Both patients in this example were evaluated for zygomaticomaxillary complex fractures. The preoperative photographs and CT images for the uninjured side are illustrated for this concept. The first two photographs illustrate (a) an oblique and (b) a side view of the uninjured orbit in a patient with deep-set eyes and a projected midface skeleton. (c, d) Corresponding CT images. Patients with these skeletal characteristics have less of a tendency to develop post-operative lid malposition. (e, f) The next patient's preoperative photographs illustrate prominent eyes with a recessed mid-facial skeleton. (g, h) Similar images of the 3D reconstruction illustrate the downward trajectory and sloped appearance of the zygoma/maxilla. Patients with these characteristics have a lack of bony support which can lead to a predisposition toward downward cicatricial contracture and ectropion. In these patients, canthal support should be entertained.

Much like bone, subcutaneous fat provides a substrate in which scars can exhibit contraction. However, unlike bone, which will reinforce an aesthetic scar, subcutaneous fat can actually worsen the appearance of scars by exhibiting contraction deeper into the facial tissue. This can result in perpendicular scar tethering in relation to the skin surface. Excessive contraction can result in a 'pin-cushioning' or 'tethered' appearance of scars (**Figure 3.9**). As we discuss in the upcoming chapters, flaps that are designed over areas of prominent subcutaneous facial fat should be designed wide and broad in an effort to distribute tension both laterally and deep (**Figure 3.10**). In addition, this is even more important in older patients who lack fat projection in the mid-cheek or lateral face.

CONCLUSION

Plastic surgery concepts that are derived from cosmetic/aesthetic surgery have broad application in facial soft tissue reconstruction following Mohs surgery. Reconstruction can effectively be categorized into distinct anatomic subunits of the face. In addition, the relationship of the facial skeleton to soft tissue (particularly in the midface) has significant ramifications for soft tissue contracture. Planning an aesthetic repair with special attention to facial fat is important in creating an aesthetic and contoured repair in facial soft tissue reconstruction.

JAYPEE BROTHERS



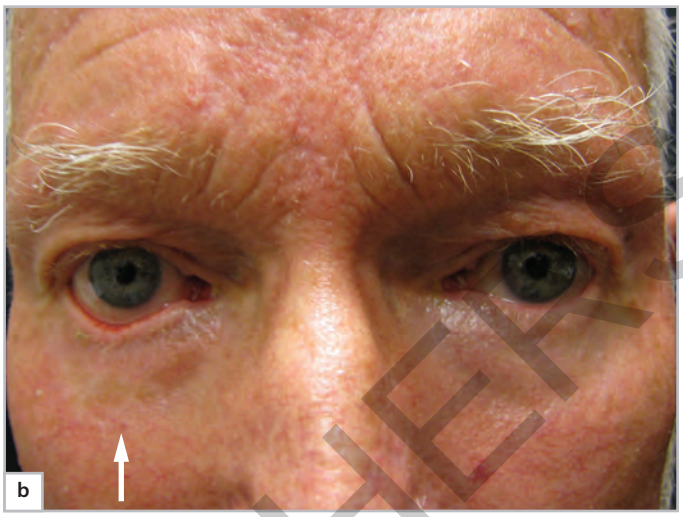

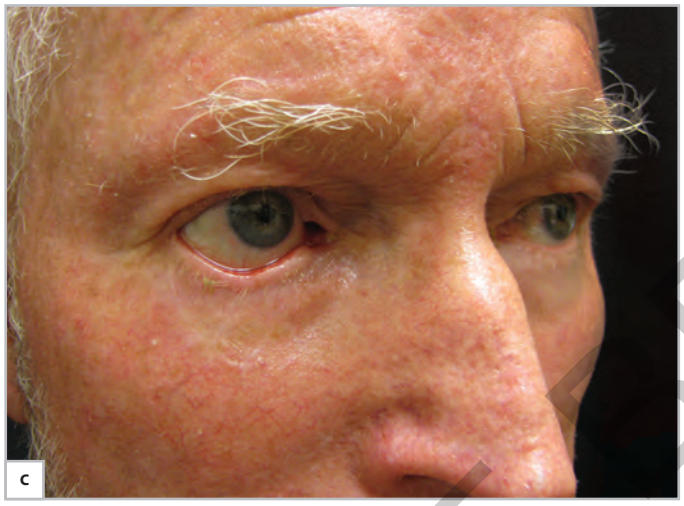

Figure 3.5 Facial aesthetics and loss of canthal support. This 81-year-old patient had a previous repair of his right lower lid-midcheek junction from a basal cell carcinoma excision performed 2 years earlier. (a–c) Secondary scar contracture has left him with right scleral show. Oblique views show that this patient had preexisting loss of canthal support in both lower eyelids. In these scenarios, canthal support should be addressed at the time of the skin cancer reconstruction. In this secondary case, this patient will require canthal support as well as anterior lamellar (i.e. skin) reconstruction.



Figure 3.6 Relaxed skin tension lines. Relaxed skin tension lines (RSTLs) lie complementary to natural age-related facial rhytids. In general, these lines represent aesthetically pleasing locations for scar or incision placement.



Figure 3.7 Fat compartments of the midcheek. Subcutaneous fat in the midface creates the substrate for facial contour. In the youthful face, fat compartments are uniform. There is little transition change or contour separation between fat compartments. In the aging face, laxity of retaining ligaments as well as fat atrophy creates a deflationary effect in the midcheek. When designing flaps for reconstruction, incorporating deep perforators and fat will maintain the position of subcutaneous fat compartments and augment facial contour.

TAYLOR & FRANCIS



Figure 3.8 Facial aging and fat atrophy. The youthful face possesses a significant amount of facial fat that is compartmentalized into the deep layers of facial soft tissue. The aged face experiences significant fat atrophy and a 'skeletonized' appearance. This 2-year-old girl possesses a full face with age-appropriate fat deposition. This results in a blending of the lid–cheek junction, a well-defined upper eyelid crease, a blended eye-shadow space and a contoured philtral complex. In contrast, her 94-year-old great grandmother illustrates significant but age-appropriate fat atrophy in the face. This results in a sharp lid–cheek transition, a poorly defined lid crease, a hollowed out upper orbit (i.e. A-frame deformity), temporal atrophy and lip atrophy. (With special thanks to Ellie and Fiorina Pacella).



Figure 3.9 Facial fat and scar contracture. An abundance of aged, subcutaneous fat can worsen the appearance of scars by exhibiting contraction and tethering of skin deeper into the facial tissue. This is particularly the case in narrow based flaps with circular or oblong shape.



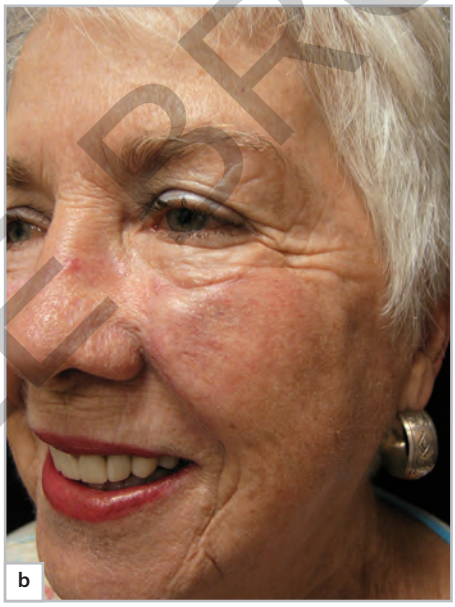



Figure 3.10 *(continues overleaf)*

JAYPEE BROTHERS











Figure 3.10 *continued.* Flap design and facial fat. Preservation of facial contour is best incorporated into repairs by understanding the relationship of facial fat to scarring and contracture. In areas where there is significant facial fat (such as the midface, midcheek or lateral cheek), facial fat should be incorporated into the repair. This is best accomplished by designing a wide and broad-based flap which includes a significant depth of facial fat. (a) In this first example, a midcheek defect is located in an area of the face with significant subcutaneous fat. A triangular advancement flap is designed which incorporates a section of deep facial fat. (b, c) Postoperative result at 1 year illustrates preservation of natural facial contour. (d, e) Similar concepts are illustrated for V-to-Y advancement flaps which utilize an island of subcutaneous fat for flap design. (f–h) Postoperative result at 1 year illustrates similar preservation of natural facial contour both in animation and repose.

JAYPEE BROTHERS

FURTHER READING

Alghoul M, Pacella SJ, McClellan WT, Codner MA. Eyelid reconstruction. Plast Reconstr Surg 2013; 132:288e–302e.

Alghoul M, Codner MA. Retaining ligaments of the face: review of anatomy and clinical applications. Aesthet Surg J 2013; 33:769–782.

Anhang Price R, Elliott MN, Cleary PD, et al. Should health care providers be accountable for patients' care experiences? J Gen Intern Med 2015; 30:253–256.

Barrett TL, Greenway HT Jr, Massullo V, Carlson C. Treatment of basal cell carcinoma and squamous cell carcinoma with perineural invasion. Adv Dermatol 1993; 8:277–304; discussion 305.

Borges AF. Relaxed skin tension lines (RSTL) versus other skin lines. Plast Reconstr Surg 1984; 73:144–150.

Codner MA, Wolfli JN, Anzarut A. Primary transcutaneous lower blepharoplasty with routine lateral canthal support: a comprehensive 10-year review. Plast Reconstr Surg 2008; 121:241–250.

Gillespie PH, Banwell PE, Hormbrey EL, et al. A new model for assessment in plastic surgery: knowledge of relaxed skin tension lines. Br J Plast Surg 2000; 53:243–244.

Hirmand H, Codner MA, McCord CD, et al. Prominent eye: operative management in lower lid and midfacial rejuvenation and the morphologic classification system. Plast Reconstr Surg 2002; 110:620–628; discussion 629–634.

Kook MS, Jung S, Park HJ, et al. A comparison study of different facial soft tissue analysis methods. J Craniomaxillofac Surg 2014; 42:648–656.

Lambros V. Models of facial aging and implications for treatment. Clin Plast Surg 2008; 35:319–327; discussion 317.

Lambros V. Commentary on: The role of gravity in periorbital and midfacial aging. Aesthet Surg J 2014; 34:823–824.

Lee EH, Klassen AF, Lawson JL, et al. Patient experiences and outcomes following facial skin cancer surgery: A qualitative study. Australas J Dermatol 2015; Apr 2. doi: 10.1111/ajd.12323. [Epub ahead of print].

Lee TH. Why patient loyalty matters--and how to enhance it. Healthc Financ Manage 2014; 68:68–72.

Levesque AY, de la Torre JI. Midface anatomy, aging, and aesthetic analysis. Facial Plast Surg Clin North Am 2015; 23:129–136.

Liebregts J, Xi T, Timmermans M, et al. Accuracy of three-dimensional soft tissue simulation in bimaxillary osteotomies. J Craniomaxillofac Surg 2015; 43:329–335.

McCord CD, Ford DT, Hanna K, et al. Lateral canthal anchoring: special situations. Plast Reconstr Surg 2005; 116:1149–1157.

Moul DK, Chern PL, Shumaker PR, et al. Mohs micrographic surgery for eyelid and periorbital skin cancer. Int Ophthalmol Clin 2009; 49:111–127.

Pallett PM, Link S, Lee K. New "golden" ratios for facial beauty. Vision Res 2010; 50:149–154.

Pessa JE, Desvigne LD, Lambros VS, et al. Changes in ocular globe-to-orbital rim position with age: implications for aesthetic blepharoplasty of the lower eyelids. Aesthetic Plast Surg 1999; 23:337–342.

Powers BW, Jain SH. Patient-centered physician selection: a necessary first step for accountable care. Am J Manag Care 2014; 20:E16.

Richter DF, Schwaiger N, Wiedner M. Aesthetic refinements in patients with prominent eyes. Facial Plast Surg 2015; 31:633–644.

Sobanko JF. Optimizing design and execution of linear reconstructions on the face. Dermatol Surg 2015; 41:S216–S228.

Surek CC, Beut J, Stephens R, et al. Pertinent anatomy and analysis for midface volumizing procedures. Plast Reconstr Surg 2015; 135:818e–829e.

Wan D, Amirlak B, Rohrich R, Davis K. The clinical importance of the fat compartments in midfacial aging. Plast Reconstr Surg Glob Open 2014; 1:e92.

Wilhelmi BJ, Blackwell SJ, Phillips LG. Langer's lines: to use or not to use. Plast Reconstr Surg 1999; 104:208–214.

JAYPEE BROTHERS

AESTHETIC FACIAL RECONSTRUCTION AFTER MOHS SURGERY

Mohs surgery is a highly effective treatment for skin cancer which enables precise identification and removal of cancerous tissue. As well as minimizing the loss of healthy tissue, it allows for the same-day repair of the cancer site and the best possible aesthetic and functional results after surgery.

Aesthetic Facial Reconstruction after Mohs Surgery provides authoritative guidance on the repair of soft tissue defects of the face after Mohs surgery. After a brief review of the technique and the histologic variations in different skin cancers, the book describes the reconstructive techniques best suited to each facial region. Examples of commonly seen Mohs defects are illustrated with before and after photographs which demonstrate the beneficial outcomes achieved with the techniques described.

With its emphasis on securing the perfect closure of facial defects, *Aesthetic Facial Reconstruction after Mohs Surgery* is an indispensable resource for all clinicians who use Mohs surgery to treat patients with skin cancer and wish to optimize the aesthetic results.

- **Descriptions of reconstructive procedures** highlight anatomic considerations and the surgical steps required for a successful outcome
- **Unique illustration program** includes clinical photos featuring anatomic overlays to help the surgeon visualize and navigate underlying structures



Accompanying DVD features 21 video clips demonstrating the instruments used in Mohs surgery, suture techniques and key reconstructive procedures

JP medical publishers

www.jpmedpub.com

ISBN 978-1-907816-91-8