

GYNECOLOGIC DERMATOLOGY

SYMPTOMS, SIGNS AND CLINICAL MANAGEMENT

Gudula Kirtschig
Susan M Cooper

Contents

Preface v

Acknowledgements vii

Contributors xiii

SECTION 1: GENERAL CONSIDERATIONS

Chapter 1
Normal vulva 1
Andreas R Günthert

Chapter 2
Normal histology of the vulva and anogenital area 9
Sigrid Regauer

Chapter 3
Vulvovaginal care 13
Jan Brockie

Chapter 4
Taking a vulvar history and examination of the vulva 17
Barbara Eberz

Chapter 5
Scoring and recording of vulvar disease 21
Gudula Kirtschig, Susan M Cooper

Chapter 6
How to take a vulvar biopsy and what to expect from a histopathological examination 29
Barbara Eberz, Sigrid Regauer

SECTION 2: SYMPTOMS AND SIGNS OF DISEASE

Chapter 7
General treatment considerations 33
Susan M Cooper, Gudula Kirtschig

Chapter 8
Pruritus 37
Tanja Gizela Bohl

Chapter 9
Pain 43
Susan M Cooper, Gudula Kirtschig

Chapter 10
Red skin 45
Gudula Kirtschig, Susan M Cooper

Chapter 11
Broken skin 49
Gudula Kirtschig, Susan M Cooper

Chapter 12
White skin 51
Susan M Cooper, Ruth Asher, Gudula Kirtschig

Chapter 13
Pigmented skin 55
Susan M Cooper, Ruth Asher, Gudula Kirtschig

Chapter 14
Scarring 59
Gudula Kirtschig, Susan M Cooper

Chapter 15
Swollen vulva 61
Susan M Cooper, Gudula Kirtschig

SECTION 3: VULVAR DISEASES

Chapter 16
Atopic eczema, lichen simplex, seborrheic dermatitis 63
Karen L Gibbon

Chapter 17
Contact dermatitis (irritant and allergic), fixed drug eruption, and immediate hypersensitivity reactions 73
Martin Zikeli, Sylvie M Franken, Thomas Rustemeyer

Chapter 18
Erythema multiforme majus, Stevens–Johnson syndrome/ toxic epidermal necrolysis, and Graft versus Host Disease 79
Maja Mockenhaupt, Mirjana Ziemer

Chapter 19
Lichen sclerosus 89
Janet McLelland, Susan M Cooper, Gudula Kirtschig

Chapter 20
Lichen planus 97
Gudula Kirtschig, Susan M Cooper

Chapter 21
Plasma cell vulvitis 107
Anne Lise Ording Helgesen

Chapter 22
Vulvar psoriasis 109
Michael Sticherling

Chapter 23
Hidradenitis suppurativa 115
Ditte M Saunte, Gregor B E Jemec

Chapter 24
Granulomatous conditions of the vulva 121
Michael A Hambardzumyan, Ad A van Bodegraven, Tom J Stoof

Chapter 25
Scleroderma, systemic lupus erythematosus, and Sjögren syndrome 129
Christiane Pfeiffer

Chapter 26
Autoimmune bullous diseases 137
Kathy Taghipour, Gudula Kirtschig

Chapter 27
Inherited bullous diseases 149
Kathy Taghipour, Gudula Kirtschig

Chapter 28
Vulvar ulcers 159
Jennifer Anne Yell, Aysha Javed

Chapter 29
Primary bacterial and fungal vulvar and vulvovaginal infections 169
Mariola Pawlaczyk, Michał Pawlaczyk

Chapter 30
Viral diseases 177
Dominique Parent, Fanny Camus

Chapter 31
Sexually transmitted diseases 191
Katherine Brown

Chapter 32
Cysts and diseases of the glands 201
George Meligonis

Chapter 33
Solid benign tumors 211
Iskander H Chaudhry, William James Merchant

Chapter 34
Benign and malignant pigmented lesions of the vulva 217
Sigrid Regauer

Chapter 35
Malignant and premalignant non-pigmented tumors 225
Joanne A de Hullu, Irene A M van der Avoort, Hedwig van de Nieuwenhof

Chapter 36
Extramammary Paget disease of the vulva 233
Laura T H Wang

Chapter 37
Vulvar vascular disease 241
Marianne G R De Maeseneer, Mirte Siemerink

Chapter 38
Vulvodynia 245
David Nunns

Chapter 39
Psychological and sexological aspects 251
Marjo J Ramakers

Chapter 40
Vulvar cosmetic surgery 257
Claudia E Marchitelli

Chapter 41
Vulvar body art 265
Christa De Cuyper

Chapter 42
Vulvar disease in children 273
Ruth Murphy

Index 279

Chapter 2 Normal histology of the vulva and anogenital area

Sigrid Regauer

The complex vulvar anatomy is reflected by the transition of hair-bearing skin in mons pubis and labia majora to glycogenated mucosa of the vestibulum featuring three different types of skin/mucosa and numerous glands. The vulva merges posteriorly with the perianal skin.

Key features of normal vulvar histology

- The vulva is composed of three types of epithelium/mucosa:
  - Hair-bearing skin
  - Non-hairy modified mucosa with cornified squamous epithelium
  - Glycogenated squamous mucosa
- There are three types of specialized glands:
  - Mammary-like glands
  - Skene glands
  - Bartholin glands
- The transition of modified to glycogenated mucosa is recognized as Hart line
- Melanocytes are evenly distributed within basal keratinocytes
- Subepithelial tissue (dermis) shows dense vascularization and sensory innervation

THE VULVA IN POSTPUBERTAL AND PREMENOPAUSAL WOMEN

Hair-bearing skin of mons pubis, labia majora (Table 2.1)

Hair-bearing skin consists of epidermis, the delicate papillary and collagen rich reticular dermis, and subcutaneous adipose tissue (**Figures 2.1a** and **2.2**). Epidermis and papillary dermis are connected by interdigitating epithelial and dermal ridges, which are separated by the basement membrane zone (junction zone). The epidermis is divided into basal and suprabasal keratinocyte layers (1), a continuous uniform granular cell layer (2), and a basket weave-stratum corneum (3) without nuclei (**Figure 2.1b**). A compact stratum corneum, retention of nuclei (parakeratosis), and discontinuous, wedge shaped or absent granular layer are features of various diseases.

Pubic/genital hair is thicker and longer than in an extragenital location. The superficial infundibular portion of the hair shaft within the epidermis contains a stem-cell population believed to be the origin of trichoepithelial tumors, basal cell carcinomas, and extramammary Paget disease. The isthmic portion is located within the dermis. Hair bulbs/roots extend into subcutaneous adipose tissue at a depth of 4–5 mm, an important distance for treatment decisions (e.g. laser versus surgical excision) when malignant disease extends along hair appendages [e.g. high-grade squamous intraepithelial lesions (HSIL) of the vulva and differentiated vulvar intraepithelial neoplasia (dVIN) in the infundibular portions] extramammary Paget cells can be found within the hair bulb (Regauer 2006). Sebaceous glands are located in the superficial reticular dermis, the secretory portions of eccrine and apocrine sweat glands in the deep reticular dermis. Apocrine and sebaceous glands terminate in the infundibulum of the hair shaft draining their secretions into the follicular lumen. Apocrine glands are lined by tall columnar cells with dense cytoplasm and luminal apocrine snouts resting on basal myoepithelial cells. Eccrine glands are lined by cuboidal cells sitting on a prominent basement membrane and terminate directly in the epidermis independently of hair shafts. A superficial and deep vascular plexus of blood vessels and lymphatic vessels supplies the dermis and adipose tissue, while the epidermis is devoid of blood and lymphatic vessels and supplied by diffusion. Androgen receptors are seen in epidermal keratinocytes, sebaceous glands, sweat glands, hair follicles, and dermal fibroblasts of vulvar skin, but no progesterone receptors are present. Estrogen receptors are restricted to basal keratinocytes (Hodgins et al. 1998) (**Table 2.2**).

'Modified mucosa' of interlabial sulci, labia minora, clitoris, clitoral prepuce

Modified mucosa lacks hair and is covered by a cornified squamous epithelium. It contains sebaceous glands that extend about 2 mm into the subepithelial tissue (**Figure 2.1c**). The density and amount of sebaceous glands vary considerably among individuals.

Table 2.1 Histological features of three types of skin/mucosa found at the anogenital site

	Hair-bearing skin	Modified mucosa	Glycogenated squamous mucosa
Location	Mons pubis and labia majora	Inner side of labia majora, interlabial sulci, outer side labia minora, clitoral hood, perineum	Vestibulum, including periclitoral and periurethral mucosa, introitus vaginae, and vagina
Stratum corneum	Present	Present	Absent
Granular cell layer	Present	Present	Absent
Skin appendages	Hair and adnexal structures	No hair, but sebaceous glands and specialized glands	Absent

JAYPEE BROTHERS

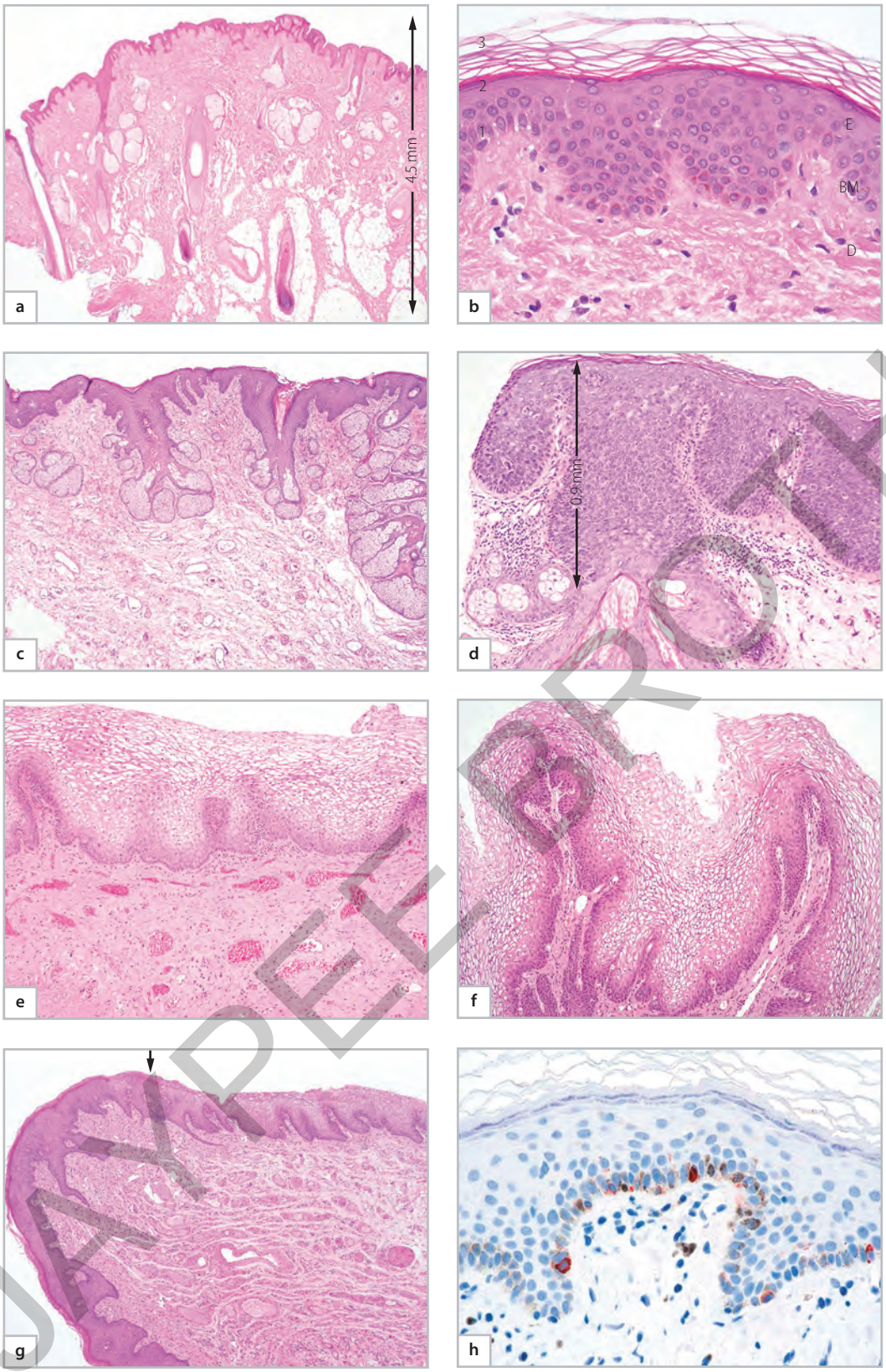

Figure 2.1 Histology of 'normal' vulva. (a) Hair-bearing skin with extension of hair bulb in subcutaneous fat at a distance of 4.5 mm. (b) The epidermis (E) is connected with the dermis (D) via the basement membrane (BM; barely visible in hematoxylin and eosin stain) and consists of a basal keratinocyte layer (1) resting on the BM and a suprabasal cell layer (synonym: spinous cell layer), a granular cell layer (2) and basket weave stratum corneum (3). (c) Modified mucosa with cornified squamous epithelium with sebaceous glands terminating directly in the epidermis. (d) Human papillomavirus (HPV)-induced high-grade squamous intraepithelial lesion) involving the infundibulum of a sebaceous gland with a vertical extension of almost 1 mm. (e) Stratified glycogenated mucosa of vestibulum devoid of skin appendages. (f) Vestibular papillomatosis. Note regular glycogenated epithelium without HPV-associated cell changes. (g) Cross section through the tip of a labium minus with the transition of cornified modified mucosa to glycogenated mucosa (arrow; Hart line). (h) Regular distribution of melanocytes (in red, immunohistochemistry with antibody to Mel-A) within basal keratinocyte layer.

They may be clinically recognized as yellow nodules or cysts with punctate openings (Fordyce spots). The infundibulum of sebaceous glands can be involved by HSIL (**Figure 2.1d**). The dermis is thinner, more delicate, and less collagenous than that of hair-bearing skin and contains numerous smooth muscle fibers, in particular in the labia minora. Subcutaneous adipose tissue is absent or scant. The vascular supply of the labia minora as part of the erectile tissues is more prominent than in hair-bearing skin and characterized by

JAYPEE BROTHERS

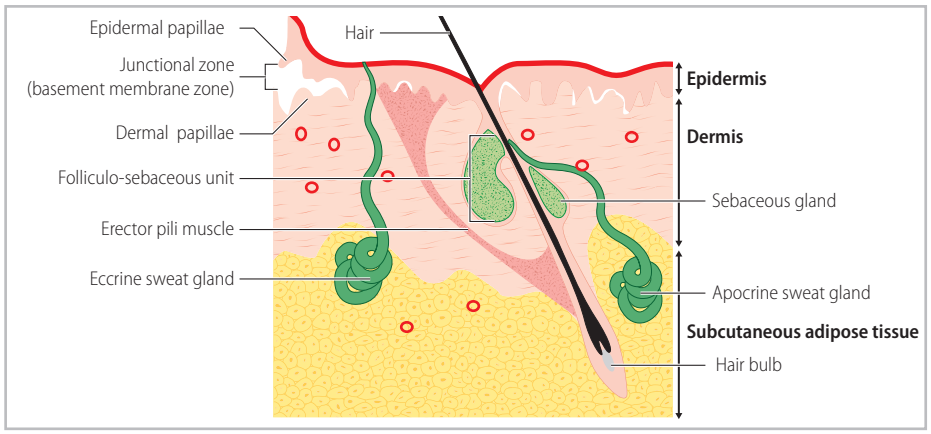

Figure 2.2 Sketch of normal skin showing the three layers of the skin with its appendages.

Table 2.2 Hormone receptors in vulvar epithelium

Receptor	Hair-bearing skin of labia majora	Modified mucosa of labia minora	Glycogenated mucosa of vestibulum
Estrogen	(+)	+	+++
Androgen	++	++	-

numerous thin, wide vascular channels, and thin-walled venous blood vessels. The erectile tissue of clitoris is composed of corpus cavernosum and spongiosum similar to that of penis with large irregular-shaped endothelial lined venous sinuses with longitudinal smooth muscle layers. Modified mucosa of the perineum and anoderm occasionally contains thin small hair. Hormone receptors for estrogens and androgens can be found. Androgen receptor expression is lower in modified mucosa of labia minora. Estrogen receptors are present in basal and suprabasal keratinocytes of the labia minora. Progesterone receptors are not present.

Glycogenated squamous mucosa of vestibulum including periurethral mucosa and introitus vagina

Glycogenated squamous mucosa is devoid of skin appendages and thin (**Figure 2.1e**), although it can assume a papillary configuration around the hymen (so-called vestibular papillomatosis) (**Figure 2.1f**), which is clinically often confused with human papillomavirus-induced condylomata. Glycogen content and epithelial thickness depend on estrogenization, e.g. receptors of estrogen α and β, but not of progesterone and androgen are expressed on basal and suprabasal keratinocytes. The highly vascularized subepithelial tissue lacks separation in papillary and reticular dermis and contains numerous smooth muscle fibers. The transition of modified to glycogenated mucosa (**Figure 2.1g**) is clinically often recognized as Hart line. The urethra is lined by urothelium, and the urethral orifice is covered by squamous epithelium.

Specialized vestibular glands

Glandular structures in the vulva are numerous. Mammary-like anogenital glands are found mainly in the interlabial sulcus between labium majus and labium minus (van der Putte 1994). They resemble mammary glands with tall columnar epithelium resting on a myoepithelial cell layer and express estrogen and progesterone receptors. They give rise to adenomas, hidradenoma papilliferum, adenocarcinomas, and the rare vulvar phyllodes tumors or invasive adenocarcinomas with overlying Paget disease (Kazakov et al. 2012). The small (about 1 mm) paired periurethral Skene glands resemble prostatic glands, express prostatic specific antigen, and are the origin of the extremely rare adenocarcinoma of Skene glands (Crum et al. 2014). The paired Bartholin glands (about 1 cm) in the deep posterolateral vestibule reveal tall columnar epithelium. The ductal portions with orifices lateral to the hymen show transitional epithelium. Minor vestibular glands in the posterior vestibulum are shallow tubular invaginations lined by tall columnar mucinous epithelium.

Normal pigmentation

Vulvar pigmentation shows wide constitutional (racial and genetic) variations. Melanocytes are of neuroectodermal origin and migrate from the neural crest into the respective organs, e.g. to vulvar skin. Melanocytes are regularly distributed among the basal keratinocytes, and their density is slightly higher in vulvar skin than in extragenital skin (1 melanocyte/15–25 keratinocytes, **Figure 2.1h**). Pigmentation depends on the type of melanin pigment (dark eumelanin, reddish pheomelanin) and melanosome maturation. Based on enzymatic activity and pigment content, melanosomes can be divided into stage I melanosomes (immature, no melanin granules) typical for mucosal sites to stage IV melanosomes (mature and pigmented) in skin and modified mucosa. Melanocytes transfer melanosomes via dendrites to adjacent basal keratinocytes in Caucasian or all keratinocytes layers in dark-skinned individuals.

Innervation

There is a network of myelinated and unmyelinated nerve fibers in the subepithelial tissues of hair-bearing skin and modified mucosa. Demonstration of sensory innervation is not possible on hematoxylin and eosin-stained sections but requires immunohistochemical staining with antibody to PGP9.5 (please note: S-100 antibody does not recognize sensory nerves). Various types of mechanoreceptors are identified in vulvar skin. Merkel cells are particularly common in modified mucosa of labia minora and the periclitoral mucosa. They are located either within the basal keratinocyte layer and/or immediately below the basement membrane. Meissner bodies are frequently found in hair-bearing skin and modified mucosa. Pacinian corpuscles are frequent near the clitoris.

JAYPEE BROTHERS

Inflammatory infiltrate

As vulvar mucosal surfaces are constantly challenged by exogenous and endogenous antigens under physiologic conditions, small numbers of circulating lymphocytes, but no plasma cells, eosinophilic and neutrophilic granulocytes, or macrophages, are considered normal. Other cells involved in physiologic immune responses are submucosal mast cells and intraepithelial Langerhans cells, both of which require special stains for visualization.

THE VULVA IN PREPUBERTAL GIRLS AND POSTMENOPAUSAL WOMEN

In prepubertal girls, the major differences are observed in skin of mons pubis, labia majora, and perineum. They appear hairless, but histologically minute hair bulbs can be identified. Although the presence and distribution of hormone receptors show no difference in prepubertal girls and pre- and postmenopausal women, hormone-dependent growth of hair and increase of adipose tissue in children has not commenced. Sebaceous and apocrine glands are minute and 'atrophic' without secretion, and the amount of adipose tissue is scant. After menopause, atrophy as a result of lower levels of estrogen can be identified as thinner epithelium and decreased glycogen content and mildly atrophic sebaceous glands. In severe atrophy, degenerative atypia may be significant and raise the histological differential diagnosis of dysplasia. All other postmenopausal changes have no histological correlate.

REFERENCES

Crum C, Herrington S, McCluggage WG, Regauer S, Wilkinson E. Tumours of the vulva. Epithelial tumours. In: Kurman RJ, Carcangiu ML, Herrington CS, Young RH (eds), World Health Organisation classification of tumours of the female genital tract. Lyon: IARC, 2014:232–242.

Hodgins MB, Spike RC, Mackie RM, MacLean AB. An immunohistochemical study of androgen, oestrogen and progesterone receptors in the vulva and vagina. Br J Obstet Gynaecol 1998; 105:216–222.

Kazakov DV, Spagnolo DV, Kacerovska D, Michal M. Lesions of anogenital mammary-like glands: an update. Adv Anat Pathol 2012; 18:1–28.

Regauer S. Extramammary Paget's disease—a proliferation of adnexal origin? Histopathology 2006; 48:723–729.

van der Putte SC. Mammary-like glands of the vulva and their disorders. Int J Gynecol Pathol 1994; 13:150–160.

JAYPEE BROTHERS

GYNECOLOGIC DERMATOLOGY

SYMPTOMS, SIGNS AND CLINICAL MANAGEMENT

Gynecologic Dermatology: Symptoms, Signs and Clinical Management is a clinically oriented resource for both specialist and non-specialist clinicians who manage patients with vulvar disorders. The book is designed to meet the needs of front line primary care providers, as well as the more in-depth information requirements of specialists working in dermatology, gynecology and sexual health disciplines.

Section one covers normal anatomy and the approach to history taking, clinical examination and biopsy taking. In section two, chapters describe the signs and symptoms of vulvar disease, using numerous tables and photographs to help the physician work through the diagnostic process. Section three includes chapters devoted to all of the key vulvar diseases, describing in detail the pathogenesis, clinical presentation, differential diagnosis and management of each individual condition.

With contributions from a team of international experts, *Gynecologic Dermatology: Symptoms, Signs and Clinical Management* is a practical, accessible guide that summarizes latest best practice and helps dermatologists, gynecologists and sexual healthcare providers devise the most effective treatment plans for their patients.

- Clinically oriented approach provides sufficient depth for specialists while maintaining accessibility to generalists and other healthcare professionals
- Lavishly illustrated format, with nearly 400 clinical photographs, depicts the signs and symptoms of vulvar disease
- Multidisciplinary, international editor and author team offers expert advice from all participating disciplines

JP medical publishers

www.jpmedpub.com

ISBN 978-1-909836-01-3

9 781909 836013