



MANAGEMENT OF THE DIFFICULT AIRWAY: A HANDBOOK FOR SURGEONS

Jerome Thompson
Francisco Vieira
Michael Rutter

JP

Contents

Preface v
Contributors viii

Chapter 1	**A brief history of airway management** *Jerome W Thompson, Francisco Vieira*	**1**
Chapter 2	**Surgical anatomy of the airway** *Jerome W Thompson, Karuna Dewan*	**5**
Chapter 3	**Imaging the airway** *Sridhar Shankar, R Ian Gray*	**21**
Chapter 4	**Anesthesia and management of the difficult airway** *Howard R Bromley, Kerry C Snyder, Adryan Emion*	**31**
Chapter 5	**Indications and techniques for airway intervention and management** *Francisco Vieira, Joshua W Wood*	**43**
Chapter 6	**Surgical management of the airway in the emergency department** *R Mario Vera, Martin A Croce*	**53**
Chapter 7	**Equipment** *Jerome W Thompson*	**63**
Chapter 8	**Pediatric airway management part 1: overview and congenital anomalies** *Jennifer McLevy, Jerome W Thompson, Rose Mary S Stocks*	**71**
Chapter 9	**Pediatric airway management part 2: management of airway emergencies** *Jerome W Thompson, Rose Mary Stocks, Jennifer McLevy*	**87**
Chapter 10	**The EXIT procedure** *Rose Mary Stocks, Jonathan P Giurintano*	**105**
Chapter 11	**Reconstruction of the airway** *Catherine K Hart, Christina J Yang, Michael J Rutter*	**113**
Chapter 12	**Balloon dilation of the airway** *Karthik Balakrishnan, Michael J Rutter*	**123**

Chapter 13 **Surgical management of the oncologic airway** **135**
Sandeep Samant, Jonathan P Giurintano

Chapter 14 **Difficult airway management in the complex patient** **143**
Francisco Vieira, Jared J Tompkins

Chapter 15 **Surgical management of the airway in the intensive care unit** **157**
Amado X Freire, Kathleen Ransom, Luis C Murillo

Index **167**

4 Anesthesia and management of the difficult airway

Howard R Bromley, Kerry C Snyder, Adryan Emion

Introduction

The failure to properly manage the serious challenge of the difficult airway can result in a chaotic situation unrivaled by few other clinical events.

The difficult airway can be defined several ways, with definitions including the level of experience of the medical personnel, repeated attempts at intubation, and whether a bougie or other intubation aid was used. Perhaps one of the most widely used classifications is by Cormack and Lehane (Cormack & Lehane 1984), which describes the best view of the larynx seen at laryngoscopy when there is visibility (**Figure 4.1**). Unfortunately, Cormack and Lehane's classification is of no use in situations where the larynx cannot be visualized, and it is not useful to predict a difficult intubation. It is used to record the visibility of the patient's airway for future reference.

Simply put, the difficult airway is defined as a clinical situation in which a caregiver experiences difficulty with mask ventilation, difficulty with tracheal intubation, or both (Caplan et al. 1993).

The overall incidence of encountering a difficult airway is estimated to be <10% of all cases of airway management (Crosby et al. 1998). However, it is apparent that the lack of planning for the possibility of

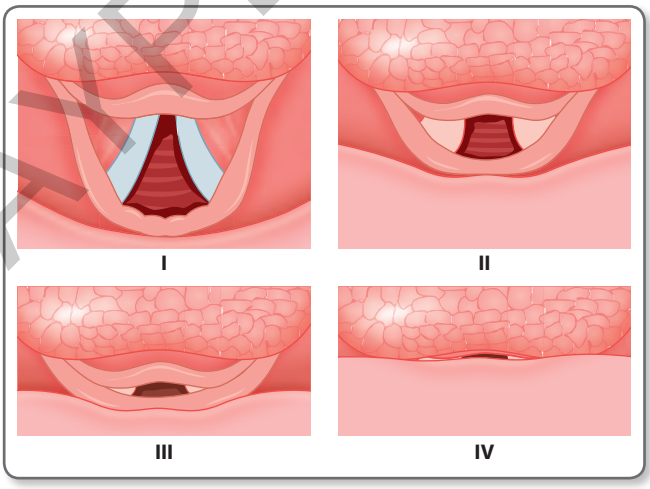

Figure 4.1 Cormack and Lehane's classification of laryngoscopy views. Class I: the vocal cords are visible; class II: the vocals cords are only partly visible; class III: only the epiglottis is seen; class IV: the epiglottis cannot be seen.

JAYPEE BROTHERS

entering a difficult airway scenario is most often the cause of poor clinical outcomes (Roberts 1995). Unfortunately, there exists no single ideal or precise method of evaluating the airway prior to intubation.

The consequences of failure to intubate or secure an airway have been associated with serious complications such as hypoxemia, hypercapnia, resultant metabolic alterations, neurological sequelae including anoxia, and death.

Airway assessment

Any abnormalities of the bony structures of the jaw and/or face, and the soft tissues of the upper airway, can result in a difficult airway scenario. If you can predict a difficult airway, then you can properly prepare yourself for what may occur.

A thorough history and examination is paramount in discovering a difficult airway. Some obvious clinical situations that are likely to present as a difficult intubation include:

- Pregnant women and morbidly obese people (due to redundant tissue)
- Facial and/or maxillary/mandibular trauma
- Small mandibles, as there is decreased space for the tongue
- Intraoral pathology such as infections or tumors
- Inability to open the mouth
- Small mouth
- Poor teeth

Craniocervical movement

Patients who suffer from rheumatoid disease of the neck or degenerative spinal diseases such as ankylosing spondylitis will often have markedly reduced neck mobility. The inability of patients to fully extend their neck decreases their capability to obtain the classic 'sniffing the morning air' position and thus results in misalignment of the laryngeal and pharyngeal axes (**Figure 4.2**).

When properly positioned, all axes are aligned (**Figure 4.3**). To minimize excessive neck movement during intubation attempts, ask someone to hold the patient's head steady and provide inline stabilization while also delivering an upward bilateral jaw thrust.

A patient's history of prior successful or unsuccessful intubations is a significant predictor, but age may change this. There a number of specific clinical assessments that have been developed to try to identify patients who may prove to be difficult to intubate.

Mallampati suggested a simple screening test that is widely used today in a modified form (Samsoon & Young 1987). The patient sits or stands in front of the examiner and opens his or her mouth as widely as possible. The patient's airway is assigned a grade according to the best view obtained (see Figure 2.10). This test should not be performed with the patient supine, as gravity will force the tongue posteriorly, resulting in an inaccurate score.

JAYPEE BROTHERS

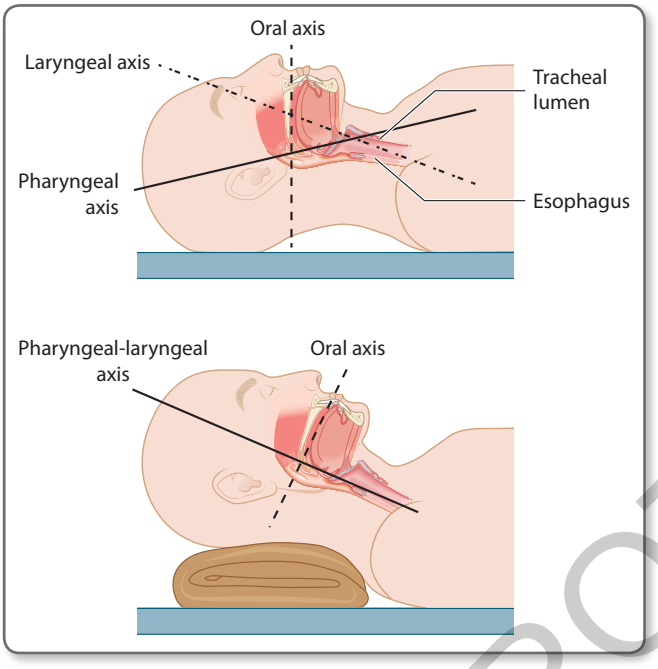

Figure 4.2 Alignment of airway axes. (a) Patient supine; all axes unaligned. (b) Neck forward, partially extended; pharyngeal and laryngeal axes aligned.

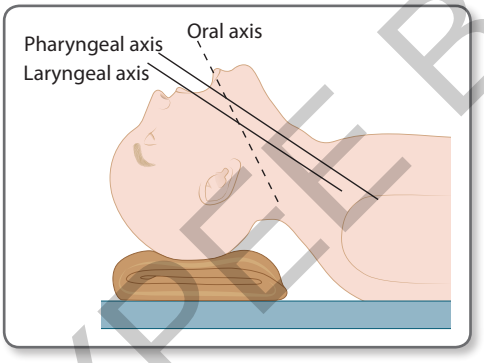

Figure 4.3 Proper alignment of airway axes to view vocal cords.

The Mallampati test is scored as follows:

1. Faucial pillars, soft palate, and uvula easily visualized
2. Faucial pillars and soft palate visualized, but the uvula is masked by the base of the tongue
3. Only the soft palate is visualized
4. Soft palate is not seen and is obscured by the tongue

Clinically, grade 1 usually means that the patient will be easy to intubate, and grade 3 or 4 suggests a high chance that the patient will prove difficult to intubate. The results of the Mallampati test are influenced by patient position, mouth opening, tongue size and mobility, and movement at the craniocervical junction.

JAYPEE BROTHERS

Thyromental distance

This is the measurement taken from the thyroid cartilage notch to the tip of the mandible with the head slightly extended. If the distance is >6.5 cm, conventional intubation is usually possible. If it is <6 cm, intubation may be difficult (Patil et al. 1983). Freck showed that by combining the modified Mallampati score and thyromental distance, patients who fulfilled the criteria of a grade 3 or 4 on the Mallampati score and who also had a thyromental distance of <7 cm were likely to present difficulty with intubation (Freck 1991).

Prognostication

Protrusion of the mandible (prognostication) is an indication of the mobility of the mandible. If the patient is able to protrude the lower teeth beyond the upper incisors and bite the upper lip, intubation is predictably easy (Calder et al. 1995). If the patient cannot prognosticate, intubation is likely to be difficult.

Mandibular space

In the supine position during laryngoscopy, the patient's tongue is lifted up into the mandibular space. If the patient's tongue is too big, or the mandibular space is too small, then either issue or both will lead to the tongue intruding into the oral space and likely obscuring the laryngoscopist's view.

A combination of tests is better than using only one. The modified Mallampati score, thyromental distance, ability to protrude the mandible, mandibular space, and craniocervical movement are the most reliable indicators.

ASA difficult airway algorithm

The American Society of Anesthesiologists (ASA) has developed an algorithm (**Figure 4.4**) for handling difficult airways. It is composed of two basic limbs: one dealing with the recognized or anticipated difficult airway and the other addressing the unrecognized condition. Any practitioner who is routinely confronted with intubating a patient should be familiar with this algorithm.

Approach to management

Practitioners must become proficient with a variety of airway alternatives in a nonemergent environment conducive to learning and practicing their skills. Practitioners must be able to work within a respectful team dynamic, manage a critical situation, and make decisions while moving through a predetermined difficult airway plan. The ultimate management goal is to safely secure the airway while maintaining oxygenation. Plans must include alternatives for management of the predicted difficult airway as well as the 'can't intubate, can't ventilate' scenario. Kits that are portable, comprehensive, and well-maintained

JAYPEE BROTHERS

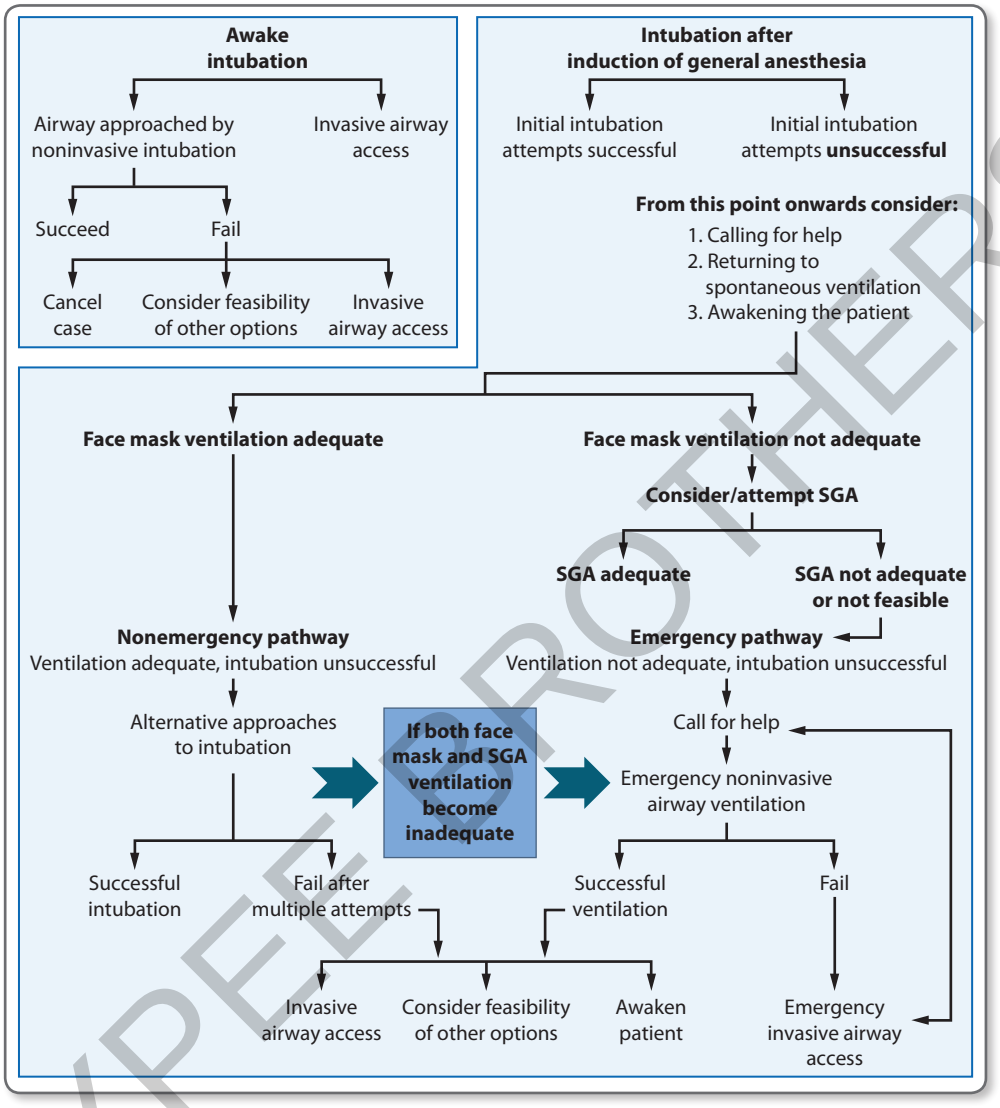

Figure 4.4 American Society of Anesthesiologists difficult airway algorithm. SGA, supraglottic airway (e.g. a laryngeal mask airway). With permission from: Apfelbaum JL, Hagberg CA, Caplan RA, et al. Practice Guidelines for Management of the Difficult Airway: An updated report by the American Society of Anesthesiologists Task Force on management of the difficult airway. Anesthesiology 2013; 118:251–270.

provide practitioners with multiple alternatives. These should include but not be limited to suction, oxygen delivery devices, bag-valve-mask ventilation devices, oral and nasal airways, multiple sized laryngoscopes, endotracheal tubes (ETT), airway exchange catheters, bougies, carbon dioxide detectors, a fiberoptic/video laryngoscope, rescue airways, and surgical airway supplies. Selection of a limited number of these airway devices allows practitioners to become proficient with their use and placement.

JAYPEE BROTHERS

Since the assessment of the airway may be abbreviated due to circumstances, a prior intubation history can be valuable if attainable. If it is determined that an airway may be difficult to intubate, consideration should be given to performing an awake intubation if not contraindicated. If time allows, the patient should be prepared psychologically and pharmacologically for an awake intervention (Rumkumar 2011). Prior to induction and intubation, patients should be preoxygenated for 3 minutes if possible to increase the blood oxygen saturation and delay significant drops in saturation during intubation (Mort 2004). Alternately, preoxygenation with four maximal breaths in 30 seconds will provide similar starting oxygen saturation levels, but desaturation may occur more quickly (Apfelbaum et al. 2013).

Medical contraindications, allergies, volume status, comorbidities, and overall condition should contribute to the selection of induction agents. Induction agents should be sufficient to provide optimal intubating conditions, because the incidence of airway-related complications increases with subsequent attempts (Mort 2004). The decision to move forward to alternative interventions should be made early when conventional efforts at laryngoscopy fail.

Patients should be monitored during intubation efforts including pulse oximetry. Oxygen saturation should be monitored closely with predetermined cutoff points to stop and ventilate/oxygenate. When oxygen saturation drops to 90%, the descent after that point is often rapid and recovery may be delayed, even with positive pressure ventilation (Mort 2004).

When a particularly ominous airway situation presents itself, it is prudent to consider a surgical airway intervention. Decisions are based on patient condition, airway assessment, and ease of surgical airway placement. The option may be to attempt an awake or asleep 'look' or to proceed directly with a surgical airway.

Nonsurgical cricothyrotomy may be attempted by needle cricothyrotomy utilizing an intravenous catheter, but this technique has a high failure and complication rate (Mort 2007). The percutaneous placement of a wide-bore cannula through the cricothyroid membrane utilizing the Seldinger technique may offer a method with a higher comfort level for nonsurgical providers (Mort 2007).

Anesthetizing the airway and techniques

It is imperative that the patient is cooperative and ventilation is maintained throughout the process to prevent a difficult situation from evolving into a dangerous one. The airway should ideally be free of any fluids including blood and saliva that would impair visualization of the airway, and adequately topically anesthetized in awake patients. There are many different methods of topically anesthetizing the airway, and techniques will vary among individuals according to experience and personal beliefs about efficacy.

JAYPEE BROTHERS

Agents and techniques

Glycopyrolate (0.2–0.4 mg intravenous) is an antimuscarinic agent with potent antisialagogue activity, allowing the local anesthetic agents more contact time with the oral mucosa. Glycopyrrolate should be administered 20–30 minutes before topical anesthetics so that salivary function is adequately impaired (Pai et al. 2001). Once the airway is topically anesthetized, the practitioner should ideally perform the airway management before the effects of the local anesthetics diminish.

Lidocaine 5% ointment may be applied to the distal third of a tongue blade and placed as far back in the patient's mouth as tolerable so that the lidocaine contacts the posterior tongue. The patient then clenches his teeth on the tongue blade to hold it in place. Through a combination of melting, gravity, and swallowing, the ointment will be distributed in the posterior pharynx in approximately 10 minutes. Lidocaine 2% liquid or viscous may be swished and gargled by the patient and then swallowed.

Nebulized lidocaine may be used to prepare the airway for manipulation with 5 mL of 4% lidocaine via facemask or mouthpiece. Benzocaine spray may also be used in small amounts to anesthetize the oral mucosa, but it must be used sparingly as its use is limited due to possible methemoglobinemia (Taleb et al. 2013). If nebulization is not performed, it may be desirable to perform a transtracheal block using 3–4 mL of 4% lidocaine administered through the cricothyroid membrane to help prevent coughing and vocal cord spasm during the intubation of awake patients.

Both the nasopharynx and the oropharynx should be topically prepared for a nasotracheal approach. Bleeding is a common concern: to reduce the risk of bleeding, a topical atomized vasoconstrictor such as oxymetazolone should be administered to both nares, so that the contralateral side may be utilized if necessary. Prewarming of the ETT may reduce bleeding and damage in the nasopharynx (Yong et al. 2000). Lidocaine gel 2% or ointment 5% can be applied to the nasal mucosa several minutes prior to intubation to increase the patient's comfort.

The 'awake look'

If the practitioner suspects that there may be a chance that a traditional laryngoscopy might be successful, a technique called the 'awake look' may be utilized for assessment of the airway. Since direct laryngoscopy may activate the gag reflex and cause a hemodynamic response, the patient's oropharynx should be topically anesthetized. The 'awake look' consists of a gentle, brief laryngoscopy to assess which airway structures may be viewed. The BURP (backward upward rightward pressure) technique (Knill 1993) may be used to move the thyroid cartilage posterior, cephalad, and toward the patient's right side. This technique may be useful to reposition the anterior glottis into view during awake or asleep laryngoscopy.

JAYPEE BROTHERS

Blind nasal intubation

Useful in awake or sedated spontaneously breathing patients, blind nasal intubations don't require additional equipment other than an ETT. The ETT should be introduced into a nare and slowly advanced until fogging is seen and breath sounds are heard in the tube, indicating that the tip is very near the glottic opening. Timed with inspiration, the ETT is quickly advanced. If in the trachea, this will almost always result in significant coughing and obvious air movement through the ETT. If there is inadvertent esophageal placement indicated by a lack of breath impulses, the tube may be withdrawn until the breath sounds are just reacquired, and the method repeated.

Video laryngoscope and fiberoptic bronchoscope

The video laryngoscope has evolved into an extremely valuable tool in the management of difficult airways. With the camera positioned at the distal tip of the blade, the anterior glottis is easily visualized without the need to align the laryngeal and oral axes. Flexible fiberoptic bronchoscopes (FOB) may be used for both oral and nasal approaches to the difficult airway. A standard ETT may be preloaded onto the FOB. Upon advancement of the FOB past the vocal cords into the trachea, the ETT is guided captively into the trachea over the scope. A medium-sized bronchoscope has the advantage of a larger suction channel to clear secretions from the oropharynx.

In situations where the FOB is of limited use related to unidentifiable or swollen airway anatomy, a combination technique using video laryngoscopy and fiber optic intubation may prove useful. One practitioner places the video laryngoscope in the mouth to obtain a view of the glottis, while a second practitioner guides the FOB either orally or nasally into the view of the video monitor. The ETT is then advanced over the FOB into the trachea as viewed on the video laryngoscope monitor.

Rescue airways

Preparation for the 'can't intubate, can't ventilate' event must include the immediate availability of rescue airway devices. Features of these devices include placement without the use of laryngoscopy or visualization, a high success level in placement, and allowance for oxygenation and ventilation while the patient is allowed to wake up, or a more definitive airway plan is put in place. Commonly used rescue airways include a variety of supraglottic devices as well as variations on esophageal obturators (EOs).

The most commonly used supraglottic airway is the laryngeal mask airway (LMA), which appears as part of the ASA Difficult Airway Algorithm in the case of inability to intubate and inadequate face mask ventilation (Law et al. 2013). Variations include a variety of cuff configurations, disposable or reusable LMAs, gastric drainage ports, and those that allow endotracheal intubation while in situ. LMAs

JAYPEE BROTHERS

are often used by providers as an alternative to face mask ventilation during an anesthetic and as a rescue device when conventional intubation techniques fail. There is an associated learning curve to their successful placement (Zundert et al. 2012). The most common cause of placement failure of an LMA is a small oral aperture, short, thick neck, large tongue, blood/mucus in the mouth and retrognathy (Zundert et al. 2012). Since there is no occlusion of the esophagus with the LMA, there is no protection against aspiration of gastric contents and it should be replaced when appropriate with a definitive airway for long-term ventilation.

Intubation through the LMA is possible with the Fastrach LMA or by the use of an Aintree Intubation Catheter (AIC) through which a fiberoptic intubating scope is placed. Proper placement of the device will ideally allow the Fastrach ETT to be passed through the lumen of the LMA into the trachea. After intubation, the Fastrach may be left in place temporarily or removed by using the pusher rod supplied with the kit.

EOs allow prehospital providers who are untrained in endotracheal intubation to rapidly secure the airway. The King Laryngeal Tube (King LT) is a single lumen device with a closed end that is placed into the oropharynx and blindly passed into the esophagus. Occlusive balloons are inflated in the esophagus and pharynx, and the patient is ventilated through supraglottic lumens. The possibility exists to place the lumen in the trachea that would prevent ventilation of the patient. If this occurs, the tube should be removed and replaced with manual anterior displacement of the trachea.

The Combitube is also inserted blindly. It has a dual cuff, dual tube design that allows for placement in either the esophagus or the trachea. The assumption is also that the tube will seat in the esophagus, but offers an alternative if tracheal placement occurs in that it does not occlude the trachea.

Any EO should not be placed in an alert patient or one with an intact gag reflex, and cannot be placed in patients with clenched teeth. They are contraindicated in patients with upper airway obstruction, known esophageal disease, or suspected tracheal injury (Zundert et al. 2012). EOs must be removed prior to endotracheal intubation in most cases. Possible complications of EO use include aspiration, soft tissue damage, tracheal or esophageal injury, and tongue swelling during prolonged use (Zundert et al. 2012).

Extubation

Knowing when to extubate is important and best done when the patient is awake and responsive. Various maneuvers can be utilized to validate extubation. Adequate spontaneous respiratory function with a vital capacity of >15 mL/kg and a negative inspiratory force of >20 Torr is recommended.

Airway edema may be assessed both audibly and visually prior to extubation. If air is heard escaping during positive pressure ventilation

JAYPEE BROTHERS

after the cuff is deflated (called the cuff leak test), then the patient is unlikely to have significant airway edema. If no escaping air is heard, extubation is not recommended.

For visual assessment of airway edema, the FOB can be placed in a nare and advanced until the ETT cuff is seen. Performing the cuff leak test then provides both an audible and a visual affirmation of an air leak. If significant tracheal edema is visualized, extubation should not proceed.

In the event that both of the above tests validate an acceptable air leak and minimal edema, but there is still a suspicion of airway problems, a bougie or AIC may be placed through the ETT prior to extubation. Lidocaine, 2% or 4%, 10 mL, should be administered down the ETT. The ETT may then be carefully removed, leaving the bougie or AIC in place in the event of the need for emergent reintubation. If the patient is breathing spontaneously without any evidence of upper airway edema after 30 minutes, the bougie or AIC may be removed.

Documentation

When a patient has had a difficult airway event, it is prudent to assume that future intubations will also be difficult, unless a significant change in the patient's status has occurred (e.g. weight, airway swelling, or cervical immobilization). Complete and thorough documentation including the number of attempts at intubation, ease of ventilation, other interventions, devices used, and intubation views throughout the event is the key to the prevention of future similar situations. Communication may be accomplished by a hospital-wide system of 'Difficult Airway' wristbands.

After a difficult airway event, a letter given to the patient regarding his or her airway history will provide other practitioners with the details of the event. The patients should be instructed to keep the letter with them and produce it on the occasion of future hospitalizations or surgeries.

Conclusion

While there is no single ideal or precise method of evaluating the airway prior to intubation, the ability to appreciate the issues of management of the airway will help medical personnel properly anticipate and plan for potential problems. Such prior and proper planning may help place providers in a position of a successfully secured airway, rather than that of a morbid outcome. Even in the most mundane clinical airway situations, backup plans, including videoscopy, FOB, and establishing an emergent surgical airway must always be considered.

Most patients without any difficult intubation indicators will prove easy to intubate, although occasional difficulties may still be encountered. The majority of difficult airways can be predicted by clinical assessment. However, none of these tests are 100% accurate

JAYPEE BROTHERS

and may erroneously predict a difficult intubation in some patients to whom intubation will subsequently prove to be uncomplicated. In the extreme case of the patient who could not be easily intubated or ventilated, the price of premature extubation may be serious and life threatening. Extra precautions should be taken prior to extubation.

Lastly, when a difficult intubation has been encountered, thorough documentation and proper communication may preclude a future repeat of the event.

References

Apfelbaum JL, Hagberg CA, Caplan RA, et al; American Society of Anesthesiologists Task Force on Management of the Difficult Airway. Practice guidelines for management of the difficult airway: an updated report by the American Society of Anesthesiologists Task Force on Management of the Difficult Airway. Anesthesiology 2013; 118:251–270.

Calder I, Calder J, Crockard HA. Difficult direct laryngoscopy in patients with cervical spine disease. Anaesthesia 1995; 50:756–763.

Caplan RA, Benumof JL, Berry FA, et al. Practice guidelines for management of the difficult airway. Anesthesiology 1993; 78:597–602.

Cormack RS, Lehane J. Difficult intubation in obstetrics. Anaesthesia 1984; 39:1105–1111.

Crosby ET, Cooper RM, Douglas MI, et al. The unanticipated difficult airway with recommendations for management. Can J Anaesth 1998; 45:757–776.

Freck CM. Predicting difficult intubation. Anaesthesia 1991; 46:1005–1008.

Knill RL. Difficult laryngoscopy made easy with a 'BURP.' Can J Anaesth 1993; 40:798–799.

Law JA, Broemling N, Cooper RM, et al. The difficult airway with recommendations for management – part 1– difficult tracheal intubation encountered in an unconscious/induced patient. Can J Anaesth 2013; 60:1089–1118.

Mort TC. Complications of emergency tracheal intubation: immediate airway-related consequences: Part II. J Intensive Care Med 2007; 22:208–215.

Mort TC. Emergency tracheal intubation: complications associated with repeated laryngoscopic attempts. Anesth Analg 2004; 99:607–613.

Pai S, Ghezzi EM, Ship JA. Development of a Visual Analogue Scale questionnaire for subjective assessment of salivary dysfunction. Oral Surg Oral Med Oral Pathol Oral Radiol Endod 2001; 91:311–316.

Patil VU, Stehling LC, Zaunder HL. Fiberoptic endoscopy in anesthesia. Chicago: Year Book Medical Publishers, 1983.

Roberts JT. Fundamentals of tracheal intubation. New York: Grune and Stratton, Inc., 1995:105–116.

Rumkumar V. Preparation of the patient and the airway for awake intubation. Indian J Anaesth 2011; 55:442–447.

Samsoon GLT, Young JRB. Difficult tracheal intubation: a retrospective study. Anaesthesia 1987; 42:487–490.

Taleb M, Ashraf Z, Valavoor S, et al. Evaluation and management of acquired methemoglobinemia associated with topical benzocaine use. Am J Cardiovasc Drugs 2013; 13:325–330.

Yong CK, Seung HL, Gyu JN, et al. Thermosoftening treatment of the nasotracheal tube before intubation can reduce epistaxis and nasal damage. Anesth Analg 2000; 91:698–701.

Zundert TV, Brimacombe JR, Ferson DZ, et al. Archie Brain: celebrating 30 years of development in laryngeal mask airways. Anaesthesia 2012; 67:1375–1385.

JAYPEE BROTHERS

MANAGEMENT OF THE DIFFICULT AIRWAY:
A HANDBOOK FOR SURGEONS

Securing and maintaining the airway is crucial to the assessment and management of the critically ill or injured patient. Many books focus on the role of the anesthesiologist, but *Management of the Difficult Airway: A Handbook for Surgeons* is the first book written specifically to help surgeons with the issues they face maintaining a clear airway and preventing obstruction.

The book provides practical guidance not just on emergency situations, but also on complex planned interventions such as surgery for congenital airway anomalies. Early chapters cover anatomy, imaging, indications and techniques in airway management; later ones cover situations in specific groups, for example patients requiring reconstruction of the airway as a result of cancer.

Management of the Difficult Airway: A Handbook for Surgeons is a comprehensive, timely review of the core knowledge and clinical skills necessary for successful airway management in the surgical environment.

- Provides a 'go-to' skills manual for surgeons focusing on difficult airway management in surgical patients
- Covers surgical airway management issues in both adult and pediatric patients
- Multidisciplinary author team combines the expertise of ENT surgeons, radiologists and anesthesiologists

JP medical publishers

www.jpmedpub.com

ISBN 978-1-909836-05-1

9 781909 836051