Recent Advances in Paediatrics



Edited by **Ian Maconochie**

Contents

Preface		**v**
Chapter 1	**Respiratory consequences of premature birth** *Sarah J Kotecha, Sailesh Kotecha*	**1**
Chapter 2	**Developmental dysplasia of the hips** *Sami Al-Ali, Deborah M Eastwood*	**11**
Chapter 3	**Sport and exercise medicine for health in children** *Bhavesh D Kumar, Charlotte Hamlyn Williams, Julian Redhead*	**27**
Chapter 4	**Paediatric simulation training** *Gabrielle Nuthall, Patricia Wood, Michael Shepherd*	**39**
Chapter 5	**C-reactive protein and procalcitonin in assessment of children with fever in the emergency department** *Ruud G Nijman, Alain Gervaix, Ian K Maconochie, Rianne Oostenbrink*	**51**
Chapter 6	**Respiratory syncytial virus prophylaxis in congenital heart disease** *Robert MR Tulloh, Jessica Green*	**65**
Chapter 7	**Noninvasive measurements of airway inflammation in children** *Louise Fleming, Prasad Nagakumar*	**73**
Chapter 8	**Advances in paediatric intensive care** *Benedict T Griffiths, Shane M Tibby*	**85**
Chapter 9	**Intranasal medicines in paediatrics** *Danielle S Hall, Ian Chi Kei Wong*	**97**

Chapter 10 **Introducing paediatric life-support courses into a low-income country** 109
Tom Lissauer, Martin Becker, Samuel Van Steirteghem, John Wachira, Lisine Tuyisenge

Chapter 11 **Rehabilitation after acquired brain injury in childhood** 121
Hayley Griffin, Robert Forsyth

Chapter 12 **Neurotoxicity of agents used in paediatric anaesthesia** 131
Hannah Gill

Index 139

Chapter 2

Developmental dysplasia of the hips

Sami Al-Ali, Deborah M Eastwood

INTRODUCTION

Developmental dysplasia of the hips (DDH) describes a continuum of hip pathology present both in the neonate and in the child that ranges from the slightly shallow acetabulum with potentially unstable movement through to more significant hip instability and subluxation, and on to frank dislocation of the femoral head which may or may not be reducible. Klisic introduced the term DDH to replace the previous label of 'congenital dislocation of the hip' to reflect our improved understanding of the pathophysiology and the realisation that only a few cases were frank dislocations at birth [1]. Most cases of hip dysplasia involved more subtle subluxation with unstable movement preventing the normal maturation of the infant acetabulum with worsening subluxation and dysplasia: thus any individual case of DDH may progress from mild dysplasia with clinically undetectable instability at birth to a dislocated hip.

Early detection and simple treatment with a harness that facilitates concentric reduction and encourages stable movement almost invariably leads to a 'normalisation' of anatomy with remodelling of acetabular dysplasia. Unfortunately, a significant number of cases continue to be identified late necessitating more challenging interventions including surgery of significant magnitude with much higher risk and less favourable outcome. Residual dysplasia and subluxation at skeletal maturity can lead to the early onset of osteoarthritis with increasing pain and limitation of activity in early adult life necessitating joint replacement surgery. A hip replacement in a patient's 30s and 40s will inevitably fail within 15–20 years meaning a revision procedure with higher associated risks may be necessary in the 50s and 60s. It is reported that DDH accounts for 10% of all primary hip arthroplasty and 30% of those performed in the under 60s [2]. For those with more minor degrees of dysplasia at skeletal maturity, excessive point loading of the outer edge of the acetabulum and its labrum can lead to painful tears and associated morbidity, and a new subspecialty has arisen in orthopaedics to deal with such problems in the young adult hip.

Our first challenge as a professional body must be to improve our early detection of DDH or hip instability so that early treatment can be instigated when appropriate. Subsequent

Sami Al-Ali BM MRCS FRCS, The Catterall Unit, Royal National Orthopaedic Hospital, Middlesex, UK

Deborah M Eastwood FRCS, The Catterall Unit, Royal National Orthopaedic Hospital, Middlesex, UK. Email: d.m.eastwood@btinternet.com (for correspondence)

JAYPEE BROTHERS

challenges involve recognition of whether the treatment has stabilised the hip, how to monitor these patients after treatment and for how long, and how to recognise residual dysplasia and decide when, how and if to intervene. This review will outline how the paediatric orthopaedic teams are tackling these challenges. Hip dysplasia in the context of neurological injury or as part of a more complicated syndrome or skeletal dysplasia is beyond the scope of this chapter.

AETIOLOGY AND RISK FACTORS

The aetiology remains unknown but is likely to be multifactorial. Hormonal factors probably influence the female predominance of 5:1 but there has been no demonstrated association with umbilical cord relaxin or oestrogen levels and DDH [3,4]. There is a 'genetic susceptibility' to DDH with a positive family history of one or more first-degree relatives or two or more second-degree relatives constituting a significantly increased risk. There is a strong maternal effect with a higher prevalence for offspring of mothers compared to fathers or siblings [5]. As yet, no specific gene has been identified but concordance is higher with monozygotic (33%) than dizygotic twins (8%) [6].

DDH is associated with 'packaging' disorders where there is little space in the uterus (**Table 2.1**).

The left hip is more commonly affected owing to the adducted position of the left leg in utero as the baby presents in the left occipitoanterior position for delivery. Tight packaging after birth with swaddling of infants with the hips both extended and adducted contributes to an increased incidence of DDH in certain populations [4]. This detrimental effect was recognised in Japan where a nationwide programme instigated to educate and discourage swaddling led to a five-fold decrease in incidence of DDH [7]. Swaddling garments that allow the legs more freedom to move into abduction and flexion are recommended by the International Hip Dysplasia Institute (www.hipdysplasia.org).

Breech presentation is a major independent risk factor even though twice as many females are born breech. The greatest risk is for those who are breech and delivered vaginally; the risk decreases with an elective caesarean section. A breech position at any stage in the last trimester will also increase the infants' risk for DDH.

PREVALENCE

The reported incidence varies widely between countries and populations and depends heavily on the means and/or criteria used for diagnosis. In populations with a high uptake

Table 2.1 Associations with in utero tight 'packaging'

Conditions associated with tight packaging	First pregnancy
	Oligohydramnios
	Birth weight >5 kg
	Multiple pregnancies
Other clinical features of packaging disorders	Foot deformities
	Plagiocephaly and torticollis
Postnatal packaging	Swaddling with hips extended

JAYPEE BROTHERS

of ultrasound assessment, the reported rate of dysplasia will be higher, though many would go on to normalise. The lowest incidence is reported in unscreened populations reporting a prevalence of 0.8–1.6 per 1000 [8]. With clinically screened populations, the prevalence was generally higher but with significant variability: 1.6–28.5 per 1000 [8]. If the screening includes ultrasound or radiographic assessment, rates vary depending on how the parameters are defined, but are much higher: 34–60.3 per 1000. About 20% of cases have bilateral hip involvement, and this group is more likely to be diagnosed late.

PATHOPHYSIOLOGY

The hip begins to form around the seventh week of gestation. By week 11, the spherical femoral head, its matching acetabulum and the ligamentum teres are identifiable. The hip is most lax and shallow in late pregnancy to facilitate delivery [9]. The growth potential of the infant and the modelling capacity of the largely cartilaginous acetabulum are both high.

There is a significant degree of joint laxity at birth and some clinical instability is relatively common; much of this will resolve spontaneously within the first 1–3 weeks of life. Similarly, many hips identified as dysplastic soon after birth with ultrasound will normalise over the first 3 weeks without intervention. Despite this trend, many clinicians feel that any clinical or sonographic concern should be taken seriously and observed in the appropriate setting by those with the appropriate specialist interest and insight.

While preterm infants may have more laxity and are 'behind' in their normal development, they do not have a higher incidence of DDH. This may be explained in part because the term infant has the greatest laxity and is more 'tightly packed' in the late stages than its preterm counterpart.

For neonates who demonstrate instability or where excessive pressure is concentrated on part of the acetabulum, distortion of anatomy and failure of uniform growth can occur.

An unstable hip with a dysplastic (shallow) acetabulum detected early in the first few weeks of life which is concentrically reduced, and in which stable movement is facilitated, should respond well to the more physiological forces applied to it and, in the majority of cases, a normal hip will result.

DIAGNOSIS

DDH is diagnosed either early or late; there is no agreed cut-off between the two which makes it difficult to compare many studies that discuss incidence, treatment and outcomes. For the neonate and nonambulant infant, DDH is asymptomatic and its detection must be a proactive process.

History

In the context of early detection, the useful history is confined to the detection of risk factors as outlined above. Particular attention should be paid to family history and full obstetric history.

In the older infant, the family may notice 'stiff hips' when changing a nappy and there may be signs noticeable in the walking infant such as a limp or a waddle, a short leg and a tendency to tip toe. Parental concerns should always be taken seriously. Although DDH does not usually hamper the infants from taking to their feet, 20% of children with DDH will not have stood or walked by 18 months compared to 5% of children without [10].

JAYPEE BROTHERS

The description of a 'clicky' hip should be taken seriously but it is not synonymous with DDH and frequently arises from iliopsoas anteriorly or fascia lata laterally clicking over the greater trochanter rather than the dislocation/reduction of a hip. Pain is not a presenting feature in childhood.

Clinical examination

In the neonate

Clinical examination of the neonate is a difficult skill to master. The environment and the hands must be warm and the baby relaxed, perhaps after a feed. The nappy must also be removed fully during a hip assessment. A general assessment of the baby is required to ensure a syndromic cause for any associated hip problems is excluded.

In the UK, it is a legal requirement that all neonates are examined and the hip assessment is an integral part of this examination. Too often, this task falls to an inexperienced member of a clinical team who is more likely to miss the clinical signs; the clinical examination should answer three questions as given in **Table 2.2**.

Inspection, with the nappy removed, may reveal a leg length discrepancy with the legs lying in extension. Asymmetrical skin creases in the groin do have an association (not absolute) with DDH; those more distally do not.

The Ortolani and Barlow [11] tests are a major part of the neonatal hip examination. While both have a high specificity of 100%, they have a low sensitivity of 60% [12] which drops significantly in inexperienced hands. Both are conducted with the hips flexed to 90° and with both knees held gently within the examiner's first web space; the fingers lie over the greater trochanter and the thumb over the medial proximal thigh. In this positon, one thigh may feel shorter than the other (Galeazzi sign positive).

The hips are then abducted in >90° of flexion; if there is any unilateral or bilateral limitation of abduction, a dislocated hip(s) must be suspected. The Ortolani test attempts to reduce a dislocated hip as the middle finger lying over the greater trochanter lifts the femoral head back into the acetabulum. This relocation of the femoral head may be very subtle and may happen inadvertently with the initial movement of the leg into abduction: as the hip abducts fully, a 'hiccough' or momentary catch is felt during the movement as the hip reduces. This test must be done gently.

If the hip is not clinically dislocated, it may be dislocatable; the legs are returned to the midline and the Barlow test is performed. This test seeks to dislocate an unstable hip by

Table 2.2 Clinical examination: the thought process

Clinical question	Answer
Is the hip dislocated clinically? Is it reducible?	Yes, dislocated hip Yes, Ortolani positive No, Ortolani negative
If the hip is not dislocated, is it dislocatable?	Yes, dislocatable hip, Barlow positive
If the hip is not dislocated or dislocatable, is it clinically normal? Are there any risk factors?	Yes, clinically normal hip The hip may still be at risk of DDH and warrant further investigation

DDH, developmental dysplasia of the hips.

JAYPEE BROTHERS

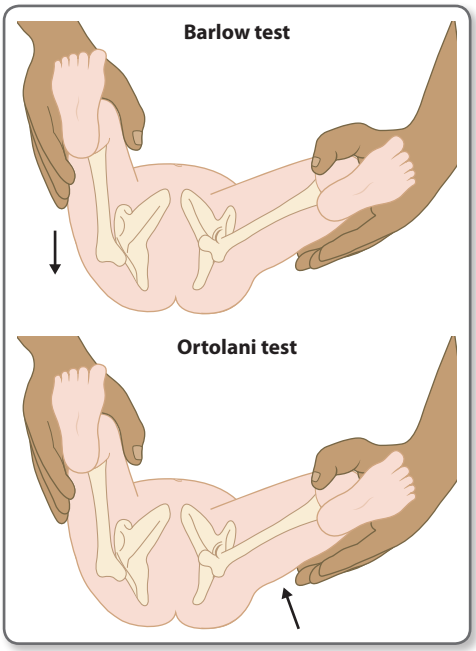

Figure 2.1 The Barlow and the Ortolani test. Arrows show the direction of force applied.

adducting the flexed hip and applying a front-to-back pressure. The Barlow test must be done gently.

Excessive force must not be applied to the vulnerable and immature femoral head. If the examination suggests the hip is clinically stable, this finding must be taken in conjunction with the history to decide whether or not the hip is still 'at risk' of DDH.

In the infant, it is important to distinguish between a 'Barlow positive hip', which is reduced at rest but unstable, and an 'Ortolani positive hip', which is dislocated at rest but reducible (**Figure 2.1**).

Both the Ortolani and Barlow tests become less sensitive after the neonatal period as the infant grows and muscle tone increases: a positive test in a child over 3 months of age should raise concerns of abnormal muscle tone and/or an underlying neurological problem.

In the infant

Limitation of hip abduction in >90° of flexion is a useful sign of DDH particularly after the age of 8 months with lower sensitivity before that age [13]. False negatives will occur if the pelvis is allowed to rock as each hip is abducted. A limitation of abduction is also less easy to detect if the hip is not flexed sufficiently. An asymmetry in movement is easier to detect than a symmetrical limitation that accompanies bilateral hip dislocation; clinicians are trained to detect asymmetry, but should be aware of 'bilateral asymmetry'.

Particularly with bilateral pathology, the perineum may seem 'wide' as both thighs have been effectively displaced laterally. The femoral head(s) may be palpable in the buttock.

While many of these signs are subtle, they are there to be elicited and any clinical concern from the history or examination should prompt the use of imaging to answer the question: is this a case of DDH or not?

JAYPEE BROTHERS

Imaging

Ultrasound

The ultrasound scan (USS) is the investigation of choice for the infant hip under 4 months of age. Graf popularised the static assessment of the dysplastic hip using USS to provide a morphological description of the cartilaginous hip (prior to the onset of femoral head ossification). He defined measurements taken from a standardised view with the line of the iliac wing denoting the axis from which the α angle of the acetabular bony roof and the β angle of the cartilage roof are measured. The acetabular rim might be flat or rounded, and the femoral head may be in or out of joint. He initially categorised hips into four grades but many of these now have subtypes (**Figure 2.2** and **Table 2.3**).

The Morin index allows a snapshot assessment to be made of whether the hip is adequately seated within its acetabulum or not. However, this emphasises again the concept of hip instability, a hip that is in joint one moment and may be out the next moment. Thus, the original static USS assessment has been broadened to include a useful dynamic assessment of stability [14].

USS can be repeated regularly without irradiation and may be used to monitor improved hip development, be it spontaneous or in response to treatment (**Figure 2.3**). It has the disadvantage that it is operator dependent.

Radiographs

Radiographs are generally a more useful imaging modality after the age of 4–5 months. The hip is still largely cartilaginous at this stage and the femoral head ossification which is taken as a sign of hip maturity and stability may not be visible until 5–6 months. Its appearance is often considerably delayed in DDH and there will be an asymmetry in size in unilateral cases.

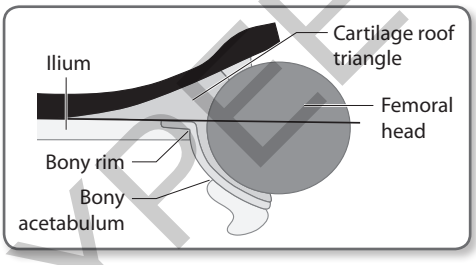

Figure 2.2 Interpretation of ultrasound.

Table 2.3 Simplified Graf classification

Graf type	α angle (bony roof) (degrees)	Bony rim
I	>60	Angular
IIa physiologically immature	50–59	Rounded
IIb delayed ossification	50–59	Rounded
IIc	43–49	Rounded
III eccentric	<43	Flattened
IV eccentric	<43	Flattened

JAYPEE BROTHERS

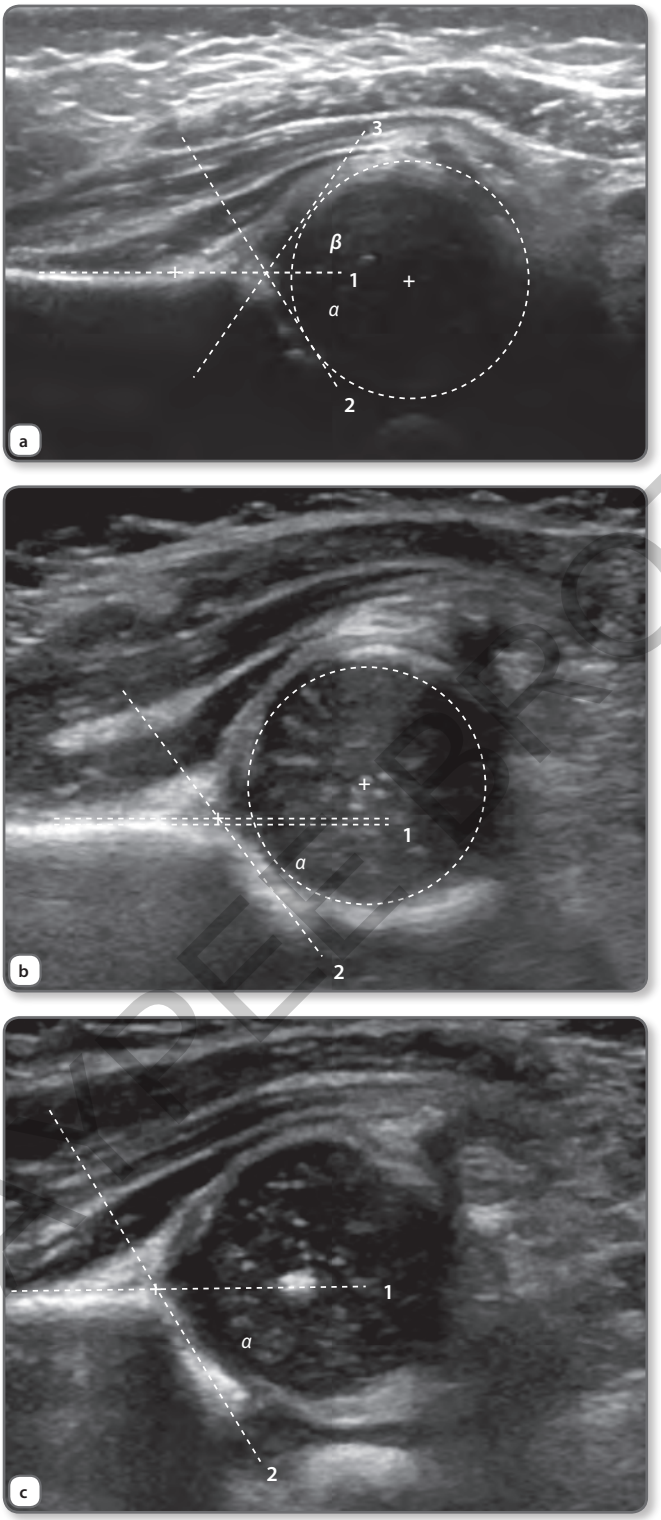

Figure 2.3 (a) Ultrasound scan of an infant hip. Baseline drawn along the ilium (1), bony acetabulum (2), cartilaginous labrum (3). The α angle formed measures the bony acetabulum. The β angle assesses the cartilaginous angle. Both angles are normal in this example. The dotted circle outlines the cartilaginous femoral head. Approximately half the femoral head should be 'below' line 1 and covered by the bony acetabulum. (b) Ultrasound scan of a dysplastic infant hip pretreatment with a Pavlik harness. The α angle is 53°. (c) Ultrasound scan of an infant hip after treatment with a Pavlik harness. The α angle is now 60°.

JAYPEE BROTHERS

Interpretation of the radiographs may be difficult in this age group but there are several features that should be noted (**Figure 2.4**).

Hilgenreiner's line is drawn through the triradiate cartilage of both hips and sets the horizontal axis. Perkin's lines are at 90° to this axis and are drawn in line with the lateral most extent of the visible bony acetabulum. These lines divide each hip radiographically into quadrants and the femoral head should lie in the inferomedial quadrant.

Shenton's line should be seen as a smooth curve going around the obturator foramen with a seamless transition to follow the curve of the medial femoral neck.

The acetabular index (the inclination of the line drawn along the ossified bony acetabular roof relative to Hilgenreiner's line) is another important measurement in children's hips (**Figure 2.4**). Its value decreases as ossification continues and the hip grows older. It is used to monitor the response of the hip to treatment. Debate continues about what angles constitute normal reflecting the appreciation of DDH as a spectrum. Tonnis set some age-related standards [15]; values between 1–2 standard deviations indicate a delay in ossification, and values greater than this signify dysplasia [16].

Other radiographic measures are used in the adolescent after ossification of the triradiate cartilage.

Serial radiographs along with clinical examination form the cornerstone of our Stanmore surveillance protocol as described in the literature [17]. There is a balance to be struck between regular surveillance and limiting radiation exposure with one study suggesting a small but slightly increased risk of leukaemias in patients treated with surgery for DDH, whom they presume to have been exposed to serial radiographs [18].

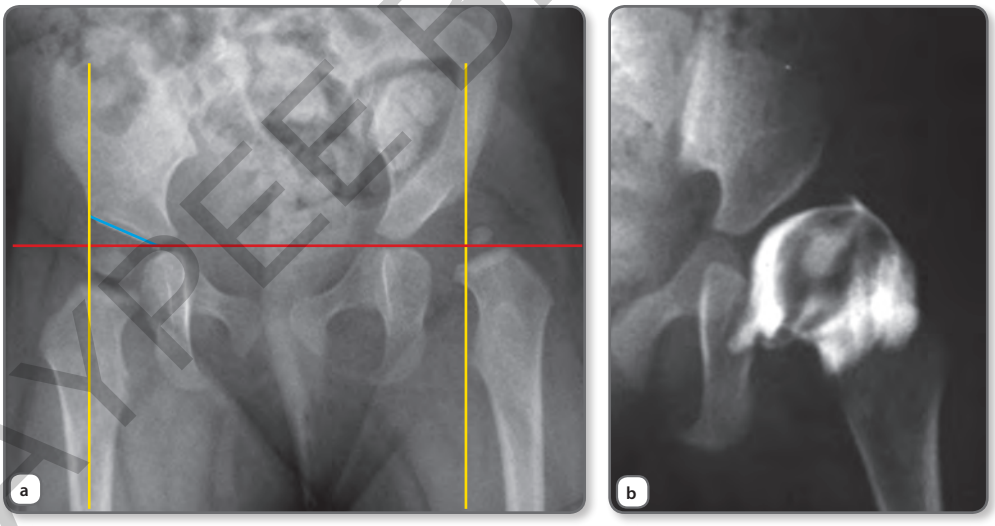

Figure 2.4 (a) Radiographic assessment of developmental dysplasia of the hips (DDH) on an anteroposterior pelvic radiograph. Hilgenreiner's line (red) passes through the open triradiate cartilages of both hips to mark the horizontal, Perkin's line (yellow) is perpendicular and vertical at the edge of the depicted bony acetabulum. The acetabular index is the inclination of the line drawn along the ossified bony acetabular roof (blue on the normal side) relative to Hilgenreiner's line. The ossific nucleus should be located in the inferior medial quadrant formed by the intersection of Hilgenreiner's and Perkin's lines. In this example, the ossific nucleus of the left hip is outside this quadrant and the nucleus is smaller in size: both signs of DDH. (b) A hip arthrogram more accurately demonstrates the cartilaginous acetabulum and femoral head and permits a dynamic assessment under anaesthesia. The white area represents dye between the subluxed femoral head and the acetabulum.

JAYPEE BROTHERS

TREATMENT

The principal aim of early treatment for DDH is to achieve a concentric reduction of the hip and facilitate stable movement while avoiding complications. The hip has a tremendous ability to remodel and 'normalise' if provided with optimum conditions, especially if those conditions can be provided early in infancy and we know that many cases of neonatal instability and dysplasia resolve spontaneously without treatment.

There is surprisingly little evidence to say that early treatment is more effective than the natural history of hip instability, but those treated before 7 weeks fare better than those treated later.

Outcomes decline the later the diagnosis is made, perhaps due to the greater need for more extensive treatments with greater risks and complications.

With respect to DDH, the spectrum of severity, stability and anatomical differences on both the acetabular and femoral sides, combined with differing responses to similar treatments, makes it difficult to outline a robust prescriptive treatment protocol. Instead, the following sections outline the treatment principles used at various stages of the pathophysiology.

Pavlik harness and splinting

In accordance with our principal aim for treatment stated above, infant hips deemed to require treatment to obtain and maintain the reduction of the femoral head within the acetabulum (Ortolani positive hips) or to improve stability (Barlow positive hips) may be treated with a harness or splint. Rigid splints such as the Von Rosen have been shown to be successful but the most popular treatment is dynamic splinting with the Pavlik harness (**Figure 2.5**).

In the presence of hip dislocation or instability, treatment usually commences between 2 and 3 weeks although some specialist centres will wait until 6 weeks: treatment of a neonatally detected hip instability should not be delayed past this point (without the agreement of your treating team).

The Pavlik harness is a dynamic, flexion/abduction orthosis that is fully adjustable both to suit the size of the patient and to accommodate the best position for his/her particular hip morphology.

Great care must be taken when using this method of treatment for an Ortolani negative hip (the irreducible dislocation): some centres would not use a harness for such a case and many would treat for only 1–2 weeks if no progress was seen.

For the Ortolani positive and Barlow positive hips, the hip is placed in the reduced position and held in the middle of the safe/stable zone of flexion/extension, abduction/adduction. The arc of movement is 'controlled' by the anterior and posterior harness straps. Extreme positions and excessive forces must be avoided as they risk compromising the vascularity of the femoral head. Avascular necrosis can be a devastating problem in the infant hip causing a stiff and painful hip from childhood onwards. The risk of avascular necrosis has been reported as low as 0.3% [19] and is minimised by careful and considered application and use of the splint.

The harness encourages a gradual stretch of the tight adductor muscles and with increasing abduction, relocation of the femoral head is more likely and the Ortolani negative hip may become an Ortolani positive hip; similarly the Ortolani positive hip may become a Barlow positive hip. The reduction can be gradual and by permitting movement,

JAYPEE BROTHERS



Figure 2.5 Baby in Pavlik harness.

JAYPEE BROTHERS

growth of the acetabulum is promoted and the socket deepens to accept the femoral head. Once the hip is reduced, it is maintained until joint stability and normal (near-normal) anatomy are achieved. The stretched and lax joint capsule 'shrinks' and muscle length and tone improve.

In our institution, the harness is applied between the ages of 2 and 6 weeks for a period of 6–8 weeks, but protocols vary considerably and there is no single best practice method. The success rates quoted may be as high as 95% of cases but this will vary with the case mix treated: the treatment of the Ortolani positive and negative hips is often less successful than treatment of the Barlow positive hips.

In many centres, treatment protocols are driven more by the Graf classification than the clinical interpretation of the pathology.

The success of the splint diminishes and is questionable between 4 and 6 months of age and generally not appropriate after 6 months of age. It is also contraindicated in hips which are teratologic and not reducible, or in whom there is poor compliance.

The splint is worn 23–24 hours per day during the treatment period and the response is assessed on ultrasound at 2–3 weekly intervals. Failure of reduction after 2–3 weeks in the splint is an indication to discontinue splinting. The baby must also be assessed clinically to adjust the splint for growth and to ensure there is no femoral nerve palsy (**Figure 2.5**) [20].

Closed reduction

For those diagnosed late or those in whom early treatment has been unsuccessful, a closed reduction under general anaesthetic forms the next level in the treatment ladder. This is often coupled with an arthrogram which outlines the cartilaginous parts of the joint and allows a radiographic dynamic assessment of the hip to be performed, and the soft tissue 'blocks' to obtaining and maintaining a reduction can be evaluated (**Table 2.4**).

If the hip reduces, surgical release of adductor longus and psoas may improve the quality of the reduction and its stability. The reduction is then held by placing the child in a hip spica cast (**Figure 2.6**). Both legs have to be included in the cast and the plaster may end at the knee or at the ankle.

Table 2.4 Structures obstructing reduction

Site of obstruction	Obstructing tissue
Extracapsular	Adductor muscles
	Psoas muscle
Capsule	Hourglass constriction which prevents the femoral head relocating
Intracapsular	Ligamentum teres
	Transverse acetabular ligament
	Pulvinar and infolded labrum



Figure 2.6 A short leg hip cast.

Table 2.5 Factors affecting joint stability

Factors	Characteristics
Bony anatomy	Are the femoral head and acetabulum well matched in terms of shape, size and orientation?
Soft tissue integrity	Are the stabilising ligaments and capsule working well?
Muscle tone	Are the muscles long enough and working well enough?

Following the procedure, maintenance of the reduction is with imaging; debate continues as to whether plain radiographs, limited slice computed tomography, magnetic resonance imaging or USS provide the most appropriate information.

Joint stability depends on three factors: bony anatomy, soft tissue integrity and muscle tone (**Table 2.5**).

The duration of cast treatment varies from centre to centre: it does take time for the stretched capsule to shrink and to provide stability for the joint and for the acetabulum and femoral head/neck to remodel to a perfect shape. Our protocol is for 12 weeks in plaster cast followed by 6 weeks in a removable brace. Some surgeons advocate much longer in plaster but there is little robust evidence for this. The use of traction preoperatively has fallen out of favour in the United Kingdom but it is still popular in Europe.

JAYPEE BROTHERS

Open reduction

The inability to obtain or maintain a closed reduction of a hip is an indication for an open reduction. Age and the surgeon's understanding of the individual pathophysiology may also be indications for open surgery.

Open reduction of the hip may be performed via a medial (groin) incision and approach or via an anterior (bikini-cut) incision below the iliac crest. The appropriate approach is chosen depending on which soft tissue blocks need to be dealt with and whether or not the surgeon wishes to take the opportunity to surgically 'shrink' the capsule and/or change the shape of the bones to improve the hip joint stability.

Following the open reduction, a hip spica cast is applied extending to the ankle on the affected side; the total time in cast varies from 6 to 10 weeks.

Late presentation

The older the child is at presentation and the longer the hip has been out of joint, the greater the likelihood that more extensive surgery will be required to obtain and maintain the hip in the reduced position. Realignment of the acetabulum and the femoral head by means of a pelvic and/or femoral osteotomy is common when the child is aged 2 years or more (**Figure 2.7**).

A femoral osteotomy results in a change in the rotational profile of the bone; as a result of this, the child may have less internal rotation ability postoperatively and may, e.g. no longer be able to 'W-sit'.

A pelvic osteotomy reorientates or reshapes the acetabulum so that it faces the correct way and is the correct size; various eponymous names are given to these operations. As a very general rule, the more surgery that is required to reduce the hip, the poorer the long term outcome is likely to be.

Ongoing evaluation

Once a hip is relocated, it is the hope of every surgeon that the child's growth potential and innate 'understanding' of how a hip should be will aid in hip development; this

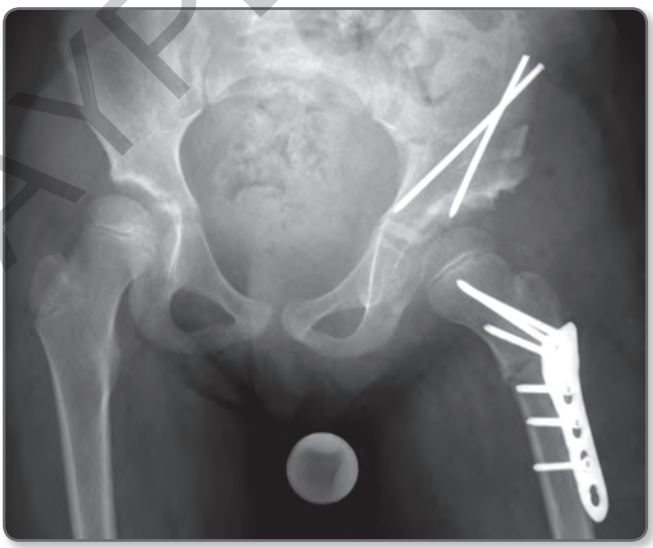

Figure 2.7 Anteroposterior pelvic radiograph showing a left hip that has been treated for developmental dysplasia of the hips with an open reduction and pelvic and femoral osteotomies.

JAYPEE BROTHERS

Recent Advances in Paediatrics 27

Recent Advances in Paediatrics 27 is the ideal resource for keeping abreast of new developments in this constantly changing field. Written by expert authors and featuring topics such as introducing paediatric life-support courses into a low-income country and advances in paediatric intensive care, each chapter highlights the latest developments of relevance to clinical practice. This book is an invaluable update and revision tool for trainees preparing for postgraduate examinations.

- Practical and clinically relevant content, enhanced by *Key Points for Clinical Practice* at the end of each chapter
- Chapters focus on significant recent developments in the field of paediatrics
- Effective revision tool for candidates preparing for postgraduate paediatric examinations

JP medical publishers

www.jpmedpub.com

ISBN 978-1-909836-25-9