EFOST

Surgical Techniques in Sports Medicine

Knee Surgery Volume 1: Soft Tissue

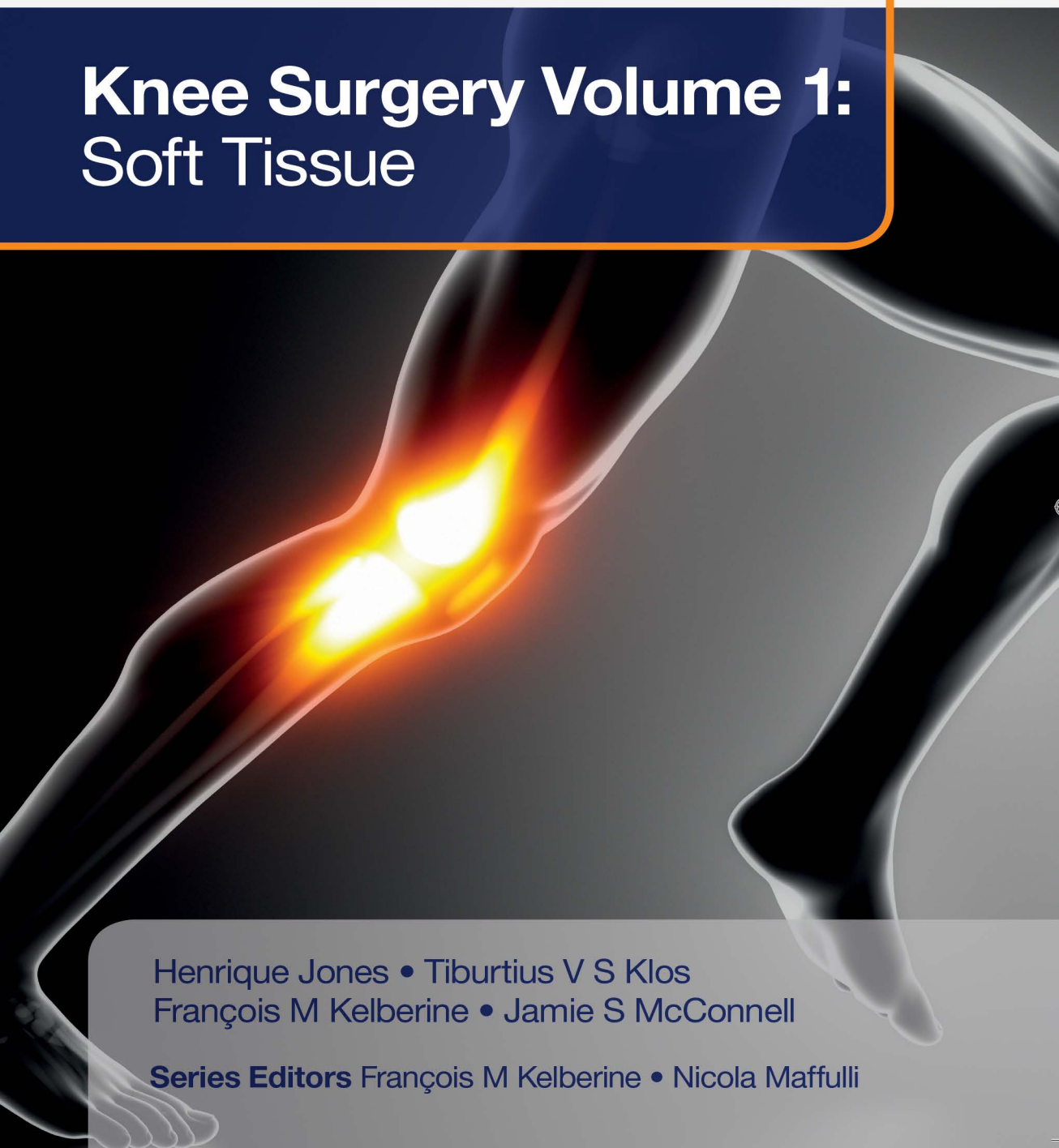

Henrique Jones • Tiburtius V S Klos
François M Kelberine • Jamie S McConnell

Series Editors François M Kelberine • Nicola Maffulli

09/10/2015 12:43

Contents

Foreword v
Contributors x

Chapter 1
Reconstruction of the anterior cruciate ligament using bone–patellar tendon–bone autograft 1
François Kelberine

Chapter 2
Reconstruction of the anterior cruciate ligament using hamstring autograft 9
Francesco Benazzo

Chapter 3
Reconstruction of the anterior cruciate ligament using iliotibial band autograft 17
Christian Lutz

Chapter 4
Reconstruction of the anterior cruciate ligament using quadriceps tendon autograft 25
Tiburtius V S Klos

Chapter 5
Reconstruction of the anterior cruciate ligament without foreign materials: bone dowel method 31
Gernot Felmet

Chapter 6
Reconstruction of the anterior cruciate ligament with open physes 41
Henrique Jones

Chapter 7
Extra-articular lateral tenodesis for anterior cruciate ligament-deficient knee 45
Andrea Ferretti

Chapter 8
Reconstruction of the posterolateral corner 53
Carlos Sánchez Marchori, Carlos Sánchez Monzó

Chapter 9
Reconstruction of the posterior cruciate ligament using a single bundle graft 59
Henk van der Hoeven

Chapter 10
Arthroscopic resection of the medial meniscus 67
Vasileios Raoulis, Michael Hantes

Chapter 11
Arthroscopic treatment of a meniscal cyst 73
Henrique Jones

Chapter 12
Arthroscopic plasty of the discoid meniscus 77
Michael R Carmont, Charlotte Tunstall, Katarina Nilsson-Helander

Chapter 13
Arthroscopic meniscal repair: the 'all-inside' method 81
Tiburtius V S Klos

Chapter 14
Reconstruction of the medial patellofemoral ligament using hamstring tendon autograft 87
Henrique Jones

Chapter 15
Dynamic reconstruction of the medial patellofemoral ligament with hamstring tendon autograft 93
Albert van Kampen, Akkie Rood

Chapter 16
Reconstruction of the medial patellofemoral ligament with quadriceps tendon autograft 97
Mirco Herbort, Christian Fink

Chapter 17
Repair of acute quadriceps tendon rupture **105**
Pedro Guillen-García, Fernando Sanz-Zapata, Isabel Guillen-Vicente, José I Garrido, Tomás Fernández-Jaen, Marta Guillen-Vicente, Enrique Ibáñez

Chapter 18
Surgery for patellar tendonitis: 'jumper's knee' **111**
Zoran Bahtijarević, Tomislav Vlahović

Chapter 19
Complete arthroscopic synovectomy **115**
Michael R Carmont, Uğur Haklar, Rohit Dhawan, Nicklas Olsson

1 Reconstruction of anterior cruciate ligament using bone–patellar tendon–bone autograft

Indications

Reconstruction of a complete tear of the anterior cruciate ligament (ACL) is indicated in:

- Patients < 25 years of age to prevent the occurrence of secondary meniscal tears, which are a causal factor of later degeneration
- Patients wishing to return to full pivoting activities
- Patients > 40 years old when an attempt at proprioceptive rehabilitation has failed to stabilize the knee
- Patients complaining of functional pivoting instability regardless of age

Preoperative assessment

Clinical assessment

Basic signs of ACL tear

- Patients describe feeling a popping from the injured knee while twisting the knee, and immediate instability. The knee became swollen quickly. Pain is variable
- Examination assesses the amount of swelling and location of pain. Both can limit the range of motion. The examiner undertakes thorough gentle manipulation with the Lachman test at 30° of flexion, anterior drawer test at 90° of flexion, and pivot shift test on the supine patient, comparing with the opposite side

Further physical assessment

- Investigate frontal laxity in extension. If present, this could indicate an additional peripheral ligamentous lesion
- Investigate the presence of pain at the joint line, which could indicate a meniscal tear
- The presence of lateral pain is often related to the bony impact

Imaging assessment

Radiographs

- Anteroposterior and lateral views detect possible avulsion of the ACL at the tibial level or a partial fracture of the lateral aspect of the tibial plateau (Segond's fracture). This fracture is an indirect sign of an ACL tear

Magnetic resonance imaging (MRI)

- MRI is useful for detecting associated lesions, although this should be delayed until swelling has partially resolved to improve image contrast
- A delay is also useful as some lesions heal spontaneously
- Direct ACL tears are visible as disorganization of the ligament fibers
- Be aware of indirect signs of ACL tear:
  - Bone bruising in the lateral compartment
  - Curved appearance of the posterior cruciate ligament
- Check the menisci and cartilage

Timing for surgery

- Surgery takes place once inflammation around the knee has mostly resolved
- The patient must display good quadriceps strength
- The knee joint must be pain free and be able to flex actively to at least 120°

JAYPEE BROTHERS

Surgical preparation

Surgical equipment

- Entire arthroscopic ACL reconstruction set including:
  - Tibial and femoral guides with pins
  - Reamers of different diameter (6–12 mm)
  - Graft calibrating devices
- Screws from 7 to 10 mm in diameter, which can be metal or absorbable
- A complete arthroscopic set with a shaver
- An arthroscopy pump, although this is not used routinely

Equipment positioning

- The arthroscopic tower faces the surgeon on the opposite side of the table at the level of the patient's shoulder

Patient positioning

- Lay the patient supine with the knee flexed at 90°, stabilized with a lateral pad and a foot bar (**Figure 1.1**)
- Ensure the knee can be mobilized from full extension up to 120° of flexion
- A pply a tourniquet to the upper thigh

Further preparation

- Implantation of material justifies antibiotic prophylaxis



Figure 1.1 Patient stabilized with a lateral pad and a foot bar.

Surgical technique

Harvesting bone–tendon–bone graft

- Inflate the tourniquet to 350 mmHg. Exsanguinate the limb before making the first incision
- Make a vertical skin incision at the medial border of the patellar tendon from the distal tip of the patella down to the tibial tubercle (**Figure 1.2**)
- The skin is supple and can slide medially above the patellar tendon, proximally over the patella, and distally under the tibial tubercle (mobile window)
- The peritendon is incised vertically in the midline, and two sleeves are detached from the tendon at its lateral and medial margins
- Using a no. 10 blade, the middle third of the tendon is harvested longitudinally, taking care not to damage the fat pad
- With the same blade, mark the outlines of both the patella and tibial bone blocks, in line with the edges of the patellar tendon
- Drill a 2.7 mm hole in the center of each bone block before excising as the blocks are more stable in situ (**Figure 1.3**)
- Use a small oscillating saw to excise the tibial bone block
- Make two 2 cm long vertical cuts in the tibial tubercle following the lines drawn previously



Figure 1.2 Surface marking of the patellar tendon from the distal tip of the patella down to the tibial tubercle.

JAYPEE BROTHERS

(**Figure 1.4**). The horizontal distal cut joins the extremities of the vertical ones
- To release the tibial bone block, use a small chisel to cut the superior part of the block just behind the tendon attachment
- The tibial bone block should now be free
- With the tip of the no. 10 blade, detach the infrapatellar fat pad from the posterior aspect of the tendon up to the distal apex of the patella (**Figure 1.5**)
- Use the same small saw to excise the patellar bone block
- Make two vertical 1.5–2 cm long cuts following the limits marked on the patella
- Make a horizontal cut joining both cuts at their proximal ends
- The final saw line is frontal, starting at the distal pole of the patella parallel to the anterior cortex (**Figure 1.6**)
- The patellar bone block should now be free
- Spread bone wax on the tibial harvesting site to stem any bleeding
- Reshape the bone blocks into cubes with a rongeur
- Pass a Monocryl 5 decimal suture through the drill hole in the smaller bone block (normally the patellar bone block)
- Make a blue mark with a pen at the tendon–bone block limit
- Pass a strong metallic suture through the drill hole of the larger bone block (normally the tibial bone block; **Figure 1.7**)

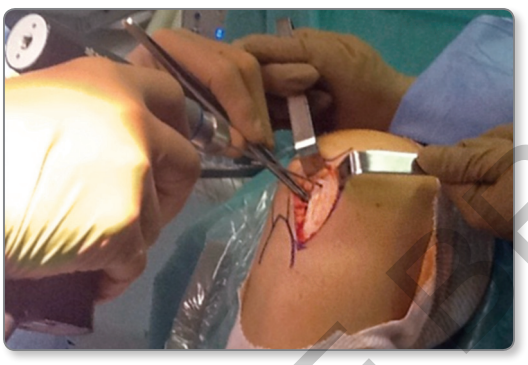

Figure 1.3 Holes measuring 2.7 mm drilled in the center of each bone block before excising.

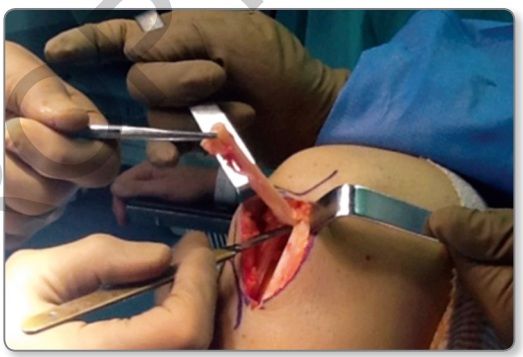

Figure 1.4 Vertical cuts in the tibial tubercle.

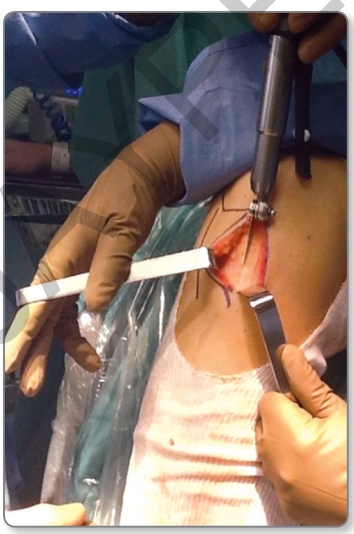

Figure 1.5 Detaching the infrapatellar fat pad.

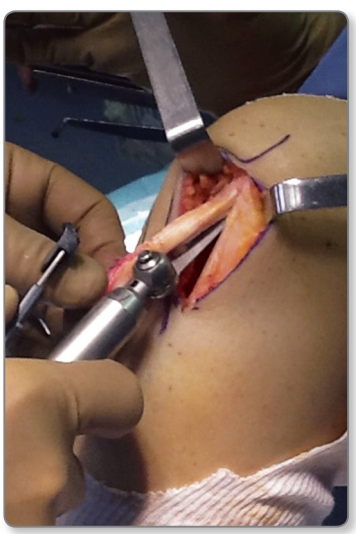

Figure 1.6 Final saw line during removal of the patellar bone block.

JAYPEE BROTHERS

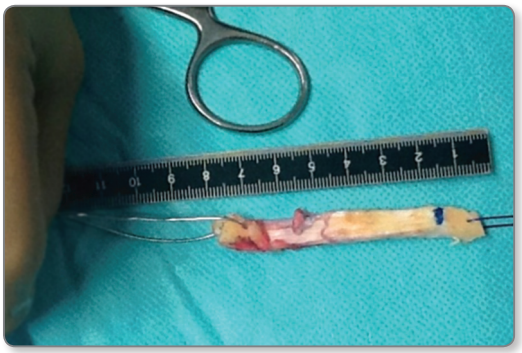

Figure 1.7 Metallic suture passed through the drill hole of the larger (tibial) bone block.

Arthroscopic cleaning

Portals

- Place anterolateral and anteromedial portals for scope insertion **(Figure 1.8)**
- The anterolateral portal should be placed 1 cm above the lateral joint line and 1 cm lateral to the margin of the patellar tendon
- The anteromedial portal should be placed opposite, 1 cm above the lateral joint line and 1 cm lateral to the margin of the patellar tendon
- Assess the menisci and cartilage by inspection and probing

Remove the ACL remnants

- Clean the axial aspect of the lateral condyle with a shaver until the periosteum is visible, the posterolateral capsular recess lying just behind it (**Figure 1.9**)
- Clean the posterior cruciate ligament by sliding a basket forceps between the two cruciate ligaments
- Finally, clean the tibial ACL footprint with the shaver

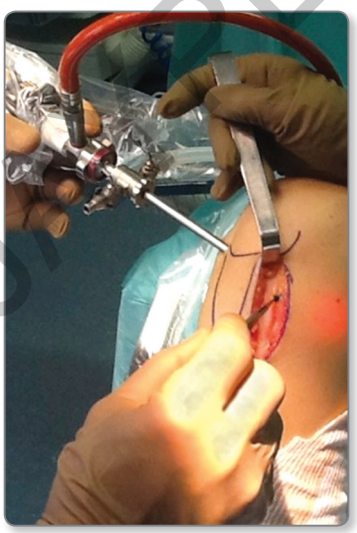

Figure 1.8 Anterolateral and anteromedial portals for scope insertion.

Making tunnels

Tibial tunnel

Flex the knee to 90° and insert the tibial alignment guide into the medial portal.

- Set the angle of the tibial guide to 45°
- Center the tip of the tibial guide so that the intra-articular guide pin enters the joint just anterior to the posterior cruciate ligament
- Fix the guide extra-articularly to the medial cortex, 15 mm above the tibial harvesting site (**Figure 1.10**)
- Push the drill through the guide
- The tunnel is drilled obliquely, up to the point of the femoral tunnel placement
- If the positioning is not perfect, use a 6 mm reamer for a slight change of direction in order for the drill to access the optimal femoral spot
- Use the reamer to make the tunnel the same size as the larger bone block
- Clean both extremities of the tunnel to allow the graft to slide through easily

Femoral tunnel

- Choose the size of the femoral guide. Its offset should be no greater than 1 mm larger than the

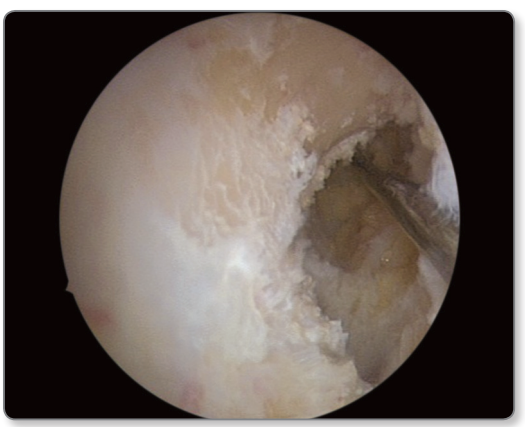

Figure 1.9 Cleaning the axial aspect of the lateral condyle.

JAYPEE BROTHERS



Figure 1.10 Tibial guide fixed extra-articularly to the medial cortex.

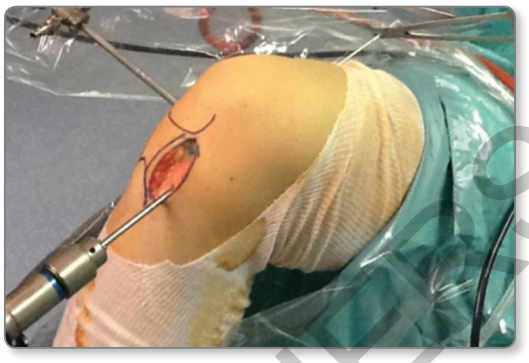

Figure 1.11 Femoral guide is passed transtibially.

radius of the smaller bone block, to ensure the posterior cortex remains intact
- Switch off irrigation to choose a good femoral spot under clear vision
- Pass the femoral guide transtibially and hook it in the over-the-top position, which is located between 9 and 11 o'clock on the right knee, and between 1 and 2 o'clock on the left knee (**Figure 1.11**)
- Transfix the femur with a long drill through the guide. This drill has an eye at its distal tip. The drill will exit at the anterolateral aspect of the thigh
- Ream the femoral tunnel on the wire up to 20 mm. The depth of the tunnel is measured at the anterior part as the tunnel entrance is oval
- Remove all the debris with the shaver to avoid interference with the passage of the graft. Check the integrity of the posterior cortex (**Figure 1.12**)

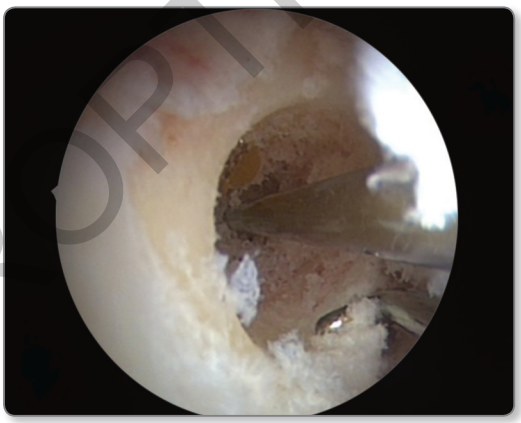

Figure 1.12 Debris removed from the femoral tunnel.

Passage of the graft

- Pass the Monocryl suture linked to the smaller bone block through the tibial tunnel so that it exits the intra-articular end of the tibial tunnel, and enters the intra-articular end of the femoral tunnel
- Once the Monocryl suture has been passed into the femoral tunnel, thread it through the eye of the drill
- Coat the graft with liquid petroleum jelly to facilitate its passage, and pull the graft into position (**Figure 1.13**)
- Once the smaller bone block has passed through the tibial tunnel and is in the joint, push the larger bone block into the tibial tunnel

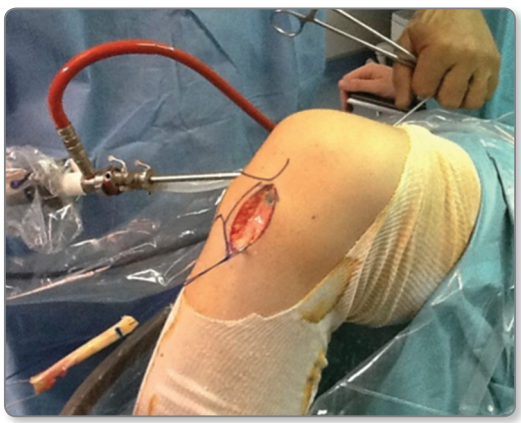

Figure 1.13 Pulling the graft into position .

- Turn the irrigation back on
- Direct the smaller intra-articular bone block

JAYPEE BROTHERS

to the entrance of the femoral tunnel with a grasper, and push the tendon into the femoral tunnel as posteriorly as possible
- Pull the suture at thigh level to insert the block in the femoral tunnel until the blue line drawn on the tendon is level with the tunnel's entrance

Fixation of the graft

Femoral fixation

- Insert a pin guide for the screw through the anteromedial portal. The tip of the pin is positioned between the bone block and the anterior edge of the femoral tunnel entrance
- Bend the knee to 120° to allow the guide to be pushed through both tunnels. The guide must slide easily toward the hard contact at the end of the tunnel
- Keep the same knee flexion to allow the insertion of a 7 × 20 mm metallic screw on the guide. Screw it in until its head is level with the entrance of the tunnel and/or the blue line on the graft
- Checks should be made:
  - Test the fixation by pulling the distal metallic suture
  - Test for absence of impingement (arthroscopic view) between the graft and the roof of the notch

mm

Tibial fixation

- Insert the pin guide for the distal interference screw between the edge of the tibial tunnel entrance and the bone block
- If the graft positioning is not perfect, change the location of the pin around the periphery of the tunnel to slightly modify the tibial bone block position
- Maintain the knee flexed to 30° in slight external rotation (**Figure 1.14**)
- Insert a 9 × 20 mm metallic screw up to be sure to lock the tibial block (the diameter can be larger in cases of a larger tunnel)
- Check the pivot shift and anterior drawer movements before removing the metallic suture



Figure 1.14 The knee flexed to 30° in slight external rotation during insertion of the distal interference screw.

Possible perioperative complications

- Fracture of patella: this should be fixed
- Slippage of the tendon in either of the bone blocks: use the remaining bone block at the femur, make a strong suture on the other extremity, and fix it with a large absorbable screw
- Disruption of the femoral posterior cortex: make a new femoral tunnel, again starting within the joint, but exiting at a different point in the posterior cortex
- Breakage of the pulling suture on the tibial side: use a 90° curve instrument to push the tibial bone block distally from the articular entrance during screw insertion

Closure

- Close the peritendon over the tendon defect (**Figure 1.15**) with an absorbable suture. It cannot be closed at the tibial level
- No drainage is needed
- Close the subcutaneous and skin layers in a standard fashion
- Apply a simple dressing
- Apply a rigid straight knee splint

Postoperative management

Postoperative regimen

- Medications: painkillers, nonsteroidal anti-inflammatory drugs, thromboprophylaxis prevention for 5 days

JAYPEE BROTHERS



Figure 1.15 Closure of the peritendon over the tendon defect.

- Full weight bearing
- Immediate mobilization without limitation
- Isometric quadriceps contractions
- Discarding of the brace once quadriceps strength is sufficient to walk with one contralateral crutch (from day 1 to 10)
- Outpatient visits at days 45 and 90 with plain radiographs to check healing of the bone blocks

Early-phase complications

- Swelling
- Stiffness in flexion and/or extension
- Quadriceps weakness
- Patellar tendinopathy

JAYPEE BROPTHERS

EFOST

Surgical Techniques in Sports Medicine

Knee Surgery Volume 1: Soft Tissue

Surgical Techniques in Sports Medicine – the gold standard series of surgical manuals published with the European Federation of National Associations of Orthopaedic Sport Traumatology

Each book in the series provides authoritative, step-by-step guidance on how to perform key surgical procedures in a specific anatomical region. Written by teams of experienced practitioners in a clear, direct style, the *Surgical Techniques in Sports Medicine* series is the ideal companion for trainee sports trauma and orthopaedic surgeons seeking to develop their surgical skills.

Knee Surgery Volume 1: Soft Tissue gives practical advice on the surgical procedures used to correct soft tissue injuries to the knee. Each chapter clearly explains how to perform a single procedure in its entirety, from indications, preoperative assessment, preparation and surgical technique to closure and rehabilitation. The technique section forms the core of each chapter and describes every step of the procedure clearly and concisely. The chapters also describe potential complications, how best to avoid them and how to manage them when they occur.

- Experienced surgeons share their knowledge of commonly performed techniques to help you improve your own skills
- Accessible design and concise text enable you to quickly find and assimilate the information you need before performing surgery
- Surgical photographs allow you to visualise techniques and follow each stage of the procedure

Titles in the *Surgical Techniques in Sports Medicine* series:

Elbow Surgery
Foot and Ankle Surgery
Hand and Wrist Surgery
Hip and Pelvis Surgery
Knee Surgery Volume 1: Soft Tissue
Knee Surgery Volume 2: Bone and Cartilage
Muscles and Tendons
Shoulder Surgery Volume 1: Instability and Trauma
Shoulder Surgery Volume 2: Rotator Cuff and Shoulder Arthroplasty
Spine Surgery

JP medical publishers

www.jpmedpub.com

ISBN 978-1-909836-37-2

EFOST_241x171.indd 1