Surgical Techniques in Sports Medicine

Knee Surgery Volume 2: Bone and Cartilage

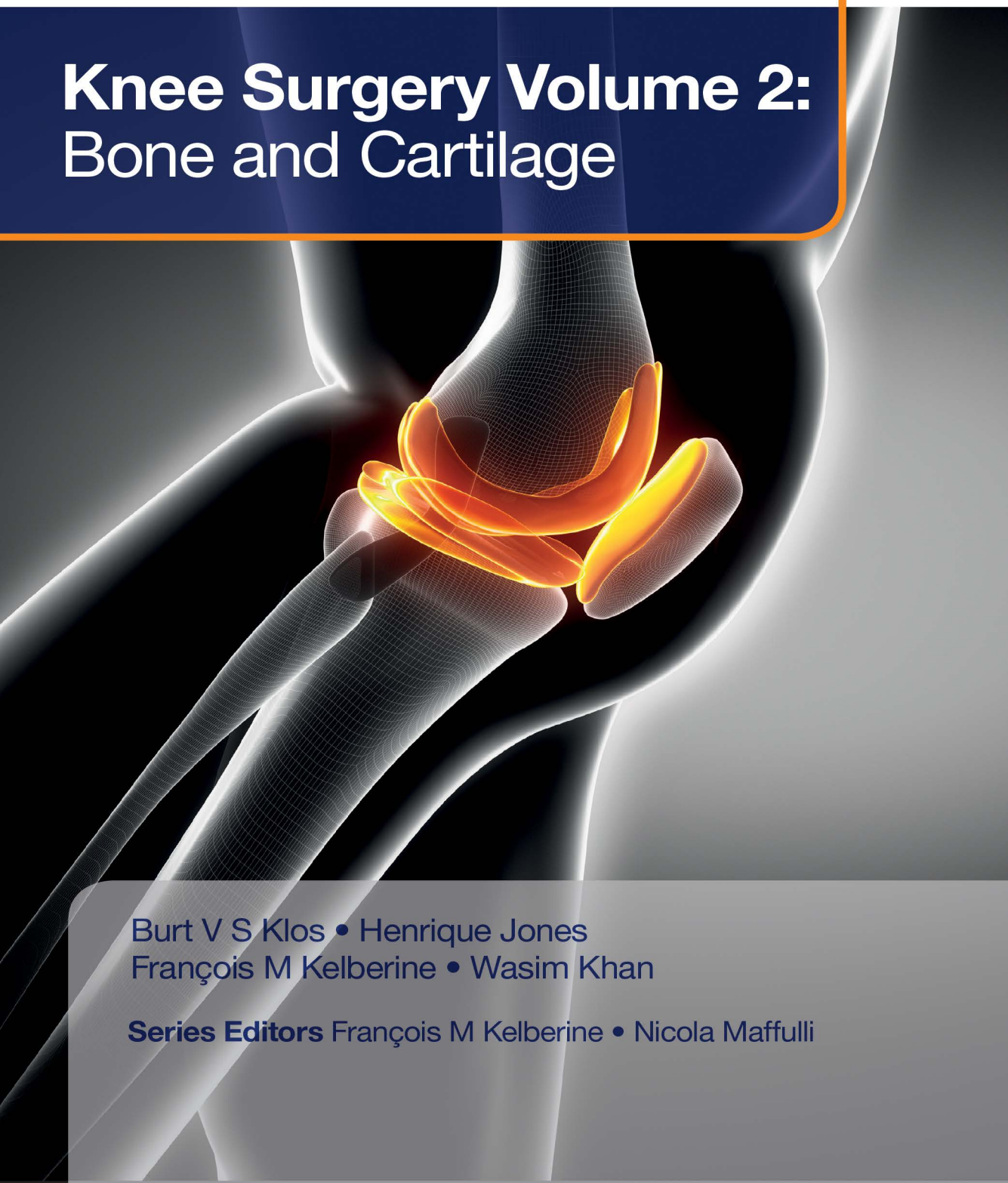

Burt V S Klos • Henrique Jones
François M Kelberine • Wasim Khan

Series Editors François M Kelberine • Nicola Maffulli

Contents

Foreword v
Contributors ix

Chapter 1
Arthroscopic fixation of distal detachment of the anterior cruciate ligament 1
Mirco Herbort

Chapter 2
Arthroscopic treatment of tibial plateau fractures 7
Nicolas Pujol

Chapter 3
Trochlear osteotomy (Albee procedure) for patellar instability 13
Albert van Kampen

Chapter 4
Repair of cartilage defects using osteochondral allograft 17
Wojciech Widuchowski, Martyn Snow

Chapter 5
Repair of cartilage defects using scaffold 21
Wojciech Widuchowski

Chapter 6
Repair of cartilage defects with microfracture surgery 25
Henrique Jones

Chapter 7
Repair of cartilage defects with mosaicplasty – osteochondral autograft transfer 29
Gernot Felmet

Chapter 8
Distal femur medial closing wedge osteotomy 37
Pedro Pessoa, Mafalda V Batista

Chapter 9
Distal femoral opening wedge osteotomy 47
G H Robert Albers

Chapter 10
Extra-articular graft for osteochondritis dissecans 53
Mirco Herbort

Chapter 11
Fixation of osteochondritis dissecans 61
Henrique Jones

Chapter 12
High tibial opening wedge osteotomy 65
Alexandre Netten, Kars Valkering, Koen Lagae, Peter Verdonk

Chapter 13
Lateral approach for distal femoral fracture reduction and fixation 71
Carlos Ribeiro, Tiago Oliveira

Chapter 14
Medial approach for distal femoral fracture reduction and fixation 77
Carlos Ribeiro, Tiago Oliveira

Chapter 15
Open fixation of tibial plateau fractures 83
Rien Heijboer

Chapter 16
Open reduction and internal fixation of patellar fractures 87
Alexander H van der Veen

Chapter 17
Surgery for Osgood–Shlatter disease 95
Eliyahu Adar

Chapter 18
Proximal tibial tubercle transfer for patella baja (infera) 101
Sebastiaan van de Groes

Chapter 19
Distal tibial tubercle transfer for patellar instability 105
Sebastiaan van de Groes

2 Arthroscopic treatment of tibial plateau fractures

Indications

- Arthroscopic treatment of tibial plateau fractures is classically indicated if the following criteria are met:
  - Schatzker type 1 (split), type 2 (split and depression) or type 3 (depression) fractures of the lateral tibial plateau (**Figure 2.1**) in non osteoporotic bone, when the soft tissues and fracture configuration allow the fracture to be managed without external fixation
  - In the acute phase (up to 2–3 weeks after injury), ideally within the first days
- Arthroscopy allows the surgeon to diagnose and treat concomitant soft tissue pathologies synchronously
- The treatment of tibial plateau fractures with arthroscopically assisted percutaneous osteosynthesis is associated with less extensive surgical dissection, lower morbidity, and a shorter period of postoperative immobilization

Preoperative assessment

Clinical assessment

- As these fractures are high-energy injuries, these patients need to be managed according to the Advanced Trauma Life Support guidelines
- Soft tissue injuries are common and include skin abrasions, muscle contusions, and meniscal (up to 47%) and ligament (up to 40%) injuries. These need to be evaluated during the clinical assessment. Medial collateral ligament injuries are more common than anterior cruciate ligament injuries
- Neurovascular injuries need to be excluded. Injuries to the popliteal trifurcation posteriorly and the peroneal nerve laterally are more common in view of the tethering of these structures at these respective locations

Imaging assessment

Radiography

- Standard anteroposterior and lateral views are mandatory (**Figure 2.2**) and help identify the fracture. They provide only limited information regarding the fracture configuration and frequently underestimate the extent of the fracture
- When further imaging is not possible or is not available, oblique views have a role in determining the fracture configuration, and stress views have a role in suspected ligament injuries and instability
- Radiographs remain the mainstay in the assessment of the quality of fracture reduction intraoperatively and in the radiological follow-up

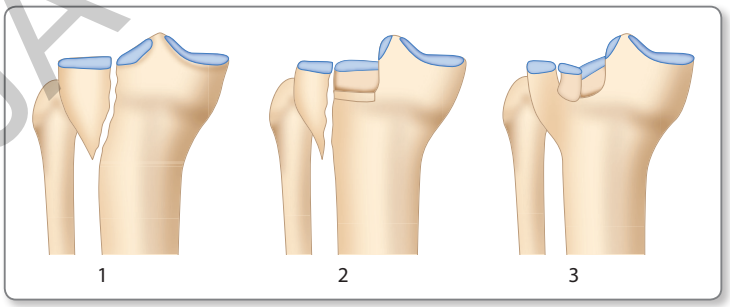

Figure 2.1 Schatzker classification.

JAYPEE BROTHERS



Figure 2.2 Anteroposterior and lateral views of a Schatzker type 3 fracture of the left knee.

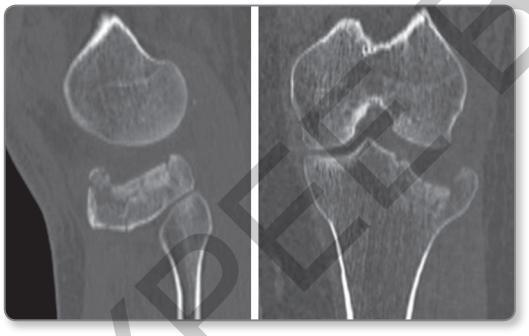

Figure 2.3 CT of a Schatzker type 3 fracture of the left knee: note the orientation of the various depressed fragments.

Computed tomography (CT)

- CT is important in determining the fracture configuration and in surgical planning (**Figure 2.3**). Three-dimensional reconstructions can be useful
- CT enables better anatomic determination of the fracture configuration including fracture lines and fragments (including ligament avulsion injuries), comminution, and displacement (including joint depression)

Other investigations

- MRI has a role in the assessment of meniscal and ligament injuries
- CT angiograpahy has a role when vascular injuries are suspected

Timing for surgery

- This is carried out in the acute phase (up to 2–3 weeks after injury), ideally within the first few days

Surgical preparation

Surgical equipment

- A complete arthroscopy set with a shaver. A 5.5 mm shaver can be used to clear the hemarthrosis
- An arthropump that maintains a constant pressure within the knee
- An anterior cruciate ligament reconstruction set that includes tibial and femoral guides with pins, reamers of different diameters (6–12 mm), graft-calibrating devices, dilators and metal or absorbable screws (7–10 mm)
- An image intensifier and a radiolucent table to facilitate intraoperative imaging

Equipment positioning

- The arthroscopy tower is positioned on the contralateral side in front of the surgeon
- The image intensifier is located on the ipsilateral side, allowing anteroposterior and lateral imaging. The optimal positions of the image intensifier and the monitor are determined before draping

Patient positioning

- The patient is positioned supine with a support or stirrup at the thigh allowing unrestricted limb mobility; the knee can be positioned in varus, valgus, or a figure-of-4 position during the procedure. The leg can be placed on the operating table in flexion or allowed to drop, according to the surgeon's preference
- An above-knee tourniquet is used
- A sterile tourniquet and U-shaped sterile drapes facilitate access to the iliac crest for bone graft harvest

Further preparation

- Antibiotic prophylaxis and deep vein thrombosis prophylaxis should be

JAYPEE BROTHERS

administered according to local institutional protocol

Surgical technique

- The principles of the surgical management of intra-articular fractures are anatomic restoration of the articular surface and stable fixation of the fracture to allow immediate postoperative mobilization

Exposure

- Arthroscopy of the knee is performed using standard arthroscopic anterolateral and anteromedial portals after inflation of the tourniquet. Outflow is established via the arthroscopic cannula sheath to minimize the intra-articular pressure
- The hematoma is evacuated. This process can be lengthy and tedious
- A third superolateral portal can be used to introduce a cannula to evacuate the hematoma and avoid excessive joint pressure
- When intra-articular visibility improves, a 5.5 mm shaver can be used to assist in removing clots and small bone fragments within the joint cavity
- The position of the instruments in the ports can be switched as needed

Fracture assessment

- Following joint lavage, a comprehensive evaluation is performed to identify bone and cartilage lesions, as well as damage to any other structures such as the menisci and ligaments
- All findings must be scrupulously recorded in the operative report as the extent of the lesions is of prognostic significance and may require additional surgical procedures
- Peripheral plateau fractures are at least partly covered by the lateral meniscus and can be difficult to visualize (**Figure 2.4**). A loop introduced from lateral to medial to retract the meniscus will aid visualization

Fracture reduction

- Split fractures are reduced by closed manipulation together with percutaneous pinning using the joystick technique
- To elevate depressed fractures, we use an anterior cruciate ligament guide to locate the centre of the depressed articular surface (**Figure 2.5**), and we make a cortical window with a 10 mm reamer (**Figure 2.6**). A second pin is placed on the other side of the depressed articular surface and a second cortical window is made (**Figure 2.7**). The fractures are elevated through the cortical windows using custom-made impactors under arthoscopic and fluoroscopic control (**Figure 2.8**)
- Arthroscopy allows direct vision of the intra-articular fracture and a more accurate reduction
- The displaced fragments are then reduced using large grasping forceps or reduction clamps

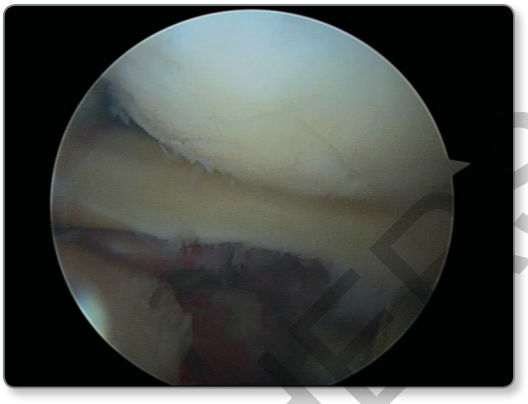

Figure 2.4 Identification of bone and cartilage lesions.

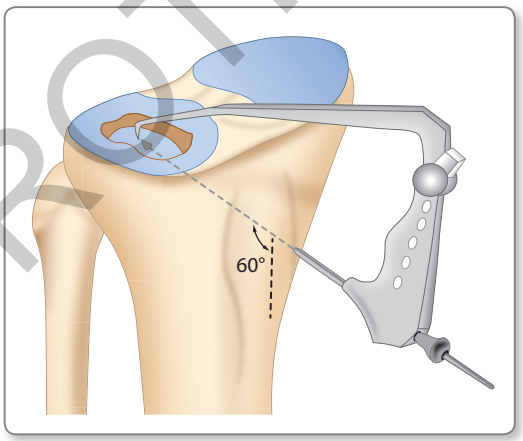

Figure 2.5 Placement of the tibial anterior cruciate ligament drill guide.

JAYPEE BROTHERS

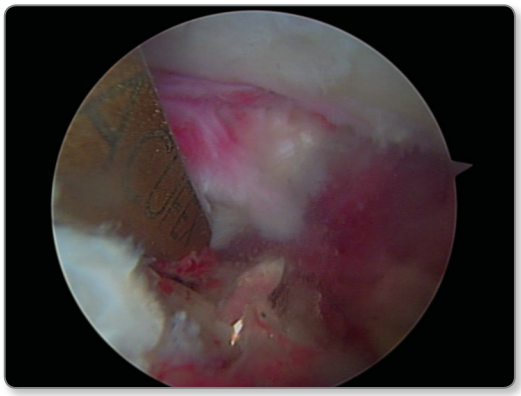

Figure 2.6 Arthroscopic view of the anterior cruciate ligament tibial guide in the depressed fragments.

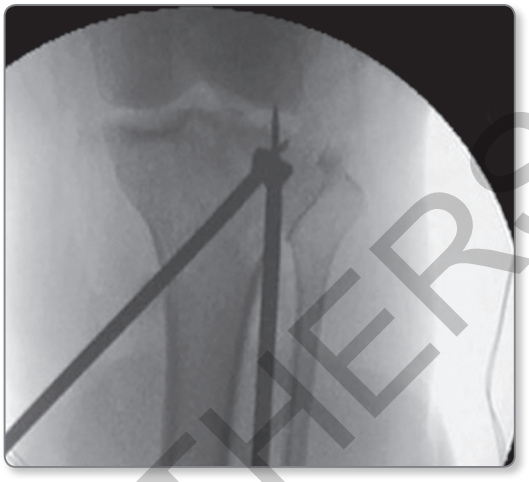

Figure 2.8 Reduction of the fragments.

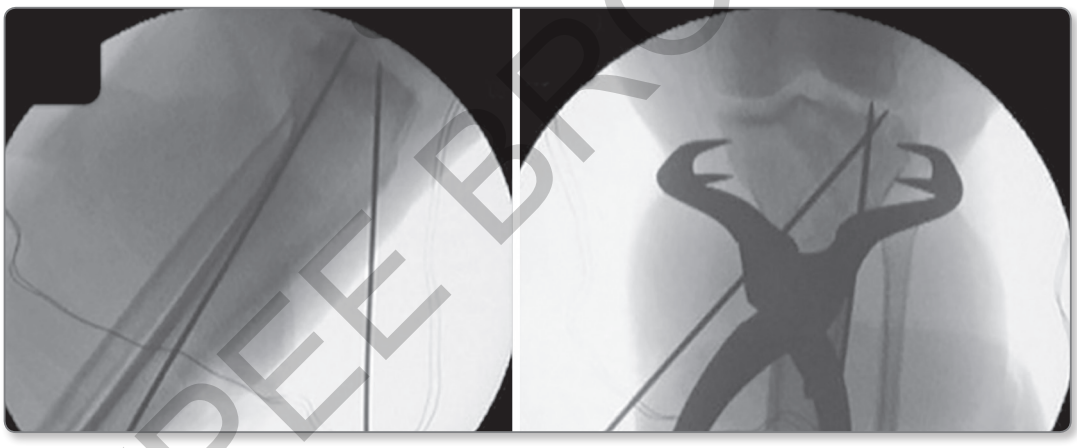

Figure 2.7 Second pin inserted into the fracture.

Fracture fixation

- Temporary stabilization is achieved using one or two Kirschner (K) wires that should ideally be placed parallel to and about 1 cm under the articular surface
- Lateral tibial plateau fractures should be stabilized using two or three large-diameter (6.5 mm) cannulated screws inserted percutaneously, in combination with a washer
- The screws should be placed horizontal to the tibial plateau, just underneath the subchondral bone (**Figure 2.9**). The screws are tightened under arthroscopic guidance (**Figure 2.10**). Care should be taken to avoid excessive tightening, which can adversely affect reduction quality. Screw length and position are checked fluoroscopically
- After fracture fixation, the intra-articular soft tissues are examined. Associated peripheral lateral meniscus tears are frequent and should be repaired using either all-inside (posterior horn) or outside-in (anterior horn or body) techniques

JAYPEE BROTHERS

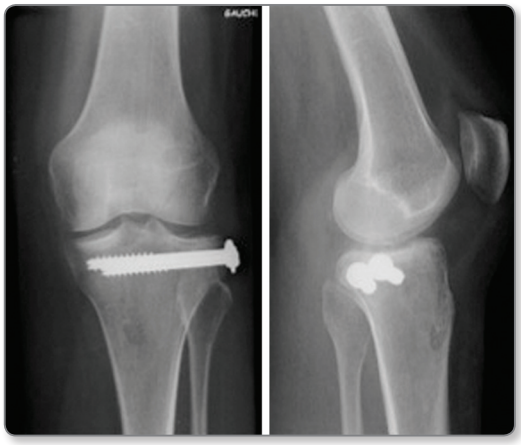

Figure 2.9 Osteosynthesis with two screws parallel to the joint line.

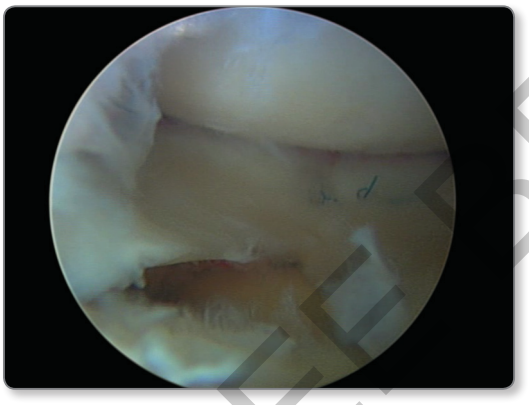

Figure 2.10 Arthroscopic control of reduction of the fractures.

Filling lost bone

- A large metaphyseal bone defect risks loss of fracture reduction; therefore consideration must be given to filling this defect. The use of autologous iliac crest cancellous bone, allograft bone and orthopedic cement can be considered depending on the defect size, patient's age, quality of reduction, and surgeon's preference

Possible perioperative complications

- If any additional injuries are identified, they will need to be dealt with appropriately. Meniscal tears, significant ligament injuries causing instability, and intercondylar fractures need to be managed at the same time

Closure

- A suction drain is placed in the joint and the wounds are closed with resorbable stiches

Postoperative management

- Patients commence active quadriceps exercises on day 1 postoperatively after drain removal
- A continuous passive motion device improves cartilage nutrition by facilitating movement and can be used until discharge
- We recommend that patients refrain from weight bearing for 30 days and that they use hinged knee braces after the edema resolves and the wound heals
- Partial and full weight bearing are allowed at 6 and 10 weeks, respectively
- Compartment syndrome, thromboembolism, and infection are the most dreaded complications but are fortunately rare

Early-phase complications

- Swelling
- Stiffness in flexion and/or extension
- Malunion
- Non-union

Outpatient follow-up

- Day 1: Walk with crutches; no weight bearing; return home
- Day 45: Partial weight bearing in the clinic
- Day 90: Full weight bearing
- Day 365: Possible hardware removal

Implant removal

- Metalwork removal can be performed at least 1 year following injury if needed. An arthroscopic assessment of the cartilage defect can be done at the same time as a prognostic evaluation tool is applied (**Figure 2.11**)

JAYPEE BROTHERS

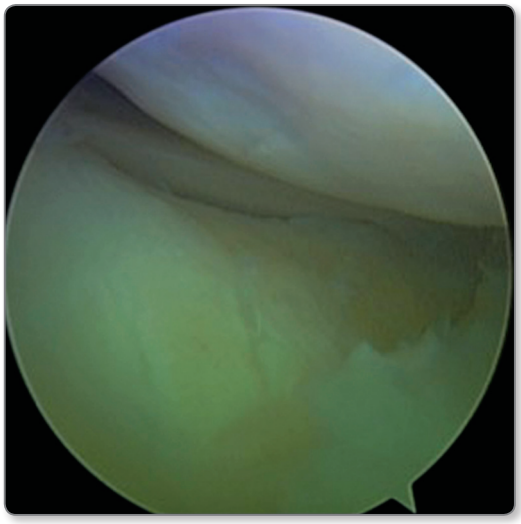

Figure 2.11 Arthroscopic assessment 1 year postoperatively during metalwork (screws) removal.

Further reading

Burdin G. Arthroscopic management of tibial plateau fractures: surgical technique. Orthop Traumatol Surg Res 2013; 99(1 Suppl):S208–S218.

Hohl M. Part I: Fractures of the proximal tibia and fibula. In: Rockwood, C, Green D, Bucyholz R (eds), Fractures in adults, 3rd edn. Philadelphia: JB Lippincott, 1992: 1725–1757.

Schatzker J, Tile M. Fractures of the tibial plateau. In: Schatzker J, Tile M (eds) The rationale of operative fracture care. New York: Springer-Verlag, 1980: 279–295.

JAYPEE BROTHERS

EFOST **Surgical Techniques in Sports Medicine**

Knee Surgery Volume 2: Bone and Cartilage

Surgical Techniques in Sports Medicine – the gold standard series of surgical manuals published with the European Federation of National Associations of Orthopaedic Sports Traumatology

Each book in the series provides authoritative, step-by-step guidance on how to perform key surgical procedures in a specific anatomical region. Written by teams of experienced practitioners in a clear, direct style, the *Surgical Techniques in Sports Medicine* series is the ideal companion for trainee sports trauma and orthopaedic surgeons seeking to develop their surgical skills.

Knee Surgery Volume 2: Bone and Cartilage gives practical advice on the surgical procedures used to correct bone and cartilage injuries to the knee. Each chapter clearly explains how to perform a single procedure in its entirety, from indications, preoperative assessment, preparation and surgical technique to closure and rehabilitation. The technique section forms the core of each chapter and describes every step of the procedure clearly and concisely. The chapters also describe potential complications, how best to avoid them and how to manage them when they occur.

- Experienced surgeons share their knowledge of commonly performed techniques to help you improve your own skills
- Accessible design and concise text enable you to quickly find and assimilate the information you need before performing surgery
- Surgical photographs allow you to visualise techniques and follow each stage of the procedure

Titles in the *Surgical Techniques in Sports Medicine* series:

Elbow Surgery
Foot and Ankle Surgery
Hand and Wrist Surgery
Hip and Pelvis Surgery
Knee Surgery Volume 1: Soft Tissue
Knee Surgery Volume 2: Bone and Cartilage
Muscles and Tendons
Shoulder Surgery Volume 1: Instability and Trauma
Shoulder Surgery Volume 2: Rotator Cuff and Shoulder Arthroplasty
Spine Surgery

JP medical publishers

www.jpmedpub.com

ISBN 978-1-909836-38-9