EFOST

Surgical Techniques in Sports Medicine

Elbow Surgery



François M Kelberine • Wasim Khan

Series Editors François M Kelberine • Nicola Maffulli

Contents

Foreword v
Contributors x

Chapter 1
Arthroscopic debridement for osteochondritis dissecans of the capitellum 1
W Jaap Willems

Chapter 2
Arthroscopic treatment of osteochondritis dissecans using mosaicplasty 7
Luigi A Pederzini, Emanuele Tripoli, Felice Di Palma, Fabio Nicoletta

Chapter 3
Open treatment for lateral epicondylitis 11
Robert G Turner

Chapter 4
Surgical repair of distal triceps tendon rupture 15
Adam Watts

Chapter 5
Reconstruction of chronic distal triceps tendon ruptures 21
Melanie Vandenberghe, Neil E Jarvis, Roger van Riet

Chapter 6
Repair of distal biceps tendon rupture 27
I F Kodde, Denise Eygendaal

Chapter 7
Radial head fracture fixation 33
Nikolaos Doxariotis, Konstantinos T Ditsios, Sokratis E Varitimidis

Chapter 8
Prosthetic radial head replacement 39
Neil E Jarvis, Roger van Riet

Chapter 9
Olecranon fracture fixation 45
Neil E Jarvis, Roger van Riet

Chapter 10
Fracture fixation for distal humeral intra-articular fractures 51
Robert G Turner

Chapter 11
Flexible intramedullary nailing for pediatric supracondylar humeral fracture 59
Sébastien Pesenti, Elie Choufani, Franck Launay, Elke Viehweger, Jean-Luc Jouve

Chapter 12
Acute ligamentous repair following elbow dislocation 65
Pierre Mansat

Chapter 13
Arthroscopic debridement for posteromedial impingement 71
Adam Watts

Chapter 14
Treatment of chronic posterolateral instability of the elbow 75
Pierre Mansat

Chapter 15
Treatment of chronic medial elbow instability 81
Luigi A Pederzini, Felice Di Palma, Fabio Nicoletta, Emilio Delli Sante

Chapter 16
Open debridement for elbow arthritis 87
Polykarpos I Kiorpelidis, Michael Hantes, Sokratis E Varitimidis

Chapter 17
Arthroscopic arthrolysis of the elbow 95
W Jaap Willems

Chapter 18
Total elbow arthroplasty without bone loss **103**
Pierre Mansat

Chapter 19
Endoscopic treatment of olecranon bursitis **111**
Mahmut Nedim Doral, Gürsel Leblebicioğlu, Seval Tanrikulu, Akin Üzümcügil

2 Arthroscopic treatment of osteochondritis dissecans using mosaicplasty

Indications

- The treatment of osteochondritis dissecans (OCD) is based on the separation of the osteochondral fragment
- Stable early lesions are managed nonoperatively, and avoidance of sports and repetitive stress on the elbow is usually sufficient to allow complete healing of the lesion
- Surgery is the treatment of choice for unstable lesions, loose bodies, and symptomatic lesions that fail nonoperative treatment after a period of 3–6 months

Preoperative assessment

Clinical assessment

- OCD typically affects the young adolescent athlete from 13 to 16 years of age involved in high-demand, repetitive overhead throwing or weight-bearing activities, e.g. baseball, gymnastics, racquet sports, American football, and weight lifting
- OCD can cause recurrent pain, progressive dysfunction, and limited range of motion. The patient may also complain of popping and clicking. The young athletes will complain of pain and limitation of activities affecting their ability to participate in sport
- On examination there may be secondary joint contracture and joint swelling

Imaging assessment

- Although lesions have been reported in the trochlea, radial head, and olecranon, the most common site of OCD of the elbow is the capitellum
- Panner's disease is a differential diagnosis and should not be confused with true OCD; Panner's disease is most common from 4 to 8 years of age and involves the entire ossification center, not only the anterolateral capitellum

Radiographs

- In the early stage, radiographs may be normal or only show localized radiolucencies or bone rarefactions
- In the advanced stage, loose intra-articular bodies and joint irregularities may be seen

Magnetic resonance imaging (MRI)

- MRI has become the standard imaging modality for OCD and provides an accurate assessment of the size, extent, and stability of the lesion
- Determination of lesion stability and the integrity of the articular cartilage cap is important in deciding between nonoperative and operative treatment

Surgical preparation

Surgical equipment

- Arthroscopy stack and intruments including a 4.5 mm 30° arthroscope

Equipment positioning

- The surgeon stands with the operating table at chest level to prevent contamination of the dependent hand. An arm board is placed parallel to the operating table at the level of the arm
- All equipment is mounted on a portable rolling platform
- The monitor, digital recorder, light and camera control and pump with irrigation bags are placed on the opposite side of the patient
- A mayo tray is on the right of the surgeon
- An assistant is on the left of the surgeon

JAYPEE BROTHERS

Patient positioning

- The patient is placed in the lateral decubitus position with the shoulder abducted to 90° and the elbow flexed to 90° with the arm in an arm holder secured to the operating table (**Figure 2.1**)
- The ipsilateral hip is externally rotated with the knee exposed to harvest the donor osteochondral tissue for mosaicplasty from the lateral trochlea
- The anesthetist identifies the nerve trunks with electrostimulation and places a catheter before general anesthesia. At the end of the surgical procedure, after an accurate neurovascular examination to exclude neurovascular lesions, a peripheral block is performed for pain relief

Surgical technique

- An examination under anesthesia is performed to assess the range of movement and ligamentous stability
- A tourniquet is applied, and after preparation of the skin with antiseptic solution and draping, the tourniquet is inflated to 250 mmHg
- The elbow joint landmarks, including the medial and lateral epicondyle, ulnar nerve, radial head, and posterior soft spot, are outlined with a skin marker. The soft spot posterolateral portals, supero-anteromedial and supero-anterolateral portals are also marked
- An 18-gauge needle is inserted into the elbow through the 'soft-spot' in the center of the triangle formed by the lateral epicondyle, the radial head, and the olecranon. The joint is distended by injecting 20 mL of normal saline, and a skin incision is made followed by blunt dissection through the soft tissues using an artery clip. The joint is distended by injecting 20 mL of normal saline that shifts the anterior neurovascular structures away. An incision is made in the skin followed by blunt dissection through the soft tissues using an artery clip. A trocar is introduced into this posterolateral portal
- Five portals, three posterior and two anterior, are always used with the skin incision, followed by blunt soft tissue disection
- Posterior compartment arthroscopy is performed first by introducing the arthroscope through the posterolateral portal. Joint distension is achieved by a pump set at 35–50 mmHg. A second portal is established 1.5 cm proximally
- These two portals allow the use of the scope and the shaver at the level of the posterior portion of the radial head and allow a good and complete view of the proximal radioulnar joint. The OCD lesion is identified and prepared to accept the osteochondral cylinder (**Figures 2.2–2.4**)



Figure 2.1 Patient positioning in the lateral decubitus position with the elbow exposed, and the hip in external rotation to allow knee arthroscopy for graft harvesting.

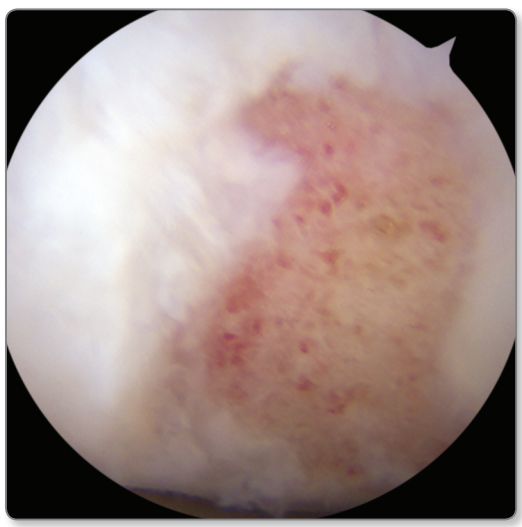

Figure 2.2 Arthroscopic view of osteochondritis dissecans of the capitellum.

JAYPEE BROTHERS

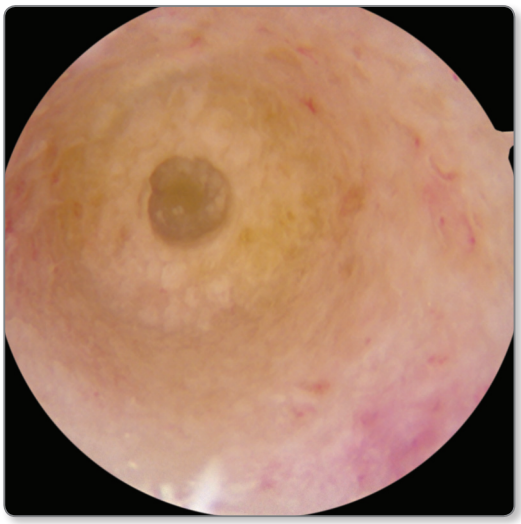

Figure 2.3 Arthroscopic view after drilling the area of osteochondritis dissecans.

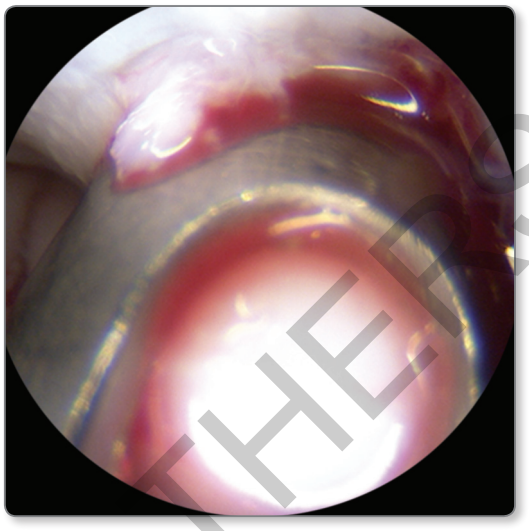

Figure 2.5 Using the mosaicplasty technique, the graft is inserted to restore the normal anatomy.



Figure 2.4 Osteochondral cylinder harvested from the lateral femoral trochlea.

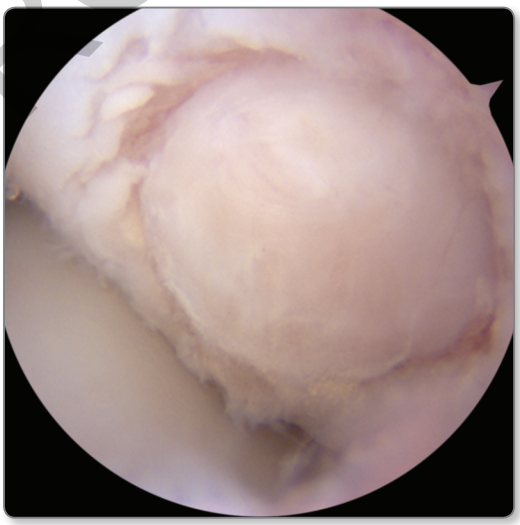

Figure 2.6 The graft is positioned on the lateral humeral condyle to fill the osteochondritis dissecans gap.

- A third posterior portal is placed in the olecranon fossa, close to the medial border of the triceps and oriented 2–3 cm proximal to the olecranon tip
- A mosaicplasty is performed with the oteochondral graft harvested from the lateral femoral trochlea of the contralateral knee arthroscopically
- The 6.5 mm cylindrical osteochondral graft taken from the lateral femoral trochlea is inserted at the prepared recipient site in the elbow lesion. A perpendicular insertion of the cylinder allows a complete coverage of the OCD area. A cylinder press-fit makes the graft stable (**Figures 2.5** and **2.6**)

JAYPEE BROTHERS

Possible perioperative complications

- Complications of elbow arthroscopy are the same as for other arthroscopic procedures, including infection, instrument breakage, iatrogenic scuffing of articular surfaces, tourniquet problems, and neurovascular injuries
- Neurological problems are the most commonly reported complications. Most of these are transient injuries

Closure

- After the procedure is completed, range of motion is assessed and the portals are closed in the standard fashion with 3-0 nylon or Prolene sutures
- A sterile compressive dressing is applied
- A long-arm splint is placed posteriorly, to immobilize the arm at 90°

Postoperative management

- Postoperative continuous passive movement commences at day 2, and passive exercises at day 4
- Patients resume normal activity at 4 months postoperatively
- MRI is performed 4 months postoperatively to confirm bone incorporation of the graft

Outpatient follow-up

- After discharge from hospital the patient returns for medication 7 days later
- At 15 days postoperatively all sutures are removed
- The patient has a follow-up appointment every month until new MRI is performed 4 months postoperatively. The patients is then reviewed every year for 2–3 years

Further reading

Baker CL, Romeo AA. Osteochondritis dissecans of the capitellum. Am J Sport Med 2010; 38:1917–1928.

Coates KE, Poehling G. Osteochondritis dissecans lesions and loose bodies of the elbow. In: Pederzini LA, Bain G, Safran MR (eds), Elbow Arthroscopy. Berlin: Springer-Verlag, 2013: 25–35.

Kandemir U, Fu FH, Mc Mahon P. Elbow injures. Curr Opin Rheumatol 2002; 14:160–167.

JAYPEE BROTHERS

EFOST

Surgical Techniques in Sports Medicine

Elbow Surgery

Surgical Techniques in Sports Medicine – the gold standard series of surgical manuals published with the European Federation of National Associations of Orthopaedic Sport Traumatology

Each book in the series provides authoritative, step-by-step guidance on how to perform key surgical procedures in a specific anatomical region. Written by teams of experienced practitioners in a clear, direct style, the *Surgical Techniques in Sports Medicine* series is the ideal companion for trainee sports trauma and orthopaedic surgeons seeking to develop their surgical skills.

Elbow Surgery gives practical advice on the surgical procedures used to correct injuries to the elbow. Each chapter clearly explains how to perform a single procedure in its entirety, from indications, preoperative assessment, preparation and surgical technique to closure and rehabilitation. The technique section forms the core of each chapter and describes every step of the procedure clearly and concisely. The chapters also describe potential complications, how best to avoid them and how to manage them when they occur.

- **Experienced surgeons share their knowledge of commonly performed techniques to help you improve your own skills**
- **Accessible design and concise text enable you to quickly find and assimilate the information you need before performing surgery**
- **Surgical photographs allow you to visualise techniques and follow each stage of the procedure**

Titles in the *Surgical Techniques in Sports Medicine* series:

Elbow Surgery
Foot and Ankle Surgery
Hand and Wrist Surgery
Hip and Pelvis Surgery
Knee Surgery Volume 1: Soft Tissue
Knee Surgery Volume 2: Bone and Cartilage
Muscles and Tendons
Shoulder Surgery Volume 1: Instability and Trauma
Shoulder Surgery Volume 2: Rotator Cuff and Shoulder Arthroplasty
Spine Surgery

JP medical publishers

www.jpmedpub.com

ISBN 978-1-909836-39-6