Surgical Techniques in Sports Medicine

Shoulder Surgery Volume 2: Rotator Cuff and Shoulder Arthroplasty

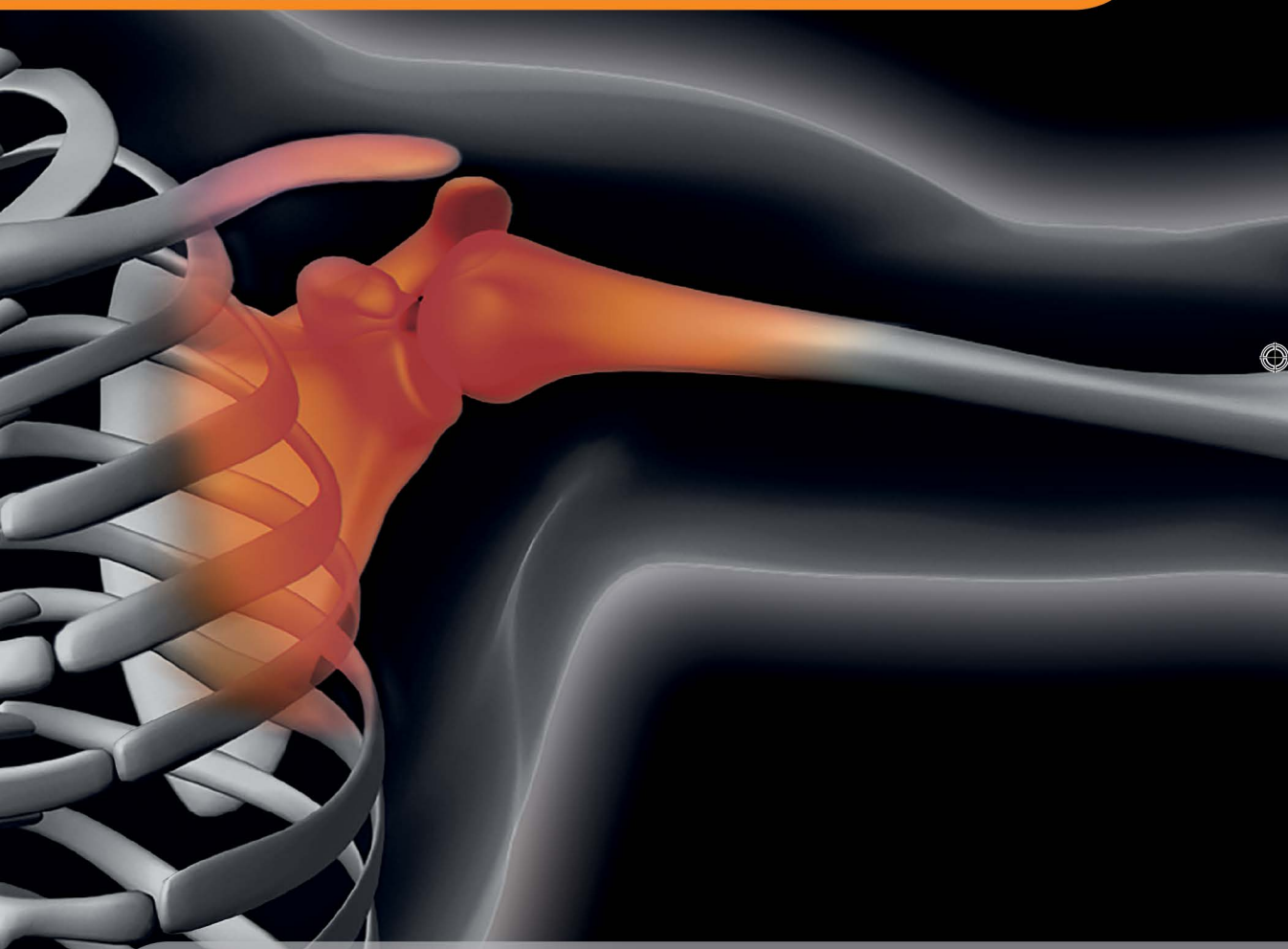

Pericles Papadopoulos • Achilleas Boutsiadis
Howard Cottam

Series Editors François M Kelberine • Nicola Maffulli

Contents

Foreword v
Contributors x

Chapter 1
Arthroscopic subacromial decompression 1
Kevin Andrieu

Chapter 2
Arthroscopic excision of the lateral end of the clavicle 7
George Alexiadis, Panagiotis P. Anastasopoulos, Emmanouil Fandridis

Chapter 3
Arthroscopic long head of biceps tendon tenodesis 15
Hubert Lenoir

Chapter 4
Arthroscopic in-situ repair of PASTA lesions 21
Emmanouil Antonogiannakis, Emmanouil Brilakis

Chapter 5
Arthroscopic subscapularis tear repair 29
Roderich Heikenfeld, Ioannis Gigis

Chapter 6
Single-row rotator cuff repair of postero-superior tears with suture anchors 35
Ioannis Gigis, Roderich Heikenfeld

Chapter 7
Arthroscopic double-row rotator cuff repair 41
Paul Brossard, Achilleas Boutsiadis, Johannes Barth

Chapter 8
Repair of massive rotator cuff tears 51
Emmanouil Antonogiannakis, Emmanouil Brilakis

Chapter 9
Latissimus dorsi transfer for irreparable massive rotator cuff tears: open technique 59
Panagiotis P. Anastasopoulos, George Alexiadis, Emmanouil Fandridis

Chapter 10
Arthroscopic release of the suprascapular nerve at the suprascapular notch 69
Lazaros Kostretzis, Pericles Papadopoulos, Ioannis Theodoroudis

Chapter 11
Arthroscopic treatment of calcifying tendinitis 75
Kevin Andrieu

Chapter 12
Pectoralis major rupture: open repair 83
Konstantinos Ditsios, Lazaros Kostretzis, Socratis Varitimidis

Chapter 13
Subacromial InSpace balloon interposition for massive irreparable rotator cuff tears 87
Vladimir Senekovič

Chapter 14
Superior capsular reconstruction with dermal allograft 93
Brad Gillman, Steve Burkhart

Chapter 15
Shoulder surface arthroplasty for arthritis 103
Gazi Huri, Rıza Mert Çetik, Onur Bilge, Egemen Turhan, Mahmut Nedim Doral

Chapter 16
Stemless shoulder arthroplasty for arthritis 111
Roderich Heikenfeld, Ioannis Gigis

Chapter 17
Anatomic total shoulder arthroplasty 117
Filippo Familiari, Olimpio Galasso, Giorgio Gasparini, Seyedali R. Ghasemi, Edward G. McFarland

Chapter 18
Reverse shoulder arthroplasty with glenosphere bony lateralization (BIO–RSA) 125
Lionel Neyton

Chapter 19
Reverse total shoulder arthroplasty (RTSA) for comminuted shoulder fractures 131
Omer Sunkar Bicer

Chapter 20
Patient-specific instrumentation for anatomic shoulder arthroplasty 137
Johannes Barth, Paul Brossard, Achilleas Boutsiadis

Chapter 21
Hemiarthroplasty for shoulder fractures 143
Giorgio Gasparini, Francesco La Camera, Filippo Familiari, Massimo De Benedetto, Roberto Castricini

2 Arthroscopic excision of the lateral end of the clavicle

Indications

Arthroscopic distal clavicle excision is indicated

- in patients with acromioclavicular joint pain that interferes with daily activities, work and participation in sports, and does not respond to conservative treatments. As a preemptive measure in cases with rotator cuff (RC) impingement secondary to a large distal clavicular osteophyte to avoid further injury

It has also been suggested as an adjunct procedure in patients operated on for RC tears to avoid mechanical abrasion.

Preoperative assessment

Clinical assessment

Signs demonstrating acromioclavicular joint pathology

- Patients commonly present with pain over the AC joint that may extend over to the trapezius and the deltoid
- The pain is most typically encountered in overhead activities and cross body adduction movements
- A close inspection may reveal a protruding AC joint secondary to swelling or due to osteophyte formation. Tenderness over the AC joint can be seen on palpation
- Crepitations can be felt over the AC joint during motion
- A positive cross-body adduction test is indicative of acromioclavicular pathology
- If uncertain, a diagnostic lidocaine injection can be used to confirm the source of pain
- Hawkins test can be positive, particularly when there is impingement from protruding inferior osteophytes
- Active compression test may elicit pain as it loads the AC joint
- Pain may also be evident in maximum internal rotation of the shoulder joint (back of the hand to the level of shoulder blade)

Further physical assessment

- A thorough shoulder evaluation should be performed to reveal any comorbidities such as RC tears, biceps tendon lesions or instability
- The stability of the AC joint should also be evaluated

Imaging assessment

Radiographs

- An AP view of the shoulder may demonstrate osteoarthritic changes with sclerosis and narrowing of the joint space. Osteolytic changes may also be apparent with bone resorption and the formation of cysts
- The orientation of the AC joint is individualized, evident in the AP view and should be evaluated preoperatively
- In cases where evaluation is not possible due to the superimposed scapula, a Zanca view can be used to assess the joint efficiently
- The axillary view can sufficiently evaluate the posterior AC joint space in patients with arthritis and the amount of anteroposterior displacement secondary to a previous injury
- Inferior osteophytes can be easily detected using a lateral Y-view

Magnetic resonance imaging (MRI)

- Magnetic resonance imaging is a valuable tool in assessing AC joint pathology as it can depict a variety of changes ranging from hypertrophic capsular changes to soft tissue effusions and bone edema. Nevertheless, such an examination has to be undertaken cautiously due to the fact it may detect abnormalities that are asymptomatic
- Bone oedema apparent on T2 weighted images is suggestive of arthritis in symptomatic patients

- Cuff abrasion from inferior AC osteophytes can also be evaluated along with associated pathologies

Timing for surgery

- Operative treatment may take place after failure of conservative management with persistence of symptoms
- It is reasonable to allow a period of 3–12 months of conservative management before scheduling the operation

Surgical preparation

Surgical equipment

A complete arthroscopy set including:

- Arthroscopic shaver (4–5 mm)
- Arthroscopic burr (5 mm)
- Electrocautery device
- An arthroscope with a 30° lens and additionally a 70° degrees lens can be useful
- Several 5–5.5 mm cannulas
- Two 22-gauge needles
- A shoulder traction device

Equipment positioning

- The arthroscopic tower should be positioned facing the surgeon on the opposite side of the operating table
- The remaining arthroscopic instrumentation may be placed on a table on top of the patient at the level of the pelvis
- The trolley containing surgical instruments may be positioned behind the surgeon

Patient positioning

- The patient should be placed in a lateral decubitus position with an axillary roll and a head support. The patient should be rolled posteriorly by 30° to allow 'parallel to the floor' glenoid orientation (**Figure 2.1a**)
- The traction device is used to position the arm in 30–40° of abduction and 15–20° of flexion. Usually, 4–6 kg of traction will suffice, depending on body type
- Alternatively, a beach chair position may be used if preferred by the surgeon

Anesthesia and chemoprophylaxis

- Routine antibiotic prophylaxis can be used and is especially advocated in concomitant rotator cuff repair with material implantation



Figure 2.1 (a) Patient in the lateral decubitus position (in 30° posterior inclination) with a traction device maintaining the arm in 30–40° abduction and 15–20° flexion. (b) Anatomic landmarks and portals marked on the skin: acromion, clavicle and clavicular axis, AC joint, coracoid process, anterosuperior portal, lateral portal, posterior portal.

- The operation can be performed under general anesthesia, while an interscalene block may minimize postoperative pain

Surgical technique

- Two basic approaches can be used for arthroscopic resection of the distal clavicle:
  - Direct (superior)
  - Indirect (subacromial)
- The direct approach can be used for patients with isolated AC pathology that does not expose the subacromial space, but has limited joint space for instrument insertion
- The indirect approach allows the evaluation of the glenohumeral joint and subacromial space, while preserving the strong posterosuperior capsule. In addition, it allows the use of conventional arthroscopic instrumentation in the AC joint and is therefore less time-consuming

Arthroscopic portals and initial evaluation

- Initially mark anatomical landmarks including the acromion, the coracoid, clavicle and AC joint (**Figure 2.1b**)

- Plan portal placement. Establish the posterior portal position by locating a soft spot 2–3 cm inferior and 1–2 cm medial to the posterolateral acromial corner depending on body type
- Make a 1 cm incision and use a blunt trocar to insert the arthroscope into the glenohumeral joint
- Create the anterior portal lateral to the coracoid process in line with the AC joint and place the outflow cannula
- Perform a complete diagnostic arthroscopy and evaluate the articular surface of the rotator cuff and biceps tendon, along with the glenohumeral joint structures
- Proceed to arthroscopy of the subacromial space with the camera inserted through the posterior portal while using the anterior portal as working cannula
- Create a lateral portal approximately 3–4 cm below the lateral acromial edge along the clavicular axis and provisionally insert a cannula

Subacromial space decompression

- Using a soft tissue shaver or an electrocautery on the lateral portal, proceed with bursectomy and remove any inflamed tissue to allow adequate visualization of the subacromial space (**Figure 2.2**)
- Debride the acromion in an anterior to posterior manner up to the AC joint line
- Use cautery to remove the fat pad underneath the AC joint capsule and avoid excessive bleeding (**Figure 2.3**)
- Rotate the arthroscope medially and use electrocautery to remove the inferior AC joint ligaments and capsule in order to outline the AC joint and its borders
- Cauterization of the periosteal vessels may help reduce bleeding, but avoid medial progression further from the tip of the clavicle
- If acromioplasty is indicated, use a burr to smooth and bevel the undersurface of the acromion. Note that removal of osteophytes will improve visualization especially in oblique orientation of the AC joint (**Figure 2.4**)

Distal clavicle excision

- Redirect the cannula of the anterior portal to the same plane as the AC joint. Applying manual pressure on the distal clavicle will verify the joint location
- If the joint orientation is uncertain, a spinal needle can be placed percutaneously through the joint
- If the portal is not in an adequately parallel position to the AC joint, a new portal can be

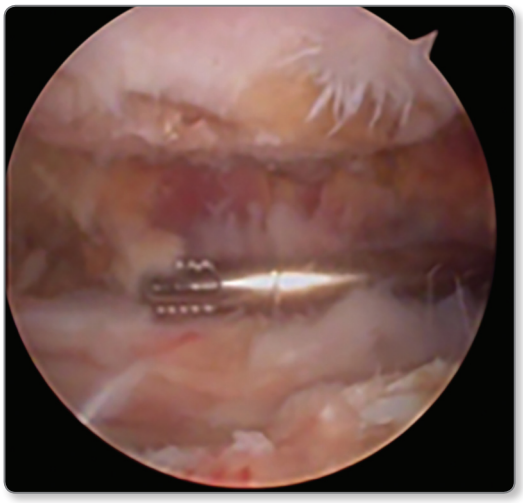

Figure 2.2 Subacromial decompression: debridement of the bursa and widening of the Subacromial space. Acromioplasty is performed in hooked acromion or protruding spurs.

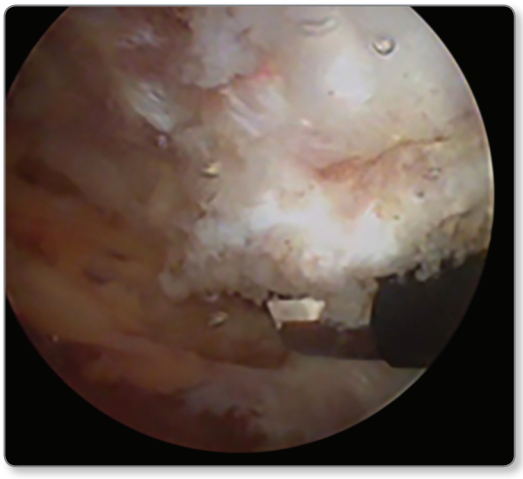

Figure 2.3 With the arthroscope rotated medially, electrocautery is used to debride the remaining inferior AC joint capsule in order to outline the distal clavicle and its borders.

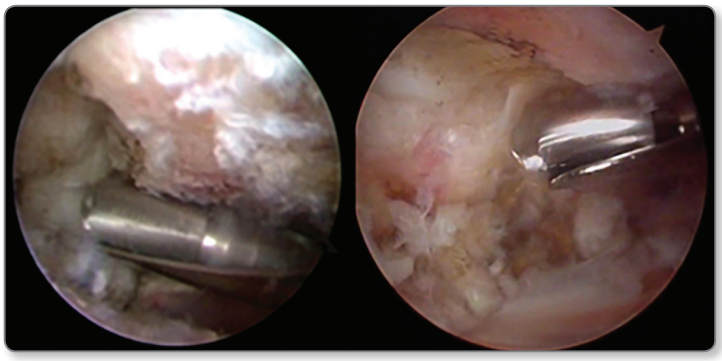

Figure 2.4 Removal of osteophytes from the medial acromial border.

established with a spinal needle in an outside-in manner

- Still using the posterior portal for the arthroscope, which is rotated upwards, insert a shaver or an electrocautery in the anterior portal (**Figure 2.5**)
- Debride any remaining soft tissue to better delineate the anterior and posterior borders to ensure adequate visualization of the distal clavicle (**Figure 2.6**)
- Try to avoid excessive medial debridement to prevent damage to the coracoclavicular ligaments
- Insert the burr in the anterior portal, and start the resection at the frontal aspect of the distal clavicle, progressing posteriorly and in a lateral-to-medial fashion (**Figure 2.7**)
- Start the resection inferiorly, progressing superiorly, with the burr in line with the plane of the AC joint in order to accomplish a symmetrical resection
- When removing the remaining superior clavicular bone, take care to avoid damage to the superior AC ligaments and capsule (**Figure 2.8**)
- Inserting the arthroscope directly into the joint and simultaneously pushing downwards the clavicle ensures adequate cortical bone resection while preserving the superior AC ligament
- At the posterior edge of the AC joint, rotating the scope medially allows visualization of the posterior and superior aspect of the distal clavicle
- A symmetric distal clavicle resection is performed with removal of up to 5 mm of bone from the clavicular side to ultimately achieve a 7–10 mm gap
- Alternatively, resection can be undertaken using the arthroscope through the lateral portal and the burr through the anterior portal. This position may require the use of a 70° scope
- Finally, evaluate the adequacy of resection (see below) (**Figures 2.9** and **2.10**)

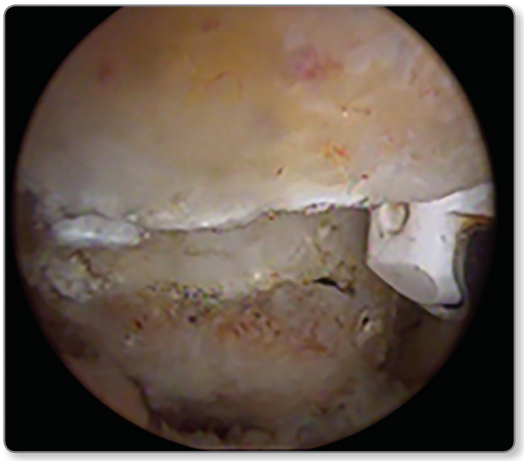

Figure 2.5 Debridement of the AC joint through the anterior portal (with the arthroscope in the posterior portal rotated upwards).

Resection evaluation

- The known diameter of a 4–5 mm burr can be used as a measurement tool to evaluate the gap (**Figure 2.11**)
- Alternatively, the diameter of a 5.5 mm cannula can be used
- Insert the arthroscope through the anterior portal to visualize and assess the amount of resection
- Additional resection assessment can be performed intraoperatively with fluoroscopy or radiographs



Figure 2.6 Rotating the arthroscope medially helps to accurately debride the posterior border of clavicle while protecting the posterior AC ligament.

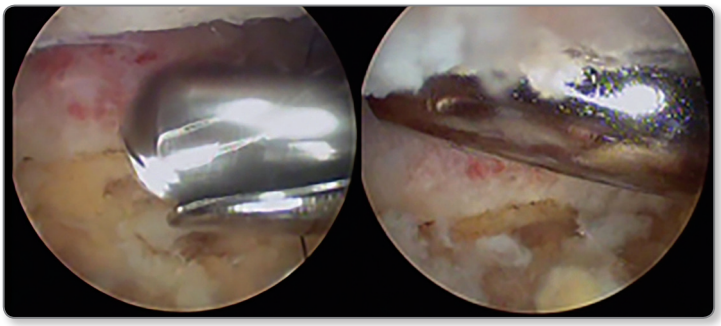

Figure 2.7 Insertion of a 5 mm burr in the anterior portal, and resection at the anterior aspect of the distal clavicle progressing posteriorly and in a lateral-to-medial fashion.

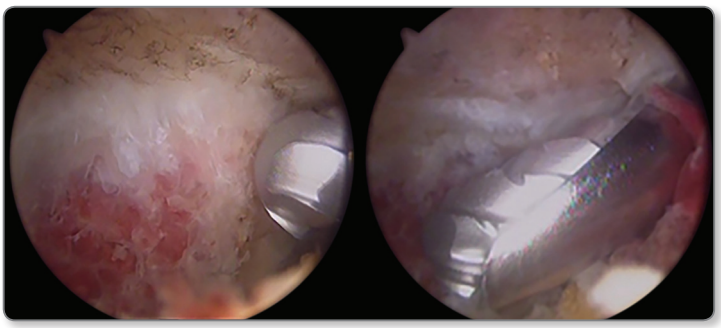

Figure 2.8 Directing the arthroscope superiorly and inserting it directly into the joint ensures adequate cortical bone resection while preserving the superior AC ligament.

Possible perioperative complications

- Violation injury to the superior and posterior ligaments: in major AC joint AP instability, fixation with sutures may be required
- Injury to the coracoclavicular ligaments: avoid progressing too far medially
- Rotator cuff injury: this can occur when resecting the inferior clavicle with a burr. Avoid damage to the underlying muscles by ensuring that the hood of the burr or shaver faces downwards when resecting
- Excessive bone resection more than 12 mm: stabilization in these cases may require fixation with osseous autograft

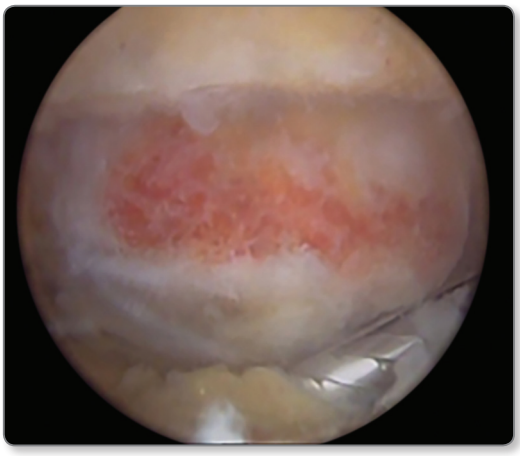

Figure 2.9 Final evaluation of the amount of resection with an arthroscope in the anterior portal.

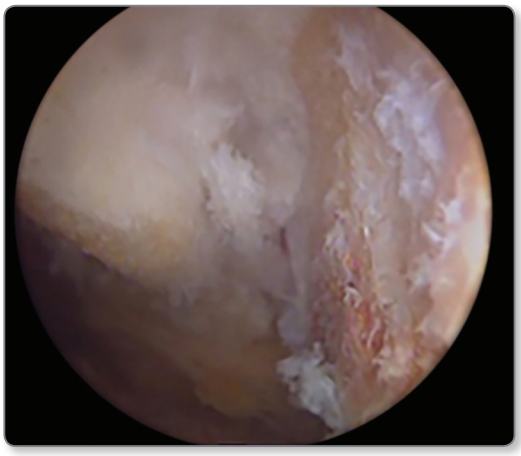

Figure 2.11 A burr can be used as a guide to determine the adequacy of distal clavicle excision.

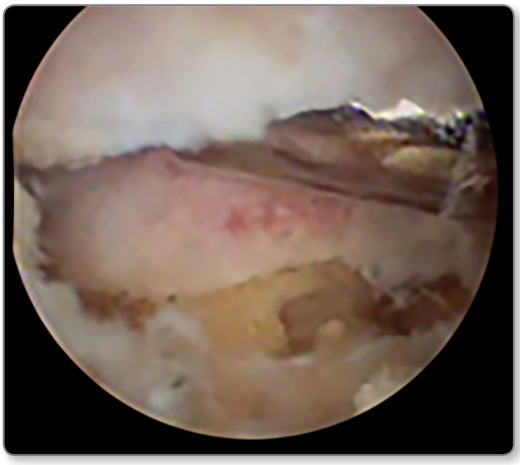

Figure 2.10 Final evaluation of distal clavicle resection with an arthroscope in the posterior portal.

- Excessive bleeding: use cautery to remove the fat pad underneath the AC joint capsule. Avoid progressing medially to the tip of the clavicle when debriding. Coracoacromial artery branches can be coagulated close to the anterior acromial edge
- Bleeding can be managed also by controlling the inflow/outflow to the joint, with the use of hypotensive anesthesia

Closure

- Drainage is not needed
- In cases where an interscalene block was not performed, the subacromial space can be injected with bupivacaine to reduce postoperative pain
- Portals should be closed in a standard fashion using 4-0 nylon sutures
- Simple dressings can be used, and the arm placed in a sling

Postoperative management

Post-operative regimen

- Medications: non-steroidal anti-inflammatory drugs and analgesics should be used to manage pain and edema
- Thromboprophylaxis should be used according to institutional guidelines
- A sling should be used to provide comfort for 5–10 days
- Assisted and active range of motion is allowed from the first postoperative day
- Active physiotherapy encompassing strengthening exercises can begin 3–4 weeks postoperatively
- A return to the previous level of activities and sports is advised when the shoulder is

painless and the patient has achieved a full range of motion approximately 12 weeks postoperatively
- A radiographic examination can be performed postoperatively to verify the amount of resection

Early postoperative complications

- Swelling / hematoma
- Shoulder stiffness
- Infection
- Heterotopic bone formation
- AC instability
- Persistent pain due to inadequate resection

Further reading

Kay SP, Dragoo JL, Lee R. Long-term results of arthroscopic resection of the distal clavicle with concomitant subacromial decompression. Arthroscopy 2003; 19:805–809.

Nuber GW, Bowen MK. Arthroscopic treatment of acromioclavicular joint injuries and results. Clin Sports Med 2003; 22:301–317.

Rabalais RD, McCarty E. Surgical treatment of symptomatic acromioclavicular joint problems: a systematic review. Clin Orthop Relat Res 2007; 455:30–37.

Tolin BS, Snyder SJ. Our technique for the arthroscopic Mumford procedure. Orthop Clin North Am 1993; 24:143-151.

EFOST **Surgical Techniques in Sports Medicine**

Shoulder Surgery Volume 2: Rotator Cuff and Shoulder Arthroplasty

Surgical Techniques in Sports Medicine – the gold standard series of surgical manuals published with the European Federation of National Associations of Orthopaedic Sports Traumatology

Each book in the series provides authoritative, step-by-step guidance on how to perform key surgical procedures in a specific anatomical region. Written by teams of experienced practitioners in a clear, direct style, the *Surgical Techniques in Sports Medicine* series is the ideal companion for trainee sports trauma and orthopaedic surgeons seeking to develop their surgical skills.

Shoulder Surgery Volume 2: Rotator Cuff and Shoulder Arthroplasty gives practical advice on surgical procedures used to correct injuries to the rotator cuff and shoulder. Each chapter clearly explains how to perform a single procedure in its entirety, from indications, preoperative assessment, preparation and surgical technique to closure and rehabilitation. The technique section forms the core of each chapter and describes every step of the procedure clearly and concisely. The chapters also describe potential complications, how best to avoid them and how to manage them when they occur.

- Experienced surgeons share their knowledge of commonly performed techniques to help you improve your own skills
- Accessible design and concise text enable you to quickly find and assimilate the information you need before performing surgery
- Surgical photographs allow you to visualise techniques and follow each stage of the procedure

Titles in the *Surgical Techniques in Sports Medicine* series:

Elbow Surgery
Foot and Ankle Surgery
Hand and Wrist Surgery
Hip and Pelvis Surgery
Knee Surgery Volume 1: Soft Tissue
Knee Surgery Volume 2: Bone and Cartilage
Muscles and Tendons
Shoulder Surgery Volume 1: Instability and Trauma
Shoulder Surgery Volume 2: Rotator Cuff and Shoulder Arthroplasty
Spine Surgery

JP medical publishers

www.jpmedpub.com

ISBN 978-1-909836-56-3