Neuroimaging

Rory Piper

Foreword by Robin Sellar

pocket tutor



Contents

Foreword *v*
Preface *vii*
Dedications and acknowledgements *xiii*

Chapter 1 First principles
1.1 Neuroanatomy 1
1.2 Radiological terminology 20
1.3 Imaging modalities 23
1.4 Patient safety 30

Chapter 2 Interpreting normal images
2.1 Terminology 33
2.2 Bone: the skull 39
2.3 Bone: the spine 42
2.4 The meninges 46
2.5 The brain 48
2.6 The spinal cord 51
2.7 The vasculature 52
2.8 Cerebrospinal fluid 57

Chapter 3 Interpreting abnormal images
3.1 Fractures 61
3.2 Intracranial haemorrhage 61
3.3 Ischaemia 62
3.4 Cerebral oedema 62
3.5 Hydrocephalus 63
3.6 Increased intracranial pressure 66
3.7 Abnormal presence of air 69
3.8 Features of ageing 70
3.9 Incidental findings 71
3.10 Artefact 72

Chapter 4 Trauma
4.1 Clinical scenario 75
4.2 Approach to the trauma patient 77

4.3 Skull fracture 80
4.4 Extradural haematoma 83
4.5 Subdural haematoma 85
4.6 Cerebral contusion 89
4.7 Diffuse axonal injury 91

Chapter 5 Cerebrovascular disease
5.1 Clinical scenario 95
5.2 Ischaemic stroke and transient ischaemic attack 97
5.3 Haemorrhagic stroke: introduction 103
5.4 Parenchymal brain haemorrhage 104
5.5 Clinical scenario 105
5.6 Subarachnoid haemorrhage 107
5.7 Arteriovenous malformation 112
5.8 Carotid and vertebral artery dissection 115
5.9 Dural venous sinus thrombosis 117

Chapter 6 Inflammatory disorders
6.1 Multiple sclerosis 121
6.2 Sarcoidosis 124

Chapter 7 Infections
7.1 Clinical scenario 127
7.2 Cerebral abscess 130
7.3 Subdural and extradural empyema 132
7.4 Spinal epidural abscess 133

Chapter 8 Intracranial tumours
8.1 Clinical scenario 137
8.2 Approach to the patient with a brain tumour 140
8.3 Glioma 142
8.4 Meningioma 146
8.5 Brain metastases 148
8.6 Pituitary adenoma 150
8.7 Medulloblastoma 152
8.8 Vestibular schwannoma 152
8.9 Image-guided neurosurgery 154

Chapter 9 Spinal conditions
9.1 Clinical scenario 157
9.2 Approach to the patient with spinal trauma 159
9.3 Spinal fractures 160
9.4 Degenerative spinal conditions 167
9.5 Spinal tumours 169

Index *175*

chapter 1

First principles

An understanding of neuroimaging rests on knowledge of the fundamental principles of:

- neuroanatomy (the structure of the normal brain)
- neuroimaging terminology (how images are described)
- neuroimaging modalities (how images are acquired)
- safety in neuroimaging

1.1 Neuroanatomy

The nervous system is divided into:

- A central nervous system and
- A peripheral nervous system

This book focuses on the central nervous system, which comprises the brain and spinal cord.

The scalp

The scalp is the soft tissue covering the skull vault. A mnemonic for the five layers that make up the scalp, from superficial to deep, is SCALP:

- **S**kin
- **C**onnective tissue
- **A**poneurosis (the galea aponeurotica)
- **L**oose areolar connective tissue
- **P**eriosteum (pericranium)

The skull

The skull is divided into:

- The neurocranium, i.e. the part encasing the brain, and
- The viscerocranium, i.e. the facial skeleton

The neurocranium

The neurocranium forms the cranial cavity, the space occupied by the brain.

JAYPEE BROTHERS

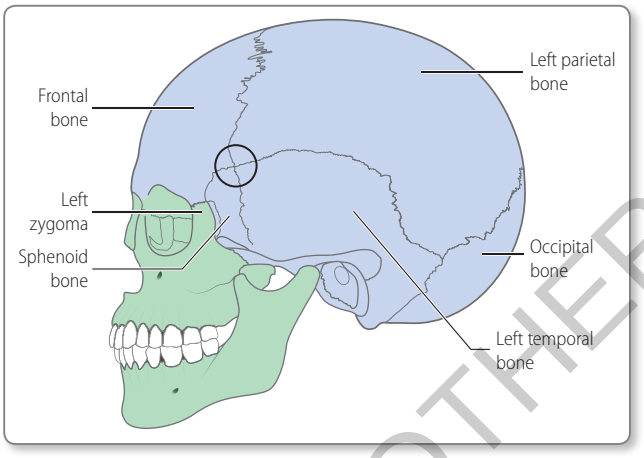

Figure 1.1 Left lateral view of the skull. The neurocranium is shown in blue, and the splanchnocranium in green. The pterion (circled) is the region where the frontal, parietal, temporal and sphenoid bones meet.

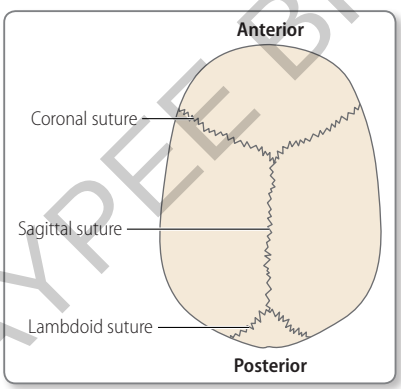

Figure 1.2 Superior view of the coronal, sagittal and lambdoid sutures.

JAYPEE BROTHERS

The skull vault The skull vault (also called the calvaria) comprises the frontal, parietal (left and right), occipital, temporal (left and right), sphenoid and ethmoid bones (**Figure 1.1**). In the fully developed skull, these bones are strongly held together

by fibrous joints called sutures, such as the sagittal, coronal and lambdoid sutures on the superior aspect (**Figure 1.2**).

The skull base

This anatomically complex structure forms the floor of the cranial cavity. It has many foramina, through which the spinal cord, cranial nerves, blood vessels and other structures pass in or out of the cavity. The largest of the foramina is the foramen magnum.

The skull base is divided into the three cranial fossae: anterior, middle and posterior (**Figure 1.3**). The small hypophyseal fossa, located in the middle fossa, holds the pituitary gland.

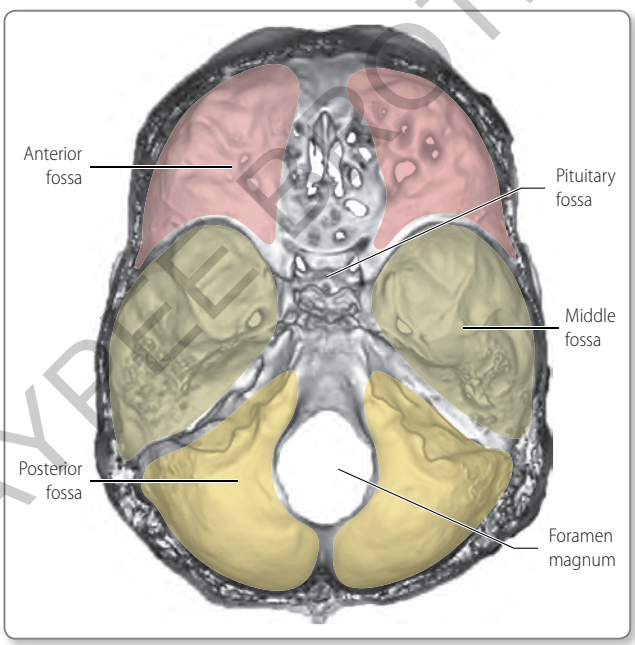

Figure 1.3 Superior view of the anterior, middle and posterior fossae of the skull base.

JAYPEE BROTHERS

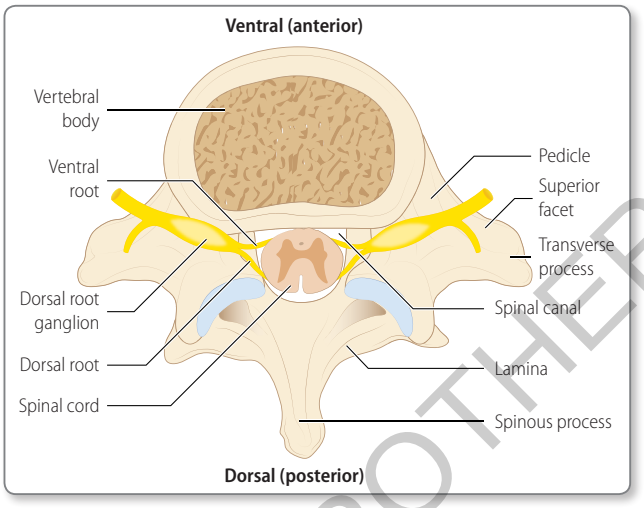

Figure 1.4 A typical vertebra and its relationship to the spinal cord and nerve roots.

The spine

The spine protects the spinal cord. It is a column of individual bones called vertebrae; these differ in structure according to their level but have several key features in common, as shown in **Figure 1.4**. From superior to inferior, the vertebrae are (**Figure 1.5**):

- Seven cervical (C1 to C7)
- Twelve thoracic (T1 to T12)
- Five lumbar (L1 to L5)
- Five sacral (S1 to S5)
- Four coccygeal (Co1 to Co4; these are fused together)

The vertebral bodies are separated by intervertebral discs. Each disc consists of an inner nucleus pulposus and an outer annulus fibrosis.

The cervical spine has several distinct features (**Figure 1.6**), including:

- The first cervical vertebra (C1) is called the atlas; it forms a joint with the occipital condyles (the atlanto-occipital joint)

JAYPEE BROTHERS

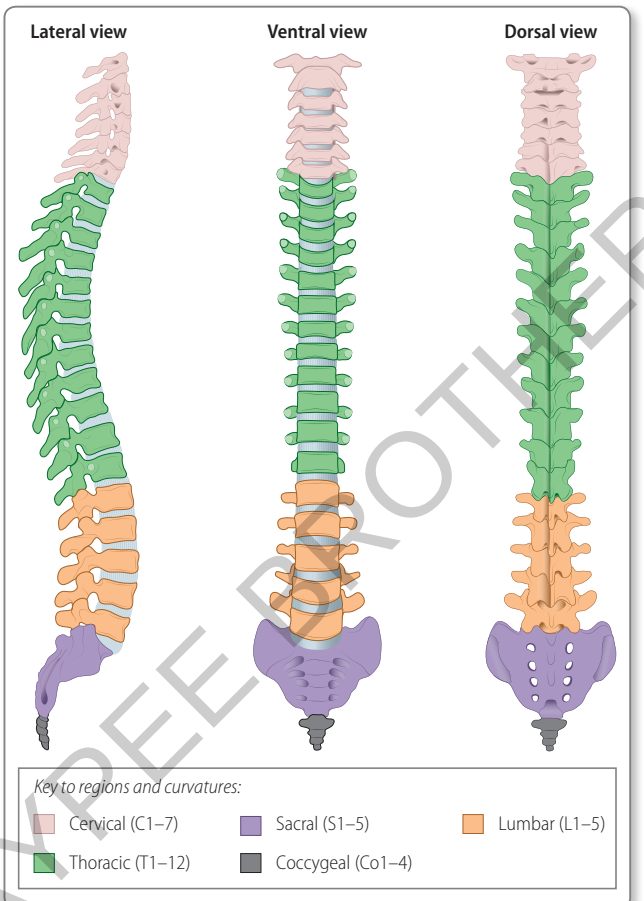

Figure 1.5 Lateral, ventral and dorsal views of the spine, showing the cervical, thoracic, lumbar, sacral and coccygeal divisions.

- The second cervical vertebra (C2) is called the axis; its odontoid process forms a pivot joint with the atlas to allow rotation of the head
- All but the seventh vertebral body of the cervical spine have transverse foramina, which transmit the vertebral arteries

JAYPEE BROTHERS

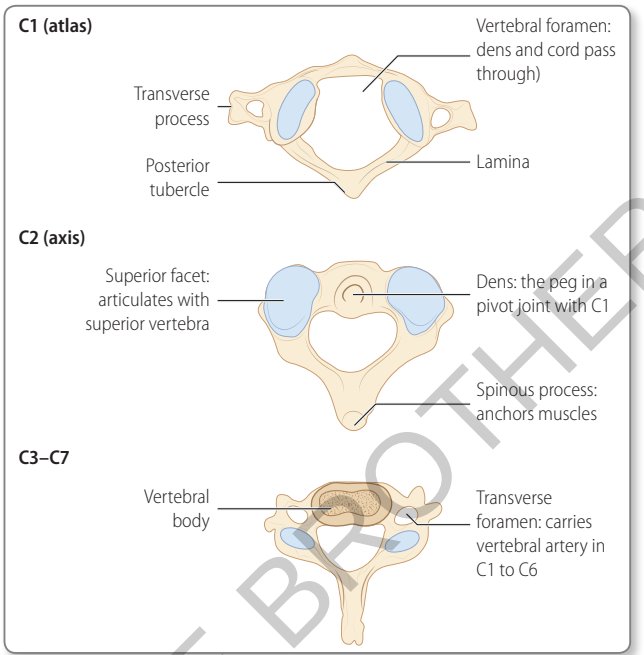

Figure 1.6 Features of the cervical vertebrae.

The meninges

The brain is separated from the skull by three membranous layers called the meninges: the dura, arachnoid and pia mater (**Figure 1.7**). The meninges extend down the spinal canal to encompass the spinal cord, cauda equina and nerve roots. The dura and arachnoid mater terminates at S2, but an extension of the pia mater, the filum terminale, continues to the coccyx.

Dura mater

The dura mater is the thick, outermost layer of the meninges, and itself has an outer (periosteal) and an inner (meningeal) layer. The outer layer of the dura mater is largely adherent to

JAYPEE BROTHERS

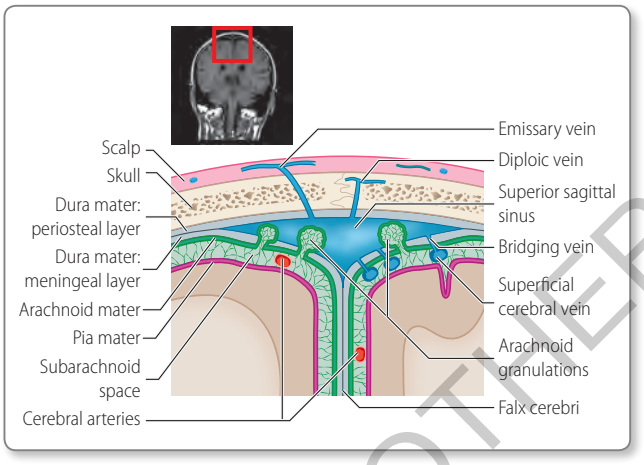

Figure 1.7 The scalp, skull and meninges.

the skull. The inner layer deviates deeply at two main locations to form the falx cerebri (within the longitudinal fissure, which separates the right and left cerebral hemispheres) and the tentorium cerebelli (which separates the cerebrum from the cerebellum). The dural venous sinuses are the channels formed between the separation of the two dural layers.

Arachnoid mater

Deep to the dura mater is the arachnoid mater. The arachnoid mater is in contact with the dura mater but separated from the pia mater by the subarachnoid space. Within the subarachnoid space are cerebral arteries, and veins that drain into the dural venous sinuses via bridging veins. Large subarachnoid spaces are termed cisterns.

Pia mater

The pia mater is the innermost meningeal layer. It is in contact with the surface of the brain.

JAYPEE BROTHERS

The cerebrum

The cerebrum is divided into two hemispheres, left and right, separated by the longitudinal (or interhemispheric) fissure. The hemispheres are subdivided into lobes: frontal, temporal, parietal and occipital (**Figure 1.8**). Each lobe has specific functions (**Table 1.1**).

Guiding principle

The functions of the left and right hemispheres are not identical. Areas responsible for language processing (Wernicke's area and Broca's area) are typically located within the dominant hemisphere. This is the left hemisphere in most people, regardless of whether they are right- or left-handed. Therefore, left hemisphere lesions involving the language areas (e.g. stroke or tumour) cause language deficits.

Cerebral cortex

The cerebral cortex is the superficial layer of the brain. It has a convoluted structure characterised by gyri and sulci. Two of the most prominent sulci are the central sulcus (or Rolandic fissure), which divides the frontal and parietal lobes, and the lateral sulcus

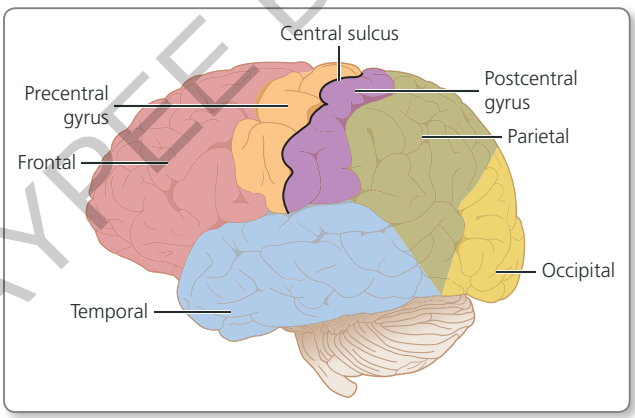

Figure 1.8 Lobes of the brain. The postcentral gyrus (somatosensory region) is part of the parietal lobe. The precentral gyrus (primary motor cortex) is part of the frontal lobe.

JAYPEE BROTHERS

Lobe	Function(s)
Frontal	Voluntary movement (primary motor cortex)
	Language* (Broca's area)
	Emotion and personality
	Intelligence and problem-solving
	Attention
Temporal	Language* (Wernicke's area)
	Hearing (auditory area)
	Memory
Parietal	Sensation (somatosensory cortex)
	Spatial orientation †
	Processing and integration of sensory information
Occipital	Vision

*Functions of the dominant hemisphere.
†Functions of the non-dominant hemisphere.

Table 1.1 Key functions of the cerebrum according to lobe

(or Sylvian fissure), which separates the frontal and temporal lobes. The cortex is made up of grey matter, which consists of neuronal cell bodies.

Subcortical structures

White matter is located within the inner part of the cerebrum. It is composed of neuronal axons surrounded by myelin (accounting for the white appearance). Arranged in bundles, these axons form tracts connecting regions of the brain and spinal cord. The corpus callosum is a large white matter tract that connects the two hemispheres of the cerebrum.

Other important subcortical structures include (**Figure 1.9**):

The basal ganglia This is a group of interconnected subcortical nuclei including the subthalamic nucleus, putamen, caudate nucleus and globus pallidus. They act as a circuit to help fine-tune voluntary movements.

JAYPEE BROTHERS

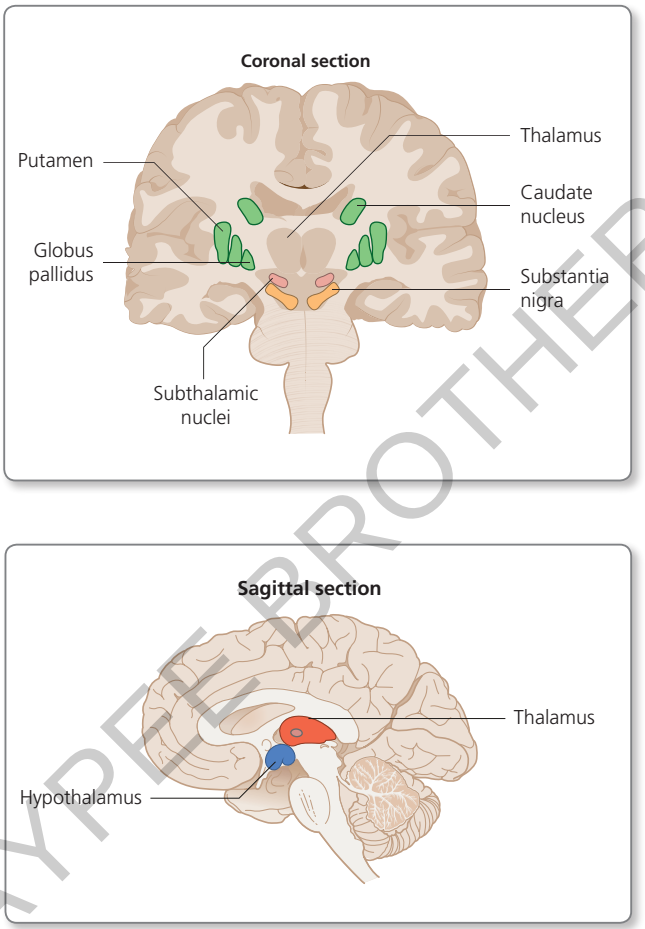

Figure 1.9 Coronal and sagittal sections through the deep structures of the brain.

JAYPEE BROTHERS

The internal capsule This is a pathway for the white matter tracts ascending to or descending from the cerebral cortex.

The thalamus The thalamus relays motor and sensory information to and from the cerebral cortex. It also has a key role in the regulation of consciousness.

The hypothalamus This is located inferior to the thalamus and superior to the pituitary gland. Its functions include mediation of emotional responses and maintenance of homeostasis (e.g. body temperature and blood pressure). The hypothalamus influences the autonomic nervous system and the release of hormones from the pituitary gland.

Clinical insight

The proximity of the pituitary gland to the optic chiasm means that a space-occupying lesion of the pituitary gland may cause bitemporal hemianopia (loss of peripheral vision).

The pituitary gland

Connected to the hypothalamus by the stalk-like infundibulum, the pituitary gland lies inferior to the optic chiasm (the point at which fibres from the left and right optic nerves cross) (**Figure 1.10**), and sits within the hypophyseal fossa in the middle cranial fossa. It is divided into an anterior and a posterior lobe. As the so-called 'master gland', it controls the secretion of hormones from other endocrine glands.

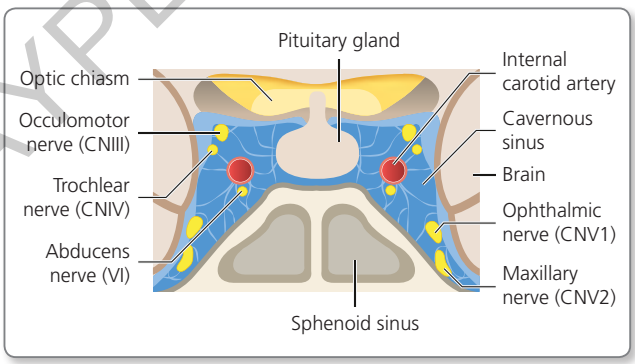

Figure 1.10 Coronal section of the pituitary gland and surrounding anatomy.

JAYPEE BROTHERS

The cerebellum

The cerebellum lies in the posterior fossa. It is connected to the brainstem by the superior, middle and inferior cerebellar peduncles.

It has a complex array of folds, called folia, and is divided into the following (**Figure 1.11**):

- The left and right hemispheres, divided by the midline vermis
- The anterior and posterior lobes, divided by the primary fissure

The cerebellum coordinates movement.

The brainstem

The brainstem is divided into three structures (**Figure 1.12**). From superior to inferior, these are the:

- Midbrain
- Pons
- Medulla

The brainstem is responsible for regulation several vital functions, including:

- the respiratory and cardiovascular systems
- the sleep–wake cycle
- arousal and consciousness
- bowel and bladder control
- nausea and vomiting
- pain

It is also where the nuclei of the cranial nerves (III to XII) are located. Running through the brainstem are white matter tracts made up of the axons of motor and sensory pathways, which enable communication between the brain and the spinal cord.

JAYPEE BROTHERS

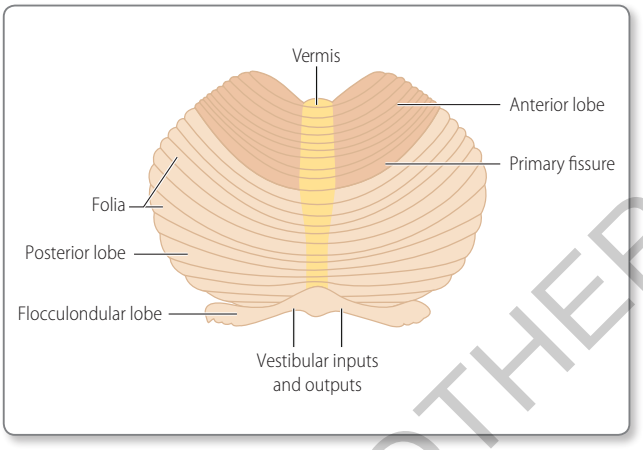

Figure 1.11 The cerebellum: anterior lobe, posterior lobe, vermis, primary fissure, folia.

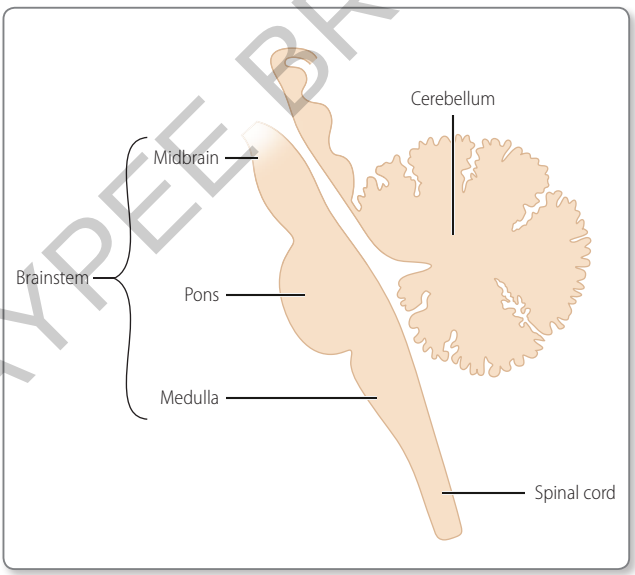

Figure 1.12 The brainstem.

JAYPEE BROTHERS

Clinical insight

Most of the fibres of the corticospinal tract decussate (cross from one side of the midline to the other) at the medullary pyramids. This explains why a lesion (e.g. a stroke or tumour) involving the right corticospinal tract above the medulla causes left-sided weakness.

The spinal cord

The spinal cord is contained within the spinal canal, the space formed by the vertebral foramina of successive vertebrae. It extends from the brainstem via the foramen magnum in the skull base, to the conus medullaris at about the level of L1 (normal range, T12 to L2). From the conus medullaris, the lumbar and sacral nerve roots descend

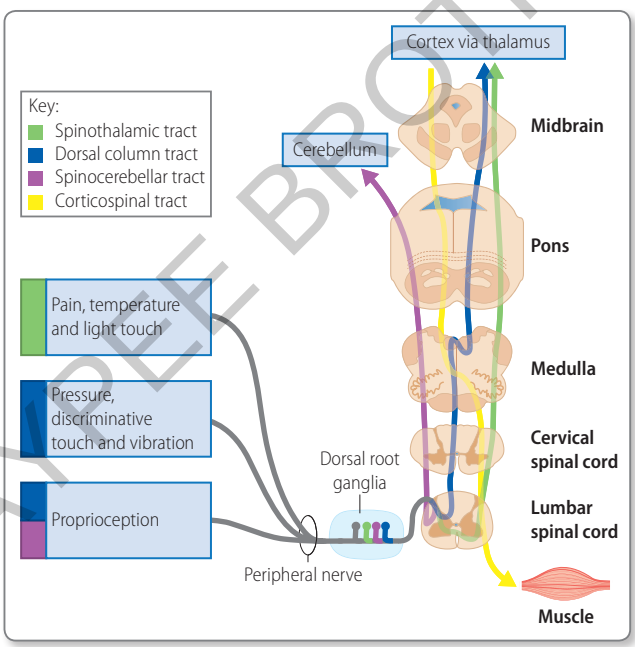

Figure 1.13 The ascending (sensory) and descending (motor) spinal tracts.

JAYPEE BROTHERS

pocket tutor

Neuroimaging

pocket tutor Neuroimaging is the ideal companion for medical students, junior doctors and anyone seeking an accessible and practical guide to imaging the nervous system.

- ✔ **First principles chapter** covers neuroanatomy and the principles of radiological imaging
- ✔ Chapters on the **radiological appearance of normal and abnormal anatomy** show how to correctly identify pathology
- ✔ **High quality images and detailed descriptions** help you correlate key anatomical structures and pathology with clinical findings

pocket tutor is the best-selling series that reinforces knowledge fast: in practice, in tutorials, before exams. Reminders of key underlying principles, insightful clinical scenarios and an accessible format mean you can trust **pocket tutor** to provide you with the right answer, whenever you need it.

JP medical publishers

www.jpmedpub.com

ISBN 978-1-909836-57-0

9 781909 836570