Second Edition

# Neurological Examination

John Goodfellow

Foreword by Martin R Turner

pocket tutor



# Contents


*Foreword* *v*
*Preface* *vii*
*Acknowledgements* *xii*

**Chapter 1 Clinical skills in neurology**
1.1 The consultation 1
1.2 The neurological history 1
1.3 The neurological examination 4
1.4 Case summary and synthesis 5
1.5 Describing and referring cases 6
1.6 The junior doctor's neurology toolkit 7
1.7 Ethicolegal considerations 8

**Chapter 2 Gait and general inspection**
2.1 Anatomy and physiology review 9
2.2 Clinical features and pathophysiology 14
2.3 General inspection 19
2.4 Abnormal posture and movements 21
2.5 Assessing gait 25
2.6 System summary 28

**Chapter 3 Head and neck (cranial nerves)**
3.1 Objectives 29
3.2 Anatomy and physiology review 29
3.3 Clinical features and pathophysiology 41
3.4 General observations 54
3.5 The nose (CN I) 56
3.6 The eyes: part 1 (CN II and III) - pupils, acuity, fields and fundi 57
3.7 The eyes: part 2 (CN III, IV and VI) 65
3.8 The face (CN V, VII) 68
3.9 The ears (CN VIII) 74
3.10 The mouth (CN IX, X, XII) 78
3.11 The neck (CN XI) 80
3.12 System summary 82

**Chapter 4 Upper limb**
4.1 Objectives 83
4.2 Anatomy and physiology review 83
4.3 Clinical features and pathophysiology 92
4.4 General observations 95
4.5 Tone 96
4.6 Power 97
4.7 Reflexes 104
4.8 Co-ordination 106
4.9 Sensation 107
4.10 System summary 112

**Chapter 5 Lower limb**
5.1 Objectives 113
5.2 Anatomy and physiology review 113
5.3 Clinical features and pathophysiology 117
5.4 General observations 119
5.5 Tone 120
5.6 Power 120
5.7 Reflexes 125
5.8 Co-ordination 129
5.9 Sensation 130
5.10 System summary 136

**Chapter 6 Cerebellum**
6.1 Objectives 137
6.2 Anatomy and physiology review 137
6.3 Clinical features and pathophysiology 139
6.4 General observations 140
6.5 VANISHD 141
6.6 System summary 147

**Chapter 7 Higher cortical function**
7.1 Objectives 149
7.2 Anatomy and physiology review 150
7.3 Clinical features and pathophysiology 152
7.4 Bedside testing of cognitive domains 155
7.5 System summary 165

**Chapter 8 Autonomic nervous system**
8.1 Objectives 167
8.2 Anatomy and physiology review 167
8.3 Clinical features and pathophysiology 170
8.4 History 172
8.5 Bedside examination and tests 172
8.6 System summary 175

**Chapter 9 Examining the stroke patient**
9.1 Objectives 177
9.2 Anatomy and physiology review 177
9.3 Clinical features and pathophysiology 179
9.4 Stroke: history 183
9.5 Stroke: neurological examination 186
9.6 Stroke: general examination 187
9.7 Acute stroke treatments 189
9.8 System summary 192

**Chapter 10 Examining the coma patient**
10.1 Objectives 193
10.2 Anatomy and physiology review 193
10.3 Clinical features and pathophysiology 193
10.4 General observations 198
10.5 Eyes and reflexes 200
10.6 System summary 204

**Chapter 11 The neurological screening examination in 4 minutes**
11.1 Objectives 205
11.2 Sequence 205

**Chapter 12 The neurological examination in undergraduate exams**
12.1 Objectives 207
12.2 Common conditions in examinations 207
12.3 Examination instructions 208
12.4 Questions and answers 208

Further reading 211

*Index* *213*

chapter 3

# Head and neck (cranial nerves)

## 3.1 Objectives

Examination of the cranial nerves is a vital skill for students and junior doctors. The principles are identical to any other portion of the neurological examination but many students and physicians find this part daunting. It need not be so.

This chapter is on the 'head and neck' rather than on 'cranial nerves' to remind the clinician that the neurological assessment includes not only the nerves themselves but also the whole neuroaxis from the muscle or sensory endings, neuromuscular junction, peripheral cranial nerve fibres and brainstem nuclei to the higher centres.

As with other parts of the examination, the key principles are to:

- detect abnormal signs
- localise any lesions
- identify potential pathogenic processes

## 3.2 Anatomy and physiology review

Relevant anatomy, physiology, connections, functions and arterial supply of the 12 cranial nerves are summarised in **Tables 3.1–3.3**. The nerves exit the skull through the exit formina (**Figure 3.1**); the location of their nuclei in the brainstem are shown in **Figure 3.2**.

### CN I: the olfactory nerve

The olfactory nerve:

- is a purely sensory nerve
- runs in the olfactory groove
- is prone to damage from head injury

### CN II: the optic nerve

Testing the visual field produces characteristic abnormal findings depending on the location of the lesion (**Figure 3.3**).

JAYPEE BROTHERS

| Cranial nerve | Motor innervation | Sensory input | Autonomic component | Brainstem nuclei |
|---|---|---|---|---|
| I Olfactory | – | Bipolar sensory cells of olfactory epithelium | – | – |
| II Optic | – | Axons from retinal ganglion cells | – | Thalamus Midbrain |
| III Oculomotor | Levator palpabrae superioris Superior rectus Medial rectus Inferior rectus Inferior oblique | – | Preganglionic para-sympathetic fibres to sphincter of iris (constriction and acco-mmodation) | Parasym-pathetic Edinger–Westphal nucleus Motor Oculomotor nucleus |
| IV Trochlear | Superior oblique | – | – | Pons |
| VI Abducens | Lateral rectus | – | – | Junction of pons and medulla |

**Table 3.1** Cranial nerve supply to the nose and eyes

The optic nerve:

- is a purely sensory nerve originating as retinal ganglion cells
- passes through the optic canal (**Figure 3.1**)
- contributes the afferent limb of the pupillary reflex (**Figure 3.4**)

## CN III, IV and VI: the eye muscle nerves

CN III, IV and VI:

- control eye movements (**Figure 3.5**)
- IV and VI are purely motor

JAYPEE BROTHERS

| Cranial nerve | Motor innervation | Sensory input | Autonomic component | Brainstem nuclei |
|---|---|---|---|---|
| V Trigeminal | Muscles of mastication; tensor tympani | Mucous membranes of mouth, nose and paranasal air sinuses and skin of head and face | Ciliary, pterygopalatine, otic and submandibular ganglia | Motor nuclei in pons Sensory in pons, brainstem and spinal cord dorsal horn nuclei |
| VII Facial | Muscles of facial expression Stapedius muscle of middle ear | Taste fibres from anterior 2/3 of the tongue Sensory fibres from external ear | Parasympathetic secretomotor fibres to sublingual and submandibular salivary glands, lacrimal gland and nasal mucosa | Motor in pons Sensory in medulla |
| VIII Vestibulocochlear | – | Bipolar spiral ganglion cells Vestibular fibres | – | Cochlear nuclei in medulla Vestibular nuclei in medulla and pons |

**Table 3.2** Cranial nerve supply to the face and ears

- III is motor with a parasympathetic component of CN III mediating the efferent limb of the pupillary reflex via the ciliary ganglion (**Figure 3.4**)
- III innervates all eye muscles (inferior oblique, inferior rectus, superior rectus, medial rectus and levator palpabrae superioris) except superior oblique (IV) and lateral rectus (VI)
- pass through the cavernous sinus and the superior orbital fissure and can be involved in a lesion in either (**Figure 3.1**)

JAYPEE BROTHERS

| Cranial nerve | Motor innervation | Sensory input | Autonomic component | Brainstem nuclei |
|---|---|---|---|---|
| IX Glosso-pharyngeal | Stylo-pharyngeus muscle | Pharynx and posterior 1/3 of the tongue | Para-sympathetic secretomotor fibres to the parotid gland | Motor in medulla Para-sympathetic in pons |
| X Vagus | Muscles of larynx, pharynx and palate involved in speech | Larynx Portion of external auditory meatus Viscerosensory from gastrointestinal tract, lungs, heart and aortic arch | Para-sympathetic innervation of bronchi, bronchioles, atria of heart, liver, gallbladder, pancreas, oesophagus, stomach, gut (to colonic flexure) and kidneys | Motor, sensory and para-sympathetic in medulla |
| XI Accessory | Cranial roots: muscles of palate, larynx and pharynx Spinal roots: trapezius and sternocleido-mastoid muscles | – | – | Cranial root in medulla Spinal root in spinal cord |
| XII Hypoglossal | Muscles of the tongue | – | – | Medulla |

**Table 3.3** The lower cranial nerves

JAYPEE BROTHERS

## CN V: the trigeminal nerve

The trigeminal nerve is:

- a large nerve with ophthalmic ($V_1$), maxillary ($V_2$) and mandibular divisions ($V_3$)

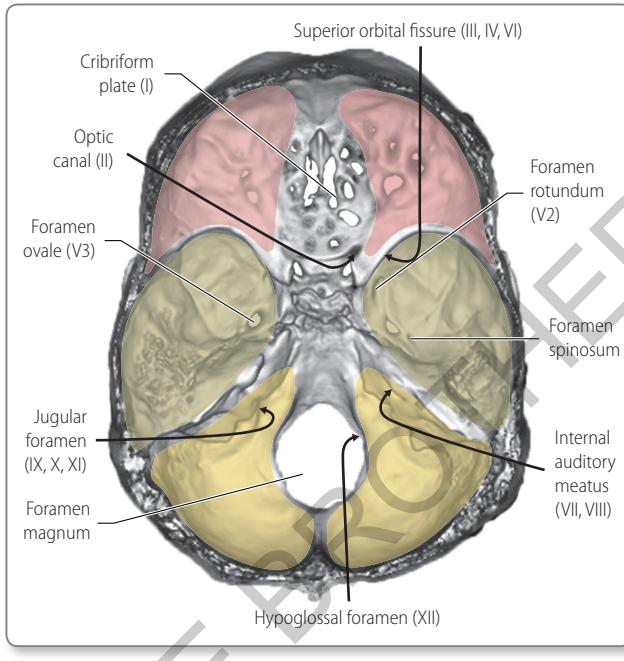


**Figure 3.1** The skull foramina.

- mixed motor, sensory and autonomic (**Figure 3.6**)
- Each division courses to a different area of the head and face (**Figure 3.6**):
- $V_1$ passes through the cavernous sinus and carries sensation from the forehead and upper eyelid and nose
- $V_2$ passes through the foramen rotundum and carries sensation from around the cheekbones and from the sinus and nose
- $V_3$ passes through the infratemporal fossa and carries sensation from the lower jaw and innervates the muscles of mastication

JAYPEE BROTHERS

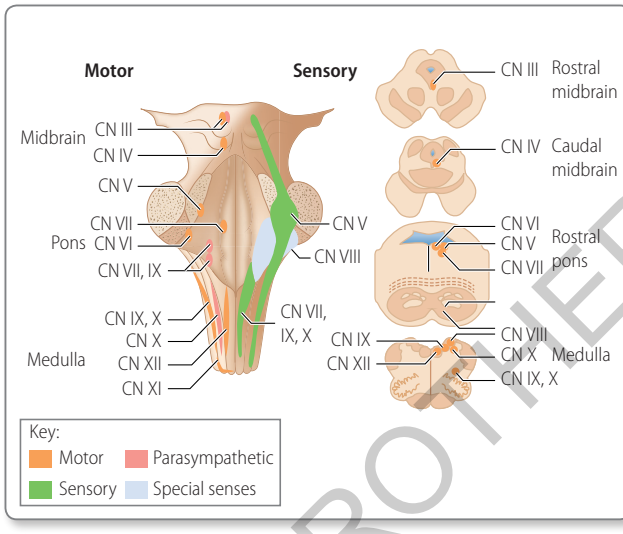


**Figure 3.2** Brainstem localisation of cranial nerve nuclei.

## CN VII: the facial nerve

The facial nerve:

- is a mixed motor, sensory and autonomic nerve
- controls the muscles of facial expression, stapedius muscle of the inner ear (problems with which lead to hyperacusis), taste from the anterior two-thirds of the tongue and innervation of the lacrimal gland
- passes through the internal auditory meatus/cerebellopontine angle (**Figure 3.1**) and the parotid gland (**Figure 3.7**)

### Clinical insight

Think 'face, ear, taste, tear' to remember the basic functions of CN VII.

## CN VIII: the vestibulocochlear nerve

The vestibulocochlear nerve:

- is purely sensory
- mediates hearing and vestibular balance

JAYPEE BROTHERS

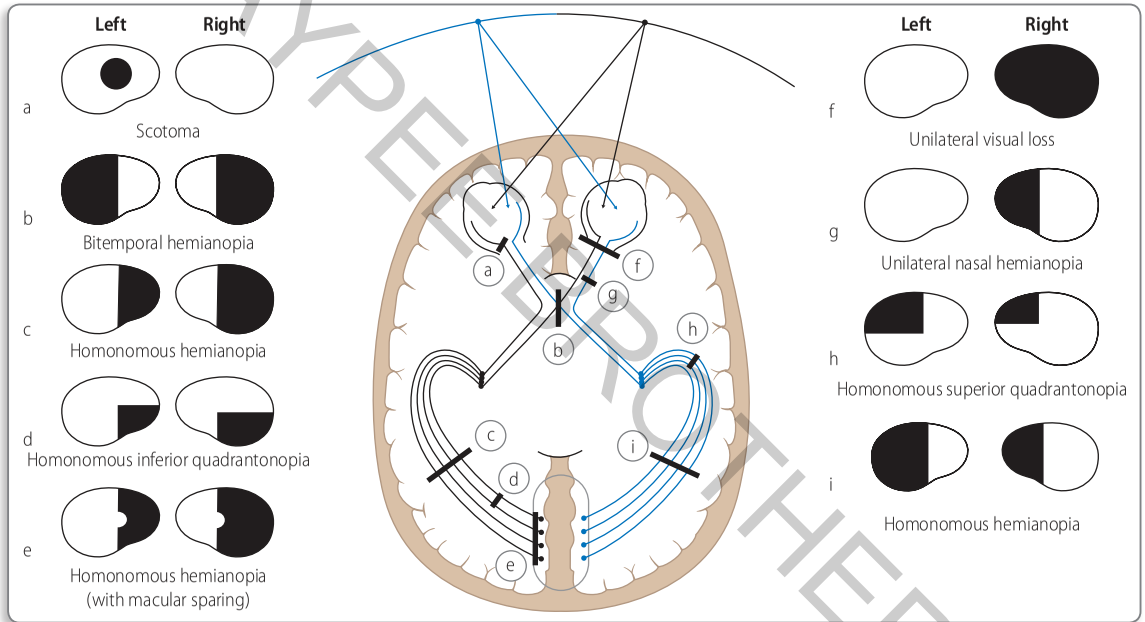


**Figure 3.3** Localising visual field defects.

JAYPEE BROTHERS

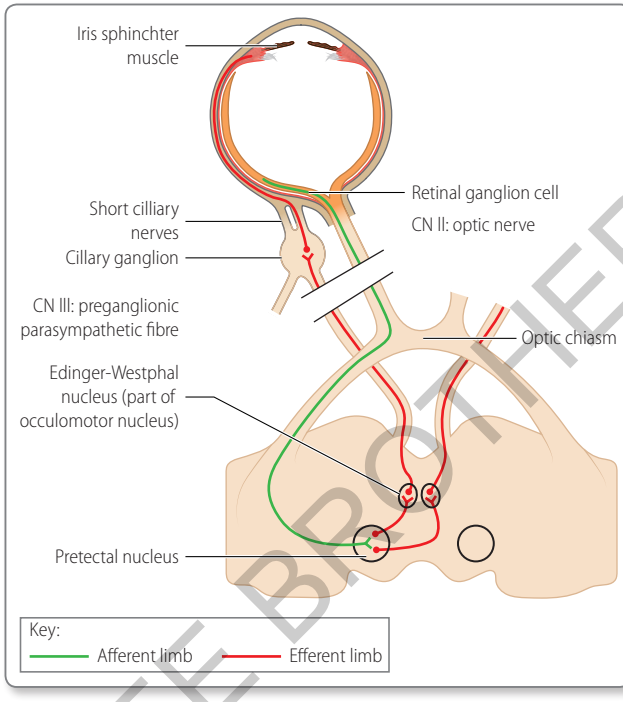


**Figure 3.4** The pupillary reflex arc involves CN II (afferent limb) and CN III (efferent limb) at the level of the midbrain.

- passes through the cerebellopontine angle with the facial nerve

## CN IX: the glossopharyngeal nerve

The glossopharyngeal nerve:

- is mixed motor, sensory and autonomic
- passes through the jugular foramen (**Figures 3.1** and **3.8**)
- elevates the pharynx and larynx
- carries sensation from the pharynx and posterior one-third of the tongue

JAYPEE BROTHERS

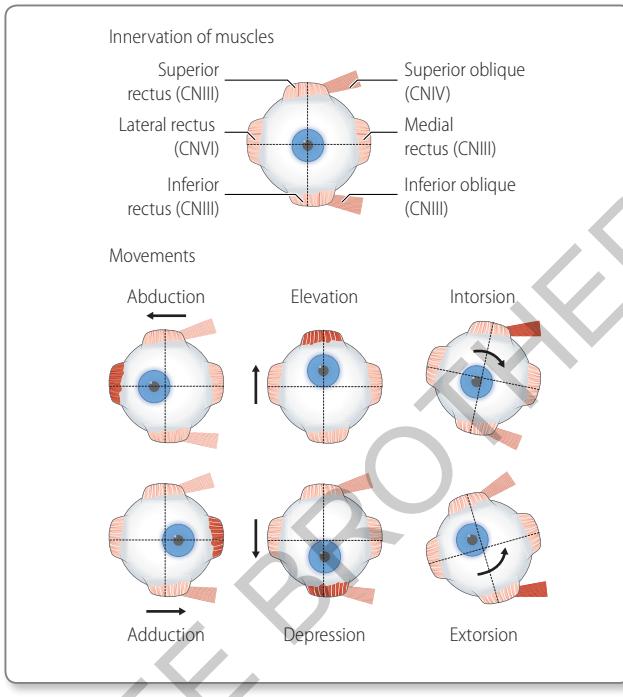


**Figure 3.5** Cranial innervation of eye muscles and eye movements. The tendon of the superior oblique muscle loops through the trochlear nerve, changing the direction of muscle movement. As a result, activation of the superior oblique rotates the pupil inward toward the nose and downward (intorsion). The inferior oblique rotates the pupil outward and upward (extorsion).

JAYPEE BROTHERS

- carries parasympathetic fibres to the parotid
- carries sensory information from the carotid sinus and carotid bodies

## CN X: the vagus nerve

The vagus nerve:

- innervates some of the muscles of speech

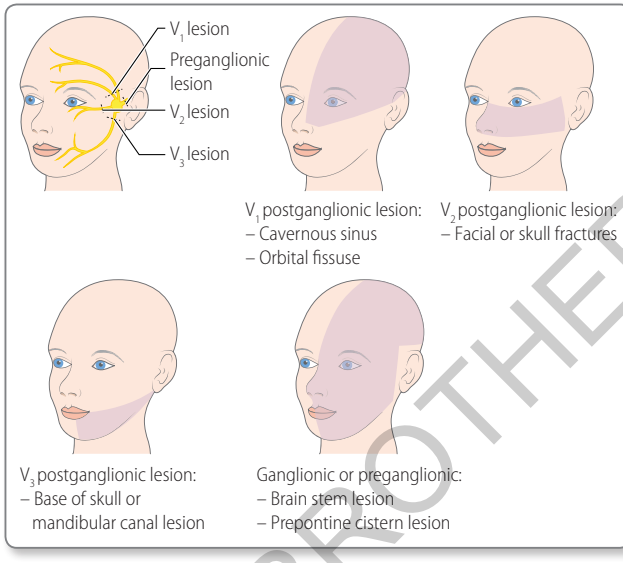


**Figure 3.6** The trigeminal nerve. The pattern of sensory changes points towards which part of the nerve is damaged.

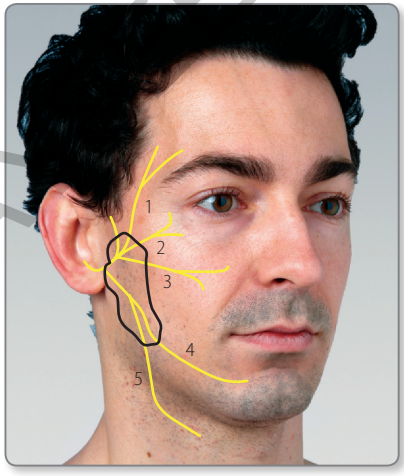


**Figure 3.7** The facial nerve passes through the parotid gland. Tumours here can cause lower motor neuron facial nerve lesions. 1, Temporal branch; 2, zygomatic branch; 3, buccal branches; 4, marginal mandibular branch; 5, cervical branch.

JAYPEE BROTHERS

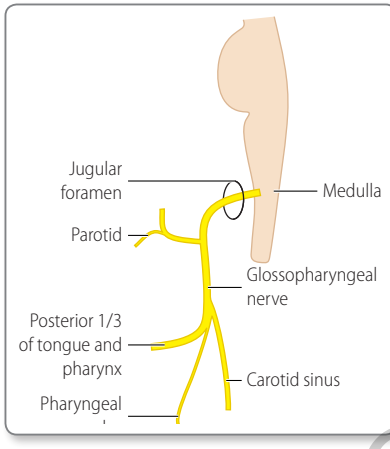


**Figure 3.8** The glossopharyngeal nerve mediates the afferent limb of the gag reflex.

- carries much of the parasympathetic innervation of the chest and abdominal cavity
- passes through the jugular foramen (**Figure 3.1**) and over the hilum of the lung

## CN XI: the accessory nerve

The accessory nerve:

- is purely motor
- has cranial and spinal roots
- passes through the foramen magnum and jugular foramen (**Figures 3.1** and **3.9**)
- cranial roots are essentially a caudal portion of the vagus
- spinal roots innervate trapezius and sternocleidomastoid

### Clinical insight

Any lesion in the hilum can cause a phrenic nerve (a branch of the vagus) palsy.

## CN XII: the hypoglossal nerve

The hypoglossal nerve:

- is purely motor
- passes through the hypoglossal foramen (**Figure 3.1**)
- innervates the muscles of the tongue

JAYPEE BROTHERS

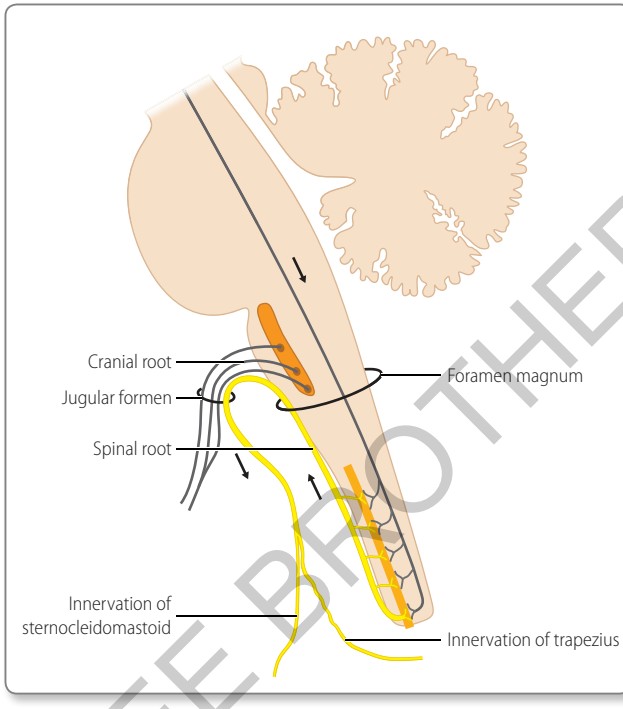


**Figure 3.9** Accessory nerve. The spinal roots pass up through the foramen magnum and join the cranial root, which then branches off to run with the vagus nerve. The remainder forms the main body of the accessory nerve and innervates the trapezius and sternocleidomastoid muscles.

JAYPEE BROTHERS

## The pupillary reflexes

The pupillary reflexes include:

- the light reflex to adjust retinal exposure
- the accommodation reflex to adjust focus
- vergence to co-ordinate binocular focus

### Direct reflex

The afferent limb of the light reflex consists of the retina, optic nerve, optic chiasm, optic tract, superior colliculus and

pocket tutor

Second Edition

# Neurological Examination

**pocket tutor Neurological Examination** is the ideal companion for medical students, junior doctors and general practitioners seeking an accessible and practical guide to performing an examination of the nervous system.

- ✔ **Covers core examination techniques** relevant to all patients, including those with stroke, coma and other less common conditions
- ✔ **Clear, logical description** of examination sequences demystifies the examination process
- ✔ **System summaries** provide a framework for approaching the clinical examination with confidence
- ✔ New to this edition: coverage of examination sequences expanded to include more **clinical photographs** and a new section on **acute stroke treatments**

**pocket tutor** is the best-selling series that reinforces knowledge fast: in practice, in tutorials, before exams. Reminders of key underlying principles, insightful clinical scenarios and an accessible format mean you can trust **pocket tutor** to provide you with the right answer, whenever you need it.

JP medical publishers

www.jpmedpub.com

ISBN 978-1-909836-70-9

9 781909 836709