FRCS (Oral & Maxillofacial Surgery) Part 2: 100 Clinical Cases

Johno Breeze
Ross Elledge
Rhodri Williams



Contents

Preface		v
Contributors		ix
About the examination		x
Abbreviations		xi
Acknowledgements		xv
Chapter 1	Dentoalveolar surgery	1
Chapter 2	Head and neck oncological surgery	25
Chapter 3	Orthognathic surgery	77
Chapter 4	Facial cutaneous surgery	127
Chapter 5	Facial trauma	155
Chapter 6	Salivary gland disease	195
Chapter 7	Oral pathology	217
Chapter 8	Temporomandibular joint surgery	261
Chapter 9	Craniofacial and paediatric surgery	291
Chapter 10	Cleft lip and palate surgery	313
Chapter 11	Facial aesthetic surgery	331

Chapter 3

Orthognathic surgery

SHORT CASES

1 Taking an orthognathic patient history
2 Examination of the orthognathic patient
3 Use of imaging in orthognathic surgery
4 Preoperative assessment and planning in orthognathic surgery
5 Inverted L osteotomy
6 Hemimandibular hyperplasia
7 Low angle class II skeletal relationship
8 High angle class III skeletal relationship
9 Postoperative sagittal split osteotomy
10 Condylar resorption following sagittal split osteotomy
11 Segmental osteotomy
12 Transverse maxillary deficiency

LONG CASE

13 High angle class II skeletal relationship

JAYPEE BROTHERS

Short case 1: Taking an orthognathic patient history

A patient has been referred to your clinic for potential orthognathic surgery.

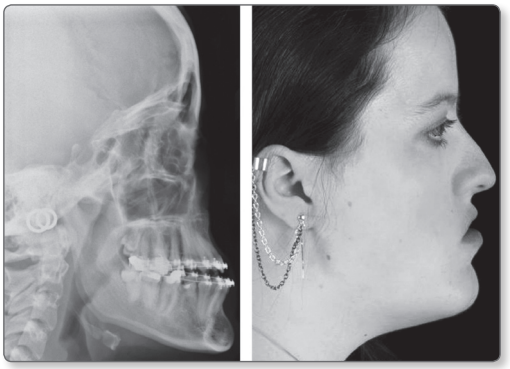

1.1 Question

What are the key points in the history?

Answer

- Referral source (Box A)
- Presenting complaint
- History of presenting complaint (Box B)
- Previous temperomandibular joint (TMJ) symptoms
- Previous orthodontic treatment
- Previous dental treatment
- Previous surgical treatment
- Past medical history
- Drug history
- Social history
- Expectations of treatment
- Summarise back to the patient

1.2 Question

How would you assess this patient further?

Answer

- Ask 'What has brought you in to see us today?'
- Type of clinician making the referral (Box A)
- Function and/or appearance (face and/or teeth)

JAYPEE BROTHERS

1.3 Question

What specific TMJ symptoms should you ask about?

Answer

- Pain when chewing
- Clicking
- Previous treatment
- Trauma to TMJ

1.4 Question

What questions about any previous orthodontic treatment are relevant?

Answer

- Removable or fixed appliances
- Tooth extractions
- How long the braces was worn for
- Compliance

1.5 Question

What questions about any previous dental treatment are relevant?

Answer

- Ongoing care or past treatment
- Assessment of risk for caries or periodontal disease

1.6 Question

What questions about any previous surgical treatment are relevant?

Answer

- Third molars removed
- Prior orthognathic surgery
- Existing altered sensation to lip, chin or tongue as result of surgery

1.7 Question

What questions about the patient's past medical history are relevant?

Answer

- Comorbidities relevant to anaesthetic or surgical risk
- Allergies
- Psychiatric issues (Box C)

JAYPEE BROTHERS

1.8 Question

Why are questions about their drug history relevant and how would you manage anticoagulants?

Answer

- Relevant to intra- or postoperative complications
- Anticoagulation should be discussed with a haematologist to see whether they can be potentially omitted

1.9 Question

What questions about the patient's social history are relevant?

Answer

- Support in immediate postoperative period
- Effect of surgery on relationships
- Occupation

1.10 Question

Why is it important to ascertain the patient's expectations of treatment?

Answer

- Patient must be clear on expectations
- Ensure expectations are realistic
- Clarify if evidence of secondary gain (such as improvement in a relationship or work)

Box A: Potential sources for referral

- General dental practitioner: pointed out by clinician or patient
- Orthodontist: general practice, specialist practice, secondary care
- General medical practitioner
- Other clinician: e.g. respiratory physician for obstructive sleep apnoea (OSA)

Box B: History of the presenting complaint

- Congenital or acquired
- Progression
- Chewing and eating
- Occlusion
- Previous trauma: to bones or teeth
- Childhood infections
- OSA (Box B)
- Effect on quality of Life

JAYPEE BROTHERS

Box C: Tailored OSA history

- Assessment by respiratory physicians: this is essential before consideration of treatment
- Symptoms: snoring, daytime sleepiness
- Mandatory preoperative assessments: polysomnography, apnoea–hypopnoea index (AHI) and Epworth Sleepiness scale (ESS) questionnaires
- Previous nonsurgical treatment: avoidance of alcohol, weight loss, continuous positive airway pressure (CPAP) devices, protrusive mandibular splints
- Previous surgical treatment: uvulopalatopharyngoplasty, hyoid advancement, midline glossectomy

Box D: Tailored psychiatric history

- The most challenging component of an orthognathic assessment
- Previous or current mental health problems are not a contraindication to treatment but must always be carefully explored
- Questions must come naturally from you and should therefore be practiced
- A simple question might be as follows 'we ask all patients coming in for this type of surgery the same question as it is important we choose the correct treatment for you. One of these questions is that I have to ask you if you have ever suffered from problems with your mental health?'

Further reading

Bailey LJ, Proffit WR, White R Jr. Assessment of patients for orthognathic surgery. Semin Orthod 1999; 5:209–222.

JAYPEE BROTHERS

Short case 2: Examination of the orthognathic patient

This patient has presented to the joint orthognathic clinic following referral from their orthodontist.

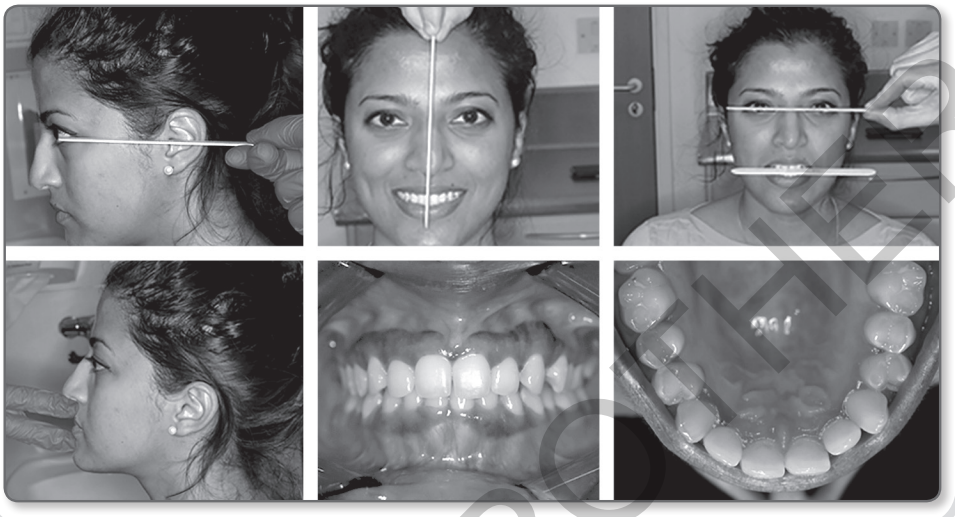

2.1 Question

What are the sequential steps of an examination for potential orthognathic surgery in a newly presenting patient as shown in the figure?

Answer

- Preparation
- Examination from the front
- Examination from the side
- Examination from behind
- Intraoral examination

2.2 Question

What steps are required in preparation?

Answer

- Patient sitting upright (Box A)
- Frankfort plane level to floor/or neutral head position
- Remove camouflage: hair over face, hats, glasses
- Confirm if a syndromic case

2.3 Question

How would you examine the patient from the front?

Answer

- Symmetry: use a spatula placed intercanthally

JAYPEE BROTHERS

- Facial fifths (Box B)
- Vertical proportions (Box C)
- Maxillary cant
- Upper lip length
- Incisor show at rest
- Incisor show dynamic
- Dental centre line: should be coincident with facial midline
- Lip competence
- Lower lip to chin length
- Lower dental midline: coincident with face and/or chin
- Chin asymmetry

2.4 Question

How would you examine the patient from the side?

Answer

- Skeletal class (Box D)
- Fronto nasal angle
- Scleral show and malar projection
- Nasolabial angle
- Labiomental angle
- Chin throat length
- Chin shape

2.5 Question

How would you examine the patient from behind?

Answer

- Symmetry
- Scleral show
- TMJ palpation

2.6 Question

How would you perform the intraoral examination?

Answer

- Oral hygiene
- Overjet
- Overbite
- Upper to lower dental centre lines
- Teeth present
- Crowding
- Pathology
- Deviation on closing

JAYPEE BROTHERS

2.7 Question

How would you summarise your findings?

Answer

- Summarise (Box E)
- Study models
- Radiographs
- Treatment plan

Box A: Measuring facial fifths

- Lines drawn vertically from medial and lateral canthi, lateral aspect of alar bases and canine teeth tips
- Intermedial canthal distance = alar base width = intercanine width

Box B: Measuring vertical proportions

- Anterior versus posterior facial heights
- Posterior facial height: utilises the Frankfort mandibular plane angle
- Anterior facial height: utilises anterior facial thirds
- Middle anterior: glabella to subnasale
- Lower anterior: subnasale to soft tissue menton
- Anterior lower facial third is further subdivided into: upper third (subnasale to stomion) and lower two-thirds (stomion to soft tissue menton)

Box C: Measuring skeletal class

- "Please put your tongue to the roof of mouth, close teeth until just about to touch"
- Skeletal class: fingers into A and B points (1, 2 or 3)

Box D: Mean examination values (Caucasian)

- Middle anterior third (45%), lower anterior third (55%)
- Upper lip length: 22 mm (males), 20 mm (females)
- Incisal show at rest: 2 mm (males), 3 mm (females)
- Lower lip to chin length: 44 mm (males), 40 mm (females)
- Overjet: 2–4 mm (class I), >2 mm (class II), <2 mm (class 3)
- Nasolabial angle: 90–110 degrees (less in males, greater in females)

JAYPEE BROTHERS

Box E: Summarising

This must be brief and not simply repeating the assessment. A suggested outline is as follows:

- Patient complaint
- Pertinent medical and social history
- Syndromic or not
- Symmetrical or not
- Skeletal class
- Problem lies in maxilla or mandible or both?
- Low, normal or high angle
- Plan

For example: 'This patient dislikes how prominent her front teeth are. They are medically well and are currently at university. On examination, this is a nonsyndromic symmetrical patient with a low angle class II skeletal relationship with mandibular hypoplasia. My orthodontic plan is to align, level and coordinate. My surgical plan is to perform a bilateral sagittal split osteotomy (BSSO) to advance to a class I incisal relationship'.

Further reading

Wolford LM. Surgical Planning in Orthognathic Surgery and Outcome Stability. In: Brennan P, Schliephake H, Ghali G, Cascarini L (Eds). Maxillofacial Surgery, 3rd Edition, 2017.

JAYPEE BROTHERS

Short case 3: Use of imaging in orthognathic surgery

This patient attends your clinic to discuss what plan will be undertaken for their forthcoming orthognathic surgery.

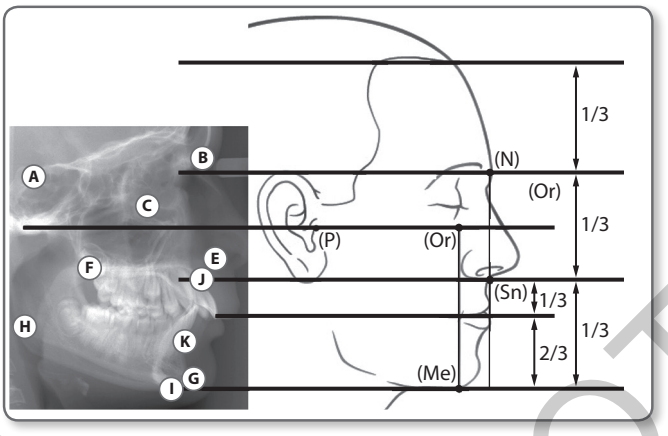

3.1 Question

What types of imaging should be requested prior to orthognathic surgery?

Answer

- Lateral cephalogram
- OPG
- Periapical radiograph
- Occlusal radiograph
- CBCT

3.2 Question

What are the practical concepts of taking a lateral cephalogram?

Answer

- Standardised and reproducible method of determining angles and measurements that can be compared to mean values for a particular population
- Ear rods placed in external auditory meatus
- Image is taken with Frankfort plane horizontal and teeth in maximum intercuspation
- Dose is 6 microsieverts (lower than OPG)

3.3 Question

Name the commonly used cephalometric points labelled in the figure?

JAYPEE BROTHERS

Answer

- A: Sella: centre of sella turcica
- B: Nasion: most anterior point of fronto-nasal suture
- C: Orbitale: most inferior anterior point on margin of orbit
- D: Porion: uppermost point on bony external auditory meatus
- E: Anterior nasal spine (ANS): most anterior point (the tip) of hard palate
- F: Posterior nasal spine (PNS): most posterior point of bony hard palate
- G: Pogonion: most prominent point on contour of chin in sagittal plane
- H: Gonion: projected point on mandible of bisected angle between a line along lower mandibular border and line down posterior ramus border
- I: Menton: most inferior point on mandibular symphysis
- J: A point: position of deepest concavity on anterior profile of maxilla
- K: B point: position of deepest concavity on anterior profile of mandibular symphysis

3.4 Question

What are the commonly used lines on a lateral cephalogram?

Answer

- Cranial base: sella to nasion (SN)
- Maxillary plane: ANS to PNS
- Mandibular plane: gonion to mention
- Frankfort plane: highest point on the upper margin of the external auditory canal and the lowest point on the lower margin of the orbit
- Middle anterior facial height (nasion to ANS)
- Lower anterior facial height (LAFH, ANS to menton)

3.5 Question

What are the commonly used cephalometric measurements?

Answer

- Maxillary-mandibular plane angle (MMPA):27 ± 5 degrees
- Frankfort-mandibular plane angle (FMPA)
- LAFH/TAFH ratio: approximately 50–55%
- SNA: 81 degrees (relationship of maxilla to cranial base)
- SNB: 79 degrees (relationship of mandible to cranial base)
- ANB: 2–4 degrees (class I), >4 degrees (class II), <2 degrees (class III)
- Upper central incisor (U1) inclination: 109 degrees
- Lower central incisor (L1) inclination: 120 degrees minus MMPA (mean of average 93)

3.6 Question

Describe simplistically how you would determine whether it is the maxilla or mandible that is positioned wrongly?

Answer

- Steiner analysis: relating the cranial base (S–N) to A and B points (SNA and SNB)

JAYPEE BROTHERS

- McNamara Analysis: a line is dropped down from nasion perpendicular to Frankfort plane. The distance from this line to A point is measured (normal value is 1 mm ahead)
- Ricketts zero-meridian line: with the Frankfort plane horizontal, drop a vertical line from Nasion and relate that line to pogonion. Pogonion lies behind line in skeletal class II and in front in class III

3.7 Question

What parameters would you check on an OPG?

Answer

- Third molars: presence or absence
- Pathology: cysts, caries, bone levels and root lengths
- Position of the inferior alveolar (IA) nerve: to assist in positioning lingual surgical cut

3.8 Question

When would you request periapical radiographs?

Answer

- These should be taken if diagnosis of tooth condition is suspicious (especially suspected short roots)

3.9 Question

When would you request an occlusal radiograph?

Answer

- To assess position of unerupted canine tooth, in conjunction with OPG

3.10 Question

When would you request a cone beam CT?

Answer

- For three-dimensional (3D) virtual planning, including cutting guides
- Printing 3D models
- Bending custom plates
- Assess position of displaced teeth including canines and potential effect on adjacent teeth

3.11 Question

What is your protocol for follow-up imaging post-surgery?

Answer

- Refer to BAOS/BAOMS guidelines (Box A)

JAYPEE BROTHERS

Box A: BAOS/BAOMS guidelines for follow-up imaging post-surgery

- Prior to discharge post-surgery: OPG
- 1–3 weeks: lateral cephalogram
- 6 months (prior to debonding): lateral cephalogram

Further reading

Bell RB. Computer planning and intraoperative navigation in cranio-maxillofacial surgery. Oral Maxillofac Surg Clin North Am 2010; 22:135–156.

Levine JP, Patel A, Saadeh PB, et al. Computer-aided design and manufacturing in craniomaxillofacial surgery: the new state of the art. J Craniofac Surg 2012; 23:288–293.

JAYPEE BROTHERS

FRCS (Oral & Maxillofacial Surgery) Part 2: 100 Clinical Cases

FRCS (Oral & Maxillofacial Surgery) Part 2: 100 Clinical Cases is an ideal revision guide for candidates preparing for the FRCS OMFS Part 2 examination. Cases are organised according to the syllabus and are presented in the form of both long and short cases to reflect the formats used and provide a comprehensive set of materials to prepare for the exam.

With each case posing a series of examiner questions before providing brief, bullet-style answers designed to help you formulate effective responses under time pressure, **FRCS (Oral & Maxillofacial Surgery) Part 2: 100 Clinical Cases** is an essential revision tool for maximising chances of exam success.

- First book to cater specifically for the clinical component of the FRCS OMFS exam
- Ideal for practicing exam scenarios with colleagues and role playing as candidate or examiner
- Complete coverage of the curriculum with practice cases for every part of the syllabus
- Advice boxes in each case highlight key 'take home' messages for each one

Johno Breeze is a Lieutenant Colonel in the Royal Army Medical Corps and Consultant Oral and Maxillofacial Surgeon at the Royal Centre for Defence Medicine and University Hospitals Birmingham NHS Foundation Trust. He has deployed to Bosnia, Oman, Northern Ireland and Afghanistan. He completed his medical and dental degrees in London, and his PhD in Birmingham, UK. He completed Higher Surgical Training in the West Midlands and a year post CCT fellowship in Craniomaxillofacial Trauma at Duke University Medical Centre, North Carolina USA. He was awarded military healthcare person of the year in 2013 for developing a new design of body armour worn by all UK military personnel. In 2015, he was presented by Her Majesty The Queen the civil service prize for innovation. He is currently the Editor-in-Chief of the BMJ Journal of the Royal Army Medical Corps. His research interests centre around the optimisation of body armour, emergency preparedness and protection of the national infrastructure against ballistic threats.

Ross Elledge studied dentistry at the University of Malta and medicine at the University of Birmingham, being awarded the Chancellor's Prize and Sir Arthur Thomson Gold Medal. His higher surgical training was in the West Midlands Deanery, during which he also completed a Masters in Medical Education with the University of Dundee. Following Training Interface Group (TIG) Fellowships in Reconstructive and Aesthetic Surgery and the Management of Skin Cancer, he was appointed as Consultant Oral and Maxillofacial Surgeon at University Hospitals Birmingham NHS Foundation Trust in 2018. He is Honorary Senior Lecturer at the College of Medical and Dental Sciences, University of Birmingham and regularly examines for the Royal College of Physicians and Surgeons of Glasgow.

Rhodri Williams studied dentistry at University of Birmingham and medicine at the University of Bristol. His higher surgical training was in the South West of England. He was a Craniofacial Fellow at Birmingham Children's Hospital and a Fellow in Paediatric Maxillofacial Surgery at Royal Melbourne Children's Hospital. He was appointed as Consultant Oral and Maxillofacial Surgeon at University Hospitals Birmingham NHS Trust in 2005 and is an Honorary Clinical Lecturer at the College of Medical and Dental Sciences, University of Birmingham. He is the Training Program Director for OMFS in the West Midlands and has recently been accepted to be an examiner for FRCS (OMFS).

JP medical publishers

www.jpmedpub.com

ISBN 978-1-909836-83-9