Second Edition

Chest X-Ray Interpretation

Ladli Chandratreya
Mike Darby

pocket tutor



JP

Chest X-Ray Interpretation

Second Edition

Ladli Chandratreya MBBS DMRD FRCR
Consultant Radiologist
North Bristol NHS Trust
Bristol, UK

Mike Darby BA MBBS MRCP FRCR
Consultant Radiologist
North Bristol NHS Trust
Bristol, UK

JAYPEE BROTHERS

pocket tutor

JP medical publishers

Contents

Preface *v*

Chapter 1 First principles

1.1 Physics of X-rays 1
1.2 Positioning the patient and obtaining the image 3
1.3 Radiographic densities 9
1.4 Picture archiving and communication systems: image optimisation and pitfalls 10
1.5 Errors of perception and interpretation 12

Chapter 2 Understanding the normal chest X-ray

2.1 Normal chest anatomy 17
2.2 Normal variants and congenital anomalies 24
2.3 Artefacts 39
2.4 Systematic approach to reviewing the chest X-ray 41
2.5 Postsurgical appearances 54

Chapter 3 Recognising abnormal signs

3.1 Lung opacities 59
3.2 Atelectasis 69
3.3 Reticular opacities 85
3.4 Pleural abnormalities 88
3.5 Mediastinal abnormalities 97
3.6 Diaphragm, subdiaphragmatic area and chest wall abnormalities 106

Chapter 4 Thoracic infections

4.1 Community-acquired pneumonia 113
4.2 Hospital-acquired pneumonia 116
4.3 Active tuberculosis 119
4.4 Old tuberculosis 126
4.5 *Pneumocystis* pneumonia 131
4.6 Aspergilloma 134
4.7 Histoplasmosis 137

JAYPEE BROTHERS

Chapter 5 Interstitial lung diseases
5.1 Sarcoidosis 141
5.2 Idiopathic pulmonary fibrosis 145
5.3 Asbestosis 148
5.4 Silicosis 151

Chapter 6 Bronchogenic malignancy and metastatic disease
6.1 Bronchogenic malignancy 155
6.2 Metastatic disease 161

Chapter 7 Pleural disease
7.1 Mesothelioma and other pleural malignancies 169
7.2 Solitary fibrous tumour of the pleura 174
7.3 Pleural infection 176
7.4 Pneumothorax 177

Chapter 8 Mediastinal disease
8.1 Thymoma 183
8.2 Hiatus hernia 185
8.3 Bronchogenic cyst 187
8.4 Retrosternal goitre 189
8.5 Pneumomediastinum 191
8.6 Mitral regurgitation 193
8.7 Pericardial effusion 194
8.8 Aortic dissection 197

Chapter 9 Airway pathology
9.1 Asthma 201
9.2 Allergic bronchopulmonary aspergillosis 203
9.3 Chronic obstructive pulmonary disease 205
9.4 Alpha 1-antitrypsin deficiency 208
9.5 Bronchiectasis and cystic fibrosis 210
9.6 Inhaled foreign body 213

Chapter 10 Pulmonary oedema
10.1 Cardiogenic pulmonary oedema 217
10.2 Acute lung injury and acute respiratory distress syndrome 221

JAYPEE BROTHERS

Chapter 11 Lines, tubes and other devices
11.1 Nasogastric tubes 223
11.2 Central venous lines and pacemakers 226
11.3 Tracheal intubation 228
11.4 Chest drains 229
11.5 Other devices in the intensive care situation 232
11.6 Devices used in lung volume reduction 234
11.7 Tracheal and bronchial stents 238
11.8 Embolisation coils in treatment of pulmonary AVM 239
11.9 Thoracic aortic stent 242
11.10 Implantable loop recorder 242
11.11 Left ventricular partitioning device 244
11.12 Atrial septal defect closure device 245
11.13 Bariatric surgical treatment 245
11.14 Oesophageal stent 246
11.15 Oesophageal variceal embolisation coils 247
11.16 Transhepatic portosystemic shunt 249
11.17 Breast implants 249
11.18 Nipple-areolar prosthesis 249
11.19 Occipital nerve stimulation system 250
11.20 Incorrectly placed devices and pitfalls 252

Chapter 12 Thoracic trauma
12.1 Pneumothorax and haemothorax 255
12.2 Aortic and vascular injury 257
12.3 Chest wall injuries 257
12.4 Pulmonary injury 263
12.5 Tracheal and bronchial injuries 263
12.6 Oesophageal tear 266
12.7 Diaphragmatic rupture 268
12.8 Pneumoperitoneum 270
12.9 Penetrating injuries 271
12.10 Lines and tubes 275

Index *277*

JAYPEE BROTHERS

Recognising abnormal signs

chapter 3

The various radiographic densities or the lack of them form the basis of understanding and recognising abnormal signs on a chest X-ray. Some of the radiological features described are specific to an anatomical structure and vital in diagnosis. The radiographic densities and their rationale are dealt with in Chapter 1, Section 1.3. This chapter aims to familiarise the reader with the various terminologies routinely encountered in chest X-ray interpretation.

3.1 Lung opacities

Airspace opacification

Airspace opacification is otherwise known as alveolar opacification. It is caused by replacement of the alveolar air by fluid, cells or other material. The history usually helps differentiate between these entities. X-rays may show either a diffuse or a localised airspace disease. **Table 3.1** lists the causes of alveolar opacification.

Radiographic findings The findings are unilateral or bilateral. The condition begins with small irregular, nodular or fluffy opacities, which then form more confluent opacification. Diffuse or patchy consolidation is often seen. Perihilar 'bat's wing' distribution (**Figure 3.1a**) is typical of pulmonary oedema but is also seen in other conditions (e.g. *Pneumocystis* pneumonia). The air bronchograms in **Figure 3.1a** and a computerised tomography (CT) scan (**Figure 3.1b**) are caused by air in the bronchi (black or grey) surrounded by consolidated lung. Airspace opacification can clear rapidly, within hours, in cardiac failure. In infection and haemorrhage, resolution is much slower.

Pulmonary masses

Various conditions can present as a pulmonary mass lesion on a chest X-ray (**Table 3.2**). The conditions may manifest as solitary or multiple pulmonary masses and can be benign or malignant.

JAYPEE BROTHERS

Cause	Example(s)
Exudate	Infection (bacterial, viral or fungal)
	Aspiration
Transudate	Cardiac failure
	Acute respiratory distress syndrome
	Hypoproteinaemia
	Any cause of fluid overload
Blood	Trauma
	Vasculitis
	Haemosiderosis
Cells	Alveolar cell carcinoma
	Metastases
	Lymphoproliferative infiltration
Other	Alveolar proteinosis

Table 3.1 Causes of alveolar opacification

Radiographic findings A pulmonary mass (**Figure 3.2**) appears as an opacity >3 cm in diameter. Single or multiple masses may be visible. The masses may have irregular or smooth margins, depending on their nature. Abscesses may show areas of cavitation. Calcification is often seen in granulomas and hamartomas but these are usually smaller.

Pulmonary nodules

Macronodular opacities

Nodules are rounded opacities of <3 cm. Macronodular opacities are usually defined as nodules >5 mm in diameter. Nodules may contain cavitation or calcification. Multiple nodules are seen in various conditions (**Table 3.3**).

Radiographic findings The nodular lesions are often rounded with smooth or irregular margins. The density, distribution, size and other associated radiological findings allow diagnosis.

JAYPEE BROTHERS

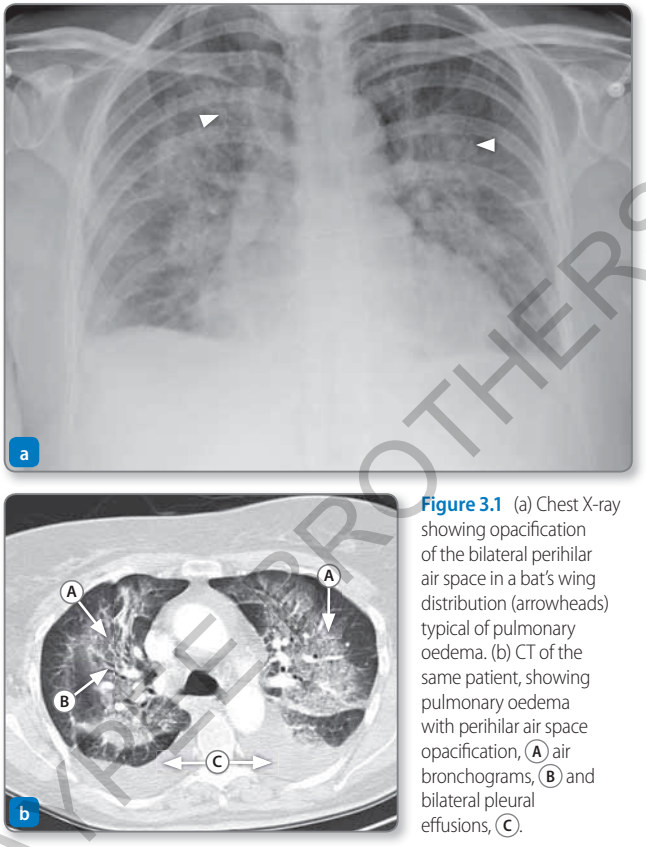

Figure 3.1 (a) Chest X-ray showing opacification of the bilateral perihilar air space in a bat's wing distribution (arrowheads) typical of pulmonary oedema. (b) CT of the same patient, showing pulmonary oedema with perihilar air space opacification, (A) air bronchograms, (B) and bilateral pleural effusions, (C).

- Cavitation is seen in abscesses or cavitating metastases
- Metastases usually have smooth margins but vary in size (**Figure 3.3**)
- Sarcoid and pneumoconioses have nodules of about the same size
- Sarcoid nodules tend to be perihilar and in the upper zones
- Rheumatoid nodules are most often in the lower zones
- Calcified hilar nodes are seen with sarcoid, silicosis and tuberculosis

JAYPEE BROTHERS

Cause	Examples
Malignant lesions	Squamous cell, small cell or adenocarcinoma lung cancer
	Sarcoma
	Pulmonary lymphoma
	Melanoma
	Metastatic lung lesions
Benign conditions	
Infections and infestations	Pneumonia
	Lung abscesses
	Hydatid cysts
	Aspergilloma (fungal ball)
	Granulomas
Congenital	Arteriovenous malformation
	Bronchogenic cyst
	Sequestration
Other	Pulmonary infarct
	Lung contusion or haematoma
	Round atelectasis
	Pulmonary artery aneurysm
	Bronchial carcinoid
	Focal scarring or massive fibrosis in pneumoconioses

Table 3.2 Differential diagnosis of pulmonary masses

JAYPEE BROTHERS

Small nodular opacities

Small nodular opacities are nodules of 2–5 mm. They may be single or multiple. Some of the causes of small nodules are the same as those of micro- and macronodular disease. Tuberculosis, sarcoid, and metastases from thyroid, breast and melanoma all give rise to small nodules. Other causes of

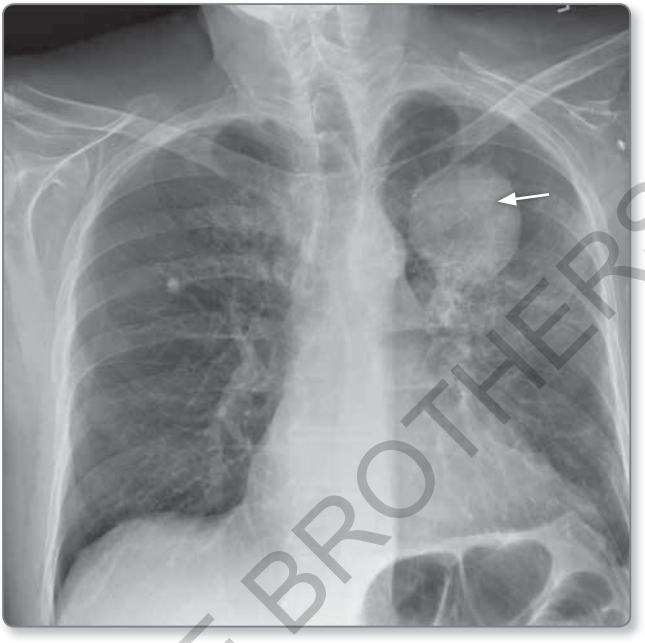

Figure 3.2 Chest X-ray showing a pulmonary mass (arrow) in the left upper zone, later diagnosed as a sarcoma.

Cause	Examples
Metastases	Metastases arising in breast, lung, kidney or gastrointestinal tract
Infection	Tuberculosis
	Abscesses
	Fungal infection
Collagen vascular disease	Rheumatoid arthritis
	Granulomatosis with polyangiitis
Pneumoconiosis	Silicosis
Other	Sarcoid, amyloid and arteriovenous malformations

Table 3.3 Differential diagnosis of macronodular opacities

JAYPEE BROTHERS

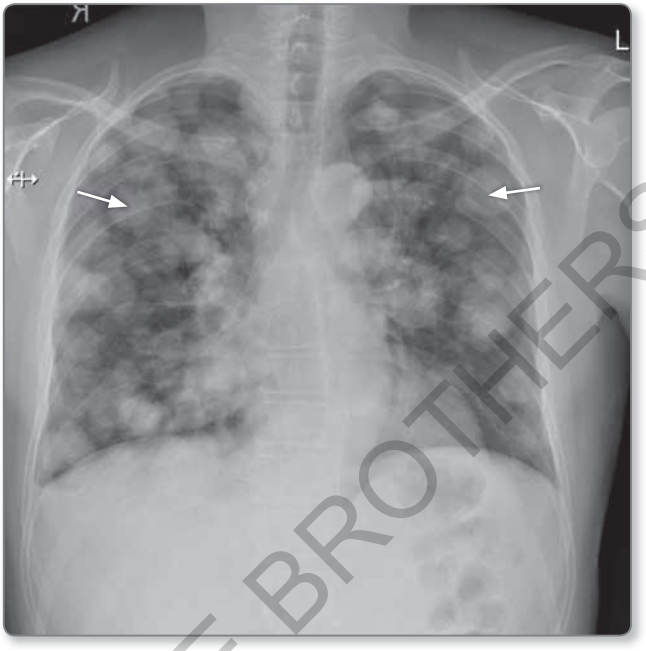

Figure 3.3 Chest X-ray showing multiple large nodules of varying sizes (arrows) in both lungs. These large metastases are often referred to as 'cannon ball' metastases, owing to their size and rounded appearance.

multiple small nodular opacities are eosinophilic granulomas, hypersensitivity pneumonitis, histiocytosis and pulmonary oedema. Previous chickenpox (varicella pneumonia, **Figure 3.4**), histoplasmosis, coccidioidomycosis and old tuberculosis give rise to multiple small calcified nodules.

Radiographic findings chest X-ray and CT scans show small, rounded and occasionally calcified opacities. Nodules of metastases, tuberculosis, granulomas and sarcoid are more discrete than the poorly defined or confluent opacities seen in pulmonary oedema.

JAYPEE BROTHERS

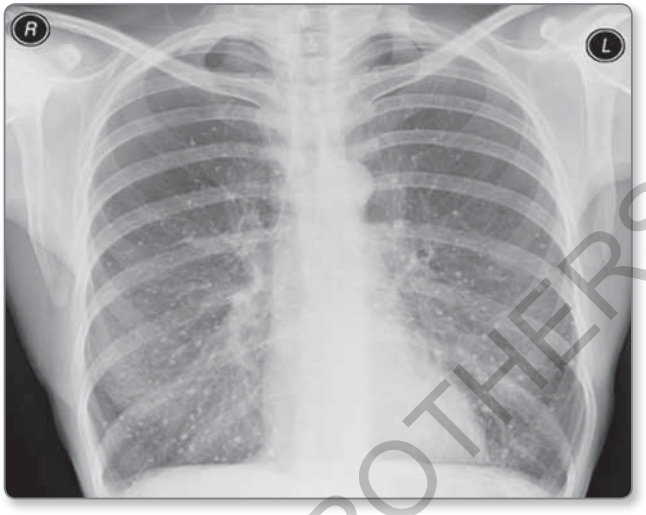

Figure 3.4 Chest X-ray showing multiple small calcified nodular opacities secondary to old varicella pneumonia.

JAYPEE BROTHERS

Micronodular opacities

Micronodular opacities are often interchangeably referred to as miliary nodules. Micronodules are 0.5–1 mm, whereas miliary nodules may be up to 2 mm in diameter. However, in practice micronodules are those measuring 0.5–2 mm (**Table 3.4**). Examples are shown in **Figures 3.5** and **3.6**.

Radiographic findings The nodules appear as fine pinpoint opacities or miliary opacities. These opacities are widespread in the lungs in miliary tuberculosis (**Figure 3.5**) and histoplasmosis, and they have no zonal predominance.

Sarcoid usually has a perihilar distribution. Rarely, it has a widespread miliary appearance.

Clinical insight

Miliary means 'resembling millet seeds'. Miliary nodules should be evenly distributed, without a zonal predominance.

Type	Causes
Widespread, soft tissue density	Miliary tuberculosis (**Figure 3.5**) and histoplasmosis, both caused by disseminated haematogenous spread and difficult to differentiate
	Sarcoid, hypersensitivity pneumonitis and panbronchiolitis (**Figure 3.6**)
Miliary metastases	Thyroid carcinoma and melanoma
High-density micronodules	Silicosis, haemosiderosis, berylliosis and stannosis

Table 3.4 Types and causes of micronodular opacities

High-density fine nodules are seen in silicosis and other heavy metal inhalational diseases (e.g. stannosis and berylliosis). In silicosis, nodules tend to be distributed in the upper zones and may have calcified mediastinal and hilar nodes, usually in an eggshell pattern of calcification of the nodes. Associated upper zone fibrosis is often present.

Cavitating lesions

A cavitation in the lung is an area of transradiancy surrounded by opacification or wall. Cavitating lesions may be a ring lesion, cavity or transradiancy in an area of consolidation or mass. Assessment of the size, site, number, wall thickness, margins and intracavitary contents of the lesions helps differentiate the cause (**Table 3.5**).

Radiographic findings A cavitating lesion is generally seen as a ring lesion with central lucency, with or without an air-fluid level.

- Cavitating lesions are thick-walled and irregular in carcinoma (**Figure 3.7**) and tuberculosis
- They are multiple in metastases, granulomatosis with polyangiitis and rheumatoid arthritis (**Figure 3.8**)

JAYPEE BROTHERS

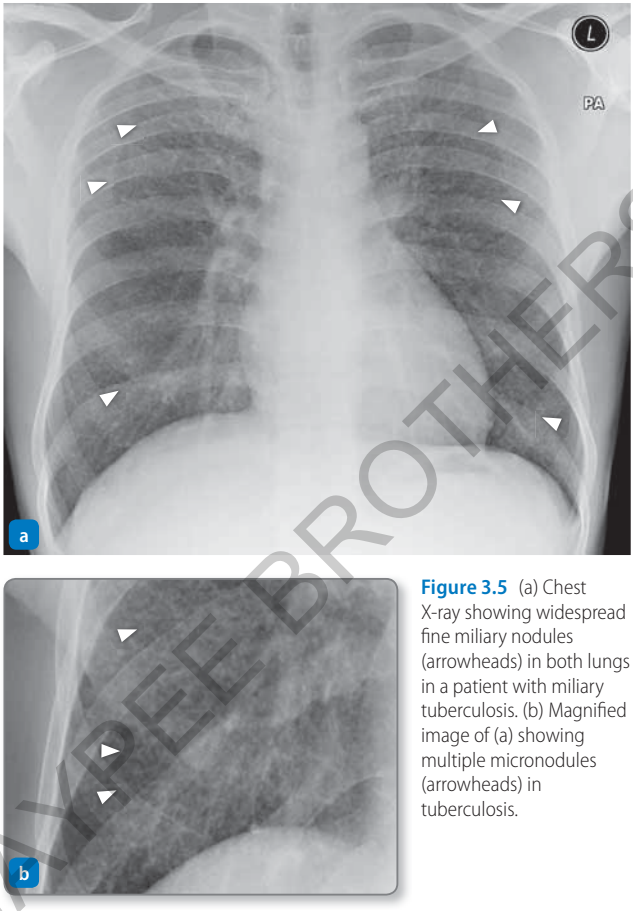

Figure 3.5 (a) Chest X-ray showing widespread fine miliary nodules (arrowheads) in both lungs in a patient with miliary tuberculosis. (b) Magnified image of (a) showing multiple micronodules (arrowheads) in tuberculosis.

JAYPEE BROTHERS

- They are multiple with thin walls in staphylococcal pneumatoceles
- An intracavitatory mass may indicate an aspergilloma, tumour or clot and often has as an air crescent sign, particularly in aspergillomas

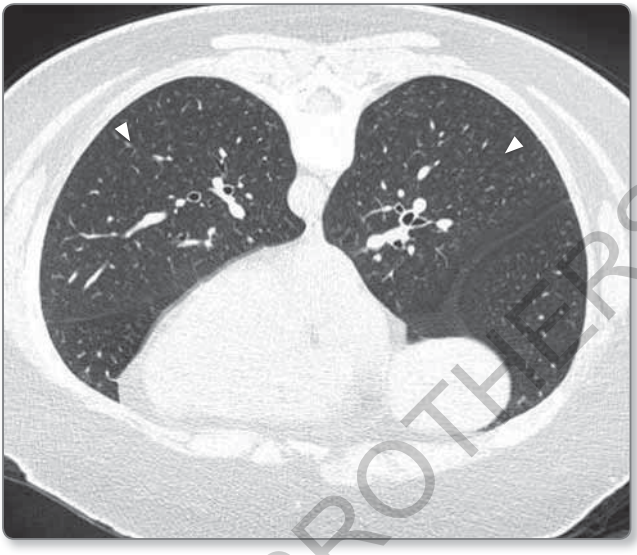

Figure 3.6 Prone CT image showing multiple fine branching micronodular opacities (arrowheads) in a patient with extensive bronchiolitis.

Cause	Example(s)
Infections	*Klebsiella*
	Staphylococcus
	Tuberculosis
	Fungal infection
Tumours	Squamous cell lung cancer
	Metastases
Vascular	Pulmonary infarcts
	Septic emboli
	Granulomatosis with polyangiitis (vasculitis)
Connective tissue disorders	Rheumatoid arthritis
Trauma	Laceration of lung
	Cysts

Table 3.5 Differential diagnosis of cavitating lesions

JAYPEE BROTHERS

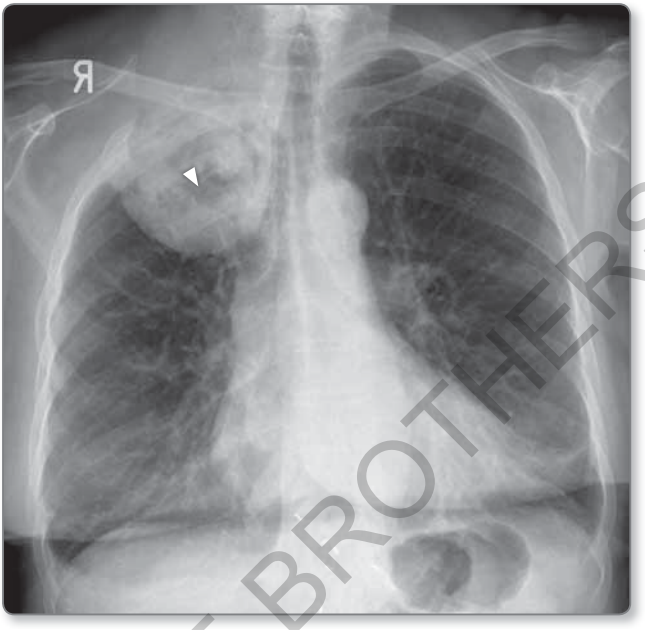

Figure 3.7 Chest X-ray showing large Pancoast tumour (arrowhead) in the right upper zone with central cavitation. The first two ribs on the right have been destroyed by the tumour.

JAYPEE BROTHERS

3.2 Atelectasis

Atelectasis is partial or complete loss of volume, i.e. collapse, of the lung. Partial atelectasis may be lobar (involving the whole lobe), segmental or subsegmental. **Table 3.6** lists the causes of atelectasis.

Types of atelectasis

There are four types of atelectasis.

- Obstructive or resorption atelectasis: secondary to a foreign body, mucus or tumour (**Figure 3.9**)
- Passive atelectasis: a large pleural effusion or mass, pneumothorax, diaphragmatic paralysis or rupture



Figure 3.8 Reformatted coronal CT showing cavitating lower zone nodules (arrowheads) in rheumatoid disease.

JAYPEE BROTHERS

- Cicatrisation atelectasis (caused by scarring): seen after infections, particularly tuberculosis, and in sarcoid and pulmonary fibrosis
- Adhesive atelectasis: caused by loss of alveolar surfactant (i.e. respiratory distress syndrome)

Radiographic findings Atelectasis shows general signs of lack of aeration of the involved lung and displacement of fissures, hilum and diaphragm. The sections below cover more specific signs for individual lobar and segmental atelectasis on X-ray.

Whole lung atelectasis

Atelectasis of the whole lung is not an uncommon occurrence. Loss of volume of the whole lung could be secondary to any

Type of atelectasis	Causes	Examples
Endoluminal obstruction	Tumour	Bronchogenic carcinoma
		Metastases from breast, melanoma, colon and kidney
		Carcinoid
	Mucus	–
	Foreign body	–
	Infection or inflammation	Tuberculous granulomas
		Sarcoid granulomas
		Granulomatosis with polyangiitis
	Other	Amyloid
		Broncholith
Extrinsic compression of airways or lung	Adenopathy	Lymphoma
		Metastases
		Tuberculosis
		Sarcoid
	Other	Large pleural effusion
		Scarring
		Cardiomegaly
		Pleural tumours
		Pneumothorax

Table 3.6 Causes of atelectasis

JAYPEE BROTHERS

of the causes of atelectasis listed in **Table 3.6**. Endoluminal obstruction, when present, is within the main bronchus leading to whole lung atelectasis. Passive atelectasis is usually due to compression of the lung by tumour or fluid outside the lung.

Radiographic findings The chest X-ray shows complete opacification (white-out) and loss of volume of the affected hemithorax. The loss of volume is evidenced by deviation of the trachea and mediastinum to the side of the atelectasis and crowding of the ribs on the affected side (**Figure 3.9**).

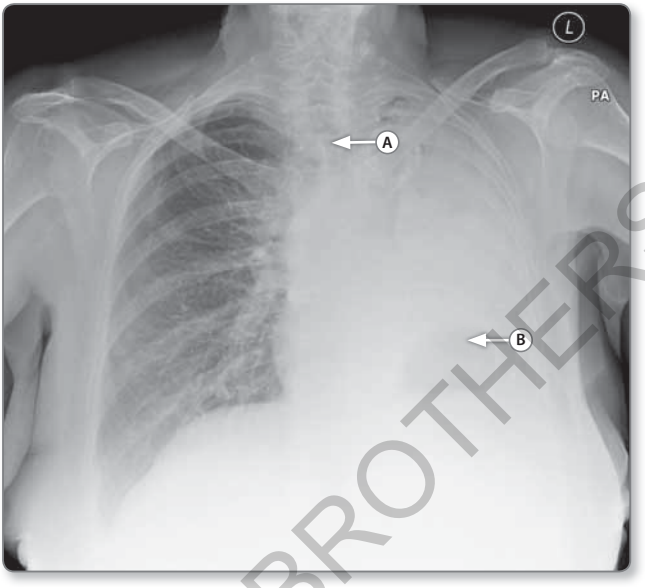

Figure 3.9 Chest X-ray showing total white-out of the left hemithorax, with loss of volume caused by atelectasis of the left lung and with mediastinal and tracheal (A) shift to the left. Elevation of the left hemidiaphragm is visible as raised gastric air bubble (B). The left sided ribs are crowded.

JAYPEE BROTHERS

Lobar atelectasis

This refers to loss of volume and collapse of a lobe of the lung. The radiological signs required for the diagnosis of collapse of the various lobes are described below.

Radiographic findings In right upper lobe atelectasis, the horizontal fissure rises upwards, depending on the degree of right upper lobe atelectasis, and becomes more vertical. This effect is best seen on posteroanterior (PA) X-rays (**Figure 3.10**). The fissure may even be concave inferiorly. The atelectatic lobe lacks air and becomes more opaque. The oblique fissure is more vertical and is visualised on lateral view as the posterior margin of the wedge-shaped opacity (**Figure 3.11**). The trachea is often deviated to the right. The

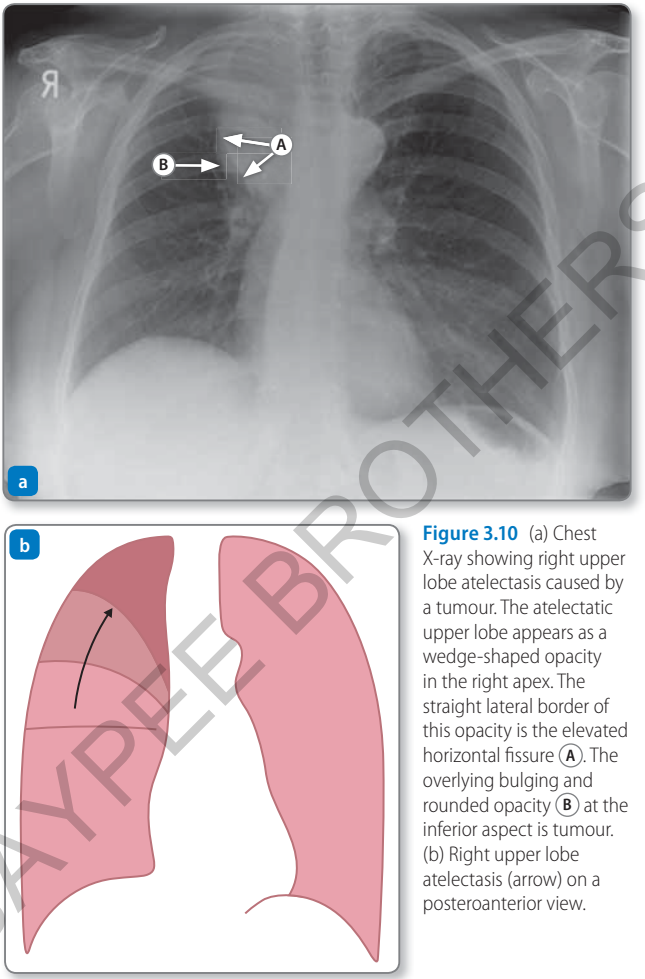

Figure 3.10 (a) Chest X-ray showing right upper lobe atelectasis caused by a tumour. The atelectatic upper lobe appears as a wedge-shaped opacity in the right apex. The straight lateral border of this opacity is the elevated horizontal fissure (A). The overlying bulging and rounded opacity (B) at the inferior aspect is tumour. (b) Right upper lobe atelectasis (arrow) on a posteroanterior view.

right hilum and right hemidiaphragm are elevated. There may be compensatory hyperinflation of the middle and lower lobes, which may be more lucent. CT is useful to assess the cause of the atelectasis.

JAYPEE BROTHERS

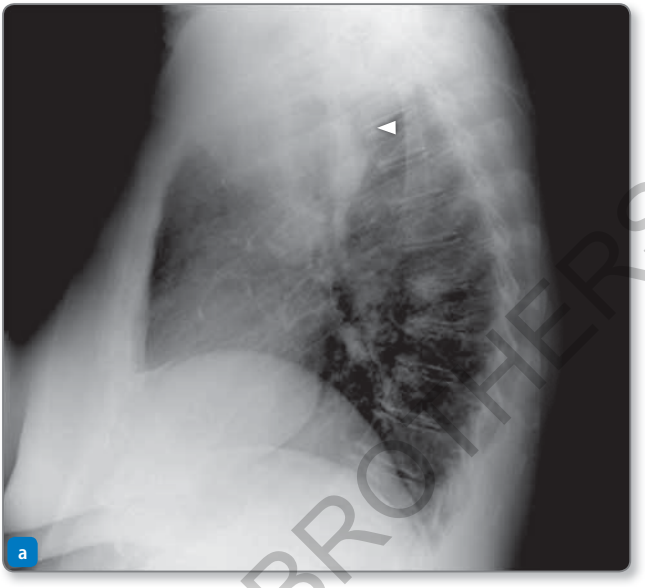

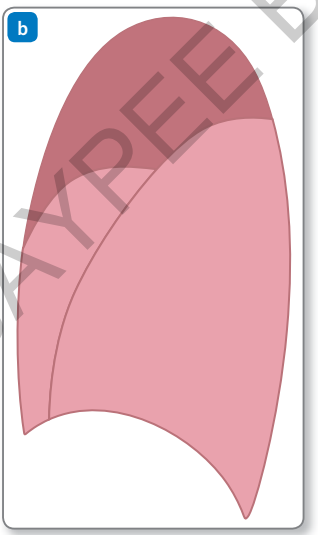

Figure 3.11 (a) Lateral X-ray of right upper lobe atelectasis, showing elevation of an oblique fissure (arrowhead), seen as a straight margin posterior to the wedge opacity of the atelectatic right upper lobe in the apex. (b) Lateral view of right upper lobe atelectasis.

JAYPEE BROTHERS

pocket tutor

Second Edition

Chest X-Ray Interpretation

pocket tutor Chest X-Ray Interpretation is the perfect companion for medical students, junior doctors and anyone seeking to improve their working knowledge of this most universal of diagnostic techniques.

- ✔ **Guide to appearance of normal images and abnormal signs** helps you navigate imaging results successfully and recognise underlying pathology
- ✔ **Clearly labelled, high-quality images** teach you to identify anatomical landmarks and clinical signs
- ✔ **Concise disease descriptions** give key facts and cardinal imaging features to look out for in practice
- ✔ New to this edition: **chapter on thoracic trauma** and over **50 additional X-ray images**, including those of newer medical devices

pocket tutor is the best-selling series that reinforces knowledge fast: in practice, in tutorials, before exams. Reminders of key underlying principles, insightful clinical scenarios and an accessible format mean you can trust **pocket tutor** to provide you with the right answer, whenever you need it.

JP medical publishers

www.jpmedpub.com

ISBN 978-1-909836-86-0

9 781909 836860