FRCEM Final OSCE: 125 OSCE Stations

THIRD EDITION

Kiran Somani
James Miers



Contents

Foreword to First Edition v
Dedication v
Acknowledgements v
Preface to Third Edition vii
How to use this book x
Introduction to the FRCEM Final OSCE examination xi

Chapter 1 History taking 1
Chapter 2 Communication skills 95
Chapter 3 Systems examination 147
Chapter 4 Joint examination 187
Chapter 5 Psychiatry 231
Chapter 6 Practical skills and teaching 255
Chapter 7 Acute adult presentations 389
Chapter 8 Paediatric acute presentations 433
Chapter 9 Trauma presentations 471

3.1 Introduction

Your ultimate goal for these objective structured clinical examinations (OSCEs) is, of course, to score as many marks as possible. The areas where marks are scored can be divided into three (opening the station, the examination itself and closing the station). By focusing on each of these areas individually, you should be able to maximise your score.

Opening the station

Several basic things are required to start the station. You must always introduce yourself to the patient, confirm their identity and explain what you intend to do. You should always ask the patient if they are in pain and if appropriate offer them some painkillers and remember to exercise caution when examining any painful areas. It will detract from your global score if you cause undue pain to the patient. Finally before touching the patient you should always clean your hands and seek their permission for the examination.

The examination

This should be a well-rehearsed routine. A candidate who must stop between steps of the examination to think about what they need to do next is unlikely to do very well. It also means they are unable to concentrate on the clinical findings that they elicit, and may also run out of time. From the examiner's and patient's point of view it makes the candidate seem at best nervous and at worst inexperienced with what are fundamental examinations.

In this chapter each examination is outlined in full and should be thoroughly rehearsed so that steps become second nature. Each is based on the principles of inspect, palpate, percuss then auscultate. It is best to practice these in small groups of two or three to allow you to grow accustomed to being observed while examining and also provides an opportunity for feedback on your technique.

It might be the case that you will be asked to talk through the steps in your examination while performing it. This may not suit all candidates so it is worth practicing. If there is any doubt as to whether or not this is expected of you it is acceptable to ask the examiner at the start of the station if they would like you to talk through your examination or not.

Closing the station

Having finished the examination, you should always thank the patient and offer them help getting redressed. The OSCE will usually require the candidate to present their findings in a particular way. It is important that attention is paid to this – and the style required. Some OSCEs require a management plan to be explained to (and agreed with) the patient, whereas others may simply require presentation of findings to the examiner. You should be clear which is required. It is always tempting when presenting your findings to look from the examiner to the patient. However this causes the presentation to be fragmented and can make a candidate seem uncertain of their clinical findings.

It is likely that a diagnosis (or at least a differential diagnosis) will be expected as well as an appropriate management plan.

JAYPEE BROTHERS

3.2 Cardiovascular examination

Begin by introducing yourself, washing your hands, confirming the name of the patient and asking for permission to examine them.

Ask if the patient has any pain and offer analgesia if appropriate.

The patient will often already be appropriately positioned. If not, they should be positioned at 45°, naked from the waist up. In the examination, this patient will usually be a man. If they are a woman, it is appropriate to tell the examiner that ideally you would expose the whole of their chest for some parts of the examination, but to ask whether you may preserve their dignity in the examination by leaving a bra or sports top in place.

General inspection

Stand at the end of the bed and perform a general inspection. The main features to note are:

- The patient's general appearance and level of comfort
- Is the patient breathless?
- Are there any scars indicating previous interventions (e.g. a scar below the left clavicle from a pacemaker or internal defibrillator, a midline sternotomy scar which may indicate valve replacement or a coronary artery bypass or a left thoracotomy scar from a valvotomy for mitral stenosis)?
- The presence of any medical equipment or medication (oxygen, glyceryl trinitrate spray, tablets)

Hand inspection

The next step is to inspect the hands for:

- Clubbing (present in cyanotic congenital heart disease or subacute bacterial endocarditis)
- Splinter haemorrhages suggest endocarditis. Also look for Osler's nodes (tender nodules in the finger pads) and Janeway lesions (purpuric macules on the palms)
- Tar staining of the finger tips indicating a significant smoking history
- Nail bed pulsation of aortic regurgitation (Quincke's sign)

Pulses and blood pressure

Palpate the radial pulse to determine the rate and rhythm.

Then move on to palpate the brachial artery for a collapsing pulse of aortic regurgitation. A collapsing pulse feels like a sudden unusually powerful upstroke followed by a palpable 'whoosh' as the blood rushes away and pours back through the incompetent aortic valve into the left ventricle. Continue to move up the arm and comment on the need to check the patient's blood pressure (or lying and standing blood pressures if relevant). This could be mentioned once your examination is complete but the examiner may give you a blood pressure reading if you mention it at this stage. A wide pulse pressure raises the possibility of aortic regurgitation and a narrow one aortic stenosis. Hypotension or a postural drop will be relevant if there is a history of collapse, dizziness or new medication. Also if it is left until the end you may forget to mention the blood pressure (or run out of time).

JAYPEE BROTHERS

Head and neck examination

Move up to the patient's face and examine the eyes for:

- Conjunctival pallor (suggesting anaemia)
- Cholesterol deposits (xanthelasma) in the skin below the eyes or corneal arcus, both suggesting hyperlipidaemia

Next examine the tongue for central cyanosis.

Examine the internal jugular vein in the neck to assess the patient's jugular venous pressure (JVP). This is measured with the patient at 45° and is reported as how many centimetres above the sternal angle the JVP can be seen, as shown in **Figure 3.2.1**. Unlike the carotid pulse the JVP is biphasic and not palpable. To help identify the JVP gentle pressure can be applied over the liver which causes increased venous return and distension of the neck veins. This hepatojugular reflux then subsides as a healthy heart is able to accommodate the increased venous return by increasing cardiac output. In patients with congestive cardiac failure the venous distension may persist as the cardiac output cannot increase adequately.

Observe and palpate the carotid pulse. A forceful carotid pulse associated with the ear lobes moving may suggest aortic regurgitation (Corrigan's sign). A slow rising pulse may be due to aortic stenosis.

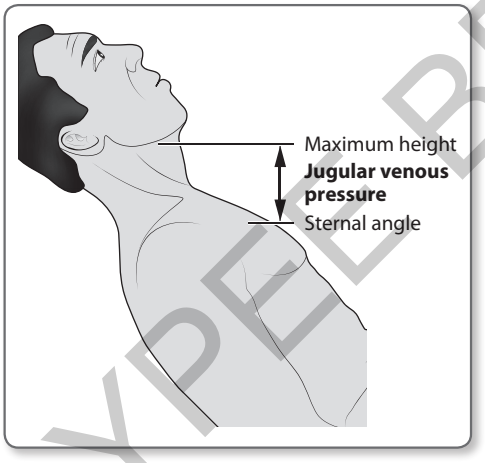

Figure 3.2.1 Measuring the jugular venous pressure, with the patient at 45° to the horizontal.

Precordium examination

Palpate the precordium. Begin by locating the apex beat and determine its position with reference to both the rib space it lies within and the clavicle (the normal position is in the fifth intercostal space in the mid-clavicular line). Next rest your hand over each valve area feeling for any heaves or thrills (palpable murmurs) associated with valve disease. Consider palpating below the lateral part of the left clavicle to demonstrate or exclude the presence of a cardiac device implanted under the skin.

JAYPEE BROTHERS

Auscultation

Perform auscultation while palpating the carotid or brachial pulse upstroke to time the first heart sound. The first heart sound is caused by the mitral and tricuspid valves closing, while the second heart sound is the aortic and pulmonary valve closing. Identify these and any added sounds.

Auscultate the:

- Apex with the diaphragm
- Apex with the bell while positioning the patient on their left side in expiration (for mitral stenosis – the bell is used for low pitched sounds)
- Left axilla for radiation of a mitral regurgitation murmur
- Remaining three valve areas (**Figure 3.2.2**) with the diaphragm
- Carotids for radiation of an aortic stenosis murmur (or a carotid bruit)
- Left sternal edge while leaning forward in full expiration (for aortic regurgitation)

While the patient is sitting up, auscultate the lung bases for crackles signifying left ventricular failure and palpate for sacral oedema.

Finally expose the lower legs and palpate for pedal oedema, you may also note scars from saphenous vein harvesting for bypass.

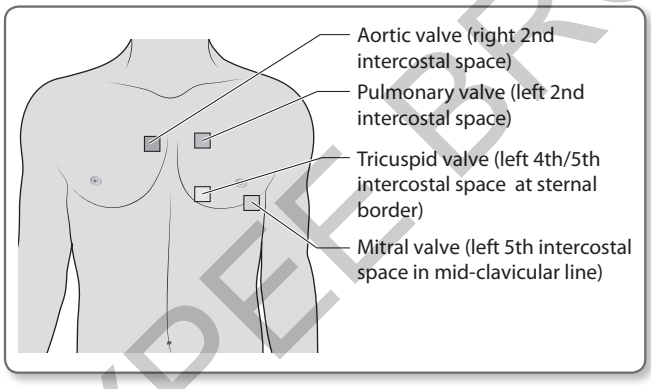

Figure 3.2.2 Auscultation positions for heart valves.

Ending the examination

Thank the patient, offer to help them redress and ensure they are comfortable.

Tell the examiner you would like to:

- Examine the peripheral pulses (and check for radiofemoral delay)
- See an ECG
- See a urine dip to exclude haematuria/proteinuria (as immune complex deposition in endocarditis may lead to glomerulonephritis)

JAYPEE BROTHERS

Common cases

Aortic stenosis

The pulse may be slow rising. The apex beat will normally be undisplaced with a possible systolic thrill palpable over the aortic area. There will be a harsh ejection systolic murmur loudest in the aortic area radiating into the neck. There may be a narrow pulse pressure (**Figure 3.2.3**).

Mitral regurgitation

The rhythm may be atrial fibrillation. The apex beat may be thrusting and displaced inferiorly and/or laterally with a possible systolic thrill. The murmur is pansystolic and usually radiates into the axilla (**Figure 3.2.3**).

Aortic regurgitation

The pulse is collapsing in character with a wide pulse pressure. The apex beat may be thrusting and displaced inferiorly and towards the axilla. There is an early diastolic murmur audible at the left sternal edge. It is best heard with the patient leaning forward in full expiration.

The large volume pulse of aortic regurgitation is associated with many additional signs such as Quincke's (nail bed pulsation), de Musset's (head nodding) and Corrigan's (carotid pulsation causing the ear lobe to twitch) (**Figure 3.2.3**).

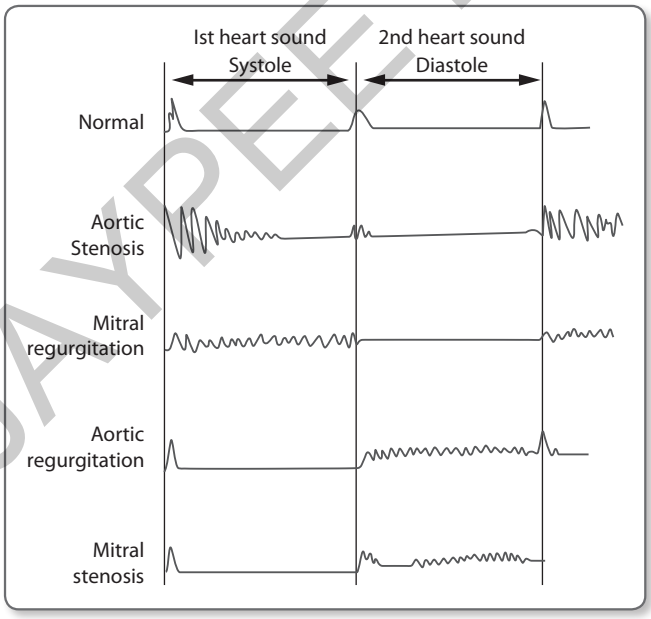

Figure 3.2.3 Heart sounds in valve pathology.

JAYPEE BROTHERS

Mitral stenosis

There may be a malar flush or a left thoracotomy scar from a mitral valvotomy. The rhythm may be atrial fibrillation. The apex will typically be undisplaced. The murmur is a mid-diastolic rumbling (hence best heard with the bell) sound over the mitral area and is most easily picked up with the patient rolled to their left (**Figure 3.2.3**).

Prosthetic valves

There may be a midline sternotomy scar (although an increasing number of patients are having aortic valves replaced endovascularly). Bruising may be apparent if the patient is anticoagulated (routine with an artificial valve). A clicking sound may be audible even without a stethoscope.

A click (artificial valve) or loud (tissue valve) first heart sound and a diastolic flow murmur suggest a mitral valve replacement.

A normal first heart sound, a systolic flow murmur and click or loud second heart sound suggest an aortic valve replacement.

A normal examination

If you have failed to identify any abnormal clinical signs, don't be afraid to say so. A normal examination is always a possibility.

Scenario

Mrs Hall has attended after a collapse. You see her in the major's area of the ED. Examine her cardiovascular system and then explain your diagnosis and management plan to her.

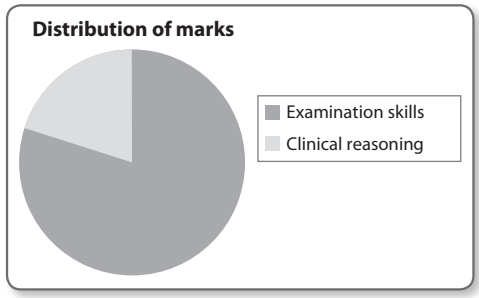

Mark sheet	Achieved	Not achieved
Introduces self to patient appropriately		
Confirms patient identity		
Explains reason for examination and obtains consent		
Enquires regarding presence of pain and offers analgesia if needed		
Cleans hands appropriately		
Positions and exposes patient correctly		
Performs initial inspection from end of bed		
Inspects hands and fingernails		
Palpates radial pulse and determines heart rate and rhythm		
Examines for a collapsing pulse		

Cont'd...

JAYPEE BROTHERS

Cont'd...

Mark sheet	Achieved	Not achieved
Comments on the need to check blood pressure		
Inspects eyes for cholesterol deposits/pallor and mouth for cyanosis		
Examines jugular venous pressure		
Palpates carotid pulse		
Palpates apex beat and determines its position		
Palpates for heaves/thrills over precordium		
Auscultates all four valve areas		
Uses correct manoeuvres for mitral stenosis and aortic regurgitation		
Auscultates for radiation to axilla and carotids		
Auscultates lung bases		
Palpates for sacral and pedal oedema		
Comments on need to examine peripheral pulses		
Thanks patient and offers to help patient dress		
Correctly identifies clinical signs		
Correctly states diagnosis		
Describes appropriate management plan		
Global mark from patient		
Global mark from examiner		

JAYPEE BROTHERS

3.3 Abdominal examination

Begin by introducing yourself, washing your hands, confirming the name of the patient and asking for permission to examine them.

Ask if the patient has any pain and offer analgesia if appropriate.

The patient should be positioned flat with a pillow under their head and their arms relaxed by their sides. Their upper body should be exposed from the level of the pubis symphysis upwards.

General inspection

Stand at the end of the bed and perform a general inspection. The main features to note are:

- The presence of pallor, jaundice, spider naevi, gynaecomastia, abdominal distension, visible swellings and dilated veins on the abdominal wall
- The presence of any scars/stomas/catheters/drains (**Figure 3.3.1**)

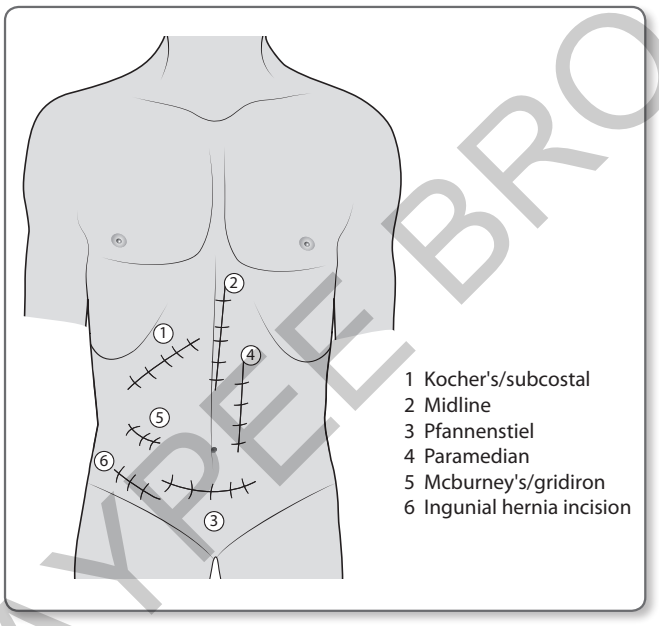

Figure 3.3.1 Common abdominal scars.

Hand inspection

The next step is to approach the patient and examine both hands for:

- Clubbing (can be present in cirrhosis, inflammatory bowel disease, malignancy and malabsorption)
- Leukonychia (white nails due to hypoalbuminaemia)
- Palmar erythema
- Dupuytren's contracture

Ask the patient to hold their hands in front of them and observe for asterixis (liver flap)

Inspect the patient's arms for fistulae related to dialysis. If a fistula is present palpate it to note whether or not it is functioning.

JAYPEE BROTHERS

Head and neck examination

Move up to the patient's face and examine for:
- Conjunctival pallor suggesting anaemia
- Oral mucosal ulceration
- Examine the tongue for central cyanosis

If the patient is able to do so comfortably ask them to sit up and palpate their neck for cervical lymphadenopathy. A hard palpable lymph node in the left supraclavicular fossa (Virchow's node) suggests gastrointestinal malignancy and if lymph nodes are present in the neck, the axillae and groin should also be examined. While they are sitting up inspect their back for spider naevi and for any scars that you would otherwise miss e.g. over the loins.

Abdominal examination

Return the patient to the supine position and note relevant signs on their chest:
- Gynaecomastia
- Spider naevi

Take a further opportunity to inspect the abdomen to ensure no scars or other signs are missed. Ensure inspection includes looking round to the patient's left flank. Then begin palpating the abdomen with light palpation only. Great care should be taken not to hurt the patient. Palpation should be performed using the pulp of the fingers rather than the finger tips and the patient's face should be observed for any signs of discomfort. The abdomen should then be examined again with deeper palpation.

Next, focus on the liver, spleen and kidneys in turn. To palpate the liver, start in the right iliac fossa and palpate towards the right hypochondrium while the patient takes deep breaths (**Figure 3.3.2**). If a liver edge is felt gently try to assess if it is smooth or nodular. Tenderness in the right hypochondrium with inspiration, where the patient stops breathing in, 'catches' their breath and winces represents a positive Murphy's sign. This is most commonly caused by cholecystitis.

For the spleen, begin again in the right iliac fossa and while the patient takes deep breaths palpate towards the left hypochondrium. If the spleen is not felt the patient should be asked to roll onto their right hand side and the left subcostal margin palpated for a splenic tip, which is found in mild splenomegaly.

Each kidney should then be examined bimanually. Candidates must be able to identify or at least form an appropriate differential diagnosis for any masses they identify (**Box 3.3.1** and **Box 3.3.2**).

Then percuss over the liver and spleen to assess the size from their upper to lower border and palpate in the midline for an abdominal aortic aneurysm.

Shifting dullness of ascites should be assessed for. First percuss the flanks for stony dullness. If this is present ask the patient to roll onto their side and assess whether the level of stony dullness has shifted.

Finally auscultate the abdomen to check for normal bowel sounds and the presence of bruits over the aorta and renal arteries.

JAYPEE BROTHERS

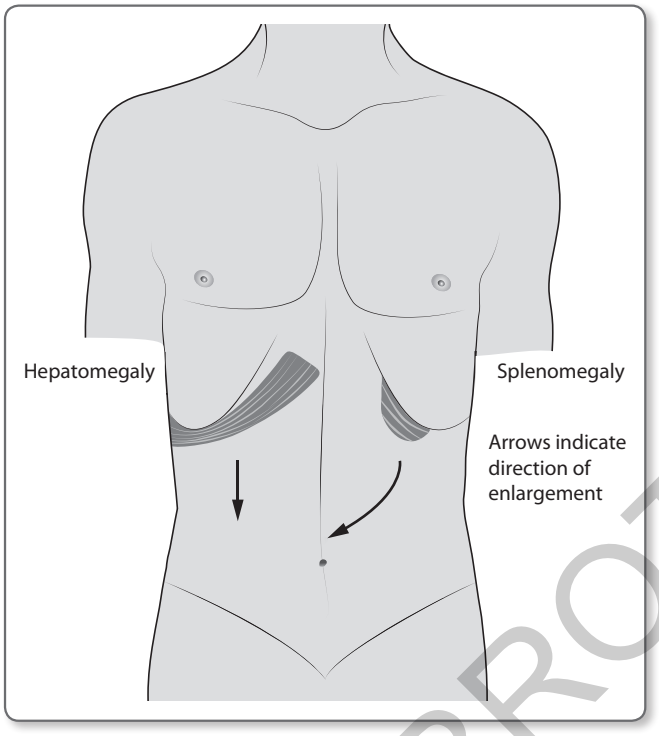

Figure 3.3.2 Hepatomegaly and splenomegaly.

Ending the examination

Thank the patient, help them redress and ensure they are comfortable.
Tell the examiner you would like to:

- Examine the external genitalia and hernial orifices
- Perform a rectal examination
- See the result of a urine dip analysis

Box 3.3.1 Distinguishing spleen from kidney

Unlike the kidney, the spleen:

- is not bimanually palpable (ballotable)
- does not have a palpable upper border (you can't get above it)
- moves down on inspiration
- is dull to percussion
- has a notch on its lower medial border

JAYPEE BROTHERS

Box 3.3.2 Abdominal masses by site. On occasion it may simply be necessary to give a differential diagnosis for an abdominal mass and a plan for investigation and management. This table offers a differential list based on the position of any mass

Right hypochondrium Liver (causes as below) Kidney	**Epigastrium** Pancreatic cyst/pseudocyst/ malignancy Lymphoma Gastric malignancy Aortic aneurysm	**Left hypochondrium** Spleen (causes as below) Kidney
Right lumbar Kidney	**Umbilical** Aortic aneurysm	**Left lumbar** Kidney
Right Iliac fossa Caecal malignancy Crohn's disease Transplanted kidney Tuberculosis mass Ovarian cyst/malignancy	**Hypogastric (suprapubic)** Bladder Uterine fibroids/malignancy/ pregnancy	**Left Iliac fossa** Transplanted kidney Colon malignancy Faeces Ovarian cyst/malignancy Diverticular abscess

Common cases

Chronic liver disease

Causes:
- Alcohol
- Viral hepatitis
- Autoimmune hepatitis
- Primary biliary cirrhosis
- Deposition disorders (Haemochromatosis: a disorder of iron metabolism leading to deposition in many organs and causing grey pigmentation of the skin. Wilson's disease: where copper accumulates in the liver and central nervous system sometimes causing pathognomonic Kayser–Fleischer rings in the eyes)

Hepatosplenomegaly

Causes:
- Myeloproliferative disease
- Lymphoproliferative disease
- Liver cirrhosis and portal hypertension
- Infection (viral hepatitis, cytomegalovirus, malaria, leishmaniasis, schistosomiasis, tuberculosis)

Hepatomegaly

Causes:
- Cirrhosis (secondary to alcohol, drugs, autoimmune or deposition disorders)
- (Note: the liver is not always enlarged in cirrhosis)
- Infections (viral hepatitis, infectious mononucleosis, Lyme disease)
- Malignancy (in which the liver may be hard and irregular)
- Congestive cardiac failure

JAYPEE BROTHERS

FRCEM Final OSCE: 125 OSCE Stations

THIRD EDITION

FRCEM Final OSCE: 125 OSCE Stations is the ideal revision guide for candidates preparing for the OSCE element of the FRCEM Final exam. Each station opens with a summary of relevant clinical information, followed by a practice OSCE scenario and examiner mark sheet to provide a comprehensive set of materials with which to prepare for the exam.

Thoroughly updated to match the complexity encountered in the fellowship level exam and with new OSCE scenarios, **FRCEM Final OSCE: 125 OSCE Stations** remains the 'go-to' revision tool for the OSCE element of the FRCEM examination.

- Each station includes a scenario, mark sheet and actor instructions, enabling candidates to practise in the roles of candidate, examiner and actor, either independently or in small groups under exam conditions
- New and updated OSCEs to reflect the level of complexity encountered in the latest fellowship exam
- Background information facilitates revision and consolidates understanding of key concepts

JP medical publishers

www.jpmedpub.com

ISBN 978-1-909836-97-6