Textbook of Color Doppler Imaging

4th Edition

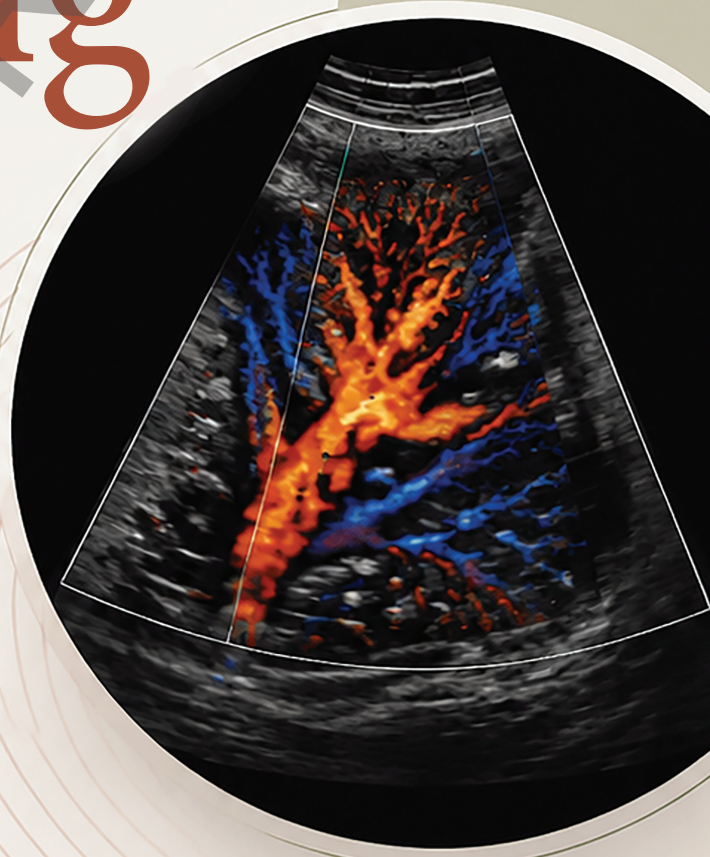

Sumeet Bhargava
Satish K Bhargava
Rajul Rastogi

JAYPEE BROTHERS

JAYPEE

CONTENTS

Chapter 1: The Story of Doppler 1

- *History* 1
- *Real-Life Applications of the Doppler Effect* 1
- *Medical Applications of the Doppler Effect* 2

Chapter 2: Basic Hemodynamics 3

- *Physical Aspects* 3
- *Venous Hemodynamics* 10

Chapter 3: Doppler Principle and Instrumentation 13

- *Doppler Effect* 13
- *Instrumentation* 16
- *Multigated PW Doppler Systems* 19

Chapter 4: Doppler Spectral Analysis 21

- *Sample Volume* 21
- *Direction of Flow* 22
- *Waveform* 22
- *Envelope Traces of the Doppler Spectrum* 23
- *Diagnosis of Arterial Obstruction* 25

Chapter 5: Color Flow Imaging 29

- *Principles of Color Flow Imaging* 29
- *Clinical Advantages of Color Flow Imaging and its Limitations* 31
- *Power Doppler Flow Imaging* 33
- *Harmonic Imaging* 34

Chapter 6: Contrast Agents in Ultrasound 36

- *The Impact of Contrast Enhancement* 37
- *Clinical Applications* 38
- *Transcranial Doppler* 39
- *Carotid Doppler* 40
- *Renal Doppler* 40
- *Portal Vein Doppler* 41
- *Peripheral Arterial Doppler* 41
- *Inferior Vena Cava* 41
- *Peripheral Venous Doppler* 41
- *Functional Uses of Contrast Doppler* 41

JAYPEE BROTHERS

Chapter 7: Cerebrovascular Doppler Sonography 45
- *Technique* 45
- *Abnormal Findings* 47
- *Doppler Criteria* 47
- *Direct Stenotic Measurements* 48
- *Vertebral Arteries* 52

Chapter 8: Transcranial Doppler Sonography 56
- *Basic Instrumentation* 56
- *Arterial Stenosis and Occlusion* 62
- *Middle Cerebral Artery Stenosis/Occlusion* 62
- *Assessment of Effects of Extracranial Occlusive Disease* 64
- *Emboli Detection* 65
- *Intraoperative and Procedural Monitoring* 66
- *Functional Reserve Testing* 68
- *Other Uses* 68

Chapter 9: Doppler in Liver 71
- *Doppler In Liver Technique* 71
- *Normal Patterns* 71
- *Portal Hypertension* 72
- *Qualitative Findings* 73
- *Semiquantitative Findings* 75
- *Quantitative Findings* 77
- *Evaluation of Medical Treatment in Portal Hypertension* 77
- *Color Doppler in Hepatic Lesions* 80
- *Liver Transplantation* 83

Chapter 10: Role of Color Doppler in Splenic Lesions 88
- *Splenic Infarction* 89
- *Intrasplenic Pseudoaneurysm* 89

Chapter 11: Color Doppler in Pancreas 91
- *Pancreatic Transplantation* 91

Chapter 12: Role of Color Doppler in Urinary System 94
- *Color Doppler Sonography in Detection of Vesicoureteric Reflux* 107
- *Doppler Evaluation of the Prostate* 108

Chapter 13: The Retroperitoneum and Great Vessels 113
- *Aorta* 113
- *Aortic Pathology* 115
- *Aortic Grafts* 120
- *Complications of Graft Implantation* 120
- *Aortic Branches* 121
- *Superior Mesenteric Artery* 121
- *Renal Arteries* 123
- *Inferior Vena Cava* 123
- *IVC Branches and Tributaries* 125
- *Intraoperative Applications of Doppler* 125

JAYPEE BROTHERS

Chapter 14: Current Role of High-Resolution Ultrasonography and Color Doppler in the Diagnosis of Scrotal Diseases 128
- *Normal Ultrasound Anatomy* 128
- *Testicular Torsion* 129
- *Inflammatory Diseases* 130
- *Scrotal Trauma* 131
- *Hydrocele* 132
- *Undescended Testis* 133
- *Scrotal Calcifications* 134
- *Varicocele* 134
- *Scrotal Hernias* 134
- *Testicular Tumors* 134

Chapter 15: Duplex Ultrasonography of Erectile Dysfunction 138
- *Anatomy and Physiology of Penile Erection* 138
- *Evaluation of Erectile Dysfunction* 138
- *Treatment of Complications* 141
- *Peyronie's Disease* 141

Chapter 16: Color Doppler of Small Parts 143
- *Skin and Subcutaneous Tissues* 144
- *Vascular Lesions* 145
- *Parathyroid Adenoma* 151
- *Color Doppler Imaging in Orbit* 153

Chapter 17: Doppler Imaging of Peripheral Arteries 156
- *Instrumentation* 156
- *Normal Anatomy and Doppler Waveform* 156

Chapter 18: Venous System 166
- *Lower Limb Veins* 166
- *Upper Limb Veins* 166
- *Characteristics of a Normal Vein* 168
- *Lower Extremity Deep Venous Thrombosis* 169
- *Chronic Deep Venous Thrombosis* 171
- *Upper Extremity Thrombosis* 172

Chapter 19: Intravascular Ultrasound: Newer Advances, Current Applications and Future Directions 175
- *Rationale for Intravascular Ultrasound Imaging* 175
- *Appearance on IVUS in Various Disease States* 177
- *Clinical Applications* 179
- *Miscellaneous Applications* 180
- *Limitations of Intravascular Ultrasound* 180
- *Future Directions* 180

Chapter 20: Role of Color Flow and Doppler in Obstetrics, Gynecology, and Infertility 183
- *Imaging Problems* 183
- *Clinical Uses* 183
- *Color Doppler in Gynecology* 185
- *Role of Color Doppler in Infertility* 193

JAYPEE BROTHERS

- *Role of Transvaginal Color Doppler in Other Conditions Associated with Infertility 196*
- *Tubal Evaluation 199*
- *Color Doppler in Relation to Obstetrics 201*

Chapter 21: Gray Scale Ultrasonography and Color Doppler Study in Fracture Healing 213
- *Experimental Study 213*
- *Clinical Study 213*

Chapter 22: 3D and 4D Ultrasound: Principles, Advantages, and Applications 217
- *Applications in Clinical Practice 217*
- *Limitations of Volumetry USG 218*

Chapter 23: The Renaissance of Hemodynamics: Integrating Artificial Intelligence in Doppler Imaging 220
- *The Artificial Intelligence Imperative: Mastering the Doppler Waveform 220*

Index ***225***

JAYPEE BROTHERS

CHAPTER 6

Contrast Agents in Ultrasound

JAYPEE BROTHERS

INTRODUCTION

The major motivation and need for the current rapid rate of development of contrast agents for ultrasound lies in the nature of the current performance limits of ultrasound and color Doppler. At present most Duplex and color Doppler imaging systems are capable of detecting flow from vessels whose lumina lies below the resolution of the image. The detection of such unresolved flow using Doppler systems can be demonstrated simply by using a Duplex scanner to create a power Doppler image of the kidney in which vessels not visible on gray scale image become visible using Doppler mode. These vessels are the arcuate and the interlobar branches of the renal arteries. Their diameter is known to be less than 100 μm and therefore below the resolution limits of the image. However, as we progress distally, the blood flows more slowly as the rate of bifurcation increases giving lower Doppler shift frequencies and the quantity of blood in a given volume of tissue also decreases, weakening the back scattered echo. Eventually a point is reached at which the vessel cannot be visualized and the Doppler signals cannot be detected.

Two factors determine where that point will lie—Doppler shift frequency and echo strength.

First the velocity of blood must be sufficient to produce a Doppler shift frequency that is distinguishable from that produced by the normal motion of tissue, and second the received intensity of the backscattered ultrasound must provide adequate signal strength for detection by the transducer above the acoustic and electric noise of the system. Using a higher frequency ultrasound helps in both aspects. The Doppler shift frequency corresponding to a given flow velocity increased in proportion to the transmitted sounds frequency and the backscattered intensity increases with the fourth power of transmitted frequency as predicted by the Rayleigh relationship. In practice the penetration of sound through tissue places an upper limit on the ultrasound frequency that can be used.

For deeper vessels of the abdomen ultrasound frequencies above 5 MHz produce blood echoes whose amplitude at the skin surface is too small for detection by most current systems. In this and many other applications involving small vessels, it is the strength of the backscattered echo rather than Doppler shift frequency that defers the smallest vessel from which Doppler signals can be detected. It also defines the scale of vasculature. It is possible to detect in a neovascularized mass or a collateral vessel to a vascular occlusion. For larger vessels the effect of increasing the echo from blood is to enhance the signal to noise ratio which again determines detectability in such vessels as the renal artery or the middle cerebral artery when approached transcranially. There is then clear clinical potential for contrast agents capable of enhancing the echo of moving blood especially in systemic arterial system.

The principal requirements for an ultrasound contrast agent are that it should be easily introducible into the vascular system, be stable for the duration of the diagnostic examination, have low toxicity and modify one or more acoustic properties of tissues that determine the ultrasound imaging process.

The essential mechanisms whereby microbubbles act as echo-enhancers are same as pertain to scattered echoes elsewhere, the echo intensity is proportional to change in acoustic impedance as the sound beam crosses from blood to the gas in bubbles. The impedance mismatch at such an interface is very high and essentially all the incident sound is reflected though all will not travel back to the transducer. However, though the reflection is near complete by itself. This would not produce a very effective enhancing agent because microbubbles are very small and present in only small numbers. The reflectivity is proportional to the sixth power of the particle-diameter and directly to their concentration.

Rather the intense echogenicity of microbubbles results from the fact that they resonate when insolated

and this makes them behave as though much larger and thus more echogenic than a rigid bubble of the same diameter (10^{14} × or larger). Maximizing this resonance is a critical aspect of this design. Obviously, the microbubbles must be made small enough to cross the capillaries (<7 μ) and like any other mechanical resonance system, the critical frequency depends on their diameter. It is a most fortunate coincidence that microbubbles in this size range happen to have their resonance frequencies in the 2–15 MHz. This most fortunate coincidence makes microbubbles such extremely effective reflectors that even in the low concentration after they have been dispersed throughout the systemic circulation, they produce some 20 dB of enhancement in echo strength-an increase of some 100-folds. Range of ultrasound frequencies that are used for clinical diagnosis microbubbles at (1–7 μ diameter) do not diffuse across the endothelium. So, there is no interstitial phase of enhancement. Thus, they are essentially markers for the blood pool (or for any other body space into which they have been placed) and their distribution is similar to those of tagged red cells. Typically, the effective duration of vascular enhancement is a few minutes after which the microbubbles dissipate although, this model is complicated by evidence that some microbubbles are taken up by the phagocytic cell systems and these have liver/spleen specific effects.

The techniques for making microbubbles have been devised both to control their size and to make them sufficiently stable to provide a clinically useful enhancement time of at least a few minutes.

Levovist

It consists of galactose ground into tiny crystals whose irregular surfaces act as nidation sites on which air pockets form when it is suspended in water. A trace of palmitic acid is added as a surfactant to stabilize the resultant microbubbles which therefore are in effect tiny soap bubbles.

Optison

It represents another class of microbubbles with a shell formed by sonicating a solution of human serum albumin. The resulting capsules are filled with a perfluorocarbon gas (perfluoropropane) whose high molecular weight shows dissolution and thereby prolongs the enhancement for several minutes.

Sonovue

It is a family of microbubbles whose membrane consists of phospholipids. In this case, the gas is sulphur hexafluoride which diffuses slowly like perfluoro compounds.

Extensive preclinical and clinical trials have demonstrated an excellent safety profile for intravenous injection of microbubbles. The total amount used is minute (<200/mL) compared to the dose of levovist and their small size makes embolization most unlikely.

The main unwanted effect is a mild and transient local discomfort at the injection site which results from the high osmolality of this agent.

THE IMPACT OF CONTRAST ENHANCEMENT

The arrival of the contrast agent some seconds after peripheral venous injection in the portion of the systemic vasculature is marked by a dramatic increase in signal strength. In spectral Doppler, this is seen as intensifying of the gray scale of the spectrum for spectral Doppler examinations that fail because of lack of signal strength, the effect of the contrast agent is to rescue the examination.

In color Doppler, the parameter mapped to color is the estimated Doppler shift frequency, which corresponds to the relative blood flow velocity. Color should therefore remain unaltered by contrast enhancement, what does change is the range of locations from which color signals are detected. The effect of contrast agent is to raise the signals from small vessels above that threshold to that point at which they are effectively detectable on a color image. Thus, more vessels appear in a contrast enhanced ultrasound image.

KEY POINTS

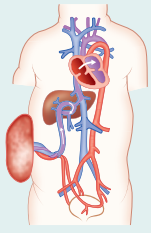

- Arcuate and interlobar branches of renal arteries and arteries (less than 100 μ) has low resolution to make image.
- Hence, shift frequency and echo strength determines the visualization of small vessels.
- Contrast agents increases both above and hence, act as echo enhancer.
- Echo enhancers are microbubbles—levovist, optisan, and sonovue.
- Non-vascular use—tubal patency in infertility, ureteric reflux in children with urinary tract infections.
- Vascular use—cardiac, transcranial, carotid, and renal.

Studies have demonstrated the capacity of contrast agents to increase the technical success rate of Doppler ultrasound, e.g., in clinical transcranial Doppler studies of middle cerebral artery administration of 10 mL of levovist in concentration of 200, 300, 400 mg/mL resulted in dose dependent increases in both surgical intensity and duration of enhancement. At a concentration of 400 mg/mL levovist

JAYPEE BROTHERS

increased the Doppler signal by approximately 25 dB. The time to peak enhancement was between 30 and 60 seconds and duration of enhancement was reported to be sufficiently long to be clinically useful.

If the target vessel is larger than the flow detectable, the impact of the agent may be to shorten the examination time. In one study, levovist halved the examination time for the Duplex investigation of renal artery stenosis. Yet another study suggested improved accuracy in measuring peripheral vascular velocity when contrast is used.

In a satisfactory color Doppler study of the abdomen one use of the agent might simply be to enable a higher ultrasound frequency to be used, exploiting the agent to counter the higher tissue attenuation. In such a case, contrast enhancement translates into higher spatial solution.

Alternatively, the color system may be set to use fewer pulses per scan line (that is a lower ensemble length) while still achieving the same sensitivity to blood flow by means of contrast enhancement. The agent will then provide the user with a higher frame rate.

An important general concept in the practical use of microbubble enhancing agents is their fragility, so that, they are readily destroyed by the insolating beam. In some situation strategies to preserve them improve their visualization significantly. The most important example is in echocardiography where the entire microbubble population generally passes through the ultrasound beam. A major increase in both the amount and duration of enhancement can be achieved by scanning intermittently (triggered by ECG) rather than continuously such approaches allow gray scale visualization of myocardial perfusion.

If the bubbles in a tissue slice are deliberately destroyed, then their reappearance is related to the rate of inflow of fresh bubbles which depends on the tissue flow rate. This destruction-reperfusion approach has been used for the myocardium and can be expected to be useful also in kidney and other abdominal organs.

As microbubbles resonate in the ultrasound beam, they behave like a musical instrument and emit harmonic signals at double their resonance frequency. If a scanner is modified to detect these harmonic signals and use those to form the image or Doppler trace, the confusing clutter signal from tissue stationary or moving are suppressed and a cleaner image or trace is produced.

In harmonic mode, echoes from the contrast agent are received preferentially by means of a bandpass filter whose center frequency is at the second harmonic. Echoes from the solid tissues as well as from red blood cells themselves are suppressed.

The particular potential application of this entirely new diagnostic method is the detection of blood flow in small vessels surrounded by tissue that is moving in the branches of coronary arteries or in the myocardium itself as well in the parenchyma of abdominal organs.

Another way to improve the signal/clutter ratio is to use a pair of pulses to form each B-mode line, the second of each pair being inverted in phase. The final image line is formed by summing the two resultant echo trains. Since the echoes from linear reflectors such as tissue, are inverted they cancel out but the non-linear response of the microbubbles means that their echoes are not exactly symmetrical in the compression and expansion phase and so they do not cancel out. This phase inversion scan mode has similar effect in reducing clutter as the harmonic mode but with the important advantage of retaining the full spatial resolution of B-mode which is compromised in the latter because a narrow band pulse must be used.

CLINICAL APPLICATIONS

Non-vascular Use

Contrast agents have been used to evaluate tubal patency in infertility and ureteric reflux in children with renal tract infections.

Echovist is installed into the uterine cavity via a small Foleys catheter and using transvaginal sonography tracking of the echogenic contrast along the tubes and into the adnexal peritoneum is observed to establish tubal patency **(Figs. 6.1 to 6.3)**. Some false negative results may be obtained due to tubal spasm and it does not offer the same anatomical detail as HSG when tubal surgery is an option. However, it a simple OPD procedure and is radiation free.

For vesicoureteric reflux, levovist is instilled into the bladder as for conventional MCU. The lower ureters and renal pelvis are examined transabdominally as the bladder is filled to stimulate micturition. Sensitivity seems to be higher than for X-ray MCU, perhaps because there are no time constraints on imaging and the level of reflux can be assessed using the same criteria. Avoidance of radiation is an obvious advantage though the posterior urethra is not well seen. So, it may not be possible to replace the initial investigation in boys. For girls and for all follow-up studies, the US MCU has become standard in many pediatric departments.

KEY POINTS

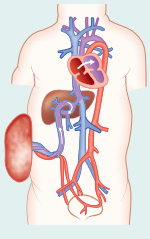

- Transcranial, carotid, renal, portal vein, peripheral, arterial, IVC, and venous.
- Functional uses of contrast Doppler.
- Mature scar—no vascularity while tumour recurrence shows marked vascularity.
- Hepatocellular carcinoma—fill in arterial phase while regenerating nodule and adenocarcinoma fill slowly.

JAYPEE BROTHERS

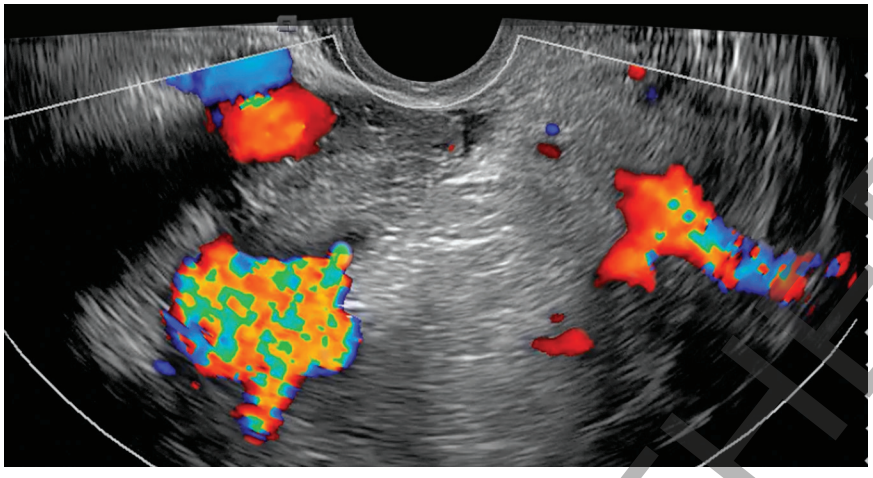

Fig. 6.1: Hydrosalpinx-contrast agent (Agitated Hemocele/Saline) with Color mode.

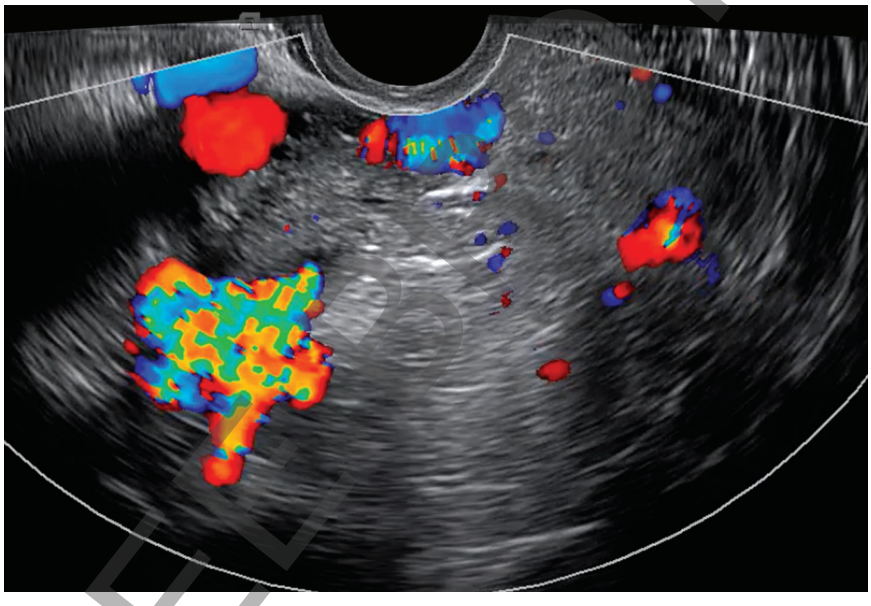

Fig. 6.2: Color mode—Patent tube.

Vascular Uses

Cardiac

The use of contrast media is to opacify the cardiac chamber. This improves delineation of the left ventricular endocardial border and allows better estimates of left ventricular function and measurement of ejection fraction. In many cardiology units, microbubble enhanced echocardiography has replaced isotope studies (particularly the MUGA scan) for left ventricular function. It is cheaper, quicker and avoids ionizing radiation.

The development of means to detect microbubbles in the myocardial capillaries is making myocardial perfusion estimates possible and ultrasound contrast stress echo studies are becoming more widely used. The possibility of studying the coronary arteries directly is also becoming an option.

■ TRANSCRANIAL DOPPLER

Transcranial Doppler (TCD) is a typical field where Doppler signals are routinely difficult to obtain because of the attenuation by the skull. Microbubbles improve signal intensity overcoming this technical difficulty. It allows a more complete depiction of the cerebral arterial system and basal veins. It is especially useful in depicting lesion with low blood flow velocities and low flow volume.

Cavernoma appears as echogenic areas with slow flow on Doppler. Flow within cavernoma themselves is undetectable but after Levovist enhancement, mean peak

JAYPEE BROTHERS

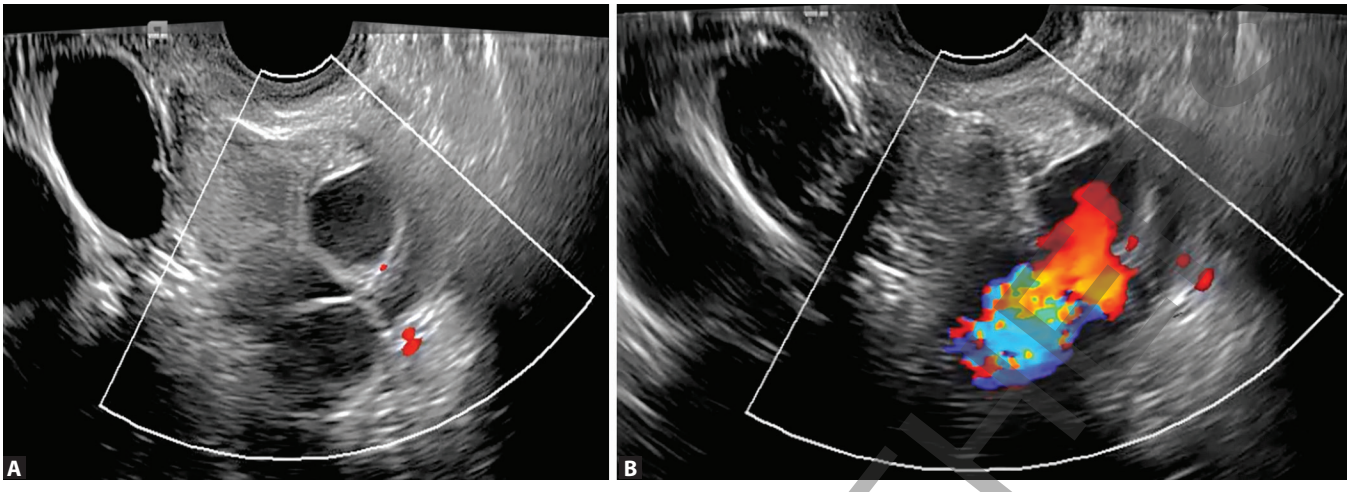

Figs. 6.3A and B: Distal turbulence in a case of hydrosalpinx (A) demonstrated by contrast agent (Agitated Hemocele/Saline) (B).

systolic flow velocities of 10–15 cm/sec are seen. Contrast enhanced TCD may therefore be especially useful in the intensive care unit as well as intra operatively and during postoperative follow-up.

As long as, there is good ultrasonic window through the temporal bone arteriovenous malformations can be detected without the need for enhancement because of their high velocity flows which is often bi- or multidirectional. Microbubbles may enhance delineation of the entire malformation and reveal even occult AVM.

Aneurysms, characteristically identified as sharp systolic bidirectional Doppler signal with a machine-like noise may be detected on unenhanced TCD but can be diagnosed with higher accuracy and at a smaller size with contrast enhanced TCD. Enhanced Doppler can be expected to assist in the management of subarachnoid hemorrhage in detecting possible sources of hemorrhage and in monitoring arterial spasm.

The diagnosis of cerebral vascular stenosis is based on demonstrating aliasing on color Doppler supported by characteristic changes in the Doppler frequency spectrum especially high velocities. In patients with poor signal transmission through the temporal bone, microbubble enhancement reduces the failure rate and may be especially helpful in distinguishing high-grade stenosis from occlusion. Low volume flow at high grade stenosis may be missed on transcranial ultrasound because the signals are weak, exactly as with the extracranial carotid arteries.

The increased signal intensity after microbubble enhancement allows a complete three-dimensional reconstruction of the circle of Willis and improves the delineation of tumor feeding vessels and the identification and localization of highly vascularized areas within the tumor. Additionally, 3D display may rescue the examiner dependence of vascular ultrasound by allowing offline analysis. It may also help overcome some of the limitation of access to cerebral vessel by allowing display of reformatted sections in planes that cannot be obtained directly.

To date harmonic imaging has been disappointing in transcranial Doppler because the stimulation of microbubbles to resonate in a non-linear mode depends upon achieving a higher acoustic intensity than for simple resonance and this is difficult to achieve through the attenuating skull bone. The recently described technique of wideband harmonic imaging seems to be less dependent on sound pressure suggesting a potential for transcranial imaging.

CAROTID DOPPLER

Echo enhancement by contrast allows carotid Doppler to be performed by less skilled operators and with inexpensive scanners so the technique could become more widely used. Enhancement may also lead to better delineation of plaque ulcers. The ability to improve demonstration of trickle flow in very light stenosis is of undoubted clinical value because these patients benefit from endarterectomy whereas surgery is of no benefit once the internal carotid artery has occluded.

RENAL DOPPLER

Preliminary studies have shown that Levovist improves the diagnosis of significant renal artery stenosis by substantially reducing the failure rate for both the main renal arteries and for changes in intrarenal waveforms. This resulted in fewer false negative and false positive results when compared to digital subtraction angiography. This could increase the value of ultrasound screening for renovascular hypertension to the extent that microbubble enhancement becomes a routine part of investigation. Ultrasonic diagnosis of renal vein thrombosis is difficult because access to the renal veins may be limited and also because the process commonly

JAYPEE BROTHERS

starts in small veins at lobar level and then propagates to the main renal vein. By this stage collaterals open up both at the capsule and in the renal hilum thus the demonstration of venous signal at renal hilum does not completely exclude renal vein thrombosis. Better delineation of the venous anatomy following enhancement may prove to be an important application of microbubbles though there are no reports on this use.

Microbubble enhancement provides valuable added confidence in the diagnosis of acute transplant occlusion affecting the surgical anastomosis.

PORTAL VEIN DOPPLER

Echo enhanced Doppler provides useful information in a failed Doppler study. Enhancement allows a decision between a technical failure and true absence of flow. This situation is common is cirrhosis because of the highly attenuating liver and because the portal vein flow velocity may be very low. A confident diagnosis of portal vein patency can be achieved more often so that DSA can be avoided in some cases.

PERIPHERAL ARTERIAL DOPPLER

Signal strength is improved by microbubble enhancement and this is likely to prove helpful in improving signals from segments where shadowing from calcific plaques attenuates the signals and from very light stenosis where the flow velocity drops (trickle flow). In addition, contrast speeds up to procedure. Levovist has been shown to improve the signals from leg arteries in a clinical trial but the diagnostic advantage has not been evaluated systematically.

INFERIOR VENA CAVA

Inferior vena cava (IVC) thrombosis is occasionally difficult to diagnosis especially in the infrarenal portion which is often obscured by intestinal gas. A microbubble enhancing agent might be very useful here and for the same reason, in the iliac veins in the pelvis. Echovist injected into a vein in the foot improves visualization of the cava and of the flow disturbances around caval filters. Whether a microbubble injected into a distant (antecubital) vein would also be useful has not been studied systematically.

PERIPHERAL VENOUS DOPPLER

Unenhanced Doppler may fail in the diagnosis of deep vein thrombosis especially where the leg is swollen or obese and in diagnosis of below-knee, deep vein thrombosis. As with other vascular beds these problems amount to between a few and 10%.

A problem with microbubbles is the dilution of contrast agent because of the large volume of these capacitance vessels as reflected in the partial success reported for Echovist injections directly into veins of foot when compared to limited value of Levovist injected into an antecubital vein. Since this is such an important clinical problem, active research continues and it may be that infusion techniques will improve the clinical usefulness of microbubble agents for DVT.

FUNCTIONAL USES OF CONTRAST DOPPLER

The clinical applications can be divided into those that interrogate the entire hemodynamics of an organ and those that study only one region, e.g., a tumor. There have been two main whole organ studies looking at the liver and the transplanted kidney.

For the liver either the inflow or the outflow can be chosen and in both the principle is to separate the venous from the arterial signals because the normal balance whereby some 25% of hepatic flow is arterial is shifted toward much higher proportions in diseases where there is arteriovenous shunting especially cirrhosis and malignancy.

The inflow measurements were originally made by estimating the flow in the hepatic artery and portal vein using conventional spectral Doppler to obtain the mean flow velocity and multiplying this by the vessels area to obtain the Doppler perfusion index—unfortunately the excellent results initially reported have proved to be difficult to reproduce but a microbubble enhanced DPI promises to be more easily reproduced. In this method a bolus of contrast is tracked using a power Doppler gate that covers both artery and vein and the relative slopes of the two arrival curves are used to derive the two values. In the outflow method a spectral Doppler gate is placed over a hepatic vein and the relative slopes of the two arrival curves is used to derive the two values. In the outflow method a spectral Doppler gate is placed over a hepatic vein and the arrival time of an IV bolus is measured. In both cirrhosis and metastatic disease, the arrival time is much earlier than in patients with chronic hepatitis or controls and this may allow early detection and avoid the need for biopsies. For the transplant kidney a spectral doppler gate that covers the artery and the vein and is used to track the arrival time of the bolus and from these the true arteriovenous transit can be calculated. It seems to be longer in rejection than in acute tubular necrosis and so unnecessary biopsies might be avoided.

The regional approach has been used for malignancies seeking to improve differential diagnosis by revealing features of neovascularization, e.g., in the liver.

Many studies in the breast show that the arrival time in cancers is earlier than in benign masses though some cases of benign breast change have been confusing especially those that have an inflammatory component.

JAYPEE BROTHERS

The lack of vascularity in mature scars in comparison to the marked vascularity of tumor recurrence has emerged as a proven clinical tool for this problem. In liver a variety of temporal patterns have been described that are generally similar to those seen in triple phase CT. Malignancies especially hepatocellular carcinomas fill during the arterial phase a few seconds after injection while regenerating nodules and hemangioma fill slowly, the latter typically from the periphery and usually in complete **(Figs. 6.4A to D)**. Focal nodular hyperplasia shows similar temporal features to malignancies though their liver specific phase discriminates them well **(Figs. 6.5A to C)**.

An interesting way to make use of the fragility of microbubbles is to set up an infusion for steady blood level, apply a destructive pulse to a region of interest and then with non-destructive interrogating pulse watch for reperfusion as the slice fill with microbubbles. This reperfusion kinetic method has been applied to the myocardium where it shows great promise as a way to detect regional perfusion defects caused by anastomotic failures or by rejection.

The liver specific phase of microbubbles seen after the agent has cleared from larger vessel is an example of tissue targeting. It occurs with agents that are phagocytosed by the reticuloendothelial system such as Sonovist, Sonazoid and Levovist. Clinically, this phase is significant because many lesions particularly malignancies do not take up the agents and so are highlighted as microbubble poor spaces.

In this phase, the microbubbles are not moving so conventional doppler does not detect them and they are not obvious on gray scale. Non-linear modes such as color doppler stimulated acoustic emission (SAE) or the phase inversion mode (PIM) imaging are needed for their depiction. The effect is transient especially with a fragile agent such as levovist because it depends on bubble destruction and so special scanning approaches have to be used taking care to minimize inadvertent exposure to the ultrasound. Allowing the vascular phase to clear (3 minutes with levovist) then scanning with slow sweeps through the region of interest and then reviewing the images in the cine loop is one practical approach. The scanner needs to be set for maximum output power using a low frequency and with the transmit few at the region of interest maximizing the SAE effect but it may also be possible to employ phase inversion techniques in a non-destruction mode. The effects can be produced in all subjects but are weaker when sound attenuation is high and with levovist fade over 30 minutes: the best effect is achieved 5–15 minutes after injection.

The SAE reveals most types of focal lesion as color defects and the increase in conspicuity is striking **(Figs. 6.6A and B)**. In a specific study where two blinded observers scored the SAE signal intensity. Both scored all

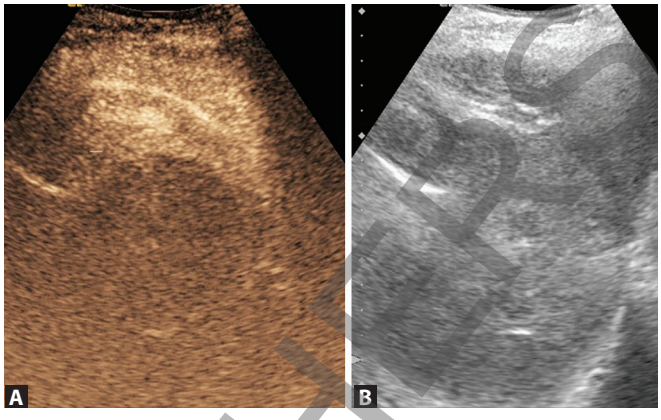

Figs. 6.4A and B: Hepatocellular carcinoma (A) Early arterial phase image of the lesion after contrast administration shows peripheral enhancement; (B) Gray scale image shows a well-defined mixed echogenicity mass lesion in the liver.

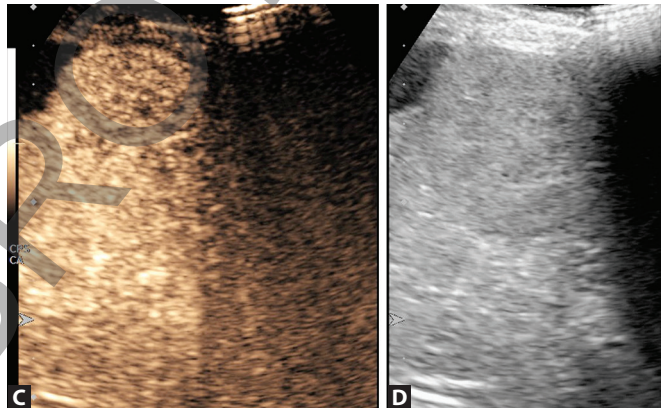

Figs. 6.4C and D: Hepatocellular carcinoma (D-right) shows progressive centripetal enhancement in the lesion is evident in late arterial phase (C-left).

15 metastases as low SAE with significantly more signal in 4 hemangiomas and in other benign lesions. One observer was able to distinguish hemangiomas from metastases completely, while the other scored an overlap in only one case (a metastasis with moderately high SAE). Scores similar to the surrounding liver were seen in two cirrhotic nodules, two focal fatty change and four focal nodular hyperplasia. High SAE activity seemed to correlate with a benign etiology and scanning in SAE mode improved specificity. Initial evaluation of suspected cases of focal nodular hyperplasia in SAE mode might replace sulfur-colloid radionuclide scanning.

Pim provides better spatial resolution so that new lesions smaller than 1 cm in diameter can be seen. It exploits the non-linearity of microbubble behavior based on the fact that bubbles are easily expanded by a negative pressure but progressively resist compression by increased

JAYPEE BROTHERS

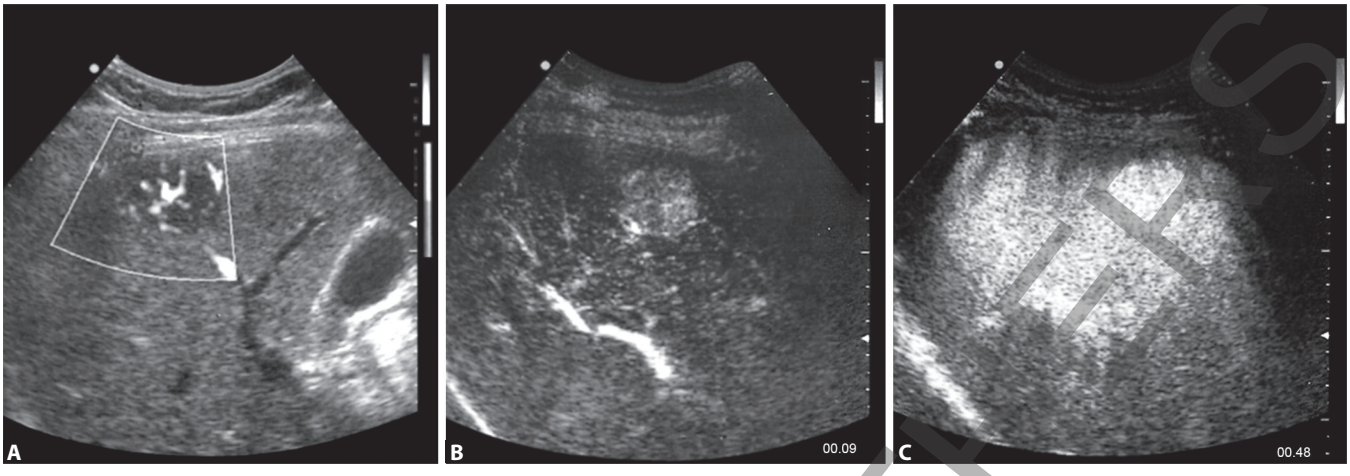

Figs. 6.5A to C: Focal nodular hyperplasia; (A) Increased vascularity is evident on power Doppler imaging; (B) Increased vascularity is also seen in early arterial phase, after contrast administration. A branch of right hepatic artery is also well visualized; and (C) Late arterial phase image shows progressive contrast enhancement.

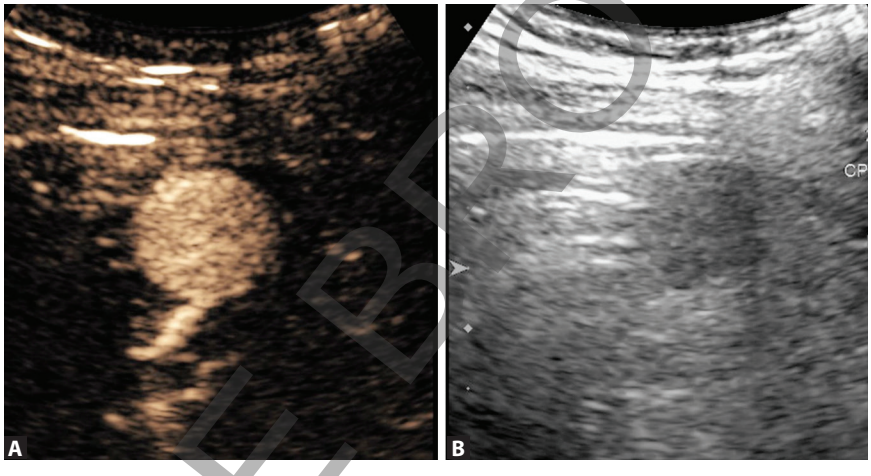

Figs. 6.6A and B: (A) After contrast administration, lesion appears as a hyperenhancing lesion with a feeding-vessel in early arterial phase representing metastasis; (B) A baseline sonogram shows an ill-defined hypoechoic lesion in the liver.

pressure. Thus they respond differently to the compression and rarefaction phases of the ultrasound wave and this information can be extracted by summing the echoes from each scan line from two pulses of inverted phase. Tissue returns opposite signals which cancel out but microbubbles give different signals and do not cancel completely. The system has a reduced frame rate but selects for the location of the microbubbles and retains the spatial resolution of gray scale imaging. In a preliminary study of 12 patients being screened for liver metastases strong gray scale signals filling the liver parenchyma were elicited while metastasis appeared as defects even if they were isoechoic on conventional ultrasound.

A multicenter study including 128 patients suspected of having liver metastases confirmed these results with greatly improved sensitivity especially for small (subcentimeter) lesions, fewer false positives and detection of some lesions that were too small to be detected on CT but were seen on gadolinium enhanced MRI.

Although, focal diseases in the liver is the most important application, these agents also collect in normal spleen and this has proved to be useful in distinguishing splenunculus from lymphadenopathy and in detecting small intrasplenic masses such as in lymphoma.

Limitations of both these methods include their transient effect fall off in the far field and artefacts such as shadowing. A difficulty with liver specific phase imaging using levovist is obtaining proof of the nature of the defects seen because the transient effect makes biopsy almost impossible.

This may be resolved with the more persistent agents undergoing clinical trials.

Stimulated acoustic emission (SAE) has relatively poor spatial resolution but has the advantage of intrinsic

JAYPEE BROTHERS

segmentation since it uses the color doppler circuitry the color signals can easily be separated from the gray scale component so that the exact correspondence between the bubble signature and the lesion or tissue seen on gray scale is apparent. PIM has the same spatial resolution as gray scale but the bubble and tissue components are inextricably enlarged and so the two signals cannot be separated.

A recently introduced mode, agent detection imaging (ADI) offers a combination of both features. A development of SAE but using power doppler it depicts the bubble destruction signature as a color overlay with the same spatial resolution as the underlying gray scale scan. It offers the combination of excellent spatial resolution and the ability to view the background and the bubble signals together or separately so that the precise location of the microbubbles can be determined.

The therapeutic potential of microbubbles is a topic of active research. They may be used in two ways, to enhance the effects of high intensity focused ultrasound (HIFU) by increasing the amount of energy deposited or by acting as vehicles for therapeutic agents. In this mode, the loaded microbubbles are ruptured at the desired site by applying sufficiently intense sound to achieve a local high concentration of agent, thrombolytic agent or an anticancer drug.

SUGGESTED READINGS

1. Blomley M, Albrecht T, Wilsons SR. Improved detection of metastatic liver lesions using pulse inversion harmonic imaging with Levovist a multicenter study. Radiology. 1999;213:1685.
2. Albrecht T, Blomley MJ, Casgron DO. Non invasion diagnosis of hepatic cirrhosis by transit time analysis of ultrasound contrast agent. Lancet. 1999;353:1579-83.
3. Albrecht T, Patel N, Cosgrove DO. Enhancement of bower Doppler signals from breast lesions with the ultrasound contrast agent Echogen emulsion: subjective and quantitative assessment. Acad Radiol. 1998;5(Suppl):S195-8, discussion S199.
4. Bauer A, Becker G, Krone A, Frohlich T. Transcranial Duplex sonography using ultrasound contrast enhancers. Clin Radiol. 1996;51:19-23.
5. Blomley M, Albrecht T, Eckersley R. Renal arteriovenous transit time measured noninvasively using bolus injections of microbubble contrast. Radiology. 1998;209:461.
6. Burns PN. Interpreting and analyzing the Doppler examination. In: Taylor KJW, Burns PN, Wells PNT (Eds). Clinical Applications of Doppler Ultrasound. New York: Raven Press: 1995. pp. 55-99.
7. Dietrich CF, Nolsøe CP, Barr RG, Berzigotti A, Burns PN, Cantisani V, et al. Guidelines and Good Clinical Practice Recommendations for Contrast-Enhanced Ultrasound (CEUS) in the Liver - Update 2020. Ultrasound Med Biol. 2020;46(10):2579-604.
8. Frinking P, Segers T, Luan Y, Tranquart F. Three Decades of Ultrasound Contrast Agents: A Review of the Past, Present and Future Improvements. Ultrasound Med Biol. 2020;46(4): 892-908.
9. Harvey C, Blomely M, Eckersley R. Improved detection of hepatic malignancies using pulse inversion mode in the late phase of enhancement with the ultrasound contrast agent Levovist (SHU 508A): Early experiences Radiology (Submitted) 1999.
10. Ho SY, Barbarese E, D'Arrigo JS. Evaluation of lipid coated microbubbles as a delivery vehicle for Taxol in brain tumor therapy. Neurosurg. 1997;40:1260-6.
11. Porter TR, LeVeen RF, Fox R, Kricsfeld A, Xie F. Thrombolytic enhancement with perfluorocarbon-exposed sonicated dextrose albumin microbubbles. Am Heart J. 1996;132(5): 964-8.
12. Kono Y, Moriyasu F, Yawada K. Conventional and harmonic gray scale enhancement of the liver with sonication activation of a US contrast agent. Radiology. 1996:201.
13. Missouris CG, Allen CM, Balen FG. Noninvasive screening for renal artery stenosis with ultrasound contrast enhancement. J Hyperten. 1996;14:519-24.
14. Porter TR, Xie F, Kriesfeld D. Improved myocardial contrast with second harmonic transient ultrasound response imaging in humans using intravenous perfluorocarbon exposed sonicated dextrose albumin. J Am Cell Cardiol. 1996;27:1479-501.
15. Sidhu PS, Cantisani V, Dietrich CF, Gilja OH, Saftoiu A, Bartels E, et al. The EFSUMB Guidelines and Recommendations for the Clinical Practice of Contrast-Enhanced Ultrasound (CEUS) in Non-Hepatic Applications: Update 2017 (Long Version). Ultraschall Med. 2018;39(2):e2-e44.
16. Tschammler A, Viesr G, Schindler R. Ultrasound contrast media in vitro studies. J Ultrasound Med. 1993;12:S33.
17. Wilson SR, Burns PN, Muradati D. Harmonic hepatic US with microbubble contrast agent: initial experience showing improved characteri-sation of haemangioma, hepatocellular carcinoma and metastasis. Radiology. 2000;215:153-61.

JAYPEE BROTHERS

Textbook of
Color Doppler Imaging

With an ever-increasing demand of this book by Postgraduate Residents, Practicing Physicians, Radiologists, Obstetricians and Gynecologists and in keeping pace with new technological advances, the book has been revised by incorporating a new chapter on 3D and 4D & Integrating Artificial Intelligence in Doppler Imaging, as well as replacing and adding a few important illustrations. The purpose is to give in-depth, clear, and concise knowledge about the use of color Doppler in diagnosing various diseases of almost every system of the human body, including abdomen, small parts, peripheral vascular diseases, obstetrics and gynecology, and echocardiography. The book definitely serves as an essential guide to the readers in their day-to-day practice.

Sumeet Bhargava MBBS DNB(Radiodiagnosis) FCGP FIAMS FICRI FIMSA MNAMS was awarded honors and gold medals in various subjects during his MBBS studies. He was trained at Diwan Chand Satyapal Aggarwal Imaging Center, New Delhi; Rajiv Gandhi Super Specialty Hospital, New Delhi; All India Institute of Medical Sciences (AIIMS), New Delhi; University College of Medical Sciences (UCMS), New Delhi; and GTB Hospital, New Delhi, India. He has published 35 research papers, in both national and international journals, besides contributing many chapters in textbooks. He is a life member of the National Academy of Medical Sciences (NAMS) and International Medical Science Academy (IMSA). He has been conferred with Dr N Ram Das Best Research Paper Award of Indian College of Radiology and Imaging (2009). Due to his extensive academic contribution, he has been awarded Fellowship of the College of General Practitioners (2010), M/s German Remedies Travelling Fellowship in Radiodiagnosis and Imaging of the Institute of Clinical Research (2011) at PGI Chandigarh, Fellowship of Indian College of Radiology and Imaging, and Fellowship of IMA Academy of Medical Specialties (2001).

Satish K Bhargava MBBS MD(Radiodiagnosis) MD(Radiotherapy) DMRD FICRI FIAMS FCCP FUSI FIMSA FAMS was Head, Department of Radiology and Imaging at School of Medical Sciences and Research and Sharda Hospital, Sharda University, Greater Noida, Uttar Pradesh, India, and was also Head, Department of Radiology at University College of Medical Sciences (UCMS; University of Delhi), New Delhi, and JN Medical College, Aligarh Muslim University, Aligarh, Uttar Pradesh. He was an advisor to the setup of the Department of Radiology at BP Koirala Institute of Health Sciences (BPKIHS), Dharan, Nepal. He also established the Department of Radiology at UCMS, New Delhi, India.

Professor Bhargava has not only authored many textbooks and contributed more than 350 research papers in various national and international journals, but also been an excellent teacher. Due to his wide academic contribution, he has been awarded Sir JC Bose Memorial Oration Award, Distinguished Medical Teachers Award, BC Roy Award, Brig SK Majumdar Oration Award, Swami Vivekanand Oration Award, Prithvinath Bhargava Memorial Oration Award, GEMS International Award, and Excellent Teacher Award by National Board of Examination, Ministry of Health and Family Welfare, Government of India. He has also served as the Chairman, Board of Research Studies (University of Delhi), New Delhi. Dr Bhargava has uniquely contributed in the field of medical sciences in his Hindi books such as *Vikiran Vigyan and Cancer ke Tathya*. In recognition of his contribution for his books in Hindi, he has been awarded *Maulik Hindi Puraskar* by the Ministry of Health and Family Welfare, Government of India. He has served as the Secretary as well as the Chairman of the Indian College of Radiology and Imaging and was also the National President of the Indian Radiological and Imaging Association.

Rajul Rastogi MD(Radiodiagnosis) Gold Medalist DipCard ADND DCA MNAMS FICRI FIMSA is a distinguished Indian Radiologist, Academician, and Guinness World Record holder with over 25 years of clinical and research excellence. Serving as Senior Professor, Chairman College Research Committee and Nodal Officer of AI in Healthcare at TMMC&RC, Moradabad, Uttar Pradesh, he bridges traditional Radiology and Digital Health. Holding prestigious international qualifications—including certifications from Harvard Medical School, Johns Hopkins, and IIIT-Hyderabad, alongside global roles with Texila American University and Tashkent Medical Academy—he champions advanced, safe, and ethical diagnostic practices. His scholarly impact spans over 240+ peer-reviewed papers, 60+ book chapters across 17 books, 35+ journal editorial roles, and 5 patents in Imaging and AI. A Fellow of IMSA and ICRI, Dr Rastogi's decorated career is marked by major accolades such as the Emerging Clinical Leader of the Year 2026, the Peacock Medical Education Award, and the Dr VP Lakhanpal Gold Medal, alongside cover features in Forbes India and other prominent media portals.

JAYPEE BROTHERS

Buy from ejaypee

JAYPEE BROTHERS

Shelving Recommendation
RADIOLOGY

ISBN 978-81-6799-911-5