led information on dermatology books, visit our website www.ejaypee.com, for detailed information on dermatology books, visit our website www.ejaypee.com

Complimentary Online 15 Videos
(Duration 15 minutes)

DERMOSCOPY PRIMER









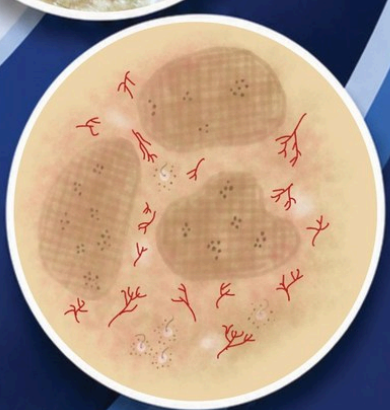

Editors
Gajanan Pise
Madhavi Pai

Foreword
Sathish Pai B

JAYPEE BROTHERS

JAYPEE

CONTENTS

PART 1: INFLAMMATORY DERMATOSES

Section 1: Papulosquamous Disorders

1. Plaque Psoriasis 3
2. Palmoplantar Psoriasis 5
3. Pityriasis Rosea 7
4. Inflammatory Linear Verrucous Epidermal Nevus (ILVEN) 9
5. Darier's Disease 11

Section 2: Eczematous and Lichenoid Disorders

6. Lichen Planus 13
7. Hypertrophic Lichen Planus 15
8. Prurigo Nodularis 17
9. Seborrheic Dermatitis 19
10. Allergic Contact Dermatitis 21
11. Irritant Contact Dermatitis 23
12. Subacute Eczema 25
13. Lichen Simplex Chronicus 27
14. Palmoplantar Eczema 29
15. Lichen Nitidus 31
16. Lichen Spinulosus 33
17. Lichen Striatus 35
18. Keratosis Pilaris 37
19. Phrynoderma 39
20. Fixed Drug Eruption 41
21. Polymorphic Light Eruption 43

JAYPEE BROTHERS

Section 3: Other Inflammatory Disorders

22. Morphea 45
23. Acquired Perforating Dermatosis 47
24. Kyrle's Disease 49
25. Malar Rash of Systemic Lupus Erythematosus (SLE) 51
26. Erythema Nodosum 53
27. Urticaria 55
28. Acne Vulgaris 57
29. Rosacea 59

Section 4: Pediatric Dermatoses

30. Ichthyosis Vulgaris 61
31. Lamellar Ichthyosis 63

PART 2: SKIN INFECTIONS AND INFESTATIONS

Section 5: Fungal, Viral, and Parasitic Disorders, Tuberculosis, Leprosy

32. Pityriasis Versicolor 67
33. Tinea Corporis 69
34. Tuberculosis Verrucosa Cutis 71
35. Molluscum Contagiosum 73
36. Herpes Zoster 75
37. Verruca Vulgaris 77
38. Pediculosis Capitis 79
39. Scabies 81
40. Cutaneous Larva Migrans 83
41. Secondary Syphilis 85
42. Leprosy 87

JAYPEE BROTHERS

PART 3: PIGMENTARY DISORDERS

Section 6: Hyperpigmented Disorders

43. Melasma 91
44. Melasma with Topical Steroid Abuse 93
45. Exogenous Ochronosis 95
46. Lichen Planus Pigmentosus 97
47. Riehl's Melanosis 99
48. Acanthosis Nigricans 101
49. Pigmentary Demarcation Line 103
50. Erythema Ab Igne 105

Section 7: Hypopigmented and Depigmented Disorders

51. Idiopathic Guttate Hypomelanosis 107
52. Vitiligo 109
53. Pityriasis Alba 111
54. Nevus Depigmentosus 113
55. Nevus Anemicus 115
56. Hypomelanosis of Ito 117
57. Dyschromatosis Universalis Hereditaria 119

Section 8: Pigmented Nevi and Melanocytic Lesions

58. Junctional Nevi 121
59. Compound Nevi 123
60. Intradermal Nevi 125
61. Blue Nevi 127
62. Halo Nevi 129
63. Café-au-Lait Macules 131
64. Solar Lentigines 133
65. Verrucous Epidermal Nevi 135
66. Nevus of Ota 137

JAYPEE BROTHERS

PART 4: TUMORS AND TUMOR-LIKE CONDITIONS

Section 9: Benign Tumors and Tumor-Like Conditions

67. Acrochordon 141
68. Seborrheic Keratosis 143
69. Stucco Keratosis 145
70. Nevus Sebaceous 147
71. Dermatosis Papulosa Nigra 149
72. Nevus Lipomatosis Superficialis 151
73. Nevus Comedonicus 153
74. Milia 155
75. Cutaneous Horn 157
76. Syringoma 159
77. Dermatofibroma 161

Section 10: Malignant Tumors

78. Basal Cell Carcinoma 163
79. Squamous Cell Carcinoma 165
80. Mycosis Fungoides 167

Section 11: Vascular Lesions

81. Schamberg's Purpura 169
82. Cherry Angioma 171
83. Lymphangioma Circumscriptum 173
84. Angiokeratoma of Fordyce 175
85. Pyogenic Granuloma 177

PART 5: TRICHOSCOPY

Section 12: Nonscarring Alopecias

86. Griscelli Syndrome 181
87. Androgenetic Alopecia 183
88. Telogen Effluvium 185
89. Alopecia Areata 187

JAYPEE BROTHERS

Section 13: Scarring Alopecias

90. Lichen Planopilaris 189
91. Trichotillomania 191
92. Discoid Lupus Erythematosus 193
93. Folliculitis Decalvans 195

PART 6: ONYCHOSCOPY

Section 14: Common Nail Disorders

94. Longitudinal Melanonychia 199
95. Nail Lichen Planus 201
96. Nail Psoriasis 203
97. Onychomycosis 205

PART 7: NAILFOLD CAPILLAROSCOPY

Section 15: Capillaroscopy Features/Findings

98. Systemic Sclerosis 209
99. Dermatomyositis 210
100. Systemic Lupus Erythematosus 211

PART 8: EXPANDING THE SCOPE OF DERMOSCOPY

Morphometry of Itraconazole Pellets 215
Assessment of Carbon Dioxide Laser Spot Quality 216
Diode Laser Endpoint Assessment 217
Evaluation of Microneedling Cartridges 218
Dermoscopy—Histopathological Correlation to Identify the Spectrum of Leprosy 219
Dermoscopic Indicators of Disease Activity in Vitiligo: Identifying Unsuitable Candidates for Surgical Treatment 224

References 227

Index 231

JAYPEE BROTHERS

PART 2

Skin Infections and Infestations

Every patient provides two questions—firstly, what can be learnt from him, and secondly, what can be done for him.

—Harvey Cushing

JAYPEE BROTHERS

SECTION 5

Fungal, Viral, and Parasitic Disorders, Tuberculosis, Leprosy

32 Pityriasis Versicolor

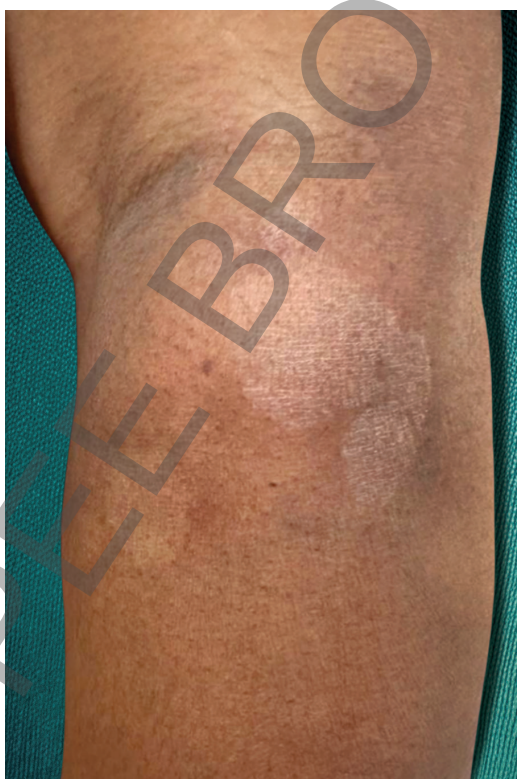

Hypopigmented, hyperpigmented, or erythematous macules and patches, commonly affecting the upper trunk, neck, and arms. Lesions may coalesce into large irregular patches with *fine branny (furfuraceous) scaling*. Scales becomes more apparent on *scratching (scratch sign/coup d'ongle sign)*. Lesions are usually asymptomatic or mildly itchy and may recur during humid climates.

JAYPEE BROTHERS



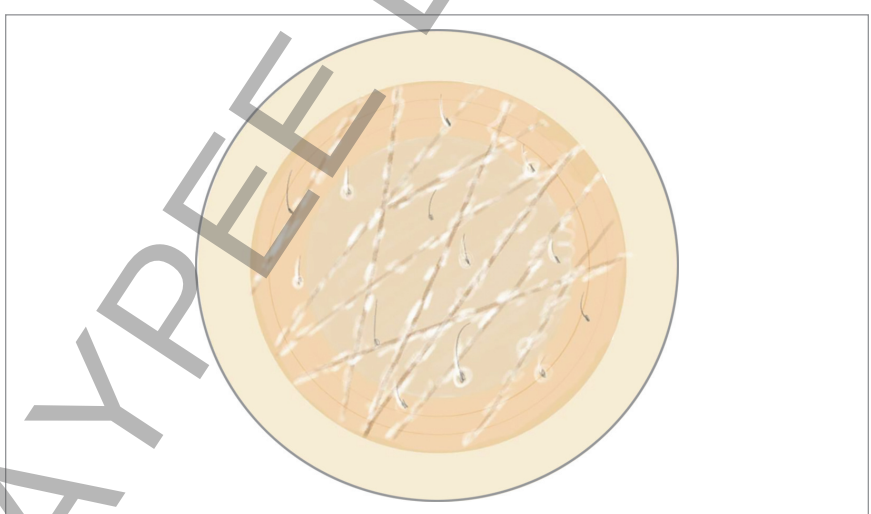

Delicate, superficial, whitish to faintly yellow scales that follow the skin furrows *"wire fence"/"crepe paper" appearance*. Perifollicular accentuation of scales and *double-edged scales* may be seen.[1,3,14]

JAYPEE BROTHERS

33 Tinea Corporis



Well-demarcated annular erythematous scaly plaque with central clearing and active raised margins and collarette-like ring of whitish scales.

JAYPEE BROTHERS

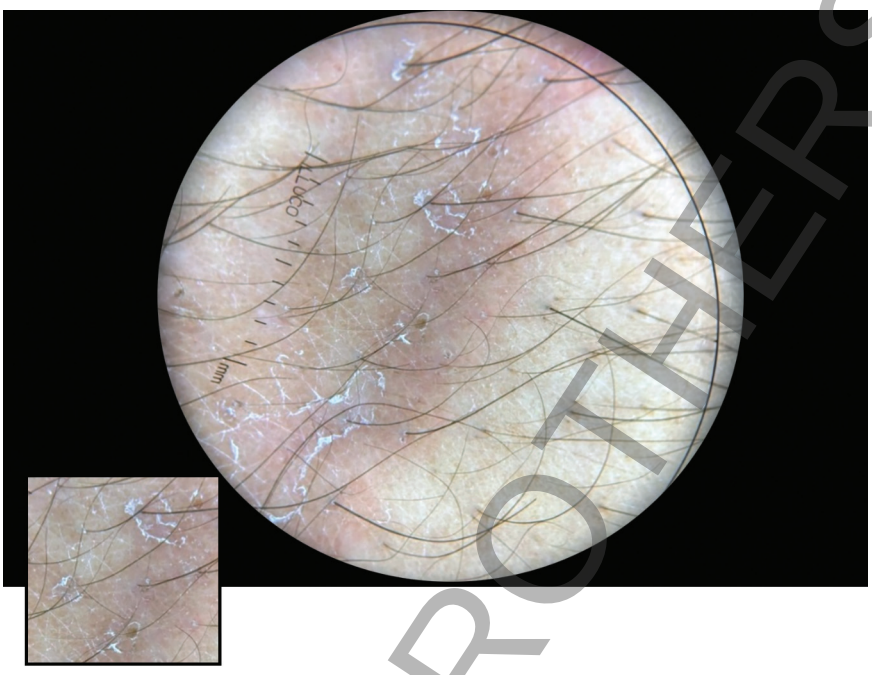

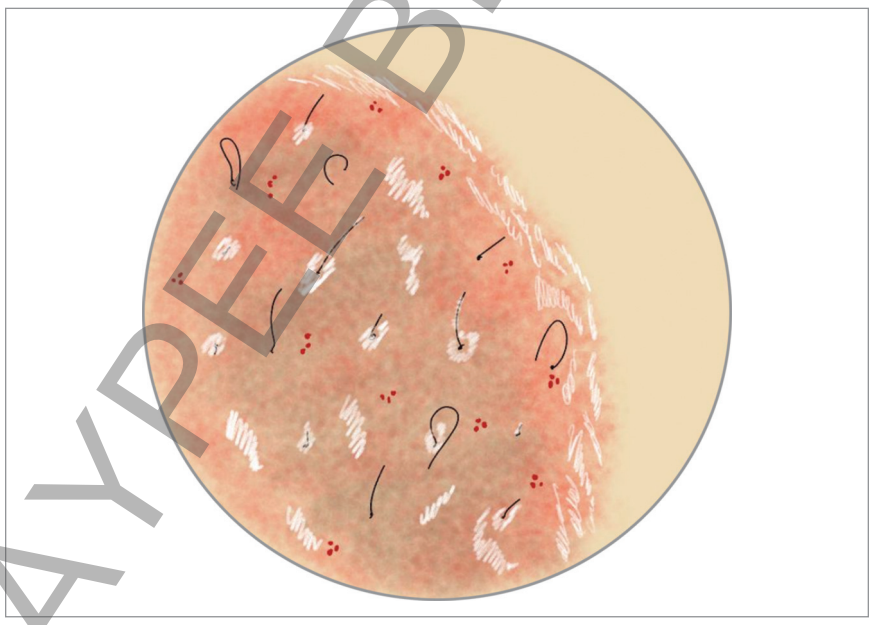

Diffuse reddish-brown background with central structureless light-brown area and *peripheral white to yellowish scales concentrated at the active border*, reddish-brown dots and globules, dotted and linear vessels and characteristic broken, bent, or translucent hairs *"morse-code hair"*.[1,3,23]

JAYPEE BROTHERS

34 Tuberculosis Verrucosa Cutis



Solitary, *slowly progressive indurated verrucous plaque with an irregular hyperkeratotic surface*, most commonly occurring on trauma-prone sites of the extremities.

JAYPEE BROTHERS

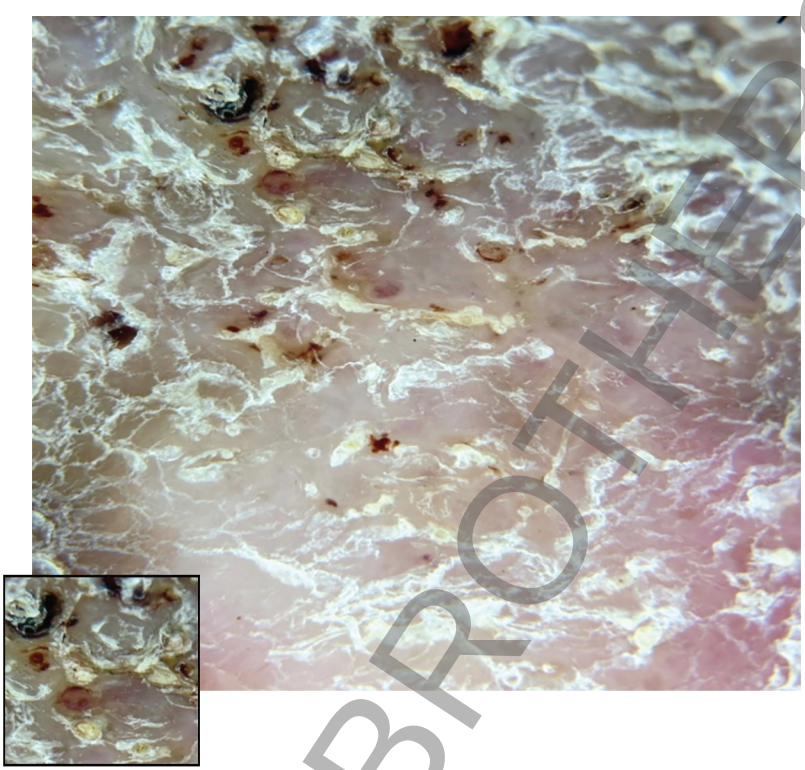

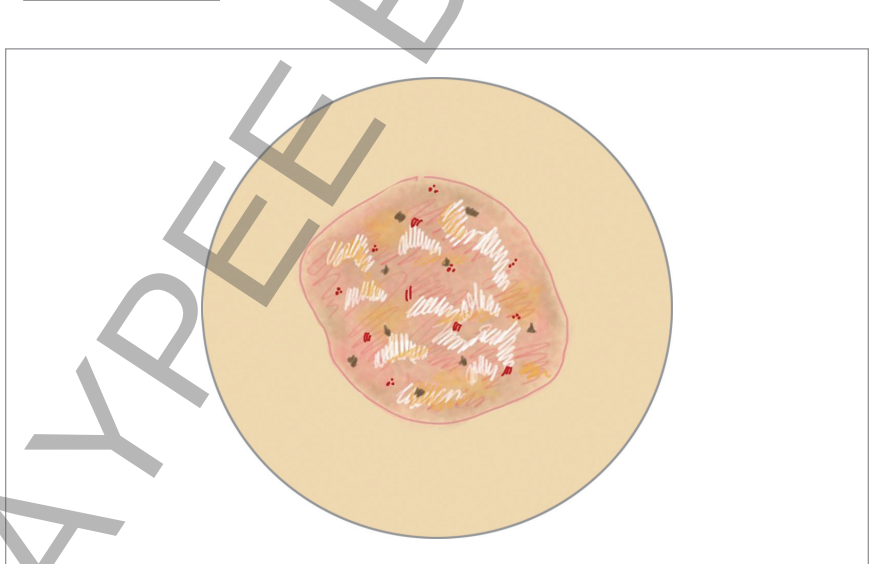

Asymmetrical yellow-orange structureless areas on a reddish background with prominent coarse whitish scales, papilliform projections, and irregular, linear or dotted vessels.[24]

JAYPEE BROTHERS

35 Molluscum Contagiosum



Multiple discrete, dome-shaped, pearly-white to skin-colored papules with characteristic central umbilication. These can appear anywhere on the body and are most commonly seen in children. Lesions may become erythematous and edematous indicating spontaneous immune-mediated clearing *"beginning of the end"*.

JAYPEE BROTHERS

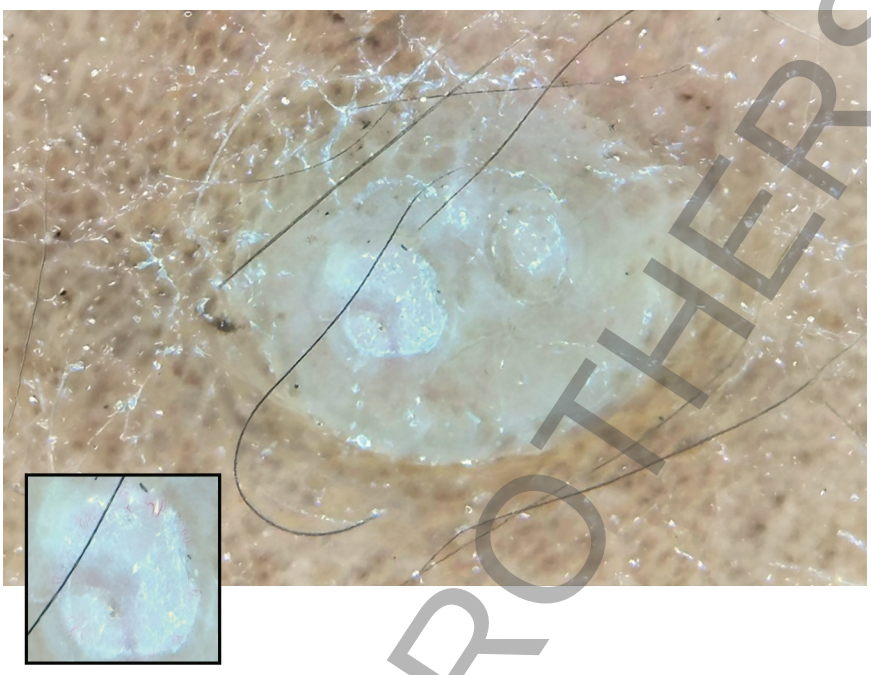

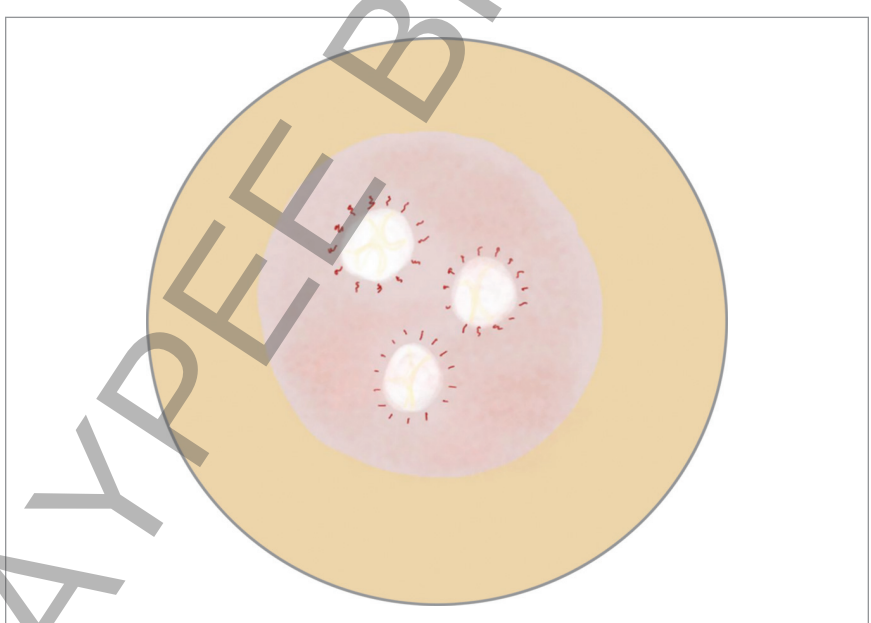

Multilobed central white-yellow amorphous area with surrounding crown-like radial vessels that do not cross the central core. White dots may be seen at the central core.[1,25]

JAYPEE BROTHERS

36 Herpes Zoster



Unilateral, dermatomal eruption of grouped vesicles on an erythematous and edematous base, frequently preceded by severe burning pain or dysesthesia. Lesions may evolve into pustules and crusts. Lesions strictly respect the midline of the body.

JAYPEE BROTHERS

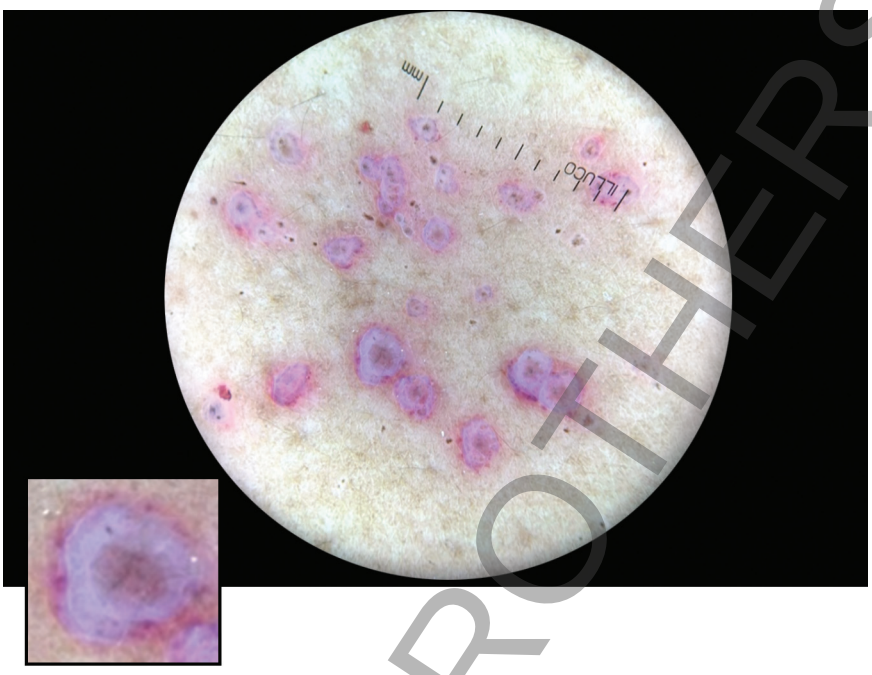

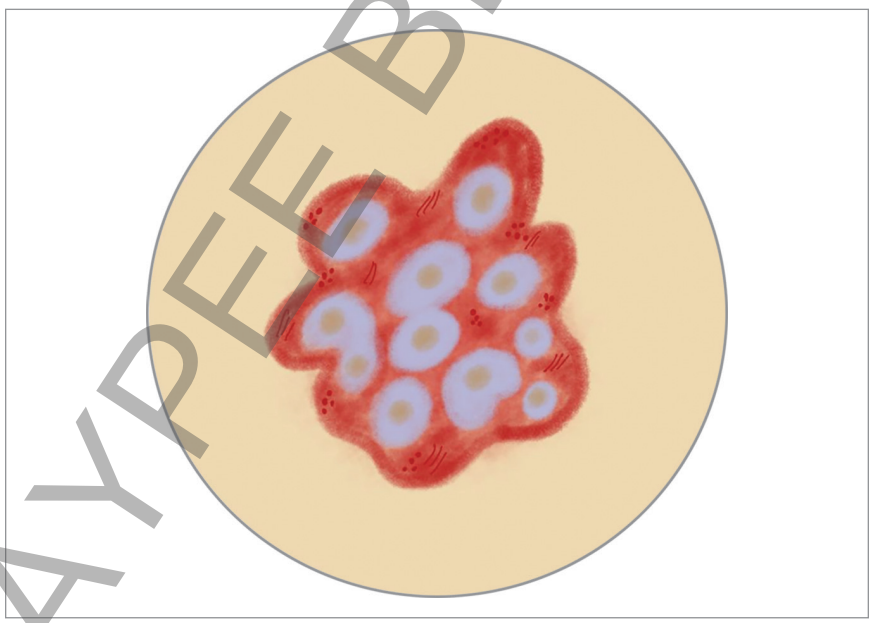

Grouped round to oval crimson to violaceous translucent globular structures with central brownish or grayish umbilication, surrounded by erythema and dotted and linear vessels and dark-red to purple globules.[1,3,26]

JAYPEE BROTHERS

37 Verruca Vulgaris

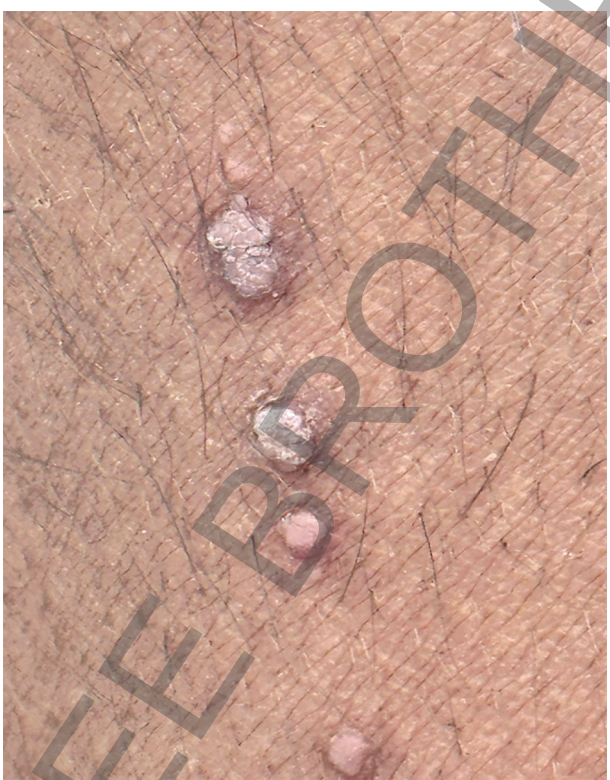

Well-demarcated firm, hyperkeratotic, rough-surfaced papule or nodule, most often seen on the trauma-prone areas like the hands, fingers, or periungual areas. *Multiple pinpoint black dots* may be seen. Lesions may demonstrate Koebner's phenomenon due to autoinoculation.

JAYPEE BROTHERS

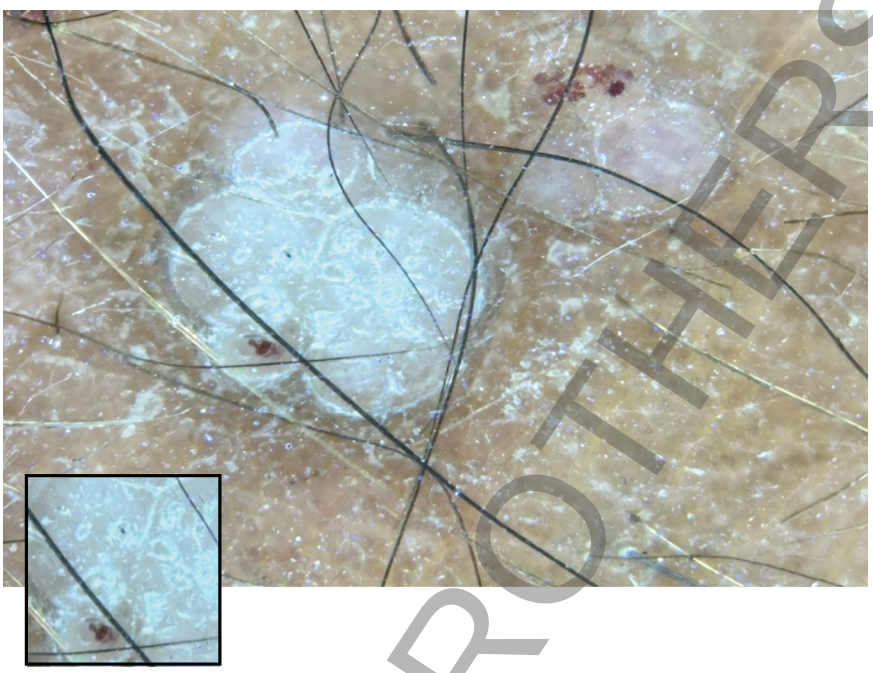

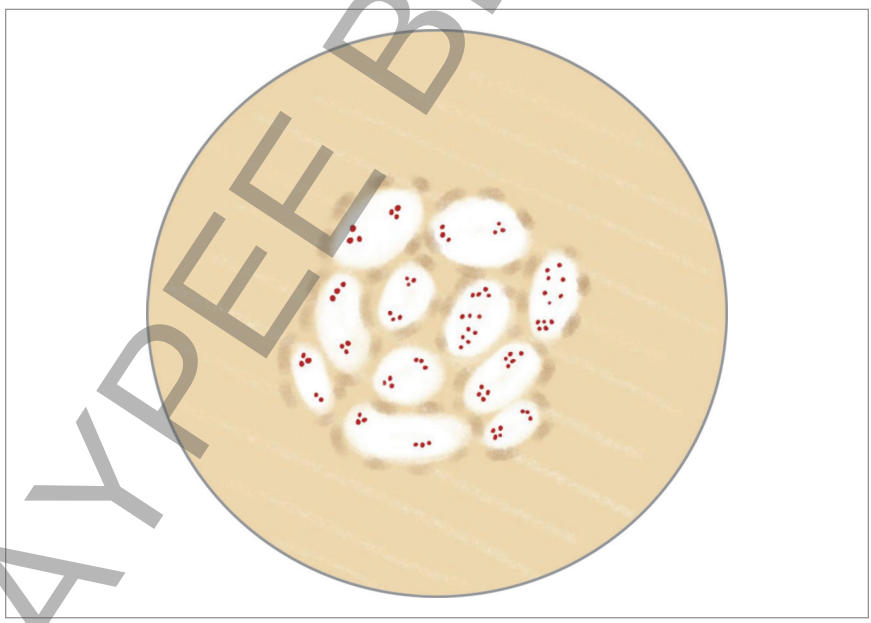

Multiple densely packed, round to oval whitish-yellow structures with *central red dotted/linear or hairpin vessels* (thrombosed vessels) and *dark-brown–black dots and globules* surrounded by a pearly-whitish keratinous halo, giving a characteristic mosaic or *"frogspawn" appearance*.[1,27]

JAYPEE BROTHERS

38 Pediculosis Capitis



Multiple adherent oval whitish nits (teardrop-shaped structures) attached to hair shafts over the occipital/postauricular scalp with excoriations.

JAYPEE BROTHERS





Multiple *well-circumscribed, teardrop-shaped translucent structure* with brown to tan ovoid internal structure and a glistening white shell.[28]

JAYPEE BROTHERS

39 Scabies



Intensely pruritic papules, vesicles, and burrows involving characteristic sites such as this includes the digital web spaces of the hands, the volar aspects of the wrists, the anterior axillary folds, the periumbilical skin, the female areolae, and the male external genitalia *"circle of Hebra"*, with nocturnal exacerbation of itching. Family history of similar complains is often present.

JAYPEE BROTHERS

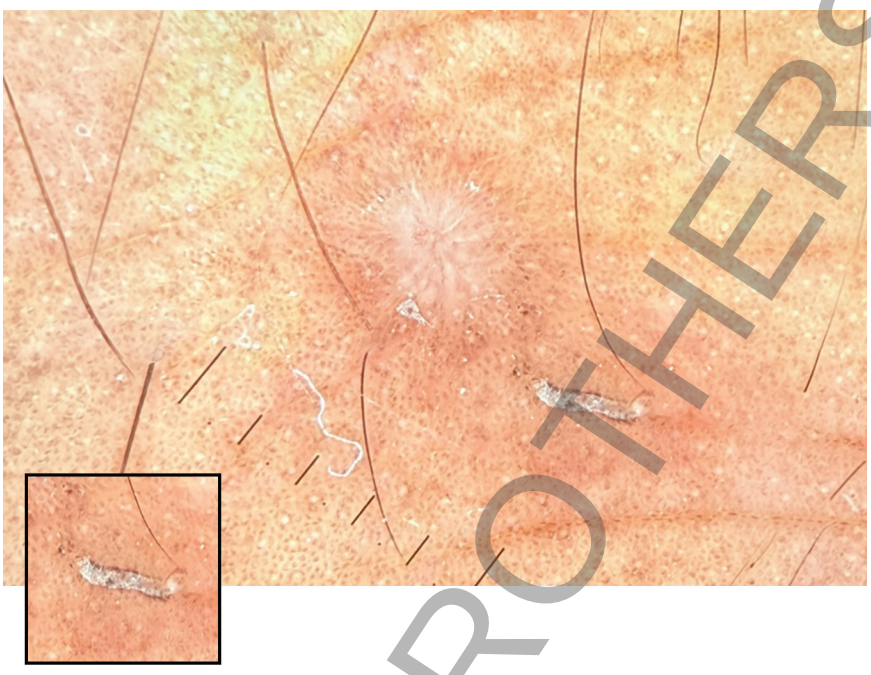

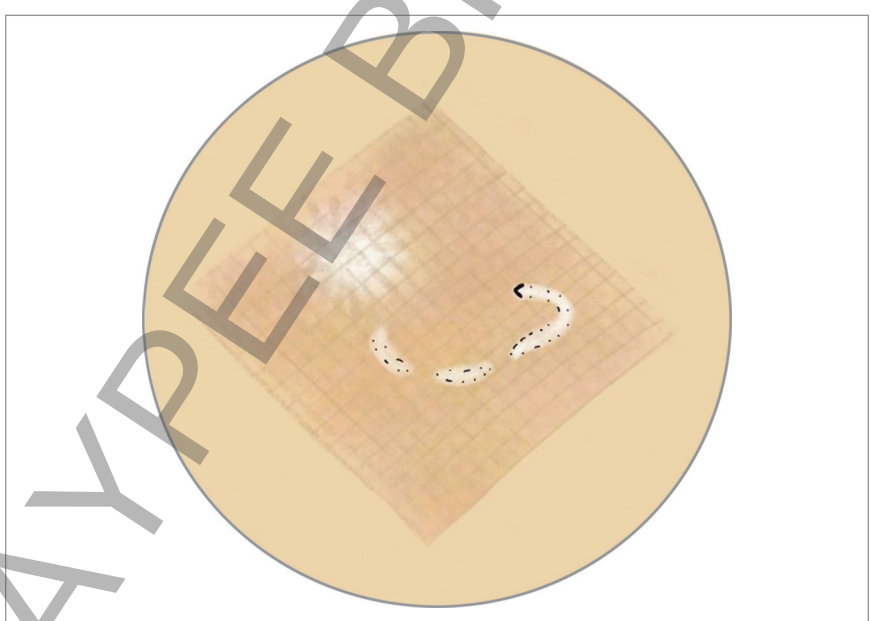

Brown triangular or wedge-shaped dark-brown to black structure represents the mite at the end of a whitish serpiginous burrow, producing the characteristic *"delta-wing or jet with contrail" sign*. Surrounding erythema with dotted vessels may be present.[1,29]

JAYPEE BROTHERS

40 Cutaneous Larva Migrans



Intensely pruritic, erythematous, serpiginous, migratory thread-like tracks at the site of penetration commonly affecting the feet and other exposed areas.

JAYPEE BROTHERS

for detailed information on dermatology books, visit our website www.ejaypee.com, for detailed information on dermatology books, visit our website www.ejaypee

DERMOSCOPY PRIMER

"Dermoscopy Primer" is a practical, image-rich atlas created to make dermoscopy simple, systematic, and clinically relevant. Featuring 100 essential dermatological diagnoses, the book integrates clinical photographs, dermoscopic images, hand-drawn dermoscopic silhouettes, and concise clinicodermoscopic correlations to facilitate rapid understanding and accurate diagnosis.

Built on the principle that dermoscopy is best learned through pattern recognition, the atlas guides readers to observe, compare, and correlate clinical and dermoscopic findings, transforming complex images into easily recognizable diagnostic patterns. The unique hand-drawn silhouettes further enhance visual learning by emphasizing the hallmark dermoscopic structures of each condition. With a special focus on skin of color, this book serves as an indispensable companion for postgraduate students, dermatologists, and practitioners seeking to strengthen their dermoscopic skills and apply them confidently in everyday clinical practice.

Gajanan Pise MBBS MD DVL is an Assistant Professor, Department of Dermatology, Venereology and Leprosy, Belagavi Institute of Medical Sciences, Belagavi, Karnataka, India. He has a special interest in dermoscopy and clinical dermatology and is passionate about mentoring young dermatologists, advancing dermatologic knowledge through teaching and research, and translating clinical expertise into excellence in patient care.

Madhavi Pai MBBS is a Postgraduate Resident (2nd Year) in the Department of Dermatology, Venereology and Leprosy at Belagavi Institute of Medical Sciences, Belagavi, Karnataka, India. She has a keen interest in dermoscopy, pigmentary disorders, and pediatric dermatology and is dedicated to simplifying dermoscopy through visual learning, pattern recognition, and clinicodermoscopic correlation.

Buy from ejaypee

JAYPEE BROTHERS

Shelving Recommendation
DERMATOLOGY

ISBN 978-81-6799-970-2