eurology books, visit our website www.ejaypee.com, for detailed information on neurology books, visit our website www.ejaypee.com, for detailed information on neurology books,

Complimentary Online Video included

IAN Reviews in NEUROLOGY 2026

Neuromuscular Disorders

A Comprehensive Update

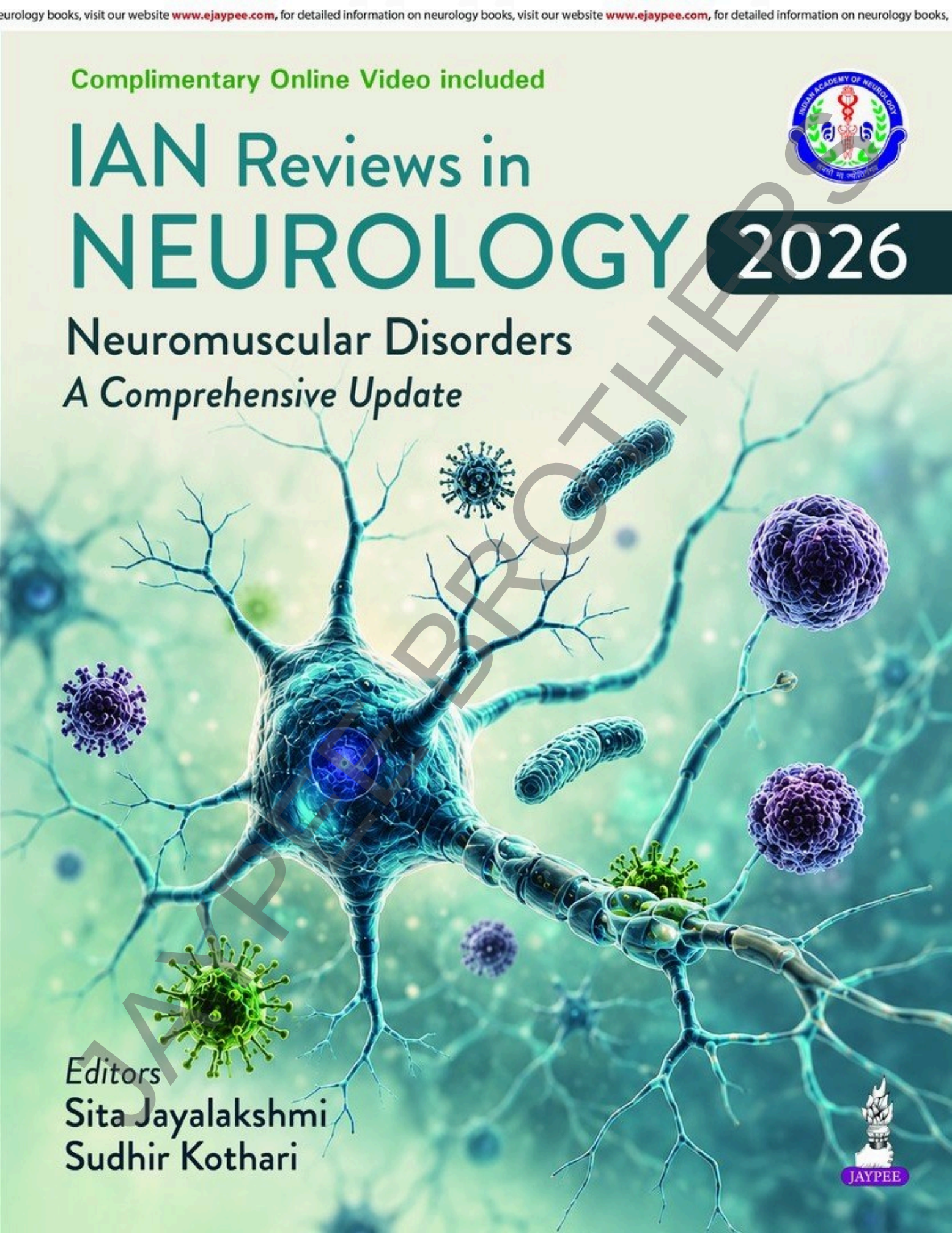

Editors
Sita Jayalakshmi
Sudhir Kothari

JAYPEE

JAYPEE BROTHERS

CONTENTS

CHAPTER 1: **Approach to a Case of Neuromuscular Weakness** 1
Satish Khadilkar, Jharna Mahajan, Shamisha Khade

CHAPTER 2: **Role of Imaging in Muscle Diseases** 16
Preethish Kumar Veeramani

CHAPTER 3: **Imaging in Peripheral Nerve Disorders** 29
Allen Johnson, Jitender Saini

CHAPTER 4: **Ultrasound in Neuromuscular Disorders** 47
Y Muralidhar Reddy

CHAPTER 5: **Myasthenia Gravis: Update on Evaluation and Treatment** 57
Deepak Menon, Seena Vengalil, Saraswati Nashi, Atchayaram Nalini

CHAPTER 6: **Congenital Myasthenic Syndromes: A Comprehensive Update** 66
Atchayaram Nalini, Dipti Baskar, Bhaswar Bhattacharya, Seena Vengalil, Saraswati Nashi, Deepak Menon

CHAPTER 7: **Classical Ocular Myasthenia, Extended Phenotypic Variations, Beyond Fatigability and Overlap Syndromes** 75
SR Chandra, CS Vidhya Annapoorni, Talakad Narasappa Sathyaprabha

CHAPTER 8: **Limb-Girdle Muscular Dystrophies: Classification and Therapies** 82
Saraswati Nashi, Seena Vengalil, Bhaswar Bhattacharya, Deepak Menon, Atchayaram Nalini

CHAPTER 9: **Facioscapulohumeral Muscular Dystrophy** 95
Vishnu VY

CHAPTER 10: **Idiopathic Inflammatory Myopathies: Current Understanding and Future Perspectives** 104
Seena Vengalil, Bhaswar Bhattacharya, Saraswati Nashi, Deepak Menon, Atchayaram Nalini

CHAPTER 11: **Skeletal Muscle Ion Channelopathies** 116
Dipti Baskar, Atchayaram Nalini, Seena Vengalil

CHAPTER 12: **Advances in the Management of Mitochondrial Myopathies** 126
Rajesh Benny, Payal Patil

CHAPTER 13: **Newer Therapies for Adult-Onset Hereditary and Degenerative Neuromuscular Diseases** 133
Megha Dhamne

JAYPEE BROTHERS

CHAPTER 14: **Metabolic Myopathies: Fatty Acid Oxidation Disorders and Glycogen Storage Disorders** 148
Gopikrishnan Unnikrishnan, Vattikuti Anusha

CHAPTER 15: **Dystrophinopathies and an Update on Gene Therapy** 156
Hansashree Padmanabha, Bhaswar Bhattacharya, Aradhya Sekhar Bagchi

CHAPTER 16: **Spinal Muscular Atrophy and Newer Therapies** 171
Vykuntaraju K Gowda, Viveka Santhosh Reddy C

CHAPTER 17: **Lambert–Eaton Myasthenic Syndrome and Botulism: A Narrative Review** 178
Rakesh K Singh, Aamna Maniyar

CHAPTER 18: **A Comprehensive Review of Hereditary Neuropathies** 188
Tanushree Chawla

CHAPTER 19: **Endocrine and Infective Myopathies** 202
Sri Sai Srujana Puppala

CHAPTER 20: **Motor Neuron Disease: An Update** 216
Vineeth Jaison, Tasha Samuel, Harmanjot Kaur Walia

CHAPTER 21: **Diabetic Neuropathy: Recent Updates in Evaluation and Management** 231
Gayathri Sreekumar, Sruthi S Nair

CHAPTER 22: **Guillain–Barré Syndrome: An Update** 242
Monojit Debnath, Madhu Nagappa

CHAPTER 23: **Chronic Inflammatory Demyelinating Polyradiculoneuropathy, Nodopathies, and Paranodopathies: Concepts and Management** 251
Vaibhav Wadwekar, Saranya B Gomathy, Vishnu KS

CHAPTER 24: **Vasculitic Neuropathies** 261
Akshata Huddar, Aditi Goyal

CHAPTER 25: **Role of Genetics in Inherited Neuromuscular Disorders** 274
Gautham Arunachal Udupi, Ramya Sukrutha, Mahima R

CHAPTER 26: **Management of Neuropathic Pain** 285
Nagalaxmi Patnala, Praveen Kumar Yada

Index 293

JAYPEE BROTHERS

CHAPTER

8

Limb-Girdle Muscular Dystrophies: Classification and Therapies

Saraswati Nashi, Seena Vengalil, Bhaswar Bhattacharya, Deepak Menon, Atchayaram Nalini

ABSTRACT

Limb-girdle muscular dystrophies (LGMDs) are a clinically and genetically diverse group of autosomal inherited genetic disorders presenting with limb-girdle muscle weakness caused by defects in various genes. They are classified as dominant and recessive subtypes. In 2018, the new nomenclature system classified dominant/recessive types as LGMD-D or LGMD-R with numbers indicating the subtypes. While traditionally they were diagnosed with low precision involving invasive procedures such as muscle biopsy and immunohistochemistry/western blot, the current diagnoses rely significantly on next-generation sequencing (NGS). Biopsies are now used only for cases unsorted by NGS. Genetic heterogeneity and genetic pleiotropy are known. The recent advances in genetics have seen an emergence of new variants in known genes as well as novel genes.

Timely diagnosis is essential to anticipate and manage complications, especially cardiac and respiratory. Accurate diagnosis allows patients to access appropriate rehabilitation measures, connect with patient groups, enroll in clinical trials, and importantly access genetic counseling to ensure disease prevention using prenatal diagnosis/screening of family members at risk of disease.[1]

Keywords: LGMD, LGMD-D, LGMD-R.

INTRODUCTION

Limb-girdle muscular dystrophy (LGMD) is a genetically inherited condition that primarily affects skeletal muscle leading to progressive, predominantly proximal muscle weakness at presentation caused by a loss of muscle fibers. To be considered a form of LGMD, the condition must be described in at least two unrelated families with affected individuals achieving independent walking, must have an elevated serum creatine kinase (CK) activity, must demonstrate degenerative changes on muscle imaging over the course of the disease, and have dystrophic changes on muscle histology, ultimately leading to end-stage pathology for the most affected muscles.

The term LGMD was first introduced by Walton and Nattrass in 1954. The global prevalence is 0.8–6.9 per 100,000 population.[2] However, regional variation is known. Also, we have founder variants in certain genes within this broad group, a classic example being fukutin-related dystrophy which is common in Japan while dystroglycanopathies and anoctaminopathies are particularly common in Northern European populations. Telethoninopathies are probably caused by a founder variant in Taiwan.[3] A new system of classification was drafted in 2018 in the 229th ENMC workshop and was classified as dominant/recessive forms.[4] The proposed subtype classification follows the formula: *"LGMD, inheritance (R or D), order of discovery (number), affected protein"*. An example of this would be: "LGMD R1 Calpain3-related". **Table 1** gives an overview of classification of LGMDs.

JAYPEE BROTHERS

TABLE 1: Classification of LGMDs: Genes, associated protein, and function (including both old and current classification).[1,3,25]

Type	Gene	Protein	Function
Type 1: Autosomal dominant			
LGMD1A	*MYOT*	Myotilin	Cross-links actin filaments + sarcomere assembly
LGMD1B	*LMNA*	Lamin A/C	Nuclear envelope in fibroblasts
LGMD1C	*CAV3*	Caveolin 3	Skeletal muscle mitochondria form and function
LGMD1D (LGMDD1)	*DNAJB6*	DNAJ homologue, family B, member 6	Z disc organization
LGMD1E	*DES*	Desmin	Maintain muscular structure and function
LGMD1F (LGMDD2)	*TNPO3*	Transportin 3	Transports serine/arginine-rich proteins into nucleus
LGMD1G (LGMDD3)	*HNRNPDL*	Heterogeneous nuclear ribonucleoprotein D-like	Regulate transcription and alternative splicing
LGMD1H	?	?	?
LGMD1I (LGMDD4)	*CAPN3*	Calpain 3	Cysteine protease
Bethlem myopathy dominant (LGMDD5)	*COL6A1, COL6A2, COL6A3*	Collagen 6	Extracellular matrix structure and muscle regeneration
Type 2: Autosomal recessive			
LGMD2A (LGMDR1)	*CAPN3*	Calpain 3	Cysteine protease
LGMD2B (LGMDR2)	*DYSF*	Dysferlin	Sarcomere stability and muscular repair
LGMD2C (LGMDR5)	*SGCG*	γ-Sarcoglycan	Cytoskeleton extracellular matrix link
LGMD2D (LGMDR3)	*SGCA*	α-Sarcoglycan	Cytoskeleton extracellular matrix link
LGMD2E (LGMDR4)	*SGCB*	β-Sarcoglycan	Cytoskeleton extracellular matrix link
LGMD2F (LGMDR6)	*SGCD*	δ-Sarcoglycan	Cytoskeleton extracellular matrix link
LGMD2G (LGMDR7)	*TCAP*	Telethonin	Myofibrillogenesis
LGMD2H (LGMDR8)	*TRIM32*	Tripartite motif-containing protein 32	Ca^{2+} movement of in skeletal muscles
LGMD2I (LGMDR9)	*FKRP*	Fukutin-related protein	Glycosylation of α-dystroglycan
LGMD2J (LGMDR10)	*TTN*	Titin	Muscle tension
LGMD2K (LGMDR11)	*POMT1*	Protein O-mannosyl transferase 1	O-mannosylation in α-dystroglycan
LGMD2L (LGMDR12)	*ANO5*	Anoctamin 5	Calcium-activated chloride channels
LGMD2M (LGMDR13)	*FKTN*	Fukutin	Glycosylation of α-dystroglycan
LGMD2N (LGMDR14)	*POMT2*	Protein O-mannosyltransferase 2	O-mannosylation in α-dystroglycan
LGMD2O (LGMDR15)	*POMGnT1*	Protein O-mannose beta-1,2-N-acetylglucosaminyltransferase 1	Catalyzes reactions in α-dystroglycan
LGMD2P (LGMDR16)	*DAG1*	Dystroglycan 1	Part of the dystroglycan complex
LGMD2Q (LGMDR17)	*PLEC1*	Plectin 1	Cell survival, cell growth, actin organization, and T-cell activation
LGMD2R	*DES*	Desmin	Connect sarcomeres to form myofibrils
LGMD2S (LGMDR18)	*TRAPPC11*	Transport protein particle complex 11	Transport between endoplasmic reticulum and Golgi apparatus
LGMD2T (LGMDR19)	*GMPPB*	GDP-mannose pyrophosphorylase B	Production of GDP-mannose for the O-mannosylation of α-dystroglycan
LGMD2U (LGMDR20)	*ISPD*	Isoprenoid synthase	Glycosylation of α-dystroglycan
LGMD2V	*GAA*	α-1,4-Glucosidase	Lysozyme function

Continued

JAYPEE BROTHERS

Continued

Type	Gene	Protein	Function
LGMD2W	*LIMS2*	Lim and senescent cell antigen-like domains 2	Cell spreading and migration
LGMD2X (LGMDR25)	*BVES*	Popeye domain containing protein 1 (POPDC1)	Structure and function of cardiac and skeletal muscle cells
LGMD2Y	*TOR1AIP1*	Torsin 1A-interacting protein 1	Link between the nuclear membrane and lamina during cell division
LGMD2Z (LGMDR21)	*POGLUT1*	Protein O-glucosyltransferase 1	Protein transport and process
Bethlem myopathy recessive (LGMDR22)	*COL6A1, COL6A2, COL6A3*	Collagen 6	Extracellular matrix structure and muscle regeneration
Laminin α2-related muscular dystrophy (LGMDR23)	*LAMA2*	Laminin α2	Myotubes stability and apoptosis
POMGnT2-related muscular dystrophy (LGMDR24)	*POMGnT2*	Protein O-linked mannose β-1,4-N-acetylglucosaminyltransferase 2	Catalyzes reactions in α-dystroglycan
POPDC3-related (LGMDR26)	*POPDC3*	Popeye domain containing 3	Membrane trafficking
JAG2-related (LGMDR27)	*JAG2*	Jagged2, a ligand for the Notch1 receptor	Component of the Notch signaling pathway
HMGCR-related (LGMDR28)	*HMGCR*	3-hydroxy-3-methylglutaryl-coenzyme A reductase	Conversion of HMG-CoA to mevalonate
SNUPN-related (LGMDR29)	*SNUPN*	Snurportin-1	Trafficking of small nuclear ribonucleoproteins

(BVES: blood vessel epicardial substance; DNAJB6: DnaJ heat shock protein family 40 member B6; FKRP: fukutin-related protein; GMPPB: guanosine diphosphate-mannose pyrophosphorylase enzyme; HMGCR: 3-hydroxy-3-methylglutaryl coenzyme A reductase; HNRNPDL: heterogeneous nuclear ribonucleoprotein D-like; ISPD: isoprenoid synthase domain containing; JAG2: jagged2; LGMD: limb-girdle muscular dystrophy; LGMDD: limb-girdle muscular dystrophy dominant; LGMDR: limb-girdle muscular dystrophy autosomal recessive; POGLUT1: protein O-glucosyltransferase 1; POMGnT1: protein O-mannose beta-1,2-N-acetylglucosaminyltransferase 1; POMGnT2: Protein O-linked mannose β-1,4-N-acetylglucosaminyltransferase 2; POMT1: protein O-mannosyltransferase 1; POMT2: protein O-mannosyltransferase 2; POPDC3: popeye domain-containing 3; *SNUPN*: snurportin-1; TNPO3: transportin-3; TRAPPC11: transport protein particle complex subunit 11; TRIM32: tripartite motif-containing protein 32)

Limb-girdle muscular dystrophies stem from protein defects in the sarcolemma, sarcoplasm, nucleus, and extracellular matrix. These proteins are involved in glycosylation modification, mitochondrial dysfunction, and mechanical signaling **(Fig. 1)**.[3]

CLINICAL FEATURES

Patients often present in childhood or adulthood or rarely later. Typically, they are not infantile in onset though some genes which cause collagenopathy and dystroglycanopathies manifest earlier in life when they are classified under congenital muscular dystrophies. The severity ranges from mild to early loss of ambulation and death. Most of them affect both genders equally.

The weakness typically manifests as difficulty in rising from floor, in climbing stairs, and in raising arms overhead, and in some subtypes such as Miyoshi myopathy, patients may present with difficulty in standing on toes while trying to grab something from a height. However, some patients, especially those with dysferlinopathies, can be excellent sportsmen before the weakness starts to affect. Distal muscles are usually spared at onset, so are the cranial nerves. Abdominal visceroptosis is described in calpainopathy. Some patients may describe wasting of muscles. Muscle pains may be reported in some patients with dysferlinopathies while in other patients it is due to compensatory posture changes caused by muscle weakness or related to contractures.

Respiratory weakness occurs later in the course and is more common in recessive forms. It may manifest as weak cough or difficulty lying flat on bed. Cardiac involvement is described in sarcoglycanopathy, telethonin, fukutin-related protein (FKRP), titin, alpha-dystroglycanopathies, and anoctamin-5, while it is usually absent (or minimal) in dysferlin, calpain, DNAJB6, TNPO3, and HNRNPDL though dysferlin protein is found in the cardiac muscle. Pain is sometimes described, especially in the pseudometabolic forms such as dysferlinopathies, anoctaminopathies, etc. Cognition is usually not affected.

The recessive variants contribute to 90% of cases and they often present earlier in life than the dominant ones.

JAYPEE BROTHERS

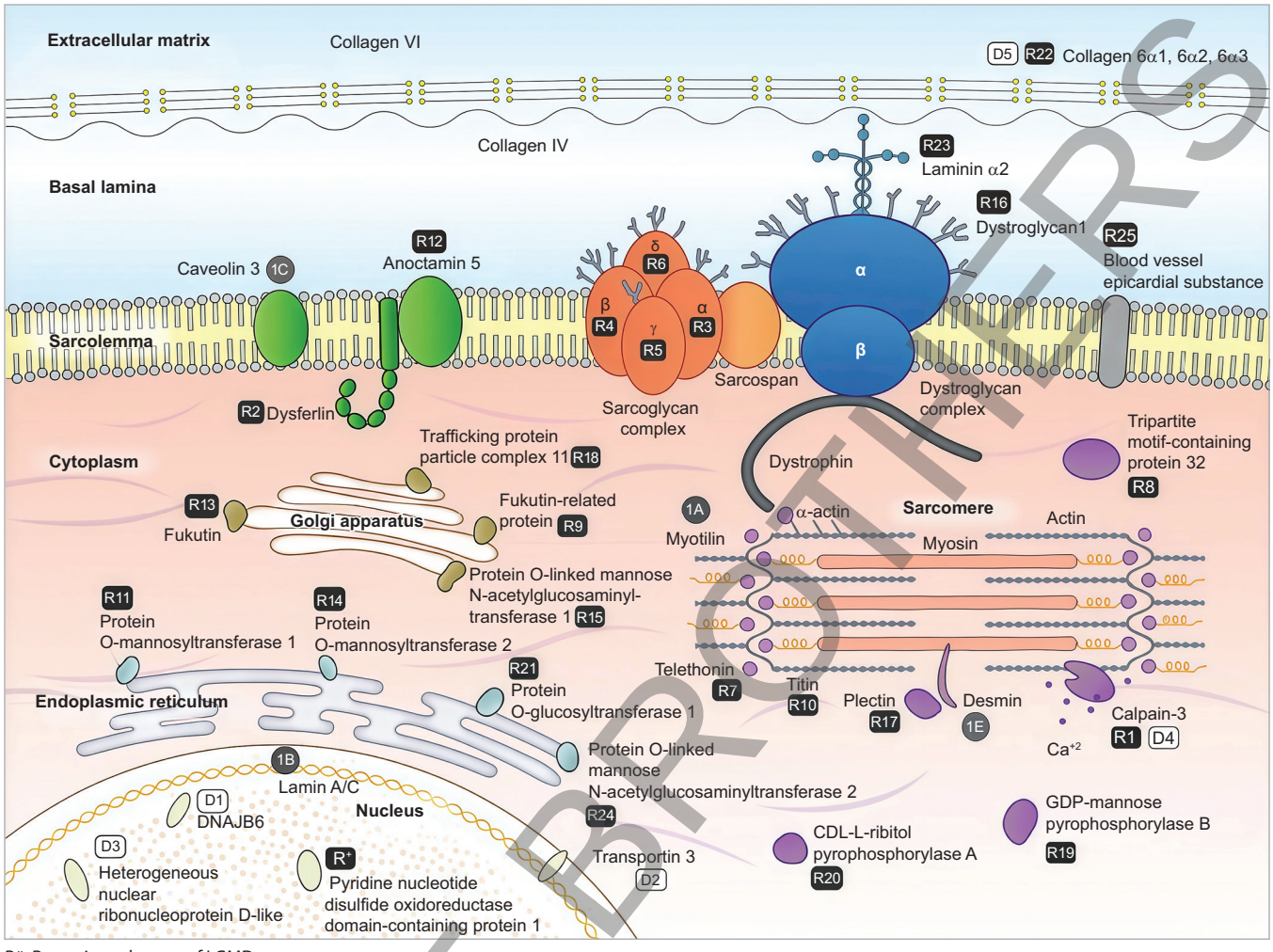

R#: Recessive subtypes of LGMD.
D#: Dominant subtypes of LGMD.
1X: Older subtypes of LGMD are no longer officially recognized as LGMD; the decommissioned recessive subtypes are not shown in the figure.

FIG. 1: Schematic diagram with the cellular localizations of proteins within the sarcolemma, cytosol or nucleus of myocytes, associated with various limb-girdle muscular dystrophy (LGMD) subtypes (*Note*: R15-related protein is also found in endoplasmic reticulum).

Source: Adapted from Georganopoulou DG, Moisiadis VG, Malik FA, Mohajer A, Dashevsky TM, Wuu ST, et al. A Journey with LGMD: From Protein Abnormalities to Patient Impact. Protein J. 2021;40(4):466-88. doi:10.1007/s10930-021-10006-9.

The degree of weakness is moderate to severe in recessive forms while the dominant ones are milder. Typically, CK is in multiples of thousands for recessive forms while being in hundreds for dominant forms.

The clinical features of few of the common recessive LGMDs are discussed in the following text and summarized in **Table 2**. **Figures 2A to G and Flowchart 1** depict the clinical features and approach to some of the common LGMDs.

Dysferlinopathy

Dysferlin plays an important role in membrane trafficking, fusion, and most notably membrane repair. The common phenotypes are LGMD (60%), Miyoshi myopathy (30%), distal myopathy with anterior tibial onset (DMAT), pseudometabolic presentations, asymptomatic hyperCKemia (3%), and rare bent spine syndrome or camptocormia.[5,6] Myalgias are seen in some, while others may have asymmetric onset.

Patterns such as calf head on trophy sign (combination of hypertrophy of deltoid and medial parts of infraspinatus muscles with wasting of trapezius and supraspinatus muscles), diamond on quadriceps sign (partial hypertrophy of a part of quadriceps muscle), and biceps lump (partial hypertrophy of biceps while the rest of muscle is atrophic) are described in dysferlinopathy. In a study done by the authors, the median time to loss of ambulation was 120 months.

JAYPEE BROTHERS

TABLE 2: Overview of clinical features of common LGMDs.

	CAPN3	DYSF	SCG	FKRP	ANO5
Onset	Second to third decade	Second to third decade	Childhood	First to second decade	
Pattern of weakness	*LGMD*: Pelvifemoral form of Leyden–Mobius and scapulohumeral form of Erb	• LGMD • Pseudometabolic • Miyoshi myopathy • Distal myopathy with anterior tibial onset • HyperCKemia	LGMD	• LGMD • Rhabdomyolysis • Exercise-induced pain • HyperCKemia	• LGMD • Distal myopathy
Peculiar symptoms and signs	Visceroptosis, toe walking, ankle contractures, thin habitus	• Calf head on trophy sign • Biceps lump • Diamond on quadriceps sign	Faster progression calf hypertrophy mimics DMD	Mimics DMD	Muscle cramps, asymmetric weakness
CK (U/L)	Several 1,000s	Highest levels (>10,000)	Very high (>10,000)	Very high (>10,000)	Several 1,000 s
Cardiac	No	No	Yes	Yes	No
Biopsy	Decreased calpain on western blot	Absence of dysferlin on IHC	Absence of SCG on IHC	Decreased alpha-dystroglycan stain on IHC	Dystrophy, inflammation, Congo-philic deposits

(ANO-5: anoctamin; CAPN3: calpain; CK: creatine kinase; DMD: Duchenne muscular dystrophy; DYSF: dysferlin; FKRP: fukutin-related protein; LGMD: limb-girdle muscular dystrophy; SCG: sarcoglycan; IHC: immunohistochemistry)

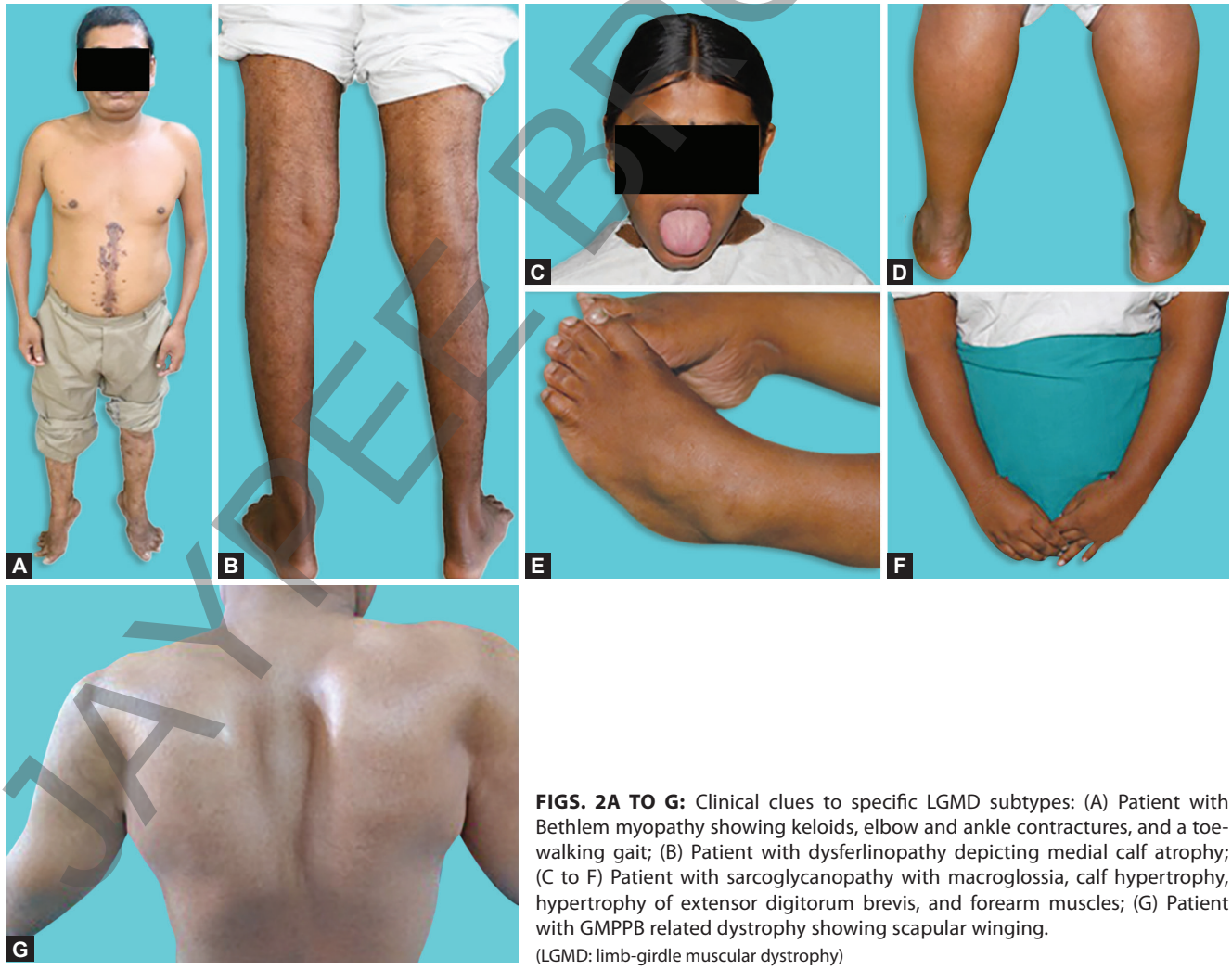

FIGS. 2A TO G: Clinical clues to specific LGMD subtypes: (A) Patient with Bethlem myopathy showing keloids, elbow and ankle contractures, and a toe-walking gait; (B) Patient with dysferlinopathy depicting medial calf atrophy; (C to F) Patient with sarcoglycanopathy with macroglossia, calf hypertrophy, hypertrophy of extensor digitorum brevis, and forearm muscles; (G) Patient with GMPPB related dystrophy showing scapular winging.
(LGMD: limb-girdle muscular dystrophy)

JAYPEE BROTHERS

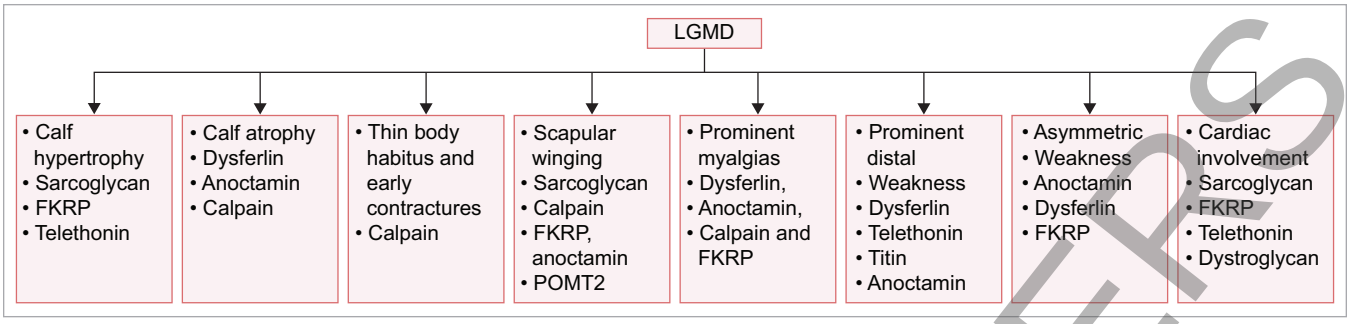

FLOWCHART 1: Clinical clues to specific subtypes of limb-girdle muscular dystrophy.

Calpainopathy

The recessive form of this disease is common while the dominant forms of calpain are rare. It is the most common LGMD subtype in nearly all population studies to date, ranging from 15–40% of cases. It is a muscle-specific calcium-activated neutral protease that binds to titin and is likely important for muscle regeneration during sarcomere remodeling.[7]

The onset of weakness varies, with 75% of cases having onset prior to 20 years of age. They usually present as pelvifemoral LGMD (Leyden–Mobius type) where weakness is first evident in pelvic and later in shoulder girdle; the second phenotype is known as scapulohumeral LGMD (Erb LGMD) where weakness is first evident in shoulder girdle muscles and rarely as hyperCKemia and pseudometabolic myopathy. Occasionally, foot drop, rigid spine, and respiratory insufficiency may be the presenting features. When present, a pattern of thin body habitus, toe walking with calf atrophy, abdominal laxity, and scapular winging help in diagnosis.

Sarcoglycanopathy

Four sarcoglycans (α, β, γ, δ) form a heterotetrameric complex spanning the sarcolemma. The typical age of onset is from 3 to 10 years. The clinical features include proximal limb weakness, scapular winging, calf hypertrophy, and exaggerated lumbar lordosis. They have respiratory deficiency and cardiomyopathy mirroring a severe progression seen in Duchenne muscular dystrophy (DMD). Early loss of ambulation/death by around 30 years of age is seen and hence they are the severe forms of recessive LGMDs.[8]

FKRP-Related Dystrophy

Clinically, patients may mimic a dystrophinopathy with a severe Duchenne-like or a milder Becker-like phenotype. Classically, they present with limb-girdle weakness, macroglossia, scapular winging, exaggerated lumbar lordosis, and calf hypertrophy. Prominent respiratory and cardiac dysfunction may occur.

Telethoninopathies

The usual age of onset of telethoninopathies is between 2 and 15 years. Patients present with mild-to-moderate limb-girdle weakness, along with thigh and anterior compartment of leg atrophy/weakness. Mild scapular winging and calf hypertrophy also may be seen. Although it may resemble LGMD 2I, telethoninopathies are characterized by severe involvement of the thigh muscles along with weakness and wasting of the tibialis anterior. Rimmed vacuoles may be seen.

Titinopathies

The onset can be in early childhood to adulthood. Predominant pelvic girdle weakness with foot drop is observed. Tibialis anterior is severely atrophic. Prominently affected muscles are iliopsoas, gluteus maximus, hip adductors, tibialis anterior, and hamstrings. Scapular winging may also be seen.

Anoctaminopathies

The age of onset of muscle weakness is variable but most commonly in adulthood, between 20 and 50 years of age. The phenotype is similar to dysferlinopathies. Muscle pain is a frequent symptom. There is no evidence for contractures, cardiomyopathy, or respiratory involvement. It is characterized by early asymmetric quadriceps and biceps atrophy.

GMPPB-Related Dystrophy

Adult-onset LGMDR19, congenital muscular dystrophy (CMD), congenital myasthenic syndrome (CMS), isolated rhabdomyolysis, epilepsy, intellectual disability, ocular involvement (Walker–Warburg syndrome), heart and

JAYPEE BROTHERS

brain abnormalities to asymptomatic hyperCKemia are phenotypes associated with GMPPB. Peculiarly, these patients may manifest with features of weakness with fatigue suggesting its role in neuromuscular junction, in which case they respond to treatment and to acetylcholinesterase inhibitors alone or combined with 3,4-diaminopyridine or salbutamol.[9]

Dominant Limb-Girdle Muscular Dystrophies

About 10% of LGMDs are inherited dominantly. These include variants in DNAJB6 (LGMD D1), transportin-3 (LGMD D2, TNPO3-related), *HNRNPDL* gene (LGMD D3), *CAPN3* gene (LGMD D4), and collagen 6 (LGMD D5, collagen 6-related). They usually present later in life and are much more slowly progressive than the recessive forms.[10] Previously included forms such as myotilin and desmin are now classified under myofibrillar myopathies, while laminopathies and caveolinopathies are also removed from the newer classification. The clinical features of the common forms of dominant LGMDs are discussed in the following text.

LGMD-D1

DNAJB6 is a ubiquitously expressed Hsp40 co-chaperone characterized by a J domain that specifies Hsp70 functions in the cellular environment.[11] This clinically presents as lower limb weakness with bulbar weakness; it is usually of adult onset and a slowly progressive disease, but rare phenotypes such as distal weakness are also described. Cardiac and respiratory involvement is rare. Despite DNAJB6 being a ubiquitously expressed protein, it is noteworthy that the disease predominantly affects skeletal muscle. Although DNAJB6 is a reported cardiomyopathy-susceptibility gene, cardiomyopathy has not been observed in any patient so far. The originally reported c.279C>G (p.Phe93Leu) mutation is now identified in four different populations and appears to be a mutational hotspot.[12]

LGMD-D2

LGMD-D2 is another newly described type involving *TNPO3* gene which is known to participate in the transport of HIV virus into the nucleus. Initially described in Italo-Spanish families, transportinopathies manifest in childhood as well as late adulthood and have a variable clinical course.

LGMD-D4

LGMD-D4 was first described in 2016. Dominant variants in calpain cause a later onset and milder form of LGMD with slower progression compared to the recessive form. Proper determination of LGMD-D4 requires western blotting for the calpain-3 protein level in a muscle biopsy.[13] The mechanism of dominant mutations is yet to be uncovered fully, and hence a future adeno-associated virus (AAV)-based calpain-3 treatment may not benefit patients with autosomal-dominant calpainopathy. This highlights the importance of accurate clinicogenetic characterization of these patients.

BIOCHEMICAL PARAMETERS

The CK levels are typically the highest in dysferlinopathies, going upward of 200 times normal.[14] The dominant forms have only a mild elevation in CK. The CK levels vary with activity and decline over the course of the disease.

Pathology

Characteristically, CK levels exhibit the prototypical dystrophic pattern with necrosis (pale-staining, liquefied/hyaline fibers) and regeneration (basophilic fibers with vesicular nuclei). There is fatty replacement of muscle tissue accompanied by fibrosis, along with classical features of muscle fiber atrophy and hypertrophy. Some diseases may show prominent inflammation as in dysferlin and calpain leading to a confusion with inflammatory myopathy. The earlier diseases which had myofibrillar disarray on the biopsy were removed from the newer classification system; these include desmin and myotilin.

Immunofluorescence helps in diagnostic confirmation of patients carrying variants of uncertain significance (VUS); however, they are not available for all the subtypes of LGMD. In the case of calpainopathies, western blotting on the muscle biopsies for the three fractions of protein (94, 60, and 30 kd) is helpful to identify absence or severe reduction of calpain-3 bands. But calpain may be reduced secondarily in patients with dysferlinopathy, titinopathies, dystrophinopathies, LMNA (Lamin A/C), and CAV3 (Caveolin-3), and hence we should be careful about false-positive results. The reduced levels of calpain may be due to its rapid half-life and/or the biopsy-processing conditions. Dysferlin is deficient in patients with dysferlinopathy on immunohistochemistry, but abnormal dysferlin expression is noted in several dystrophies. The abnormal localization of dysferlin is seen in dystrophinopathies, sarcoglycanopathies, and calpainopathies, and rarely FKRP- and LMNA-related dystrophies too.[15] In these conditions, the dysferlin expression is markedly reduced with patchy sarcolemmal staining and variable cytoplasmic staining of dysferlin. Immunoblot can be particularly useful in such conditions, as dysferlin is absent in dysferlinopathies, whereas its

JAYPEE BROTHERS

levels are normal or even increased in other dystrophies. **Figures 3A and B** depict the biopsy features in a case of LGMD.

There are peculiar features for each subtype, some of which are described as follows:

- *Calpainopathy*: Eosinophilic myositis, lobulated fibers
- *Dysferlinopathy*: Mimics polymyositis
- *Telethoninopathy*: Centronucleated fibers, lobulated fibers, type 1 predominance
- *Anoctaminopathy*: Congo red staining may reveal amyloid deposits in the intramuscular blood vessel walls and within the interstitium
- *DNAJB6*: Abnormal protein aggregates and rimmed vacuoles

Recent research focuses on transcriptomic profiling of muscle samples to identify up-/downregulation of genes related to various pathways involved in inflammation/immune response, sarcomere organization, straited muscle contraction/development, and extracellular matrix remodeling. Muti-omics approaches help us identify potential mechanisms and therapeutic targets.[16]

Genetics

While extensive myopathy panels containing over 200 genes were employed previously, whole-exome sequencing has increasingly become the preferred modality for routine testing. Although specific tests for founder variants have been identified, their utility is largely restricted to the respective ethnic populations in which these variants are prevalent. The c.3191G>A variant in the *dysferlin* gene was the most recurrent mutation identified in a study conducted by the authors.[17] Studies from China, Korea, and the United States have demonstrated distinct recurrent variants in different populations. The common variants causing calpainopathy included c.1343G>A and c.1319G>A, along with the Agarwal founder mutations c.2051-1G>T and c.2338G>C, in our cohort.[18] In *SGCB*, the c.544A>C (p.Thr182Pro) variant was frequent in our patients while the c.525del variant was identified in more than 90% of French SGCG patients.[8] The FKRP 826C>A mutation is the most prevalent variant in Europe, while the c.545A>G variant is commonly reported in China.[16] Similarly, c.191dupA represents a Northern European

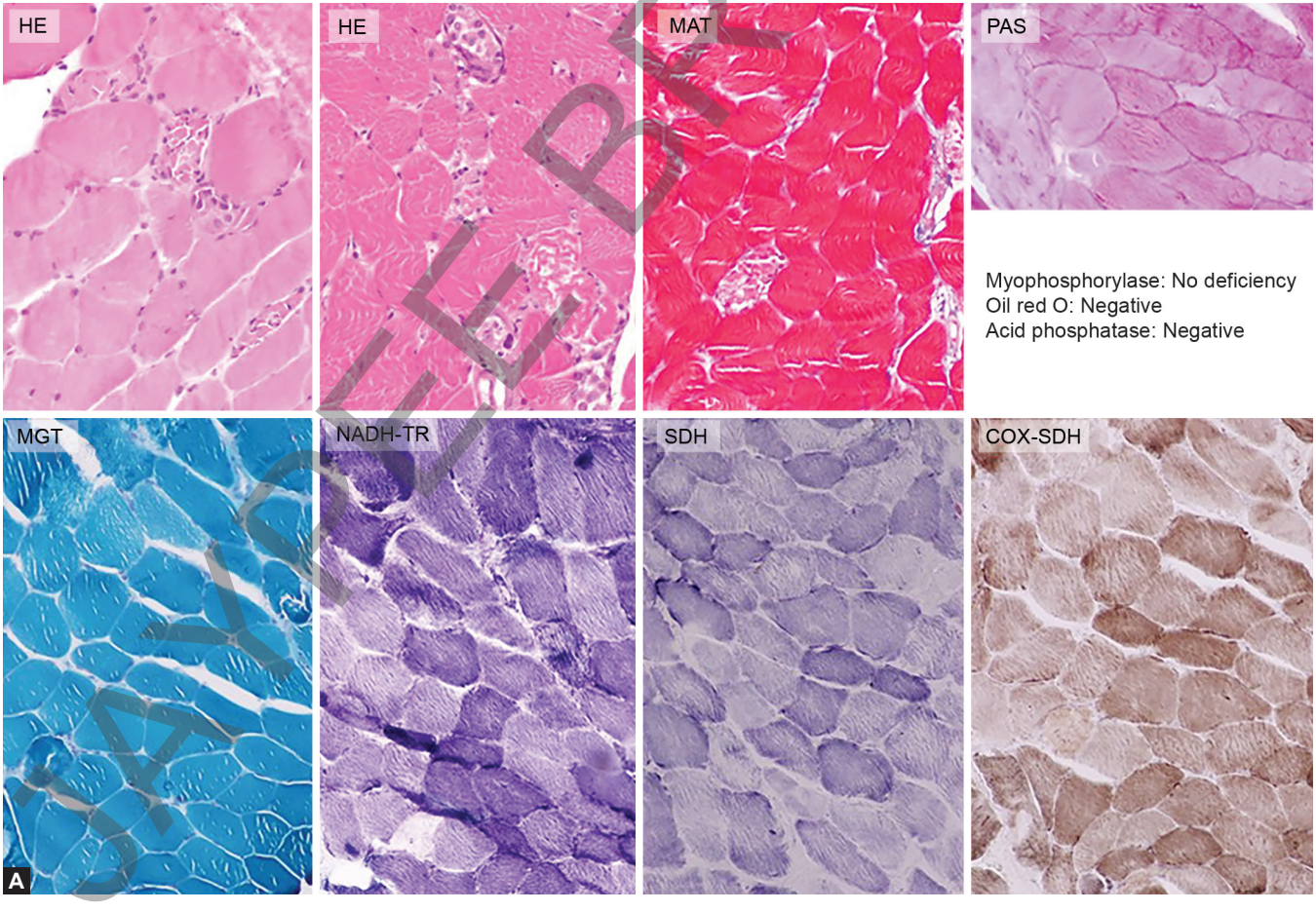

FIGS. 3A AND B: *Continued*

SAMPLE PROOFS

Continued

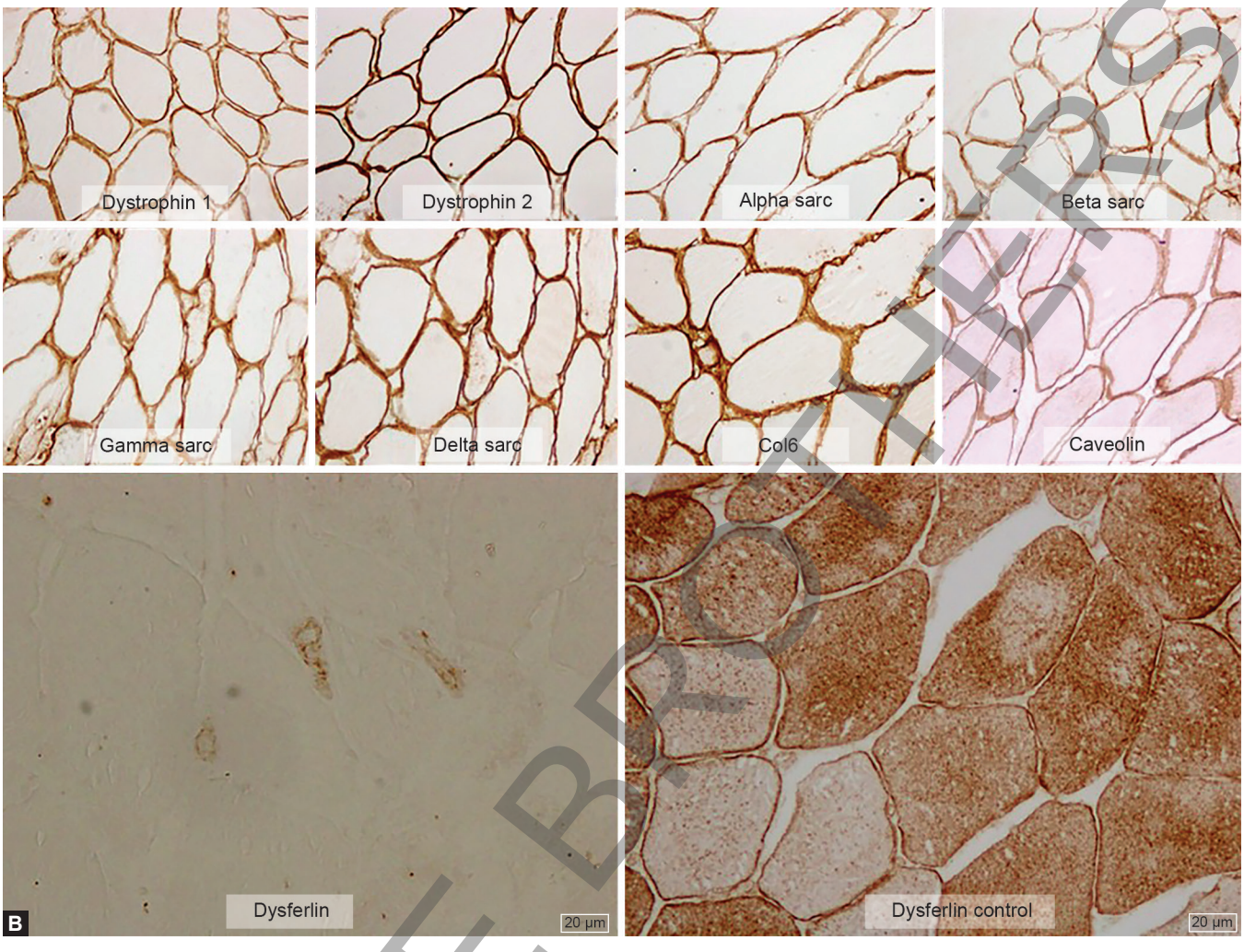

FIGS. 3A AND B: (A) Representative microphotographs showing histopathological changes. Hematoxylin and eosin (HE) stains show hypertrophic fibers, variation in fiber size, scattered atrophic fibers, and myophagocytosis. These changes are highlighted on the Masson trichrome stain (MAT). No ragged red fibers are seen on modified Gomori trichrome (MGT) and no ragged blue fibers are seen on NADH (nicotinamide adenine dinucleotide hydratase) or SDH (succinate dehydrogenase) stains. No COX-deficient fibers are seen. (B) Representative images of muscle immunohistochemistry: Preserved stains for dystrophin 1 and 2, alpha, beta, gamma and delta sarcoglycan, collagen-6, caveolin with loss of stain for dysferlin in a patient with dysferlinopathy (the adjacent image shows preserved stain in control).

JAYPEE BROTHERS

founder mutation associated with anoctaminopathy.[3] The GMPPB variant c.79G>C is the most common pathogenic variant among the compound heterozygous variants.[19] The GMPPB c.1000G>A variant is a common founder mutation in an ethnic community of South Indian descent.[9] Regarding genotype–phenotype correlation, most studies in recessive LGMDs fail to reveal a direct correlation.

It is important to consider the inheritance pattern while interpreting genetic variants and also recognizing that pseudodominant inheritance may occur in regions with high rates of consanguinity. Many patients harbor VUS; in such cases, correlation with other investigations, particularly muscle magnetic resonance imaging (MRI) and muscle biopsy findings, is recommended. In centers where available, RNA sequencing from muscle tissue may further aid diagnostic confirmation. In a cohort of 4,656 patients, about 72% had VUS, while only 23% had pathogenic variants.[2] It is now well recognized that intronic and regulatory region variants, large deletions and duplications in known genes, complex genetic rearrangements, oligogenic inheritance, and modifier gene effects may underlie LGMD subtypes that remain genetically unclassified.[21]

In cases where only a single pathogenic variant is identified in disorders with biallelic inheritance, screening for large deletions or duplications in the same gene using multiplex ligation-dependent probe amplification (MLPA) may be useful. Muscle biopsy with immunostaining can also aid diagnosis in selected cases.

Evaluation of other affected family members may also provide important diagnostic clues.

In silico variant modeling may help determine the pathogenic significance of novel variants. Additionally, functional studies using patient-derived stem cells can provide further evidence regarding the downstream effects of these variants; however, such studies are time-consuming and are not widely available in routine clinical practice.

Negative Exome Testing

Whole-genome sequencing may also be considered; however, long-read whole-genome sequencing represents the latest advancement and holds promise for identifying previously unrecognized causes, including repeat expansion disorders such as facioscapulohumeral muscular dystrophy (FSHD), a well-known phenotypic mimicker of LGMD. Long read sequencing can identify ultralong reads of 10,000 nucleotides, includes regions unmappable by short read sequencing; can cover exonic, splice-site, deep intronic, regulatory, copy number and copy neutral structural variation; short tandem repeat expansions, variants in complex genomic regions, it can detect epigenetic changes such as DNA methylation and can phase variants when segregation is difficult.[1] But it carries the risk of identifying secondary or incidental findings. Omics-based approaches, including RNA sequencing, proteomics, and metabolomics, are currently primarily research tools and hold promise for identifying the downstream functional effects of genetic variants; however, these techniques are time-consuming and labor-intensive.

Muscle MRI

The T1 or 3-point Dixon sequences allow to identify fatty infiltration and short tau inversion recovery (STIR)/T2 sequences identify edema. They serve as valuable biomarkers in natural history studies, where fat fraction analysis can quantify disease progression and potentially influence therapeutic strategies in LGMD.

The pattern and selective muscle involvement can provide clues to the specific type of muscular dystrophy, thereby aiding the development of diagnostic algorithms and heatmaps. Preserved gracilis and sartorius on muscle imaging is the common denominator for most LGMDs. Certain subtypes demonstrate a proximal to distal gradient of fatty infiltration among various thigh muscles, especially sarcoglycanopathy. Concentric fatty infiltration pattern and compensatory hypertrophy of uninvolved muscles are common. **Figure 4** depicts the muscle MRI findings in some common forms of LGMD.

Dystrophinopathies: Gluteus maximus and medius are involved from the onset. Iliopsoas is usually preserved. In the thighs, there is involvement of all compartments but sparing of sartorius, gracilis, and adductor longus.

Sarcoglycanopathies: Proximal muscles are involved early. Leg muscles are spared well into the advanced stages of disease.

Dysferlin and calpain-related LGMD: Selective involvement of the posterior compartment of thigh and leg muscles. Two studies in LGMDR1 mentioned pseudocollagen sign in the quadriceps; one study found it in 13/18 and the other in 29/57.[22] An overview of the MRI findings is summarized in **Table 3**.

DIFFERENTIAL DIAGNOSIS

- Acquired disorders such as 3-hydroxy-3-methylglutaryl coenzyme A reductase (HMGCR) myopathy and signal recognition particle (SRP) myositis mimic a long-standing dystrophy-like illness.
- Spinal muscular atrophy can mimic dystrophy.
- Pompe disease can mimic LGMD; respiratory symptoms at onset are typical of Pompe disease.
- *Others*: Duchenne muscular dystrophy, facioscapulohumeral muscular dystrophy, oculopharyngeal muscular dystrophy, myotonic dystrophy, laminopathies, myofibrillar myopathies, metabolic myopathies, inclusion body myositis, and some diseases with multigenic modes of inheritance.

OUTCOME MEASURES FOR THERAPIES

The clinical outcome study for dysferlinopathy used the North Star Ambulatory Assessment for LGMD (NSAD). It has a total of 29 items, with a maximum score of 54 points. Other tools are performance of upper limb and timed tests (rise from floor, 10-m walk/run, 4-stair climb and descend, timed up and go, 6-minute walk test, etc.).[23] Spirometry and gait analysis may be needed for selected patients during the course of illness. Muscle MRI is a valuable tool for assessing therapeutic effects on muscle, while robust biomarkers need to be developed and validated to evaluate drug efficacy in clinical trials.

Therapies

There are no curative therapies that exist. We are in an exciting era of gene-based therapies which promise cutting-edge technologies to be applied across many different genotypes, hence the need for natural history studies, phenotypically and genotypically well-characterized cohorts, and readily available outcome measures and biomarkers to study the effect of these therapies. A multidisciplinary approach involving physical therapy and rehabilitation using assistive devices, cardiac

JAYPEE BROTHERS

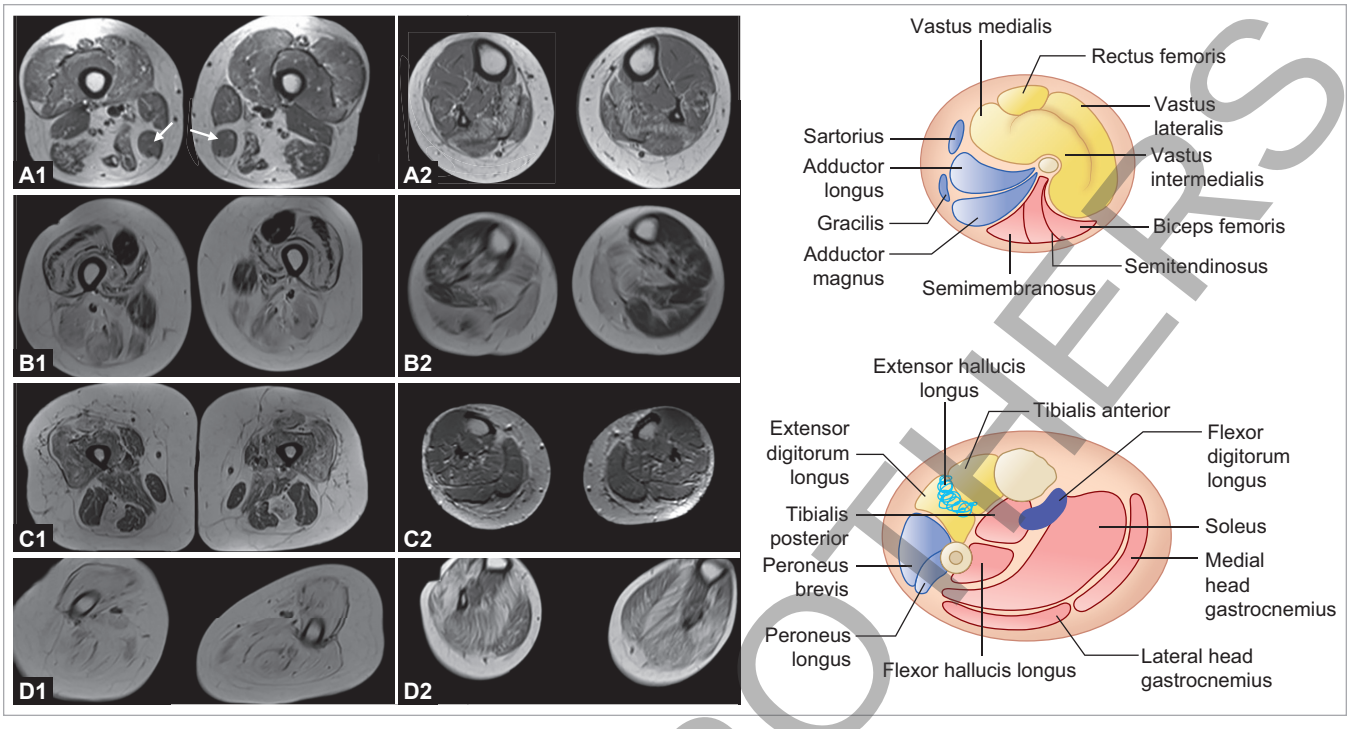

FIG. 4: The right half of the image shows a diagrammatic and simplified representation of thigh and leg muscles. The images on the left side are of thigh sections on the left-hand side and leg sections on the right-hand side. A1: Atrophy of posterior and medial thigh muscles with preserved anterior thigh, hypertrophied sartorius and gracilis, and preserved biceps femoris in a patient with dysferlinopathy. A2: Atrophy of soleus in a patient with dysferlinopathy. B1: Patient with calpainopathy showing pseudocollagen sign wherein a part of muscle within the bulk of vastus lateralis and vastus medialis is preserved centripetally. Rectus femoris and sartorius are hypertrophied. Medial and posterior thigh muscles are atrophied. B2: Patient with calpainopathy showing atrophy of medial gastrocnemius and soleus. C1: Patient with transportinopathy (LGMDD2) showing atrophy of thigh muscles with preserved sartorius and gracilis and atrophic semitendinosus with preserved semimembranosus and biceps. C2: Patient with transportinopathy (LGMDD2) showing hypertrophy of calf muscles. D1 and D2: Patient with sarcoglycanopathy with advanced thigh muscle atrophy with still preserved leg muscles; in fact, calf muscles show hypertrophy which is typical.

TABLE 3: Overview of MRI of muscle findings in lower limbs in LGMDs in the early phase of illness.[30]

Type	Pelvis: Affected muscles	Pelvis: Spared muscles	Thigh: Affected muscles	Thigh: Spared muscles	Leg: Affected muscles	Leg: Spared muscles
Dystrophinopathy	GMx, GMe	IL	All comp	Sa, Gr, AL	GM, SOL, P	
Calpainopathy	GMe, GMi	GMx	Posterior thigh, SM, AM, AL, VIM, RF	Vastii, Sa, Gr	GMmed, SOL	GMlat, P, TA, TP
Dysferlinopathy	GMi, TFL	IL	AM f/b VL, VM, VIM	Bs, Sa, Gr	GMmed, SOL	TP
Sarcoglycanopathy	All Glutei especially GMe, IL		All comp	Sa, Gr	Spared	All
FKRP	All Glutei	IL	B, SM, ST, VI, RF, AM	Sa, Gr, O	GM, SOL	TA, P
Titinopathy			Posterior thigh, RF		TA	
Anoctaminopathy (asymmetry noted)	GMx	All Spared	VL, ST, AD, Posterior thigh	RF, Sa, Gr,Bs	GMmed, SOL	

(AB: adductor brevis; AD: adductors; AL: adductor longus; AM: adductor magnus; B: biceps; Bs: biceps short head; Bl: biceps long head; Comp: compartments; f/b: followed by; GM: gastrocnemius; GMx: gluteus maximus; GMe: gluteus medius; GMi: gluteus minimus; GMlat: gastrocnemius lateralis; GMmed: gastrocnemius medialis; Gr: gracilis; IL: iliopsoas; O: obturators; RF: rectus femoris; P: peroneii; Sa: sartorius; SM: semimembranosus; SOL: soleus; TA: tibialis anterior; TFL: tensor fasciae latae; TP: tibialis posterior; VIM: vastus intermedialis; VL: vastus lateralis; VM: vastus medialis)

and pulmonary surveillance, sleep support and genetic counseling and support with family planning, and prenatal and preimplantation genetic diagnosis is the centerstage of therapy.

Steroid therapy in patients with dysferlinopathies was tried in a double-blind trial; however, it failed to show any benefit.[24] Vamorolone and deflazacort have been tried too. Sevasemten targets fast myosin to prevent

JAYPEE BROTHERS

contraction injury. Exon skipping too was studied. However, they have failed to show any significant benefit in LGMDs.

Stem Cell Transplantation

Autologous and allogenic stem cell transfer have been tried. These stem cells carry the normal copy of gene and help express the deficient protein. Myoblast transplantation has also been tried; however, they failed to show any substantial benefit.[25]

Gene Replacement Therapy

Gene replacement therapy works to replace the defective gene. It is likely to be a one-time therapy.

Many of these LGMDs are well suited for gene replacement by AAV because most of these genes have short coding sequences. Next-generation AAV are developed to improve delivery, identifying muscle-tropic capsids through directed evolution.[26] The current AAVs have compact and potent promoter regions: MHCK7, CK family, d/Tmck, and SPC5-12 which can drive expression specifically in skeletal or cardiac muscle or both. We also have a library of post-translational regulatory elements including cis regulatory modules, splice switching, and miRNA-binding sites. Capsid designs have improved over the years too: MyoAAV family, AAVMYO, AAV-SLB101, etc., help us target the muscle without the side effects in liver. They are designed to achieve higher expression at lower doses while minimizing off-target adverse effects. They require integrin homodimers in mouse and human cells. However, some proteins such as dysferlin have a larger size which is beyond the delivery capacity of AAV.

These therapies are not without adverse effects, including the potential risk of immune reactions. They are currently under trials: Askbio and Atamyo for FKRP; Sarepta has started trials for dysferlin and sarcoglycan.[3]

A first-in-human, phase 1/2 open-label trial (n = 6 patients) on bidridistrogene xeboparvovec, an AAV-based gene therapy containing a codon-optimized, full-length human *SGCB* transgene, showed a favorable safety profile. The expression of SGCB in muscle biopsies increased at 60 days and 2 years. Post hoc exploratory analysis showed preliminary motor improvements using the North Star Assessment for LGMDs maintained through year 2.[27]

Gene editing using the CRISPR-Cas9 system has been tried in mice models of calpain which showed an increase in the calpain mRNA.

Small Molecules

Small molecules act on downstream actions from loss of protein. An example is ribitol for FKRP-related dystrophy. They are usually administered orally. Ribitol 5-phosphate is a functional glycan unit required for alpha-dystroglycan function. Enzyme activities of isoprenoid synthase (ISPD), fukutin, and FKRP contribute to synthesis of ribitol 5-phosphate. FKRP expression in mice heart was increased in the presence of ribitol and specially when it is given in combination with high-dose AAV-FKRP.[28,29] There is an ongoing phase 3 randomized controlled trial (RCT) in patients with FKRP (LGMDR9).

CONCLUSION

Research in LGMDs is advancing at a pace hitherto unseen. There are developments in the domains of both diagnostic tests and therapeutics. Trial readiness is an issue, especially in developing countries, so that our patients are eligible for drug trials as and when they are designed, hence the need for accurate phenotyping, genotyping, proper follow-ups, screening for associated cardiorespiratory complications, and appropriate genetic counseling. Prenatal and preimplantation diagnoses have revolutionized the disease management.

TYPEBROTHERS

REFERENCES

1. Straub V, Clause AR, Donkervoort S, Kang PB, Laverty CG, Niu Z, et al. Expert Consensus on Genetic Diagnostic Approaches for Patients With Limb-Girdle Muscular Dystrophy. Neurology. 2025;105(10):e214291. doi: 10.1212/WNL.0000000000214291.
2. Johnson NE, Statland JM. The Limb-Girdle Muscular Dystrophies. Continuum. 2022;28(6):1698-714. doi:10.1212/CON.0000000000001178.
3. Georganopoulou DG, Moisiadis VG, Malik FA, Mohajer A, Dashevsky TM, Wuu ST, et al. A Journey with LGMD: From Protein Abnormalities to Patient Impact. Protein J. 2021;40(4):466-88. doi:10.1007/s10930-021-10006-9.
4. Straub V, Murphy A, Udd B, Corrado A, Aymé S, Bönneman C, et al. 229th ENMC international workshop: Limb girdle muscular dystrophies – Nomenclature and reformed classification Naarden, the Netherlands, 17–19 March 2017. Neuromuscul Disord. 2018;28(8):8. doi:10.1016/j.nmd.2018.05.007.
5. Khadilkar SV, Faldu HD, Patil SB, Singh R. Limb-girdle Muscular Dystrophies in India: A Review. Ann Indian Acad Neurol. 2017;20(2):87-95. doi:10.4103/aian.AIAN_81_17.
6. Harris E, Bladen CL, Mayhew A, James M, Bettinson K, Moore U, et al. The Clinical Outcome Study for dysferlinopathy. Neurol Genet. 2016;2(4):e89. doi:10.1212/NXG.0000000000000089.
7. Wicklund MP, Kissel JT. The limb-girdle muscular dystrophies. Neurol Clin. 2014;32(3):729-49, ix. doi: 10.1016/j.ncl.2014.04.005.
8. Bardhan M, Anjanappa RM, Polavarapu K, Preethish-Kumar V, Vengalil S, Nashi S, et al. Clinical, genetic profile and disease

progression of sarcoglycanopathies in a large cohort from India: high prevalence of SGCB c.544A > C. Neurogenetics. 2022;23(3):187-202. doi:10.1007/s10048-022-00690-9.
9. Polavarapu K, Mathur A, Joshi A, Nashi S, Preethish-Kumar V, Bardhan M, et al. A founder mutation in the GMPPB gene [c.1000G > A (p.Asp334Asn)] causes a mild form of limb-girdle muscular dystrophy/congenital myasthenic syndrome (LGMD/CMS) in South Indian patients. Neurogenetics. 2021;22(4):271-85. doi: 10.1007/s10048-021-00658-1.
10. Angelini C, Pegoraro V, Cenacchi G. The clinical and molecular spectrum of autosomal dominant limb-girdle muscular dystrophies focusing on transportinopathy. Expert Opin Orphan Drugs. 2019;7(5):223-32. https://doi.org/10.1080/21678707.2019.1622412.
11. Ruggieri A, Saredi S, Zanotti S, Pasanisi MB, Maggi L, Mora M. DNAJB6 Myopathies: Focused Review on an Emerging and Expanding Group of Myopathies. Front Mol Biosci. 2016;3:63. doi:10.3389/fmolb.2016.00063.
12. Jonson PH, Palmio J, Johari M, Penttilä S, Evilä A, Nelson I, et al. Novel mutations in DNAJB6 cause LGMD1D and distal myopathy in French families. Eur J Neurol. 2018;25(5):790-4. doi:10.1111/ene.13598.
13. Krag T, Nasho E, Brady L, Verebi C, Leturcq F, Malfatti E, et al. Variants in CAPN3 Causing Autosomal Dominant Limb–Girdle Muscular Dystrophy Combined With Calpain-3 Deficiency. Hum Mutat. 2025;2025:9301465. doi:10.1155/humu/9301465.
14. Bouchard C, Tremblay JP. Portrait of Dysferlinopathy: Diagnosis and Development of Therapy. J Clin Med. 2023;12(18):6011. doi:10.3390/jcm12186011.
15. Lo HP, Cooper ST, Evesson FJ, Seto JT, Chiotis M, Tay V, et al. Limb–girdle muscular dystrophy: Diagnostic evaluation, frequency and clues to pathogenesis. Neuromuscul Disord. 2008;18(1):34-44. doi: 10.1016/j.nmd.2007.08.009.
16. Yuan Q, Xie Z, Lu Y, Liu C, Lu Y, Han X, et al. New genotype–phenotype correlations and transcriptomic findings in limb-girdle muscular dystrophy R9. J Neurol. 2025;272(8):516. doi:10.1007/s00415-025-13252-4.
17. Nashi S, Polavarapu K, Bardhan M, Anjanappa RM, Preethish-Kumar V, Vengalil S, et al. Genotype–phenotype correlation and natural history study of dysferlinopathy: a single-centre experience from India. neurogenetics. 2023;24(1):43-53. doi:10.1007/s10048-022-00707-3.
18. Ganaraja VH, Polavarapu K, Bardhan M, Preethish-Kumar V, Leena S, Anjanappa RM, et al. Disease Progression and Mutation Pattern in a Large Cohort of LGMD R1/LGMD 2A Patients from India. Glob Med Genet. 2021;9(1):34-41. doi:10.1055/s-0041-1736567.
19. Jensen BS, Willer T, Saade DN, Cox MO, Mozaffar T, Scavina M, et al. GMPPB-Associated Dystroglycanopathy: Emerging Common Variants with Phenotype Correlation. Hum Mutat. 2015;36(12):1159-63. doi:10.1002/humu.22898.
20. Nallamilli BRR, Chakravorty S, Kesari A, Tanner A, Ankala A, Schneider T, et al. Genetic landscape and novel disease mechanisms from a large LGMD cohort of 4656 patients. Ann Clin Transl Neurol. 2018;5(12):1574-87. doi:10.1002/acn3.649.
21. Thompson R, Straub V. Limb-girdle muscular dystrophies — international collaborations for translational research. Nat Rev Neurol. 2016;12(5):294-309. doi:10.1038/nrneurol.2016.35.
22. Morishima R, Schoser B. A Straightforward Approach to Analyze Skeletal Muscle MRI in Limb-Girdle Muscular Dystrophy for Differential Diagnosis: A Systematic Review. Muscles. 2023;2(4):374-88. doi:10.3390/muscles2040029.
23. Moore U, Jacobs M, James MK, Mayhew AG, Fernandez-Torron R, Feng J, et al. Assessment of disease progression in dysferlinopathy. Neurology. 2019;92(5):e461-74. doi:10.1212/WNL.0000000000006858.
24. Walter MC, Reilich P, Thiele S, Schessl J, Schreiber H, Reiners K, et al. Treatment of dysferlinopathy with deflazacort: a double-blind, placebo-controlled clinical trial. Orphanet J Rare Dis. 2013;8(1):26. doi:10.1186/1750-1172-8-26.
25. Bouchard C, Tremblay JP. Limb–Girdle Muscular Dystrophies Classification and Therapies. J Clin Med. 2023;12(14):4769. doi:10.3390/jcm12144769.
26. Tabebordbar M, Lagerborg KA, Stanton A, King EM, Ye S, Tellez L, et al. Directed evolution of a family of AAV capsid variants enabling potent muscle-directed gene delivery across species. Cell. 2021;184(19):4919-38.e22. doi:10.1016/j.cell.2021.08.028.
27. Mendell JR, Pozsgai ER, Lewis S, Griffin DA, Lowes LP, Alfano LN, et al. Gene therapy with bidridistrogene xeboparvovec for limb-girdle muscular dystrophy type 2E/R4: phase 1/2 trial results. Nat Med. 2024;30(1):199-206. doi:10.1038/s41591-023-02730-9.
28. Cataldi MP, Lu QL. Ribitol and ribose treatments differentially affect metabolism of muscle tissue in FKRP mutant mice. Sci Rep. 2025;15(1):1329. doi:10.1038/s41598-024-83661-4.
29. Cataldi MP, Vannoy CH, Blaeser A, Tucker JD, Leroy V, Rawls R, et al. Improved efficacy of FKRP AAV gene therapy by combination with ribitol treatment for LGMD2I. Mol Ther. 2023;31(12):3478-89. doi:10.1016/j.ymthe.2023.10.022.
30. Díaz-Manera J, Llauger J, Gallardo E, Illa I. Muscle MRI in muscular dystrophies. Acta Myol. 2015;34(2-3):95-108.

JAYPEE BROTHERS

for detailed information on neurology books, visit our website www.ejaypee.com, for detailed information on neurology books, visit our website www.ejaypee.com, for detailed inf

IAN Reviews in NEUROLOGY 2026

Neuromuscular Disorders

A Comprehensive Update

Salient Features

- Comprehensive update about Neuromuscular Disorders from the Indian Academy of Neurology.
- This 26 chapter volume, written by leading experts in the field, provides in depth discussion of the clinical assessment, immunopathogenesis, diagnostic approaches, and current management options for diverse neuromuscular diseases. It is an essential reference for clinicians and trainees seeking an up to date, clinically relevant synthesis of advances in diagnosis and therapy of Neuromuscular Disorders.

Sita Jayalakshmi MD DM FIAN is a Senior Consultant and In-Charge of the Comprehensive Epilepsy Care Programme in the Department of Neurology at Krishna Institute of Medical Sciences, Secunderabad, Telangana, India. She currently serves as the CME Convenor of the Indian Academy of Neurology and as Treasurer of the Indian Epilepsy Society. She has authored more than 150 publications in peer-reviewed journals and serves on the editorial boards of the Annals of Indian Academy of Neurology and Neurology India. She is the recipient of the 2023 A.B. Baker Teacher Recognition Award from the American Academy of Neurology.

Sudhir Kothari MD DM FIAN FRCP is Head of the Department of Neurology at Poona Hospital and Research Centre, Pune, Maharashtra, India, and President-Elect of the Indian Academy of Neurology. His principal areas of interest include neurotology, migraine, and functional neurological disorders. He is the Managing Trustee of the Forum for Indian Neurology Education (FINE), which conducts educational programs for neurologists across India. He has previously served as an Executive Committee member of the Indian Academy of Neurology and as President of the Maharashtra Association of Neurology and the Society for Neurosciences, Pune. He co-edited the Indian Academy of Neurology's guidelines on vertigo and is the author of *Blind to the Mind*.

JAYPEE BROTHERS

Shelving Recommendation
NEUROLOGY

ISBN 978-81-6799-973-3

Buy from ejaypee

JAYPEE BROTHERS