, visit our website www.ejaypee.com, for detailed information on nursing books, visit our website www.ejaypee.com, for detailed information on nursing books, visit our website www.ejaypee.com,



The Clinical Case Record Book for

Midwifery

As per the GNM Nursing Curriculum

Name of the Candidate: _____

Name of the Institution: _____

_____

Manju Chhugani
Renu Kharb
Preysi Chauhan

Foreword
Deepika C Khakha

JAYPEE

JAYPEE BROTHERS

Contents

Chapter No.	Contents	Page No.
1.	**Anatomy**	1
2.	**Pregnancy Assessment and Antenatal Care** • Urine Pregnancy Test • History Collection in the Obstetric Patient • Antenatal Assessment • High Risk Scoring System • Antenatal Advices • Warning Signs in Pregnancy • Micro Birth Planning	9
3.	**Intranatal Care** • Stages of Labor • Physiology of Normal Labor • Mechanism of Labor • Nursing Assessment During Labor With Modified Who Partograph • Nursing Care During First, Second, Third and Fourth Stage of Labor • Episiotomy Care and Suturing • Placental Examination with Membranes and Umbilical Cord • Perineal Tear and Management • Cervical Tear and Vaginal Tear • Vulval Hematoma • Uterine Rupture	19
4.	**Postnatal Care** • Normal Puerperium • Postnatal Assessment of Women • Postnatal Advices and Exercises • Management of Common Gynecological Issues	34
5.	**Newborn Care** • Characteristics of Healthy Term Newborn • Assessment of Newborn • Nursing Care and Diagnosis	39
6.	**Planned Parenthood and Family Planning** • Role of Nurse Midwife in Planned Parenthood • Family Planning Methods • Insertion and Removal of Cu-T	43
7.	**Drugs and Instruments Used in Obstetrics**	50
8.	**Abnormal Obstetrics and Neonatology** • Disorders of Pregnancy • Mal-Positions and Malpresentations • Instrumental and Operative Delivery • Birth • Neonatal Resuscitation • Kangaroo Mother Care	56

JAYPEE BROTHERS

Chapter No.	Content	Page No.
9.	**National Health Care Programs Related to Maternal Health** • Key Strategic Programs Launched for Reducing the Maternal Mortality Ratio • Key Strategic Programs Launched for Reducing the Child Mortality Ratio • Respectful Maternity Care • Sample Questions for Preparation of Viva-Voce	72
	Practical Record • Filled Sample Performa • Filled Sample of ANC • Filled Sample of Conduction of Normal Deliveries • Filled Sample of Per-Vaginal Examinations. • Filled Sample of Episiotomy and Suturing • Filled Sample of Postnatal Care • Filled Sample of Insertion of IUCD • Filled Sample of Newborn Resuscitation • Performa for Witness Normal Deliveries – 5 • Performa for Witness Abnormal Deliveries – 5 • Performa for Witness Obstetrical Operations Including Assisting in Caesarean Section – 5 • Performa of Ante Natal Case Palpation – 20 • Performa for Conduction of Normal Deliveries – 20 • Performa for Per-Vaginal Examinations – 5 • Performa for Episiotomy and Suturing – 5 • Performa for Postnatal Care – 20 • Performa for Insertion of IUCD – 5 • Performa for Newborn Resuscitation – 5	81

UNIQUE FEATURE OF THE CASE BOOK

- ❖ Simple language and comprehensive presentation of topics.
- ❖ Theoretical information is given as per the MoHFW guidelines.
- ❖ Filled samples of proforma are given to guide the students.
- ❖ For preparation of viva voce, practice questions are given in this case book.

JAYPEE BROTHERS

CHAPTER 1

Anatomy

This chapter deals with the anatomical aspects of the female pelvis and fetal skull. The chapter covers various aspects of female pelvis including functions of pelvis, types of pelvis, pelvic bones, ligaments, important landmarks, and pelvic diameters. The chapter includes the fetal skull, its areas/landmarks, parts of the fetal skull, diameters, fontanelles, and sutures of the fetal skull. The anatomy of the female pelvis and fetal skull is critical in understanding the normal mechanism of labor.

FEMALE PELVIS

Definition

The bony pelvis forms the bony part of the birth canal through which the fetus passes during the process of labor.

Functions of Pelvis

- The primary function of the pelvic girdle is to allow movement of the body, especially walking and running.
- The pelvis bears the weight of the sitting body onto the ischial t.
- It permits the person to sit and kneel. The women's pelvis is adapted for childbearing and because of its increased width and rounded brim, women are less speedy than men. It also helps in locomotion and posture.
- The pelvis affords protection to the pelvic organs and to a lesser extent, to the abdominal organs.
- The sacrum transmits the cauda equina and distributes the nerves to the various parts of the pelvis.

Types of Pelvis

On the basis of shape of inlet, the female pelvis is divided into four parent types:

1. Gynecoid (50%)
2. Anthropoid (25%)
3. Android (20%)
4. Platypelloid (5%)

Pelvic Bones

- Two innominate bones (composed of ilium, ischium and pubis)
- One sacrum
- One coccyx

Innominate Bones (Ilium, Ischium and Pubis) (Fig 1.1)

- **Ilium:** Ilium is the large flared outer part. Main features are: Iliac crest (upper border of ilium; when hands are placed on the hip, it rests on the iliac crest) and 2/5th of acetabulum (deep cup to receive the head of the femur).
- **Ischium:** It is the thick lower part 2/5th of acetabulum. Main features are: Ischial tuberosities (large prominence on which the body rests while sitting). Ischial spines (inwards projection above the tuberosity). Lower border of obturator foramen.
- **Pubic bone:** This bone forms the anterior part 1/5th of acetabulum. Main features are: Superior ramus and inferior ramus (two ear like projections), symphysis pubis, pubic arch (two inferior rami forms the pubic arch).

JAYPEE BROTHERS

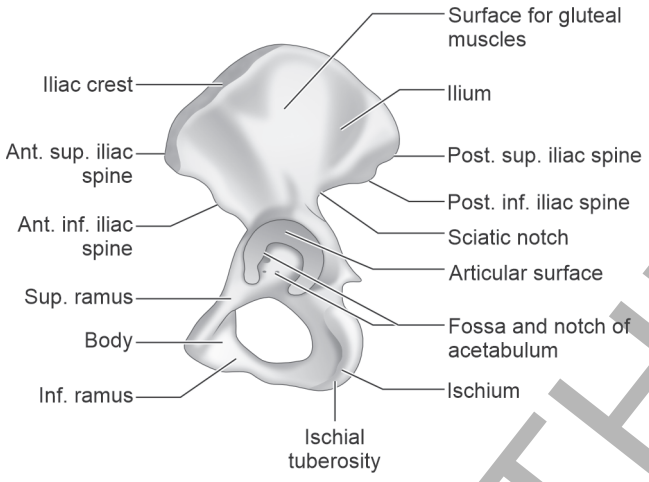

Fig. 1.1: Innominate bone.

Sacrum (Fig 1.2)

- Sacrum is a wedge-shaped bone consisting of five vertebrae. The upper border of the first sacral vertebrae just forward is known as the sacral promontory.
- The anterior surface of the sacrum is concave and is referring to as the hollow of the sacrum. Laterally the sacrum extends into a wing or ala.
- Four pairs of holes or foramina pierce the sacrum and, through these, nerves from the cauda equina emerge to supply pelvic organs.

Coccyx (Fig 1.2)

- The coccyx is a vestigial tail. It consists of four fused vertebrae, forming a small triangular bone.
- It is referred to as rudimentary tail.

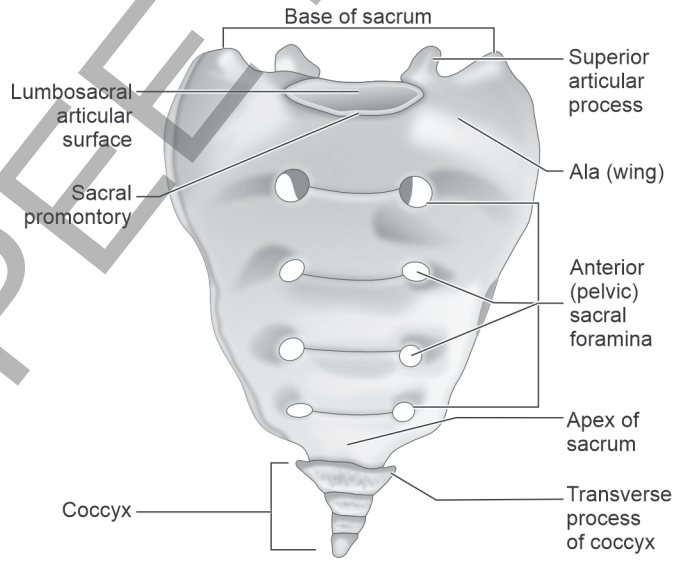

Fig. 1.2: Sacrum and coccyx.

JAYPEE BROTHERS

Joints of Pelvis

There are four pelvic joints:

- Symphysis pubis—1
- Sacroiliac joint—2
- Sacrococcygeal joint—1.

Pelvic Ligaments (Fig 1.3)

Each pelvic joint is held together by ligaments.

- Interpubic ligaments at the symphysis pubis
- Sacroiliac ligament
- Sacrococcygeal ligament
- Sacrotuberous ligament—it runs from the sacrum to the ischial tuberosity
- Sacrospinous ligament—it runs from the sacrum to the ischial spine.

The sacrotuberous ligament and sacrospinous ligament, these two ligaments cross the sciatic notch and form the posterior wall of the pelvic outlet.

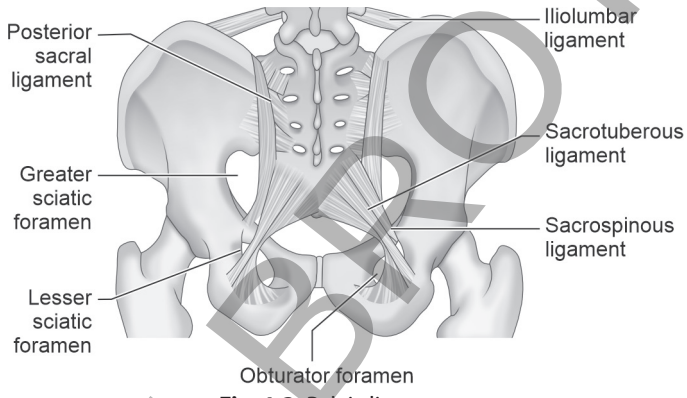

Fig. 1.3: Pelvic ligaments.

Pelvic Muscles (Fig 1.4)

There are two layers of muscle in the pelvic floor.

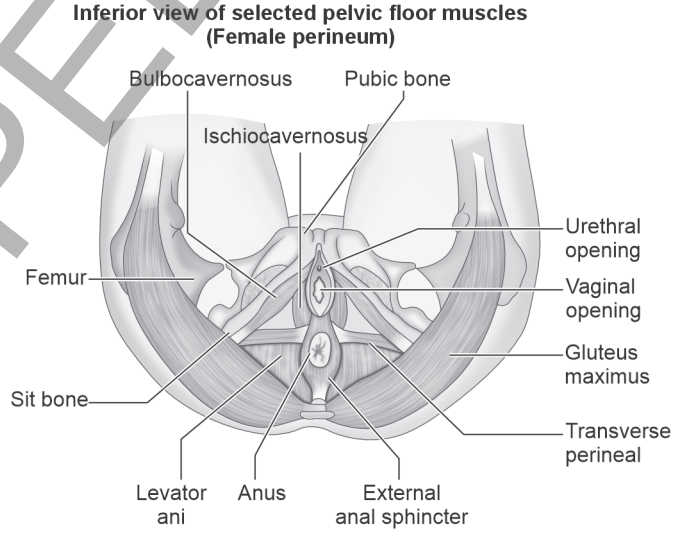

Fig. 1.4: Muscles of the pelvic floor.

JAYPEE BROTHERS

Superficial Layer

This layer is composed of five muscles:
1. External anal sphincter muscles
2. Transverse perineal muscles
3. Bulbocavernosus muscles
4. Ischiocavernosus muscles
5. Membranous sphincter of the urethra

Deep Layer of Muscles

This layer is composed of three pairs of muscles, which together are known as the levator ani muscles. They are so-called because they lift the anus. Each levator ani muscle (right and left) consists of the following:
- ❖ Pubococcygeus muscle
- ❖ Iliococcygeus muscle
- ❖ Ischiococcygeus muscle

False and True Pelvis (Table 1.1)

The pelvis is divided into two parts—the false and the true pelvis.

Table 1.1: True pelvis and false pelvis.

False pelvis	*True pelvis*
• It is the part above the brim and consists mainly of the flared out iliac bones and is bound by the iliac crest • It supports the enlarged uterus during pregnancy • It has very little obstetric importance	• Chief concern to the obstetricians • The true pelvis is the bony canal through which the fetus passes during birth. It has a brim, cavity, and outlet • Shallow in front, formed by the symphysis pubis and measures 4 cm • Deep posteriorly formed by sacrum, coccyx and measures 11.5 cm • It is divided into: Inlet (brim), cavity and outlet

Inlet of Pelvis (Pelvic Brim)

- ❖ The brim is round except where the sacral promontory projects into it.
- ❖ The promontory and wings of the sacrum form its posterior border, the iliac bones its lateral borders, and the pubic bone its anterior border.
- ❖ The midwife needs to be familiar with the fixed points on the pelvic brim, which are known as its landmarks.

Landmarks of the Pelvis (Fig 1.5)

- ❖ Symphysis pubis
- ❖ Pubic crest
- ❖ Pubic tubercle
- ❖ Pectineal line
- ❖ Iliopubic eminence
- ❖ Iliopectineal line
- ❖ Sacroiliac articulation
- ❖ Anterior border of ala of sacrum
- ❖ Sacral promontory

JAYPEE BROTHERS

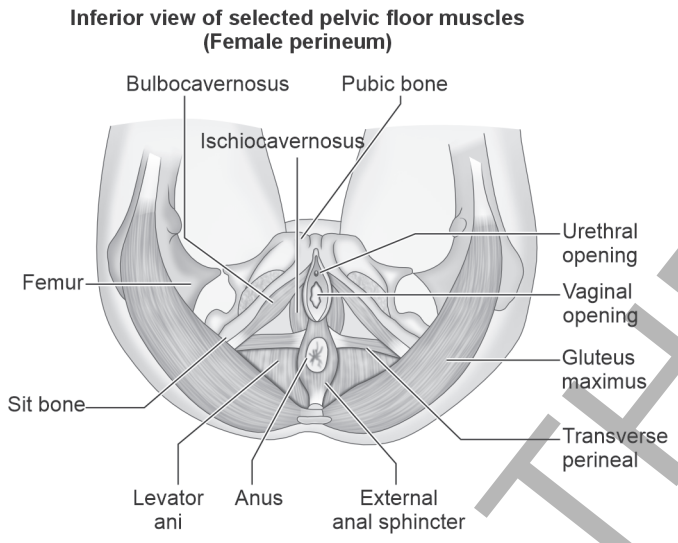

Fig. 1.5: Landmarks of pelvis.

Diameter of Inlet (Table 1.2)

Table 1.2: Diameters of inlet.

Diameter	***Measurement***
Anteroposterior	It is the distance between the midpoint of the sacral promontory to the inner margin of the upper border of the symphysis pubis (11 cm)
Obstetric conjugate	It is the distance between the midpoint of the sacral promontory to prominent bony projection in the midline on the inner surface of the pubic symphysis (10 cm)
Diagonal conjugate	It is the distance between the lower border of the symphysis pubis to the midpoint on the sacral promontory (12 cm) (can be measured during a vaginal examination)
Transverse diameter	It is the distance between the two farthest points on the pelvic brim over the iliopectineal lines (13 cm)
Oblique diameter	There are two oblique diameters—right and left. Each one extends from one sacroiliac joint to the opposite iliopubic eminence (12 cm)
Sacrocotyloid	It is the distance between the midpoint of the sacral promontory to iliopubic eminence (9.5 cm)

Cavity of Pelvis (Table 1.3)

Table 1.3: Diameters of cavity.

Anteroposterior diameter	***Transverse diameter***
It measures from the midpoint on the posterior surface of the symphysis pubis to the junction of 2nd and 3rd sacral vertebrae (12 cm)	It cannot be precisely measured as the points lie over the soft tissues covering the sacrosciatic notches and obturator foramina (12 cm)

Outlet of the Pelvis (Table 1.4)

Table 1.4: Diameters of outlet.

Diameters	Obstetrical outlet	Anatomical outlet
Anteroposterior	It extends from the inferior border of symphysis pubis to the tip of the sacrum (11 cm)	It extends from the lower border of the symphysis pubis to the tip of the coccyx (13 cm)
Transverse	It is the distance between the tips of two ischial spines (10.5 cm) (BISPINOUS)	It measures between the inner borders of the ischial tuberosities (11 cm)
Posterior sagittal	It is the distance between the tip of the sacrum and the midpoint of the bispinous diameter (5 cm)	It is the anteroposterior distance between the sacrococcygeal joint and the midpoint of transverse diameter of outlet (8.5 cm)

JAYPEE BROTHERS

FETAL SKULL

The fetal skull is to some extent compressible and made mainly of thin, pliable tabular (flat) bones forming the vault. This is anchored to the rigid and incompressible bones at the base of the skull. (Table 1.5)

Table 1.5: Sutures and fontanelles of fetal skull.

Sutures (Fig 1.7)	*Fontanelles*
The membranous space between the fetal skull bones is known as a suture. In other words, sutures are cranial joints and are formed where two bones adjoin.	Wide gap in the suture line, where two or more sutures meet.
• Frontal suture—between two frontal bones • Sagittal suture—between two parietal bones • Coronal suture—between two parietal and two frontal bones • Lambdoid suture—between two parietal and one occipital bone. It's shaped like the Greek letter lambda.	**Anterior fontanelle (Bregma)** • It is diamond or kite in shape. About 2.5 cm long and 1.25 cm wide • It is a membranous space at the junction of the sagittal, coronal, and frontal sutures **Posterior fontanelle (Lambda)** • It is situated at the junction of the sagittal and lambdoidal suture • It is smaller than the anterior fontanelle • It is triangular in shape • It should close after 6 weeks of birth

Significance of the Fetal Skull

- It protects the brain.
- Ability to mould during the birth process—fetal skull in relation to the maternal bony pelvis.
- Landmarks of the fetal skull are used to determine fetal position and attitude.

Regions of the Fetal Skull (Fig 1.6)

- **Vertex:** It is the quadrangular area bounded anteriorly by the bregma and coronal sutures, behind by the lambda and Lambdoidal sutures, and laterally by lines passing through the parietal eminences.
- **Brow or sinciput:** The area bounded on one side by the anterior fontanelle and coronal sutures and on the other side by the root of the nose and supraorbital ridges of either side.
- **Face:** It is an area bounded on one side by the root of the nose and other by the junction of the floor of the mouth with the neck.
- **Occiput:** Occiput lies between the foramen magnum and the posterior fontanelle. The part below the occipital protuberance is known as the suboccipital region. The protuberance itself can be seen and felt as a prominent point on the posterior aspect of the skull.

Bones of the Vault

- **The frontal bone**, which forms the forehead. In the fetus, the frontal bone is in two halves, which fuse (join) into a single bone after the age of eight years. These two bones form the baby's forehead or **sinciput**; at the center of each one is a slightly raised area known as a **frontal eminence (**frontal boss).
- **The two parietal bones**, which lie on either side of the skull and occupy most of the area. At the center of each parietal bone is the **parietal eminence** (ossification center).
- **The occipital bone**, which forms the back of the skull and part of its base. It joins with the cervical vertebrae (neck bones in the spinal column, or backbone). This is a single bone that is located at the back of the fetal skull. The occipital bone forms part of the base of the skull, which contains the foramen magnum that protects the spinal cord. At the center, there is the **occipital protuberance**.

JAYPEE BROTHERS

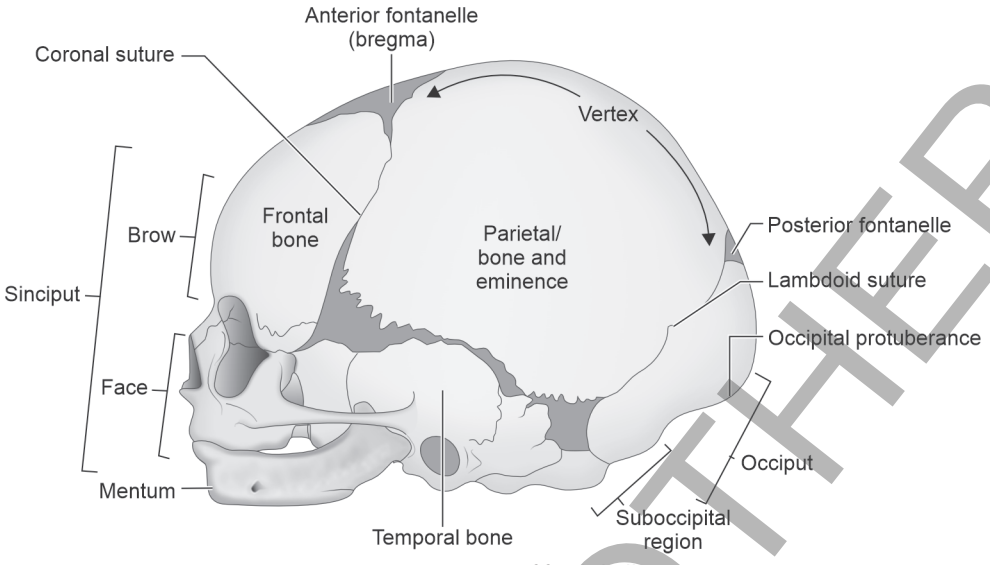

Fig. 1.6: Regions of fetal skull.

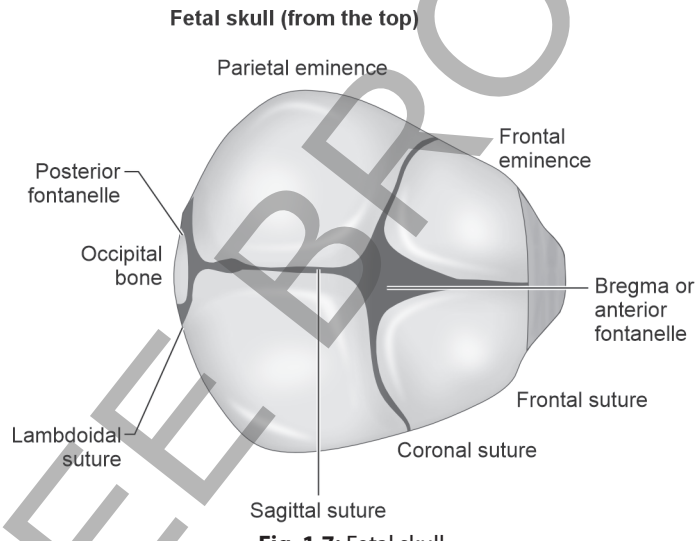

Fig. 1.7: Fetal skull.

❖ **The two temporal bones**, one on each side of the head, closest to the ear. These bones are flat, and their upper aspects form a small part of the vault of the skull; however, they do not have a significant role in childbirth, bone formation, or development.

Diameters of Fetal Skull (Table 1.6)

Table 1.6: Diameters of fetal skull.

Anterior-posterior (Fig 1.8)	*Transverse (Fig 1.9)*
Suboccipito-bregmatic (9.5 cm): Extends from the nape of the neck to the center of bregma	**Biparietal = 9.5 cm:** It extends between two parietal eminences
Suboccipito-frontal (10 cm): Extend from the nape of the neck to the anterior end of the anterior fontanelle	**Super-subparietal = 8.5 cm:** It extends from a point placed below one parietal eminence to a point placed above the other parietal eminence of the opposite side
Occipito-frontal (11.5 cm): Extend from occipital eminence to the root of the nose	**Bitemporal = 8 cm:** It is the distance between the antero-inferior ends of the coronal suture

Contd...

JAYPEE BROTHERS

Contd...

Anterior-posterior (Fig 1.8)	*Transverse (Fig 1.9)*
Mento-vertical (14 cm): Extend from mid-point of the chin to the highest point of on the sagittal suture	**Bimastoid = 7.5 cm:** It is the distance between the tips of the mastoid processes
Submento-vertical (11.5 cm): Extends from the junction of the floor of the mouth and neck to the highest point on the sagittal suture	**Biparietal = 9.5 cm:** It extends between two parietal eminences
Submento-bregmatic (9.5 cm): Extend form junction of the floor of the mouth and neck to the center of bregma	

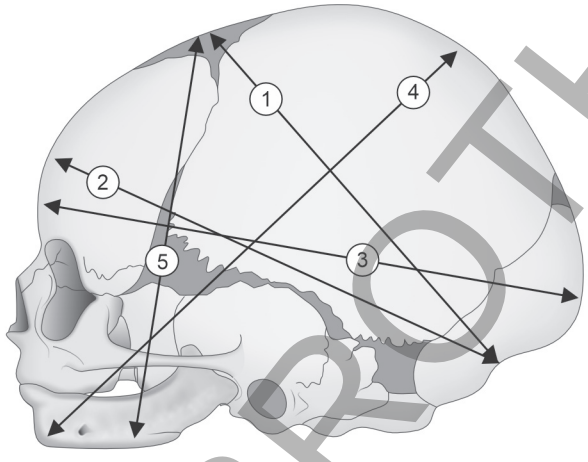

Diameter	*Length*	*Presentation*
1. Suboccipito-bregmatic	9.5 cm	Flexed vertex
2. Suboccipital-frontal	10 cm	Partially deflexed vertex
3. Occipito-frontal	11.5 cm	Deflexed vertex
4. Mento-vertical	14 cm	Brow
5. Submento-bregmatic	9.5 cm	Face

Fig. 1.8: Anterior-posterior diameters of skull.

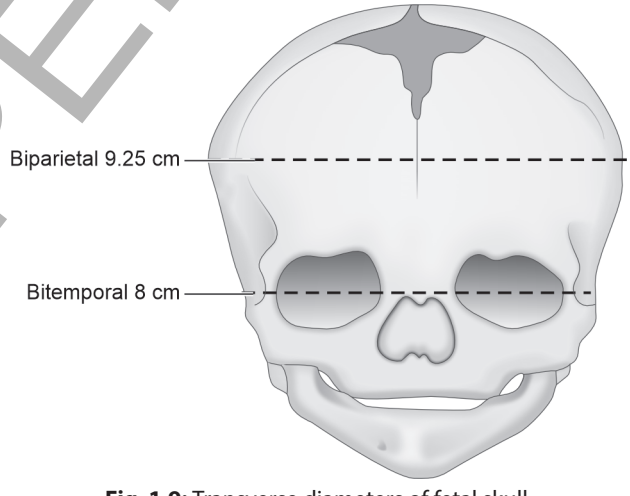

Fig. 1.9: Transverse diameters of fetal skull.

JAYPEE BROTHERS

for detailed information on nursing books, visit our website www.ejaypee.com, for detailed information on nursing books, visit our website www.ejaypee.com, for detailed information on nursing b

The Clinical Case Record Book for Midwifery

The Clinical Case Record Book for Midwifery (As per the GNM Nursing Curriculum) is designed for nursing and midwifery students. The book covers the basic and advanced conditions related to obstetrics and also structured and comprehensive proforma are provided to improve the midwifery skills of students in clinicals.

Salient Features

- Comprehensive presentation of topics is provided in simple language.
- Theoretical information is given as per the MoHFW guidelines.
- Filled samples of proforma are given to guide the students.
- For preparation of viva voce and practice questions are given at the end of this case book.

Manju Chhugani PhD is Founder Dean of School of Nursing Sciences and Allied Health, Jamia Hamdard, Hamdard Nagar, New Delhi, and former Head of the Department of Paramedical Sciences and Department of Obstetrics and Gynecological Nursing. She is a prodigious leader, trainer, researcher, and influential academician with more than 33 years of extensive experience in the area of maternal and child health and university teaching. She is a certified assessor of the National Assessment and Accreditation Council (NAAC). She has been an expert, resource person, chairperson, and organizer and participated in more than 400 workshops/seminars and conferences. She is the first Indian to receive the prestigious Marie Goubran Agent of Change Award by ICM for the year 2020 and received an award in research by TNAI.

Renu Kharb MSc Nursing is currently Faculty at School of Nursing Sciences and Allied Health, Jamia Hamdard, Hamdard Nagar, New Delhi. She was a rank holder during her BSc Nursing program and has been awarded with University Gold Medal for securing first position in MSc Nursing (2016) at MM University, Ambala, Punjab.

Preysi Chauhan MSc Nursing is currently Faculty at School of Nursing Sciences and Allied Health, Jamia Hamdard, Hamdard Nagar, New Delhi. She has received an award from the Hon. Prime Minister Sh. Narendra Modi for the best BSc (Hons.) Nursing Student in the subjects of Anatomy and Physiology, 2014, at AIIMS, New Delhi. She was the first rank holder of AIIMS Patna recruitment for the post of tutor, screening examination (2018), and BSc Nursing entrance examination conducted by Guru Gobind Singh Indraprastha University (GGSIPU) (2008).

Scan for more nursing titles...

Buy from ejaypee

JAYPEE BROTHERS

JAYPEE BROTHERS

ISBN 978-81-6799-982-5

9 788167 999825