ee.com, for detailed information on forensic medicine & toxicology books, visit our website www.ejaypee.com, for detailed information on forensic medicine & toxicology books

7th Edition

FORENSIC MEDICINE & TOXICOLOGY

FOR MEDICAL STUDENTS INCLUDING CLINICAL & PATHOLOGICAL ASPECTS

Fully updated edition with BNS, BNSS and BSA Criminal Laws

As per the Revised Competency Based Medical Education Curriculum (NMC)



Gautam Biswas

Forewords
BD Gupta
Bharath Kumar Guntheti
Parmod Kumar Goyal

JAYPEE BROTHERS

Genuine?
Scratch, Scan & Validate

New Book Features
ConceptRx
Trusted Text
Limitless Learning

JAYPEE

Contents

Section 1: Jurisprudence and Forensic Medicine

Chapter 1: Legal Procedure 3

- History of Forensic Medicine *3*
- Inquest *7*
- Police Inquest *7*
- Magistrate Inquest *8*
- Courts of Law *9*
- Subpoena/Summons *12*
- Conduct Money *12*
- Medical Evidence *12*
- Types of Witness *15*
- Recording of Evidence *16*
- Conduct and Duties of a Doctor in the Witness Box *18*

Chapter 2: Medical Practitioner—Duties and Malpractices 20

- National Medical Commission *20*
- Powers and Functions *21*
- State Medical Council *22*
- Duties of a Doctor *23*
- Professional Secrecy *26*
- Privileged Communication *27*
- Medical Malpractice *28*
- Professional Misconduct (Infamous Conduct) *29*
- Erasure of Name *30*
- Types of Physician–Patient Relationship *31*
- Professional Negligence *31*
- Safeguards Against Litigation *34*
- Defenses Against Negligence *35*
- Doctrine of Res IPSA Loquitur *35*
- Doctrine of Common Knowledge *36*
- Calculated Risk Doctrine *36*
- Contributory Negligence *36*
- Corporate Negligence *37*
- Products Liability *37*
- Medical Maloccurrence *38*
- Therapeutic Misadventure/Hazard *38*
- Vicarious Liability/Respondeat Superior *39*
- Consent *39*

Chapter 3 Ethical Aspects of Medical Practice 45

- Medical Ethics *45*
- Do Not Resuscitate *47*
- Euthanasia (Mercy Killing) *47*
- Stem Cell Research *49*
- Human Experimentation *50*
- Malingering (Shamming) *52*
- Oath *52*
- Declaration of Geneva *53*

Chapter 4: Acts Related to Medical Practice 56

- The Transplantation of Human Organs and Tissues Act, 1994 *56*
- The Consumer Protection Act, 2019 *59*
- Medical Indemnity Insurance *60*
- The Protection of Children from Sexual Offenses (POCSO) ACT, 2012 *60*
- The Transgender Persons (Protection of Rights) Act, 2019 *62*
- The Assisted Reproductive Technology (Regulation) Act, 2021 *62*
- The Medical Termination of Pregnancy (Amendment) Act, 2021 *64*
- The Preconception and Prenatal Diagnostic Techniques Act, 1994 *66*
- The Protection of Women from Domestic Violence Act, 2005 *67*
- The Mental Healthcare Act, 2017 *68*

Chapter 5: Identification I 73

- Corpus Delicti *73*
- Race (Ancestry) and Religion *74*
- Sex *75*
- Disorders of Sexual Development *78*
- Sex from Skeletal Remains *80*
- Age *84*
- Age from Ossification of Bones *89*
- Bone Age Estimation *90*
- Age Determination in Adults Over 25 years *91*
- Medico-legal Importance of Age *94*
- Stature *94*
- Scars *96*
- Tattoo Marks *97*

Chapter 6: Identification II 100

- Anthropometry (Bertillon System) *100*
- Dactylography *100*
- Poroscopy *104*
- Cheiloscopy (Lip Prints) *104*
- Hair *105*
- Medico-legal Questions *105*
- Superimposition *109*
- Forensic Odontology *109*
- Miscellaneous Methods of Identification *112*

JAYPEE BROTHERS

Chapter 7: Medico-legal Autopsy 114
- Purpose/Objectives of Autopsy *115*
- Morgue Set Up and Minimum Requirements *115*
- Procedure for Medico-legal Autopsies *117*
- Instruments for Autopsy Examination *118*
- External Examination *118*
- Internal Examination (Evisceration) *120*
- Skin Incisions *120*
- Evisceration Methods *120*
- Abdomen and Pelvis *122*
- Chest *123*
- Heart *123*
- Neck *125*
- Skull and Brain *125*
- Description of an Organ *127*
- Report *128*
- Demonstration of Pneumothorax *128*
- Demonstration of Air Embolus *128*
- Collection of Samples *129*
- Preservation of Viscera *130*
- Preservation of Samples *131*
- Samples for Laboratory Investigations *133*
- Obscure and Negative Autopsy *133*
- Digital Autopsy *134*
- Examination of Decomposed, Mutilated and Skeletonized Remains *135*
- Medico-legal Questions *136*
- Exhumation *138*

Chapter 8: Thanatology 141
- Death *141*
- Brain/Brainstem Death *142*
- Cause, Mechanism and Manner of Death *144*
- Medical Certificate of Cause of Death *146*
- Modes of Death (Proximate Causes of Death) *147*
- Anoxia *148*
- Sudden Death *148*
- Coronary Artery Atherosclerosis *149*

Chapter 9: Signs of Death 153
- Immediate Changes (Somatic Death) *153*
- Suspended Animation (Apparent Death) *154*
- Early Changes (Molecular Death) *154*
- Postmortem Staining (Livor Mortis) *155*
- Algor Mortis (Cooling of the Dead Body) *158*
- Rigor Mortis *160*
- Cadaveric Spasm (Instantaneous Rigor) *162*
- Heat Stiffening *163*
- Cold Stiffening *164*
- Putrefaction/Decomposition *165*
- Decomposition of Submerged/Buried Body *168*
- Floatation of a Dead Body on Water *169*
- Entomology *169*
- Adipocere (Saponification) *170*
- Mummification *171*
- Estimation of Time Since Death/Postmortem Interval *172*
- Preservation of Dead Bodies *174*
- Presumption of Death *175*

Chapter 10: Asphyxial Deaths 178
- Etiology of Asphyxia *178*
- Clinical Effects of Asphyxia *179*
- Hanging *179*
- Autopsy of Neck (Asphyxial Deaths) *181*
- Postmortem Findings in Hanging *182*
- Medico-legal Questions *184*
- Strangulation *185*
- Ligature Strangulation *186*
- Postmortem Examination *186*
- Medico-legal Questions *187*
- Throttling (Manual Strangulation) *189*
- Postmortem Examination *190*
- Medico-legal Questions *191*
- Hyoid Bone Fractures *191*
- Suffocation *192*
- Drowning *196*
- Postmortem Examination *198*
- Medico-legal Questions *203*
- Autoerotic Asphyxia (Sexual Asphyxia) *204*

Chapter 11: Injuries 207
- Classification of Wounds/Injuries *207*
- Abrasion *208*
- Bruise/Contusion *211*
- Lacerated Wound *215*
- Incised Wound (Cut/Slash/Slice) *217*
- Chop Wounds *220*
- Stab Wound/Puncture Wound *221*
- Defense Wounds *225*
- Fabricated/Fictitious/Forged Wounds *225*

Chapter 12: Firearm Injuries 229
- Classification of Firearms *230*
- Rifled Firearms *230*
- Smooth Bore Firearms/Shotguns *231*
- Caliber (Gauge/Bore) *232*
- Bullet *232*
- Cartridge *234*
- Gunpowders (Propellant Charge) *235*
- Mechanism of Discharge of Projectile *236*
- Wound Ballistics and Mechanism of Injury *236*
- Firearm Wounds *237*
- Characteristics of Shotgun Wounds *239*
- Characteristics of Rifled Firearms Wounds *240*
- Firearm Wounds on Skull *243*
- Exit Wounds *243*
- Peculiar Effects of Firearms *246*
- Postmortem Examination *247*
- Preservation and Marking of Exhibits *248*
- Medico-legal Questions *249*
- Detection of Gunshot Residues *252*

JAYPEE BROTHERS

Chapter 13: Regional Injuries 256
- Craniocerebral Injuries *256*
- Biomechanics of Head Injury *257*
- Soft Tissue Injury *257*
- Skull Fractures *258*
- Brain Injury *262*
- Cerebral Concussion *262*
- Diffuse Axonal Injury *263*
- Cerebral Contusion and Laceration *264*
- Coup and Contrecoup Injury *265*
- Intracranial Hematoma *267*
- Epidural/Extradural Hematoma *267*
- Subdural Hematoma *269*
- Subarachnoid Hematoma *271*
- Intracerebral Hematoma *273*
- Diffuse Injury to the Brain *276*
- Spinal Cord *277*
- Neck *278*
- Chest *279*
- Lungs *279*
- Heart *280*
- Abdomen *280*
- Kidneys *281*
- Bones and Joints *282*

Chapter 14: Thermal Injuries 286
- Cold Injury *286*
- Heat Injury *288*
- Heat Stroke/Heat Hyperpyrexia *289*
- Burns *290*
- Postmortem Examination *294*
- Medico-legal Questions *297*
- Scalds *300*
- Electrical Injuries (Electrocution) *300*
- Judicial Electrocution *304*
- Lightning Stroke *304*

Chapter 15: Transportation Injuries 307
- Pedestrian Injuries *307*
- Injuries Sustained by Vehicle Occupants *311*
- Role of Seat Belts and Air Bags *312*
- Motorcycle and Cycle Injuries *313*
- Postmortem Examination *313*
- Alcohol, Drugs and Trauma *315*
- Railway Injuries *315*

Chapter 16: Explosion Injuries and Fall from Height 317
- Explosion Injuries *317*
- Classification of Injuries *318*
- Fall from Height *320*
- Injury Patterns *321*

Chapter 17: Medico-legal Aspects of Injuries 324
- Grievous Hurt *326*
- Punishments *329*
- Causes of Death from Wounds *329*
- Medico-legal Questions *334*
- Injury Report *337*

Chapter 18: Neglect and Starvation Deaths 341
- Modes of Starvation *341*
- Pathophysiology *342*
- Signs and Symptoms *342*
- Postmortem Findings *343*
- Medico-legal Questions *343*

Chapter 19: Radiation Sickness, Anesthetic and Operative Deaths 345
- Ionizing Radiation Reactions *345*
- Anesthetic and Operative Deaths *346*
- Postmortem Examination *348*

Chapter 20: Infanticide and Child Abuse 350
- Postmortem Examination of Infants *351*
- Age of Fetus *353*
- Rule of Hasse *353*
- Demonstration of Centers of Ossification *355*
- Viability of Fetus/Infant *356*
- Live-Born/Dead-Born/Stillborn *356*
- Postmortem Findings *357*
- Signs of Dead-born Fetus *360*
- Signs of Stillborn Fetus *361*
- Infant Death *362*
- Battered Baby Syndrome *365*
- Child Abuse *367*
- Sudden Infant Death Syndrome *368*
- Munchausen Syndrome by Proxy *369*

Chapter 21: Criminal Abortion 372
- Classification of Abortion *372*
- Criminal Abortion *373*
- Complications of Criminal Abortion *375*
- Duties of a Doctor in Suspected Case of Criminal Abortion *377*
- Examination of a Woman with Alleged History of Abortion *377*
- Trauma and Abortion *378*

Chapter 22: Erectile Dysfunction and Sterility 380
- Causes of Erectile Dysfunction and Sterility in Males *380*
- Causes of Impotence and Sterility in Females *382*
- Examination of a Person in an Alleged Case of Erectile Dysfunction and Sterility *383*
- Nullity of Marriage and Divorce *385*
- Sterilization *385*
- Artificial Insemination *387*
- Surrogate Mother *389*

Chapter 23: Virginity, Pregnancy and Delivery 391
- Normal Female Genitalia *391*
- Medico-legal Aspects *393*
- Pregnancy *394*
- Presumptive Signs/Symptoms *394*
- Probable Signs of Pregnancy *395*
- Positive/Conclusive Signs of Pregnancy *397*
- Pseudocyesis (False/Phantom Pregnancy) *398*
- Superfecundation *399*
- Superfetation *399*

JAYPEE BROTHERS

- Legitimacy and Paternity 400
- Signs and Symptoms of Recent Delivery in Living 400
- Signs of Remote Delivery in Living 402
- Medico-legal Aspects of Pregnancy and Delivery 403

Chapter 24: Sexual Assault 405
- Rape 406
- Duties of a Doctor in case of a Survivor of Sexual Assault (Rape) 409
- Examination of Sexual Assault Survivor 410
- Examination Findings 414
- Specimens for Laboratory Examination 418
- Opinion 420
- Corroborative Signs of Sexual Assault 421
- Rape on Deflorate/Sexually Active Woman 422
- Rape on Children 422
- Medico-legal Questions 423
- Examination of Rape Accused 424
- Incest 425
- Adultery 426

Chapter 25: Homosexuality 428
- Sodomy 428
- Examination of Passive Partner of Sodomy 429
- Opinion 430
- Examination of Active Partner of Sodomy 431
- Legal Aspects 431
- Lesbianism/Tribadism 432
- Bestiality/Zoophilia 433
- Buccal Coitus 433

Chapter 26: Paraphilia 435
- Sadism (Algolagnia) 435
- Masochism (Passive Algolagnia) 436
- Transvestic Fetishism (Eonism) 437
- Voyeurism (Scoptophilia) 438
- Exhibitionism 438
- Fetishism 439
- Frotteurism (Toucherism) 439
- Pedophilia 439
- Masturbation (Onanism) 440
- Insertion of Foreign Objects/Fingers 440
- Indecent Assault 441

Chapter 27: Postmortem Artifacts 443
- Artifacts due to Postmortem Changes 443
- Third Party Artifacts 445
- Environmental Artifacts 447
- Miscellaneous Artifacts 447

Chapter 28: Forensic Psychiatry 449
- Delusion 449
- Hallucination 450
- Illusion 452
- Impulse 452
- Obsession–Compulsion 453
- Lucid Interval 453
- Role of Forensic Psychiatrist 454
- Psychiatric Assessment 455
- Classification of Mental, Behavioral or Neurodevelopmental Disorders (ICD-11) 456
- Neurodevelopmental Disorders 456
- Schizophrenia 456
- Catatonia 459
- Mood Disorders 459
- Anxiety or Fear-related Disorders 460
- Obsessive-compulsive or Related Disorders 461
- Stress Disorders 462
- Dissociative Disorders 463
- Feeding or Eating Disorders 463
- Bodily Distress or Bodily Experience Disorders 463
- Substance Use or Addictive Behaviors Disorders 464
- Impulse Control Disorders 464
- Disruptive Behavior or Dissocial Disorders 464
- Personality Disorders and Related Traits 464
- Factitious Disorders 465
- Neurocognitive Disorders 465
- Sleep-wake Disorders 465
- Mental Disorder and Responsibility 466

Chapter 29: Bloodstain Analysis 471
- Bloodstain Pattern Analysis 471
- Presumptive Tests for Blood 471
- Confirmatory Tests for Blood 473
- Species Identification 473
- Genetic Markers in Blood 475
- Medico-legal Application of Blood (Groups) 476
- Medico-legal Questions 477

Chapter 30: Seminal Stains and Other Biological Samples 480
- Purpose of Seminal Identification 480
- Examination of Seminal Stains 481
- Confirmatory Tests 482
- Individualization of Seminal Stains 484
- Medico-legal Questions 484
- Identification of Biological Samples and Body Fluids 484

Chapter 31: DNA Fingerprinting 487
- Restriction Fragment Length Polymorphism 487
- Polymerase Chain Reaction 489
- Specimen Selection and Preservation 490
- Uses of DNA Fingerprinting 492
- Limitations of DNA Testing 492

Chapter 32: Torture and Custodial Deaths 494
- Types of Torture 494
- Medical Practitioner and Torture 496
- Custodial Deaths 497

Chapter 33: Medico-legal Aspects of HIV 500
- HIV Testing Policy 500
- Healthcare Workers and HIV Infection 501
- Partner Notification (Contact Tracing/Partner Counseling) 501
- Clinical Trials and HIV 502
- Blood Donation and HIV 502

JAYPEE BROTHERS

Chapter 34: Newer Techniques and Recent Advances 504
- Polygraph *504*
- Brain Fingerprinting (Brain Mapping) *505*
- Narco-Analysis *505*
- Facial Reconstruction *506*
- Crime Scene Investigation *507*

Section 2: Toxicology

Chapter 35: General Toxicology 513
- Medico-legal Aspects of Poisons *514*
- Classification of Poisons *515*
- Toxicokinetics and Toxicodynamics of Poisons *516*
- Poisoning in the Living *516*
- Duties of a Doctor in a Case of Suspected Poisoning *517*
- Medical Records *518*
- Cyber Forensics and Privacy of Medical Documents *518*
- Suicide/Homicide/Accident *519*
- Management of Poisoning Cases *519*
- Removal of Unabsorbed Poison *521*
- Administration of Antidotes *523*
- Elimination of Poison by Excretion *524*
- Diagnosis of Poisoning in Dead *526*
- Samples Preserved for Toxicological Analysis *527*
- Failure to Detect Poison *528*
- Chromatography *529*

Chapter 36: Corrosive Poisons 531
- Mineral/Inorganic Acids *531*
- Vitriolage (Vitriol Throwing) *533*
- Chemical Colitis *534*
- Oxalic Acid (Acid of Sugar) *534*
- Carbolic Acid (Phenol) *535*
- Strong Alkalis (Caustic Alkalis) *537*

Chapter 37: Inorganic Metallic Irritants—Arsenic 539
- Signs and Symptoms (Acute Poisoning) *540*
- Treatment *541*
- Postmortem Findings *541*
- Chronic Arsenic Poisoning *542*
- Postmortem Findings *543*
- Postmortem Imbibition of Arsenic *543*

Chapter 38: Inorganic Metallic Irritants—Mercury 545
- Signs and Symptoms (Acute Poisoning) *546*
- Treatment *547*
- Postmortem Findings *547*
- Chronic Mercury Poisoning (Hydrargyrism) *547*
- Specific Features/Diseases *548*

Chapter 39: Inorganic Metallic Irritants—Lead 550
- Chronic Lead Poisoning (Plumbism/Saturnism) *551*
- Signs and Symptoms *552*
- Treatment *554*
- Postmortem Findings *555*

Chapter 40: Inorganic Metallic Irritants—Copper 557
- Signs and Symptoms *558*
- Treatment *558*
- Postmortem Findings *558*
- Chronic Copper Poisoning *559*

Chapter 41: Inorganic Metallic Irritants—Thallium 561
- Signs and Symptoms *561*
- Treatment *562*
- Postmortem Findings *562*

Chapter 42 Other Inorganic Metallic Irritants 564
- Cadmium *564*
- Barium *565*
- Zinc *566*
- Metal Fume Fever *567*

Chapter 43: Non-metallic Irritants 569
- Phosphorus *569*
- Signs and Symptoms *569*
- Postmortem Findings *571*
- Chronic Phosphorus Poisoning *572*
- Iodine Poisoning *572*

Chapter 44: Organic Irritants—Plant 574
- Ricinus Communis (Castor) *574*
- Croton Tiglium (Jamalgota) *575*
- Abrus Precatorius (Rati/Rosary Pea/Gunchi/Jequirity) *576*
- Suis *577*
- Semecarpus Anacardium *577*
- Capsicum Annuum *578*
- Calotropis (Rubber Bush) *579*

Chapter 45: Organic Irritants—Animal 581
- Snakes *581*
- Signs and Symptoms of Ophitoxemia *584*
- Management *587*
- Postmortem Findings *590*
- Scorpions *591*
- Bees and Wasps *592*
- Spiders *592*

Chapter 46: Somniferous Poisons (Narcotic Poisons) 595
- Opium *595*
- Signs and Symptoms *596*
- Treatment *597*
- Postmortem Findings *598*
- Chronic Morphine Poisoning (Morphinism) *600*

Chapter 47: Inebriants—Alcohol 602
- Signs and Symptoms (Acute Poisoning) *604*
- Treatment *605*
- Drunkenness *607*
- Laboratory Diagnosis *609*
- Collection of Samples in the Living *610*
- Alcohol Use Disorder *611*
- Delirium Tremens *612*
- Wernicke's Encephalopathy *612*
- Korsakoff's Psychosis *613*
- Methyl Alcohol (Methanol) *613*
- Local Made Liquor (Country Liquors) *615*
- Ethylene Glycol *615*

JAYPEE BROTHERS

Chapter 48: Sedative-hypnotic—Barbiturates 618
- Signs and Symptoms 618
- Treatment 619
- Postmortem Findings 620
- Barbiturate Automatism (Self-poisoning) 620

Chapter 49: Deliriants—Dhatura/Datura 622
- Dhatura/Datura 622
- Signs and Symptoms 623
- Treatment 624
- Postmortem Findings 625

Chapter 50: Deliriants—Cannabis 627
- Signs and Symptoms 628
- Treatment 629
- Run-amok 629

Chapter 51: Deliriants—Cocaine 631
- Signs and Symptoms 632
- Treatment 632

Chapter 52: Spinal Poisons 635
- Strychnos nux-vomica 635
- Signs and Symptoms 636
- Treatment 637

Chapter 53: Cardiac Poisons 639
- Aconite 639
- Nicotiana Tabacum (Tobacco) 641
- Digitalis Purpurea (Foxglove) 642
- Oleander (Kaner) 643
- Nerium Odorum 643
- Cascabela Thevetia 644
- Cerbera odollam 644

Chapter 54: Hydrocyanic Acid 647
- Signs and Symptoms 648
- Treatment 648
- Postmortem Findings 649
- Judicial Execution 650

Chapter 55: Asphyxiants 652
- Carbon Monoxide 652
- Treatment 653
- Postmortem Findings 654
- Tear Gases 655
- Methyl Isocyanate 656

Chapter 56: Agricultural Poisons 658
- Organophosphorus Compounds 658
- Signs and Symptoms 659
- Treatment 661
- Postmortem Findings 663
- Endrin 664
- Paraquat 665
- Pyrethrins and Pyrethroids 666

Chapter 57: Alphos (Aluminum Phosphide) 669
- Signs and Symptoms 670
- Treatment 670
- Postmortem Findings 672

Chapter 58: Medicinal Poisons 674
- Paracetamol (Acetaminophen) 674
- Iron 675
- Phenytoin 676
- Lithium 676
- Antipsychotic Drugs (Tranquilizers) 677
- Tricyclic Antidepressants 678
- Benzodiazepines (BZDs) 678
- Acetylsalicylic Acid (Aspirin) 679
- Antibiotics 680
- Muscle Relaxants 680
- Local Anesthetics 681
- Propofol 681
- Insulin 682

Chapter 59: Drug Dependence and Date Rape Drugs 684
- Patterns of Drug Use Disorders 685
- Psychoactive Substances 685
- Hallucinogens 688
- Date Rape Drugs 690
- Complications of Drug Abuse 690
- Postmortem Findings 691

Chapter 60: Supplement 693
- Medical Jurisprudence 693
- Medical Acts 694
- The Workmen's Compensation Act, 1923 698
- Employees' State Insurance Act, 1948 698
- Decompression Sickness 699
- Altitude Illness 699
- Toxicology 700
- Boric acid (Hydrogen Borate/Orthoboric Acid) 700
- Hydrofluoric Acid 701
- Methemoglobinemia Inducing Agents 702
- Ergot 702
- Cantharides (Spanish Fly) 703
- Isopropyl Alcohol 704
- Peripheral Nerve Poisons 704
- Cardiac Poisons 706
- Carbon Dioxide 707
- Hydrogen Sulfide 708
- Biological Weapons 710
- Naphthalene 711
- Kerosene Oil Poisoning 712
- Food Poisoning 714
- Poisonous Foods 716

Answer Key ***719***

Index ***721***

JAYPEE BROTHERS

ConceptRx
Trusted Text | Limitless Learning

Age, sex, stature and identity clues getting mixed up? Smart Notes organize the essentials for fast forensic recall. Scan now.

Smart Notes
SCAN NOW
Ask Dr Wise • Mind Maps • MCQs • PYQs

CHAPTER

Identification I

Learning Objectives

Must know

1. Identification, types, medico-legal importance
2. Corpus delicti
3. Cephalic index
4. Nuclear sexing, Barr body, Davidson body
5. Disorders of sexual development with examples
6. Klinefelter and Turner syndrome
7. Eruption of temporary and permanent teeth
8. Gustafson's method
9. Spacing of jaw, superadded and successional teeth, period of mixed dentition
10. Age estimation: Ossification of long bones
11. Fusion of skull sutures
12. Estimation of stature
13. Tattoo marks, scars, medico-legal importance
14. Medico-legal importance of age
15. Male and female—skull, pelvis and mandible (Diff.)
16. Age changes in mandible (Diff.)

Desirable to know

1. Stack, Boyde and Miles' method of age estimation
2. Age changes in symphysis pubis
3. Sexual development in adolescents

Definitions

❖ **Identification:** *Determination of the individuality of a person* based on certain physical, biological, and/or circumstantial characteristics.

❖ **Identity:** Set of characteristics that individualize a person.

Identification involves confirming identity through features such as age, sex, stature, ancestry, scars, deformities, fingerprints, dental records, DNA, or personal belongings.

It can be:

i. **Complete (absolute):** Absolute fixation of the individuality of a person.

ii. **Partial (incomplete):** Ascertainment of only some facts (e.g., ancestry, sex, age or stature) about the identity, while the others remain unknown.

Identification is necessary in:

1. *Living persons* pertaining to:

Criminal cases	*Civil cases*
◆ Persons accused of assault, murder or rape	◆ Marriage
◆ Interchange of newborn babies in hospitals	◆ Passport/license
◆ Impersonation	◆ Inheritance
◆ Absconding soldiers and criminals	◆ Insurance claim
	◆ Missing persons
	◆ Disputed sex

2. *Dead people:*
   i. In cases of fire, explosion and accidents.
   ii. When an unknown dead body is found on the road, fields, railway compartment or water.
   iii. In cases of decomposed body.
   iv. In cases of mutilated body.
   v. Skeleton.

Before identifying the patient in the court, the doctor should verify the identification marks noted by him.

FM4.1

Define and describe corpus delicti.

CORPUS DELICTI

Corpus delicti ('body of crime') refers to the principle that it must be proven that a crime has actually occurred before a person can be convicted of committing the crime. The prosecution must show a specific injury or loss occurred, and that injury or loss resulted from criminal activity. In a charge of homicide, it includes:

i. Positive identification of the dead body (victim).
ii. Proof of its death by criminal act of accused.

❖ The term includes body of the victim, bullet or clothing showing marks of the weapon, spilled blood or photographs showing fatal injuries.

JAYPEE BROTHERS

- The main part of corpus delicti is the establishment of identity of the body and infliction of violence in a particular way, at a particular time and place by the person or persons charged with crime and none other.
- The identification of a dead body and proof of corpus delicti is essential before a sentence is passed in murder trials, as false or coerced confessions, unclaimed, decomposed bodies or portions of a dead body (such as a forearm or a leg) or bones are sometimes produced to support a false charge.
- Courts do not allow a conviction based only on a suspect's out of court confession. The state must find separate, outside evidence to show the crime is real.

Medico-legal significance: This stops false confession or police coercion from putting innocent people in jail.

Identification Data

In living and dead both

1. Race (ancestry) and religion
2. Sex
3. Age
4. Teeth
5. General development and stature
6. Anthropometric measurements
7. Fingerprints, lip prints and footprints
8. External peculiarities, like scar or tattoo
9. Hair, blood, DNA
10. Personal effects: Clothes, pocket contents

In living only

1. Handwriting
2. Speech and voice
3. Gait, manner and habit
4. Memory and education

- *Sex, age, ancestry and stature are primary characteristics of identification* because they are fundamental biological attributes (remain unaltered even after death) that can be reliably determined even from incomplete remains and significantly reduce the range of possible identities.
- Method of identification using biometric features includes fingerprints, hand geometry, face, voice, iris or retina scan, etc.
- Biochemical method of identification can be DNA analysis, bomb curve analysis, stable isotope analysis.

FM4.1

Define and describe establishment of identity of living persons including race, religion, complexion, sex.

RACE (ANCESTRY) AND RELIGION

Race: Biological grouping within the human population classified according to genetically transmitted differences.

Important in cases of mass disasters, e.g., in case of railway accidents or air crashes, when persons of different ancestries are traveling together.

It is determined by:

i. **Clothing:** Traditional Indian dress is different from Western dress.
ii. **Complexion:** Skin is black in Negroes, brown in Indians and fair in Europeans (Caucasian).
iii. **Eye:** Indians have dark or brown iris, while Negroes have dark brown, and Europeans have blue or gray iris.
iv. **Hair:** Ethnic variations are discussed in Chapter 6. Indians have black, long and fine hair, which is rounder and thicker than Caucasians or Negroes.
v. **Skull: Cephalic Index** (formulated by Swedish anatomist Anders Retzius) *or index of breadth or cranial index* is the percentage of breadth to length in any skull.

$$CI = \frac{\text{Maximum transverse breadth of skull}}{\text{Maximum anteroposterior length of skull}} \times 100$$

Length and breadth are measured by spreading calipers.

- It is useful anthropologically to find out racial difference (ancestry) from skull shape. Skull can be classified into three types based on cephalic index (CI)—dolichocephalic, mesaticephalic brachycephalic, **(Table 5.1)**.
- Since, the Indian skull is Caucasian with few African characters, we take the value for Europeans, i.e., 75–79.9 (mesaticephalic skull).
- CI is also useful in estimating the age of fetuses for legal and obstetrical reasons.

Difference between Europeans, Asians and African skull is given in ***Diff. 5.1****.**

Table 5.1: Different types of skull based on cephalic index **(Figs. 5.1A and B)**

Type of skull	*Cephalic index*	*Race*
Dolichocephalic (long-headed)	70–74.9	Negroid (African) (Aryans, Aborigines, Negroes)
Mesaticephalic (medium-headed)	75–79.9	Caucasoids (Europeans, Chinese, Indians)
Brachycephalic (short-headed)	80–84.9	Mongoloids (Asian) (Mongolians, Native Americans)

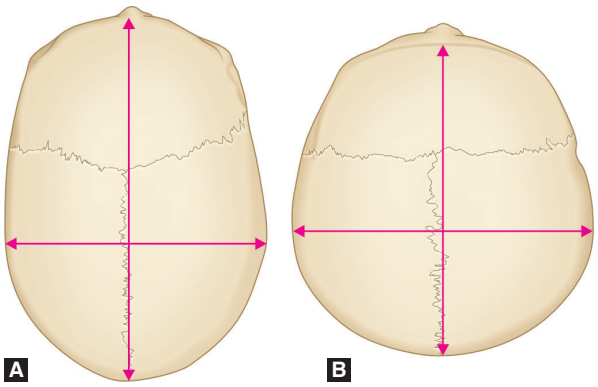

Figs. 5.1A and B: Cephalic index: (A) Dolichocephalic skull; (B) Brachycephalic skull

* Negroid, Caucasoid, and Mongoloid are obsolete racial classifications and are no longer used in modern science. They originated from outdated 18th-century racial typologies that treated humans as distinct biological races. Modern anthropology instead use ancestry, geographic origin, and population variation, which better reflect continuous human genetic diversity.

JAYPEE BROTHERS

Differentiation 5.1 European, Asian and African skull

S.No.	Feature	Europeans (Caucasians)	Asians (Mongols)	Africans (Negroes)
1.	Skull	Rounded	Square	Narrow and elongated
2.	Forehead	Raised	Inclined	Small and compressed
3.	Face	Straight lower face—orthognathism	Large and flattened, malar bones prominent	Jaw projecting—prognathism, malar bones prominent
4.	Orbits	Triangular	Small, round	Square
5.	Nasal opening	Narrow and elongated	Rounded	Broad
6.	Palate	Triangular	Rounded or horseshoe shaped	Rectangular
7.	Nasal index	<0.48	0.48–0.53	>0.53

vi. **The indices of long bones** may also help in identifying ancestry, e.g., brachial index (radiohumeral index), intermembral index, humerofemoral index and the crural index (tibiofemoral index).

IMPORTANT NOTE

- **Brachial index** = (Length of Radius/Length of Humerus) × 100
  For Indians: 76.5, Europeans: 74.5, Africans: 78.5
- **Crural index** = (Length of Tibia/Length of Femur) × 100
  For Indians: 86.5, Africans: 86.2, Europeans: 83.3
- **Humerofemoral index** = (Length of Humerus/Length of Femur) × 100
  For Indians: 71.1, Europeans: 69, Africans: 72.4
- **Intermembral index** = (Length of Humerus + Radius/Length of Femur + Tibia) × 100
  For Indians: 67.3, Europeans: >70, Africans: <70.5

- **Facial index** = (Morphological facial height/bizygomatic breadth) × 100
  Facial height is measured from nasion to gnathion, and bizygomatic breadth between the two zygions. <80 is hypereuryprosopic (very broad), 80–84.9 euryprosopic (broad), 85–89.9 mesoprosopic (medium), 90–94.9 leptoprosopic (long), and >95 hyperleptoprosopic (very long).
- **Nasal index** = (Nasal width/nasal height) × 100
  Nasal width is the maximum distance between the nostrils, while nasal height is measured from nasion to subnasale. 55–69.9 is leptorrhine (narrow), 70–84.9 mesorrhine (medium), and 85–99.9 platyrrhine (broad/flat).
  - *Europeans:* Facial index usually 85–95 (mesoprosopic to leptoprosopic); nasal index generally 55–70 (leptorrhine).
  - *Africans:* Facial index often 85–100 + (mesoprosopic to hyperleptoprosopic); nasal index generally 85–100 + (platyrrhine).
  - *Americans:* Native Americans tend to have facial indices around 85–95 and nasal indices around 70–85 (mesorrhine).

IMPORTANT NOTE

'Mongolian spots': These hyperpigmented spots or patches are most often found over the lumbosacral region of infants, and occur in people of different races (90% of Native Americans, 80% of Asians and 10% of whites) which help in racial identification.

Identify this instrument. Mention its uses.

1



Religion

- *Hindu males* are not circumcised, may have sacred thread, necklace of wooden beads, caste marks on forehead, tuft of hair on back of the head and piercing of ear lobes.
- *Muslim males* are normally circumcised, have marks of corns and callosities on lateral aspect of knees and feet due to their posture during prayer.
- *Hindu females* put on saris, vermilion on head, silver toe ornaments, tattoo marks, nose ring aperture in left nostril and few openings for ear rings along the helix.
- *Muslim females* put on trousers, no vermilion mark, nose ring in the septum, several openings on the helix for ear rings and no tattoo marks.

SEX

- **Sex:** Biological term denoting the genetic, physiologic and anatomical characteristics of an individual, based on which we can identify ourselves into 'males' and 'females'.

JAYPEE BROTHERS

- **Gender:** Sociological construct that denotes how an individual identifies according to social norms (social roles, position and behavior), based on which an individual exhibits 'masculine' or 'feminine' qualities. It is the sexual identity of an individual from birth to puberty and adulthood.*
- **Intersex:** Intermingling of sexual characters of either sex in one individual to a varying degree including the physical form, reproductive organs and sexual behavior.

In normal cases, in the living:
- **Most certain evidence of sex:** Possession of ovaries in females, and testes in males.
- **Highly probable evidence of sex:** Possession of sexual structures, e.g., developed breasts and vagina in females, and male distribution of hair and penis in males.
- **Presumptive evidence of sex:** Outward appearance of individual features, contours of face, clothes, voice and figure.

Reasons for Sex Determination

i. **Identification in living:** Sex is important in any chain of identity data and determination of the individuality of a person.
ii. **Participation in sports:** Sex segregation in sports is based on the long-term endogenous androgen exposure of men at puberty that lead to the physiological gap with women.
iii. For deciding whether an individual can *exercise certain civil rights* extended to one sex only.
iv. For deciding questions relating to legitimacy, divorce, paternity, marriage, erectile dysfunction, rape and affiliation.

At present, there are three frequent circumstances wherein determination of sex has become necessary—sports, pre-employment and sex specific crimes. Routinely at birth, identifying biological sex of an individual is based on 'external genitalia' (*phenotype sex*), i.e., whether it is penis and scrotum (in males) or vulva and vagina (in females).

Identification of 'sex' of an individual may become problematic in:

i. **Intersex:** They can be natural or acquired ('hijras' are castrated before puberty and 'zenanas' are castrated after puberty). They may have features resembling one sex and the internal gonads could be of other sex or of both sexes (true hermaphrodite).
ii. **Transvestism:** It is the practice of wearing the clothes of the opposite gender.
iii. **Transgender:** It is denoting or relating to an individual whose self-identity does not conform unambiguously to conventional notions of male or female gender. It is a state of one's gender identity or gender expression not matching one's assigned sex which may result in gender dysphoria.
iv. **Transsexuals:** Individuals who have undergone sex change surgeries or sex reassignment (male-to-female or female-to-male) **(Figs. 5.2A and B)**.**
v. **Concealed sex:** Individuals who hide their real sex for a motive by cross dressing.
vi. **Advanced decomposition and skeleton:** Sex can be determined in decomposed body by identifying uterus or prostrate, which resist putrefaction.



Figs. 5.2A and B: (A) Transexual/transgender; (B) Vaginal reconstruction

Identification of biological sex in concealed sex and transvestism can be easily done by physical examination, but difficulty arises in cases of ambiguous genitalia wherein the external genitalia are a combination of both sexes.

Sex Verification Tests

i. **Physical morphology:** External examination is done to determine the sex **(Diff. 5.2)**.
ii. **Nuclear sexing or sex chromatin or microscopic test:** Buccal epithelial cells or hair follicle cells are examined microscopically to detect the presence of *'Barr body'*.
iii. **Gonadal biopsy:** Detection of 'internal gonads and sex chromosomes' (*genotype sex*), i.e., the identification of testes and XY sex chromosomes (in males), or ovary and XX sex chromosomes (in females) is a *confirmatory method* of determining sex.
iv. **Gene-based test:** Polymerase chain reaction (PCR) is used to detect SRY gene (sex-determining region of the Y-chromosome) and/or the DYZ1 region of Y chromosome which is diagnostic. SRY gene is expressed in a small group of somatic cells of the developing gonads, and it is responsible for the expression of a

* To identify whether an individual is 'male' or 'female', the correct terminology is 'sex verification tests' and not 'gender verification tests' or 'femininity testing'.
** As per ICD-11, transsexuals and transgender are considered under **gender incongruence** which is characterized by a marked and persistent incongruence between an individual's experienced gender and the assigned sex.

JAYPEE BROTHERS

Differentiation 5.2 Determination of sex from physical/morphological feature

S.No.	Feature	Male	Female
1.	General built	Muscular, strong, stout	Less muscular, delicate, slender
2.	Scalp hair	Short, thick, coarse	Long, fine, thin
3.	Facial hair	Present	Absent
4.	Pubic hair	Thick, coarse, extends upwards with apex at umbilicus (rhomboidal)	Thin, fine, horizontal, covers mons veneris (triangular)
5.	Adam's apple	Prominent	Less prominent
6.	Shoulders	Broader than hip	Narrower than hip
7.	Waist	Not well-defined	Well-defined
8.	Trunk	Abdominal segment smaller	Abdominal segment larger
9.	Thorax	Dimensions more	Dimensions less
10.	Thighs	Cylindrical	Conical due to short femur and greater fat
11.	Breasts	Not developed	Developed after puberty
12.	Uterus and vagina	Absent	Present
13.	Penis	Present	Absent
14.	Gonads	Testes	Ovaries

male-specific cell membrane component (the H-Y antigen) and induces them to become Sertoli cells.

v. **Assay of testosterone levels** also helps in differentiating the sex of an individual. For females, they should have levels <10 nmol/L (lower than the lower limit of normal for male).

Usually, combinations of all these tests are carried out to determine the 'sex' of the individual.

Nuclear Sexing

Definition: It is a method of sexing cells which may help in determining sex in doubtful cases, decomposed and mutilated bodies and fragmentary remains **(Table 5.2)**.

Histological Examination

i. **Barr body (sex chromatin):** It is the condensed, inactive, single X-chromosome found in the nuclei of somatic cells of most females and whose presence is the basis of sex determination tests. In XO (Turner's syndrome) there will be none, and in XXX there will be two Barr bodies. It is seen during mitosis in the interphase nucleus as dark staining, small planoconvex mass of chromatin lying near the nuclear membrane **(Fig. 5.3)**. Buccal smear is usually used.

IMPORTANT NOTE

Murray Barr and *Edward Bertran* while working on stained sections of nerve cells in cats noticed a tiny, dark staining blob that was always present only in the nucleus of the female cats and never in the males. It was subsequently determined to be inactive X-chromosome, and came to be known as **Barr body**.

ii. **Davidson-Smith body:** In females, neutrophil leukocytes contain an attachment of drumstick form **(Fig. 5.4)**. A drumstick consists of a small nuclear mass of about 1.5 μ in diameter, attached to the body of the nucleus by means of a thin filament.

Table 5.2: Chromatin positivity in males and females

Test	Male (%)	Female (%)
Barr body	0–4	20–80
Davidson body	0	3
Fluorescent feulgen	0–2	50–70
Quinacrine dihydrochloride	45–80	0–4



Fig. 5.3: Barr body (arrows)



Fig. 5.4: Davidson body in neutrophil (arrow)

- Sex chromosomes (XX or XY) can be determined in the cells that are dividing, e.g., bloodstains, cartilage, bone marrow, teeth pulp and hair root.
- In decomposed bodies, sex chromatin is difficult to make out.
- Hair follicles are important for cell sexing since they resist putrefaction, and both Barr body and Y-chromosome can be demonstrated.
- **Quinacrine dihydrochloride** is used to stain the Y-chromosome, which appears as a bright fluorescent body in the nucleus, commonly referred to as the F-body.

JAYPEE BROTHERS

- **Fluorescent Feulgen reaction** using Acriflavin Schiff reagent is used for staining X-chromosome (Barr body) that is seen as bright yellow or greenish-yellow spot in nuclei under UV light.

DISORDERS OF SEXUAL DEVELOPMENT

Disorder of sexual development (DSD) is a broad term encompassing any condition where external genitalia are atypical in relation to chromosome and gonads. It results from some defect in embryonic development. Previously, Davidson divided 'intersex' into four groups:

i. Gonadal agenesis
ii. Gonadal dysgenesis
iii. True hermaphroditism
iv. Pseudohermaphroditism

- Currently, the term DSD is used to substitute the obsolete nomenclature of 'intersex', 'hermaphrodite' and 'pseudohermaphrodite', since they are based only on identifying the gonads and they fail to take into consideration whether those gonads are functioning or not.
- Moreover, the nomenclature was perceived to be pejorative or stigmatizing by some affected families.
- The karyotype is used as a prefix to define the category of DSD, replacing the earlier terminology of male or female pseudohermaphroditism (now known as XY DSD or XX DSD, respectively).

The new terms and possible diagnosis in such cases are given in **Table 5.3** and **Flowchart 5.1**. Some of these are briefly described below:

1. **Ovotesticular DSD (true hermaphroditism):** It is a rare condition; also known as double-sex or bisexual. Both ovarian and testicular tissues are present. External genitalia of both sexes exist in one individual, but sex chromatin may be either male or female pattern (46XX or 46XY or mosaics). True hermaphroditism is very similar to mixed gonadal dysgenesis. The karyotype could be 46XX/46XY or 46XX/47XXY.
2. **Sex chromosome DSD (gonadal dysgenesis):** It refers to a defect in gonad formation that is characterized by a progressive loss of primordial germ cells in the developing gonads of an embryo with consequent formation of hypoplastic and dysfunctioning gonads composed mainly of fibrous tissue—**streak gonads**. External sexual characters are present, but testes or ovaries fail to develop at puberty. Some examples are:
   i. **Klinefelter syndrome:** It is the most common sex chromosome disorder associated with male hypogonadism, most common presentation being 47XXY karyotype **(Box 5.1 and Fig. 5.5A)**.
      - Prevalence is 1:500 to 1:1000 males, chances are more with increasing maternal age.
      - These individuals are anatomically male, but fail in external genitalia examination, and have false positive Barr body testing.
   ii. **Turner syndrome (congenital ovarian hypoplasia syndrome):** First described by Henry Turner (1938), it is the most common sex chromosome disorder associated with female hypogonadism with 45XO karyotype (prevalence 1:2000 to 2500 newborns females) **(Box 5.2** and **Fig. 5.5B)**.
      - These individuals are anatomically female, pass in external genitalia examination, but have false negative Barr body testing.
   iii. **Swyer syndrome:** The individuals with pure gonadal dysplasia and a 46XY karyotype will display variable degrees of undermasculinization, dependent upon the amount of testicular dysplasia. Both XX and XY gonadal dysgenesis are due to mutation or deletion of part of the sequence of the SRY gene.

Table 5.3: Classification of disorders of sexual development (DSD)

Old name	*New name*	*Possible diagnosis*
True hermaphrodite	Ovotesticular DSD	46XX/46XY or 45X/46XY
Male pseudohermaphrodite	46XY DSD	Androgen insensitivity syndrome 5-α-reductase deficiency
Female pseudohermaphrodite	46XX DSD	Congenital adrenal hyperplasia
XX male or XX sex reversal	46XX testicular DSD	
XY sex reversal	46XY complete gonadal dysgenesis	
Gonadal dysgenesis	Sex chromosome DSD	45XO Turner 47XXY Klinefelter

Flowchart 5.1: Classification of disorders of sexual development (DSD)

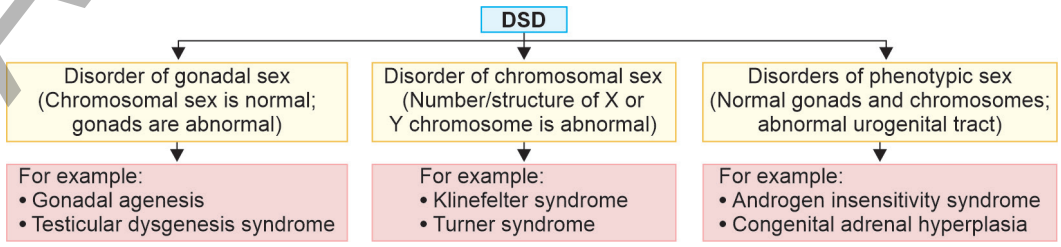

JAYPEE BROTHERS

BOX 5.1 Klinefelter syndrome

Clinical features
- Delay in onset of puberty, gynecomastia at puberty.
- Axillary and pubic hair are absent, hair on chest and chin are reduced.
- Signs of eunuchoidism, tall stature and abnormal body proportions (decreased upper to lower segment ratio).
- Firm, fibrotic, small testes and non-tender to palpation. Erectile dysfunction, loss of libido and azoospermia.
- Mental deficiency and other abnormalities, such as clinodactyly or synostosis.
- Problems with coordination and behavioral difficulties including immaturity, poor judgment, shyness, etc.

Diagnosis: Karyotyping using lymphocytes or fibroblasts or prenatally from amniocytes or chorionic villi, or by determining the presence of RNA for X-inactive-specific transcriptase (XIST) in peripheral blood leukocytes by PCR. Serum testosterone is low, and FSH, LH and estradiol are elevated.

Histological features: Testicular dysgenesis with hyalinization and fibrosis of seminiferous tubules.

BOX 5.2 Turner syndrome

Clinical features
- Short stature *(most common feature)*.
- Micrognathia, high-arched palate, webbed neck, low hairline.
- Ptosis with low-set ears, widely spaced nipples.
- Cubitus valgus (wide carrying angle), short fourth and fifth metacarpals and metatarsals, hyperconvex nails.
- Lymphedema of hands and feet, pigmented nevi and keloid formation.
- Learning disability, often involving visual-spatial skills without typical mental retardation.
- **Cardiovascular anomalies:** Coarctation of the aorta and aortic stenosis.
- **Renal abnormalities:** Hydronephrosis, horseshoe kidney, hypertension.
- Increased urinary gonadotropin excretion.
- **Sexual infantilism** due to gonadal dysgenesis with primary amenorrhea.
- High incidence of osteoporosis, type II diabetes.

Diagnosis: Evaluation for childhood short stature often leads to the diagnosis. Hypogonadism is confirmed in girls who have high serum levels of FSH and LH. A karyotype showing 45XO establishes the diagnosis.

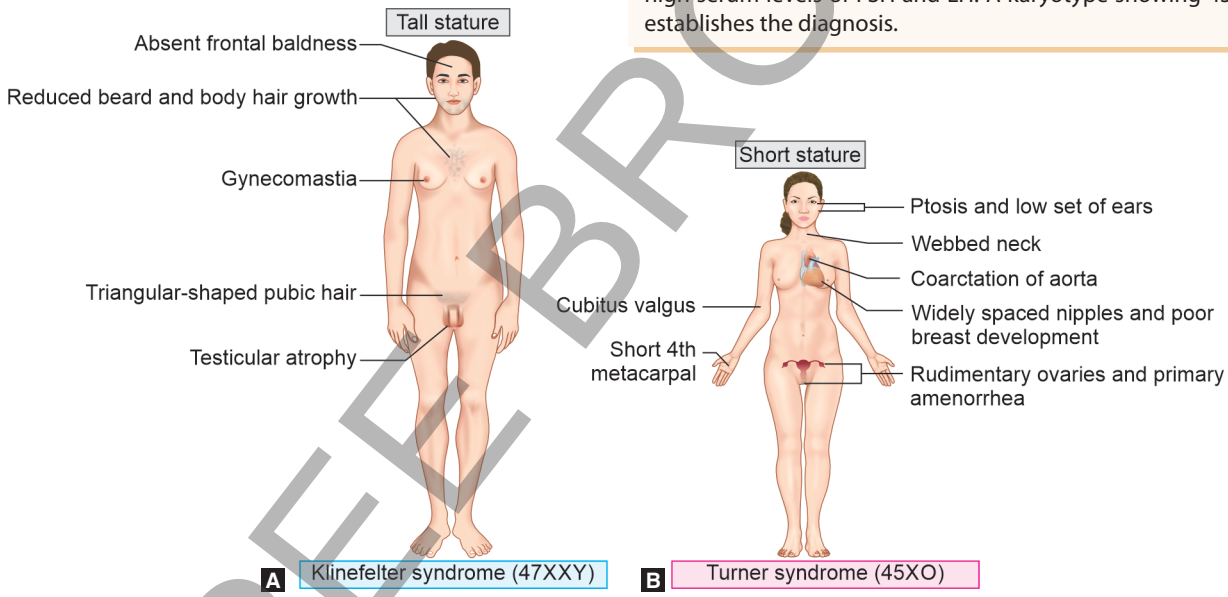

Figs. 5.5A and B: Features seen: (A) Klinefelter; (B) Turner syndrome

iv. **Mosaicism:** It is a genetic abnormality with mixture of cells with XX and XY, or X and XY sex chromosomes. Accordingly, there may be false positive or false negative Barr body tests depending on number of X chromosomes.

3. **Androgen receptor deficiency:** Androgen insensitivity is caused by receptors that are insensitive to androgens, particularly testosterone. As a result, even though they are genetically male (46XY DSD) and possess testes, but fail to develop male characteristics. These individuals are born and raised as girls and have female gender identity. They would fail the Barr body test as they have only one X chromosome. It can be:

i. **Complete androgen insensitivity syndrome** (cAIS), previously known as *testicular feminization syndrome* (most common form).
   - It is an X-linked recessive condition resulting in failure of normal masculinization of the external genitalia.
   - They have female external genitalia with normal labia, clitoris and vaginal introitus with normal size breasts but with primary amenorrhea and scanty or absent axillary and pubic hair.
   - Internally, there is a short blind-pouch vagina with absence of uterus, fallopian tubes and ovaries.

ii. **Incomplete androgen insensitivity:** The phenotype may range from mildly virilized female external

JAYPEE BROTHERS

genitalia (clitoromegaly without other external anomalies) to mildly undervirilized male external genitalia (hypospadias and/or diminished penile size) with gynecomastia. They tend to be tall.

In both cases, affected individuals have normal testes with normal production of testosterone and normal conversion to dihydrotestosterone (DHT), which differentiates this condition from 5-α reductase deficiency.

4. **5-a reductase deficiency (5-ARD):** This is an autosomal recessive sex-limited condition resulting in the inability to convert testosterone to DHT. Since, DHT is required for the normal masculinization of the external genitalia in utero, genetic males with 5-ARD deficiency are born with ambiguous genitalia.
   - The individual presents with a clitoral-like phallus, markedly bifid scrotum, pseudovaginal blind-ending introitus with perineoscrotal hypospadias and a rudimentary prostate.
   - Uterus and fallopian tubes are absent.
   - Testes are intact and are usually found in the inguinal canal or scrotum or occasionally in the abdomen.
   - At puberty, musculature, body and facial hair develop owing to normal levels of testosterone.
   - These individuals fail in external examination of genitals and fail in Barr body testing.
5. **Congenital adrenal hyperplasia (CAH):** It is a condition wherein adrenal glands produce excessive amounts of testosterone in females.
   - These individuals develop secondary male characteristics but are genetically female (46XX, DSD), lacking testes and male reproductive organs (masculinized females).
   - Among the various forms of CAH, the 21-hydroxylase deficiency resulting from mutations or deletions of CYP21A is most common, but sexual ambiguity can also be seen in defects in 17-hydroxylase, 3β-hydroxysteroid dehydrogenase, 17-ketosteroid reductase and 11β-hydroxylase.
   - Phenotypically female at birth, but do not develop breasts or menstruate in adolescence; they may present with hypertension.
   - Genital anomalies range from complete fusion of the labioscrotal folds and a phallic urethra to clitoromegaly, partial fusion of the labioscrotal folds, or both. These individuals fail in external examination of genitals but would have positive Barr body testing.

The Supreme Court has directed that all documents (including voter/Aadhar card) should have a third category marked '*transgender or third gender*'. It would only apply to transgender people but not to gays, lesbians or bisexuals.

IMPORTANT NOTE

- Men with Klinefelter syndrome are at a higher risk of autoimmune diseases, diabetes mellitus, leg ulcers, osteopenia and osteoporosis, tumors (breast and germ cells), gonadotroph adenoma and gonadotroph hyperplasia liver adenoma, systemic lupus erythematosus (SLE), rheumatoid arthritis and Sjögren syndrome.
- **Hypergonadotropic hypogonadism** (defective development of testes or ovaries and associated with excess pituitary gonadotropin secretion) is seen in Klinefelter syndrome, Noonan syndrome, viral orchitis (mumps), cytotoxic drugs, testicular syndrome or androgen insensitivity syndrome and testicular irradiation. In women with hypergonadotropic hypogonadism, the most common cause is Turner syndrome.
- Cardiovascular disease is the most common cause of death in adult women with Turner syndrome. Most common heart defects are bicuspid aortic valve (30% of children), coarctation of the aorta (5–10%) and aortic dissection. Other anomalies seen are hypoplasic left-heart syndrome, partial anomalous pulmonary venous drainage and atrial septal defects.

A 15-year-old female patient presented with complaint of primary amenorrhea. Clinically, she was short with prominent epicanthal folds, low hairline, mutliple facial nevi and a small fourth finger of both hands. Previous images of USG pelvis revealed a steaky uterus with non-visualized ovaries. What is your diagnosis?

2

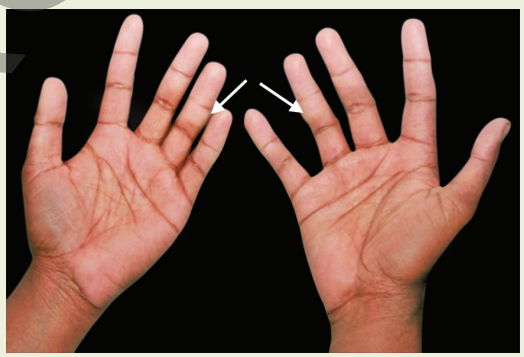

SEX FROM SKELETAL REMAINS

- Recognizable sex differences appear after puberty *except* in the pelvis. In pelvis, sex features are independent of each other, and one may even contradict the other in same pelvis.
- Among the long bones, *femur is most useful for sex determination* [larger and higher neck-shaft angle (collo-diaphyseal angle) in males, femur head diameter (males >45 mm; females <41 mm) , oblique length (447-459 mm in males; females 409-426 mm), and bicondylar width (males >78 mm; females <72 mm)].
- The sex of long bones can be determined on the basis of medullary index from tibia, humerus, ulna and radius. Sternum is least useful.

The accuracy in sexing from adult skeletal remains is given in **Table 5.4** (as reported by Wilton M Krogman).

Traits diagnostic of sex from skeleton are given in ***Diff. 5.3 to 5.6*** *and* ***Table 5.5.***

Summary of various indices is given in ***Table 5.6.***

JAYPEE BROTHERS

Table 5.4: Accuracy of sexing based on skeletal remains

Skeletal remains	*Accuracy in sexing (%)*
Entire skeleton	100
Skull + pelvis	98
Pelvis alone (best single bone)	95
Skull alone	92
Long bones	80–85
Long bones + pelvis	98

IMPORTANT NOTE

- The **preauricular sulcus** is characteristic of the *female pelvis*. The pelvic portion of the anterior sacroiliac ligament is attached to it. Its prominence results from obstetrical trauma during the course of delivery (wider pelvic dimensions due to pregnancy and parturition) which allows for differentiation between nulliparous women and males vs females who have given birth.
- **Ashley's rule:** It is used to know the *sex of the sternum* for Europeans. Also known as '149 rule'—male sternum is >149 mm and female sternum is <149.

Differentiation 5.3 Male and female skull **(Fig. 5.6)**

S.No.	*Feature*	*Male skull*	*Female skull*
1.	General appearance	Larger, heavier, rugged, marked muscular ridges	Smaller, lighter, walls thinner, smoother
2.	Cranial capacity	More capacious (1450–1550 cc)	Less capacious (1300–1350 cc)
3.	**Forehead**	Receding, irregular, rough, less rounded	Vertical, round, full, infantile, smooth
4.	Glabella	Prominent	Less prominent
5.	Supraorbital/supraciliary margin	Thick and rounded	Sharp
6.	**Supraorbital ridge**	Pronounced, 'loaf shaped' ridge	Smooth, little or no projection
7.	**Frontonasal junction (Nasion)**	Distinct angulation	Smoothly curved
8.	Orbits	Square, small	Rounded, large
9.	**Mastoid process**	Large, round, blunt	Small, smooth, pointed
10.	**Nuchal crest**	Well-defined ledge or hook of bone (rugged)	Absent or slight (smooth)
11.	Frontal and parietal eminence	Less prominent	Prominent
12.	Zygomatic arch	Prominent	Not prominent
13.	Occipital area (muscle markings and protuberance)	Prominent	Not prominent
14.	Digastric groove	Deep	Shallow
15.	Condylar facet	Long, narrow	Short, broad
16.	**Palate**	Large, U-shaped, broad	Small, parabolic
17.	Foramen magnum	Relatively large, long	Small, round
18.	Mental eminence	Large projection	Little or no projection
19.	Nasal aperture	High, thin sharp margins	Lower, wider, rounded margins
20.	Suprameatal crest	Present (extends)	Absent (no extension)

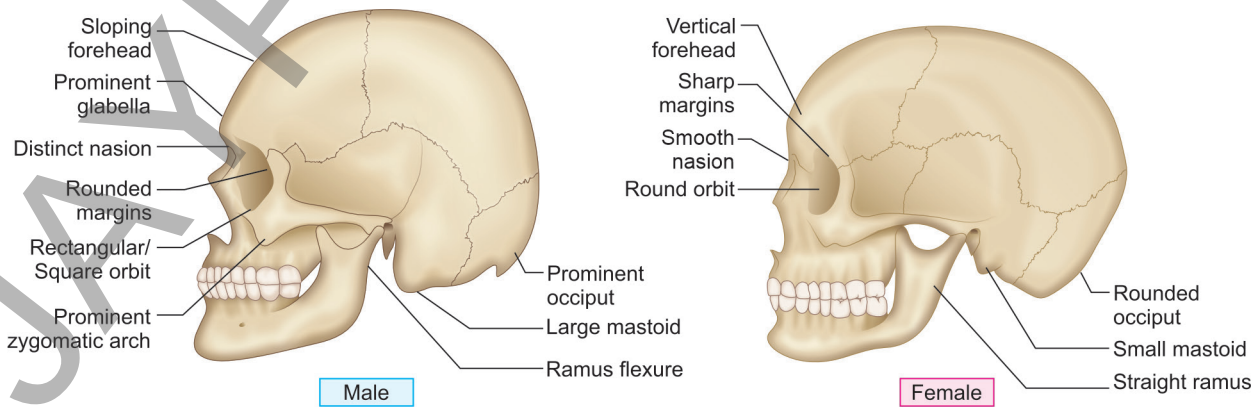

Fig. 5.6: Male and female skull

JAYPEE BROTHERS

Differentiation 5.4 Male and female mandible **(Fig. 5.7)**

S.No.	Feature	Male mandible	Female mandible
1.	General appearance	Larger, thicker	Smaller, thinner
2.	**Chin** (symphysis menti)	Square or U-shaped	Rounded
3.	**Angle of body with ramus** (gonial angle)	Less obtuse (<125°), prominent	More obtuse (>125°), not prominent
4.	**Ramus flexure**	Rearward angulation of the posterior border of ramus	Straight ramus
5.	Angle of mandible	Everted	Inverted
6.	Body height at symphysis	Greater	Smaller
7.	Ascending ramus	Greater breadth	Smaller breadth
8.	Muscular markings	Prominent	Not prominent

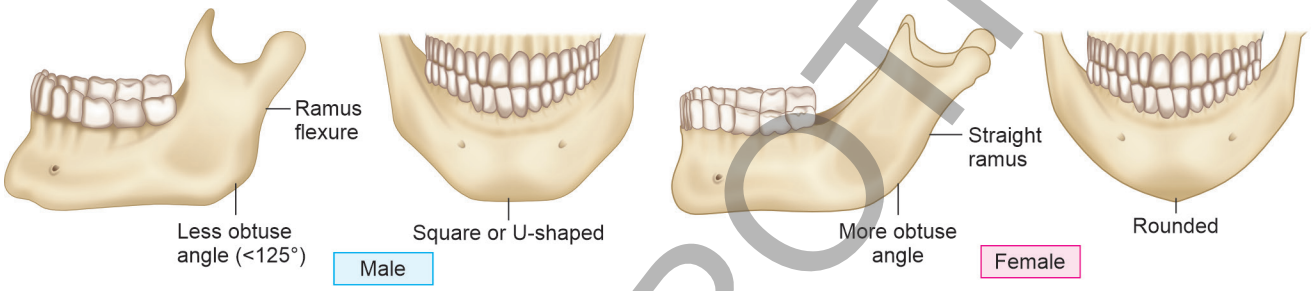

Fig. 5.7: Male and female mandible

Differentiation 5.5 Male and female pelvis **(Figs. 5.8 and 5.9)**

S.No.	Feature	Male pelvis	Female pelvis
1.	General appearance	Massive, rougher, prominent muscular markings	Less massive, slender, smoother, muscular markings not prominent
2.	**Shape**	Deep funnel with heart shaped inlet	Flat bowl shaped with elliptical/circular inlet
3.	**Preauricular sulcus** (attachment of anterior sacroiliac ligament)	Not frequent, narrow, shallow	More frequent, broad, deep
4.	**Subpubic angle**	V-shaped, sharp angle, 70–75°	U-shaped, rounded, broader angle, 90–100°
5.	**Greater sciatic notch (Fig. 5.11)**	Narrow, deep, small	Broad, shallow, large
6.	Ventral arc	Absent	Present
7.	Subpubic contour	Straight	Concave
8.	Medial aspect of ischiopubic ramus	Broad and flat	Sharp, ridged
9.	Pelvic cavity	Conical, funnel shaped	Broad, round
10.	Pelvic outlet	Smaller	Larger
11.	Body of pubis **(Fig. 5.10)**	Narrow, triangular	Broad, rectangular, pits on posterior surface, if borne children*
12.	Ischial tuberosity	Inverted	Everted
13.	Iliopectineal line	Well-marked, rough	Rounded, smooth
14.	Obturator foramen **(Fig. 5.10)**	Large, oval, base upwards	Small, triangular, apex forwards
15.	Acetabulum	Large, 52 mm diameter	Small, 46 mm diameter
16.	Ilium	High and vertical	Low and flaring
17.	Auricular surface **(Fig. 5.11)**	Raised	Flat

* Three features to determine whether parturition occurred: (i) dorsal pitting, (ii) scarring of the preauricular groove, (iii) scarring of the groove for the interosseous ligament (interosseous groove).

JAYPEE BROTHERS

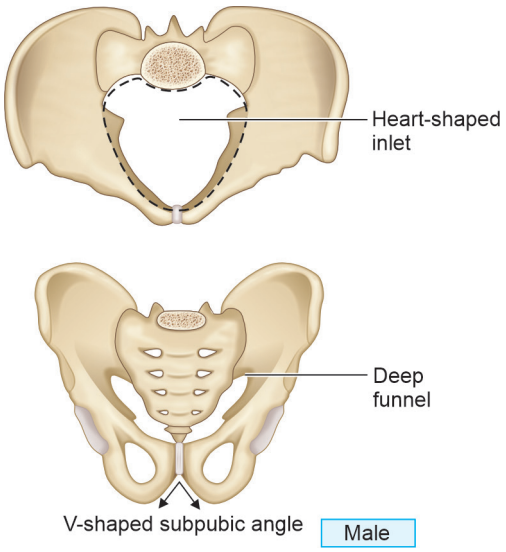

Fig. 5.8: Male pelvis

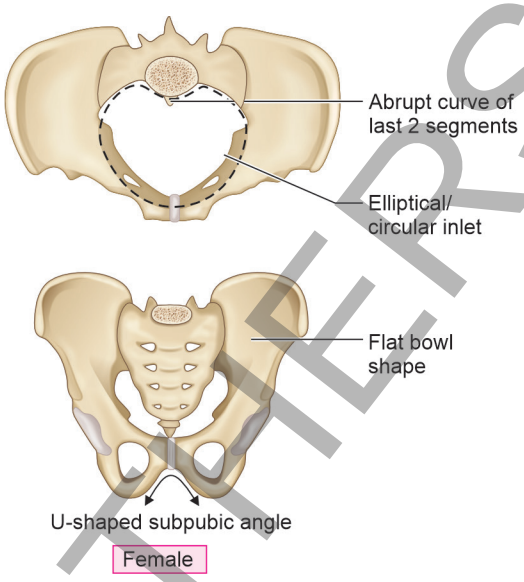

Fig. 5.9: Female pelvis

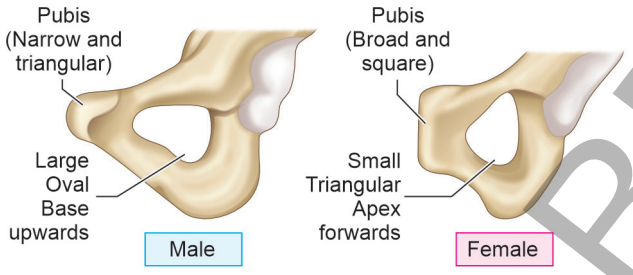

Fig. 5.10: Pelvis: Obturator foramen

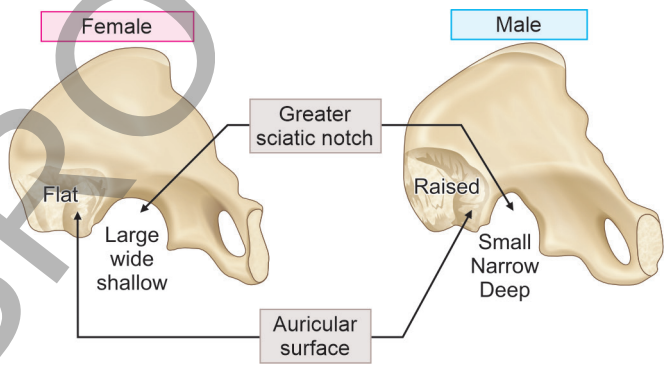

Fig. 5.11: Pelvis: Greater sciatic notch and auricular surface

Differentiation 5.6 Male and female sacrum **(Fig. 5.12)**

S.No.	*Feature*	*Male sacrum*	*Female sacrum*
1.	General appearance	Long, heavier, rough, narrow	Short, lighter, smooth, broad
2.	Breadth of body of 1st sacral vertebra	More than breadth of one side ala	Less than breadth of one side ala
3.	Inner curvature	Uniformly curved anteriorly	Abruptly curved at the last two segments
4.	Sacroiliac articulation	Large, extends up to 3rd segment	Small, extends up to 2–2½ segment
5.	Sacroiliac joint surface	Large, less sharply angulated	L-shaped, elevated anteriorly

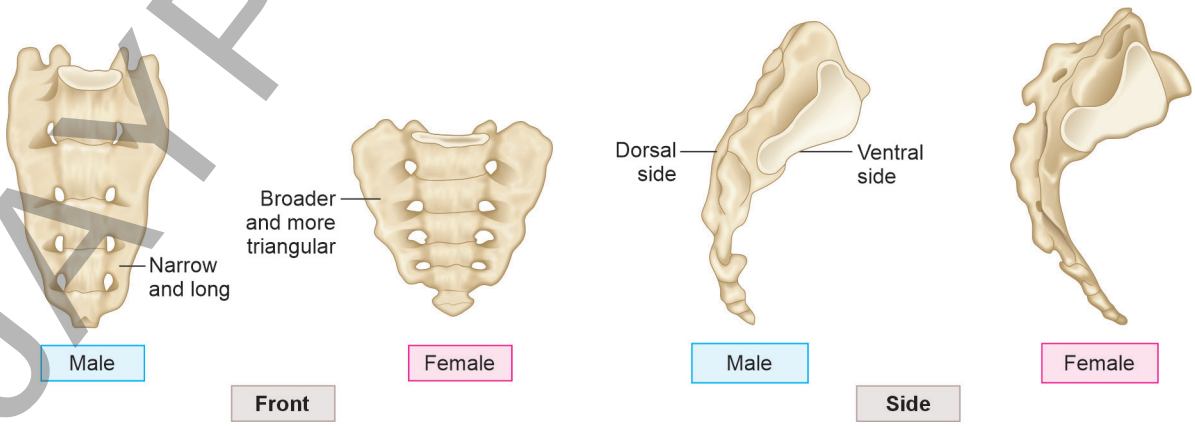

Fig. 5.12: Sacrum

JAYPEE BROTHERS

Table 5.5: Diagnostic indexes for determination of sex

S.No.	Index	Formula	Male	Female
1.	Washburn/Ischiopubic index *(Best index)*	$\frac{\text{Length of pubis}}{\text{Length of ischium}} \times 100$	73–94 (average 75)	91–115 (average 100)
2.	Sciatic notch index	$\frac{\text{Width of sciatic notch}}{\text{Depth of sciatic notch}} \times 100$	145	166
3.	Sternal index	$\frac{\text{Length of manubrium}}{\text{Length of body}} \times 100$	46.2	54.3
4.	Corporobasal index	$\frac{\text{Breadth of body of 1st sacral vertebra}}{\text{Breadth of base of sacrum}} \times 100$	>42	<42
5.	Sacral index	$\frac{\text{Transverse diameter of base of sacrum}}{\text{Anterior length of sacrum}} \times 100$	<114	>114
6.	Chilotic line index	$\frac{\text{Sacral part of chilotic line}}{\text{Pelvic part of the chilotic line}} \times 100$	>100	<100
7.	Kimura's base-wing index (Alar index)	$\frac{\text{Width of wing (ala of sacrum)}}{\text{Width of base (transverse diameter of body of S1)}} \times 100$	65	80

Table 5.6: Indices useful for identification

Race (ancestry)	Sex	Species
Cephalic index	Ischiopubic index	Medullary index
Nasal index	Sciatic notch index	
Brachial index	Chilotic line index	
Crural index	Ilium index	
Intermembral index	Sacral index	
Humerofemoral index	Kimura's base-wing index	
Facial index	Corporobasal index	
	Sternal index	

FM4.2, 4.3

Define and describe age determination using teeth-eruption, decay, bones-ossification centers.

AGE

Age determination can be done through many means, and an analysis of all possible age-related attributes is best for an overall estimate. Some of the utilized features include:

i. Dental eruption
ii. Epiphyseal unions
iii. Pubic symphyseal morphology
iv. Cranial suture closures
v. Mandibular and sacral changes
vi. Miscellaneous
   a. Secondary sexual characters
   b. Age-related degenerative conditions.

Is this a male or female skull? Give reasons.

3



Which one of these statements is true?

4

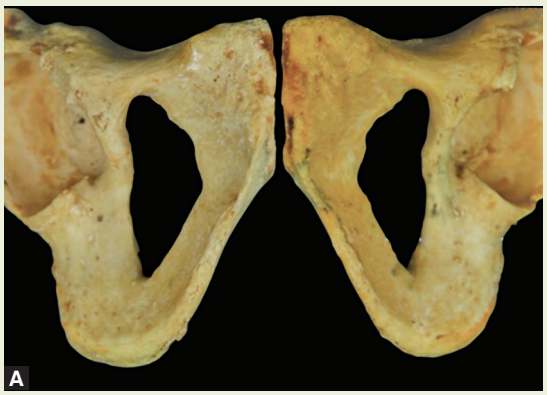

JAYPEE BROTHERS



1. (A) is male pelvis and (B) is female pelvis
2. (A) is female pelvis and (B) is male pelvis
3. Both (A) and (B) are female pelvis
4. Both (A) and (B) are male pelvis

Dentition in Determining Age

Age can be determined by using the criteria like eruption and calcification of teeth, Demirjian method, Stack's method, Miles method, Boyde's method and Gustafson's method.

- Teeth are especially useful to determine age in children and adolescents since the developmental stages are well known and characterized. Radiological analysis of dental development is preferred over morphological analysis.
- Alveolar cavities which contain teeth are formed around the 3–4th month of intrauterine life (IUL).
- At birth, rudiments of all the temporary teeth and the 1st permanent molars may be found in jaw.
- Each tooth has a crown, neck and a root embedded in jaw bone **(Fig. 5.13)**.
- Teeth are composed of *dentin* covered on the crown by enamel and on the root by cementum which is attached to the alveolar bone by periodontal membrane. Tooth enamel is the hardest substance in the body containing primarily hydroxypatite (crystalline calcium phosphate).
- Mineralization proceeds from crown tips down the sides of the tooth.

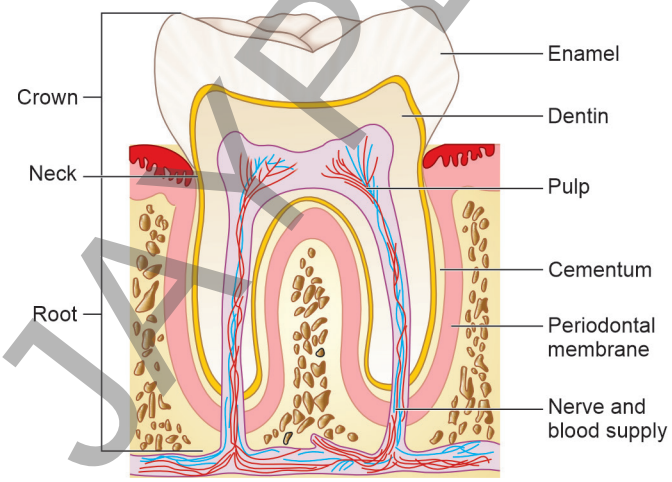

Fig. 5.13: Parts of a tooth

- Root mineralization does not begin until crown formation is complete and root formation ceases with the reduction of apical foramen. As the root becomes longer, the crown erupts through the bone.
- Mineralization of deciduous dentition begins in utero, early in 2nd trimester, and root formation of third molar may not be complete until 20 years of age.
- During eruption of a permanent tooth, the overlying root of its deciduous predecessor simultaneously undergoes absorption, until only the crown remains. The unsupported crown then falls off.
- Age of eruption of teeth depends upon:
  i. Heredity
  ii. Environment
  iii. Nutrition
  iv. Endocrine factors.

Each individual has two sets of teeth (Diff. 5.7)

i. Temporary/deciduous/milk teeth
ii. Permanent teeth

Temporary teeth

- *20 in number*: 4 incisors, 2 canines and 4 molars in each jaw **(Table 5.7** and **Fig. 5.14)**.
- The eruption of the deciduous teeth commences at about 6–7 months after birth and is completed about 2nd-3rd year. the lower central incisors anteceding those of the upper. However, upper lateral incisor erupts earlier than its lower quadrant counterpart.
- In ill-nourished children, especially in rickets, dentition may be delayed.
- In congenital syphilis, teeth may be premature or even present at birth.

Permanent teeth: 32 in number—4 incisors, 4 pre-molars, 2 canines and 6 molars in each jaw **(Table 5.7** and **Fig. 5.15)**.

Developmentally teeth are divided into two sets:

a. **Super-added permanent teeth:** These teeth do not have deciduous predecessors. All permanent molars belong to this category (6 in each jaw).
b. **Successional permanent teeth:** These teeth erupt in place of deciduous teeth, e.g., permanent premolars erupt in place of deciduous molars (10 in each jaw).

- Usually permanent tooth erupts first in lower jaw.
- Permanent teeth appear few months earlier in girls than in boys.
- Eruption of teeth is useful in estimating age up to 15 years. The third molar (wisdom tooth) erupts after this time, but is so variable in eruption that it is not a reliable age indicator.
- However, the developmental characteristics of eruption and mineralization of 3rd molars are useful for age estimation. The assessment distinguishes between the stages of alveolar eruption, gingival eruption, and having reached the occlusal plane. The latter two stages can be determined by oral visual inspection and do not require

JAYPEE BROTHERS

Differentiation 5.7 Temporary and permanent teeth

S.No.	Feature	Temporary teeth	Permanent teeth
1.	Size	Smaller, lighter, narrower, except temporary molars which are longer than permanent premolars	Heavier, stronger, broader, except permanent premolars
2.	Direction of anterior teeth	Vertical	Inclined forward
3.	Crown color	China-white	Ivory-white
4.	Neck	More constricted	Less constricted
5.	Ridge	Present at the junction of the crown and the root	Not present
6.	Root	Roots of molars are smaller, more divergent	Roots of molars are larger, less divergent
7.	Incisors	Smooth incisal edge	Ridged, especially on incisal surface
8.	Radiology	Presence of tooth germ beneath tooth will suggest that tooth is temporary	No such thing visible in case of permanent teeth

Table 5.7: Eruption of deciduous and permanent teeth

Tooth	Deciduous teeth (months)	Permanent teeth (years)
Central incisor	**6–8 (lower, 1st to erupt)** 7–9 (upper)	6–8
Lateral incisor	7–9 (upper) 10–12 (lower)	7–9
First premolar	Absent	9-11
Second premolar	Absent	10-12
First molar	12–14	**6–7 (1st to erupt)**
Canine	17–18	11–12
Second molar	20–30 (2–2½ years)	12–14
Third molar	Absent	17–25

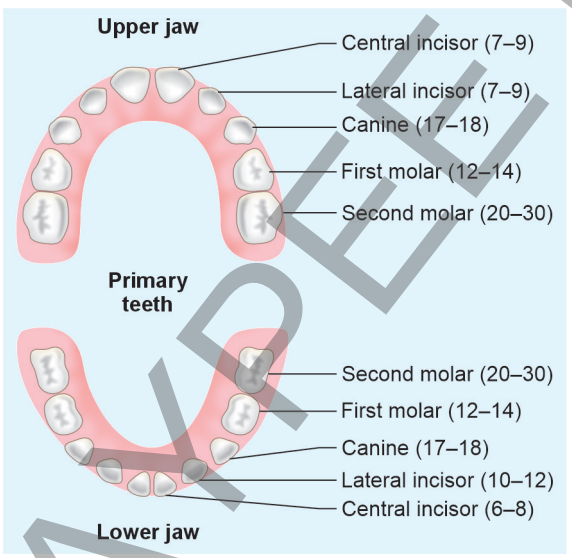

Fig. 5.14: Eruption of deciduous teeth (in months)

an X-ray. The mineralization of third molars is assessed with an orthopantomogram.

- The mandibular third molar is the most commonly impacted tooth in the mouth and is closely followed by maxillary third molar, maxillary canine and mandibular canine respectively.

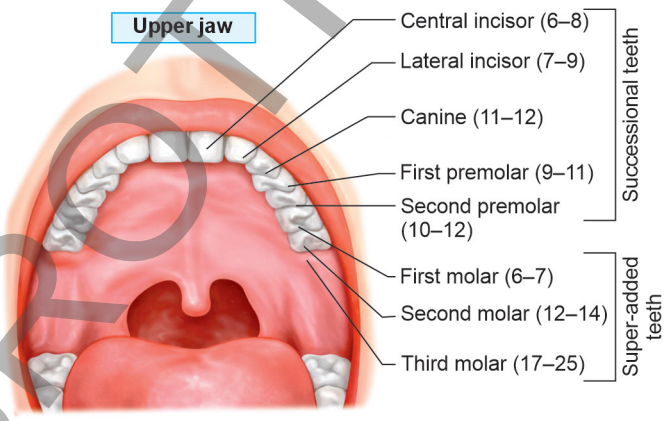

Fig. 5.15: Eruption of permanent teeth (in years)

- If, in the jaw all 3rd molars are present, then the age is over 18 years, but their absence gives no certain idea about age.

Spacing of Jaw

After eruption of 2nd molars, the ramus of mandible grows behind to make room for the eruption of 3rd molar teeth which is known as *spacing of the jaw*.

Period of Mixed Dentition

Starting from the day of eruption of first permanent molar till before the eruption of last permanent canine—both temporary and permanent teeth are present in the jaw. This duration is known as *period of mixed dentition* **(Table 5.8** and **Figs. 5.16A and B)**. Usually, it is between 6 and 11 years, but may persist until 12–13 years.

- From 6 to 11 years, the total number of teeth remains 24 because as and when a tooth erupts, it displaces another and the number remains constant.
- There is addition of teeth from the age of 12–14 years, when the second molar erupts and the total number becomes 28. Then, the number remains constant till 17 years and again 4 more teeth are added from 17–25 years and the number becomes 32.

JAYPEE BROTHERS

Table 5.8: Number of teeth with age*

Age (years)	*Number of teeth*	
2.5–5	20	(All deciduous)
6	21–24	(Eruption of 1st permanent molars)
7–9	24	(12 permanent—8 incisors, 4 molars) (12 deciduous—4 canines, 8 molars)
10	24	(16 permanent—8 incisors, 4 molars, 4 premolars) (8 deciduous—second molars and canines)
11	24	(20 permanent—8 incisors, 4 molars, 8 premolars) (4 deciduous—canines)
12–14	25–28	(Eruption of 2nd permanent molars)
14–17	28	(All permanent)
17–25	29–32	(Eruption of 3rd molars)

* Total number of permanent teeth = (Age in years–5) × 4

Estimation of age from teeth beyond 25 years
The various methods that can be used to determine age from teeth are:
- Gustafson's method
- Aspartic acid racemization
- **Chemical method:** Estimation of nitrogen content of enamel (increases with age), carbonate content (decreases with age) and concentration of ions—Cu, Se and Fe (increases with age).
- Miles' method
- Radiocarbon dating of tooth enamel

- Of the non-destructive methods (where tooth is not required to be taken out), assessing stages of development of mineralization of the teeth using radiographs are more reliable than those using tooth counts.
- *Amino acid racemization* is considered to be most reliable destructive method of dental age estimation.

Gustafson's Method

- Age estimation consists of microscopic examination of longitudinal section of central part of the tooth to assess changes in teeth as a result of wear and tear with advancing age.
- Estimate age between 25 and 60 years (applicable only in adults).
- Useful only while examining a *dead body or skeletal remains,* as teeth need to be extracted for examination.
- It is based on criteria given in **Table 5.9** and **Figures 5.17**.
- Anterior teeth are more suitable than posterior teeth. Merit decreases from incisors to premolars, molars are quite unsuitable.
- All changes are absent at 15 years. Error is ± 10–15 years. Limit of error increases above 50 years of age.

Other Information from Teeth

- **Sex determination**
  i. *Visual and microscopic*: Mandibular canines show the greatest dimensional differences with larger teeth in males than in females. Optical scanner and radiogrammetric measurements of root length and crown diameter of mandibular permanent teeth help in sex determination.
     - Identifying Y-chromosome in dental pulp tissue using quinacrine and fluorescent microscopy.
     - Isolation of sex-specific banding patterns in DNA profiles of X and Y-chromosomes.
  ii. *Sex determination from enamel protein*: Amelogenin (AMEL) is a major protein found in human enamel. It has a different signature in male and female.
- **Race (ancestry)**
  i. '*Shovel-shaped*' upper central incisors can be found in most Asians (Mongoloids) and Americans. In Europeans, lateral incisor in upper jaw is smaller than the central, especially in females.

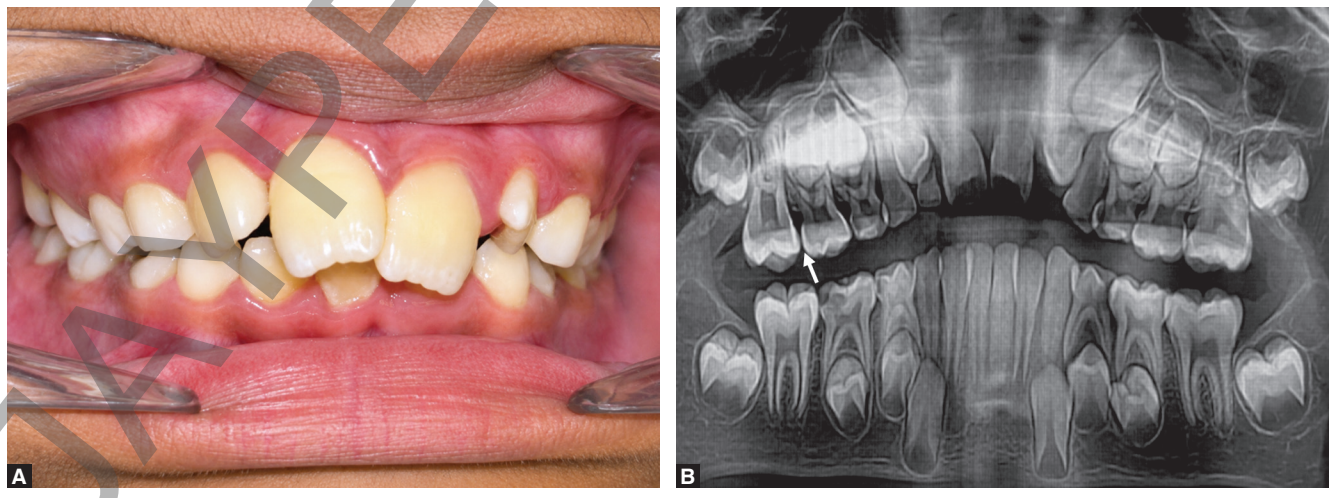

Figs. 5.16A and B: Mixed dentition: (A) 7–8-years-old child (permanent incisors and temporary canines can be seen); and (B) 9-years-old child (orthopantomogram showing erupted permanent incisors and first molars with retained primary teeth, developing permanent canines/premolars, and resorption of primary tooth roots.)
[*Courtesy* (A) Naveen Oberoi, Dept of Dentistry, BJS Dental college, Ludhiana; and (B): Vineet Galhotra, Dept of Dentistry, DMCH, Ludhiana]

JAYPEE BROTHERS

Table 5.9: Gustafson's criteria **(Fig. 5.17)**

S.No.	Changes	Description
1.	Attrition	Wearing down of occlusal surface due to mastication, first involving enamel, then dentin and lastly pulp
2.	Periodontosis	Retraction of gum margin and loosening of tooth exposing the neck and adjacent parts of roots
3.	Secondary dentin	Progressive infilling of the dental pulp cavity decreases the size of cavity and may completely obliterate it
4.	Cementum apposition	Cementum increase in thickness around the root due to changes in tooth position; continuously deposited throughout life and forms incremental lines
5.	Root resorption	Involves both cementum and dentin. Starts at apex and extends upwards. *Least reliable of all criteria*
6.	Root transparency	Occurs in root from below upwards in lower jaw and above downwards in upper jaw due to rarefaction of the dentin tissue. *Most reliable of all criteria*

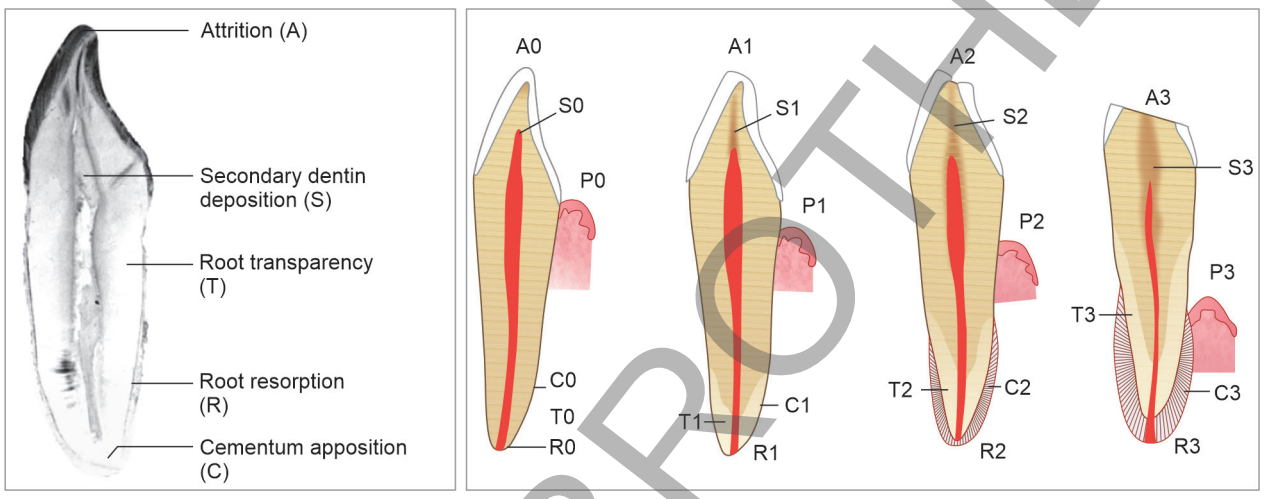

Fig. 5.17: Gustafson's method and its criteria. Scoring system: Each factor is scored 0–3 (absent → marked); total score (0–18) is calculated. Age (years) = 11.43 + (4.56 × total score)

ii. *Carabelli's cusp* (seen in whites), *taurodontism* (bull tooth) and *enamel pearls* (common in Asians) have been listed as racial determinants.

IMPORTANT NOTE

- **Carabelli's tubercle** is an anomalous cusp on the lingual surface of maxillary first permanent molars, most commonly seen among Europeans (75–85%) (50% of American whites and 34% of Afro-Americans).
- **Taurodontism** is an aberration of teeth that lacks the constriction at the level of the cementoenamel junction characterized by elongated pulp chambers and apical displacement of bifurcation or trifurcation of the roots, giving it a rectangular shape.
- **Enamel pearls** are small nodules of enamel on the root surface of permanent maxillary molar.
- Taurodontism, especially in maxillary molars, enamel pearls on premolars and congenital lack of upper 3rd molars are commonly seen in Asians *(Mongoloids)*.

❖ **Occupation and habits**

i. Cobblers or tailors usually show notched upper incisors from wear and tear.

ii. Dark brown stains on the back of incisors are seen in 'cigarette smokers'.

❖ **Social status:** From general cleanliness, dentures and dental fillings by gold, silver or other metal.

IMPORTANT NOTE

- **Stack's method:** Method to estimate the age from sum of the weight of the erupting teeth of *fetus and infant* (from 5 months in utero to postnatal age of 7 months).
- **Boyde's method:** Estimate age of dead infants, based on counting the number of cross striations in the enamel of teeth (incremental lines) from *neonatal line* (darkest band) onwards. Neonatal line is formed soon after birth.
- **Demirjian method:** Dental age estimation in children based on assessment of maturity score of lower left permanent mandibular teeth (except 3rd molar) using an orthopantomogram.
- **Lamendin method:** Periodontosis and translucency of root are taken into consideration for estimation of age at death for adults by analyzing single-rooted teeth—considered better than Gustafson's method.
- **Miles' method:** Amount of wear on all three permanent molars is assessed for age estimation. Miles also developed a formula to determine age at death by measuring the thickness of enamel and dentin from neonatal line and divided it by daily rate of formation.
- **Histological technique:** The amount of dentin laid down after the formation of the neonatal line (incremental lines) in deciduous dentition, and counting of cross-striations and striae of Retzius in primary and secondary enamel may help in

JAYPEE BROTHERS

finding the chronological age. Once enamel depositions are complete, the use of cemental annulations rings can be used.

- **Aspartic acid racemization:** During the course of aging, L-forms of amino acids (in crown dentin) are transformed by racemization to D-forms. Thus, the extent of racemization of amino acids may be used to estimate the age. Of all amino acids, aspartic acid racemization is most commonly used for age estimation.
- **Radiocarbon analysis of tooth enamel:** Method to determine the year of tooth formation based on levels of radiocarbon present in tooth enamel.

AGE FROM OSSIFICATION OF BONES

- The clavicle is the first bone to ossify in the body from two membranous primary ossification centers during the 5–6th postovulatory week (3rd to 4th week after conception). A secondary center forms in the sternal end between 15–17 years and fuses by 20–22 years. In majority of the bones, primary centers of ossification appear between 7th and 12th weeks of IUL. By the age of 11–12th week of IUL, there are 806 centers of ossification.
- The process of appearance and union has a sequence and time (approximate age ranges) **(Table 5.10 and Fig. 5.18)**.

Table 5.10: Appearance of ossification centers (in males)

S.No.	Bone	Centers of ossification	Age of appearance	Age of union
1.	Sternum	Manubrium	5th month IUL	60–70 years (Manubriosternal joint)
		1st sternebrae	5th month IUL	(From below upwards; 3rd and
		2nd and 3rd sternebrae	7th month IUL	14–25 years 4th–15 years; 2nd and 3rd–20 years;
		4th sternebrae	10th month IUL	1st and 2nd–25 years)
		Xiphisternum	3rd year postnatal	40–45 years (With body)
2.	Clavicle	Medial end	15–17 years	20–22 years
3.	Scapula	Coracoid base	10–11 years	14–15 years
		Acromion process	14–15 years	17–18 years
Upper Limb				
4.	Humerus	Head	1 year	At 5–6 years, the three fuses
		Greater tubercle	3 years	together (*conjoint epiphysis*) and at
		Lesser tubercle	5 years	17–18 years, fuses with the shaft
		Capitulum	1 year	At 14–15 years, all three
		Trochlea	9–10 years	fuses with the shaft*
		Lateral epicondyle	10–11 years	
		Medial epicondyle	5–6 years¥	16 years
5.	Radius	Upper end	5–6 years	15–17 years
		Lower end	1–2 years	17–19 years
6.	Ulna	Upper end (olecranon)	8–9 years	15–17 years
		Lower end	5–6 years	17–19 years
7.	Carpals	Pisiform	9–12 years	—
Lower Limb				
8.	Hip bone	Ischiopubic rami	—	7 years
		Triradiate cartilage	—	12–14 years
		Iliac crest$	15–16 years	19–21 years
		Ischial tuberosity	16–17 years	20–22 years
9.	Femur	Head	1 year	17–18 years
		Greater trochanter	4 years	14–15 years
		Lesser trochanter	14 years (puberty)	15–17 years
		Lower end	9 months IUL	17–18 years
10.	Tibia	Upper end	At birth	17–18 years
		Lower end	1 year	16–17 years
11.	Fibula	Upper end	4 years	17–18 years
		Lower end	2 years	16–17 years
12.	Tarsals	Calcaneum	5th month IUL	
		Talus	7th month IUL	
		Cuboid	9th month IUL	

* Ossification centers of lateral epicondyle, capitulum and trochlea fuse with each other at about 13–14 years to form a conjoint epiphysis which fuses with shaft at about 14–15 years.

¥ Sequence of appearance of elbow ossification centers: **CRITOE:** Capitulum → Radial head → Internal (medial) epicondyle → Trochlea → Olecranon → External (lateral) epicondyle.

$ Radiographically, Risser classification is used to grade skeletal maturity of ossification and fusion of iliac crest on a scale of 0-5. Risser 0 indicates that there is significant amount of growth remaining, while Risser 5 indicates skeletal maturity.

JAYPEE BROTHERS

for detailed information on forensic medicine & toxicology books, visit our website www.ejaypee.com, for detailed information on forensic medicine & toxicology books, visit our

FORENSIC MEDICINE & TOXICOLOGY FOR MEDICAL STUDENTS

The 7th edition is a comprehensive, student-friendly resource to Forensic Medicine and Toxicology, designed to bridge the gap between medical knowledge, legal principles, and clinical practice. Developed as per the latest NMC competency-based curriculum, the book empowers learners to understand, analyze, and apply forensic principles confidently in clinical practice, courtroom scenarios, and competitive examinations, through a clear, application-based approach with real-life cases, visual learning tools, and exam-focused resources.

Decode Forensic Medicine with NMC Aligned Content
Aligned with the revised NMC Competency-Based Undergraduate Curriculum, integrating essential competencies and outcome-based learning approaches throughout the text.

Updated Knowledge from Crime Scene to Courtroom
Evidence-based approach incorporated with latest guidelines, recent advances, and updated approaches to poisoning and its management in forensic medicine and toxicology for up-to-date knowledge.

Your Learning Roadmap Before Every Chapter
Clearly defined learning objectives at the beginning of each chapter guide students toward focused and effective preparation with must-know topics for exams and desirable-to-know topics.

Understand the "Logic Behind the Law"
Simplified conceptual explanations focus on reasoning, interpretation, and clinical application with emphasis on understanding the "why" behind the facts, rather than rote learning.

Remember More with Visual Learning Aids
This edition includes more memory aids—pearls, mnemonics, footnotes, and fascinating forensic facts—to make complex concepts easier to recall and encourage deeper exploration of the subject.

See, Analyze, Remember with Engaging Presentation
A visually engaging format refined over 18 years, incorporating evolving educational needs and feedback from learners including color-coded tables, flowcharts, illustrations, and concept boxes for better understanding and faster revision.

Think Like a Forensic Expert with Clinical Correlation
Engaging case scenarios, forensic images, real case reports, and thought-provoking questions, thus bringing forensic concepts to life and developing analytical skills as well as strengthening diagnostic reasoning.

Rapid Revision Before the Final Verdict
End-of-chapter high-yield revision points summarize must-know concepts of the chapter for quick review and quick reference before examinations, viva-voce, and various entrance examinations.

Concept Rx—Smart Learning Beyond the Textbook
QR-enabled digital resource providing examination preparation materials such as smart notes, chapter summaries, PYQs, MCQs, mind maps, and other learning tools for revision support anytime, anywhere.

JAYPEE BROTHERS

Buy from ejaypee

JAYPEE BROTHERS

Shelving Recommendations
FORENSIC MEDICINE & TOXICOLOGY

ISBN 978-81-6799-992-4