al care books, visit our website www.ejaypee.com, for detailed information on critical care books, visit our website www.ejaypee.com, for detailed information on critical care books

Complimentary 51 Infographic Images

ISCCM
INDIAN SOCIETY OF CRITICAL CARE MEDICINE

CRITICAL CARE PEARLS

CASE-BASED DISCUSSIONS

Editors
Soumya Sankar Nath
Ranvir Singh Tyagi

Co-Editors
Nandhini Nachimuthu
Neeraj Kumar
Tanmoy Ghatak

Forewords
Pradeep Rangappa
CM Singh



JAYPEE BROTHERS

JAYPEE

Contents

SECTION 1: Diseases of the Central Nervous System

1. **Acute Ischemic Stroke** 3
   Amiya Kumar Barik, Srikant Behera
2. **Acute Inflammatory Demyelinating Polyneuropathy with Bulbar Palsy** 11
   Suhail Sarwar Siddiqui, G Sradhanjali
3. **Viral Encephalitis** 19
   Ankur Khandelwal, Jitupam Baishya, Kalyan Sarma
4. **Status Epilepticus** 23
   Ankur Khandelwal, Jitupam Baishya, Kalyan Sarma
5. **Hemorrhagic Stroke** 30
   Ravi Ranjan, Mrudula BS
6. **Tuberculous Meningitis** 39
   Sharif Alam, Rachana Gupta

SECTION 2: Diseases of the Respiratory System

7. **Severe Community-acquired Pneumonia** 53
   Gyanendra Agrawal, Anand Vardhan
8. **Acute Exacerbation of Chronic Obstructive Pulmonary Disease with Cor Pulmonale** 60
   Kunal Deokar, Sanjay Singhal
9. **Severe Acute Respiratory Distress Syndrome** 70
   Supradip Ghosh, Anirban Bhattacharjee, Rajathadri Hosur Ravikumar
10. **Venovenous Extracorporeal Membrane Oxygenation in Acute Respiratory Distress Syndrome** 80
    Arpan Chakraborty, Oendrila Roy
11. **Difficult Weaning from Mechanical Ventilation** 90
    Apoorva Gupta

SECTION 3: Diseases of Cardiovascular System

12. **Acute Myocardial Infarction and Left Ventricular Failure** 101
    Ganesh KM, Ranajit Chatterjee
13. **Undifferentiated Shock** 112
    Santosh Kumar Sharma

JAYPEE BROTHERS

14. **Pulmonary Artery Hypertension and Right Heart Failure** 121
Kaushik DS, Sulagna Bhattacharjee

15. **Acute Pulmonary Embolism** 132
Akshay A Chhallani, Prashant Bankar

16. **Integrating Point-of-Care Ultrasound in Cardiopulmonary Resuscitation** 142
Badri Prasad Dash

17. **Postcardiac Arrest Care** 153
Nikhil Kothari, Darshan BK

SECTION 4: Acute Abdominal Diseases

18. **Acute Pancreatitis** 163
Rajathadri Hosur Ravikumar, Dalim Kumar Baidya

19. **Acute Gastrointestinal Injury** 173
Gaurav Jain

20. **Acute Liver Failure** 180
Sahil Kataria, Sumit Ray

21. **Acute-on-Chronic Liver Failure** 187
Vaishali Agrawal, Jitendra Chahar

SECTION 5: Infectious Diseases

22. **Burn Sepsis and Septic Shock** 197
Bhavya Naithani Dube, Shreyas Gutte

23. **Severe Dengue Fever** 206
Tanmoy Ghatak

24. **Viral Pneumonia** 211
Amit Srivastava, Anupam Mishra

25. **Invasive Fungal Infection in an Immunocompetent Critically Ill Patient** 218
Ganshyam Jagathkar

26. **Emerging Viral Infections** 226
Kiran Rajagopal

27. **Diarrhea and *Clostridioides difficile* Infection** 235
Rupali Pathak, Sharmili Sinha

28. **Complicated Intra-abdominal Infections** 241
Nandhini Nachimuthu, Soumya Sankar Nath

29. **Navigating Antimicrobial Resistance** 249
Srivats Valliyur Ramamoorthy, Vijayasri SG

30. **Scrub Typhus** 256
Himanshu Dandu

JAYPEE BROTHERS

SECTON 6: Endocrine Emergencies

31. Diabetic Ketoacidosis 267
Mohit Kumar Roy

32. Hyperosmolar Hyperglycemic State 273
Swarna Deepak K, Lalit Kumar Rajbanshi

SECTION 7: Poisoning/Overdose

33. Organophosphorus/Organocarbamate Poisoning 281
Vivek Badada, Diptimala Agarwal

34. Veno-arterial Extracorporeal Membrane Oxygenation in Aluminum Phosphide Poisoning 288
Vinay Singhal, Vivek Gupta

35. Paraquat Poisoning 304
Chandra Shekhar Gaur, Prateek Koolwal

36. Snakebite Envenomation 308
Jacob George

SECTION 8: Pregnancy Related

37. Neurological and Systemic Complications of Pregnancy-induced Hypertension 323
Sulekha Saxena, Deen Bandhu Prasad

38. Puerperal Sepsis 333
Neeraj Kumar

39. Postpartum Hemorrhage 337
Gunchan Paul, Priya Logia

SECTION 9: Transplant Related

40. Acute Renal Graft Rejection 349
Divya Srivastava, Abhilash Chandra

41. Brain Death and Management of Organ Donor 356
Venkat Raman Kola, Durgesh Jagdish Satalkar

SECTION 10: Miscellaneous

42. Nutritional Support in the Adult Septic Patient 367
Ritu Singh, Mallikarjun Gunjiganvi

43. Old Age and Frailty 376
Suresh Ramasubbamanian

JAYPEE BROTHERS

44. Heat Stress Injury **381**
Deen Bandhu Prasad, Saumitra Misra

45. Post-intensive Care Syndrome **388**
Gunjan Chanchalani, Abhishek Singh Ranbahadur Rajput

SECTION 11: Malignancy Related

46. Tumor Lysis Syndrome **399**
Neeraj Pal Singh, Amol Trimbakrao Kothekar

47. Sepsis in the Immunocompromised Host **406**
Anirban Hom Choudhuri, Priyanka Harsinghani

SECTION 12: Kidney Related

48. Sepsis-associated Acute Kidney Injury **415**
Neeraj Patel, Sai Saran PV

SECTION 13: Trauma Related

49. Polytrauma **427**
Khusrav Bajan

50. Traumatic Brain Injury **437**
Sananta Kumar Dash, Debomoy Ghatak

51. Inhalational Injury **446**
Bhavya Naithani Dube, Mallikarjun Dube

Index *455*

JAYPEE BROTHERS

CHAPTER 6

Tuberculous Meningitis

Sharif Alam, Rachana Gupta

Kindly scan the QR code below to access the online infographic image.

CASE VIGNETTE

A 26-year-old male patient with no comorbidities was brought to the emergency department with complaints of fever and headache for 20 days, multiple episodes of vomiting for 5 days, and altered sensorium for 3 days. There was no history of trauma, drug abuse, pesticide exposure, and focal neurological deficit or seizures reported.

On arrival, the patient was disoriented, restless, and febrile (101°F). At the time of examination, his Glasgow Coma Scale (GCS) was 11 (E3V4M5), heart rate 120 beats/min, regular, respiratory rate 26 breaths/min, BP 130/86 mm Hg, and 96% SpO_2 on room air. Pupils were bilaterally 4 mm in size and sluggishly reactive to light.

Systemic examination showed nuchal rigidity and a positive Kernig's sign. Patient was moving all four limbs actively (DTR grade +2) with no sign of focal neurological deficits. Routine blood investigations were sent, and blood was collected for culture and sensitivity testing. Blood sugar was 103 mg/dL.

A provisional diagnosis of central nervous system (CNS) infection was made, and injection paracetamol 1 g, injection mannitol 20% 100 mL, injection ceftriaxone 2 g IV, vancomycin 2 g IV, injection acyclovir 800 mg, and injection dexamethasone 8 mg IV stat were administered in the triage area. After this, the patient was transferred from the triage area to the critical care unit due to a fall in GCS, for further management.

INTRODUCTION

Tuberculous meningitis (TBM) is the most severe form of extrapulmonary tuberculosis and remains a major cause of mortality and long-term neurological disability, particularly in tuberculosis-endemic regions. It results from hematogenous dissemination of *Mycobacterium tuberculosis* to the CNS, leading to basal meningeal inflammation, hydrocephalus, vasculitis, cerebral infarction, and cranial nerve involvement. Delayed diagnosis is common because of its insidious onset and nonspecific clinical features, often resulting in poor outcomes. This case-based discussion presents a practical, evidence-based approach to the diagnosis and management of TBM, emphasizing early recognition, appropriate neuroimaging and cerebrospinal fluid (CSF) evaluation, timely initiation of antitubercular therapy (ATT) and corticosteroids, management of complications, and principles of neurocritical care.

Q1. What should be the initial ICU approach to a patient presenting with fever and altered sensorium?

Management of a patient with fever and altered sensorium in the ICU requires immediate stabilization

JAYPEE BROTHERS

and simultaneous neurological assessment. The initial evaluation includes airway, breathing, and circulation (ABC) as well as a focused neurological examination, because delays in stabilization or treatment may significantly worsen neurological outcomes.[1,2]

Airway assessment is the first priority. In a patient with a GCS of 11, airway reflexes may still be preserved, but the risk of aspiration, hypoventilation, or sudden neurological decline remains significant. If the patient's responsiveness or airway reflexes decrease, endotracheal intubation should be considered immediately.

Breathing is assessed by the use of accessory muscles, respiratory rate and pattern, oxygen saturation, and arterial blood gas analysis. Supplemental oxygen should be administered immediately to maintain oxygen saturation >94%, as hypoxemia worsens cerebral injury. Tachypnea in such patients may reflect fever-induced raised metabolic demand, metabolic acidosis, sepsis, or rising intracranial pressure (ICP).[2]

Circulatory assessment includes heart rate, blood pressure, capillary refill time, urine output, and serum lactate. Maintaining adequate cerebral perfusion pressure is crucial for preventing cerebral injury. A hypovolemic or septic patient should receive a balanced salt solution promptly. Vasopressor support (norepinephrine preferred) should be started if hypotension persists despite fluid resuscitation.[1,2]

Continuous monitoring of blood pressure, temperature, oxygen saturation, urine output, and blood glucose is mandatory. Strict fever control is important, because hyperthermia increases cerebral metabolic demand.[2] Urinary catheterization for fluid balance assessment and insertion of a Ryle's tube permits gastric decompression and early enteral nutrition.

Serial GCS evaluation is required, because a falling GCS may indicate worsening cerebral edema, hydrocephalus, seizures, encephalopathy, or progression of intracranial pathology.[2] Pupillary examination should assess size, symmetry, and light reflexes, as anisocoria, sluggish reactivity, or fixed dilated pupils may indicate impending herniation. Quantitative pupillometry offers superior sensitivity for early neurological deterioration. A search for focal deficits, cranial nerve involvement, and abnormal posturing should be performed. Signs of meningeal irritation, such as neck stiffness, Kernig sign, and Brudzinski sign, help support the diagnosis of meningitis. Patients must be screened for evidence of raised ICP (deteriorating/reduced level of consciousness, papilledema, dilated and poorly reactive pupils, sixth nerve palsies, decerebrate posturing, and Cushing reflex) and impending herniation.[2]

Simultaneous diagnostic evaluation should include complete blood count, serum electrolytes, renal and liver function tests, blood glucose, arterial blood gas analysis, CSF analysis, and two sets of blood cultures.[1]

Because of persistent fever and ongoing neurological deterioration, empiric antimicrobial therapy was initiated while further diagnostic evaluation was planned.

Q2. Why should empiric antimicrobials be administered before definitive investigations such as lumbar puncture (LP)?

Neuroinfectious disease guidelines recommend initiating empiric antimicrobial therapy as early as possible, ideally within the first hour of suspicion, after obtaining blood cultures if feasible, even if LP or neuroimaging is delayed.[1-3] In patients with fever, altered sensorium, and meningeal signs, delaying treatment may rapidly lead to cerebral edema, raised ICP, hydrocephalus, ischemia, herniation, and permanent neurological injury. The usual empirical regimen includes a third-generation cephalosporin and vancomycin, with intravenous acyclovir added when encephalitis is suspected. Adjunctive dexamethasone should be administered when bacterial or TBM is suspected.[1]

The principal reason for deferring LP in this patient was the concern for raised ICP, as elevated ICP carries a potential risk of brain herniation during LP. Therefore, bedside and radiological assessment for intracranial hypertension must be undertaken before CSF removal in selected patients.[1,2]

Although antibiotics may reduce the microbiological yield of CSF culture after some hours (approximately 4–6 hours), CSF analysis still retains diagnostic value even after therapy has started. Pleocytosis, elevated protein, hypoglycorrhachia (CSF glucose level <45 mg/dL or CSF to serum glucose ratio <0.6), stain results, and molecular tests often remain informative. Hence, early antimicrobial administration should not be postponed.[2]

After initial resuscitation, the patient was catheterized, an nasogastric tube was inserted, and empiric antimicrobials were started. Despite initial therapy, the patient demonstrated a progressive decline in GCS, necessitating endotracheal intubation and mechanical ventilation.

JAYPEE BROTHERS

Q3. What precautions should be taken during endotracheal intubation in patients with suspected CNS infection and raised ICP?

Patients with a GCS score ≤8, inability to protect the airway, uncontrolled seizures, refractory hypoxemia, hypercapnia, status epilepticus, or impending respiratory failure require urgent endotracheal intubation.[1,2] Rapid sequence intubation with adequate sedation and analgesia is preferred to minimize ICP fluctuations and preserve hemodynamic stability. Mechanical ventilation should aim to maintain normoxia and normocapnia as both can exacerbate cerebral edema and worsen neurological outcome.[2] Excessive positive end-expiratory pressure should be avoided, as it can reduce cerebral venous drainage. Ventilator settings must be individualized to the patient's neurological and respiratory status.

Q4. What monitoring should be instituted following intubation and mechanical ventilation?

Postintubation monitoring should be comprehensive, including ECG, pulse oximetry, blood pressure, end-tidal carbon dioxide, and temperature monitoring. Serial neurological assessment should include GCS (where assessable), pupillary size and reactivity, focal neurological examination, and screening for signs of raised ICP. Strict fluid balance, urine output, serum sodium, osmolality, and arterial blood gases should also be monitored. EEG monitoring should be considered to detect nonconvulsive status epilepticus in selected patients.[2,4,5]

Q5. What are the principles of nutritional support in this critically ill patient?

These patients are frequently nutritionally depleted, hypercatabolic, and at high risk of refeeding syndrome. Enteral nutrition should be initiated within 24–48 hours of ICU admission, once the patient becomes hemodynamically stable. Trophic feeding (low-calorie, low-volume feeds of approximately 10–20 mL/h) is recommended initially, with gradual escalation as tolerated. This approach maintains gut integrity while minimizing feed intolerance and reducing the risk of refeeding syndrome, particularly in malnourished patients. Monitoring of serum phosphate, potassium, and magnesium is required to detect electrolyte shifts and maintain correction.[2,6]

Usually, feeding is started through a nasogastric or Ryles tube. The nasojejunal or postpyloric route is considered in a patient with persistent vomiting, poor gastric emptying, absent airway protection, or high aspiration risk.

Q6. What are the important differential diagnoses in a patient presenting with fever and altered sensorium?

The differential diagnosis for fever and altered sensorium can be broadly classified into infectious, structural, neurological, metabolic-toxic, autoimmune-inflammatory, and systemic etiologies.[2]

Infectious causes include acute bacterial meningitis, TBM, viral encephalitis, fungal meningitis, and endemic infections such as scrub typhus, leptospirosis, cerebral malaria, dengue encephalopathy, and viral hemorrhagic fevers, which may present with fever and encephalopathy.[2,4,7]

Structural neurological causes include subarachnoid hemorrhage, intracerebral hemorrhage, ischemic stroke with cerebral edema, cerebral venous sinus thrombosis, brain abscess, subdural empyema, and obstructive hydrocephalus, all of which may present with fever secondary to neuroinflammation or associated infection.[2] Intracranial space-occupying lesions should also be considered, particularly when symptoms are subacute.

Metabolic and toxic causes are common ICU differentials and include hyponatremia, hypernatremia, hepatic encephalopathy, uremic encephalopathy, severe acid-base disturbances, hypoxia, hypercapnia, drug intoxication, alcohol withdrawal, and toxic exposures. These may mimic CNS infection and should always be rapidly excluded through bedside and laboratory evaluation.[2]

Autoimmune and inflammatory conditions, such as autoimmune encephalitis, acute disseminated encephalomyelitis (ADEM), CNS vasculitis, and neuropsychiatric lupus, can present with fever and altered mental status, often making differentiation from infectious encephalitis challenging. Systemic causes such as sepsis-associated encephalopathy, malignant hypertension, thyroid storm, adrenal crisis, and heat stroke must also be considered.[4,7]

The subacute history (approximately 20 days) with progressive neurological worsening raised a strong suspicion of CNS infection.

Q7. What clinical features in this patient favored a diagnosis of CNS infection, particularly TBM?

Among patients presenting with acute febrile encephalopathy, the coexistence of fever and altered mental status with meningeal signs significantly increases the likelihood of meningitis or meningoencephalitis.[1,2]

The subacute course, with progressive worsening rather than abrupt deterioration, favored chronic infective

JAYPEE BROTHERS

etiology such as TBM. Absence of focal neurological deficits or trauma made structural causes such as intracranial hemorrhage or traumatic brain injury less likely, while the lack of history suggestive of toxin exposure, metabolic derangement, or seizure disorder reduced the probability of noninfectious causes of altered sensorium.[4,7]

Q8. What clinical features and risk factors help distinguish bacterial, tuberculous, viral, and fungal meningitis?

Assessment of host risk factors, healthcare exposure, immune status, and tempo of illness helps identify the likely etiology of CNS infection and guides early empiric therapy.[1,2]

Acute bacterial meningitis presents with a rapid onset (hours to <5–7 days) of high fever, severe headache, neck stiffness, vomiting, altered sensorium, and may rapidly progress to seizures, septic shock, or raised ICP.

Community-acquired disease is associated with diabetes, alcoholism, chronic liver disease, Human Immunodeficiency virus (HIV), malignancy, splenectomy, and immunosuppressive therapy, with common pathogens being *Streptococcus pneumoniae* and *Neisseria meningitidis*. *Listeria monocytogenes* is more common in elderly, pregnant, alcoholic, and immunocompromised patients.[8]

Healthcare-associated meningitis occurs after neurosurgery, skull fractures, CSF leaks, ventricular drains, or shunts, and is often caused by multidrug-resistant (MDR) organisms such as *Staphylococcus aureus*, coagulase-negative *Staphylococci*, *Pseudomonas*, and *Acinetobacter*.[1,2]

Tuberculous meningitis typically has a subacute course (1–4 weeks) with persistent headache, low-grade fever, vomiting, progressive altered sensorium, cranial nerve palsies, and hydrocephalus. Risk factors include TB exposure, HSV, diabetes, malnutrition, chronic kidney disease, and prolonged corticosteroid use.[6,7]

Viral encephalitis usually presents acutely with fever, behavioral changes, confusion, seizures, and focal neurological deficits. Herpes Simplex virus (HSV) encephalitis classically causes temporal lobe dysfunction, aphasia, and focal seizures.[2]

Fungal meningitis (especially cryptococcal) presents insidiously (>4 weeks) with prolonged headache, lethargy, visual symptoms, and prominent symptoms related to raised ICP, usually in patients with advanced HIV, transplantation, malignancy, or prolonged immunosuppression.[9] Important distinguishing features among major CNS infections are summarized in **Table 1**.

TABLE 1: Key clinical features in major central nervous system (CNS) infections.

Feature	*Acute bacterial meningitis*	*Tuberculous meningitis (TBM)*	*Viral encephalitis*	*Fungal meningitis*
Onset/Course	Hyperacute to acute (hours to 2–5 days)	Subacute to chronic (1–4 weeks)	Acute to subacute	Chronic (>4 weeks), insidious
Meningeal signs	Prominent	Present, may appear later	Often mild or absent	Often subtle
Altered sensorium	Rapid progression	Gradual worsening	Early prominent feature	Slowly progressive
Seizures/focal neurological deficits	May occur	Occasional	Common, often early	Less common
Raised intracranial pressure (ICP)/hydrocephalus	Possible	Very common	Less common	Common (especially cryptococcal)
Characteristic clinical features	Petechial rash (meningococcal), septic shock, and rapid deterioration	Cranial nerve palsies (most commonly 6th nerve), hydrocephalus, and constitutional symptoms	Behavioral changes, confusion, memory loss, and temporal lobe signs	Visual symptoms, gradual cognitive decline
Risk factors	Diabetes, alcoholism, splenectomy, and immunosuppression	TB exposure, endemic area, malnutrition, and HIV	Viral exposure and seasonal outbreaks	HIV, transplant, malignancy, and prolonged steroids
Common organisms	*Streptococcus pneumoniae*, *Neisseria meningitidis*, and *Listeria*	*Mycobacterium tuberculosis*	HSV, VZV, enteroviruses, and arboviruses	*Cryptococcus neoformans*

(TB: tuberculosis; HIV: human immunodeficiency virus; HSV: herpes simplex virus; VZV: varicella zoster virus)

JAYPEE BROTHERS

The patient shows no improvement in GCS, raising concern for elevated ICP. Neuroimaging and bedside assessment were considered before LP.

Q9. What investigations should be performed in a patient with suspected CNS infection?

The purpose of investigation in suspected CNS infection is to confirm infection, identify the causative organism, detect complications and guide early targeted therapy.[2]

The initial laboratory workup should include complete blood count, serum electrolytes, renal and liver function tests, blood glucose, coagulation profile, inflammatory markers (C-reactive protein/procalcitonin where available), and arterial blood gas analysis. These tests help identify metabolic derangements that may mimic or worsen encephalopathy and are essential for therapeutic planning. Blood glucose measurement is particularly important for accurate interpretation of CSF glucose and calculation of the CSF-to-blood glucose ratio.[2]

At least two sets of blood cultures should be obtained before antimicrobial therapy whenever feasible, as they remain positive in a significant proportion of cases of acute bacterial meningitis and may identify the pathogen even when CSF cultures become sterile after antibiotic exposure.[1,2]

Human immunodeficiency virus serology, tuberculosis screening, malaria testing, scrub typhus serology, leptospira serology, and fungal markers are required, depending on clinical context and endemic exposure.

Q10. Is a computed tomography (CT) scan mandatory before a LP? What is the role of optic nerve sheath diameter (ONSD) ultrasonographic assessment in ICU practice?

A noncontrast CT scan is not mandatory for every patient before LP. It should be performed in patients with altered consciousness, focal neurological deficits, papilledema, new-onset seizures, immunocompromised state, or suspected raised ICP.[1,2] CT helps identify cerebral edema, hydrocephalus, mass lesions, or impending herniation. It is equally important to recognize that a normal CT scan does not completely exclude raised ICP or eliminate the risk of herniation, as early intracranial hypertension may not always be radiologically apparent. Hence, clinical assessment remains paramount.

In modern ICU practice, when ICP is suspected to be elevated, rapid bedside ultrasonography of the ONSD provides a valuable adjunct to clinical decision-making. An ONSD > 5–5.7 mm demonstrates good diagnostic accuracy for intracranial hypertension (sensitivity ~85–95% and specificity ~75–90%), while the ONSD/eyeball transverse diameter (ETD) ratio >0.25 offers improved standardization and diagnostic performance (sensitivity ~90–95% and specificity ~85–93%).[10] Bedside ONSD ultrasonographic assessment may support early recognition of intracranial hypertension and help determine LP safety; however, it does not replace neuroimaging or clinical judgment.

Magnetic resonance imaging (MRI) of brain with contrast is more sensitive and is preferred when available, particularly for detecting common features of TBM such as leptomeningeal enhancement, tuberculomas, encephalitic changes, infarcts, ventriculitis, and basal exudates[2,4] **(Figs. 1A and B)**.

After contraindications are ruled out, a LP was performed. CSF findings suggested a chronic meningitic process.

Q11. What CSF investigations should be performed in suspected meningitis and meningoencephalitis, and how are they interpreted?

Once LP is considered safe and not contraindicated, the first essential parameter is the measurement of opening pressure (in the lateral decubitus position). Raised opening pressure suggests cryptococcal meningitis, TBM, severe bacterial meningitis, or obstructive hydrocephalus.[2,4]

Routine CSF studies should include total and differential count, protein, and glucose. Neutrophilic pleocytosis suggests bacterial meningitis, while lymphocytic pleocytosis is more typical of TBM, viral, or fungal infections. Bacterial meningitis is characterized by markedly elevated protein levels and low glucose levels. Viral infections often present with normal glucose and mild protein elevation. TBM shows lymphocytic predominance, very high protein levels, and low glucose levels.[2,4,7]

Microbiological testing includes Gram, Ziehl-Neelsen, and fungal staining. Bacterial, fungal, mycobacterial culture, and cryptococcal antigen when relevant. Molecular diagnostics such as multiplex polymerase chain reaction (PCR) (VZV, CMV, enteroviruses, and neurotropic viruses), HSV PCR, GeneXpert Mycobacterium tuberculosis/Rifampicin (Xpert MTB/RIF) Ultra, and other pathogen-specific assays may improve test yield. CSF lactate is used to distinguish bacterial from aseptic meningitis (≥4.2 mmol/L favors bacterial infection).[2] Elevated CSF Adenosine Deaminase (ADA) concentrations are not specific for TBM and have a weak recommendation for use in the diagnosis of TBM.[6,7]

In molecular assays, GeneXpert MTB/RIF (sensitivity 60–80% and specificity 90–100%), a World Health Organization (WHO)-endorsed real-time PCR–based assay,

JAYPEE BROTHERS

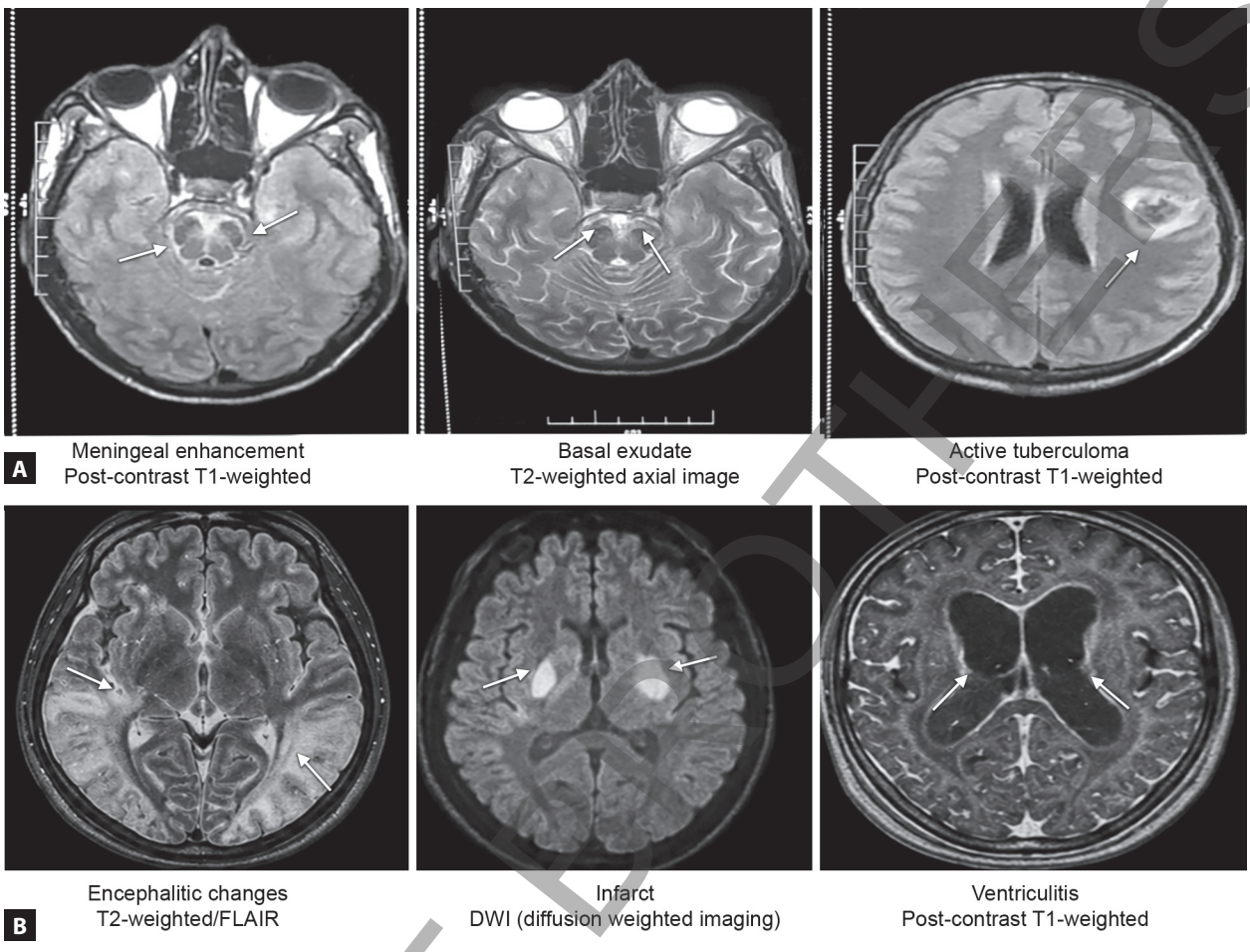

Figs. 1A and B: MRI findings of tuberculous meningitis.

enables rapid detection of *M. tuberculosis* and rifampicin resistance directly from CSF samples. Conventional GeneXpert demonstrates high specificity with moderate sensitivity. Diagnostic yield improves when large volumes of the last collected tube CSF samples are centrifuged (>6 mL at 3,000 g for 20 minutes). A second-generation molecular assay, Xpert MTB/RIF Ultra (sensitivity 85–95% and specificity 90–98%), targeting multicopy genes, offers higher sensitivity, particularly in paucibacillary TBM, and is now preferred for rapid diagnosis.[4,7,10]

Molecular assays are considered primarily as "rule-in" tests (a negative result does not exclude TBM), and treatment should not be delayed in clinically suspected cases. CSF analysis provides definitive diagnostics in meningitis **(Table 2)**, integrating cytological, microbiological, biochemical, and molecular data to identify the pathogen, guide therapy, and improve neurological outcomes.[1,2,4,7]

Based on the clinical presentation, CSF profile, and neuroimaging findings, TBM was strongly suspected.

Q12. What is the role of EEG and neuroimaging in the evaluation of CNS infections?

EEG is useful in CNS infections, particularly for detecting nonconvulsive seizures and nonconvulsive status epilepticus in ICU patients. Generalized slowing reflects diffuse cortical dysfunction, while focal temporal abnormalities and periodic lateralized epileptiform discharges may suggest herpes simplex encephalitis.[2,5]

Contrast-enhanced CT and MRI commonly demonstrate basal meningeal enhancement, hydrocephalus, infarcts, and tuberculomas.[4,11] Basal meningeal enhancement on contrast CT has been reported to have a sensitivity of approximately 85–90% and a specificity of 90–95% in some pediatric studies, although sensitivity is substantially lower in adults and in early-stage disease.

JAYPEE BROTHERS

TABLE 2: Characteristic cerebrospinal fluid (CSF) profiles in bacterial, tuberculous, viral, and fungal meningitis.

Parameters (normal values)	*Bacterial meningitis*	*Tuberculous meningitis*	*Viral meningitis*	*Fungal meningitis*
Opening pressure (10–20 cmH_2O)	↑↑	↑	Normal/↑	↑
Appearance (Clear)	Turbid	Clear/slightly opalescent, straw color	Clear	Clear/slightly cloudy
Cells (0–5 cells/µL, lymphocytes)	200–20,000 cells/µL (0.2–20 × 109/L) polymorphonuclear neutrophils	100–1,000 cells/µL (0.1–1.0 × 109/L), mostly lymphocytes	25–2,000 cells/µL (0.025–2.0 × 109/L), mostly lymphocytes	100–1,000 cells/µL (0.1–1.0 × 109/L), mostly lymphocytes
Protein (15–45 mg/dL)	Markedly ↑	Markedly ↑↑	Mild–moderate ↑	Mild–moderate ↑
Glucose (40–70 mg/dL or ~60% of serum glucose)	↓ (<40 mg/dL)	↓ (often very low)	Normal	↓
Chloride (118–132 mEq/L)	Normal or ↓	↓(classically low)	Normal	Normal or ↓
Lactate (1.1–2.4 mmol/L)	↑ (>3.5 mmol/L)	↑	Normal	↑/Normal
ADA (<5–10 U/L)	Normal	↑ (>10 U/L supportive)	Normal	Normal/↑ (mild)
Microbiology (Sterile)	Gram stain positive, culture positive	AFB stain, CBNAAT, culture	PCR positive	India ink, cryptococcal antigen

(ADA: adenosine deaminase; CBNAAT: cartridge-based nucleic acid amplification test; PCR: polymerase chain reaction)

TABLE 3: Antitubercular drugs: Adult dosage, cerebrospinal fluid (CSF) penetration, duration, and adverse effects.

Drug	*Usual adult dose in tuberculous meningitis (TBM)*	*Approximate CSF penetration*	*Recommended duration*	*Major adverse effects*
Rifampicin	10 mg/kg/day (maximum 600 mg/day)	Low–moderate (10–20%)	Entire treatment course (12 months)	Hepatitis, flu-like syndrome, thrombocytopenia, potent drug interactions, and orange-red discoloration of body fluids
Isoniazid	5 mg/kg/day (maximum 300 mg/day)	Excellent (80–90%)	Entire treatment course (12 months)	Hepatitis, peripheral neuropathy, encephalopathy, seizures, lupus-like reaction, and pyridoxine deficiency
Pyrazinamide	20–25 mg/kg/day	Excellent (90–100%)	Initial intensive phase (first 2 months)	Hepatotoxicity, hyperuricemia, arthralgia, and gastrointestinal intolerance
Ethambutol	15–20 mg/kg/day	Variable/moderate (20–30%)	Initial intensive phase (first 2 months)	Optic neuritis, impaired red-green color vision, and visual blurring
Moxifloxacin/ Levofloxacin	Moxifloxacin 400 mg/ day; levofloxacin 750–1,000 mg/day	Good (70–80%)	Individualized	QT prolongation, tendinopathy, dysglycemia, and central nervous system (CNS) irritability
Amikacin	15 mg/kg/day IV/IM	Low (10–20%)	Intensive phase only	Nephrotoxicity, ototoxicity, and electrolyte disturbances
Kanamycin	15 mg/kg/day IV/IM	Low (10–20%)	Intensive phase only	Nephrotoxicity and ototoxicity
Capreomycin	15 mg/kg/day IM/IV	Poor/limited data	Intensive phase only	Nephrotoxicity, electrolyte abnormalities, and ototoxicity
Ethionamide/ Prothionamide	15–20 mg/kg/day	Excellent (80–90%)	Throughout treatment	Severe gastrointestinal intolerance, hypothyroidism, hepatotoxicity, and neurotoxicity

Contd…

JAYPEE BROTHERS

Contd…

Drug	*Usual adult dose in tuberculous meningitis (TBM)*	*Approximate CSF penetration*	*Recommended duration*	*Major adverse effects*
Cycloserine	10–15 mg/kg/day (maximum 1 g/day)	Excellent (80–90%)	Throughout treatment	Depression, psychosis, seizures, and peripheral neuropathy
Linezolid	600 mg/day	Moderate–good (30–70%)	Individualized	Bone marrow suppression, optic neuropathy, peripheral neuropathy, and lactic acidosis
Clofazimine	100–200 mg/day	Limited data	Individualized	Skin discoloration, gastrointestinal intolerance, and QT prolongation
Para-aminosalicylic acid (PAS)	8–12 g/day	Poor/limited data	Individualized	Severe gastrointestinal intolerance, hypothyroidism, and hepatotoxicity
Bedaquiline	400 mg daily for 2 weeks, then 200 mg thrice weekly	Limited/uncertain CNS penetration	Individualized	QT prolongation, hepatotoxicity, and arthralgia
Delamanid	200 mg/day	Limited data	Individualized	QT prolongation, nausea, and dizziness

The combination of hydrocephalus, basal enhancement, and infarction increases specificity to nearly 95–100%, but overall sensitivity remains limited (~40%), because these findings may be absent early in the disease.[11]

Magnetic resonance imaging with contrast is more sensitive than CT and is preferred whenever possible for detecting leptomeningeal enhancement, small tuberculomas, brainstem involvement, and early ischemic infarcts, particularly with gadolinium-enhanced and diffusion-weighted imaging. However, normal neuroimaging does not exclude TBM, as up to 30% of early TBM cases may have normal CT scans and nearly 15% may initially have normal MRI findings.[11]

In view of clinical, radiological, and CSF findings, the patient was managed as a case of TBM.

Q13. What is the recommended treatment approach once TBM is suspected?

Once TBM is strongly suspected, treatment should begin immediately, even if microbiological confirmation is still pending. Delayed treatment is associated with poor neurological outcome and high mortality.[6,7]

Current WHO guidelines recommend a 12-month anti-tubercular therapy (ATT) regimen for adult TBM, as available evidence does not support modifying the duration of therapy. Standard ATT consists of an intensive phase (2 months) with four drugs: Isoniazid, rifampicin, pyrazinamide, and ethambutol. This is followed by a continuation phase (10 months) with isoniazid and rifampicin. The recommended doses and frequencies for TBM treatment are the same as for pulmonary tuberculosis.[6,7,11]

For drug-susceptible TBM, the WHO recommends first-line therapy with rifampicin, isoniazid, pyrazinamide, and ethambutol. The pharmacological characteristics, CSF penetration, treatment duration, and major adverse effects of commonly used antitubercular drugs are summarized in **Table 3**.[11]

In patients with MDR-TBM, therapy should be individualized according to molecular and culture-based drug susceptibility testing. Current WHO recommendations favor all-oral regimens incorporating agents with good CNS penetration, particularly fluoroquinolones (moxifloxacin/levofloxacin), linezolid, bedaquiline, cycloserine, and other second-line ATT.[4,7,11]

Patients should also be monitored for paradoxical reactions (immune-mediated inflammatory exacerbation), which are generally managed by optimizing corticosteroid therapy rather than altering ATT.[4]

Despite initiation of therapy, the patient showed evidence of raised ICP and ongoing inflammation.

Q14. What is the role of adjunctive corticosteroids in CNS infections, and specifically in TBM?

In TBM, neurological damage results from the inflammatory response rather than solely from the pathogen. TBM

JAYPEE BROTHERS

produces a robust inflammatory exudative response at the basal cisterns. Multiple clinical trials and systematic reviews have shown that adjunctive corticosteroid therapy significantly reduces meningeal inflammation, limits exudate formation, decreases cerebral edema, improves cerebral perfusion, and reduces mortality in TBM, particularly in patients with moderate-to-severe disease.[1,2,4,7]

Commonly used regimens include dexamethasone 0.3–0.4 mg/kg/day, weaned over 6–8 weeks, or prednisone 2 mg/kg/day (maximum 60 mg/day) for 4 weeks, followed by a 2–4- week tapering period, unless a clinical contraindication exists. The duration and tapering schedule can be individualized based on clinical response, severity at presentation, and the presence of complications.[6]

Despite their benefits, corticosteroids require careful monitoring for adverse effects, including hyperglycemia, secondary infections, gastrointestinal bleeding, proximal myopathy, and delayed wound healing, particularly in critically ill ICU patients.

Q15. What is the management approach for raised ICP and hydrocephalus in TBM?

Hydrocephalus is the most common cause of elevated ICP, and they are among the most frequent and life-threatening complications of TBM. If raised ICP is suspected, immediate measures such as head-end elevation to 15–30°, maintenance of neutral neck alignment to avoid venous obstruction, adequate sedation and analgesia, strict normothermia, and correction of hypoxia or hypercapnia should be instituted to prevent cerebral herniation.[2]

Osmotherapy with mannitol (0.25–1 g/kg IV bolus) or hypertonic saline is commonly used to control acute rise in ICP. Recent evidence favors hypertonic saline due to sustained ICP reduction, a lower risk of hypovolemia, and simultaneous correction of TBM-associated hyponatremia. Brief hyperventilation ($PaCO_2$ 30–35 mm Hg) may be considered only as a rescue measure in impending herniation while definitive management is arranged.[1,2]

Hydrocephalus may be communicating or noncommunicating and often manifests clinically with worsening sensorium, persistent vomiting, papilledema, sixth nerve palsy, pupillary abnormalities, Cushing response, or progressive decline in GCS. Hydrocephalus may initially be managed medically in selected cases with acetazolamide (a carbonic anhydrase inhibitor that reduces CSF production by inhibiting choroid plexus carbonic anhydrase activity), particularly when communicating hydrocephalus is present, though its benefit is often temporary. Persistent hydrocephalus, worsening GCS, or failure of medical therapy necessitates neurosurgical CSF diversion through external ventricular drainage, ventriculoperitoneal shunting, or endoscopic third ventriculostomy in selected cases.[6,7]

The patient does not show any seizure activity but is at risk for seizure activity due to persistent cortical irritation and hydrocephalus.

Q16. What is the role of prophylactic antiepileptic therapy in TBM?

Seizures in TBM may result from cortical irritation due to meningeal inflammation, tuberculomas, cerebral infarction, hydrocephalus, or metabolic disturbances. Overt convulsive and nonconvulsive seizures may occur, the latter often remaining clinically unrecognized in mechanically ventilated or sedated ICU patients.[2,4]

Regarding prophylactic antiepileptic therapy, it is not routinely recommended for all patients with TBM. Current practice supports individualized prophylaxis based on risk stratification. Prophylactic antiepileptic therapy should be strongly considered in patients with high-risk features (cortical involvement, tuberculomas, cerebral infarction, hydrocephalus with raised ICP, prior seizure episodes, evidence of cortical irritation, or epileptiform activity on EEG). These patients have a substantially higher mortality risk and poorer neurological outcomes.[4-6]

Levetiracetam or brivaracetam is generally preferred in the ICU because of its favorable pharmacokinetic profile, minimal hepatic metabolism, lack of significant interactions with ATT, ease of intravenous administration, and low sedative burden. This is particularly important, because enzyme-inducing antiepileptic drugs such as phenytoin and carbamazepine may interact with rifampicin, complicating TBM treatment.[6,7]

When seizures occur, treatment follows standard protocols, beginning with benzodiazepines (e.g., lorazepam) followed by second-line antiepileptic agents, while simultaneously correcting precipitating factors.[2,4,5]

Long-term ATT was planned, with close biochemical monitoring.

Q17. How should ATT-induced hepatotoxicity be recognized and managed?

Baseline liver function testing is recommended before ATT initiation, followed by regular monitoring, particularly during the intensive phase.

JAYPEE BROTHERS

Antitubercular therapy-induced hepatotoxicity should be suspected in a patient who develops nausea, vomiting, anorexia, malaise or fatigue, jaundice, or dark urine. Hepatotoxicity is typically defined as serum Alanine Aminotransferase (ALT) and Aspartate Aminotransferase (AST) levels elevation greater than 3 times the upper limit of normal with symptoms, or greater than 5 times the upper limit of normal without symptoms, or serum bilirubin exceeding 2 mg/dL. Pyrazinamide (the most hepatotoxic), isoniazid, and rifampicin are the principal causative agents. In ATT-induced liver dysfunction, hepatotoxic agents should be withheld, and an alternative regimen modified to include ethambutol, streptomycin, and a fluoroquinolone such as levofloxacin or moxifloxacin should be initiated. At this stage, TB treatment must not be completely stopped. This temporary regimen maintains antimycobacterial coverage while allowing hepatic recovery.[4,7]

Liver function tests should be monitored serially until normalization. Once transaminases fall to near-baseline levels and clinical symptoms resolve, first-line drugs are reintroduced sequentially, typically starting with rifampicin, followed by isoniazid, to identify the offending agent.[7] If hepatotoxicity recurs following reintroduction, the offending drug should be permanently discontinued and an alternative longer regimen designed using second-line agents under expert guidance.[4,7]

Table 3 lists the adult dosage, CSF penetration, duration, and adverse effects of various antitubercular drugs.

During the ICU stay, serial assessments were performed to evaluate the response to therapy.

Q18. How is therapeutic response monitored in patients with TBM?

Therapeutic response is assessed through clinical improvement, laboratory trends, and neuroimaging, as response is often slow and may be confounded by paradoxical reactions.

- *Clinical parameters (most important):* Clinical recovery is the most reliable indicator of treatment response and is characterized by improvement in sensorium/GCS, defervescence (resolution of fever), reduction in headache, vomiting, and meningism, stabilization or improvement of focal neurological deficits (cranial nerve palsies and hemiparesis), reduction in seizures or absence of new-onset seizures, and improvement in signs of raised ICP.[2,4]
- *Laboratory parameters:* CSF parameters improve slowly and lag behind clinical response in the form of decreasing CSF protein levels, rising CSF glucose (toward normal), reduction in CSF lymphocytic pleocytosis, sterilization of CSF (culture/PCR usually becomes negative early in therapy but is not used for serial monitoring), and inflammatory markers (Erythrocyte Sedimentation Rate/CRP) may decline but are nonspecific.[2]
- *Radiological parameters:* Radiological improvement is delayed and may initially show paradoxical worsening. Improvement is marked by a reduction in basal meningeal enhancement on contrast MRI, a decrease in size/number of tuberculomas, resolution, or improvement of hydrocephalus, and a decrease in perilesional edema and exudates, evolution, or stabilization of infarcts (established infarcts may persist permanently).[4]

The patient was doing well and clinically improved for 3 days; thereafter, the patient's consciousness declined without features of raised ICP. Laboratory evaluation revealed hyponatremia with a serum sodium level of 121 mEq/L.

Q19. What complications should be anticipated and monitored in TBM?

Cerebral salt wasting (CSW) and syndrome of inappropriate antidiuretic hormone secretion (SIADH) are common etiology for the development of hyponatremia in TBM (incidence is around 40–50%). SIADH is usually characterized by euvolemia or mild hypervolemia and is traditionally managed with fluid restriction, whereas CSW shows hypovolemia and requires saline and salt replacement. Management requires close monitoring of serum sodium, fluid balance, urine output, and volume status. Treatment includes saline and oral salt (10–12 g salt/day), while 3% saline should be used in severe hyponatremia with coma and seizure. In refractory cases of CSW, fludrocortisone helps in early normalization of serum sodium. V2 receptor antagonist conivaptan or tolvaptan may be used in SIADH if the patient does not responding to fluid restriction.[11,12]

Other major neurological complications include hydrocephalus, raised ICP, cerebral infarction, seizures, cranial nerve palsies, tuberculomas, and cognitive dysfunction. Cerebral vasculitis and vasculopathy may lead to ischemic stroke, particularly involving the basal ganglia and internal capsule, resulting in hemiparesis and focal neurological deficits.[4,12]

JAYPEE BROTHERS

Critically ill patients may additionally develop secondary infections, malnutrition, acute kidney injury, and ATT-related drug toxicities.

Despite treatment, TBM carries a poor prognosis, with mortality approaching 20–30%, particularly in advanced disease and HIV coinfection. Among survivors, epilepsy, hearing loss, visual impairment, motor deficits, and persistent neurocognitive dysfunction (memory, executive function, and processing speed) persist, highlighting the importance of prolonged neurological rehabilitation.[4,6,12]

Following stabilization, plans were made for the patient to be transferred out of the ICU for long-term neurological recovery.

Q20. What is the role of rehabilitation and long-term follow-up in survivors of TBM?

Early neurorehabilitation (physiotherapy, occupational therapy, speech therapy, and cognitive rehabilitation) improves functional recovery. Long-term follow-up should include assessment of neurological status, seizure control, nutritional rehabilitation, treatment adherence, and a search for delayed complications such as shunt malfunction or recurrent hydrocephalus.

CONCLUSION

Once TBM is suspected, therapy must be rapidly tailored through early initiation of ATT, adjunctive corticosteroids, complication-directed neurocritical care, toxicity surveillance, and individualized adjustment of the treatment plan based on organism resistance pattern. Early aggressive intervention by a multidisciplinary team involving intensivists, neurologists, infectious disease specialists, and neurosurgeons is essential for optimizing neurological recovery and reducing long-term disability. The key practical Do's and Don'ts in the management of TBM are summarized below.

LIST OF DOs AND DON'Ts

DOs	*DON'Ts*
Start ATT immediately when TBM is strongly suspected	Do not delay empiric ATT while awaiting microbiological confirmation of diagnosis
Use adjunctive corticosteroids routinely in noncontraindicated patients	Do not stop ATT completely during drug toxicity unless absolutely unavoidable
Aggressively monitoring and management of raised ICP and hydrocephalus	Do not perform LP without assessing for raised ICP in selected high-risk patients

Contd…

Contd…

DOs	*DON'Ts*
Perform structured neurocritical care monitoring (GCS, pupils, electrolytes, seizures, imaging, ONSD, and ONSD/ETD)	Do not rely on a negative molecular test (e.g., Xpert/Ultra) to exclude TBM
Recognize and manage paradoxical inflammatory reactions	Do not underestimate hyponatremia and electrolyte disturbances

REFERENCES

1. Tunkel AR, Hartman BJ, Kaplan SL, Kaufman BA, Roos KL, Scheld WM, et al. Practice guidelines for the management of bacterial meningitis. Clin Infect Dis. 2004;39(9):1267-84.
2. Roos KL. Central nervous system infections. In: Jameson JL, Fauci AS, Kasper DL, Hauser SL, Longo DL, Loscalzo J (Eds). Harrison's Principles of Internal Medicine, 22nd edition. New York: McGraw Hill; 2025.
3. National Institute for Health and Care Excellence. Meningitis (bacterial) and meningococcal disease: recognition, diagnosis and management. London: NICE; 2024.
4. Thwaites GE, van Toorn R, Schoeman J. Tuberculous meningitis: more questions, still too few answers. Lancet Neurol. 2013;12(10):999-1010.
5. Brophy GM, Bell R, Claassen J, Alldredge B, Bleck TP, Glauser T, et al.; Neurocritical Care Society Status Epilepticus Guideline Writing Committee. Guidelines for the evaluation and management of status epilepticus. Neurocrit Care. 2012;17(1):3-23.
6. Donovan J, Cresswell F, Tucker E, Davis AG, Rohlwink UK, Huynh J, et al. A clinical practice guideline for tuberculous meningitis. Lancet Infect Dis. 2026;26:e96-e111.
7. World Health Organization. WHO consolidated guidelines on tuberculosis. Module 4: treatment and care. Geneva: World Health Organization; 2025.
8. van de Beek D, Brouwer MC, Hasbun R, Koedel U, Whitney CG, Wijdicks E. Community-acquired bacterial meningitis. Nat Rev Dis Primers. 2016;2:16074.
9. Perfect JR, Dismukes WE, Dromer F, Goldman DL, Graybill JR, Hamill RJ, et al. Clinical practice guidelines for the management of cryptococcal disease: 2010 update by the Infectious Diseases Society of America. Clin Infect Dis. 2010;50(3):291-322.
10. Robba C, Santori G, Czosnyka M, Corradi F, Bragazzi N, Padayachy L, et al. Optic nerve sheath diameter measured sonographically as non-invasive estimator of intracranial pressure: a systematic review and meta-analysis. Intensive Care Med. 2018;44(8):1284-94.
11. Misra UK, Kalita J; Tuberculous Meningitis International Research Consortium. Mechanism, spectrum, consequences and management of hyponatremia in tuberculous meningitis. Wellcome Open Res. 2021;4:189.
12. Wilkinson RJ, Rohlwink U, Misra UK, van Crevel R, Mai NTH, Dooley KE, et al.; Tuberculous Meningitis International Research Consortium. Tuberculous meningitis. Nat Rev Neurol. 2017;13(10):581-98.

JAYPEE BROTHERS

for detailed information on critical care books, visit our website www.ejaypee.com, for detailed information on critical care books, visit our website www.ejaypee.com, for detailed i

CRITICAL CARE PEARLS

CASE-BASED DISCUSSIONS

Highlights

- 51 real-world ICU cases with evidence-based solutions
- Authored by leading DM/DrNB critical care faculty
- Stepwise management aligned with the latest international guidelines
- Question-and-answer format for rapid learning and easy recall
- Clinical pearls that bridge theory and bedside practice
- Richly illustrated with attractive, full-color figures and flowcharts
- Every chapter begins with high-yield infographics
- Practical, concise, and focused on real ICU decision-making
- Key learning points at a glance for quick revision
- Essential DOs and DON'Ts at the end of every chapter
- Guideline-driven management with practical bedside insights
- From presentation to discharge, every step explained clearly.



Soumya Sankar Nath MD PDCC PGDHHM FACEE is a Professor of Anesthesia and Critical Care Medicine, Dr Ram Manohar Lohia Institute of Medical Sciences, Lucknow, Uttar Pradesh, India. An alumnus of the Institute of Medical Sciences, Banaras Hindu University (IMS-BHU), Varanasi, and Sanjay Gandhi Postgraduate Institute of Medical Sciences (SGPGIMS), Lucknow, he is an accomplished Clinician, Academician, Researcher, and Innovator with over two decades of experience in anesthesia and critical care.

Critical Care Pearls: Case-based Discussions is his fifth book and third in the field of Critical Care Medicine. His previous books, *Handbook of Critical Care* and *Critical Care Perspectives: From Bench to Bedside*, have been widely appreciated by the critical care community for their practical and evidence-based approach.

He has authored over 70 publications in peer-reviewed indexed journals and contributed more than 50 book chapters. He also holds four patents and is a Training Centre Faculty of the American Heart Association (AHA) for Basic Life Support (BLS) and Advanced Cardiovascular Life Support (ACLS) courses. His academic interests include critical care, medical education, clinical research, and innovation in health care.



Ranvir Singh Tyagi MD FICCM FCCM is a distinguished Anesthesiologist, Intensivist, Educator, and Academician with over 25 years of experience in critical care medicine. He obtained his MD in Anesthesiology from SMS Medical College, Jaipur, in 2000 and has since made significant contributions to critical care education, research, and clinical practice. He is presently the Director of Department of Anesthesia and Critical Care Medicine at Synergy Plus and Galaxy Hospital, Agra, Uttar Pradesh, India. A dedicated Teacher, he has mentored numerous DNB (Anesthesiology) trainees and served as a Faculty Member for the Indian Diploma in Critical Care Medicine (IDCCM) program at Synergy Plus Hospital for more than a decade. He has delivered over 500 national and 25 international invited lectures, reflecting his commitment to disseminating evidence-based critical care practices. He had edited the ISCCM Manual of Critical Care Nursing. He has authored more than 25 book chapters, edited four academic books, published 15 research papers in reputed indexed journals, and has been a member of five National Guideline Committees, contributing to the development of standards in critical care practice. He is the Chancellor of the Indian Society of Critical Care Medicine (ISCCM).

Shelving Recommendation
CRITICAL CARE

ISBN 978-81-68052-96-3

Buy from ejaypee

JAYPEE BROTHERS

NOT FOR SALE