site www.ejaypee.com, for detailed information on dental books, visit our website www.ejaypee.com, for detailed information on dental books, visit our website www.ejaypee.com,

Thoroughly revised multiple choice questions and fill in the blanks according to the latest syllabus of NDC

Includes 2026 Papers

Mastering the BDS IVth Year-I

11th Edition

Last 15 Years Solved Questions

Image-based Questions as per NEET-MDS & INI-CET Examination

- Oral Medicine
- Oral Radiology
- Orthodontics
- Periodontics
- Public Health Dentistry



Hemant Gupta

JAYPEE

JAYPEE BROTHERS

Contents

Section 1: Oral Medicine

1. Investigations in Dentistry 3
2. Developmental Disorders of Teeth and Jaw 6
3. Keratotic and Nonkeratotic White Lesions 7
4. Oral Premalignant Lesions and Conditions 7
5. Cysts of Jaw 19
6. Odontogenic Tumors 25
7. Benign Tumor of Jaws (Nonodontogenic) 31
8. Malignant Tumors of Jaws 32
9. Vesicular, Bullous and Ulcerative Lesions 39
10. Orofacial Pain 48
11. Infections of Oral Cavity and Oral Sepsis 56
12. Oral Pigmentation 58
13. Diseases of Tongue 64
14. Diseases of Dental Pulp 67
15. Gingival and Periodontal Diseases 68
16. Temporomandibular Joint Disorders 70
17. Salivary Gland Disorders 78
18. Disorders of Maxillary Sinus 86
19. Bacterial Infections of Oral Cavity 87
20. Fungal Infections 88
21. Viral Lesions 91
22. Specific System Disorders 97
23. Disease of Bone Manifested in the Jaws and Fibro-osseous Lesions 100
24. Acquired Immunodeficiency Syndrome (AIDS) 104
25. Endocrine Disorders 107
26. Blood Disorders 110
27. Forensic Odontology 116
28. Drugs Used in Dentistry 117
29. Miscellaneous 120

Multiple Choice Questions as per NDC and Examination Papers of Various Universities 123

Fill in the Blanks 132

Additional Information 135

Various Important Classifications 147

One Liner (Knowledge Enhancers) 160

Section 2: Oral Radiology

1. Properties of X-ray 167
2. Production of X-ray 169
3. Radiation Biology 176
4. Protection from Radiation 183
5. Ideal Radiography 187
6. Faulty Radiograph 188
7. X-ray Films and Accessories 193
8. Processing of X-ray Films 197
9. Intraoral Radiographic Techniques 203
10. Extraoral Radiographic Techniques 216
11. Panoramic Radiography or Orthopantomography (OPG) 222
12. Specialized Radiographic Techniques 225
13. Magnetic Resonance Imaging (MRI) 231
14. Digital Radiography 233
15. Normal Anatomy of Intraoral and Extraoral Radiographs 238
16. Differential Diagnosis of Periapical Radiolucencies 240
17. Radiographic Diagnosis of Pathology Affecting the Jaws 247

Multiple Choice Questions as per NDC and Examination Papers of Various Universities 252

Fill in the Blanks 258

Additional Information 260

One Liner (Knowledge Enhancers) 264

Section 3: Orthodontics

Development of Concept

1. Introduction to Orthodontics 269

Growth and Development

2. Growth and Development: General Principles and Concepts 271
3. Growth and Development of Cranial and Facial Region 282

JAYPEE BROTHERS

4. Development of Dentition and Occlusion 287
5. Functional Development 297

Development of Problems

6. Occlusion: Basic Concepts 301
7. Classification of Malocclusion 302
8. Etiology of Malocclusion 307
9. Habits 310
10. Epidemiology of Malocclusion 317

Diagnosis

11. Orthodontic Diagnosis 317
12. Cephalometrics 327
13. Skeletal Maturity Indicators 336
14. Model Analysis 339

Biology, Mechanics and Orthodontic Materials

15. Biology of Tooth Movement 344
16. Mechanics of Orthodontic Tooth Movement 352
17. Anchorage in Orthodontics 355

Early Orthodontic Treatment

18. Preventive Orthodontics 361
19. Interceptive Orthodontics 366
20. Methods of Gaining Space 369
21. Arch Expansion as Method of Gaining Space 372

Orthodontic Appliances

22. Extractions 376
23. Removable Appliances 378
24. Fixed Appliances and Techniques 383
25. Myofunctional Appliances 389
26. Orthopedic Appliances 401

Corrective Orthodontics

27. Management of Some Common Malocclusions ... 404
28. Management of Class II Malocclusion 405
29. Management of Class III Malocclusion 412
30. Management of Open Bite and Deep Bite 416
31. Management of Crossbite 418

Surgical Consideration in Orthodontics

32. Management of Cleft Lip and Palate 421
33. Surgical Orthodontics 425

Miscellaneous

34. Retention and Relapse 428
35. Laboratory Procedures 433
36. Materials Used in Orthodontics 434
37. Genetic Factors in Orthodontics 436
38. Computers in Orthodontics 437

Multiple Choice Questions as per NDC and Examination Papers of Various Universities *439*

Fill in the Blanks *454*

Additional Information *458*

One Liner (Knowledge Enhancers) *470*

Section 4: Periodontics

1. The Normal Periodontium 477
2. Periodontal Structures in Aging Humans 492
3. Classification System of Periodontal Diseases 492
4. Epidemiology of Gingival and Periodontal Diseases 494
5. Periodontal Microbiology 495
6. Calculus and Other Etiological Factors Including Food Impaction 500
7. Trauma from Occlusion 505
8. Smoking and Periodontal Disease 510
9. Defense Mechanisms of Gingiva 512
10. Oral Malodor 512
11. Genetic Factors Associated with Periodontal Disease 514
12. Systemic Factors and Periodontium 515
13. Clinical Features of Gingivitis 516
14. Host Response: Basic Concept 522
15. Gingival Enlargement 523
16. Acute Gingival Infections 528
17. Periodontal Pocket 532
18. Bone Loss and Patterns of Bone Destruction 538
19. Chronic Periodontitis 542
20. Aggressive Periodontitis 544
21. Periodontal Abscess 550
22. Refractory Periodontitis 552
23. AIDS and the Periodontium 552
24. Periodontal Medicine and Influence of Systemic Disorders and Stress on the Periodontium 554
25. Examination and Diagnosis of Periodontal Diseases 559
26. Advanced Diagnostic AIDS 560
27. Risk Factors 565
28. Determination of Prognosis 567
29. Treatment Plan 571
30. Rationale for Periodontal Treatment 574
31. Host Modulation Therapy 575
32. Periodontal Instrumentation 576
33. Principles of Periodontal Instrumentation Including Scaling and Root Planing 580
34. Plaque Control 584
35. Ultrasonic Scaling 592
36. Principles of Periodontal Surgery 593
37. Gingival Surgical Techniques 597
38. Periodontal Flap 601
39. Resective Osseous Surgery 605

JAYPEE BROTHERS

40. Reconstructive Osseous Surgery 608
41. Mucogingival Surgery/Periodontal Plastic Surgery 616
42. Furcation Involvement and its Management 628
43. Splints in Periodontal Therapy 632
44. Endodontic–Periodontic Relationship 635
45. Perioprosthodontics/Occlusal Evaluation 637
46. Supportive Periodontal Therapy 638
47. Drugs used in Periodontal Therapy 639
48. Periodontal Restorative Inter-relationships 642
49. Recent Advances in Surgical Technology in Periodontics 643
50. Dental Implants 644

Multiple Choice Questions as per NDC and Examination Papers of Various Universities 648

Fill in the Blanks 673

Additional Information 674

One Liner (Knowledge Enhancers) 689

Section 5: Public Health Dentistry

Introduction

1. Introduction to Dentistry 697

Public Health and Dental Public Health

2. Public Health 700
3. Dental Public Health 710

Environment and Health

4. Water 712
5. Waste Management 718

Behavioral and Social Sciences

6. Social Sciences and Health Behavior 724
7. Behavior of Child in Dental Office 725

Epidemiology

8. General Epidemiology 728
9. Epidemiology, Etiology and Prevention of Dental Caries 741
10. Epidemiology, Etiology and Prevention of Periodontal Disease 753
11. Epidemiology, Etiology and Prevention of Oral Cancer 762
12. Epidemiology, Etiology and Prevention of Malocclusion 768

Preventive Dentistry

13. Health Education and Promotion 770
14. Nutrition and Oral Health 781
15. School Oral Health Program 783
16. Fluorides 790
17. Pit and Fissure Sealants 805
18. Atraumatic Restorative Treatment (ART) 807

Problem Solving

19. Survey Procedures in Dentistry 808
20. Planning and Evaluation 811

Case History and Indices

21. Indices in Dental Epidemiology 815

Provision of Health Care

22. Healthcare Delivery 823
23. Dental Manpower 833
24. Finance in Dental Care 838

Research Methodology and Biostatistics

25. Research Methodology and Biostatistics 843

Practice Management and Administration

26. Occupational Hazards in Dentistry 858
27. Infection Control in Dentistry 862
28. Establishing and Maintaining a Dental Office 863
29. Mobile Dental Clinics 865
30. Computers in Dentistry 865

Legal Issue in Health Care

31. Ethics in Medicine and Dentistry 867
32. Medical Jurisprudence 871

Miscellaneous

33. Miscellaneous 872

Multiple Choice Questions as per NDC and Examination Papers of Various Universities 886

Fill in the Blanks 904

Answer in a Sentence or a Word 908

Additional Information 909

One Liner (Knowledge Enhancers) 924

Image-based Questions 929

JAYPEE BROTHERS

IMAGE-BASED QUESTIONS
(Asked in NEET, AIIMS and PGI Postgraduate Entrance Examinations)

SECTION 1: ORAL MEDICINE

Q.1. Identify the anomalies present in the patient: *(AIIMS 2016)*

Or

Identify the tooth anomaly: *(AIIMS 2021)*

Or

Name the following clinical condition shown in the image below: *(AIIMS 2023)*



a. Fusion
b. Gemination
c. Concrescence
d. Twinning

Q.2. Linear defect in permanent dentition, as shown in the picture seen is: *(AIPG 2016)*



a. Chickenpox
b. Hypophosphatemia
c. HIV/AIDS
d. Caries

Q.3. The picture shown in figure is having which syndrome: *(AIPG 2016)*



a. Treacher Collins syndrome
b. Pierre Robin syndrome
c. Down syndrome
d. Apert syndrome

Q.4. All of the following can occur in the following syndrome given, *except*: *(AIIMS 2015)*



a. Hypertelorism
b. Crowding of teeth
c. Maxillary protrusion and mandibular retrognathism
d. *CBFA1* gene mutation

Q.5. The soft, fluctuating, translucent bluish lesion depicted in the below picture could be due to:



a. Hemangioma
b. Gingival cyst
c. Ranula
d. Mucocele

Q.6. This patient presented with dryness of mouth. On questioning, he was complaining of dry eyes also. His treatment modalities include all of the following, *except*:



a. Steroids
b. Pilocarpine
c. Artificial tears
d. Anticholinergics

Answers: **1. a** **2. a** **3. a** **4. c** **5. c** **6. d**

JAYPEE BROTHERS

Q.7. The below picture depicts which one of the following conditions:



a. Amyloidosis
b. Leukoplakia
c. Nicotinic stomatitis
d. Denture stomatitis

Q.8. The patient with the kind of lesion shown in the image has come with history of developing such ulcers repeatedly along with redness of eyes and scrotal ulcers. His treatment options include all of the following drugs, *except*:



a. Colchicine
b. Pentoxifylline
c. Pilocarpine
d. Thalidomide

Q.9. Identify the following condition shown in the image:



a. Sebaceous cyst
b. Ranula
c. Epidermoid cyst
d. Lingual varices

Q.10. Following dental condition can be seen in:



a. Congenital syphilis
b. Cleidocranial dysplasia
c. Marfan's syndrome
d. All of the above

Q.11. Identify the possible syndrome shown in figure:



a. Sturge-Weber syndrome
b. Rendu-Osler-Weber syndrome
c. Maffucci syndrome
d. Hemangioma

Q.12. Identify the following condition:

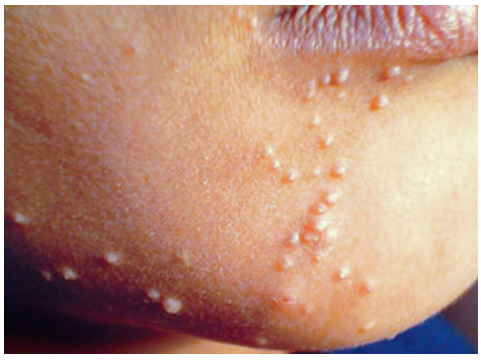

a. Condyloma latum
b. Mollascum contagiosum
c. Verrucous vulgaris
d. Condyloma acculamata

Answers: 7. c 8. c 9. b 10. a 11. a 12. b

JAYPEE BROTHERS

Q.13. The patient is not able to express from left side identify the anomaly (shown in image) of face:

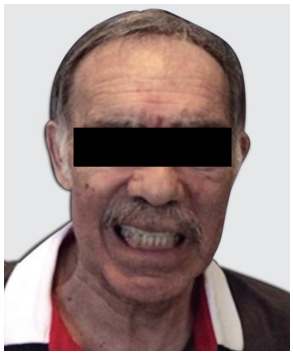

a. Left lower motor facial nerve palsy
b. Right lower motor facial nerve palsy
c. Left upper motor facial nerve palsy
d. Right upper motor facial nerve palsy

Q.14. A patient presenting with an ulcer surrounded by an erythematous halo in tonsillar area with a positive ELISA test, histologically showing intraepithelial acantholytic vesicle formation most likely could be: *(AIPG 2017)*

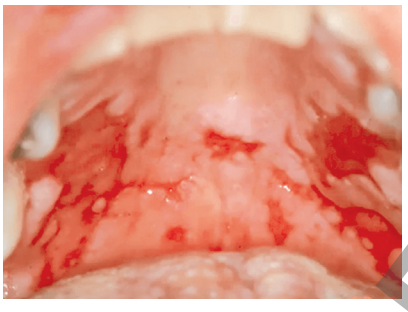

a. Cicatricial pemphigoid
b. Pemphigus vulgaris
c. Lupus erythematosus
d. Mucous membrane pemphigoid

Q.15. A young girl with lesion that peels on touch on left buccal mucosa presents with burning mouth on spicy food intake with histologic findings of suprabasilar cleft and acantholysis. What is the condition? *(AIIMS 2017)*

Or

A young girl with the lesion that peels on touch on left buccal mucosa presents with burning mouth on spicy food intake and bleeding from gingiva even on slight touch with histological findings of suprabasilar cleft and acantholysis. Which is the condition? *(AIIMS 2022)*

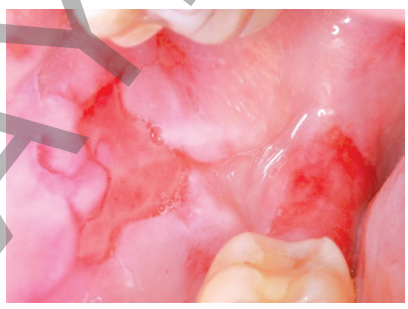

a. Pemphigus
b. Mucous membrane pemphigoid
c. Lichen planus
d. Erythema multiforme

Q.16. Female patient presents with red white lesion on tongue, burning on spicy food intake, red lesion disappear after burning subside. What is the condition? *(AIIMS 2017)*



a. Leukoplakia
b. Atrophic candidiasis
c. Erythematous lichen planus
d. Geographic tongue

Q.17. Identify the lesion shown in the image which is HMB 45 positive: *(AIIMS 2017)*



a. Malignant melanoma
b. Verrucous carcinoma
c. Squamous cell carcinoma
d. Minor salivary gland tumor

Q.18. Identify the lesion: *(AIIMS 2017)*



a. Hemangioma
b. Lymphangioma
c. Kaposi sarcoma
d. Squamous carcinoma

Answers: **13. a** **14. b** **15. a** **16. d** **17. a** **18. b**

JAYPEE BROTHERS

Q.19. Identify the condition given in following picture: *(AIIMS 2017)*



a. Transmigration
b. Transposition
c. Fusion
d. Torsiversion

Q.20. Identify the picture: *(AIPG 2019)*



a. Epulis fissuratum
b. Carcinoma
c. Leukoplakia
d. Cystic lesion

Q.21. Name the condition given in the image below, which is attributed to mutation in *ENAM* gene and seen radiographically as generalized thinning of enamel: *(AIIMS 2019)*



a. Osteogenesis imperfecta
b. Amelogenesis imperfecta
c. Dentinogenesis imperfecta
d. Fluorosis

Q.22. The condition (image) can be seen in all of the following syndromes, *except*: *(AIIMS 2019)*



a. Beckwith-Wiedemann syndrome
b. Pierre Robin syndrome
c. Fraser syndrome
d. Apert syndrome

Q.23. A 13-year-old patient came to dentist with complaint of less number of teeth. The clinical picture and radiographs are below (image). Describe the condition. *(AIIMS 2019)*



a. Cleidocranial dysplasia
b. Ectodermal dysplasia
c. Craniofacial fibrous dysplasia
d. Crouzon's syndrome

Answers: **19. b** **20. a** **21. b** **22. d** **23. b**

JAYPEE BROTHERS

Q.24. A 40-year-old male presented with painless lesion of the gingiva. His blood picture showed CD4 count <150. What could be the possible condition? *(AIPG 2020)*



a. Kaposi sarcoma
b. Ewing's sarcoma
c. Oral hairy leukoplakia
d. Lichen planus

Q.25. A 20-year-old female patient came with painless swelling in gingiva. She mentions that she is in first trimester of pregnancy. What could be the diagnosis? *(AIPG 2020)*



a. Pyogenic granuloma
b. Epulis
c. Fibroma
d. Pregnancy tumor

Q.26. A 40-year-old male complains of painless gradually increasing swelling in preauricular region with chromosome 8 involvement is: *(AIPG 2020)*



a. Pleomorphic adenoma
b. Warthin's tumor
c. Canalicular adenoma
d. Lymph duct blockage

Q.27. A 40-year-old medically compromised female patient came with swelling in the lower jaw, gives history of extraction of molar few days back. With tongue raised and difficulty in breathing and high grade fever. What is the diagnosis? *(AIPG 2020)*



a. Cellulitis
b. Ludwig's angina
c. Ranula
d. Laryngeal edema

Q.28. A child of 10th grade was having a painful ulcer on the lower lip. He had exams since 10 days. What could be the possible cause? *(AIPG 2020)*



a. Bacterial
b. Viral
c. Fungal
d. Parasitic

Q.29. Identify which of the following is seen in photograph: *(AIPG 2021)*



a. Bohn's nodule
b. Epstein pearls
c. Gingival cyst of newborn
d. Alveolar cyst

Answers: **24. a** **25. d** **26. b** **27. b** **28. b** **29. c**

JAYPEE BROTHERS

Q.30. Image showing periapical radiolucency on a radiograph of lower anteriors along with a draining sinus through the chin area. The diagnosis is: *(AIPG 2021)*

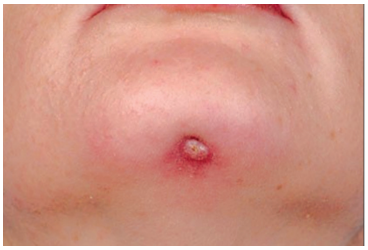
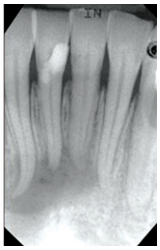

a. Acute alveolar abscess
b. Chronic alveolar abscess
c. Periapical granuloma
d. Periapical cemental dysplasia

Q.31. Identify the following condition: *(AIPG 2021)*



a. Supernumerary tooth
b. Dentinogenesis imperfecta
c. Hypomineralization
d. Enamel hypoplasia

Q.32. Small painless growth on tongue: *(AIPG 2021)*



a. Lipoma
b. Fibroma
c. Papilloma
d. Xanthoma

Q.33. Fibrous gingival overgrowth in upper left quadrant without bleeding. The diagnosis is: *(AIPG 2021)*



a. Pyogenic granuloma
b. Central ossifying fibroma
c. Solitary neurofibroma
d. Peripheral adamantinoma

Q.34. A patient visited a clinic with ulceration on lip area. She gives previous history of similar lesions. What is the most probable diagnosis? *(AIPG 2021)*



a. Recurrent herpes simplex
b. Recurrent aphthae
c. Recurrent herpetiform ulcers
d. Recurrent herpes zoster

Q.35. Premature exfoliation of anterior teeth and incomplete root formation: *(AIPG 2021)*


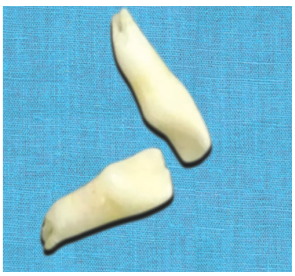

a. Hypophosphatasia
b. Cleidocranial dysplasia
c. Achondroplasia
d. Down's syndrome

Q.36. What is shown in the image? *(AIPG 2021)*

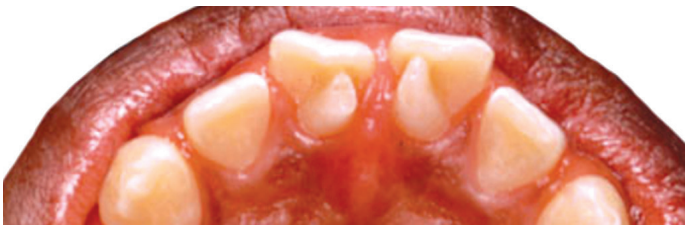

a. Trace talon
b. True talon/complete talon
c. Semi talon
d. Incomplete talon

Answers: 30. b 31. a 32. b 33. a 34. a 35. a 36. b

JAYPEE BROTHERS

Q.37. A patient comes with a complaint of swelling in the right lower posterior region. A thick cheesy material on aspiration along with the thin epithelial lining with corrugated surface. Identify the lesion: *(AIIMS 2022)*



a. OKC
b. Dentigerous cyst
c. Ameloblastoma
d. Myxoma

Q.38. A patient comes with the following radiograph with radiopaque thin radiolucent rim surrounding entire structure. Identify the lesion: *(AIIMS 2022, AIPG 2022)*



a. Cementoblastoma
b. Odontoma
c. Condensing osteitis
d. Hypercementosis

Q.39. In this image, cyst in the mandibular region is present, the adjacent canine and first premolar to cyst is vital. Identify the cyst:



a. Apical periodontal cyst
b. Radicular cyst
c. Botryoid odontogenic cyst
d. Gingival cyst

Q.40. There was a young male consisting of the calcification of falx cerebri and multiple radiolucent lesion present in maxilla and mandible. Identify the lesion: ***(AIPG 2022)***

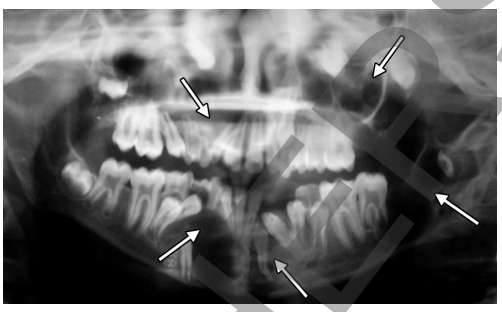

a. Nevoid basal cell carcinoma
b. Cherubism
c. Brown's tumor
d. Cleidocranial dysplasia

Q.41. A patient came with a complaint of swelling in inferior and lingual border of mandible. On examination premolar was grossly carious and is painless. There was no sign of fever and periosteum surrounding the premolar is not intact. What is the cause of the problem? *(AIPG 2022)*

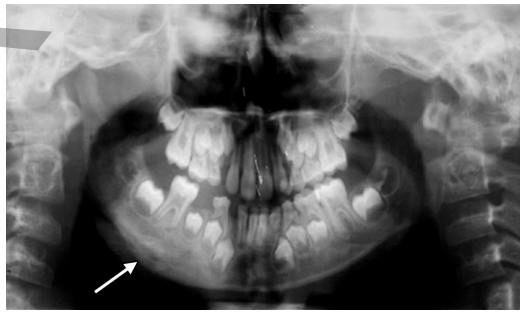

a. Garre's osteomyelitis
b. Osteosarcoma
c. Condensing osteitis
d. Fibrosarcoma

Q.42. Which of the following defect is shown in the radiograph? *(AIPG 2022)*

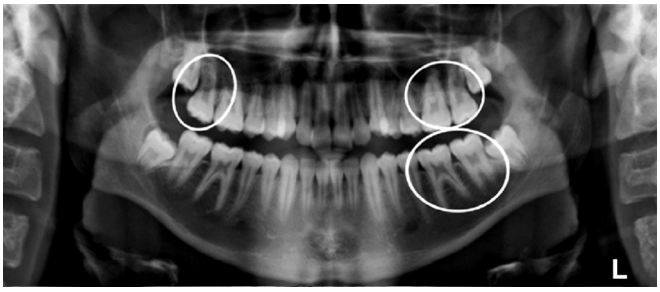

a. Taurodontism
b. Gemination
c. Concrescence
d. Dentine dysplasia

Answers: **37. a** **38. a** **39. c** **40. a** **41. a** **42. a**

JAYPEE BROTHERS

Q.43. Patient is experiencing sensitivity which diagnosis is shown in the radiograph: *(AIPG 2022)*



a. Talon cusp
b. Dens invaginatous
c. Dens evaginatus
d. Enamel pearl

Q.44. Patient said I have caries, on examination the dentist found an anomaly above the spices. Identify the structure: *(AIPG 2022)*

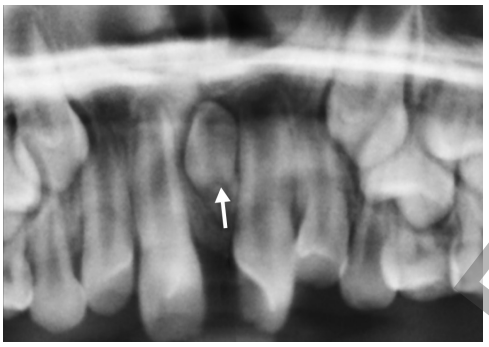

a. Paramolars
b. Mesiodens
c. Distodens
d. Peridens

Q.45. Identify the condition given in the below radiograph: *(AIIMS 2021)*

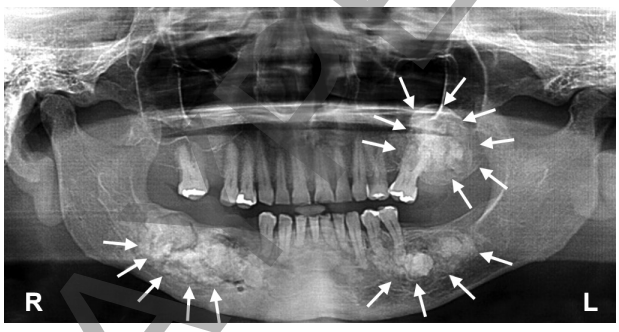

a. Cemento-osseous dysplasia
b. Florid osseous dysplasia
c. Fibrous dysplasia
d. Paget's disease

Q.46. A patient came with complaint of dull pain in lower left back region. He had history of trauma in same area from 2 years back. On radiograph, large radiolucent lesion is seen near the left lower premolar and extra-oral sinus drainage. Pulp vitality of that tooth is not done, but clinically, the tooth seems fine. What is the pathosis? *(AIIMS 2022)*



a. Lymph node obliteration
b. Chronic osteomyelitis
c. Periapical pathosis
d. Chronic osteitis

Q.47. Patient comes with pulsatile lesion on dorsum of tongue with lymphatic vessels enlarged and pinpoint blood vessels involved in the lesion. What is the diagnosis? *(AIIMS 2022)*

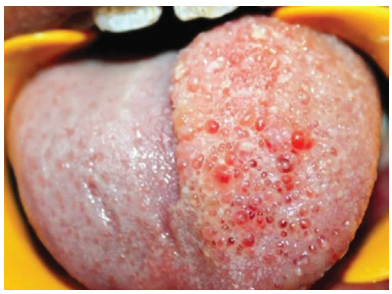

a. Hemangioma
b. Lymphangioma
c. Fibroma
d. Sarcoma

Q.48. A female patient comes to the OPD with bilateral buccal mucosa tree-like lesion with burning sensation. Patient takes medications for hypertension and diabetes. Identify the pathosis: *(AIIMS 2022)*





a. Grinspan syndrome
b. Burning mouth syndrome
c. Candidiasis
d. OSMF

Answers: **43. b** **44. b** **45. a** **46. b** **47. b** **48. a**

JAYPEE BROTHERS

Q.49. A patient is having a slow growing painless swelling from last 7 years below the ear, which is causing elevation of ear lobule and patient is having no discomfort. Identify this lesion: *(AIPG 2022)*



a. Pleomorphic adenoma
b. Lipoma
c. Warthin's tumor
d. Cold abscess

Q.50. What is the lesion present on tongue, as shown in the diagram? *(AIPG 2022)*



a. Verrucous carcinoma
b. Squamous cell carcinoma (SCC)
c. Verrucous hyperplasia
d. Fibroma

Q.51. A patient with history of smoking came to the clinic and on diagnosis, white nonscrapable patches were seen on buccal mucosa and tongue. Identify the lesion and treatment required: *(AIPG 2022)*



a. Homogenous leukoplakia, topical triamcinolone given
b. Homogenous leukoplakia, vitamin A (retinoic acid)
c. Pseudomembranous candidiasis, amphotericin B
d. Lichen planus, topical triamcinolone given

Q.52. A 4-year-old child showing crescent-shaped yellow and white discoloration on tooth when dried, it is: *(AIPG 2022)*



a. Incipient caries
b. Fluorosis
c. SCC
d. Rampant caries

Q.53. A pulsating granular lesion of tongue is shown in the image is: *(AIIMS 2021)*



a. Hemangioma
b. Lymphoma
c. Nodular leukoplakia
d. Erythroplakia

Q.54. Identify the image showing a nodular mass that is spreading in size from last 2 months with pain to the patient: *(AIPG 2022)*



a. Melanotic macule
b. Horizontal melanoma
c. Vertical melanoma
d. Amalgam tattoo

Answers: **49. a** **50. b** **51. b** **52. a** **53. a** **54. c**

JAYPEE BROTHERS

Q.55. A patient present with long standing swelling on left side of the face. Examination confirmed it to be a swelling associated with the parotid gland which is associated with uncontrolled systemic disease. What could be the possible diagnosis: *(AIPG 2023)*



a. Pleomorphic adenoma
b. Cystadenoma lymphomatosum
c. Adenoid cystic carcinoma
d. Sialadenosis

Q.56. What is the most appropriate terminology for the given condition: *(AIIMS 2023)*



a. Mesiodens
b. Supernumerary tooth
c. Compound odontoma
d. Composite odontoma

Q.57. A 40-year-old patient presents with following intra-oral clinical findings. What is the diagnosis and how will you manage this patient? *(AIIMS 2023)*



a. Tobacco pouch keratosis—Scaling, tobacco cessation counseling and recall after 1 month
b. Oral leukoplakia—Chlorhexidine mouth wash, topical steroids
c. Oral leukoplakia—Antibiotics
d. Tobacco pouch keratosis—Chlorhexidine mouthwash

Q.58. The given condition is associated with which syndrome: *(AIIMS 2022)*



a. Van der Woude syndrome
b. Melkersson-Rosenthal syndrome
c. Treacher Collins syndrome
d. Weber syndrome

Q.59. A 15-year-old reported to the clinic with multiple bone fractures in childhood, worn teeth, brownish grey discoloration of teeth, obliterated pulp chambers and stunted roots: *(AIIMS 2022)*



a. COL1 A1
b. SQS TM1
c. AMEL X
d. APC tumor suppressor gene

Q.60. Patient reported with the multiple unerupted teeth, sparse hair and the saddle nose. The clinical diagnosis of the condition as depicted in this picture is: *(AIIMS 2022)*



a. Ectodermal dysplasia
b. Syphilis
c. Cleidocranial dysplasia
d. Paget's disease

Answers: **55. d** **56. a** **57. a** **58. a** **59. a** **60. a**

JAYPEE BROTHERS

Q.61. A 18-year-old patient present with ossification of falx cerebri, multiple unilocular radiolucencies in the skull as shown in the radiograph. There is associated palmar plantar keratosis noted in the hands and feet. What is the syndrome associated? *(AIPG 2023)*

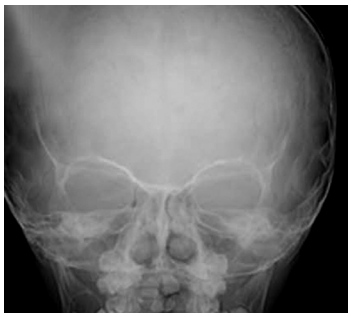


a. Papillon-Lefèvre syndrome
b. Gardner's syndrome
c. Multiple dentigerous cysts
d. Basal cell nevus syndrome

Q.62. What are the yellowish white spots denoted on the picture? *(AIPG 2023)*



a. Wickham's striae
b. Fordyce's granules
c. Herpes simplex
d. Minor aphthous ulcer

Q.63. A patient shows generalized mobility of the dentition, with a history of early exfoliation of deciduous dentition. On examination there is hyperkeratosis of the palm. The probable condition is: *(AIPG 2023)*




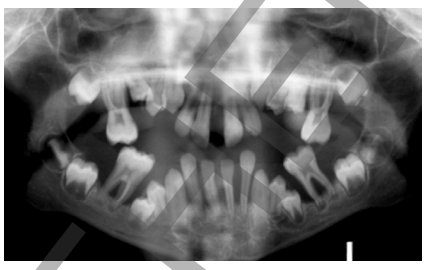

a. Parry-Romberg syndrome
b. Papillon-Lefèvre syndrome
c. Meischer syndrome
d. Pierre Robin syndrome

Q.64. A patient present to the clinic with a history of trauma with clinical and radiographic appearance as shown below. What could be the lesion present in the mucosa? *(AIPG 2023)*


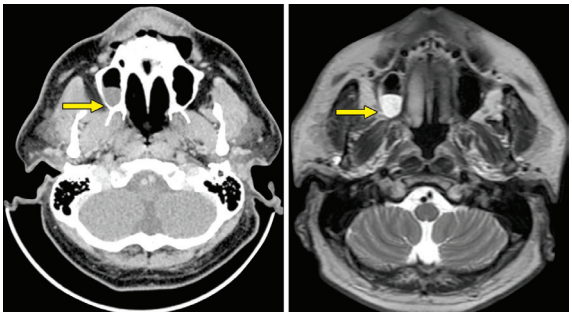

a. Post-traumatic ecchymosis
b. Malignant melanoma
c. Thrombocytopenia
d. Blue nevus

JAYPEE BROTHERS

Answers: 61. d 62. b 63. b 64. b

Q.65. In the condition shown in the image below, which statement is not true? *(AIIMS 2024)*



a. Such calcified structures are infrequently seen in the parotid gland and duct
b. A straight, short course of the submandibular duct (Wharton's duct) and thick mucoid secretions increase the likelihood of submandibular gland duct involvement
c. Sialoliths are typically not associated with pain or swelling
d. Sialoliths can also be found in minor salivary glands

Q.66. The following denotes which condition: *(AIIMS 2023)*



a. Acromegaly
b. Gigantism
c. Cushing syndrome
d. Addison's syndrome

Q.67. Patient presented with bilateral mandibular swelling and eye towards heaven appearance. Identify the condition: *(AIPG 2024)*





a. CGCG
b. Cherubism
c. Crouzon syndrome
d. Apert syndrome

Q.68. A patient reported with history of multiple bony fractures and following clinical condition of teeth. The disorder is likely due to: *(AIIMS 2023)*



a. Mutation in COL1A1 gene
b. Mutation in APC tumor suppressor gene
c. Mutation in AMELX gene
d. Mutation in GNAS1 gene

Q.69. The following clinical condition is: *(AIIMS 2023)*



a. Fusion
b. Gemination
c. Dilaceration
d. Dens in dente

Answers: 65. c 66. a 67. b 68. a 69. a

JAYPEE BROTHERS

SECTION 2: ORAL RADIOLOGY

Q.1. A CT scan of a patient with swelling in left angle of ramus shows a bony growth that is painless and present on lateral surface of ramus indicates: *(AIPG 2016)*

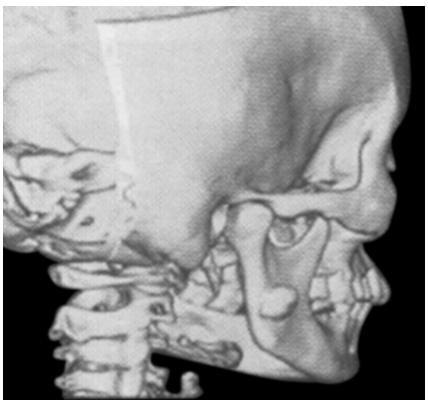

a. Osteoma
b. Sialolithiasis
c. Pleomorphic adenoma
d. Fibrous dysplasia

Q.2. Which condition is depicted in the CT picture given below?



a. Mandibular tori
b. Torus palatinus
c. Complex odontoma
d. Sialolithiasis

Q.3. The condition highlighted by the arrow in the occlusal radiograph in an 8-year-old child could be due to:

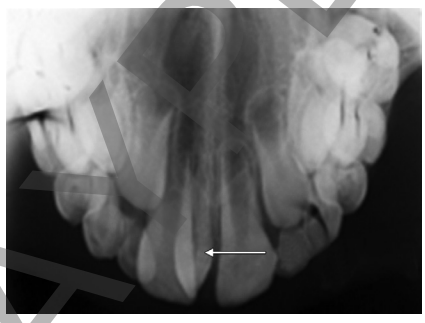

a. Non-vital tooth
b. Impacted tooth
c. Ghost tooth
d. Mesiodens

Q.4. Radiolucent ballooning osteolytic expansion involving the angle and ascending ramus of mandible with vital teeth is probably: *(AIIMS 2016)*



a. Dentigerous cyst
b. Keratocystic odontogenic tumor
c. Aneurysmal bone cyst
d. Radicular cyst

Q.5. What is seen in the X-ray below? *(AIPG 2017)*



a. Mucus retention cyst
b. Chronic sinusitis
c. Acute sinusitis
d. Periapical abscess of upper left premolar tooth

Q.6. OPG of dentition, identify the anomaly: *(AIIMS 2017)*

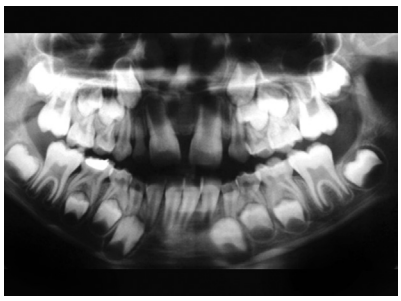

a. Fusion on 72, 82
b. Anomalous developing molar
c. Concrescence 72, 73 and 82, 83
d. Congenitally missing 32, 42

Answers: **1. a** **2. a** **3. d** **4. c** **5. b** **6. d**

JAYPEE BROTHERS

Q.7. Identify the condition shown in the OPG: *(AIIMS 2017)*



a. Left condyle hypoplasia
b. Right condyle hypoplasia
c. Left side condyle hyperplasia
d. Right side condyle hyperplasia

Q.8. Identify the condition shown in radiograph: *(AIIMS 2017)*



a. Floating tooth
b. Hanging tooth
c. Flipper teeth
d. Fleeting teeth

Q.9. Diagnosis given in the image is: *(AIIMS 2017)*

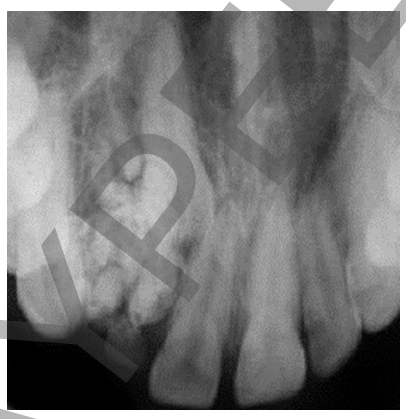

a. Odontoma
b. Rudimentary mesiodens
c. Erupting canine
d. Impacted lateral incisor

Q.10. Identify the intraosseous lesion which is associated with impacted tooth aggressive infiltration, highly recurrent growing along length of bone shown in the picture below: *(AIPG 2017)*

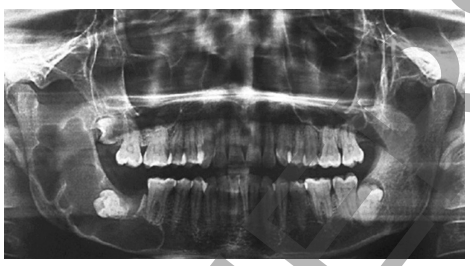

a. Warthins tumor
b. Dentigerous cyst
c. Unicystic ameloblastoma
d. Keratocystic odontogenic tumor

Q.11. True for the image given below: *(AIPG 2017)*

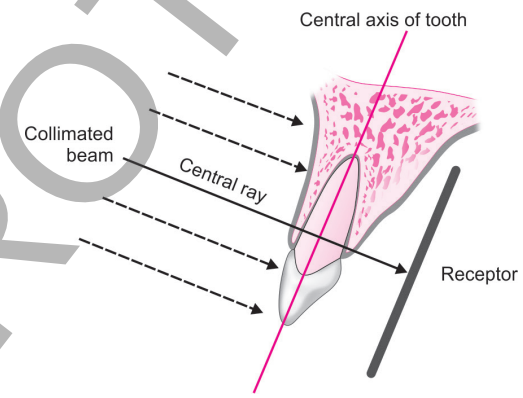

a. Central ray is perpendicular to the line bisecting the angle between tooth and film
b. Central ray of X-ray beam is directed at right angle to teeth and receptor
c. Both a and b
d. None of the above

Q.12. Given radiographic image is suggestive of: *(AIIMS 2017, AIIMS 2023)*

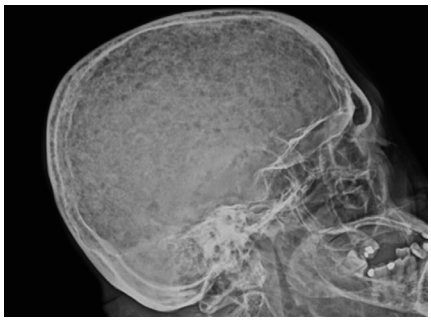

a. Paget's disease
b. Multiple myeloma
c. Crouzon disease
d. Bimaxillary protrusion

Answers: 7. c 8. a 9. a 10. d 11. b 12. b

JAYPEE BROTHERS

Q.13. Diagnostic radiograph of a patient is shown here. What is the diagnosis? *(AIIMS 2018)*



a. Dentin dysplasia I
b. Short root syndrome
c. Taurodontism
d. Hypophosphatasia

Q.14. Identify the lesion shown in radiograph: *(AIIMS 2016)*



a. Dentigerous cyst
b. Ameloblastoma
c. Primordial cyst
d. Lateral periodontal cyst

Q.15. Identify the radiographic view shown below: *(AIIMS 2016)*

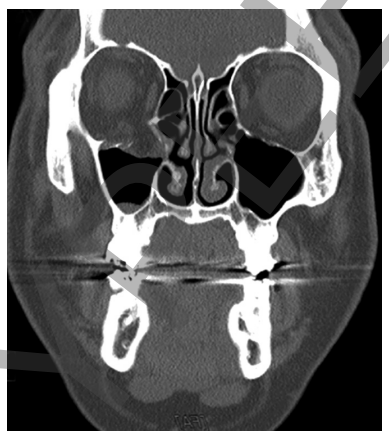

a. Coronal
b. Sagittal
c. Axial
d. None of the above

Q.16. Below given figure is suggestive of: *(AIIMS 2016)*

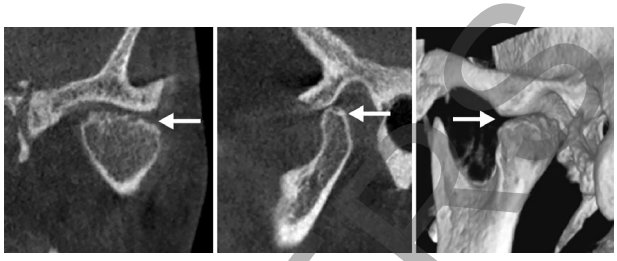

a. Osteoarthritis
b. Rheumatoid arthritis
c. Idiopathic bone resorption
d. Inflammatory bone resorption

Q.17. The following image shows: *(AIIMS 2019)*



a. Oligodontia with missing 41, 42, 31, 32 with hypodontia 13, 23, 33, 43
b. Oligodontia with missing 12, 21, 31, 32 with hypodontia 13
c. Oligodontia with missing 21, 22, 31, 32, 41, 42 with microdontia 13, 33, 43
d. Oligodontia with missing 21, 31, 32, 41, 42 with microdontia of 13, 23, 43

Q.18. Which phenomenon is denoted in this radiograph? *(AIIMS 2019)*



a. Fenestration
b. Gemination
c. Dilaceration
d. Concrescence

Answers: **13. a** **14. a** **15. a** **16. a** **17. c** **18. c**

JAYPEE BROTHERS

Q.19. Identify the cyst given: *(AIPG 2019)*



a. Stafne's cyst
b. Submandibular sialadenitis
c. Odontome
d. Cementoblastoma

Q.20. Radiograph – IOPA showing eruption of permanent teeth keeping an arrow: *(AIPG 2019)*



a. Supernumerary teeth
b. Erupting canine
c. Permanent incisor
d. Deciduous central incisor

Q.21. A patient desires of replacement of his missing first molar. On taking an OPG following anomaly is seen: *(AIPG 2019)*

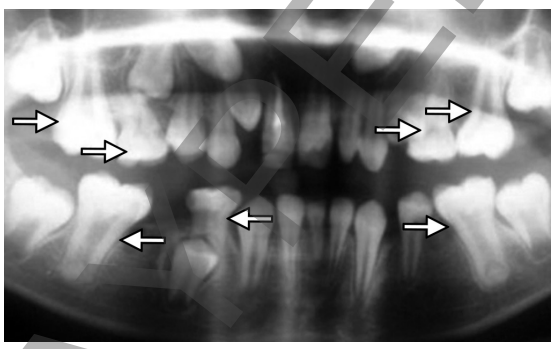

a. Taurodontism
b. Concrescence
c. Connation
d. Dentinogenesis imperfect

Q.22. A mandibular prognathic patient visited your clinic with calcification of falx cerebri, bifid ribs along with the following OPG which show multiple radiolucencies. The tentative diagnosis is: *(AIPG 2021)*

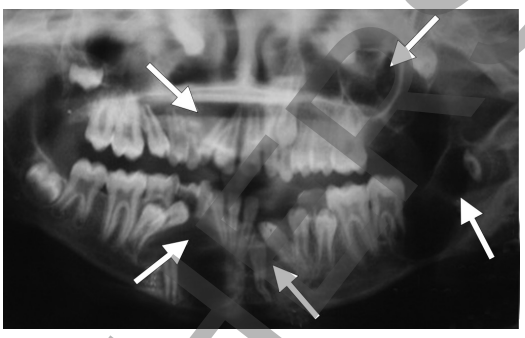

a. Nevoid basal cell carcinoma
b. Down syndrome
c. Cleidocranial dysplasia
d. Craniofacial synostosis

Q.23. Patient complaints of pain on opening the mouth, ringing of ears, discomfort and pain on moving head right and left. OPG taken is shown below. The diagnosis is: *(AIPG 2021)*

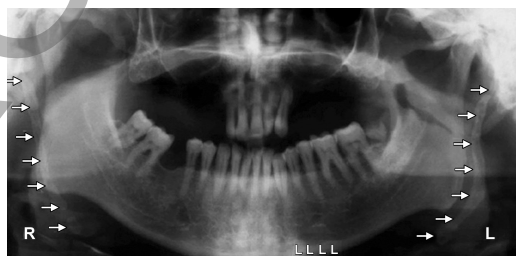

a. Trotters syndrome
b. Eagle syndrome
c. Sphenopalatine neuralgia
d. Costen's syndrome

Q. 24. Patient showing high arch palate, hypertelorism as shown in the below radiograph. The diagnosis is: *(AIPG 2021)*

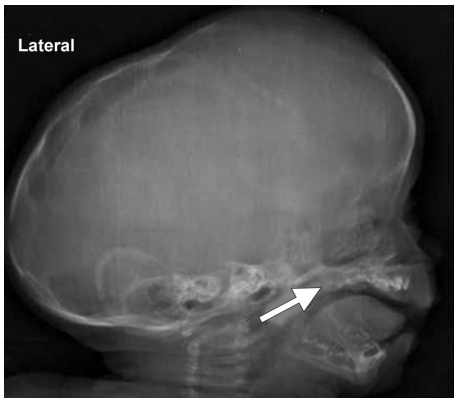

a. Crouzon syndrome
b. Treacher Collins syndrome
c. Cleidocranial dysplasia
d. Pierre-Robin syndrome

Answers: 19. a 20. a 21. a 22. a 23. b 24. a

JAYPEE BROTHERS

Q.25. Anteroposterior extension of lesion with mild expansion of OPG image given: *(AIPG 2021)*

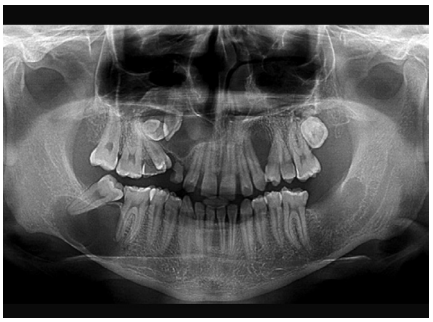

a. OKC
b. Dentigerous cyst
c. Ameloblastoma
d. Central giant cell granuloma

Q.26. Identify the disease based on the radiograph given below: *(AIPG 2021)*

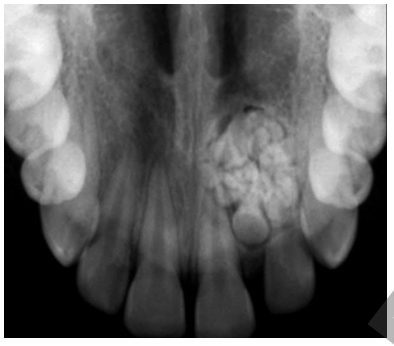

a. Compound odontome
b. Complex odontome
c. Supernumerary tooth
d. Periapical cemental dysplasia

Q.27. Find the following radiographic image showing radiopaque mass in posterior jaw. The diagnosis is: *(AIPG 2021)*



a. Supernumerary tooth
b. Impacted tooth
c. Compound odontome
d. Complex odontome

Q.28. Identify the condition: *(AIPG 2021)*

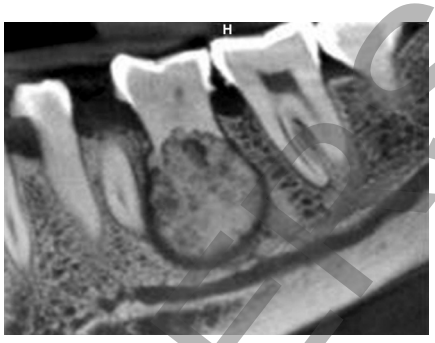

a. Condensing osteitis
b. Cementoblastoma
c. Osteosarcoma
d. Osteoid

Q.29. Identify the pathology given below: *(AIPG 2021)*

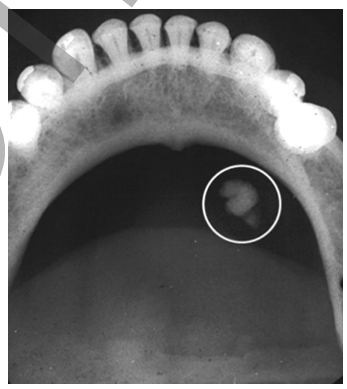

a. Sialolith
b. Foreign body
c. Artifact
d. Displaced prosthesis

Q.30. Identify the marked structure shown by arrows: *(AIPG 2022)*

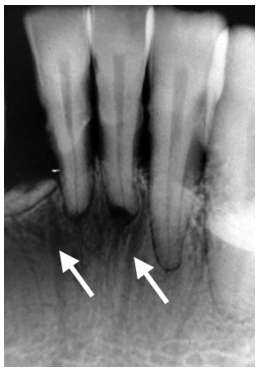

a. Nutrient canal
b. Multiple alveolar fractures
c. Artifact
d. Hypomineralized structure

Answers: **25. a** **26. a** **27. d** **28. b** **29. a** **30. a**

JAYPEE BROTHERS

Q.31. Identify the marked structure: *(AIPG 2022)*

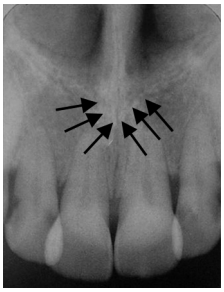

a. ANS
b. Maxillary sinus
c. Supernumerary teeth
d. Fracture line

Q.32. Which of the following is not a succedaneous tooth? *(AIIMS 2021)*



a. 16
b. 54
c. 45
d. 13

Q.33. A 65-year-old lady came with the following OPG, diagnosis is: *(AIIMS 2021)*



a. Fibrous dysplasia (monostotic)
b. Florid osseous dysplasia
c. Cemento-ossifying fibroma
d. Paget's disease

Q.34. Identify the artefact visible in the digital film: *(AIPG 2022)*

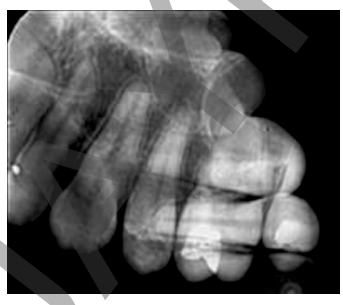

a. Chewing gum
b. Finger with painted nails
c. Without erasing previous image
d. Nose pin

Q.35. Bulbous root apices seen in the IOPA. What is the probable cause of this? *(AIPG 2022)*



a. Hypercementosis
b. Enamel pearl
c. Cementoblastoma
d. Condensing osteitis

Q.36. Identify the pathology in an attached radiograph: *(AIPG 2022)*

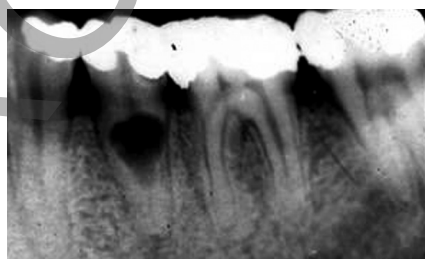

a. Internal resorption
b. External resorption
c. Inflammatory resorption
d. Chemical resorption

Q.37. Which of the following image shows the beam hardening effect scattered as an artefact? *(AIPG 2022)*

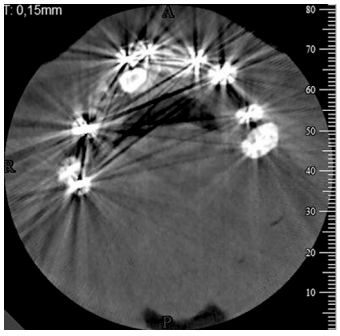

a. CBCT
b. Digital radiography
c. OPG
d. USG

Answers: 31. a 32. a 33. b 34. c 35. a 36. a 37. a

JAYPEE BROTHERS

Q.38. Identify the given image: *(AIIMS 2022)*



a. Right condylar hyperplasia
b. Right hemimandibular hyperplasia
c. Left hemimandibular hyperplasia
d. Left condylar hyperplasia

Q.39. Which of the following couldn't be the cause of the radiolucency as seen in the OPG? *(AIIMS 2023)*

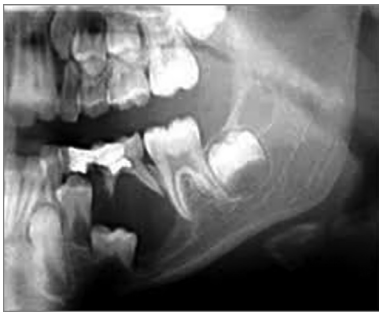

a. Infection spreading from primary teeth
b. OKC
c. Odontogenic tumor
d. Dentigerous cyst

Q.40. OPG shows unerupted central incisor which is blocked by a radiopaque mass. Which of the following is not the cause of it? *(AIIMS 2023)*

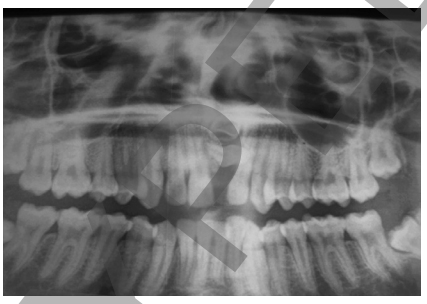

a. Mesiodens
b. Dentigerous cyst
c. Compound odontoma
d. Complex odontoma

Q.41. The following image shows lateral skull radiograph. This radiological picture is seen in which clinical condition: *(AIIMS 2023)*

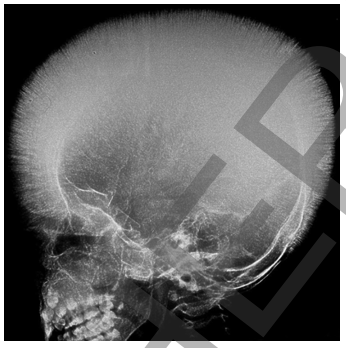

a. Only sickle cell anemia
b. Only thalassemia
c. Disorders of hemoglobin
d. Only iron deficiency anemia

Q.42. The lesion in the radiograph leading to displacement of the molar is: *(AIPG 2023)*

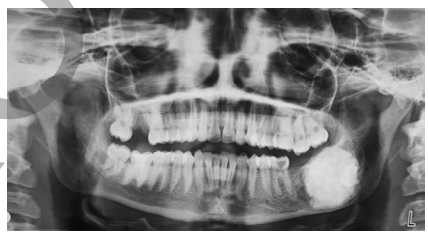

a. Phlebolith
b. Carotid artery calcification
c. Complex odontoma
d. Calcification of lymph node

Q.43. What is the structure indicated by the arrow marked in radiograph? *(AIPG 2023)*



a. Dens in dente
b. Dens evaginatus
c. Talon's cusp
d. Leong's tooth

Answers: 38. c 39. a 40. b 41. c 42. c 43. c

JAYPEE BROTHERS

Q.44. The CT images shown below depict a condition due to an elongated styloid bone. What is the pathology associated with this condition? *(AIIMS 2024)*



a. Glossopharyngeal neuralgia
b. Otic neuralgia
c. Postherpetic neuralgia
d. Trigeminal neuralgia

Q.45. What is the cause of septae in the multilocular pathology of ameloblastoma? *(AIPG 2024)*

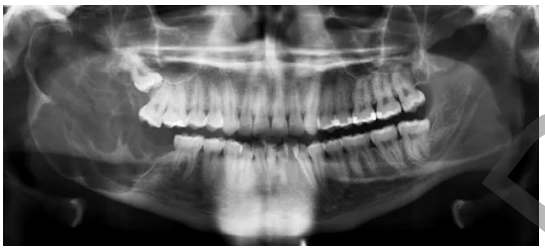

a. Formation of new bone within the pathology
b. Entrapment of normal bone within the pathology
c. Deposits of dead bone within the pathology
d. Fractured bone within the pathology

Q.46. Patient presented with absence of 2nd and third mandibular molars. OPG showing impacted 47 and radiopacity in place of 48. Identify the lesion: *(AIPG 2024)*



a. Odontoma
b. Ameloblastoma
c. Ossifying fibroma
d. Lymphoma

Q.47. A 10-year-old boy comes with multiple carious teeth. He is treated for Hodgkin's lymphoma at 2 years of age with therapeutic radiation and chemotherapy. What is the effect seen on roots of permanent teeth? *(AIIMS 2024)*



a. Fusion
b. Gemination
c. Stunting
d. Concrescence

JAYPEE BROTHERS

Answers: 44. a 45. b 46. a 47. c

for detailed information on dental books, visit our website www.ejaypee.com, for detailed information on dental books, visit our website www.ejaypee.com, for detailed information on d

Mastering the BDS IVth Year-I (Last 15 Years Solved Questions)

Salient Features

- Written in simple and lucid language.
- Provides broad coverage of all the subjects in BDS IVth year—Part 1.
- Includes vast topics in simple flowcharts, tables, and diagrammatic forms so as to make the content easy to understand and recall.
- Supports in quick revision during examinations.
- **One weapon, three targets, i.e., BDS examinations, PG and PSC entrance, and MDS (Basic Sciences):** It is the only book written, which can be used to clear university graduation examinations, for postgraduate entrance examinations and also to crack basic sciences examination for postgraduate students.

The earlier editions have been immensely popular among the dental students, postgraduate aspirants, and dental practitioners. Other highlights of Eleventh edition are:

- Exam-oriented book with unique collection of last 15 years solved question papers.
- All the sections are thoroughly revised and various answers of previous editions are changed in this present edition because of changes of various concepts and inculcation of the new researches.
- In this section, Oral Medicine and Oral Radiology, Orthodontics, Periodontics, and Public Health Dentistry are modified with the change answers.
- Consists of solved Multiple Choice Questions (MCQs) and Fill in the Blanks, which are added by National Dental Council (NDC) in latest curriculum.
- As in NEET PG, PGI, and AIIMS examination, image-based questions are asked, so an idea to BDS student regarding these are introduced, which further help them to study for abovementioned competitive examinations.
- Additional Information at the end of every section is introduced to quickly memorize and revise the topic in short. This will also help in solving MCQs very fast in university as well as in competitive examinations.
- One Liner (Knowledge Enhancers) is added for quick revision of dental postgraduate entrance examinations such as NEET, PGI, INI-CET, and PSCs.
- Contains illustrations and high-quality photographs with explanatory legends for easy explanation of text.
- Provides recent and internationally accepted classification systems by eminent professional bodies; World Health Organization (WHO), Centers for Disease Control and Prevention (CDC), National Health Programmes/guidelines such as Indian Council of Medical Research (ICMR), National Centre for Disease Control (NCDC), Revised National Tuberculosis Control Programme (RNTCP), National AIDS Control Programme, etc.
- Includes solved papers of year 2025 and 2026, with better and improved answers.
- Illustrates photographs in color plates, which help students to understand the various diseases clinically.
- Incorporates a clinical overview in various chapters for highlighting the clinical applications.
- A highly structured, user-friendly, systemic, and attractive layout with enriched illustrations.

The hallmark features of the previous editions have been retained.

- Content is more with less pages—handy look is there which saves the time of student.
- Concise, bullet format, and to the point text, which is easy to read during BDS university examinations and MDS basic sciences examination.
- Language is simple and lucid, which makes the understanding easy.
- MCQs, IBQs, Fill in the Blanks, Additional Information, and One Liner (Knowledge Enhancers) are present at end of each subject.

Hemant Gupta MDS has over 21 years of experience of authorship. He is CEO of Shivom Multispeciality Dental Clinic and Implant Centre, Indore, Madhya Pradesh, India. He is a general practitioner and maxillofacial implantologist and also a consultant as oral cancer diagnostician at various clinics and hospitals. He has also specialized in pathology technique such as immunohistochemistry. He has published research papers in various indexed journals of national and international repute. He has experience of providing coaching to dental students at personal level, which helps them to build up the basics in dentistry, and also to clear the various university examinations. His pioneer work in "Forensic Odontology is on Ameloglyphics". He has also contributed some chapters in two academic textbooks.

Dr Hemant Gupta has also authored several other popular books which are extremely appreciated among BDS and MBBS students:

- **Mastering BDS First Year**
- **Mastering BDS Second Year**
- **Mastering BDS Third Year**
- **Mastering BDS Final Year—Part II**
- **Mastering MBBS Ist Year**

JAYPEE BROTHERS

Shelving Recommendation
DENTISTRY

ISBN 978-81-68259-98-0

Buy from ejaypee

JAYPEE BROTHERS