umatology books, visit our website www.ejaypee.com, for detailed information on rheumatology books, visit our website www.ejaypee.com, for detailed information on rheumatology books

DECISION MAKING IN RHEUMATOLOGY

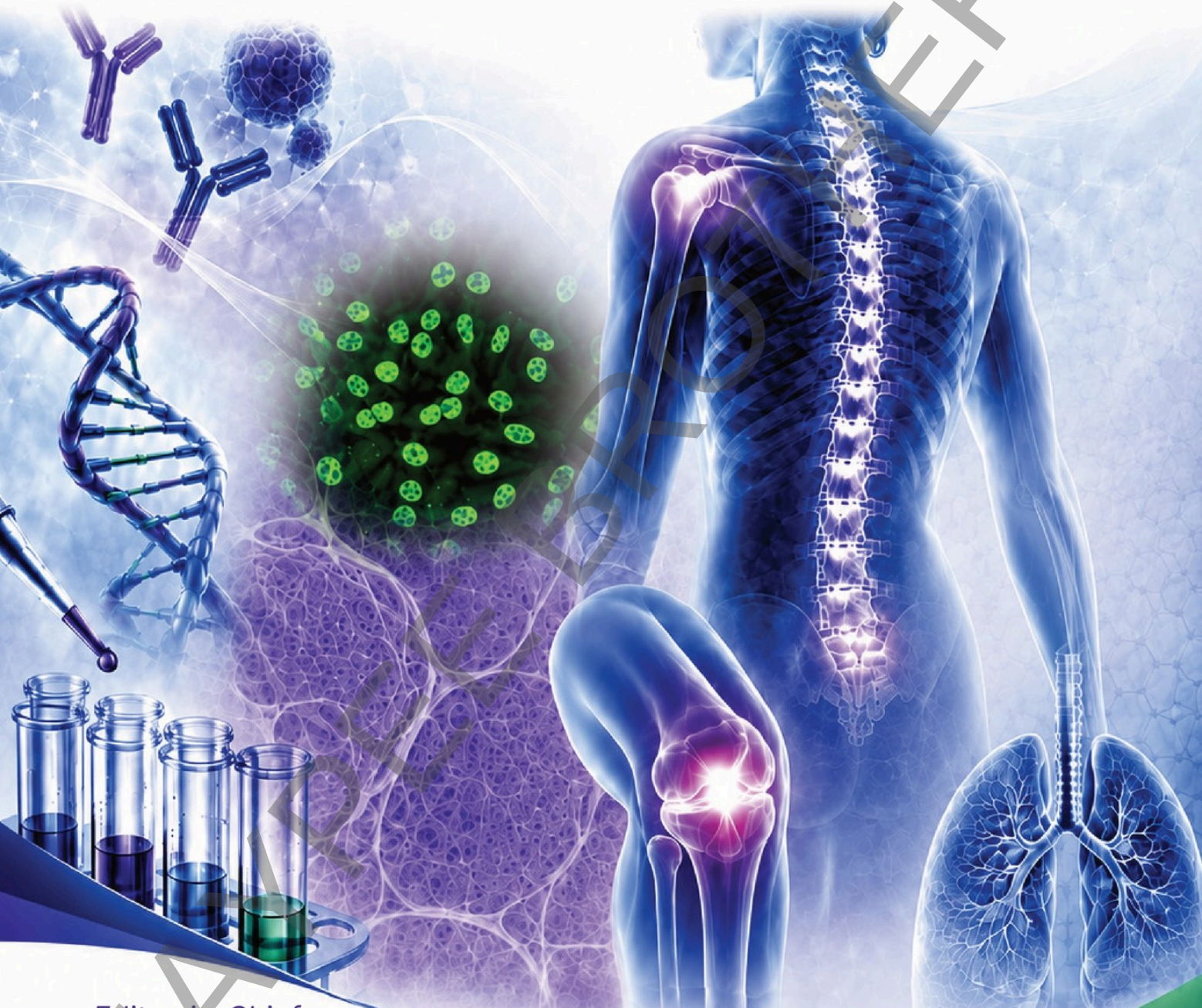

Editor-in-Chief
Uma Kumar

Editor
Siddharth Jain

JAYPEE

JAYPEE BROTHERS

CONTENTS

CHAPTER 1: **Clinical Evaluation and Differential Diagnosis of Monoarthritis** 1
Subin Philip, Ritesh Kumar Mishra, Molly Mary Thabah

CHAPTER 2: **Approach to a Patient with Polyarthritis** 11
Shrreya Agarawal, Joydeep Samanta

CHAPTER 3: **Laboratory Investigations in Rheumatology: Principles and Pitfalls** 20
Seema Chhabra, Varun Dhir

CHAPTER 4: **Nuts and Bolts of Radiology in Rheumatological Disorders** 29
Stanzin Spalkit, Shujaut Farooq, Surabhi Vyas

CHAPTER 5: **Spondyloarthritis: Clinical Decision-Making** 44
Meera Shah, Srujana Budumuru, Bhowmik Meghnathi

CHAPTER 6: **Myositis Diagnosis: Integrating Clinical Clues, Biomarkers, Imaging, and Histology** 53
Vineeta Shobha, Harikrishnan Gangadharan

CHAPTER 7: **Management of Idiopathic Inflammatory Myositis** 62
Danveer Bhadu, Simar Saluja

CHAPTER 8: **Systemic Sclerosis: From Diagnosis to Therapeutic Strategies** 70
Shefali K Sharma, Bhargavi Pridhivi

CHAPTER 9: **Sjögren's Disease** 77
Mahabaleshwar Mamadapur, Harshwardhan Patil, Pulukool Sandhya

CHAPTER 10: **Systemic Lupus Erythematosus with Antiphospholipid Syndrome and Pregnancy** 90
Sai Yasaswini Kommaraju, Lekshmi Minikumari Rahulan, Amita Aggarwal

CHAPTER 11: **Small Vessel Vasculitis: A Guide to Diagnosis and Therapeutic Decision-Making** 99
Rajeswari Sankaralingam, Sreya Yarlagadda

CHAPTER 12: **ANCA-Associated Vasculitis: Clinical Suspicion and Red Flags** 110
Kodali Ramyasri, Benzeeta Pinto

CHAPTER 13: **ANCA-Associated Vasculitis: Assessment of Disease Activity and Severity** 120
Vineetha K, GSRSNK Naidu, Aman Sharma

JAYPEE BROTHERS

CHAPTER 14: **Management of ANCA-Associated Vasculitis** 126
Vineetha K, GSRSNK Naidu, Aman Sharma

CHAPTER 15: **How to Approach Large Vessel Vasculitis: Diagnosis to Treatment** 135
Durga Prasanna Misra

CHAPTER 16: **IgG4-Related Disease: Clinical Spectrum, Diagnosis, and Management** 142
Lalit Duggal, Neeraj Jain, Malavika Mittal

CHAPTER 17: **Crystal Arthropathies** 153
Aradhana Singh, Avinash Jain, Rashi Maheshwari

CHAPTER 18: **Therapeutic Decision-Making in Connective Tissue Disease-Associated Interstitial Lung Disease** 163
Anant Mohan, Irfan Shekh, Nipun Malhotra

CHAPTER 19: **Infection: A Trigger, Mimicker, and Complication in Autoimmune Disease** 175
Swetal Chouhan, PD Rath

CHAPTER 20: **Thinking Beyond Autoimmune Rheumatic Diseases** 181
Pavneet Kaur, Narendra Kumar Bagri

CHAPTER 21: **A Practical Guide for Offering and Interpreting Genetic Tests in Rheumatology** 190
Selvamanojkumar S, Neerja Gupta, Madhulika Kabra

Index 199

JAYPEE BROTHERS

CHAPTER

2

Approach to a Patient with Polyarthritis

Shrreya Agarawal, Joydeep Samanta

JAYPEE BROTHERS

INTRODUCTION

The word *polyarthritis* comes from *poly-* meaning "many" and *arthritis* meaning "inflammation of joints." In clinical terms, polyarthritis refers to inflammation in five or more joints. It is not a diagnosis, but rather a presentation that may occur in several diseases, ranging from short-lived viral infections to chronic autoimmune disorders, such as rheumatoid arthritis (RA) and systemic lupus erythematosus (SLE). When fewer joints are affected, the presentation is termed monoarthritis (one joint) or oligoarthritis (two to four joints). The number of joints involved is a key diagnostic clue: monoarthritis often represents an acute, potentially urgent problem such as septic arthritis, gout, hemarthrosis, or trauma, while *polyarthritis* is more likely to indicate a systemic or autoimmune process such as RA or lupus. Oligoarthritis often serves as an intermediate pattern, seen in spondyloarthritis (SpA) or early connective tissue disease. Recognizing this distribution early helps to prioritize investigations and distinguish emergent from chronic or self-limiting causes.

Because so many conditions can present with multiple painful or swollen joints, the clinician's challenge is to identify the cause through careful reasoning rather than by ordering large panels of tests. Laboratory investigations often lack specificity and should support, not replace, a structured clinical assessment.

A practical way to approach polyarthritis is to:

- Confirm that the pain is truly *articular* and *inflammatory*.
- Determine whether the process is *acute* (<6 weeks) or *chronic* (≥6 weeks).
- Recognize the *pattern* of joint involvement—which joints are affected and whether the pattern is symmetric or asymmetric.
- Look for *systemic* or *extra-articular* features
- Use investigations selectively to confirm the suspected diagnosis

When followed systematically, this approach efficiently narrows the differential diagnosis and helps prevent unnecessary investigations or delays in treatment.

APPROACH TO EVALUATION

Evaluation begins at the bedside—history and examination often provide the crucial diagnostic direction.

Articular versus Periarticular Pain

Evaluation begins with distinguishing true articular from periarticular pain, as this directs the subsequent line of inquiry.

Articular (true joint) pain arises from inflammation or pathology within the joint capsule itself.

The following structures, when affected, produce articular pain **(Fig. 1)**.

- *Synovium*—as in synovitis of RA or psoriatic arthritis (PsA)
- *Articular cartilage*—typically damaged in osteoarthritis (OA)
- *Joint capsule and subchondral bone*—stretched or inflamed in traumatic or degenerative arthritis

Pain is usually deep, diffuse, and associated with restriction of both active and passive movements, and pain is usually present in all directions of movement.

In contrast, *periarticular pain* originates from structures around but outside the joint capsule, and passive motion is usually painless and preserved.

Common sources include:

- *Tendons and their sheaths* → tendinitis, tenosynovitis (e.g., De Quervain's tenosynovitis).
- *Entheses (tendon or ligament insertions)* → enthesitis in spondyloarthropathies

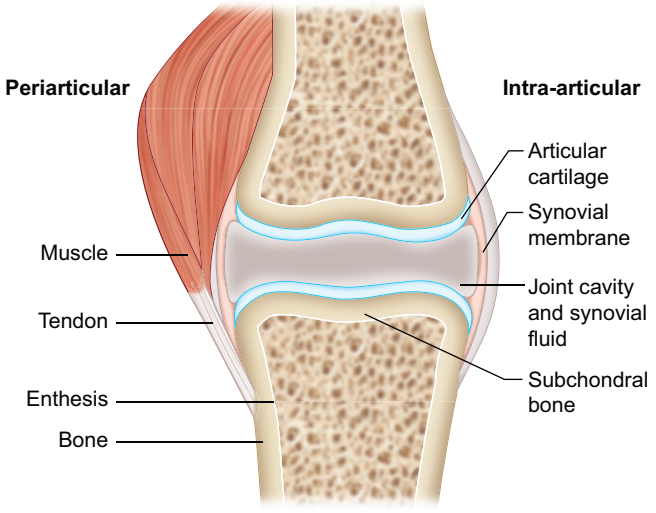

FIG. 1: Structure of a synovial joint showing various articular and periarticular sources of pain.

- *Bursae* → bursitis (e.g., subacromial and olecranon)
- *Muscles and fascia* → myofascial pain and fibromyalgia

Periarticular pain is typically localized, often worsened by active use, and may be associated with point tenderness rather than diffuse swelling.

Inflammatory versus Noninflammatory

Arthritis refers to inflammation of the joint structures, primarily the synovial membrane, and is accompanied by the cardinal features of inflammation—pain, swelling, warmth, and sometimes redness. Morning stiffness lasting >30–60 minutes, pain that improves with activity but worsens after rest, and the presence of systemic symptoms such as fatigue, weight loss, or low-grade fever further support an inflammatory etiology. Common causes include RA, SLE, PsA, and SpA. This morning stiffness occurs due to the overnight accumulation of inflammatory cytokines within the synovium and periarticular tissues, which is washed away by increased blood flow following movement of the joint, with resultant resolution of the symptom of stiffness. This feature contrasts sharply with noninflammatory causes of polyarthritis, where stiffness is usually absent or, even if present, is typically brief and related to mechanical joint use rather than inflammation.

In contrast, *arthralgia* refers to pain perceived in or around a joint without objective signs of inflammation. It may result from noninflammatory articular conditions such as OA, or from periarticular disorders involving adjacent structures such as tendons, bursae, or entheses. In conditions such as tendinitis, bursitis, or fibromyalgia, the pain arises from periarticular tissues but is often experienced by the patient as joint pain. Passive joint motion remains full and painless, helping distinguish these from true arthritis. Stiffness, if present, is brief, and pain typically worsens with use or towards the end of the day.

The time course of symptoms often provides the next diagnostic clue.

Acute versus Chronic Polyarthritis

Acute polyarthritis (symptom duration <6 weeks) is most often self-limited and may result from viral infections such as parvovirus B19, hepatitis B or C, or chikungunya, as well as from crystal-induced disease (gout, calcium pyrophosphate deposition disease) or serum sickness reactions. Arthrocentesis is mandatory in any acutely swollen joint to exclude sepsis and crystal arthritis. Occasionally, an acute-onset presentation may represent the initial phase of a chronic disorder, such as early RA or SLE.

Chronic polyarthritis (symptoms persisting for 6 weeks or more) indicates a sustained inflammatory or degenerative process, most commonly RA, SLE, PsA, SpA, or chronic infections such as tuberculosis.

Eliciting symptom duration helps to avoid over-treatment of transient illnesses while ensuring timely therapy in progressive disease. The broad etiologic groups are summarized below.

Causes of Polyarthritis

Polyarthritis can arise from a broad spectrum of disorders, details of which are enumerated in **Table 1**.

Pattern of Joint Involvement

- *Axial joints* including the spine, sacroiliac, and sternoclavicular joints—are typically involved in SpA [e.g., ankylosing spondylitis and reactive arthritis (ReA)], whereas *peripheral joints* of the limbs—such as shoulders, elbows, wrists, hands, hips, knees, ankles, and feet—are more commonly affected in RA, SLE, and viral arthritis.
- *Symmetric involvement* implies that *the same group of joints on both sides of the body* are affected—for example, both wrists or both sets of metacarpophalangeal (MCP) joints, not necessarily an exact mirror image. This pattern is characteristic of RA, SLE, and viral arthritis, which typically involve the small joints of the hands, wrists, and feet.
- *Asymmetric involvement* means that different joints or unequal extent of involvement occurs on each side. It is commonly seen in PsA, ReA, and other spondyloarthritides, which often affect large, weight-bearing joints such as the knees, ankles, or hips.

Certain joint predilections further refine the diagnosis.

JAYPEE BROTHERS

TABLE 1: Causes of polyarthritis.

Category	*Examples*
Autoimmune/ Inflammatory arthritides	• Rheumatoid arthritis • Systemic lupus erythematosus • Psoriatic arthritis • Spondyloarthritis including ankylosing spondylitis, reactive arthritis, enteropathic arthritis • Mixed connective tissue disease • Systemic vasculitis • Sjögren's syndrome • Dermatomyositis/polymyositis • Adult-onset Still's disease (AOSD) • Behçet's disease
Infection-related arthritides	• Viral arthritis (*parvovirus B19, hepatitis B or C, chikungunya, and rubella*) • Reactive arthritis (postenteric or genitourinary) • Rheumatic fever • Chronic infections (*tuberculosis, brucellosis, Whipple's disease, and leprosy*)
Crystal-induced arthropathies	• Gout • Calcium pyrophosphate deposition disease (CPPD/pseudogout) • Hydroxyapatite arthropathy
Degenerative/ Mechanical arthropathies	• Osteoarthritis
Metabolic/ Endocrine arthropathies	• Hemochromatosis • Hyperparathyroidism • Hypothyroidism • Acromegaly • Amyloidosis
Malignancy-associated arthritides	Paraneoplastic arthritis (solid or hematologic malignancies)
Drug- or immune-mediated arthritides	• Serum-sickness-like reaction • Dipeptidyl peptidase-4 (DPP-4) inhibitors • Antibiotics (rifampicin and quinolones) • Immune checkpoint inhibitors
Granulomatous/ Miscellaneous disorders	Whipple's disease

Recognizing the typical joint distribution for common rheumatologic diseases helps narrow the differential at the bedside **(Table 2)**.

- *Temporal pattern of involvement*: The sequence in which joints are affected over time also helps in diagnosis—
  - *Additive arthritis*: New joints become inflamed while previous ones remain involved. This is typical of chronic conditions such as RA, PsA, and SLE.
  - *Migratory arthritis*: Inflammation moves from one joint to another, with the initial joints improving as new ones are affected. Seen in acute rheumatic fever, gonococcal arthritis, serum sickness, and granulomatosis with polyangiitis (GPA).
  - *Intermittent or episodic arthritis*: Attacks of inflammation separated by symptom-free intervals. Seen in gout, pseudogout, and palindromic rheumatism.

Recognizing this pattern over serial visits is often the key to diagnosis when a single examination is inconclusive.

Associated Systemic and Extra-Articular Features

Systemic manifestations, when present along with an articular pattern, usually identify the disease family—autoimmune, infectious, crystal-induced, or other. Various important extra-articular manifestations are described in **Table 3**.

Most cases of polyarthritis can be diagnosed through careful history and examination, while investigations primarily confirm and define the underlying disease.

INVESTIGATIONS

Investigations confirm and refine the clinical impression. A logical, stepwise approach prevents over-testing and ensures cost-effective diagnosis:

- Begin with baseline tests to establish the presence of inflammation and assess general health
- Proceed to targeted serology based on the clinical pattern
- Use imaging to confirm and stage disease, not to make the initial diagnosis
- Perform arthrocentesis with synovial fluid analysis whenever a joint effusion is present or septic arthritis is suspected.

Initial Evaluation: Baseline and Screening Tests

Basic laboratory investigations are universally indicated in all patients with suspected polyarthritis. They help to differentiate inflammatory from noninflammatory causes and screen for systemic disease.

JAYPEE BROTHERS

TABLE 2: Characteristic patterns of joint involvement in major arthritides.

Disease/Category	*Typical joint involvement*	*Distribution/Symmetry*	*Characteristic features*
Rheumatoid arthritis	Small joints of hands and feet—MCP, PIP, MTP; wrists, elbows, knees	Symmetric, peripheral	Chronic synovitis, deformities (ulnar deviation, swan-neck, boutonnière) **(Fig. 2)**
Systemic lupus erythematosus	Small joints (MCP, PIP, wrists, knees)	Symmetric, nonerosive	Jaccoud's arthropathy (reducible deformities), minimal radiographic changes
Osteoarthritis	DIP (Heberden's), PIP (Bouchard's), first CMC, knees, hips, spine	Asymmetric or mildly symmetric	Bony enlargement, crepitus, limited range of motion, absence of warmth
SpA *(including PsA, ReA, and IBD-associated)*	Large lower-limb joints, sacroiliac, spine, entheses	Asymmetric, often axial or oligoarticular	Enthesitis, dactylitis, back pain improving with exercise
Crystal arthropathies	First MTP, ankles, knees, wrists, elbows	Asymmetric, intermittent	Recurrent attacks, complete intercritical resolution
Viral arthritis	Small joints—hands, wrists, knees	Symmetric, acute	Self-limited, often accompanied by rash or constitutional symptoms

(CMC: carpometacarpal joint; DIP: distal interphalangeal joint; IBD: inflammatory bowel disease; PIP: proximal interphalangeal joint; MCP: metacarpophalangeal joint; MTP: metatarsophalangeal joint; PsA: psoriatic arthritis; ReA: reactive arthritis; SpA: spondyloarthritis)

TABLE 3: Important extra-articular manifestations (symptoms and signs) in polyarthritis.

System/Site	*Key symptoms and signs*	*Diseases commonly associated*
Skin and mucosa	Malar or discoid rash, photosensitivity, oral, or nasal ulcers **(Figs. 3 and 4)**	Systemic lupus erythematosus (SLE)
	Psoriatic plaques, nail pitting, or onycholysis **(Fig. 5)**	Psoriatic arthritis
	Vasculitic rash, palpable purpura, livedo reticularis	Systemic vasculitis like PAN, antiphospholipid syndrome
	Painful erythematous nodules (erythema nodosum)	Sarcoidosis, IBD, streptococcal infection
	Erythema marginatum, migratory rash	Acute rheumatic fever
	Skin tightening, salt-pepper appearance **(Fig. 6)**	Systemic sclerosis
	Genital ulcers, recurrent aphthous ulcers	Behçet's disease, reactive arthritis
	Subcutaneous nodules, tophi	RA, gout, rheumatic fever
Eyes	Eye pain, redness, photophobia (anterior uveitis, iritis, episcleritis, scleritis)	Spondyloarthritis, RA, sarcoidosis
	Blurred vision, visual loss (posterior uveitis, choroiditis, retinal vasculitis, optic neuritis)	Behçet's disease, SLE, sarcoidosis, vasculitis
	Dryness, grittiness, foreign-body sensation (sicca symptoms/keratoconjunctivitis sicca)	Sjögren's syndrome, RA, SLE
ENT	Dry mouth, parotid enlargement	Sjögren's syndrome, sarcoidosis
	Nasal pain or deformity, saddle-nose	Relapsing polychondritis, GPA
	Hearing loss or tinnitus	Relapsing polychondritis, GPA
Cardiovascular	Chest pain, dyspnea (pericarditis, myocarditis)	SLE, acute rheumatic fever, vasculitis
	Aortic regurgitation, conduction defects	Ankylosing spondylitis, relapsing polychondritis
	Raynaud's phenomenon, digital ischemia	Systemic sclerosis, MCTD
Respiratory	Pleuritic chest pain, cough, dyspnea (pleuritis, effusion, interstitial lung disease)	RA, SLE, systemic sclerosis, vasculitis
	Cough, hemoptysis, pulmonary nodules or infiltrates	GPA, RA, vasculitis

JAYPEE BROTHERS

System/Site	Key symptoms and signs	Diseases commonly associated
Gastrointestinal	Abdominal pain, diarrhea, perianal disease	IBD-associated arthritis, reactive arthritis
	Nausea, jaundice, hepatosplenomegaly	SLE, RA, sarcoidosis, viral hepatitis
	Abdominal tenderness, ischemic pain	Vasculitis (PAN, GPA)
Renal	Edema, frothy urine, hematuria, oliguria	SLE (lupus nephritis), vasculitis, amyloidosis
	Proteinuria, renal dysfunction (chronic inflammatory states)	RA, AS, chronic infections
Neurologic	Numbness, paresthesia, weakness (peripheral neuropathy, mononeuritis multiplex)	Vasculitis, SLE, RA
	Facial palsy, cranial neuropathies	Lyme disease, sarcoidosis
	Seizures, psychosis	Neuropsychiatric SLE
Musculoskeletal (extra-articular)	Heel pain, tenderness at tendon insertions (enthesitis)	Spondyloarthritis, PsA
	Diffuse finger/toe swelling ("sausage digits", dactylitis)	PsA, ReA
	Proximal muscle weakness or pain (myositis)	Polymyositis, dermatomyositis, SLE
Hematologic/ Reticuloendothelial	Fatigue, pallor (anemia of chronic disease), easy bruising, lymphadenopathy, splenomegaly	RA, SLE, AOSD, chronic infection
General/ Constitutional	Fever, fatigue, malaise, weight loss, night sweats	Most inflammatory arthritides (RA, SLE, vasculitis, AOSD)

(AOSD: adult-onset Still's disease; GPA: granulomatosis with polyangiitis; IBD: inflammatory bowel disease; MCTD: mixed connective tissue disease; PAN: polyarteritis nodosa; PsA: psoriatic arthritis; RA: rheumatoid arthritis; ReA: reactive arthritis)



FIG. 2: Hand deformity in a patient with advanced rheumatoid arthritis (RA).



FIG. 3: Malar rash in a patient with systemic lupus erythematosus (SLE).

Complete blood count (CBC) reveals anemia of chronic disease (seen in RA and SLE due to cytokine-mediated suppression of erythropoiesis), leukocytosis in infection, corticosteroid use or primary systemic vasculitis, leukopenia in SLE or Felty's syndrome, and thrombocytosis as part of the acute-phase response.

Erythrocyte sedimentation rate (ESR) and C-reactive protein (CRP)—both are sensitive though nonspecific markers of inflammation.

Liver and renal function tests evaluate both disease impact and treatment safety. Raised transaminases may suggest viral hepatitis or drug toxicity, while elevated creatinine may indicate lupus nephritis, vasculitis, or nonsteroidal anti-inflammatory drug (NSAID) toxicity. Hypoalbuminemia supports chronic inflammation or protein loss.

Proteinuria or hematuria may point to lupus nephritis or vasculitis. Sterile pyuria may occur in ReA. Renal

JAYPEE BROTHERS



FIG. 4: Palatal ulcer in a patient with systemic lupus erythematosus (SLE).



FIG. 5: Psoriatic rash in a patient with psoriasis vulgaris.



FIG. 6: Salt-pepper appearance of skin in a patient with systemic sclerosis.

disease can be clinically silent, hence urinalysis should be performed in all suspected inflammatory arthritides.

Serum uric acid assists in diagnosing gout (though it may be normal during an acute attack). Calcium, phosphate, and alkaline phosphatase abnormalities suggest metabolic bone disease or crystal arthropathy. Thyroid dysfunction may cause arthralgia or myopathy mimicking arthritis.

Hepatitis B surface antigen (HBsAg), anti-hepatitis C antibody (anti-HCV), human immunodeficiency virus (HIV), and interferon-γ release assay (IGRA) or Mantoux test are recommended before starting biological disease-modifying antirheumatic drugs. In acute polyarthritis, viral serology for parvovirus B19, hepatitis B/C, and chikungunya should be considered.

Directed Investigations Based on Clinical Pattern

Acute Polyarthritis (<6 weeks)

The priority is to look for infection, crystals, or early autoimmune disease.

- *Baseline inflammatory markers (ESR and CRP)* confirm systemic inflammation
- *Synovial fluid analysis* is mandatory in any joint effusion to rule out sepsis or crystal deposition.
- *Viral serology* (parvovirus B19, hepatitis B/C, and chikungunya) and *ASO titers* or *Chlamydia polymerase chain reaction (PCR)* are performed when history suggests an infective trigger.
- *Autoantibodies* [rheumatoid factor (RF), anticyclic citrullinated peptide (anti-CCP), and antinuclear antibody (ANA)] are reserved for patients with persistent or evolving disease beyond 6 weeks.

Chronic Symmetric Polyarthritis

This pattern typically suggests RA, SLE, or other connective-tissue disease.

- *ESR and CRP* confirm inflammation
- *RF* and *anti-CCP* are first line. Anti-CCP is highly specific and may appear years before symptom onset. *Anti-carbamylated protein (anti-CarP)* antibodies may identify seronegative RA subsets.
- *ANA* screening is indicated when features suggest SLE or overlap syndromes. Positive results should be followed by an *extractable nuclear antigen (ENA) profile*, including *anti-dsDNA, anti-Sm, anti-U1RNP, anti-Ro/SSA, and anti-La/SSB.*
- *Thyroid function tests* may identify hypothyroidism mimicking inflammatory arthritis.
- *Plain radiographs* of hands and feet serve as baseline imaging to document erosions or joint-space loss.
- *Ultrasound or MRI* can detect early synovitis and erosions not visible on X-ray.

JAYPEE BROTHERS

Chronic Asymmetric or Axial Polyarthritis

When involvement is predominantly axial or lower-limb asymmetric, SpA should be considered.

- *Inflammatory markers* (ESR and CRP) usually correlate with disease activity.
- *HLA-B27* supports the diagnosis but is not diagnostic alone.
- *Infection workup* may include stool cultures or *Chlamydia PCR* if ReA is suspected.
- *MRI of the sacroiliac joints or spine* is the investigation of choice for early detection of sacroiliitis or bone marrow edema, which may precede radiographic changes.

Polyarthritis with Systemic Manifestations

When accompanied by fever, rash, cytopenia, or organ involvement, evaluation for connective-tissue disease or vasculitis is essential.

- *ANA and ENA profile, complement levels (C3, C4)*, and *antineutrophil cytoplasmic antibody (ANCA)* testing help to classify autoimmune and vasculitic disorders.
- *Urinalysis* for glomerulonephritis and *chest imaging* for pulmonary or cardiac involvement (e.g., in lupus, sarcoidosis, and vasculitis) may be necessary.
- *Ferritin* levels can be markedly elevated in adult-onset Still's disease, and *angiotensin-converting enzyme (ACE)* levels in sarcoidosis.

Synovial Fluid Analysis

Arthrocentesis is the most direct and valuable investigation whenever a joint effusion is present, helping distinguish infectious, inflammatory, and crystal-induced causes. The *appearance, leukocyte count, and crystal content* classify effusions as follows **(Table 4)**.

Crystals under polarized light microscopy confirm the diagnosis:

- *Monosodium urate (MSU)*: Needle-shaped, strong negative birefringence → gout.
- *Calcium pyrophosphate (CPPD)*: Rhomboid, weak positive birefringence → pseudogout.

Gram stain and culture must be performed in all cases to exclude infection.

Imaging

Imaging complements clinical and laboratory findings, defining the pattern, extent, and chronicity of joint damage.

- *Plain radiography (X-ray)*: Remains the first-line modality.
  - Rheumatoid arthritis typically shows marginal erosions and periarticular osteopenia **(Fig. 7)**
  - Osteoarthritis is characterized by asymmetric joint-space narrowing and osteophytes.
  - Psoriatic arthritis may demonstrate erosions with new bone formation ("pencil-in-cup").
  - Gout and CPPD can reveal tophi or chondrocalcinosis.
  - Ankylosing spondylitis shows sacroiliitis and syndesmophytes **(Fig. 8)**
- *Musculoskeletal ultrasound*: Detects *synovial hypertrophy, effusion, power Doppler signal*, and *enthesitis*, and allows guided aspiration. It is now widely used for early diagnosis and disease monitoring.
- *MRI*: Identifies *bone marrow edema, synovitis, cartilage loss, and sacroiliitis* before radiographic changes. MRI is especially valuable for early RA and axial SpA.
- *Dual-energy CT (DECT)*: Distinguishes *urate from calcium crystal deposition* and delineates erosions precisely.
- *Whole-body MRI or PET-CT*: Reserved for *systemic vasculitis, occult infection, or paraneoplastic arthritis.*

Imaging supports diagnosis and defines disease stage, but interpretation must always align with the clinical context—*treat the patient, not the scan.*

TABLE 4: Synovial fluid analysis in different types of arthritis.

Type of fluid	*WBC/mm³*	*Predominant cells*	*Examples*
Noninflammatory	<2,000	Mononuclear	OA, trauma
Inflammatory	2,000–50,000	Neutrophils 50–75%	RA, PsA, gout, CPPD, ReA
Septic	>50,000	Neutrophils >90%	Bacterial arthritis
Hemorrhagic	Variable	RBCs	Trauma, tumor, coagulopathy

(CPPD: calcium pyrophosphate deposition; OA: osteoarthritis; PsA: psoriatic arthritis; RA: rheumatoid arthritis; RBCs: red blood cells; ReA: reactive arthritis)

JAYPEE BROTHERS

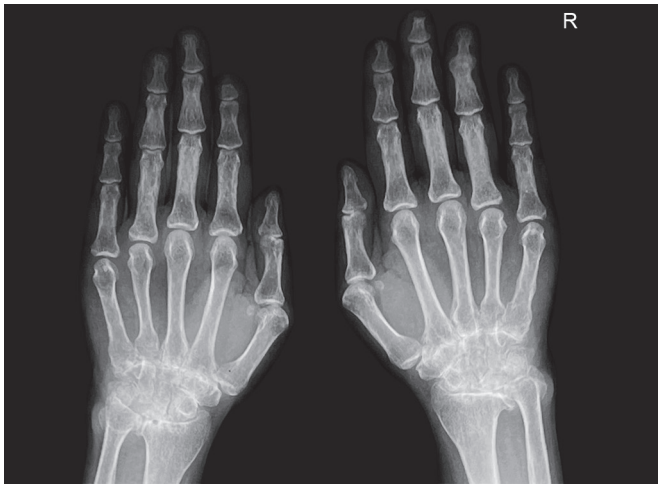

FIG. 7: Plain radiograph of the hands of a rheumatoid arthritis (RA) patient showing juxta-articular osteopenia and crowding of carpal bones.

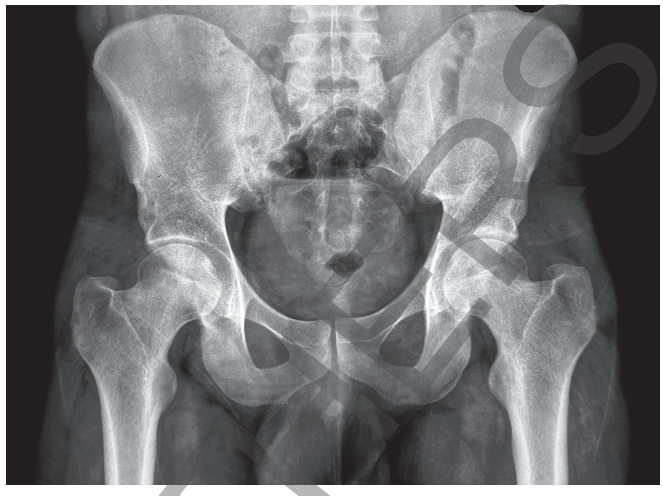

FIG. 8: Plain radiograph of the pelvis of a patient with spondyloarthritis showing bilateral sacroiliitis.

CONCLUSION

Polyarthritis may result from diverse causes—from transient viral infections to chronic autoimmune diseases. While RA is common, many patients have self-limited or noninflammatory conditions that do not require immunosuppression. The essence of evaluation lies in clinical judgment—interpreting joint patterns, systemic clues, and selective investigations in context. Modern tools such as musculoskeletal ultrasound enhance early recognition of true synovitis and guide management decisions. Above all, the clinician must resist premature labeling and maintain diagnostic flexibility, as autoimmune diseases may evolve or overlap over time.

CASE STUDIES

Case 1: Acute Polyarthritis Following Chikungunya Infection

A 38-year-old male farmer from a village presented with high-grade fever for 5 days, after which he developed pain and swelling of the wrists, knees, and ankles. The joint pain was severe enough to restrict walking and daily activities. There was no prior history of joint disease or morning stiffness. Examination revealed tender swelling of wrists and ankles with mild warmth but no deformity or nodules.

Routine investigations showed mild leukopenia, elevated ESR and CRP, and negative RF and anti-CCP antibodies. Chikungunya immunoglobulin M (IgM) antibody was positive. The patient was treated symptomatically with NSAIDs and adequate hydration. The fever subsided within a week, and the joint symptoms gradually resolved over the next 2–3 weeks without residual deformity.

Learning Point

Chikungunya arthritis is a common cause of acute polyarthritis in tropical regions. It can closely mimic early RA but is distinguished by abrupt onset, preceding fever, and spontaneous resolution without persistent synovitis or joint deformities.

Case 2: All Polyarthritis with Rheumatoid Factor Positivity is Not RA!

A 58-year-old man presented with inflammatory polyarthritis affecting the small joints of the hands and both elbows and wrists for 3 months. Examination revealed multiple tender and swollen joints affecting the proximal interphalangeal (PIP) and MCP joints. Investigation showed raised ESR, CRP, mild thrombocytosis, positive RF, and negative anti-CCP. A diagnosis of RA was made, and he was started on weekly methotrexate 15 mg. Initially, his symptoms improved, but he came to the emergency after 2 months with a history of breathlessness, cough with hemoptysis and decreased urine output for 3 days. On further probing, he gave a history of nasal crusting and occasional epistaxis for the past 6 months. He also complained of

JAYPEE BROTHERS

decreased hearing in his left ear for the past 7 months, which he ignored as an age-related problem. Investigation revealed deranged renal parameters, microscopic hematuria, and proteinuria. Chest CT showed features of alveolar hemorrhage. Serum PR3-ANCA was positive. Renal biopsy revealed pauci-immune crescentic glomerulonephritis.

He was diagnosed with GPA and started on high-dose pulse steroids and rituximab. He required hemodialysis initially for deranged renal parameters; however, he gradually improved over the next 10 days and was discharged with normal renal function.

Learning Point

RF-positive polyarthritis can be seen in many diseases like GPA, SLE, or Primary Sjögren's syndrome. A detailed and careful history and clinical examination can differentiate these diagnoses. For example, in this case, the history of nasal crusting, epistaxis and hearing loss was a clue for GPA, which was missed during initial diagnosis.

These cases underscore the diversity of causes and the importance of periodic reassessment in patients with polyarthritis.

KEY POINTS

- Not every polyarthritis is RA—always correlate serology with clinical findings.
- Avoid reflex immunosuppression; treat inflammation when proven, not presumed
- Clinical reasoning supersedes investigation results in deciding diagnosis and therapy
- Overlap and transition between autoimmune diseases are common—reassess periodically.
- Early, individualized intervention prevents irreversible joint and functional damage

SUGGESTED READINGS

1. Richie AM, Francis ML. Diagnostic approach to polyarticular joint pain. Am Fam Physician. 2003;68(6):1151-60.
2. Alpay-Kanıtez N, Çelik S, Bes C. Polyarthritis and its differential diagnosis. Eur J Rheumatol. 2019;6(4):167-73.
3. Foster ZJ, Day AL, Miller J. Polyarticular joint pain in adults: evaluation and differential diagnosis. Am Fam Physician. 2023;107(1):42-51.
4. van de Sande MGH, van Vollenhoven RF. Evaluation of Monoarticular and Polyarticular Arthritis. In: Firestein GS, McInnes IB, Koretzky GA, Mikuls TR, Neogi T, O'Dell JR (Eds). Firestein and Kelly's Textbook of Rheumatology, 12th edition. Philadelphia, PA: Elsevier; 2025. pp. 647-61.
5. Cush JJ. Approach to Articular and Musculoskeletal Disorders. In: Loscalzo J, Fauci AS, Kasper DL, Hauser SL, Longo DL, Jameson JL (Eds). Harrison's Principles of Internal Medicine, 21st edition. New York: McGraw-Hill; 2022. pp. 2844-54.
6. Hübscher O. Pattern recognition in arthritis. In: Hochberg MC, Silman AJ, Smolen JS, Wenblatt ME, Weisman MH (Eds). Rheumatology, 6th edition. Philadelphia, PA: Elsevier; 2015. pp. 225-30.

JAYPEE BROTHERS

for detailed information on rheumatology books, visit our website www.ejaypee.com, for detailed information on rheumatology books, visit our website www.ejaypee.com, for detailed inform

DECISION MAKING IN RHEUMATOLOGY

Salient Features

- A first-of-its-kind decision-making resource in rheumatology, built around real-world clinical scenarios encountered in everyday practice
- Authored by leading national experts bringing together global perspectives and contemporary best practices
- 21 comprehensive chapters covering the entire spectrum of major rheumatological disorders
- Case-based approach that emphasizes clinical reasoning, problem-solving, and evidence-informed decision-making
- Richly illustrated content with numerous figures, tables, algorithms, and flowcharts for quick understanding and easy retention
- Practical solutions to common clinical dilemmas, from diagnosis to treatment selection and long-term monitoring
- Designed for rapid bedside application for postgraduate trainees, fellows, internists, and practicing rheumatologists while also serving as a valuable reference for in-depth learning

Uma Kumar MD FRCP(Edinburgh) FNAMS is a distinguished rheumatologist and the Founder Head of the Department of Rheumatology at the All India Institute of Medical Sciences (AIIMS), New Delhi, India. A pioneer in advancing patient-centered rheumatology care in India, she has led several transformative initiatives, including the establishment of the country's Rheumatology Day Care model. Dr Kumar has mentored numerous postgraduate and doctoral trainees, led multiple research collaborations, and contributed extensively to scientific publications and academic books over the last three decades at AIIMS, New Delhi. She is the recipient of several national and international awards, including the prestigious National Award for Science and Technology Communication by Government of India, in recognition of her contributions to science and technology. She continues to actively promote excellence in clinical practice, education, and research in rheumatology.

Siddharth Jain MD DM is a rheumatologist and clinical immunologist currently working as Assistant Professor in the Department of Medicine at the All India Institute of Medical Sciences (AIIMS), New Delhi, India. An alumnus of AIIMS, New Delhi (MBBS, MD), and PGIMER, Chandigarh (DM), he is a gold medalist and recipient of several prestigious national and international academic distinctions, fellowships, and research accolades. He has authored over 75 peer-reviewed publications and continues to lead several funded research projects. A committed clinician-educator, Dr Jain is actively involved in mentoring undergraduate and postgraduate students and fostering interest in rheumatology through innovative teaching, academic quizzes, and research mentorship.

Shelving Recommendation
RHEUMATOLOGY

ISBN 978-81-69781-60-2

Buy from ejaypee

JAYPEE BROTHERS

JAYPEE BROTHERS