With Interactive CD ROM

Anatomical Principles of Endoscopic Sinus Surgery: A Step by Step Approach







Renuka Bradoo

Foreword
MV Kirtane

JAYPEE

Anatomical Principles of Endoscopic Sinus Surgery: A Step by Step Approach

Renuka Bradoo
MS DORL
Professor and Head
Department of ENT
and
Head and Neck Surgery
Lokmanya Tilak Municipal Medical College
and General Hospital
Sion, Mumbai

JAYPEE BROTHERS
MEDICAL PUBLISHERS (P) LTD
New Delhi

JAYPEE BROTHERS

Index for VCD (Endoscopic Anatomy)

1. Diagnostic Endoscopy
2. Uncinectomy and Maxillary Sinus
3. Dissection of Frontal Recess (Intact Bulla Technique)
4. Anterior Ethmoidectomy
5. Further Dissection of the Frontal Recess
6. Perforation of the Ground Lamella and Posterior Ethmoidectomy
7. Approaches to the Sphenoid
    - Lateral Approach
    - Intermediate Approach
    - Medial Approach
8. Nasolacrimal System

JAYPEE BROTHERS

Contents


1. Embryology 3


2. Osteology 13


3. The Lateral Nasal Wall 31


4. Endoscopic Anatomy 59

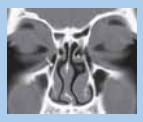
5. Radiological Anatomy 73

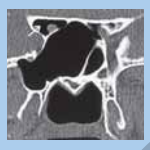
6. Anatomical Variations 89


7. Surgical Anatomy 109

In Conclusion ... 115

Index 117

JAYPEE BROTHERS

Abbreviations

A	Atrium
AEA	Anterior ethmoid artery
AEC	Anterior ethmoid cell
Ag	Agger nasi
AO	Accessory ostium
B	Bulla ethmoidalis
CG	Crista galli
EO	Eustachian tube opening
FS	Frontal sinus
FI	Frontal infundibulum
FO	Frontal ostium
FR	Frontal recess
GL	Ground lamella
HSI	Hiatus semilunaris inferioris
HSS	Hiatus semilunaris superioris
I	Infundibulum
ICA	Internal carotid artery
IT	Inferior turbinate
LP	Lamina papyracea
MO	Maxillary ostium
MR	Medial rectus
MS	Maxillary sinus
MT	Maxillary turbinate
NLD	Nasolacrimal duct
ON	Optic nerve
PEA	Posterior ethmoid artery
PEC	Posterior ethmoid cell
Pit	Pituitary
PPF	Pterygopalatine fossa
S	Septum
SER	Sphenoethmoidal recess
SL	Sinus lateralis
SO	Sphenoid ostium
SS	Sphenoid sinus
ST	Superior turbinate
U	Uncinate process
V	Vestibule

JAYPEE BROTHERS

3 The Lateral Nasal Wall

Having studied the underlying osteology in the previous chapter, we will now re-articulate all the bones to form an intact lateral nasal wall and cover it with nasal mucosa. Thus due to the underlying bony processes and their articulation, the lateral nasal wall in the live person shows a series of elevations and depressions. We will study these in a sequential manner.

1. Anteriorly in the area of the nostril, the lateral nasal wall is lined by skin and has hair; this is the vestibule (Figs 3.1A and B). Behind this is a plain structureless area lined by nasal mucosa called the atrium. The atrium shows

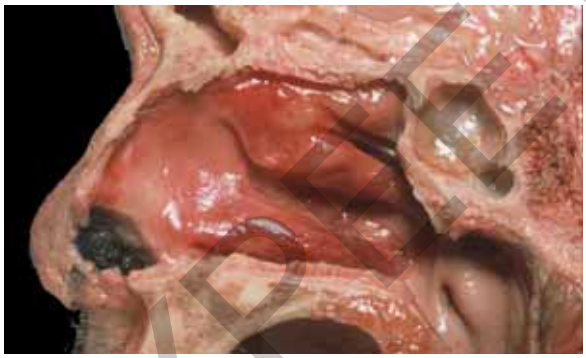

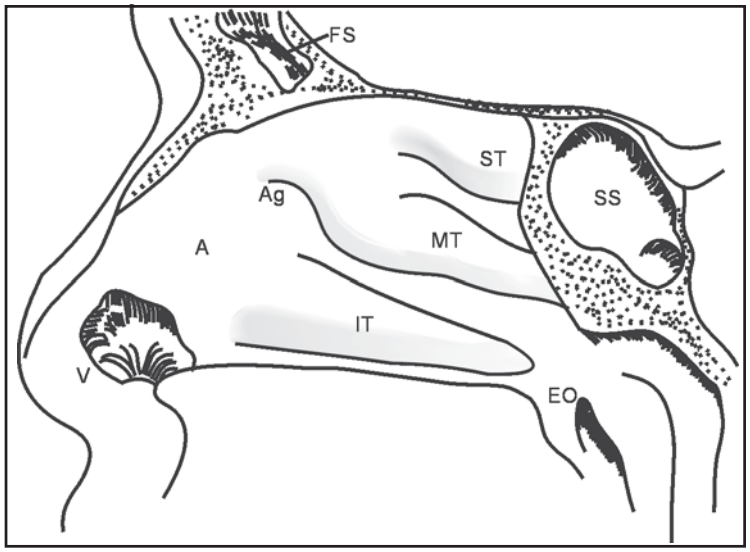

Figs 3.1A and B: The lateral nasal wall

JAYPEE BROTHERS

a bulge anterior to the middle turbinate formed by the underlying agger nasi cell. Very often a ridge can be discerned extending from the agger nasi cell to an apex on the superior border of the inferior turbinate. This ridge overlies the nasolacrimal duct.

Behind the atrium are the three scrolls of the inferior, middle and superior turbinates, overlying the respective meatii. Occasionally, there may be a supreme turbinate. Above the superior turbinate is the sphenoethmoidal recess, which gets its name from the fact that this area forms a niche between the posterior ethmoid cells and the sphenoid sinus.

Certain other important features seen are:

- The inferior turbinate is fairly straight and structureless as compared to the middle turbinate, which is convoluted showing many features and anatomical variations.
- The posterior end of the middle turbinate ends at the level of the roof of the posterior choana.
- The eustachian tube lies in the nasopharynx at the level of the inferior turbinate 1 cm behind its posterior attachment. The fossa of Rosenmueller forms a deep cleft behind the torus tubaris.

A close up view of the skull base in the anterior cranial fossa shows (Fig. 3.2):

- The base skull sloping downwards from an anterior to posterior direction at an angle of 15 .
- The olfactory nerves can be seen perforating the cribriform plate.
- The frontal sinus is seen between the two tables of the frontal bone. Anteroinferior to the frontal sinus is the thickened frontal beak.
- The pituitary gland lies posterosuperior to the sphenoid sinus. The relationship of the pituitary and optic nerves to the sphenoid sinus is best seen in the well-pneumatized sellar type of sphenoid sinus. One can also see that the anterior wall of the sphenoid is thicker inferiorly than superiorly.

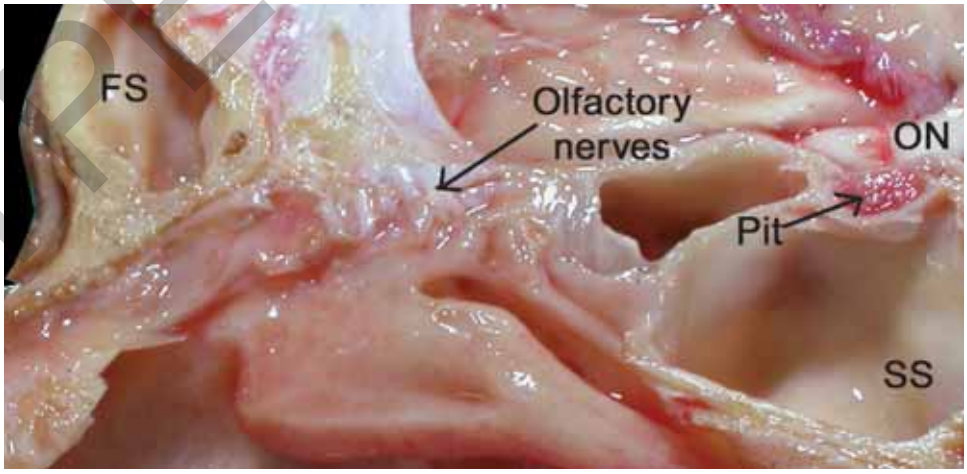

Fig. 3.2: A close up of the base of the skull in the anterior cranial fossa

JAYPEE BROTHERS

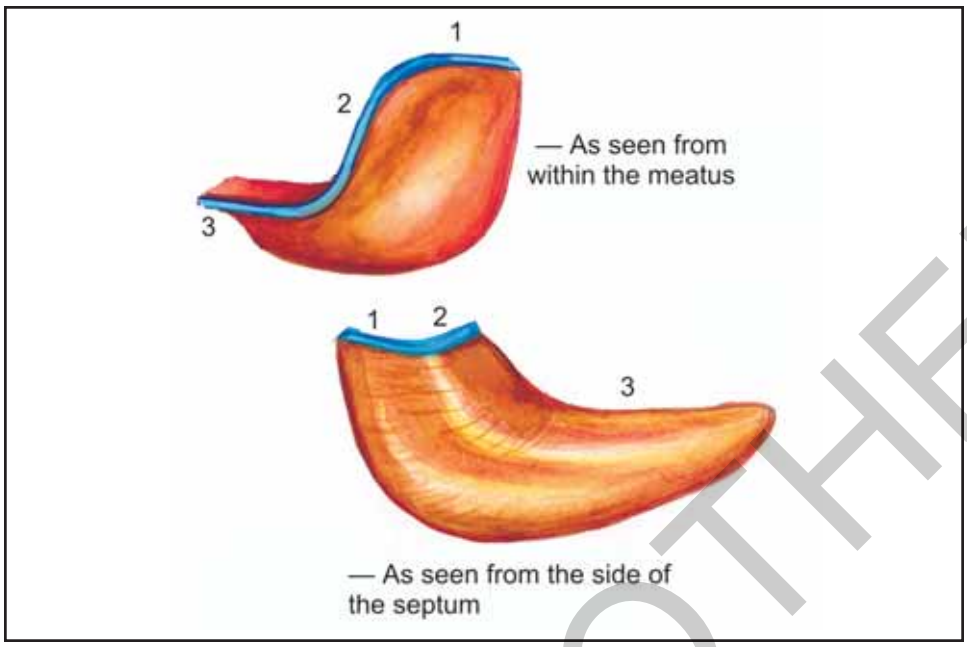

Fig. 3.3: Attachments of middle turbinate (1) to cribriform plate and frontonasal process of the maxilla, (2) to lamina papyracea, (3) to perpendicular plate of palatine

2. The middle turbinate is a convoluted structure bending in different planes similar to a dried leaf. It can be divided into three parts, depending on its attachment and its orientation in the three-dimensional space (Fig. 3.3).

- The anterior one-third is in the sagittal plane and is attached to the cribriform plate at the junction of the medial and lateral lamellae. It also takes a small anterior attachment to the frontonasal process of the maxilla.
- The middle one-third lies in the coronal plane and is attached to the lamina papyracea. It separates the anterior ethmoidal cells from the posterior ethmoidal cells. Since it stabilizes the middle turbinate, it is called the ground lamella or the basal lamella.
- The posterior third lies in the horizontal plane and is attached to the lamina papyracea and the perpendicular plate of the palatine bone extending upto the roof of the posterior choana.

3. A window is cut in the middle turbinate to view the relationship of structures within the middle meatus (Figs 3.4A and B). Most anteriorly is a curved ridge called the uncinate process. Behind this is the well pneumatized and most constant anterior ethmoidal cell, namely the ethmoidal bulla. These structures are separated by a semilunar groove called the hiatus semilunaris. The hiatus semilunaris is two-dimensional and leads into a three-dimensional space called the infundibulum.

The uncinate process, the bulla and the intervening infundibulum form the key area or the osteomeatal unit into which the frontal, the maxillary and anterior ethmoidal sinuses drain.

JAYPEE BROTHERS

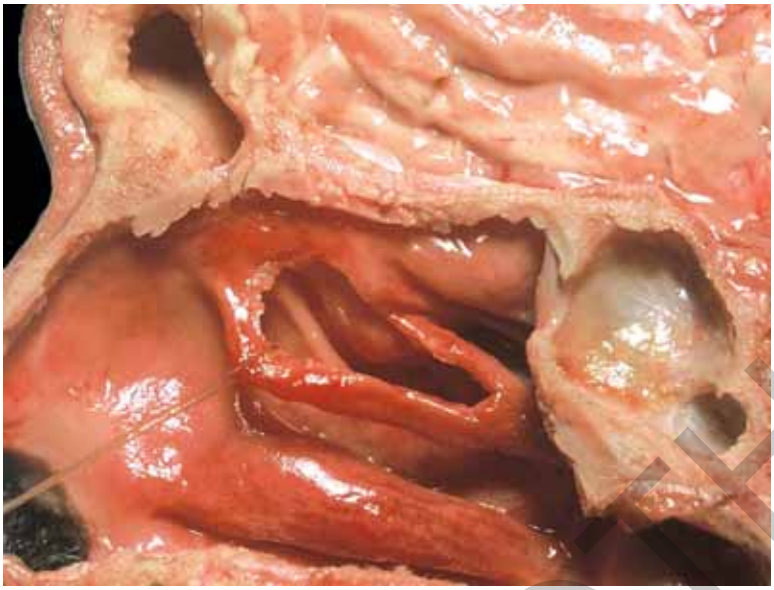

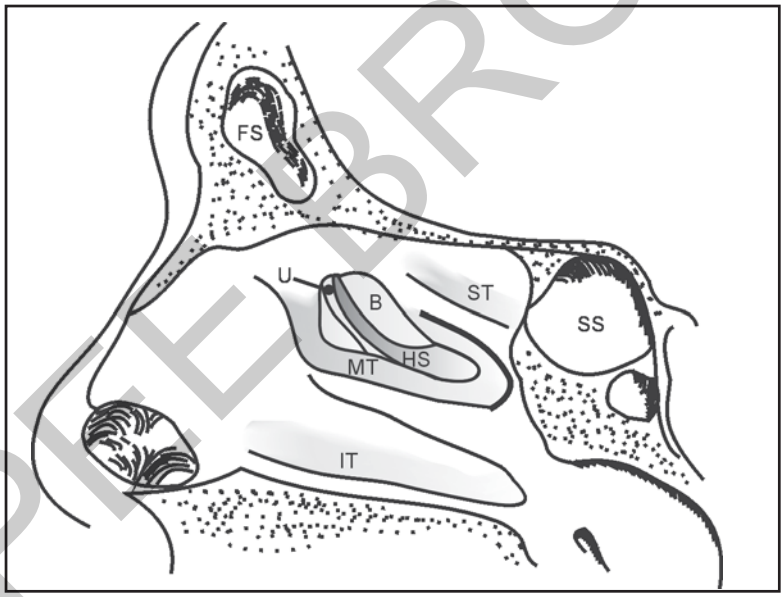

Figs 3.4A and B: The osteomeatal unit

JAYPEE BROTHERS

Coronal and axial sections through the osteomeatal unit show the relationship between its components (Figs 3.5A and B).

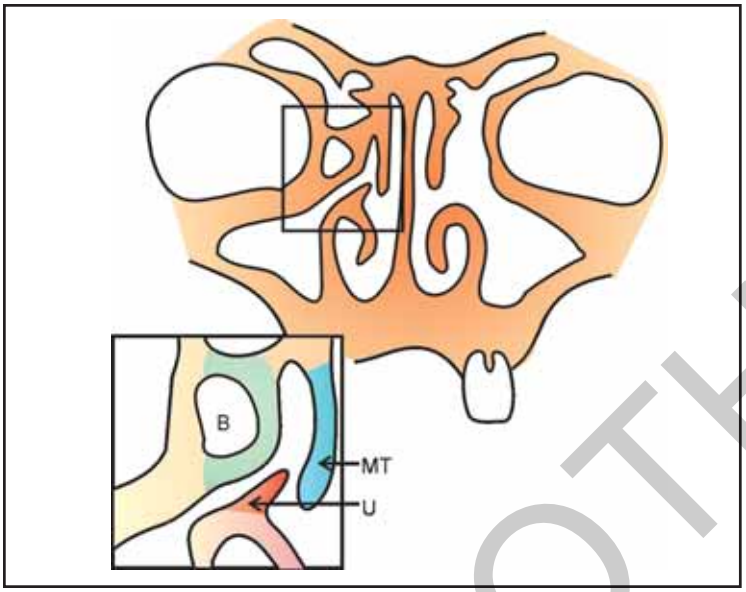

Fig. 3.5A: Coronal section of the osteomeatal unit

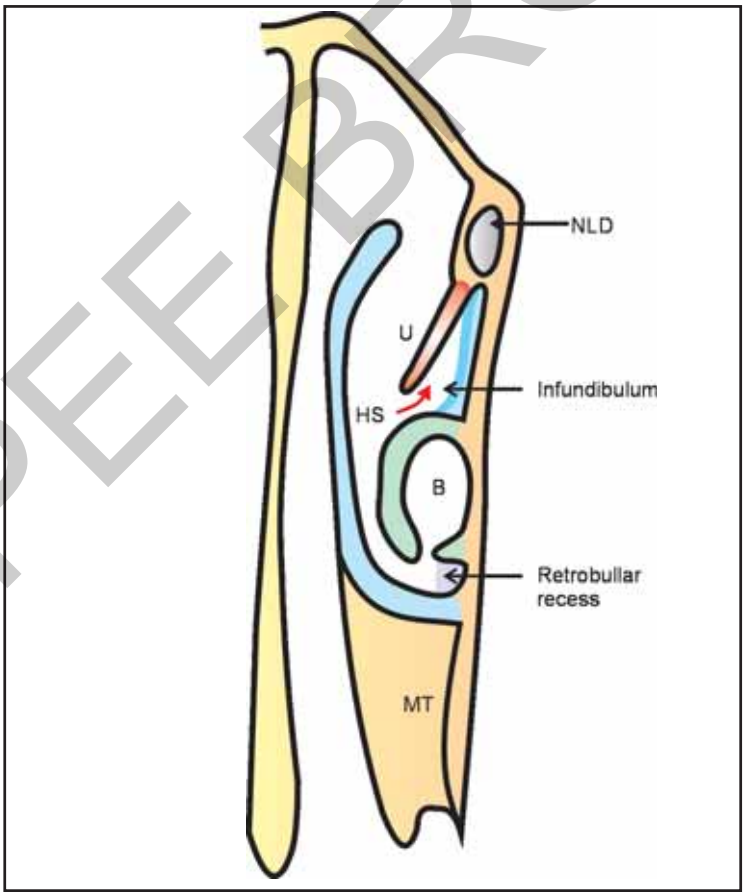

Fig. 3.5B: Axial section of the osteomeatal unit

JAYPEE BROTHERS

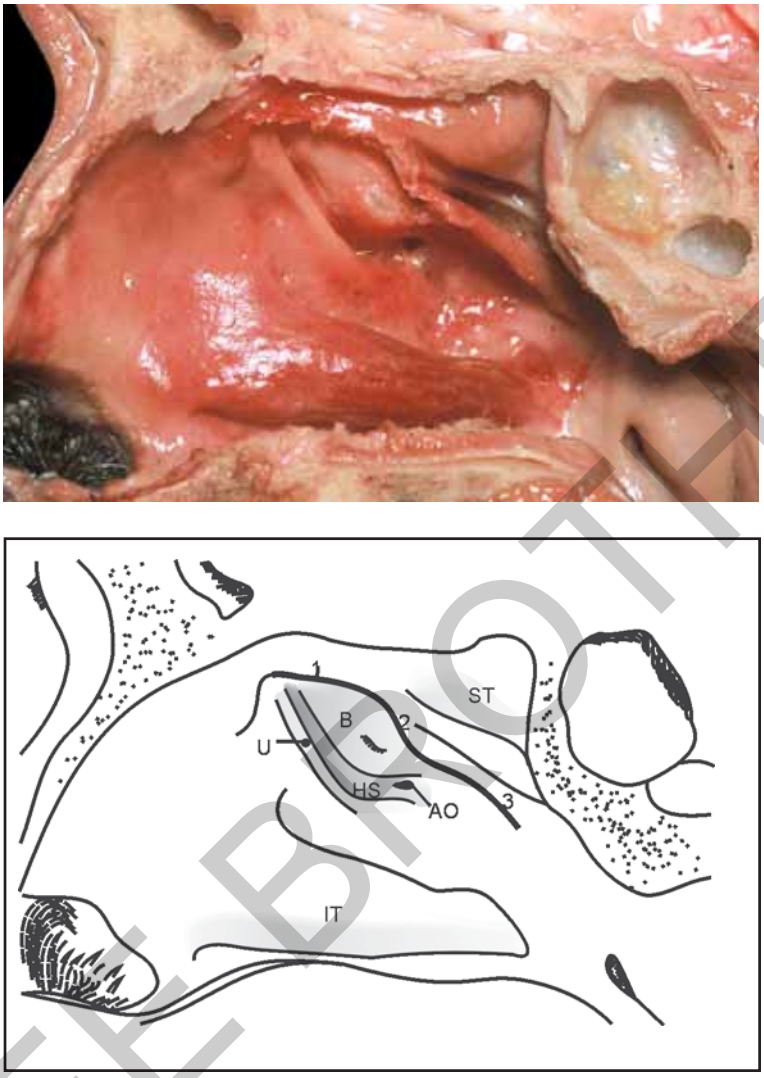

Figs 3.6 A and B: (1) Anterior attachment of middle turbinate to cribriform plate. (2) Middle attachment (ground lamella) to lamina papyracea. (3) Posterior attachment to perpendicular plate of palatine bone. An accessory ostium is seen in the hiatus semilunaris

4. The middle turbinate is trimmed. Its anterior, middle and posterior attachments, which have been described earlier are now obvious. The structures within the middle meatus are now seen more clearly (Figs 3.6A and B).

The uncinate process is sickle shaped. It has a vertical and a horizontal limb with an intermediate transitional part.

The ethmoidal bulla is usually a well pneumatized, most constant, anterior ethmoidal cell. Rarely (8%) the bulla may be rudimentary or absent. It is separated posteriorly from the ground lamella of the middle turbinate by a recess called the retrobullar recess (Fig. 3.7). Occasionally the bulla does not extend upto the base of the skull and is separated from it by the suprabullar recess. The retrobullar and suprabullar recesses together form a semilunar space

JAYPEE BROTHERS

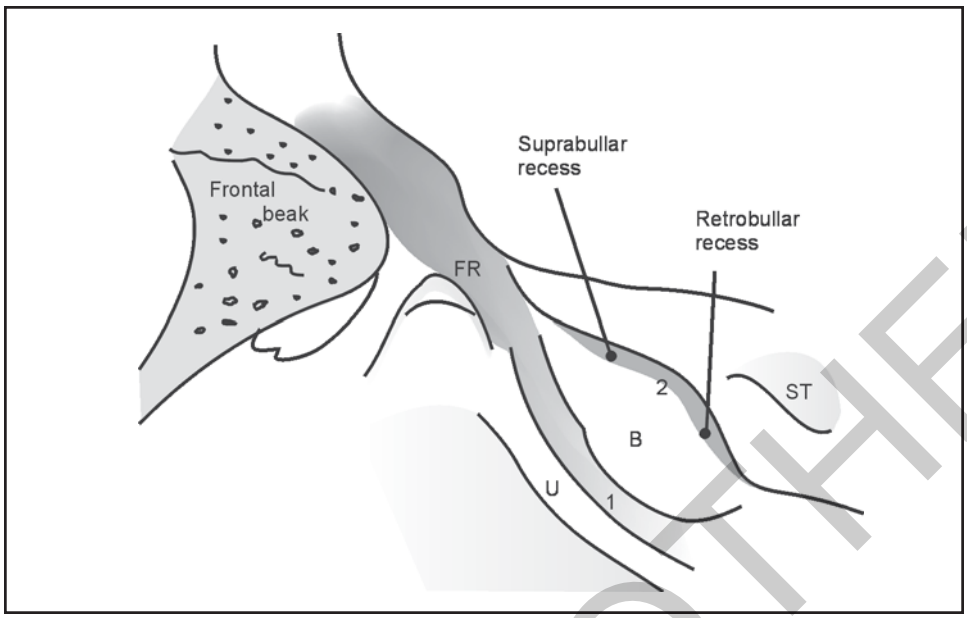

Fig. 3.7: The suprabullar and retrobullar recesses: (1) The hiatus semilunaris inferoris, (2) the hiatus semilunaris superioris

above and behind the bulla called the sinus lateralis of Grunwald. This sinus opens into the middle meatus by a semilunar cleft which is opposite in orientation to the hiatus semilunaris and is called the hiatus semilunaris superioris. Thus the hiatus semilunaris inferioris leads into the infundibulum and the hiatus semilunaris superioris leads into the sinus lateralis of Grunwald.

The roof of the sinus lateralis is formed by the ethmoid fovea and its floor by the ethmoidal bulla. It is limited posteriorly by the ground lamella of the middle turbinate and anteriorly it opens into the frontal recess. Laterally is the lamina papyracea and medially is the middle turbinate. The hiatus semilunaris superioris is absent when the bulla is attached either to the base skull superiorly or to the ground lamella posteriorly.

5. The infundibulum leads directly or indirectly into the frontal recess (Figs 3.8A and B). The frontal recess has been the subject of many debates due to the fact that it shows variations in anatomy and requires special skill to approach it surgically.

- The frontal recess is bounded anteriorly by the agger nasi cell, which is considered to be a part of the frontal recess. Therefore the anterior wall of the frontal recess is formed by the anterior wall of the agger nasi cell.
- The posterior wall is formed by the bulla ethmoidalis. If there is a suprabullar recess it will open into the posterior wall of the frontal recess.
- The lateral wall of the frontal recess is formed by the lamina papyracea.
- The medial wall is formed by the middle turbinate.
- Superiorly the frontal recess opens via the frontal ostium into the frontal sinus. Seen from above the frontal sinus opening is funnel shaped and is placed at the posterior and medial end of the floor of the frontal sinus. This funnel shaped region is called the frontal infundibulum. Thus in sagittal

JAYPEE BROTHERS

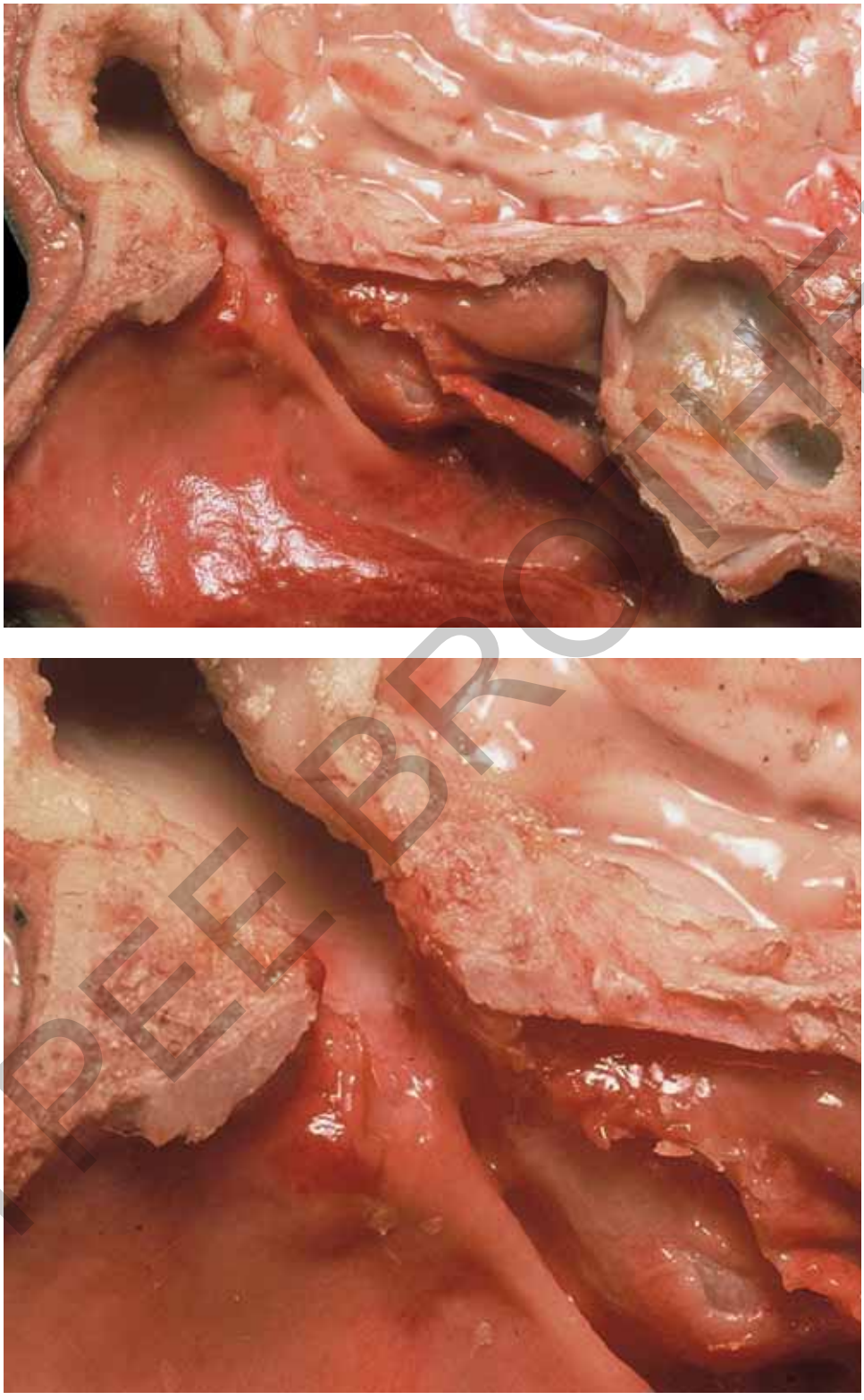

Figs 3.8A and B: (A) The frontal recess, (B) A close up view of the frontal recess showing its boundaries and contents

JAYPEE BROTHERS

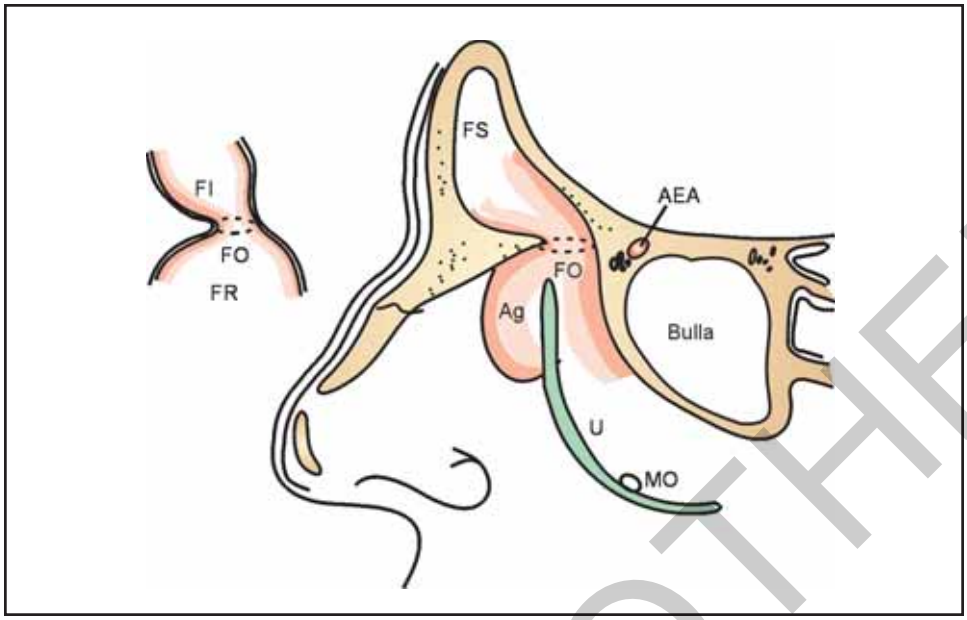

Fig. 3.9: Schematic representation of the frontal recess (note the hour-glass configuration)

cross-section the frontal infundibulum, frontal ostium and the frontal recess together form the ***"hour-glass configuration"*** so often described (Fig. 3.9)

Thus, the frontal sinus lies far more anterior to the frontal recess when seen endoscopically.

The upper end of the uncinate process lies within the frontal recess. It shows great variation in anatomy. It can

— extend upto the base skull.
— attach to the middle turbinate.
— may turn forwards to be attached to the insertion of the middle turbinate.
— lie free in the middle meatus.
— may be pneumatized.

Most commonly (80%) it attaches to the lamina papyracea in the form of a dome. This upper dome shaped attachment of the uncinate process within the frontal recess has been graphically described by Stammberger as an eggshell in an inverted egg-cup. The recess, which is enclosed within this dome, is called the recessus terminalis (Figs 3.10A and B). In this case the frontal sinus opens medial to the uncinate process.

The components and contents of the frontal recess are extremely variable:

- The agger nasi cell may be small or large, single or multiple and rarely absent.
- The bulla may be small or large, extending upto base skull or stopping short at the suprabullar recess.
- The upper end of the attachment of the uncinate process has many variations, as already described.

JAYPEE BROTHERS

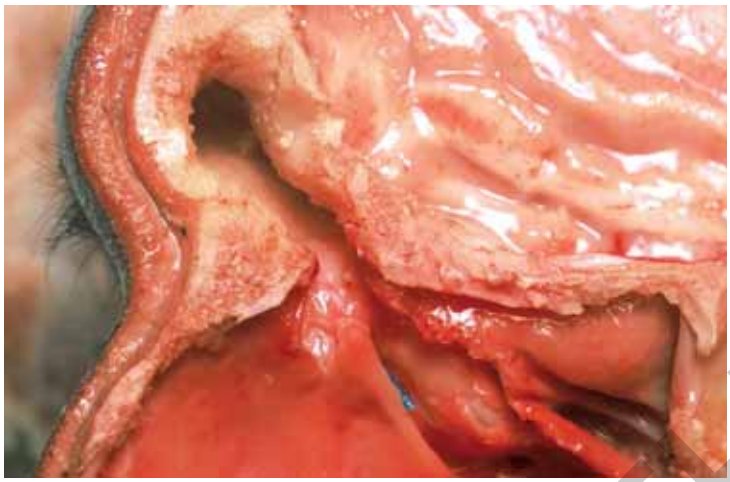

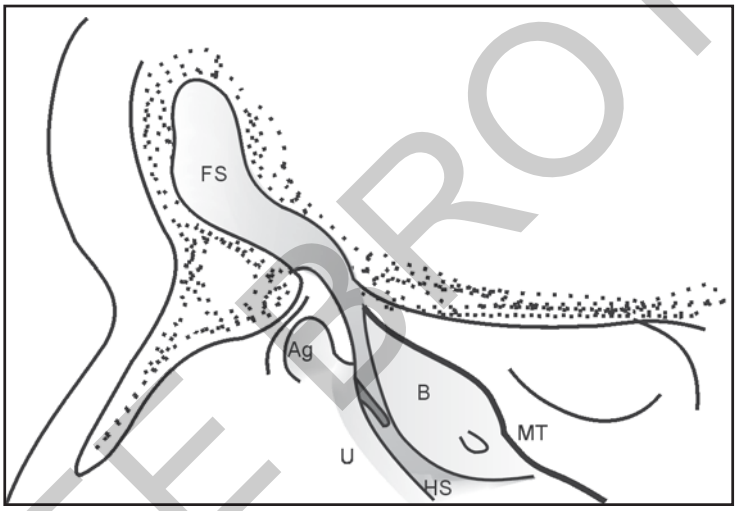

Fig. 3.10A and B: A blue probe inserted in the hiatus semilunaris cannot enter the frontal sinus as it is obstructed by the recessus terminalis

- The anterior ethmoidal cells may migrate anterosuperiorly into the frontal recess to produce different types of **frontal cells** viz

Type I A single cell above the agger nasi cell (Figs 3.11A and B).
Type II Two or more cells above the agger nasi cell.
Type III A large cell extending well into the frontal sinus mimicking the frontal sinus itself (frontal bulla).
Type IV An isolated **"loner cell"** separately within the frontal sinus.

JAYPEE BROTHERS