Clinical Manual for Oral Medicine and Radiology






Ravikiran Ongole
Praveen BN

Forewords
Keerthilatha M Pai
NS Yadav

JAYPEE

CONTENTS

SECTION-1 ORAL MEDICINE

1. Case History **3**
2. Evaluation of Patients with Special Care Needs **55**
3. Evaluation of Gingival and Periodontal Diseases **87**
4. Evaluation of Pulp and Periapical Diseases **104**
5. Examination of Ulcers and Swellings of the Orofacial Region **120**
6. Evaluation of Oral Precancers and Oral Cancers **138**
7. Evaluation of Fractures of Maxillofacial Skeleton **163**
8. Evaluation of Lymph Nodes of the Head and Neck Region **177**
9. Examination of Temporomandibular Joint **195**
10. Assessment of Orofacial Pain **213**
11. Examination of Salivary Glands **226**
12. Examination of Maxillary Sinus **238**

SECTION-2 RADIOLOGY

13. X-ray Machine and Production of X-rays **253**
14. Radiation Hazards and Protection **269**
15. Image Receptor Systems **293**
16. Projection Techniques **303**
17. Processing Technique **349**
18. Radiographic Faults **362**
19. Normal Radiographic Anatomical Landmarks **374**
20. Interpretation of Radiographs **393**
21. Specialized Imaging Techniques **405**

Appendices

Oral Medicine *443*

Radiology *531*

Index *543*

JAYPEE BROTHERS



Evaluation of Pulp and Periapical Diseases

Dental caries is considered as one of the most common infectious diseases affecting the human race which is also the commonest cause for pulpal inflammation.

A common source of infection of the jaws is inflammatory disease of the pulp. Other causes include infections from the periodontal ligament, wasting diseases (attrition, abrasion, erosion), extraction wounds, compound fractures and rarely from hematogenous infection.

Dental caries is defined as a microbial disease of the calcified tissues of the teeth characterized by demineralization of the inorganic portion and destruction of the organic structure of the tooth.

CLINICAL CLASSIFICATION OF DENTAL CARIES

1. Depending on the location on the individual tooth:
   A. Type
      - Pit and fissure caries
      - Smooth surface caries
   B. Site involved
      - Occlusal caries
      - Proximal caries
      - Facial, buccal and lingual caries
      - Root surface caries.
2. Depending on the rapidity of the process
   A. Duration
      - Acute dental caries
      - Chronic dental caries

JAYPEE BROTHERS

B. Progression
   - Incipient lesions
   - Moderate lesions
   - Severe lesions

3. Depending on whether the lesion is a new one or attacking a previously carious surface
   - Primary caries (virgin)
   - Recurrent caries (secondary)
4. Other form of dental caries
   - Rampant caries
   - Nursing bottle caries
   - Radiation caries

CLINICAL EXAMINATION OF THE CARIES LESION

Dental caries is diagnosed by the following
- Visual examination–tooth surface texture or color
- Tactile examination–with an explorer which is used judiciously
- Transillumination
- Radiographs

Other newer techniques include electrical conductance and laser fluorescence tests.

Clinical Features

Patient's age, dental history, oral hygiene and diet may suggest a clinical pattern of caries activity and susceptibility.

Dental caries usually tend to occur bilaterally and on adjacent proximal surfaces. If caries is found on the occlusal surface and a proximal surface in one tooth on one side of the arch, then chances are increased that it will occur in the same locations on the opposite side. If caries is found on the proximal surface of one tooth, then the adjacent tooth's proximal surfaces may also be involved. In the clinical examination for dental caries every assessable surface of each tooth must be examined for localized changes in color, texture, and translucency.

JAYPEE BROTHERS

Caries is most prevalent in the faulty pits and fissures of the occlusal surfaces, where developmental lobes of the posterior teeth fail to coalesce, partially or completely. Fissures and pits are detected visually.

Earlier sharp explorers were used to detect the fissure caries. However in recent times it is strongly discouraged as it was found to fracture enamel and serve as a source for transferring pathogenic bacteria among various teeth. It was also noted that the use of an explorer did not increase diagnostic validity compared to visual examination.

The occlusal surface is examined visually. It is conducted in a dry, well-illuminated field. Through direct vision or reflecting light, the occlusal surface is diagnosed as diseased if there is chalkiness or apparent softening, cavitation of the tooth structure forming the fissure or pit or brown gray discoloration radiating peripherally from the fissure or a pit. Care should be taken to distinguish between the superficial staining and the carious lesion.

Precarious or carious pits are occasionally present on cusp tips. Carious pits and fissures also occur on the occlusal two thirds of the facial or lingual surface of the posterior teeth and on the lingual surface of maxillary incisors. Occlusal enamel can be evaluated for loss of translucency and change in color, which are characteristics of caries. Care should be taken to rule out extrinsic stains.

Proximal surface caries is usually diagnosed radiographically. Clinically when caries have invaded the proximal surface enamel and dentin, a white chalky appearance or a shadow under the marginal ridge may be seen. Careful probing with an explorer on the proximal surface may detect cavitation, which is defined as a break in the surface contour of enamel. Proximal caries can also be detected by tooth separation or through transillumination. Brown spots on intact hard proximal surface enamel adjacent to and usually gingival to the contact area are often seen in older patients whose caries activity is low. Such a spot is no longer carious and in fact are more resistant to

JAYPEE BROTHERS

caries as a result of fluorhydroxyapatite formation. Restorative treatment is not indicated for such lesions.Visual inspection, probing, and transillumination may identify proximal surface caries in anterior teeth. Transillumination is accomplished by placing the mirror or light source on the lingual side of the anterior teeth and directing the light through the teeth.

Another form of smooth surface caries often occurs on the facial and lingual surfaces of the teeth, particularly in the surfaces covered by gingiva that are less accessible for cleaning. The earliest clinical evidence of incipient caries on these surfaces is a white spot that is visually different from the adjacent translucent enamel and will partially or totally disappear on wetting. Drying again will cause it to reappear. This disappearing reappearing phenomenon distinguishes the smooth incipient caries from the white spots resulting from nonhereditary enamel hypocalcificaton.

In patients with periodontal pockets, care must be taken to inspect for root surface caries. Carious lesion occurs on the cemental surfaces of the teeth. Active root caries is detected by the presence of softening and cavitation.

The presence of several facial or lingual smooth surface carious lesions within the patient's dentition suggests a high caries rate. In a caries susceptible patient the gingival third of the facial surfaces of maxillary posterior teeth and the gingival third of the facial and lingual surfaces of the mandibular posterior teeth should be evaluated carefully because these teeth are at a greater risk for caries. Advanced smooth surface caries will exhibit discoloration and demineralization and will feel soft to penetration by the explorer. The discoloration may range from white to dark brown, with rapidly progressive caries usually being light in color. With slowly progressive caries in a patient with low caries activity, darkening occurs over time because of extrinsic staining and remineralization of decalcified structure occasionally may harden the lesion. Such an arrested lesion may at times be rough, although cleanable and a restoration is

JAYPEE BROTHERS

not indicated except for esthetic reasons. The dentin in an arrested remineralized lesion is termed eburnated or sclerotic dentine.

Regardless of the location or type of carious lesions, a careful, thorough clinical examination is critical in the diagnosis of caries and for confirmation of radiographic evidence of the disease.

SEQUELAE OF DENTAL CARIES

The initial lesion may appear as an opaque white or brown spot beneath the plaque layer. As the carious lesion advances it invades, involves pulp the dentin and then involves the pulp.

Depending on the condition of the associated tooth/ teeth, the infectious products from the diseased pulp may be released from the tooth into the oral cavity or to the periapex. If the infected tooth continues to drain into the oral cavity it will remain asymptomatic and cause no detectable pathologic response. If however the infectious agents or their degradation products from the infected pulp reach the periapical connective tissue, the reaction they elicit will depend on their nature and amount and the resistance of the host.

Enamel Caries: (Figure 4.1)

Chief complaint: Food lodgment, decayed tooth, occasional sensitivity.

On examination: Discoloration, cavity formation, may not be deep enough for probing depth. Caries lesions of the proximal surfaces of teeth show fraying of the dental floss.

Clinical diagnosis: Enamel caries

Radiographic finding: Diffuse radiolucency involving enamel (need not necessarily be shown on all radiographs as a minimum of 40% demineralization is required to be evident on a radiograph).

Treatment plan: Restoration.

JAYPEE BROTHERS

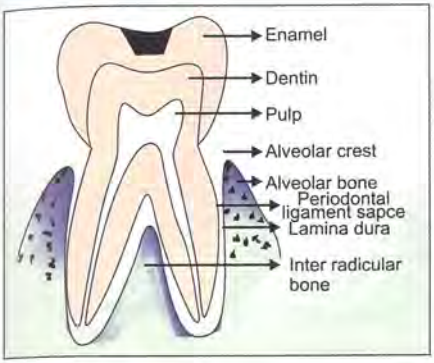

Figure 4.1

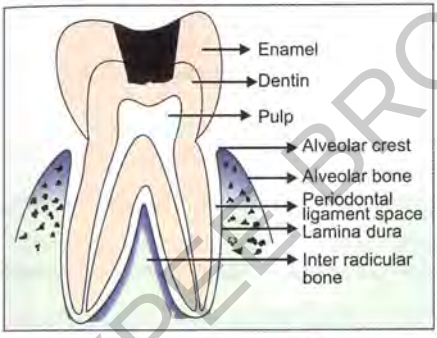

Figure 4.2

Dentinal Caries (Figure 4.2)

Chief complaint: Food lodgment, decayed tooth, sensitivity for heat/cold *only* on stimulus.

On examination: Discoloration, cavity formation, may be sensitive to probing. *Non tender* on vertical percussion. Carious lesions of the proximal surfaces of teeth show fraying of the dental floss.

Clinical diagnosis: Dentinal caries

Radiographic finding: Diffuse radiolucency involving dentin.

Treatment plan: Restoration.

JAYPEE BROTHERS

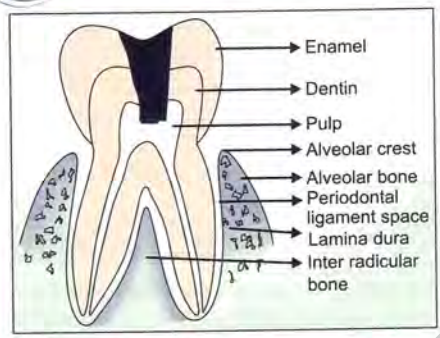

Figure 4.3

Irreversible Pulpitis (Figure 4.3)

Chief complaint: Continuous pain, severity of pain depends on duration or due to exacerbation of chronic lesion. Pain may be described as lancinating, throbbing or pricking. Pain increases on lying down.

On examination: Deep cavity formation, may show pulpal involvement

The offending tooth will be non-tender on vertical percussion.

Clinical diagnosis: Acute/Acute exacerbation of chronic/ chronic irreversible pulpitis.

Radiographic finding: Diffuse radiolucency involving pulp.

Treatment plan: Root canal therapy.

Apical Periodontitis (Figure 4.4)

Chief complaint: Similar to irreversible pulpitis.

On examination: Similar to irreversible pulpitis with one additional finding, i.e. tooth will be tender on vertical percussion.

Clinical diagnosis: Acute/acute exacerbation of chronic/chronic apical periodontitis

Radiographic finding: Diffuse radiolucency involving pulp with widening of periodontal ligament space at the periapex

JAYPEE BROTHERS

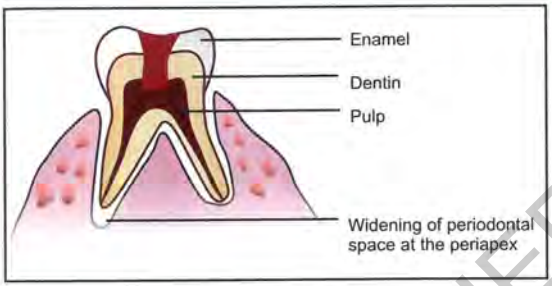

Figure 4.4

Note: Acute apical periodontitis will generally not reveal any periapical radiographic changes. Periapical radiographic changes can be appreciated only in chronic lesions as it requires three to four weeks to appreciate the changes on the radiograph.

Periapical Abscess (Figure 4.5)

Chief complaint: Similar to irreversible pulpitis

On examination: Similar to apical periodontitis with one additional finding, i.e. vestibular tenderness

Radiographic finding: Similar to apical periodontitis with one additional finding, i.e. diffuse periapical radiolucency or discontnuity of lamina dura at the periapical region of the tooth.



Figure 4.5

JAYPEE BROTHERS

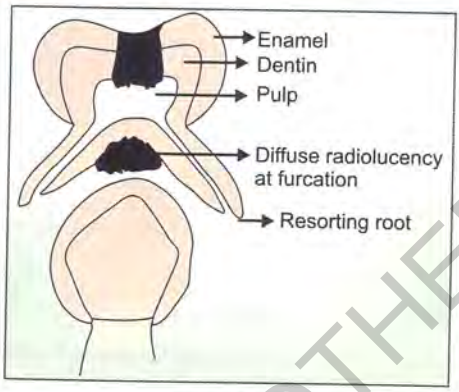

Figure 4.6

Dento-alveolar Abscess

Chief complaint: Similar to irreversible pulpitis with a complaint of extraoral swelling.

On examination: Extraoral swelling. Location depending on the offending tooth.
Intraoral examination is similar to periapical abscess with one additional finding ie vestibular obliteration.

Radiographic finding: similar to periapical abscess.

Furcal Abscess (Figure 4.6)

Commonly seen in deciduous teeth. It is due to infection spreading into the furcation area as the infection spreads to the area of least resistance, via the accessory/lateral canals.

Chief complaint: Similar to irreversible pulpitis

On examination: Dental caries involving pulp, generally swelling is noticed in the attached gingiva, No vestibular obliteration.

Radiographic finding: Diffuse radiolucency in the furcation area. Resorption of the roots.

JAYPEE BROTHERS



Figure 4.7

Cellulitis: The only feature that differentiates cellulitis from dento-alveolar abscess is the diffuse extraoral swelling. The swelling involves fascial spaces depending upon the drainage of the offending tooth (e.g: buccal, submandibular, sub-massetric space, etc.) (Figure 4.7).

Table 4.1: Common sites of localisation of acute dental infections

Tooth involved	*Usual site of exit of infection from the bone*	*Relation of muscle attachment to root apices*	*Site of localisation of the infection*
Upper central incisor	Labial	Above	Oral vestibule
Upper lateral incisor	Labial Palatal	Above	Oral vestibule Palate
Upper canine	Labial	Above Below	Oral vestibule Canine space
Upper premolars	Buccal Palatal	Above	Oral vestibule Palate
Upper molars	Buccal Palatal	Above Below	Oral vestibule Buccal space Palate
Lower incisors	Labial	Above Below	Submental Space Oral vestibule

Contd...

JAYPEE BROTHERS

Contd...

Tooth involved	*Usual site of exit of infection from the bone*	*Relation of muscle attachment to root apices*	*Site of localisation of the infection*
Lower canine	Labial	Below	Oral vestibule
Lower Premolars	Buccal	Below	Oral vestibule
Lower 1st molar	Buccal	Below	Oral vestibule
	Lingual	Above	Buccal space
		Below	Sublingual space
Lower 2nd molar	Buccal	Below	Oral vestibule
	Lingual	Above	Buccal space
		Below	Sublingual space
		Above	Submandibular space
Lower 3rd molar	Lingual	Above	Submandibular space
			Pterygomandibular space

Ludwigs-angina

Ludwigs-angina is a type of cellulitis, which involves submandibular, sub-lingual, sub-mental spaces, crosses the midline to the other side of the face. The significant clinical finding is the raise of the floor of the mouth (Figure 4.8).

Patient may complain of difficulty in swallowing and severe cases may have difficulty in breathing.



Figure 4.8

JAYPEE BROTHERS

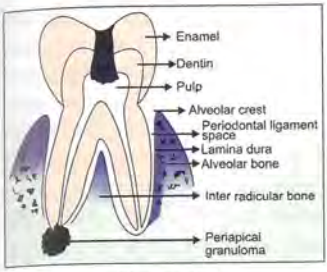

Figure 4.9

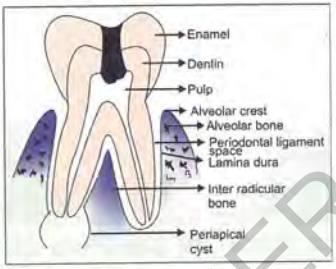

Figure 4.10

Periapical Granuloma (Figure 4.9)

It is a radiographic diagnosis.

Chief complaint: similar to irreversible pulpitis.

On examination: similar to chronic periapical abscess

Radiographic finding: well defined radiolucency at the periapex measuring less than 1.5 centimeters in diameter

(It is rarely large enough to cause cortical expansion).

Periapical Cyst

Chief complaint: Similar to chronic irreversible pulpitis, it may show acute signs if it gets infected.

On examination: If the cyst is large enough an intraoral swelling is appreciated. Usually it is firm in consistency with areas of decortication.

Radiographic finding: well defined radiolucency with sclerotic border, which measures more than 1.5 centimeters in diameter (Figure 4.10).

(The sclerotic response is mark of chronicity.)

Note: In order to confirm whether the lesion is a cyst or granuloma histopathological examination has to be carried out. However, the sclerotic border is generally not evident in cysts that are secondary infected.

Osteomyelitis

Osteomyelitis is defined as inflammation of the bone and the bone marrow. Although the osteomyelitis of the jaw is caused

JAYPEE BROTHERS

by variety of causes, dental caries is the most common of all. Other causes include radiation, fractures, gunshot wound, and specific infections like tuberculosis, syphilis, actinomycosis and sometimes-fungal infections like blastomycosis and coccidomycosis and rarely hematogenous spread. Although different organisms are cultured the most commonly isolated organisms are *Staphylococcus aureus* and *Staphylococcus albus* and various streptococci. The disease may be acute, sub acute or chronic and presents a different clinical course depending upon its nature.

Acute Suppurative Osteomyelitis

It is a serious sequelae of periapical infection that often results in spread of infection throughout the medullary spaces, with subsequent necrosis of a variable amount of bone.

Clinical features: Patient may present with elevation of body temperature, difficulty in chewing and severe pain of the involved tooth. There will be no swelling until periostitis develops. Paresthesia or anesthesia of the lip is a common feature.

Intraoral finding may be that of any periapical disease.

Radiographic features: There will be no radiographic evidence until the disease has progressed for at least one to two weeks. By the end of two weeks diffuse lytic changes in the bone will be appreciated. Individual trabeculae become fuzzy and indistinct and radiolucent areas begin to appear.

Treatment: Drainage to be established and antibiotic coverage to prevent further spread and complications.

Chronic Suppurative Osteomyelitis

Chronic suppurative osteomyelitis may develop after the acute phase of the disease has subsided or sometimes as a chronic lesion from its onset. On few occasions the chronic lesion may go into acute exacerbations.

JAYPEE BROTHERS

Clinical features: The clinical features are similar to acute osteomyelitis except that all signs and symptoms are milder. In chronic lesions or in acute exacerbated lesions the suppuration may perforate the bone and the overlying skin to form a fistulous tract and drain on the surface (Figure 4.11).



Figure 4.11

Chronic Focal Sclerosing Osteomyelitis (Condensing Osteitis)

Condensing osteitis is an unusual reaction of bone to infection. It occurs when there is extremely high tissue resistance or in cases of low-grade infection. In such instances the tissues react to the infection by proliferation rather than destruction, since the infection acts as a stimulus rather than as an irritant. It is a radiographic diagnosis.

Clinical features: Usually seen in persons below 20 years of age. Mandibular first molar is the most commonly involved tooth Signs and symptoms will be that of the infected pulp.

Radiographic features: The periapical radiograph shows a well-circumscribed radiopaque mass of sclerotic bone surrounding and extending below the apex of one or both roots. The entire root outline is nearly always visible. This helps in distinguishing it from benign cementoblastoma. The border of this radiopacity, abutting the normal bone may be smooth and distinct or appear to blend into the surrounding bone.

Treatment: The infected tooth is endodontically treated or extracted. The dense bone may get remodelled or sometimes recognized even after years on a radiograph.

Chronic Diffuse Sclerosing Osteomyelitis

Chronic diffuse sclerosing osteomyelitis is similar to the focal type except that the port of entry is periodontal disease and not the carious lesion.

JAYPEE BROTHERS

Clinical features: May be seen at any age but most commonly seen in older individuals.

Usually does not present with any clinical indications but sometimes mild suppuration and fistula opening onto the mucosal surface may be seen. In such cases with suppuration patient may present with vague pain and a bad taste in the mouth.

Radiographic features: Chronic diffuse sclerosing osteomyelitis shows diffuse sclerosis of the bone. The radiopaque lesion may be extensive and bilateral. Because of the diffuse nature of the disease the border between the sclerosis and the normal bone is often indistinct. This is described as "cotton wool" appearance and it also resembles Paget's disease of bone.

Treatment: Conservative treatment. Acute exacerbated lesions may require antibiotic coverage.

Chronic Osteomyelitis with Proliferative Periostitis (Garre's Osteomyelitis)

Garre described chronic diffuse sclerosing osteomyelitis in 1893 as a focal gross thickening of the periosteum of long bones, with peripheral reactive bone formation resulting from mild irritation or infection. It differs from the other type of osteomyelitis as it is of periosteal osteosclerosis while others represent endosteal osteosclerosis.

Clinical features: Seen in young adults under 25 years of age

Patient may present with toothache or pain in the jaw or of a hard bony swelling on the outer surface of the jaw

Radiographic features: Radiograph will reveal a carious tooth opposite the hard bony mass.

Occlusal radiograph will show a focal overgrowth of bone on the outer surface of the cortex, which may be described as a duplication of the cortical layer of bone. This mass of bone is smooth and rather well calcified and may itself show a thin but definitive cortical layer. It is also described as an "onion peel" appearance.

Treatment: Chronic osteomyelitis with proliferative periostitis is best treated with endodontic treatment or extraction of the

JAYPEE BROTHERS

carious tooth with no surgical intervention for the periosteal lesion except for biopsy to confirm the diagnosis.

Flowchart 4.1: Sequelae of pulpitis

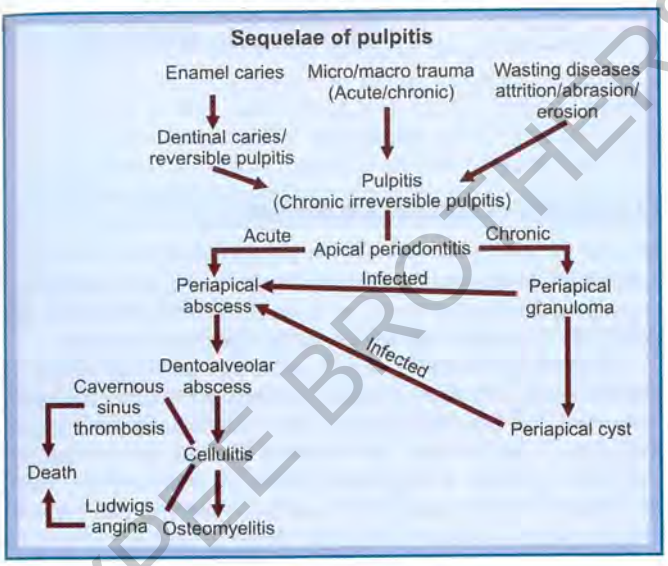

JAYPEE BROTHERS

Clinical Manual for Oral Medicine and Radiology

Salient Features

- Simple, well-illustrated and lucid in content and style
- Explains concise and update information on the subject.
- Discusses various oral and facial abnormalities as well as basic aspects of dental radiology
- Provides clear understanding of the diagnosis and management of oral soft tissue diseases, facial pain, oral diseases in medically compromised patients, systemic diseases and dental manifestation, etc.
- Emphasises step by step examination protocol for all parts of tissues in oral cavity.
- Serves as a day-to-day reference book for the undergraduate and graduate students of dentistry.

Available at all medical book stores
or buy directly from Jaypee Brothers through online shopping
at www.jaypeebrothers.com

or call + 91-11-32558559

JAYPEE BROTHERS
Medical Publishers (P) Ltd.
www.jaypeebrothers.com

ISBN 81-8448-114-4

9 788184 481143