Essentials of

ANATOMY

SECOND EDITION

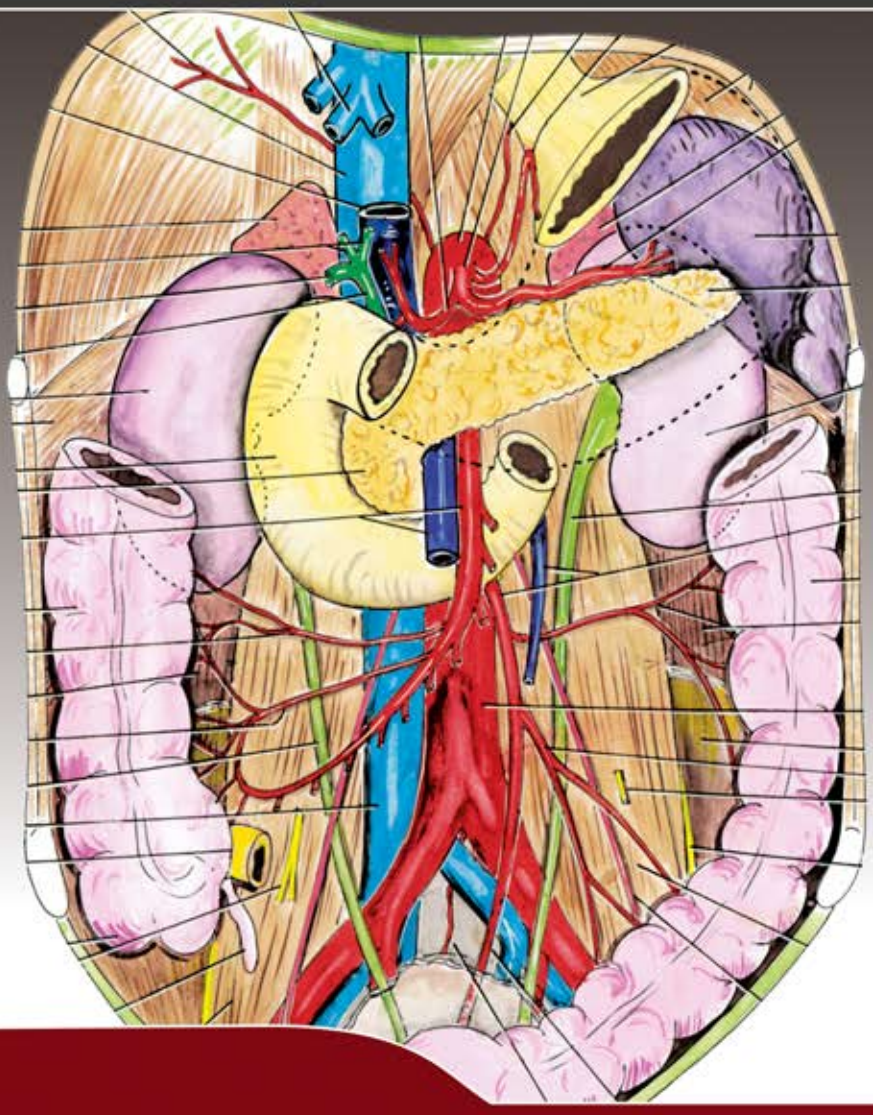

INDERBIR SINGH

JAYPEE

Contents

PART 1: UPPER EXTREMITY

1. Some Descriptive Terms ---- 2
2. Bones of the Upper Extremity ---- 4
3. Pectoral Region, Axilla and Breast ---- 18
4. The Back and Scapular Region ---- 26
5. Superficial Nerves and Veins: The Arm and Cubital Fossa ---- 33
6. The Forearm and Hand ---- 42
7. Joints of the Upper Limb ---- 65
8. Surface Marking of Some Structures and Clinical Correlations of the Upper Limb ---- 71

PART 2: LOWER EXTREMITY

9. Bones of the Lower Limb ---- 78
10. Front and Medial Side of Thigh ---- 100
11. Gluteal Region, Back of Thigh, Popliteal Fossa ---- 117
12. Front and Lateral Side of Leg: Dorsum of Foot ---- 130
13. Back of Leg and Sole ---- 139
14. Joints of the Lower Limb ---- 152
15. Surface Marking and Clinical Correlations of Lower Limb ---- 160

PART 3: THORAX

16. Bones and Joints of the Thorax ---- 165
17. Walls of the Thorax ---- 174
18. The Thoracic Cavity, Trachea, Bronchi and Lungs ---- 184
19. The Heart and Pericardium ---- 194
20. Blood Vessels of the Thorax ---- 202
21. The Oesophagus, The Thymus. Lymphatics and Nerves of the Thorax ---- 209
22. Surface Marking and Clinical Correlations of the Thorax ---- 218

PART 4: ABDOMEN AND PELVIS

23. Introduction to the Abdomen: Bones and Joints ---- 223
24. Anterior Abdominal Wall ---- 230
25. The Perineum and Related Genital Organs ---- 241
26. Oesophagus, Stomach and Intestines ---- 250
27. The Liver, Pancreas and Spleen ---- 258
28. Blood Vessels of Stomach, Intestines, Liver, Pancreas and Spleen ---- 265
29. Kidney, Ureter, Suprarenal Gland ---- 269
30. Posterior Abdominal Wall and Some Related Structures ---- 273
31. Walls of the Pelvis ---- 282
32. Pelvic Viscera and The Peritoneum ---- 287
33. Lymphatics and Autonomic Nerves of Abdomen and Pelvis ---- 298
34. Surface Marking and Clinical Correlations of Abdomen and Pelvis ---- 304

JAYPEE BROTHERS

4 : The Back and Scapular Region

The muscles of the upper limb, to be seen on the back, are concerned with movements of the scapula. It is important to understand these movements as they, in turn, affect movements of the arm.

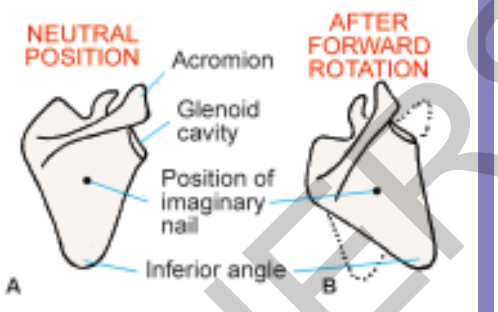

Fig. 4.1. Neutral position of the scapula and position after forward rotation.

Movements of the scapula

The scapula is held in position by muscles attached to it and its position depends upon the relative degree of contraction of different muscles. In ***protraction*** the entire bone slides forwards over the chest wall. Reversal of this movement is ***retraction***. In ***elevation*** the entire bone moves upwards (as in shrugging the shoulders); and the opposite movement is called ***depression***.

In addition to these simple movements the scapula can undergo rotation. To understand rotation imagine that the scapula is transfixed by an imaginary nail passing through the centre of its body (Fig. 4.1). Rotation is described in terms of movement of the inferior angle of the scapula.

In ***forward rotation*** (also called ***lateral rotation***) the inferior angle passes forwards and somewhat laterally (Fig. 4.1B). Simultaneously, the superior angle and the acromion pass backwards and medially. The glenoid cavity comes to face upwards. This movement takes place during abduction of the arm, and is essential for raising the arm above the head. Reversal of this movement constitutes ***backward (or medial) rotation***.

MUSCLES OF THE UPPER LIMB SEEN ON THE BACK

These are the trapezius, the latissimus dorsi, the levator scapulae, the rhomboideus major and the rhomboideus minor (Fig. 4.2).

Trapezius (Figs 4.2 and 4.3)

Origin:

The muscle has a long linear origin from the following structures.

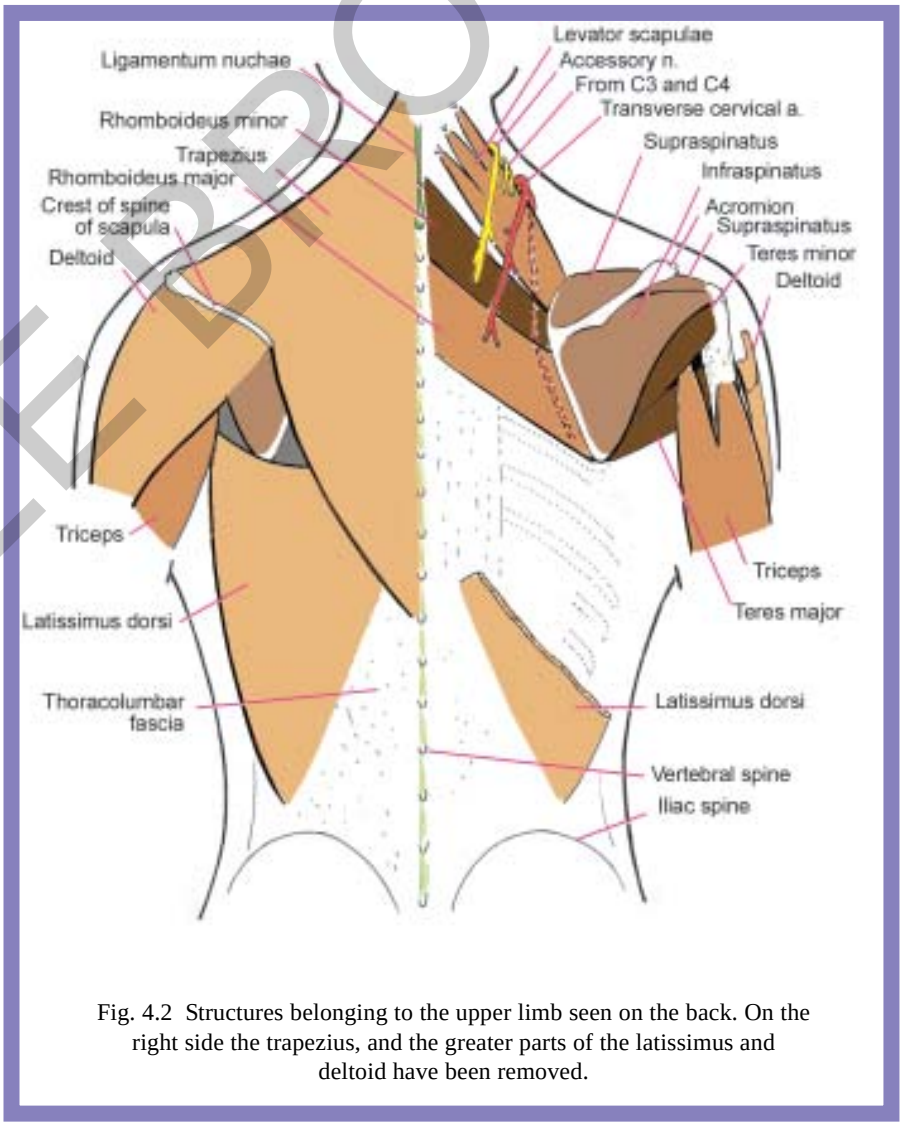

Fig. 4.2 Structures belonging to the upper limb seen on the back. On the right side the trapezius, and the greater parts of the latissimus and deltoid have been removed.

JAYPEE BROTHERS

1. Medial one-third of superior nuchal line.
2. External occipital protuberance.
3. Ligamentum nuchae.
4. Spine of 7th cervical vertebra.
5. Spines of all thoracic vertebrae and intervening supraspinous ligaments.

Insertion:
The muscle is inserted into:
1. The posterior border of the lateral one-third of the clavicle.
2. The medial margin of the acromion.
3. The spine of the scapula.

Nerve Supply:
The muscle is supplied by the spinal part of the accessory nerve and by branches from the third and fourth cervical nerves.

Actions:
The trapezius takes part in performing the following movements:
1. Forward rotation of the scapula, along with the serratus anterior.
2. Elevation of the scapula, along with the levator scapulae.
3. Retraction of the scapula, along with rhomboids.
4. The muscles of the two sides acting together draw the head backwards. Each muscle acting alone draws the head backwards and laterally to its own side.

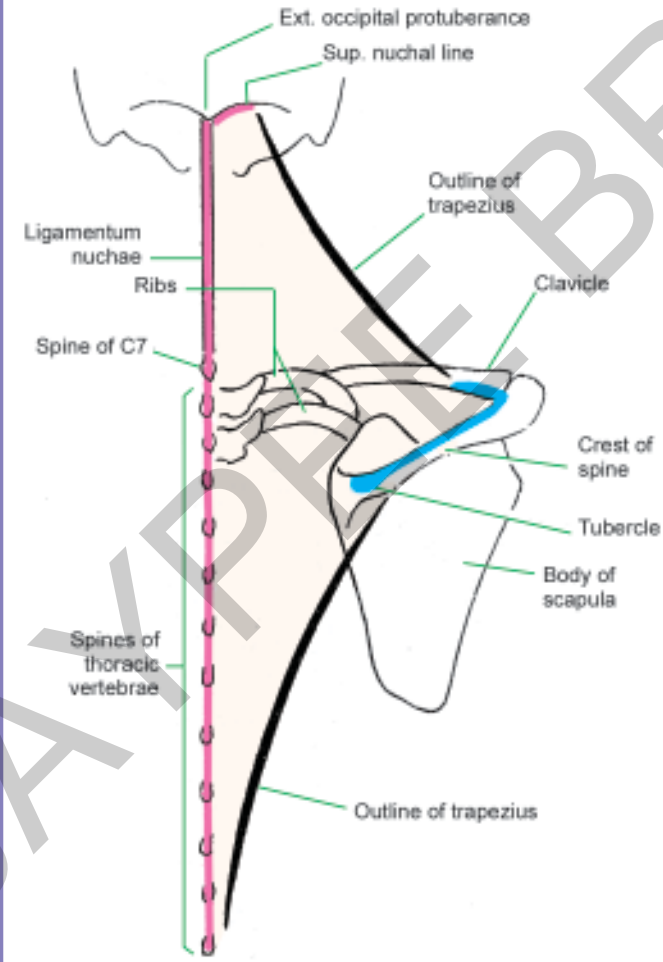

Fig. 4.3. Scheme to show the attachments of the trapezius.

Latissimus Dorsi (Figs 4.2 and 4.4)

Origin:
The latissimus dorsi has a long origin from the following:
1) The spines of the lower six thoracic vertebrae and the intervening supraspinous ligaments.
2) The lumbar fascia.
3) The iliac crest.
The fibres of the muscle converge towards the axilla. Here the muscle winds round the lower border of the teres major to reach its anterior aspect. These two muscles together form the posterior fold of the axilla.

Insertion:
The muscle ends in a tendon that is inserted into the ***anterior*** aspect of the upper end of the humerus, in the floor of the intertubercular sulcus.

Nerve Supply:
The muscle is supplied by the thoraco-dorsal nerve (C6, C7, C8).

Actions of Latissimus dorsi:
1. Adduction of the arm.
2. Medial rotation of the arm.
3. Extension of the arm.

Levator Scapulae (Fig. 4.2)

Origin:
From the transverse processes of the upper four cervical vertebrae.

Insertion:
Medial margin of the scapula from the superior angle to the root of the spine.

Nerve Supply:
Branches from spinal nerves C3 and C4 and from the dorsal scapula nerve (C5).

Actions: See under rhomboideus major.

Rhomboideus minor (Fig. 4.2)

Origin:
From lowest part of ligamentum nuchae and from the spines of vertebrae C7 and T1.

Insertion:
Medial margin of the scapula opposite the root of the spine.

JAYPEE BROTHERS

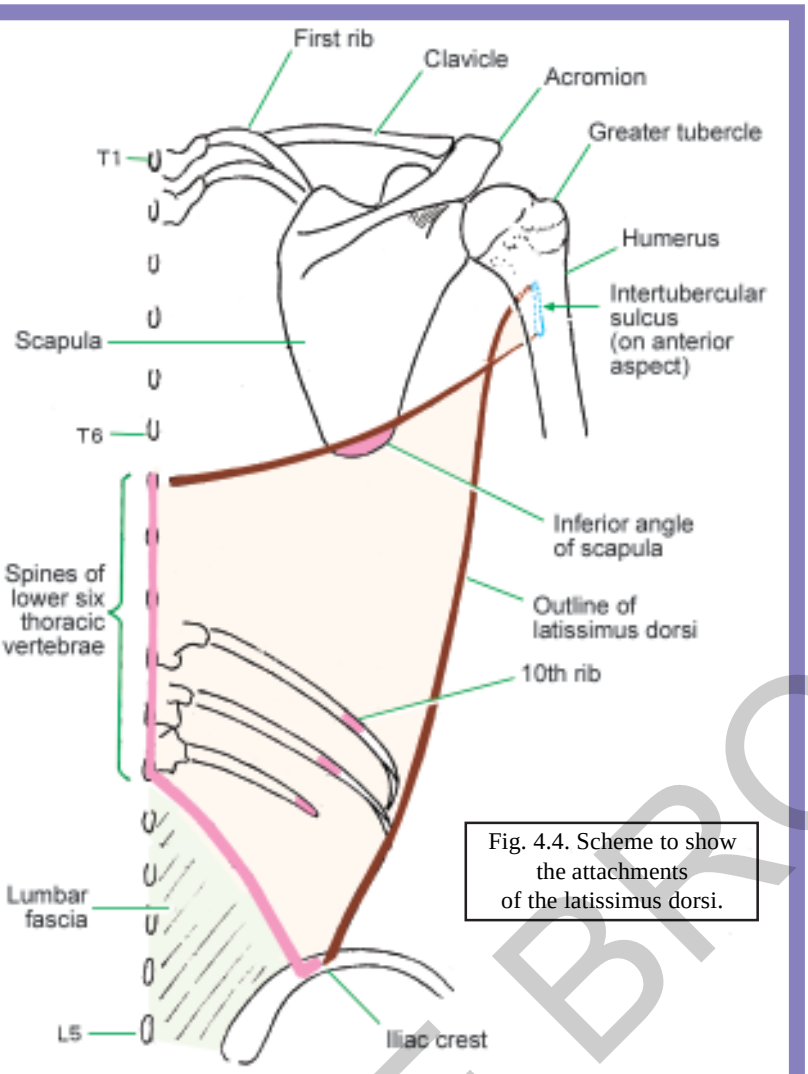

Fig. 4.4. Scheme to show the attachments of the latissimus dorsi.

Nerve supply: Dorsal scapular nerve.

Actions: See under rhomboideus major

Rhomboideus major (Fig. 4.3)

Origin:
From spines of vertebrae T2 to T5.

Insertion:
Into medial margin of scapula (from the level of the root of the spine to the inferior angle).

Nerve supply: Dorsal scapular nerve (C5).

Actions of levator scapula and rhomboideus muscles:
The levator scapulae elevates the scapula, while the rhomboideus muscles retract it. Acting together they steady the scapula during movements of the upper limb. They also produce backward rotation of the scapula.

NERVES OF THE BACK

Cutaneous nerves of the back

The skin of the back is supplied mainly by cutaneous branches arising from ***dorsal rami*** of spinal nerves (Fig. 4.5). The lateral parts of the back are innervated by cutaneous branches from ventral rami. Note that dorsal rami make no contribution to the cutaneous supply of the free upper limb.

Nerves supplying muscles of the upper limb seen on the back

Spinal part of accessory nerve

The accessory nerve is the eleventh cranial nerve. It has a cranial part, and a spinal part. The spinal part of the nerve reaches the trapezius in the lower part of the neck and descends into the back deep to this muscle, supplying it.

Dorsal scapular nerve

The dorsal scapular nerve arises from root C5 of the brachial plexus. It passes backwards and downwards through the lower part of the neck to reach the anterior aspect of the levator scapulae. It then descends into the back to reach the anterior (i.e. deep) aspect of the rhomboideus muscles. The dorsal scapular nerve supplies the rhomboideus major and minor and may give a branch to the levator scapulae.

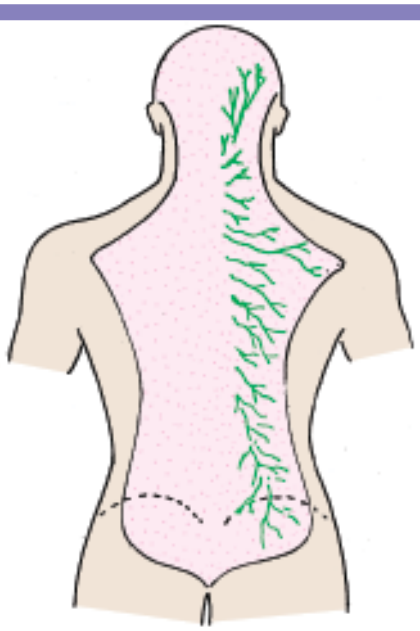

Fig. 4.5. Areas of skin of the back supplied by dorsal rami of spinal nerves.

JAYPEE BROTHERS

THE SCAPULAR REGION

In the scapular region we see several muscles that take origin from the scapula and gain insertion into the humerus. These are the deltoid, the supraspinatus, the infraspinatus, the teres major, the teres minor, and the subscapularis.

Deltoid (Figs 4.3 and 4.6)

Origin:
The deltoid has one continuous origin from the following.
1. Upper surface and anterior border of the lateral one-third of the clavicle.
2. Lateral margin and upper surface of the acromion.
3. Lower lip of crest of spine of scapula.

Insertion:
Deltoid tuberosity on the lateral aspect of the shaft of the humerus.

Nerve Supply:
By the axillary nerve (C5, C6).

Actions:
1. The anterior fibres cause flexion and medial rotation of the humerus.
2. The posterior fibres cause extension and lateral rotation.
3. The acromial part of the muscle produces abduction of the arm at the shoulder joint (See below).

Mechanism of abduction of the arm:
Abduction of the arm is a complicated movement and the deltoid is one of the most important muscles for it. Abduction of the arm takes place partly at the shoulder joint, and partly by rotation of the scapula. The first few degrees of abduction at the shoulder joint are produced by the supraspinatus. Abduction up to 90 degrees is produced by the deltoid. Further abduction is produced by forward rotation of the scapula produced by the serratus anterior and the trapezius acting together.

Supraspinatus (Fig. 4.2)

This muscle covers the posterior aspect of the scapula above the spine, and passes to the uppermost part of the humerus.

Origin:
From medial two-thirds of supraspinous fossa of scapula.

Insertion:
Into uppermost impression on greater tubercle of humerus.

Actions:
1. The supraspinatus, acting along with other muscles, around the shoulder joint, stabilises it.
2. It is an abductor of the arm.

Infraspinatus (Figs 4.2 and 4.8)

Origin:
From medial two-thirds of the infraspinous fossa, of the scapula.

Insertion:
Into middle impression on greater tubercle of humerus .

Actions:
These are described along with those of the teres minor.

Nerve Supply:
The supraspinatis and the infraspinatus are supplied by the suprascapular nerve (C4, 5, 6) arising from Erb's point.

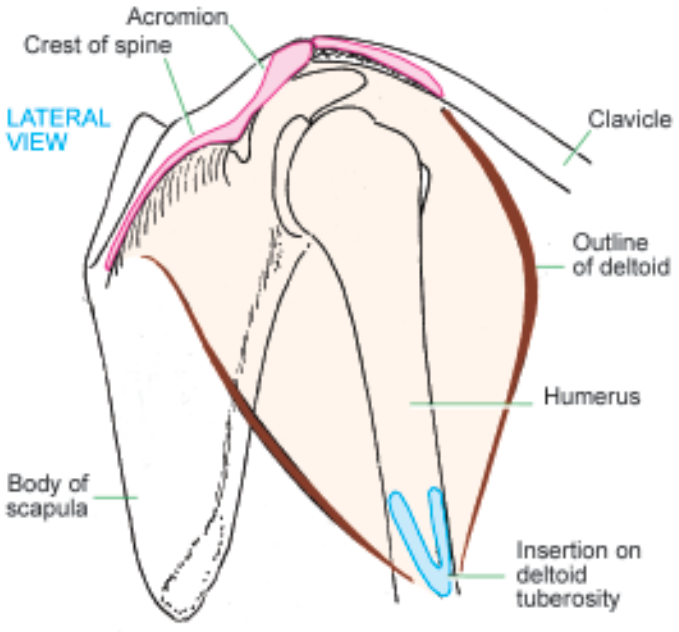

Fig. 4.6. Attachments of the deltoid muscle.

JAYPEE BROTHERS

Teres Minor (Figs 4.2 and 4.8)

Origin:
From dorsal surface of scapula along the upper two-thirds of the lateral border.

Insertion:
Into lowest impression on greater tubercle of humerus.
Nerve suppply: Axillary nerve.

Actions common to infraspinatus and teres minor:
1. These muscles are adductors and lateral rotators of the humerus.
2. They stabilise the shoulder joint and strengthen the posterior part of its capsule.
3. During abduction of the arm (by the deltoid and the supraspinatus) their downward pull prevents the head of the humerus from getting stuck under the coraco-acromial arch. This allows abduction to take place smoothly.

Teres Major (Figs 4.2, 4.7 and 4.8)

Origin:
From dorsal surface of scapula; the area of origin overlies the inferior angle and the lower one-third of the lateral border.

Insertion:
On ***anterior*** aspect of humerus, into the medial lip of intertubercular sulcus.

Nerve supply:
Lower subscapular nerve (C6, 7).

Actions:
These are described along with those of the subscapularis.

Subscapularis (Fig. 4.7)

Origin:
Medial two-thirds of the subscapular fossa (on costal surface of scapula).

Insertion
Lesser tubercle of humerus.

Nerve supply:
Upper and lower subscapular nerves (C5, 6, 7).

Actions of teres major and subscapularis:
Both the teres major and the subscapularis are adductors and medial rotators of the arm. In addition the teres major can extend the arm.

Along with other muscles surrounding the shoulder joint these muscles strengthen the capsule and stabilise it. During abduction of the arm (by the deltoid and the supraspinatus) these two muscles pull the head of the humerus downwards, and thus prevent it from getting stuck under the coraco-acromial arch.

Important relations:
The subscapularis and the teres major form the posterior wall of the axilla, and are related to the contents of the axilla.

Musculotendinous cuff of shoulder

The tendons of the subscapularis, teres minor, supraspinatus and infraspinatus unite to form a cuff (covering) for the shoulder joint.

Quadrangular and Triangular Spaces

These spaces are present just below the medial border of the scapula (Fig. 4.8). Their boundaries are as follows:
The ***quadrangular space*** is bounded above by the teres minor and the subscapularis, below by the teres major, medially by the long head of the triceps, and laterally by the surgical neck of the humerus. The axillary nerve and the posterior circumflex humeral artery pass backwards through this space.
The upper and lower boundaries of the ***triangular space*** are the same as those of the quadrangular space. Its lateral boundary is formed by the long head of the triceps. The circumflex scapular branch of the subscapular artery passes through this space.

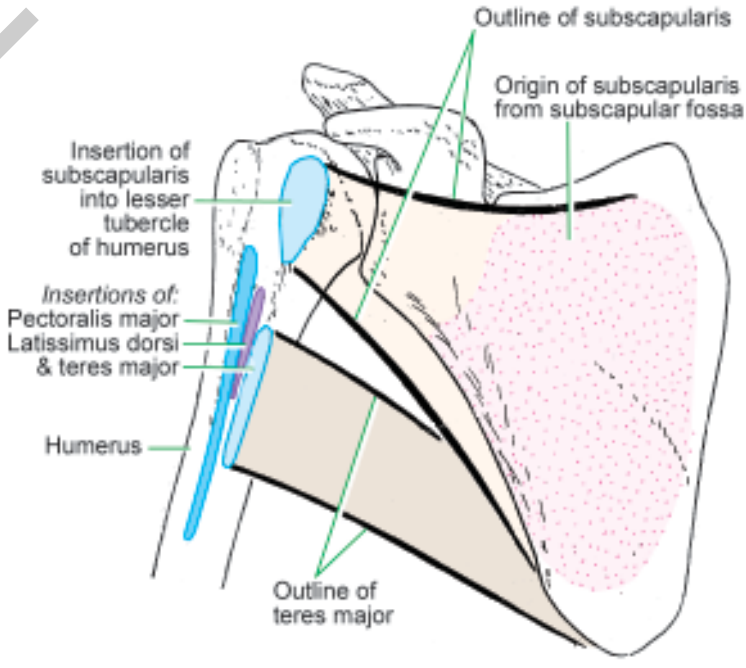

Fig. 4.7. Attachments of the subscapullaris. The teres major is also shown.

JAYPEE BROTHERS

NERVES OF SCAPULAR REGION

The nerves of the scapular region are the upper and lower subscapular nerves (already described), the suprascapular nerve and the axillary nerve.

The Suprascapular Nerve

The suprascapular nerve runs laterally and backwards over the shoulder (Fig. 4.9), deep to the trapezius. Reaching the upper border of the scapula it passes backwards through the suprascapular notch (below the transverse scapular ligament) to enter the supraspinous fossa. After supplying the supraspinatus the nerve enters the infraspinous fossa where it ends by supplying the infraspinatus. The nerve also gives branches to the shoulder joint and to the acromioclavicular joint.

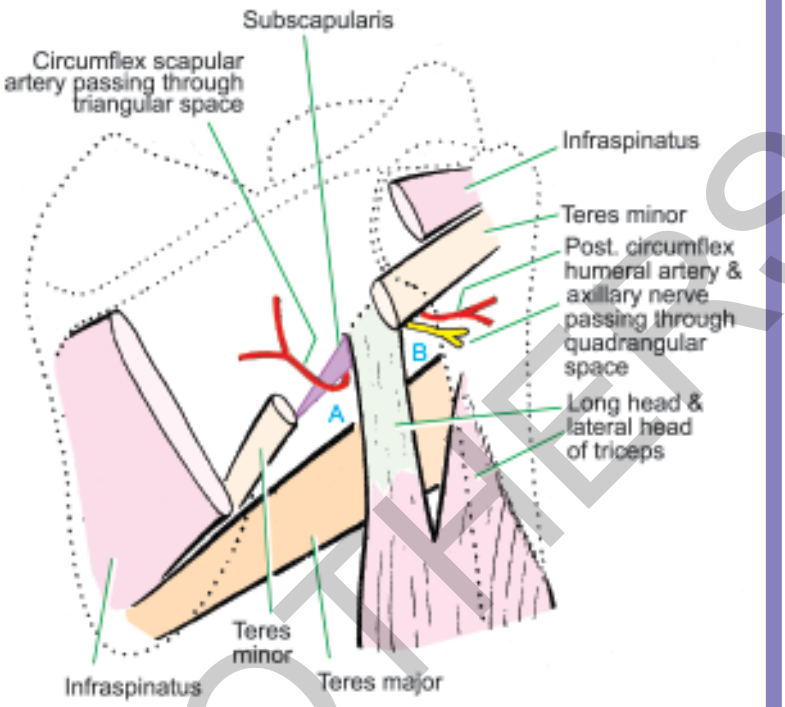

Fig. 4.8. Diagram to show the triangular space (A) and the quadrangular space (B), of the scapular region.

The Axillary Nerve

The axillary nerve (Fig. 4.10) supplies the deltoid and the teres minor. It is a branch of the posterior cord of the brachial plexus. At its origin it lies behind the axillary artery. It descends over the subscapularis, and reaching its lower border it passes backwards through the quadrangular space.

The nerve ends by dividing into an anterior and a posterior branch. The ***anterior branch*** passes round the surgical neck of the humerus and ends by supplying the deltoid. Some ramifications reach the skin. The ***posterior branch*** supplies the posterior part of the deltoid and also the teres minor. Its terminal part becomes the ***upper lateral cutaneous nerve of the arm***: this nerve supplies the skin over the lower part of the deltoid muscle.

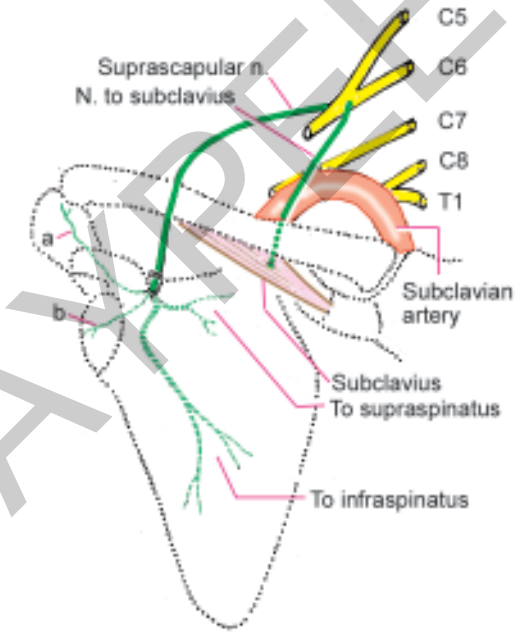

Fig. 4.9. Scheme to show the course of the suprascapular nerve, and the nerve to the subclavius.

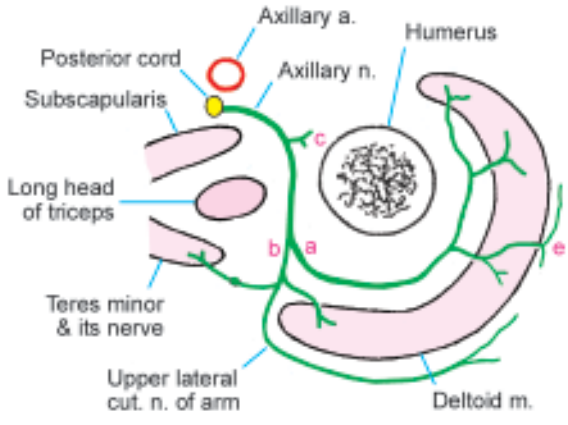

Fig. 4.10. Scheme to show the course and distribution of the axillary nerve. a - anterior branch; b - posterior branch; c - branch to shoulder joint; e - cutaneous twig from anterior branch.

JAYPEE BROTHERS

ARTERIES OF SCAPULAR REGION

In the back and scapular region we see some arteries that begin in the neck as (direct or indirect) branches of the subclavian artery. Like the axillary artery, the subclavian artery is divided into first, second and third parts (by a muscle called the scalenus anterior). A short artery called the ***thyrocervical trunk*** arises from the junction of the first and third parts of the subclavian artery (Fig. 4.11). The thyrocervical trunk divides into three arteries: inferior thyroid, suprascapular and transverse cervical. The suprascapular and transverse cervical arteries are encountered in the scapular region.

The Transverse Cervical Artery (Fig. 4.11)

This artery divides into superficial and deep branches. The ***superficial branch*** runs laterally across the posterior triangle of the neck to reach the trapezius. It then ascends deep to the trapezius, supplying it and neighbouring structures. The ***deep branch*** of the transverse cervical passes laterally and backwards in the lower part of the posterior triangle of the neck to reach the upper angle of the scapula. It then runs along the medial border of this bone up to the inferior angle (deep to the levator scapulae and rhomboideus muscles). It supplies these muscles and the trapezius. It gives branches that anastomose with the suprascapular and subscapular arteries (See below).

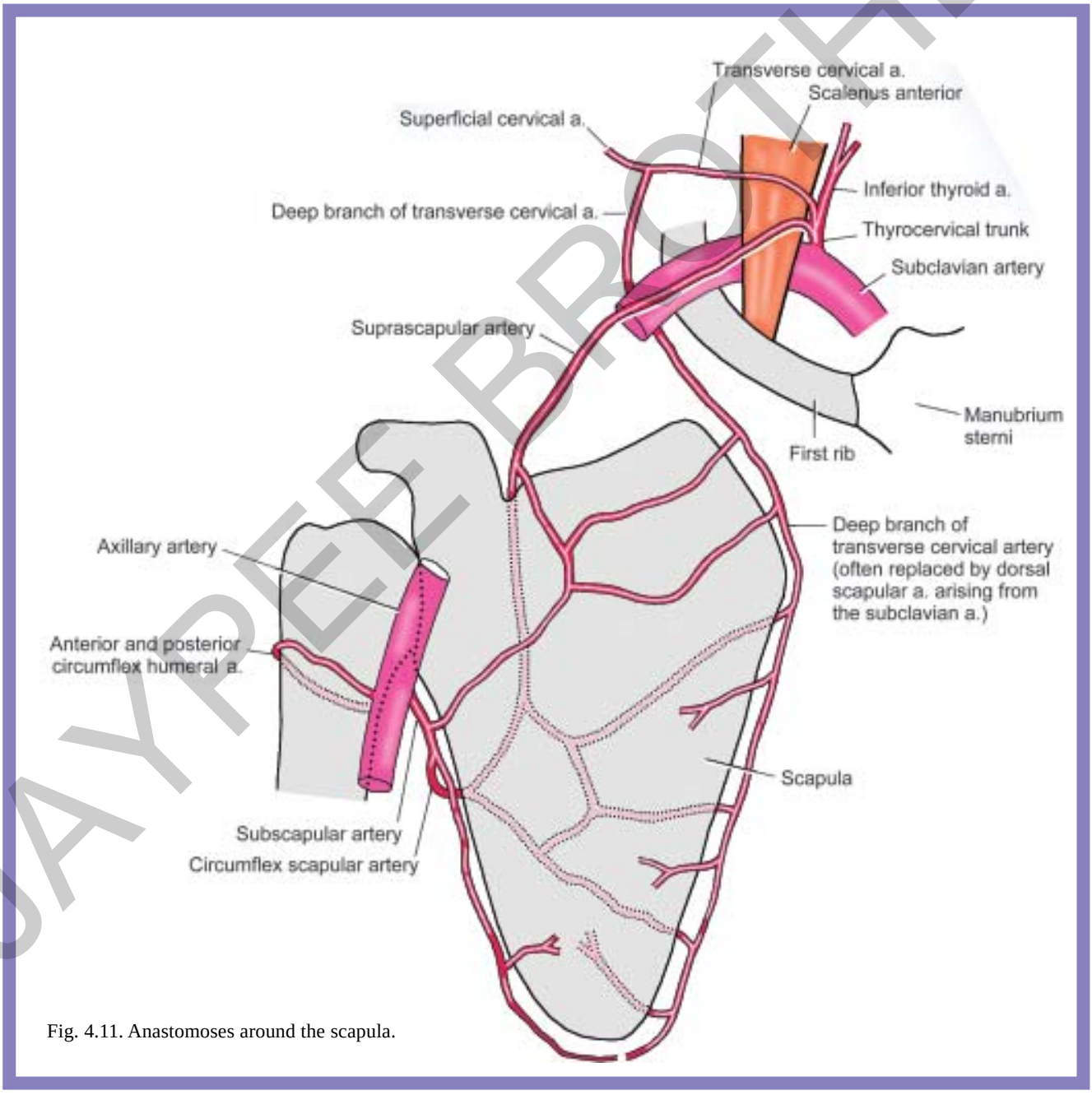

Fig. 4.11. Anastomoses around the scapula.

JAYPEE BROTHERS

Essentials of
ANATOMY

- Entire course of gross human anatomy in ONE volume
- Suitable for one year first professional MBBS course
- Also for BDS students
- Profusely illustrated in colour
- Written in easy language
- No unnecessary details

THIS IS JUST THE BOOK YOU HAVE BEEN WAITING FOR

Available at all medical book stores
or buy directly from Jaypee Brothers through online shopping at www.jaypeebrothers.com

or call + 91-11-32558559

JAYPEE BROTHERS
Medical Publishers (P) Ltd.
www.jaypeebrothers.com

ISBN 81-8448-461-5
9 788184 484618