Satish Chandra
Shaleen Chandra
Mithilesh Chandra
Girish Chandra
Nidhee Chandra



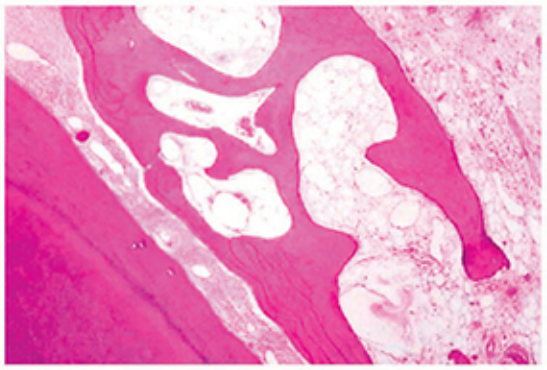

2nd Edition

Textbook of
Dental & Oral Histology with Embryology
(With MCQs)

Forewords
Anil Kohli
RK Bali
TS Bastian

JAYPEE

Contents

1. Introduction to Oral and Dental Tissues 1
2. General Embryology and Growth & Development of Oromaxillofacial Structures 5
3. Development of Teeth 31
4. Enamel 53
5. Dentin 83
6. Dental Pulp 112
7. Cementum 146
8. Periodontal Ligament 166
9. Oral Mucous Membrane 187
10. Bone and Alveolus 229
11. Salivary Glands 242
12. Eruption of Teeth and Physiologic Teeth Movements 262
13. Shedding of Deciduous Teeth 274
14. Temporomandibular Joint 283
15. Maxillary Sinus 294
16. Age Changes in Oral Tissues 301
17. Methods Used in Preparation of Specimen for Histological Study 309
18. Advanced Techniques in the Study of Oral Tissues 319
19. Repair and Regeneration of Dental Tissues 331
20. Fibroblast and Its Products 342

Multiple Choice Questions *349*

Index *383*

CHAPTER 1

Introduction to Oral and Dental Tissues

- The tooth
  - Enamel
  - Dentin
  - Pulp
  - Cementum
- Periodontal ligament (PDL)
- Oral mucous membrane
- Bone and alveolus
- Salivary glands
- Eruption of teeth
- Shedding of deciduous teeth
- Temporomandibular joint

JAYPEE BROTHERS

In this chapter a brief introduction of the basics of the subject and the important chapters is given to facilitate the students to easily and clearly understand the subject matter.

THE TOOTH

Approximately twenty percent of the surface area of the oral cavity are constituted by teeth. Maxillary teeth constitute about 11 percent and mandibular teeth constitute about 9 percent surface area. The tooth has two parts, crown and root, divided by a cervical line. Usually crown is visible in oral cavity and root remain inside the gums and jaw bone and is not visible. The part of the tooth visible in oral cavity is the clinical crown usually called as crown. In healthy conditions in young adults anatomical crown i.e. up to only cervical line is visible in oral cavity and anatomical crown (crown up to cervical line) is equal to the clinical crown (visible part of crown in oral cavity).

Anatomical crown is covered by enamel (hardest and most mineralized tissue of the body). The anatomical root is covered by the cementum. The anatomical crown and root is divided by a thin line called cervical line. In all further descriptions, unless specified otherwise the crown means anatomical crown and the root means anatomical root.

The supporting tissues of the tooth surrounding the roots constitute periodontium which consist of cementum, periodontal ligament and the alveolar bone. The tooth is suspended in the socket of alveolar bone by the fibers of periodontal ligament. These fibers act as shock absorber. The inner most part of the tooth in the crown and root is hollow and is called pulp cavity which is filled with most vital part of tooth called pulp. Pulp in crown and root is covered by the dentin. The dentin of the crown is covered by enamel and of the root is covered by cementum (Fig. 1.1).

In childhood the face and jaws are smaller hence fewer teeth of smaller size are present. These smaller teeth are called deciduous or primary teeth. With the growth, the jaw bones grow in size but the teeth once fully formed do not grow in size. Therefore to have the larger sized teeth the deciduous teeth which are of smaller size have to be shed and permanent teeth of larger size erupt in oral cavity replacing the smaller deciduous teeth. Permanent teeth are larger in size and more in number to bear the increased work load of the adulthood.

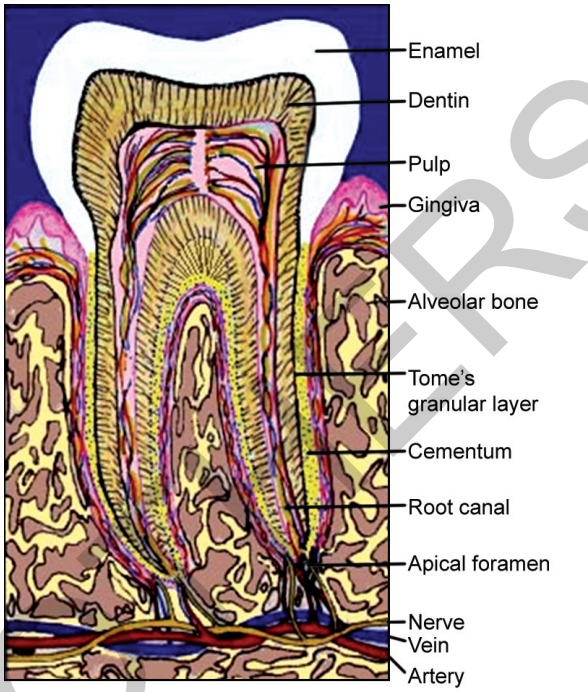

Figure 1.1: Mesiodistal longitudinal section of the mandibular molar tooth and supporting structures. In the pulp chamber, pulp is shown at two different levels. In the right half is shown the central region of the pulp showing thicker blood vessels and in the left half is seen the peripheral pulp showing thinner blood capillaries

The name of the cells ending with blast do generate the tissues, like ameloblast (generate enamel) osteoblast (generate bone) odontoblast (generate dentin) and cementoblast (generate cementum). Likewise the words ending with clast do resorb the tissue like osteoclast and odontoclast etc. Odontoblast and odontoclast are also known as dentinoblast and dentinoclast respectively.

Enamel

The enamel is brittle in nature and may fracture under masticatory load. Enamel is the only ectodermal derivative in the tooth. Enamel consist of 96 percent of inorganic material in the form of apatite crystals. Enamel is formed by the cells called ameloblasts which disappear once enamel is completely formed, hence when enamel is destroyed it cannot be regenerated. Enamel is insensitive, nonvital, selectively permeable and ionic exchange can occur between the enamel and the environment of the oral cavity especially saliva.

To prevent dental caries fluoride is topically applied to the surface of the enamel. By this hydroxyapatite of the enamel is converted to fluorapatite which is more resistant to the dissolution in acid and thus prevent dental caries.

JAYPEE BROTHERS

Dentin

The bulk of the tooth is formed by dentin. Dentin is slightly resilient yellowish white, sensitive and avascular tissue which is less calcified than enamel. Dentin surrounds the pulp in the pulp chamber. Dentin consists of dentinal tubules. These tubules contain the extension of the odontoblasts made up of cytoplasm, and are called odontoblastic processes. Present around the tubules is the calcified matrix called intertubular matrix. The walls of the tubules are more calcified than the intertubular matrix.

Enamel must be supported by the resilient dentin to withstand the masticatory forces. Dentin supports the enamel to prevent fracture of enamel under masticatory forces. The specialized cells which form and maintain the dentin are called odontoblasts. Their bodies remain in the pulp and are aligned along the inner border of dentin, and there they form the peripheral boundary of the pulp. The dentin is capable of repair as odontoblasts deposit rapidly more dentin as and when required and also slowly and regularly throughout the life. The dentinoenamel junction is scalloped to create a mechanical retention. The dentin and pulp act as one unit. Dentin protects the pulp and the pulp nourishes the dentin.

Pulp

The central hollow part of the tooth contains the soft and most vital and vascular part of the tooth which is called pulp. Pulp is lost in dried ground sections, leaving an empty pulp chamber. Developmentally and functionally dentin and pulp are alike and may be considered simultaneously. All the functions of the pulp are related to the dentin. Functions of the pulp are as follows.

A. Formative (produces dentin)
B. Nutritive (nourishes dentin)
C. Protective (protect dentin from damage by providing sensitivity to dentin)
D. Reparative (pulp produces dentin for repair as and when required). The pulp is connected through periapical foramen with periodontal ligament and alveolar bone.

Cementum

Cementum is a mineralized connective tissue. It is bone like in structure covering the root of the teeth. Like dentin cementum is also continuously formed to compensate for occlusal wear and to keep the tooth in occlusion. Cementum is also avascular and non- innervated. Cementum is formed by cementoblasts. Cementum is firmly interlocked with the dentin of the root. Cementum contains fifty percent inorganic material like apatite crystals and rest fifty percent is organic matrix mainly collagen.

The cementum is of two types acellular (primary) and cellular (secondary). Acellular cementum is covering the cervical portion of the root. The cellular cementum is covering the apical portion of the root. It is called cellular because in it cementoblasts become entrapped in the lacunae of their own matrix, like osteocytes get entrapped in bone. The cementoblasts which get entrapped in the cementum are called cementocytes. Periodontal fibers on one hand are anchored into the cementum of the tooth and on the other hand into the bundle bone of alveolar bone. In this way the tooth remain suspended in the bony socket.

PERIODONTAL LIGAMENT (PDL)

The PDL is a very specialized connective tissue. Its width is about 0.2 mm. It is made up of fibers which on one hand are embedded in the cementum and on the other hand are embedded in the alveolar bone. In this way they connect tooth to the bone. PDL fibers are made up of collagen and act as shock absorber. The PDL also has sensory function. When teeth of opposing arch as soon as touch each other, through proprioceptive fibers in PDL the sensation is perceived. When the opposing teeth strike with heavy force the sensation of pain is perceived by PDL.

ORAL MUCOUS MEMBRANE

The oral cavity is lined by a specialized mucosa which is well adapted to perform its functions.

It consists of two layers, an epithelium which is superficial and connective tissue (lamina propria) which is deeper. Functions of the oral mucosa are (a) lining (b) protecting and (c) taste. Histologically oral mucosa is of following three types (a) masticatory mucosa (b) lining mucosa and (c) specialized mucosa.

The masticatory mucosa covers the gingiva and hard palpate. It is tightly attached to the underlying bone by the lamina propria. Its covering epithelium is keratinized

JAYPEE BROTHERS

so as to bear the forces of food bolus during mastication without damage. The lining mucosa is flexible and nonkeratinized. The lamina propria is loosely bound to the underlying structures. The dorsal surface of the tongue is covered by specialized mucosa which contains papillae and taste buds.

For their eruption the teeth perforate the oral mucosa. The mucosa immediately surrounding to the erupted tooth is called gingiva. Gingiva is absent before eruption and disappear after loss of tooth.

BONE AND ALVEOLUS

The teeth are attached to the alveolar processes of the jaw bone by the PDL. When the teeth are lost the alveolar process are also gradually lost. Alveolar processes of the jaws form and support the sockets of the teeth. The orthodontic treatment is made possible by this property of the bone, to form under tension and resorb under pressure. This property is not present in cementum.

SALIVARY GLANDS

There are three pairs of major salivary glands, the parotid, submandibular and sublingual. The minor salivary glands are numerous and are scattered throughout the oral cavity except in gingiva and anterior part of hard palate. The basic histological structure of major salivary glands are similar. The salivary gland is like a bunch of grapes.

Saliva is a complex fluid. Normally exposed portion of each tooth is continuously bathed with saliva.

ERUPTION OF TEETH

The jaws of infants are smaller and can accommodate only smaller and lesser number of teeth which are only sufficient for soft and limited diet, required and taken in infancy. Adults take harder food and more in quantity, for them stronger, larger and more number of teeth are required. Teeth do not grow hence the deciduous (primary) teeth of infancy shed and in their place permanent teeth erupt in growing jaws. In adulthood jaws become grown up to full size and stronger. Hence to meet the requirements human being have two dentitions.

SHEDDING OF DECIDUOUS TEETH

Shedding of deciduous teeth is the physiological process by which deciduous teeth are removed to create space for the permanent teeth. For shedding the roots of the deciduous teeth are resorbed. The successional tooth develop lingually and erupt in an occlusal and vestibular direction. The developing tooth occupy a position directly apical to the shedding deciduous tooth and exerts pressure on the root. This pressure causes resorption of root resulting in exfoliation of the deciduous tooth.

TEMPOROMANDIBULAR JOINT (TMJ)

TMJ is formed by the articulation of lower jaw with the cranium and upper facial skeleton. TMJ is a synovial, bicondylar diarthrodial joint. It shows both side to side sliding and hinge movements. During mastication the masticatory muscles move the mandible in opening and closing direction and side to side direction. TMJ functions in speech, mastication and deglutition.

JAYPEE BROTHERS

Textbook of

Dental & Oral Histology with Embryology

(With MCQs)

Sailent Features

- Book focuses on physiology and allied area of dental & oral histology
- Subject matter has been made clear by lucid language and well-labeled schematic diagrams
- More than 450 MCQs with answers have been included for the benefit of students
- A book of immense value for undergraduates, postgraduates, teachers, researchers and practitioners.

Available at all medical book stores
or buy directly from Jaypee Brothers through online shopping
at www.jaypeebrothers.com

or call + 91-11-32558559

JAYPEE BROTHERS
Medical Publishers (P) Ltd.
www.jaypeebrothers.com

ISBN 978-81-8448-712-1