Textbook of Human Oral Embryology, Anatomy, Physiology, Histology and Tooth Morphology

KMK Masthan





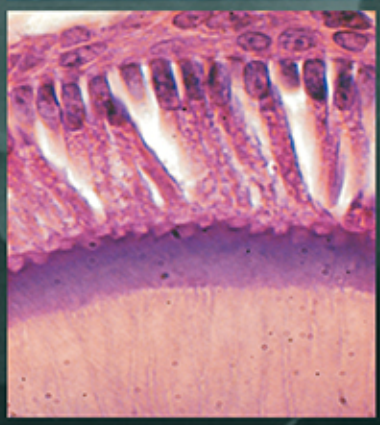

Foreword
C Bhasker Rao

JAYPEE

Contents

Section 1: Oral Embryology and Histology

1. Development of Face and Oral Cavity *3*
2. Development and Growth of Teeth *17*
3. Enamel *28*
4. Dentin *42*
5. Pulp *56*
6. Cementum (Substantia Ossea) *70*
7. Periodontal Ligament *76*
8. Alveolar Process *83*
9. Oral Mucous Membrane *90*
10. Salivary Glands *105*
11. Maxillary Sinus *120*
12. Temporomandibular Joint *125*
13. Tooth Eruption *132*
14. Shedding of Deciduous Teeth *140*

Section 2: Oral Physiology

15. Age Changes in Dental Tissues and Jaws *147*
16. Effects of Hormones on the Oral Structures *153*
17. Role of Calcium *177*

Section 3: Dental Anatomy

18. Introduction of Dentition *185*

Section 4: Histochemistry

19. Histochemistry of Oral Tissue *253*
20. Microtechnique *261*

Index *269*

Chapter 2

Development and Growth of Teeth

DENTAL LAMINA

Two-three weeks after the rupture of buccopharyngeal membrane, when the embryo is 6 weeks old, certain areas of basal cells of oral ectoderm proliferate at rapid rate than cells of adjacent areas, thus forming the dental lamina, which is a band of epithelium that has invaded the underlying ectomesenchyme along each of the horse-shoe shaped future dental arches.

Development of the 1st permanent molar is initiated at 4th month in utero.

Development of second molar is initiated at first year after birth.

The distal proliferation of the dental lamina is responsible for the location of the germs of the permanent molars in the ramus of the mandible and the tuberosity of the maxilla.

The successors of the deciduous teeth develop from a lingual extension

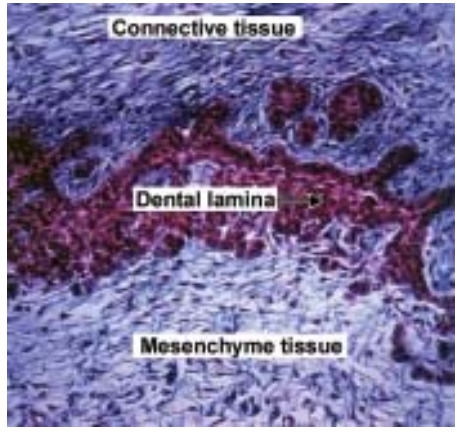

Fig. 2.1: Development of dental lamina

JAYPEE BROTHERS

of the free end of the dental lamina opposite to the enamel organ of each deciduous tooth.

The lingual extension of the dental lamina is named the successional lamina and develops from the fifth month *in utero* (permanent central incisor) to the tenth month of age (second premolar).

Fate of Dental Lamina

The total activity of dental lamina extends over a period of 5 years.

The dental lamina may still be active in the 3rd molar region after it has disappeared elsewhere. As the teeth continue to develop, they lose their connection with the dental lamina.

Remnants of the dental lamina (cell rests of serrae) persist as epithelial pearls or islands within the jaw as well as in the gingiva.

TOOTH DEVELOPMENT

At certain points of the dental lamina, ectodermal cells multiply more rapidly and form little knobs that grow into the underlying mesenchyme. These represents areas of 10 mandibular and 10 maxillary deciduous teeth in their respective arches.

Each of these little knobs represent beginning of enamel organ.

First to appear are the anterior mandibular incisors.

Developmental Stages

Several 'morphologic' stages named after the shape of the epithelial part of the tooth germ.

a. Bud stage
b. Cap stage
c. Bell stages
   - Early
   - Advanced

JAYPEE BROTHERS

Bud Stage

Epithelium of dental lamina is separated from the underlying ectomesenchyme by a basement membrane.

With differentiation of each dental lamina, round swelling arises at 10 different points in each jaw.

These represent the future position of deciduous teeth and are primordia of enamel organs, the tooth buds.

Thus, development of the tooth germs are initiated and cells continue to proliferate faster than adjacent cells.

Main function of certain epithelial cells of tooth bud is to form enamel - hence ***enamel organ***.

In bud stage, enamel organ consists of:

- Peripherally located low columnar cells.
- Centrally located polygonal cells.

Many cells of tooth bud and surrounding mesenchyme, undergo mitosis; due to this and migration of neural crest cells into the area, ectomesenchymal cells sorrounding the tooth bud condense.

This ectomesenchymal condensation subadjacent to the enamel organ is the ***dental papilla***.

Condensed ectomesenchyme surrounding the tooth bud and dental papilla is called ***dental sac***.

Dental papilla → Gives rise to dentin and the tooth pulp.

Dental sac → Gives rise to cementum, periodontal ligament and alveolar bone.

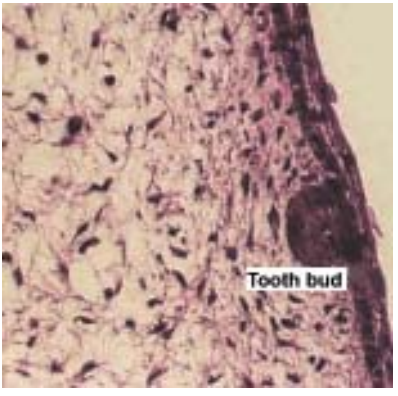

Fig. 2.2: Illustrates the earliest extension of the epithelium, called a tooth bud. The epithelia will continue to proliferate and form a process, shown in the following photograph

Cap Stage

As tooth bud proliferates, unequal growth in different

JAYPEE BROTHERS

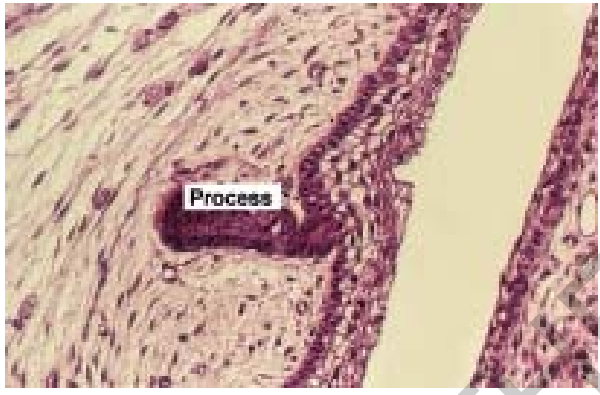

Fig. 2.3: Tooth bud forming process, extending in from dental lamina

parts of the tooth bud leads to a shallow invagination in the deeper surface of the bud leading to cap stage.

Peripheral cells of the cap are cuboidal, cover the convexity of the cap forming outer enamel epithelium.

Cells covering concavity are tall-columnar and they represent inner enamel epithelium

Outer enamel epithelium is separated from dental sac and inner enamel epithelium from dental papilla by a delicate basement membrane. Hemidesmosomes anchor the cells to basal lamina.

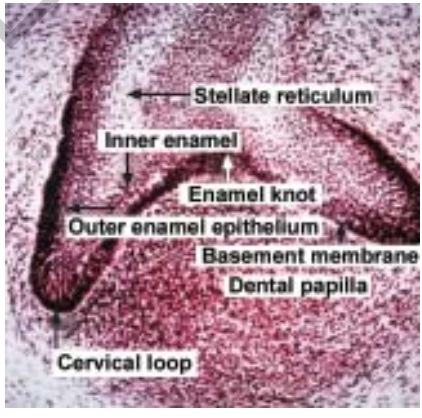

Fig. 2.4: Cap stage

JAYPEE BROTHERS

Stellate Reticulum (Enamel Pulp)

Polygonal cells in center of epithelial enamel organ between outer and inner epithelium begin to separate as more intercellular fluid is produced and form a cellular network called the stellate reticulum.

The spaces between the cells are filled with a mucoid fluid rich in albumin, which gives a cushioning consistency that may support and protect delicate enamel- forming cells. Cells assume a branched reticular network.

Cells in the center of enamel organ are densely packed and form the enamel knot.

There arises a vertical extension from the enamel knot called enamel cord.

Both the structures are temporary and disappear before enamel formation.

Function of Enamel Knot and Cord

Act as a reservoir of dividing cells for the growing enamel organ.

Dental Papilla

Proliferating epithelium of enamel organ influences the ectomesenchymal enclosure by invaginated portion of inner enamel epithelium.

It condenses to form dental papilla which is the formative organ for dentin and primordium of dental pulp.

Dental papilla shows active budding of capillaries and mitotic figures and peripheral cells adjacent to inner enamel epithelium enlarge and differentiate into odontoblasts later.

Dental Sac

Marginal condensation of mesenchyme surrounding the enamel organ and dental papilla is dental sac which is dense and fibrous in the primitive stage and forms periodontal ligament, cementum and alveolar bone.

JAYPEE BROTHERS

Bell Stage

As invagination of the epithelium deepens and its margins continue to grow, it assumes a 'Bell' shape.

In this stage, four types of epithelial cells can be distinguished by light microscope.

a. Inner enamel epithelium
b. Stratum intermedium
c. Stellate reticulum
d. Outer enamel epithelium

Inner Enamel Epithelium

Consists of a single layer of cells that differentiate into tall columnar cells prior to amelogenesis called ameloblasts, which are 4-5 µm width and 40 µm tall.

The cells are attached laterally by junctional complexes and to cells of stratum intermedium by desmosomes.

Cells of inner enamel epithelium exert an organizing influence on underlying mesenchymal cells in the dental papilla which later differentiate into odontoblasts.

Stratum Intermedium

Few layers of squamous cells form stratum intermedium between inner enamel epithelium and stellate reticulum.

Cells are closely attached by desmosomes and junctional complexes.

- High degree of metabolic activity is seen.
- This layer seems to be essential for enamel formation.

Stellate Reticulum

Expands by increase in intercellular fluid.

Cells are star-shaped, with long processes that anastamose with those of adjacent cells.

Before enamel formation, stellate reticulum collapses, reducing the distance between centrally situated ameloblasts and nutrient capillaries near outer enamel epithelium.

JAYPEE BROTHERS

Outer Enamel Epithelium

Cells are flattened to low - cuboidal.

During and prior of enamel formation, smooth surface of outer enamel epithelium is laid in folds.

Between folds, the adjacent mesenchyme of the dental sac forms papilla that contains capillary loops thus providing nutritional supply to avascular enamel organ.

Dental Papilla

Before inner enamel epithelium forms enamel, the peripheral cells of the dental papilla differentiate to odontoblasts. They assume cuboid form initially later becomes tall columnar.

The basement membrane between enamel organ and dental papilla just prior to dentin formation is called membrana preformativa.

Dental Sac

With development of root, fibers of dental sac differentiate into periodontal fibers that become embedded in developing cementum and alveolar bone.

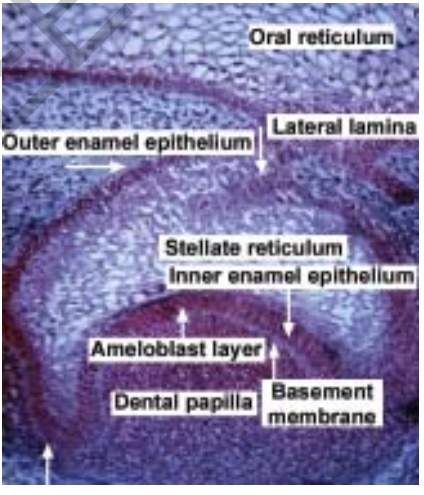

Fig. 2.5: Early bell stage

JAYPEE BROTHERS

Advanced Bell Stage

The boundary between inner enamel epithelium and odontoblasts outlines the future dentino-enamel junction.

Cervical portion of enamel organ gives rise to Hertwig's epithelial root sheath.

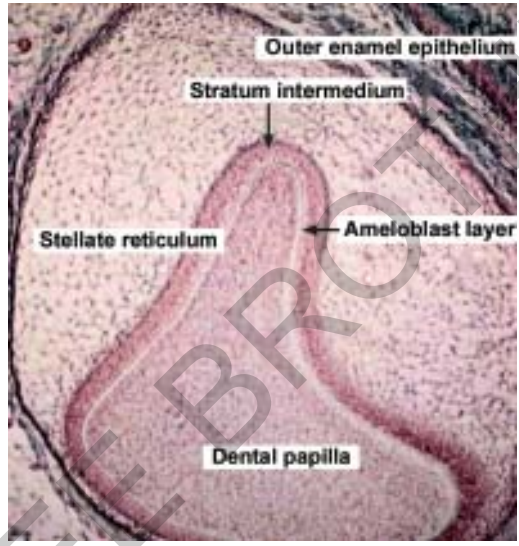

Fig. 2.6: Advance bell stage

HERTWIG'S EPITHELIAL ROOT SHEATH AND ROOT FORMATION

Root development begins after enamel and dentin formation has reached future cemento-enamel junction.

Enamel organ forms Hertwig's epithelial root sheath, which molds shape of roots and initiates radicular dentin formation

Hertwig's root sheath has inner and outer enamel epithelia without stratum intermedium and stellate reticulum.

The cells of inner enamel epithelia remains short, normal and don't produce enamel.

JAYPEE BROTHERS

When these cells have induced differentiation of radicular cells into odontoblast, first layer of dentin has been laid down.

Hertwig's root sheath loses its structural continuity and its close relation to the surface of root.

The remnants of it persists near the external surface of the teeth in the periodontal ligament of erupted teeth called cell rests of Malassez.

Pronounced difference is seen in development of roots of one (or) multirooted teeth.

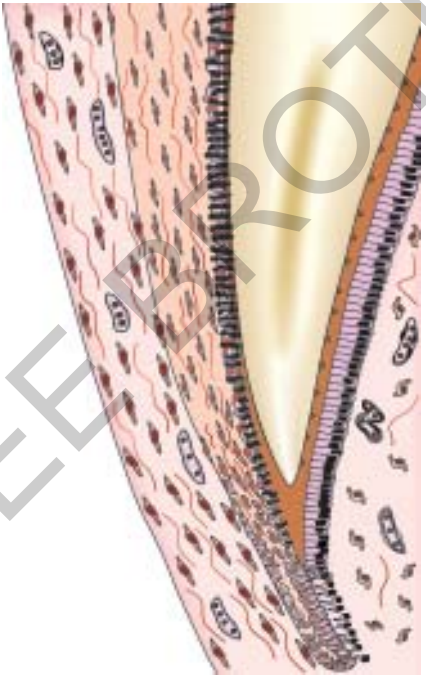

Fig. 2.7: Hertwig's epithelial root sheath

Before beginning of root formation, root sheath forms the epithelial diaphragm.

Outer and inner enamel epithelia bend at future cemento-enamel junction in a horizontal plane.

JAYPEE BROTHERS

Proliferation of cells of epithelial diaphragm is accompanied by proliferation of the cells of connective tissue of the pulp, which occurs adjacent to diaphragm.

Free end of diaphragm doesn't proliferate into connective tissue but proliferates coronally to epithelial diaphragm.

Differentiation of odontoblasts and formation of dentin, follows root sheath lengthening.

Connective tissue of dental sac surrounding the root sheath divides into double continuous epithelial layer.

Epithelium moves away from root surface of dentin. Connective tissue cells contact the surface and differentiate to cementoblasts and forms cementum.

Wide apical foramen is reduced first to width of diaphragmatic opening and then further narrowed by deposition of dentin and cementum at apex of the root.

Differential growth of epithelial diaphragm causes division of root trunk into 2 (or) 3 roots.

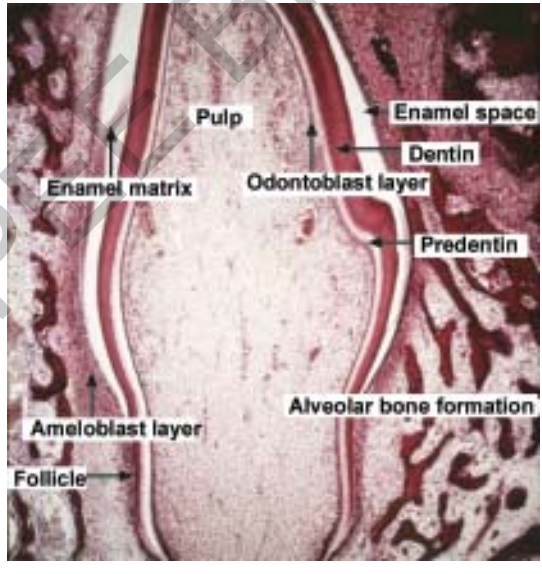

Fig. 2.8: Single rooted tooth formation

JAYPEE BROTHERS

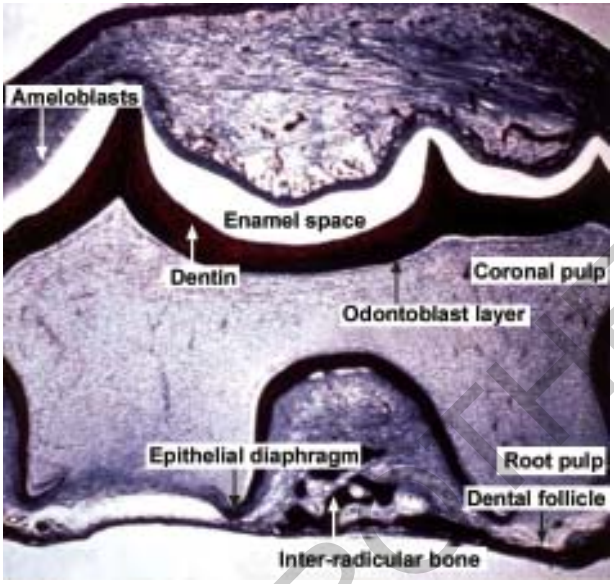

Fig. 2.9: Multirooted tooth formation

Long tongue-like extensions of horizontal diaphragm develop.

Two such extensions are seen in germs of lower molars and three are in upper molars.

JAYPEE BROTHERS



Textbook of Human Oral Embryology, Anatomy, Physiology, Histology and Tooth Morphology

SALIENT FEATURES

- Simplified but comprehensive coverage of Oral Histology and Tooth Morphology in a single textbook
- Additional sections of Human Oral Embryology, Oral Anatomy and Physiology are also included in the textbook.
- A special section has been dedicated to the Histochemistry of oral tissues
- Multicolor figures are provided in almost all the chapters for better understanding and appreciation of the concept.
- This textbook will be of immense help to the first and second year undergraduate students as all these topics come under their syllabus.



KMK Masthan is Professor and Head, Department of Oral Pathology and Vice Principal (Academics) of Sree Balaji Dental College and Hospital, Chennai, India. He completed his BDS in 1990 and MDS in 1993 from Tamil Nadu Government Dental College, Chennai, India. He has an extensive 16 years experience in teaching BDS and MDS students. He holds two books to his credit namely 'Guide to Oral Pathology' and 'Jaypee Gold Standard Mini Atlas Series Oral Pathology' published by Jaypee Brothers Medical Publishers (P) Ltd.

Available at all medical book stores
or buy directly from Jaypee Brothers through online shopping
at www.jaypeebrothers.com

or call + 91-11-32558559

JAYPEE BROTHERS
Medical Publishers (P) Ltd.
www.jaypeebrothers.com

ISBN 978-81-8448-892-0