Interesting X-rays in General Surgery



RP Gupta

JAYPEE

Contents

1. Chest **1**

2. Abdomen **57**

3. Genitourinary **127**

4. Hepatobiliary **157**

5. Important X-rays of Head and Neck **179**

6. Breast **187**

7. Bones **201**

8. Esophagus **211**

9. Miscellaneous **231**

Index *251*

Chapter **Two**

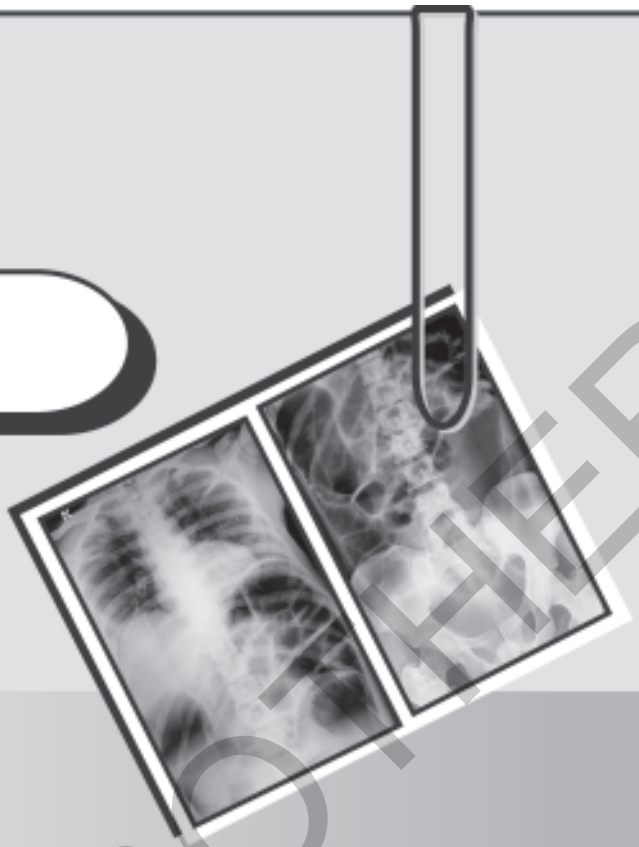

Abdomen

JAYPEE BROTHERS

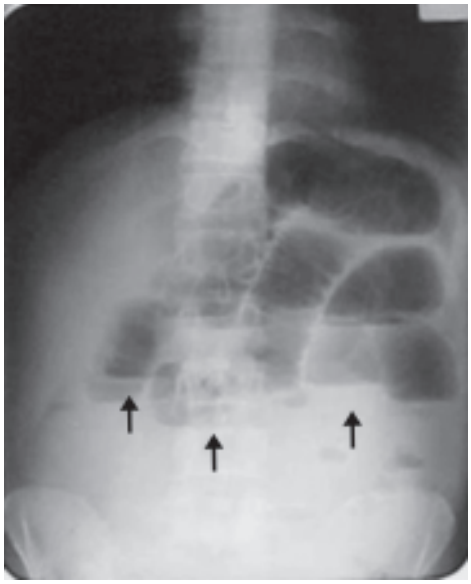

Fig. 1: Dilated small bowel loops along with fluid levels



Fig. 2: Multiple fluid levels



Fig. 3: Distended small bowel loops



Fig. 4: Dilated small bowel loops

JAYPEE BROTHERS

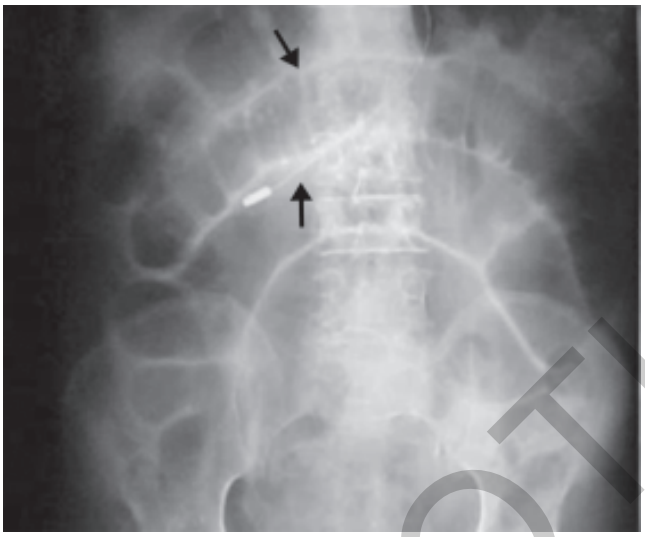

Fig. 5: Dilated small bowel loops

Whenever a patient comes with acute abdomen, always take two views of plain X-ray abdomen one in sitting position and other in lying down position to see for any gas filled loops and air fluid levels.

SMALL BOWEL OBSTRUCTION

- Dilated loops are mostly central and numerous.
- Measure less than 5 cm in diameter.
- Have a small radius of curvature.
- Contain valvulae convitentes which pass right across the bowel lumen, are thin and are close together.
- Fluid levels are seen in erect film, if more than 3-5 fluid levels are seen, it is suggestive of small bowel obstruction.

JAYPEE BROTHERS

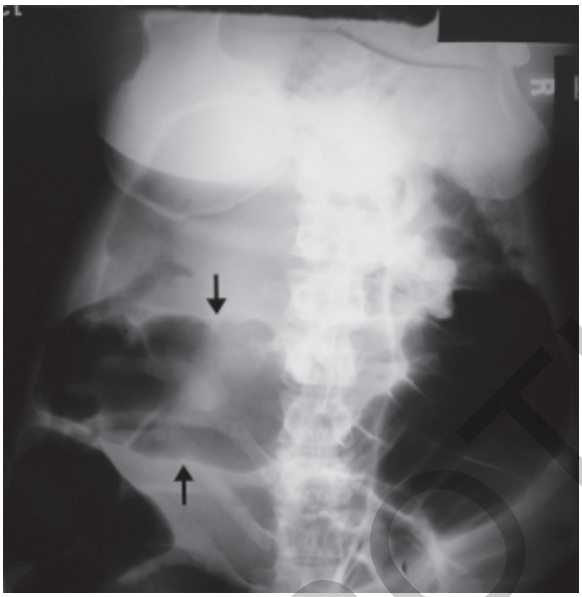

Fig. 6: Dilated large gut loops

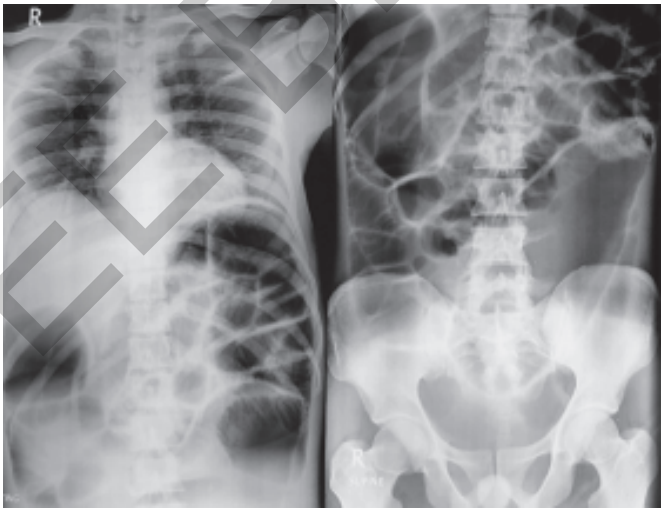

Fig. 7: Dilated large gut loops

JAYPEE BROTHERS

LARGE BOWEL OBSTRUCTION

- Large bowel loops are peripheral.
- Loops have wide radius of curvature.
- Are greater than 5 cm in diameter.
- Contain Haustrations which are thick and widely separated.

JAYPEE BROTHERS

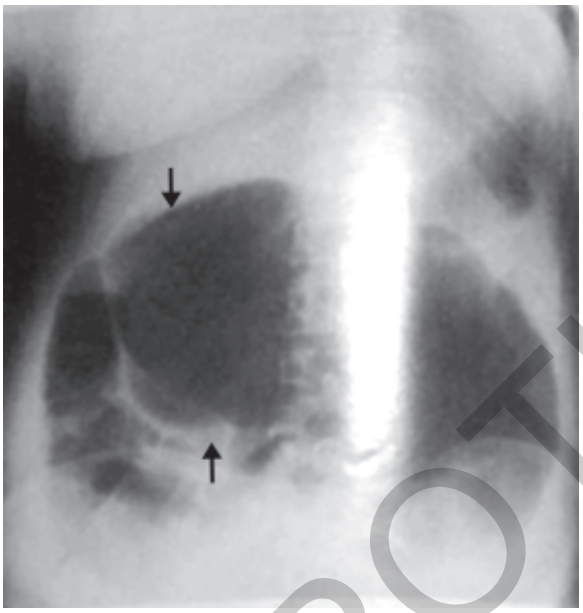

Fig. 8: Caecal volvulus

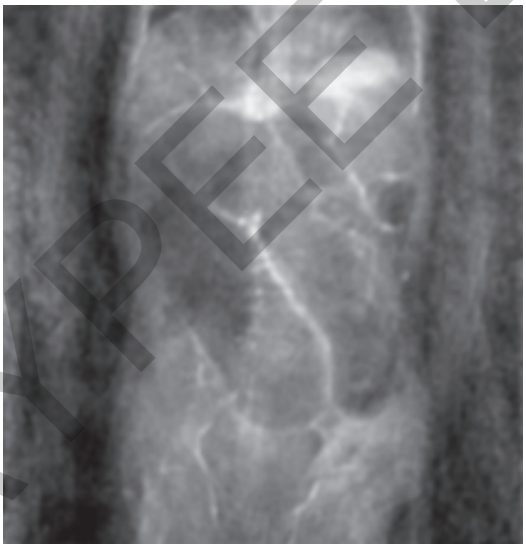

Fig. 9: Large gut distended

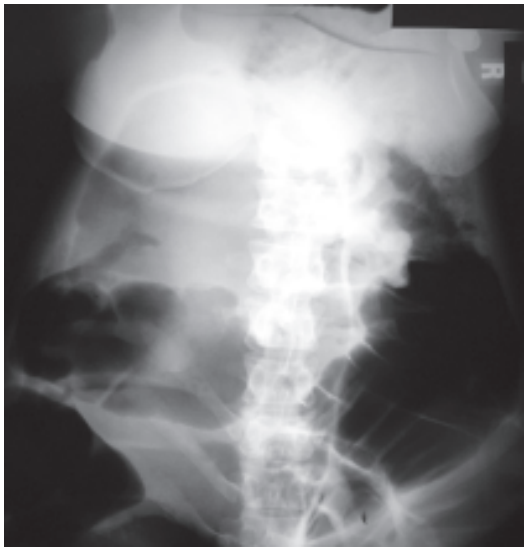

Fig. 10: Large gut volvulus (sigmoid volvulus)

JAYPEE BROTHERS

CAECAL VOLVULUS

- Massively dilated caecum in the central abdomen.
- Contains thick haustral markings.

SIGMOID VOLVULUS

- Grossly dilated Sigmoid colon arising from Pelvis.
- Lack of Haustral marking.
- Outer and inner walls of dilated loops converge in pelvis.

JAYPEE BROTHERS

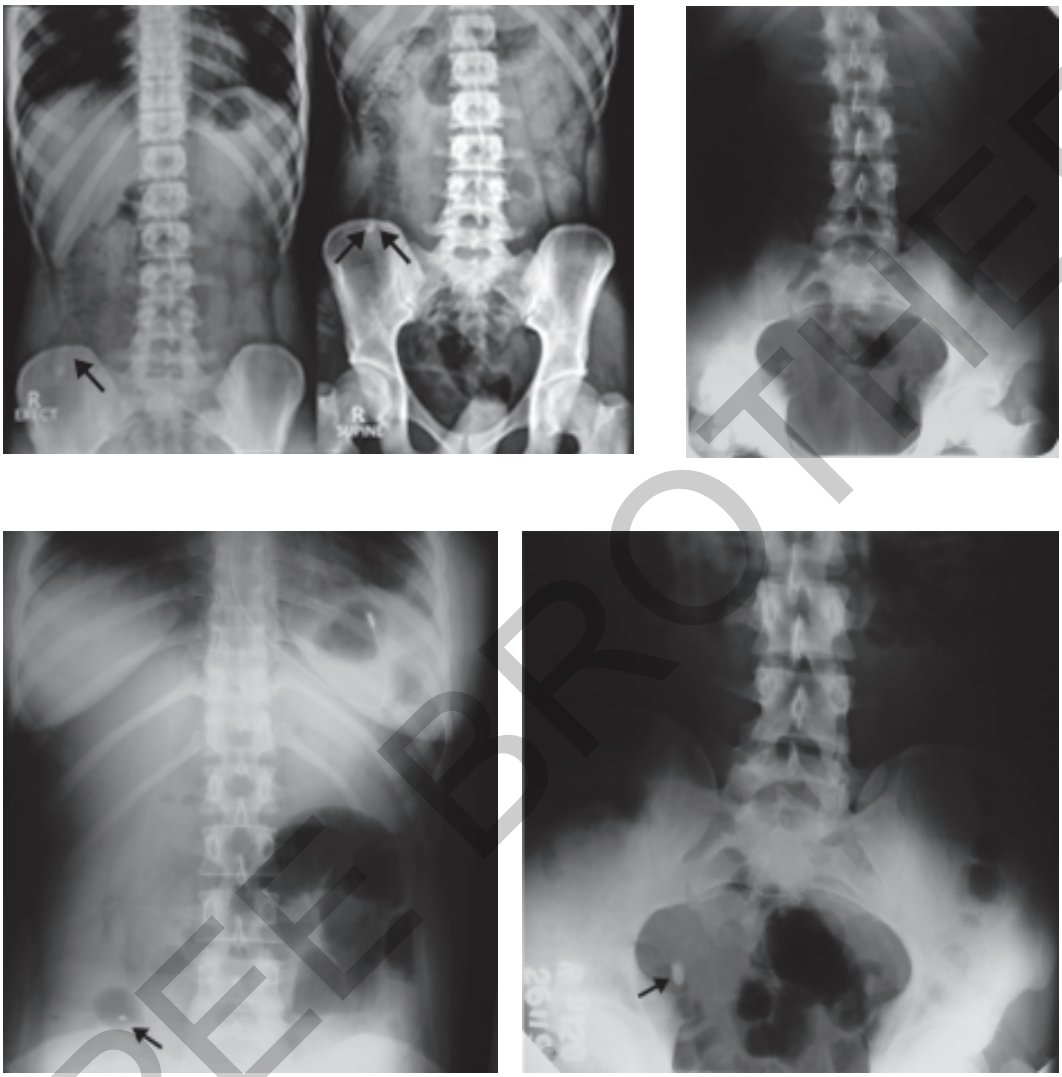

Fig. 11: Appendicolith

JAYPEE BROTHERS

APPENDICOLITH

- Radio opaque shadow lying over right ileum bone.
- Shadow usually is outside the line of ureter.
- In acute appendicits there is localized ileus in the region of right iliac fossa.

JAYPEE BROTHERS

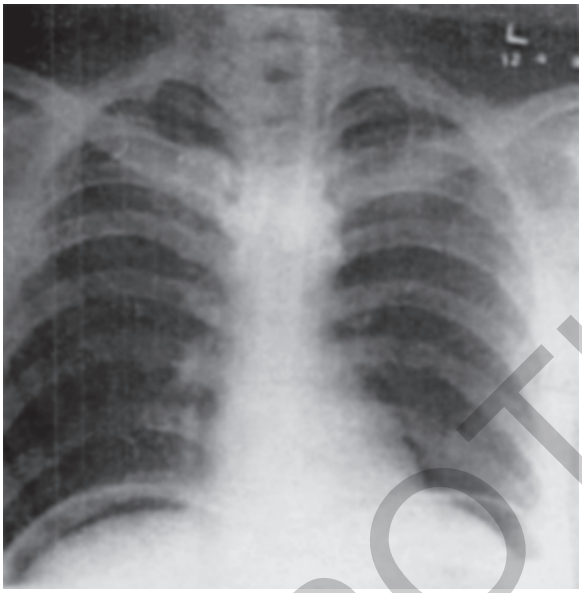

Fig. 12: Free gas under diaphragm

JAYPEE BROTHERS

PERFORATION OF GUT

- Presence of free gas under the diaphragm on one of both sides.
- At times this may be confused with colon lying between liver and diaphragm but presence of haustral markings will make it clear that this is not free gas but colon inter posed between diaphragm and liver.
- Free gas is usually seen under both domes of diaphragm.

JAYPEE BROTHERS

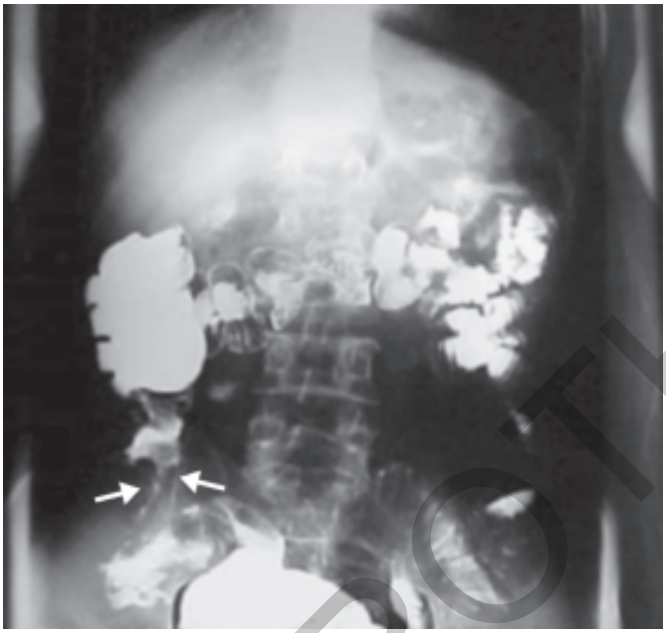

Fig. 13: Carcinoma of ascending colon (see arrow)



Fig. 14: Cancer caecum (see arrow)

JAYPEE BROTHERS

CARCINOMA OF COLON

- Seen on Barium enema as filling defect in colon. Always look for a second growth in rest of the colon.
- See for rolled elevated margins "Apple Core" appearance.

CAECAL CARCINOMA

- Seen as irregular filling defect on the medial wall of the caecum.
- Contraction of distal part of caecum is seen due to compression and inversion by tumor.

JAYPEE BROTHERS