Manual of Vascular Surgery



AK Khanna
Puneet

Foreword
SA Hussain

JAYPEE

CONTENTS

1. **Introduction to Peripheral Arterial Disease 1**
   AK Khanna
2. **Clinical Examination of a Vascular Case 5**
   SK Gupta, Puneet
3. **Vascular Imaging 21**
   Pankaj Patel
4. **Surgical Exposure of Vessels 35**
   Somprakas Basu
5. **Vascular Sutures and Anastomoses 84**
   AK Khanna
6. **Endovascular Interventions– Surgeon's Perspective 97**
   Rajiv Parakh
7. **Management of Vascular Trauma 104**
   Rakesh Mahajan
8. **Acute Arterial Ischemia 118**
   Seema Khanna, AK Khanna
9. **Chronic Arterial Insufficiency 127**
   Rahul Khanna
10. **Lower-extremity Atherosclerotic Arterial Disease 150**
    Vivek Srivastava, AK Khanna
11. **Buerger's Disease or Thromboangiitis Obliterans 174**
    Puneet, Rahul, AK Khanna
12. **Raynaud's Disease and Raynaud's Phenomenon 195**
    D Agrawal, TK Lahiri, A Pandey
13. **Nonspecific Aortoarteritis 204**
    D Agrawal, TK Lahiri, A Pandey, Renu Kushwaha

14. Arterial Aneurysms 225
Sudhir Rai

15. Arteriovenous Fistulas and Malformations 244
KK Pandey

16. Varicose Veins 267
AK Khanna, Nikhil

17. Deep Venous Thrombosis 291
AK Khanna, Nikhil

18. Diabetic Foot 312
SK Gupta, S Mahalik, Puneet

19. Hemangiomas 329
AN Gangopadhyay, Anand Pandey

20. Lumbar Sympathectomy 348
Sanjeev Kumar, AK Khanna

21. Amputations of Lower Extremity 359
Amit Rastogi

22. Compartment Syndrome 374
Puneet, Rahul, AK Khanna

23. Lymphedema 392
V Bhattacharya, Biswajit Mishra, Umesh Kumar

24. Portal Hypertension 417
AK Khanna

25. Microvascular Surgery: Basic Technique and Clinical Applications 436
P Jain, Seema Khanna

Index 455

Chapter 2

Clinical Examination of a Vascular Case

SK Gupta, Puneet

Vascular diseases include disorders of the arteries, veins or lymphatics. Diseases of the vascular system commonly seen in clinical practice are peripheral arterial disease, chronic venous insufficiency (including venous ulcers), venous thromboembolism and lymphedema. The clinical approach to a patient suffering from a vascular disease is no different than that applied to various other clinical situations. It essentially involves a careful history taking and a systematic clinical examination of the whole body rather than only of the part affected. Vascular diseases are one of the few areas in medicine which can be readily diagnosed only by a detailed history and a thorough clinical examination, the role of investigations being essentially limited for therapeutic decision making. This chapter will provide an overview of the salient features in history and clinical examination to make an accurate diagnosis of common vascular diseases.

History

The age and sex of the patient are important to note. Buerger's disease (Thromboangiitis obliterans) is more common in males while Raynaud's disease predominantly affects females. The former affects the lower extremities mostly whereas the latter is more commonly seen in the upper extremity. History of smoking is particularly important because it has been seen that Buerger's disease rarely occurs in nonsmokers. Any history of trauma should be elicited. Presence of diabetes, hypertension and hypercholesterolemia in the

JAYPEE BROTHERS

patient or family should also be recorded. Occupational history is also important because varicose veins are more commonly seen in persons whose occupation involves prolonged standing.

Pain: The two classical symptoms seen in patients with occlusive extremity arterial disease are "claudication" and "rest pain". Claudication derived from the Latin *claudicatio* refers to the discomfort or pain in the extremity which occurs on exertion, is aggravated by further exercise and relieved by rest. Since it occurs intermittently, it is better known as "intermittent claudication". The exact location of pain or discomfort gives a clue to the site of arterial occlusion as symptoms occur in the most proximal muscle group with inadequate perfusion. Thus severe iliac stenosis will cause pain in the buttock or thigh while superficial femoral and infrapopliteal disease will cause pain in the calf and pedal region respectively. Pain that disappears immediately after cessation of activity is not claudication and therefore not related to impaired perfusion. Similarly pain which occurs with specific positional changes or is relieved by activity is more likely to be neurogenic or musculoskeletal in origin. The "Walking Impairment Questionnaire" is a validated tool that not only evaluates the extent of walking impairment but also its etiology. The pain of claudication in the calf region is a cramping pain whereas in the buttock and thigh region (in patients with more proximal arterial occlusive disease) is more of an aching discomfort associated with weakness. This may mimic the pain or discomfort of osteoarthritis that is also brought on by exercise but here the amount of exercise causing pain is variable and the pain does not disappear promptly with rest. Moreover the intensity of pain varies from day to day. Bilateral aortoiliac disease severe enough to produce disabling claudication is almost always associated with impotence in men. Thus, absence of impotence in a man with bilateral hip or thigh pain suggests that pain is not due to aortoiliac occlusive disease unless the lesions are limited to external iliac arteries. Although claudication is a feature of arterial occlusive disease, venous occlusion can also cause claudication – the so called venous claudication. It is seen in patients with iliofemoral venous thrombosis in whom recanalization has not occurred. At rest, collaterals allow venous outflow to match arterial inflow but are unable to keep pace

JAYPEE BROTHERS

with the increased arterial flow after exercise. This results in engorgement of the venous channels which become tense and painful often described as a bursting pain. Because the venous engorgement subsides slowly on resting, the pain also does not disappear as quickly as that of claudications.

Pain or discomfort associated with tightness in the calf and precipitated by exercise, often occurring in an athlete may be seen in chronic compartment compression syndrome. Muscle swelling, increased compartment pressure and impaired venous outflow are the common features. However, pain occurs after considerable exercise and does not subside quickly on resting. Foot claudication without calf claudication, due to diffuse infrapopliteal arterial occlusive disease is relatively uncommon. This form of claudication may be confused with arthritic or inflammatory conditions involving the foot (e.g., rheumatoid arthritis, plantar fasciitis or metatarsalgia). However in the other conditions the relationship with exercise is variable and is not as precisely precipitated and relieved.

Rest pain seen in chronic critical ischemia occurs when perfusion pressure during inactivity is unable to meet basal requirements. It is typically a nocturnal pain of disturbing severity that affects the most acral part of the limb, usually the toes or foot but may be sharply localized in the vicinity of an ischemic ulcer or gangrenous toe. The pain may be so severe that it may not be relieved even by narcotic analgesics. Gravity often helps in alleviating the rest pain with most patients reporting relief when the leg is kept dependent as occurs when dangling from the bed.

The pain of acute limb ischemia (ALI) is variable. In lesser degrees of ischemia, pain may be absent or transient. However when it does occur, it is quite characteristic and different from the rest pain seen in chronic critical ischemia. Pain due to ALI is not as well localized to the distal foot nor is it clearly affected by gravity. It may be of a similar intensity as rest pain but tends to be more diffuse often extending above the ankle in severer cases. It begins suddenly and reaches a peak rapidly in the case of arterial embolism. The persistence of pain particularly if followed by numbness, weakness or both indicates that one is dealing with severe limb threatening ALI.

JAYPEE BROTHERS

Pain associated with venous diseases is not as characteristic as that in arterial disease. Fortunately, venous diseases are usually recognized from their associated clinical findings. Although symptoms associated with venous valvular insufficiency or obstruction are quite variable their aggravation by standing and relief by elevation are consistent. This is in marked contrast to the relative lack of discomfort associated with lymphedema.

Raynaud's Phenomenon: Episodic vasospasm of the digital arteries in response to cold is the hallmark of Raynaud's phenomenon. Clasically it comprises of three phases: digital pallor associated with arterial spasm, cyanosis from the deoxygenated blood collecting in the dilated arterioles and venules and redness from the rewarming and subsequent hyperemia. Patients may complain of coldness or numbness during the first two phases and a throbbing pain during the phase of reactive hyperemia. However, all three phases need not be present to infer a diagnosis. The severity ranges from intermittent mild attacks to prolonged vasospasm associated with ulceration and gangrene. There are a number of causes of secondary Raynaud's phenomenon which should be suspected in patients that have asymmetrical involvement of the digits, have prolonged vasospasm or develop tissue loss. Primary or idiopathic Raynaud's disease typically affects women and has a bilateral and symmetric distribution.

Swelling: After pain, swelling is the next most common symptom which is present in patients with vascular disease. High venous pressure is the most common cause particularly in long standing cases. In a chronically swollen leg, a diagnosis can often be made by noting the distribution of the swelling, its response to elevation and the associated discomfort and skin changes. If there are no obvious skin changes and the edema pits readily then the cause is usually central or systemic. It is almost always bilateral but may be unequal and the distribution is diffuse but the swelling is greatest peripherally. In contrast, the edema associated with venous disease does not pit readily and is associated with skin changes (stasis dermatitis) and have a "gaiter" distribution (the feet are often spared compared to the ankles and lower half of legs). It may be occasionally

JAYPEE BROTHERS

bilateral. The distribution of swelling in lymphedema is diffuse but is always greater distally. Skin pigmentation and ulceration are rare.

PHYSICAL EXAMINATION

Examination of arterial pulses is mandatory in patients with vascular disease. It should be done in a consistent and systematic manner. Pulses should be palpated by the fingertips (and not the thumb) exerting gentle pressure at first and increasing it gradually. Pulses should be palpated in the neck, arms, legs and trunk (Figs 2.1 to 2.10). Pulses should be examined bilaterally to appreciate subtle changes. In the neck, the carotid pulse may be palpated between the trachea and sternocleidomastoid muscle below the angle of the jaw (Fig. 2.4). The subclavian pulse may be palpated either in the supraclavicular fossa or between the lateral clavicle and pectoralis muscle (Fig. 2.3).

Upper extremity pulses typically examined include the brachial, radial and ulnar pulses (Figs 2.1 and 2.2). The brachial pulse is superficial and is found in the medial third of the antecubital fossa. The radial pulse is palpated at the wrist at the base of the first digit. It is a superficial pulse which is readily appreciated. The ulnar pulse



Fig. 2.1: Palpation of radial artery

JAYPEE BROTHERS



Fig. 2.2: Palpation of brachial artery



Fig. 2.3: Palpation of subclavian artery

requires deeper palpation and may be difficult to detect. In the lower extremity, the common femoral pulse can be examined just above or below the inguinal ligament, medial to the quadriceps muscle (Fig. 2.6). In the obese patients, femoral pulse may be palpated 4 cm below

JAYPEE BROTHERS



Fig. 2.4: Palpation of carotid artery



Fig 2.5: Palpation of abdominal aortic pulsation

and lateral to the pubic tubercle over the pubic ramus after externally rotating the hip. Popliteal pulse which is located in the popliteal fossa can be palpated by gently flexing (approximately 40°) the patient's leg (Fig. 2.7). The pulse is a transmitted impulse and generally not discrete. The examiner should use four fingers of both

JAYPEE BROTHERS



Fig. 2.6: Palpation of femoral artery



Fig. 2.7: Palpation of popliteal artery

hands to palpate in the lower part of fossa while applying a moderate counter pressure by the thumbs on the knee-cap. The posterior tibial pulse can be found just behind the medial malleolus midway between it and the tendo-Achilles (Fig. 2.8). Relaxation and dorsiflexion of the foot help in its palpation. The dorsalis pedis

JAYPEE BROTHERS



Fig. 2.8: Palpation of posterior tibial artery



Fig. 2.9: Palpation of dorsalis pedis artery

artery is felt on the dorsum of the foot just lateral to the tendon of the extensor hallucis longus (Fig. 2.9). It is usually 3-4 cm above the digits. Since the artery is absent congenitally in about 10% of the population, absence of pulsation may not be pathological. In the lower limb one can feel anterior tibial artery and peroneal artery

JAYPEE BROTHERS



Fig. 2.10: Palpation of anterior tibial artery



Fig. 2.11: Palpation of peroneal artery

(Figs 2.10 and 2.11). One should also palpate the abdominal aortic pulsation which is visually felt in thin patient and above the umbilicus slightly to the left side (see Fig. 2.5). An apparently normal pulse may disappear after exercising the patient to the point of

JAYPEE BROTHERS

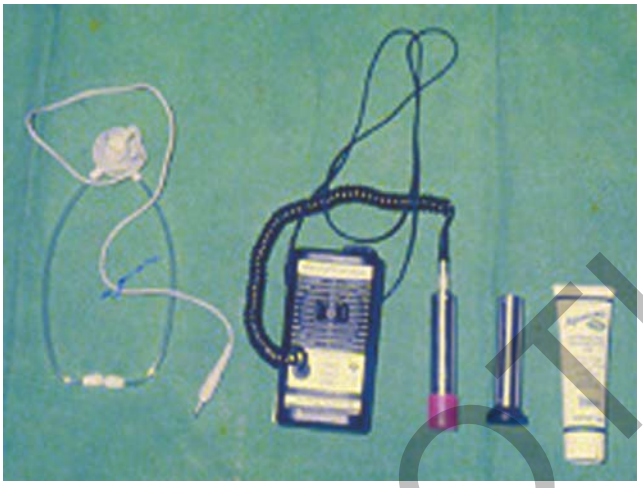

Fig. 2.12: Hand held Doppler

claudication. The disappearing pulse reappears following cessation of exercise. While examining the pulses one should note its rate, rhythm, volume, character, condition of the arterial wall and whether it is bilaterally symmetrical or not. A hand held Doppler probe (Fig. 2.12) provides a simple means of identifying blood flow in a vessel and a blood pressure cuff allows measuring of systolic blood pressure in the upper and lower limb arteries. Ankle Brachial Pressure index is a very important test for the diagnosis of ischemia (Fig. 2.13).

There may be a palpable thrill and/or an audible bruit or occasionally the machinery murmur of an arterio-venous fistula. Bruit is a sound caused by turbulence of blood flow which may be due to arterial stenosis, extrinsic compression, aneurysmal dilation or arterio-venous connection. As the severity of the stenosis progresses the pitch of the bruit increases. Similarly if the bruit continues into diastolic phase it suggests advanced stenosis. Continuous bruits are heard during both systole and diastole and are pathognomonic for arterio-venous connections.

A complete and thorough systemic examination is an essential component of the physical examination in vascular cases. Particular

JAYPEE BROTHERS



Fig. 2.13: Measurement of ankle systolic pressure

attention should be paid to the central nervous system, the heart and the abdomen. In the cerebrovascular system, in addition to the carotid arteries, the superficial temporal artery also should be palpated. The patient's higher mental functions, speech abnormalities if any, visual defects and any evidence of motor and sensory disorders should be carefully noted. Discovery of previously undetected hypertension, fibrillating heart, valvular abnormalities or abdominal aortic aneurysm may be useful pointers. Abdomen should be examined not only for an aortic aneurysm but also for an abdominal or pelvic mass causing inferior vena caval obstruction. Auscultation should be done for detecting celiac, renal or iliac bruits. Renal artery bruits are best heard posteriorly just below the 12th rib (renal angle).

Signs of Advanced Ischemia

Pallor and coldness of the ischemic extremity with delayed capillary refilling after pressure on the pulp of the digit and slow venous refilling after the elevated extremity is dropped back into the dependent position are signs of advanced ischemia. Normal patients have pedal venous refill in less than 15 seconds while, in the ischemic

JAYPEE BROTHERS

limb it takes 30-45 seconds. The chronically ischemic extremity undergoes nutritional or trophic changes in the form of atrophy of calf muscles, thin, shiny and atrophic skin and absence of hair and brittle and deformed nails. *Buerger's sign,* i.e. pallor on elevation and rubor on dependency indicate advanced ischemia. The angle at which pallor appears on raising the legs is called the *Buerger's angle*. Color changes in the skin should also be noted. Arterial occlusive disease or embolism may lead to ischemic ulcers. They tend to be small, annular, pale and dessicated. They are usually located in the acral areas of the limbs, specifically the toes, heel and finger tips. Ischemic ulcers are painful in contrast to the painless neurotropic ulcers of diabetes. Diabetic ulcers which occur frequently in the setting of arterial occlusive disease, occur in the area of callus formation, bony prominence or areas exposed to trauma such as those caused by ill-fitting shoes. Progression of ulceration leads to tissue necrosis and gangrene. Presence of gangrene is unmistakable. The extent and the type (whether wet or dry) of gangrene should be noted. Presence of crepitus is characteristic of gas gangrene and is a grave prognostic sign.

Allen Test: The circulation of the hand is supplied by the radial and ulnar arteries through the palmar arch. This test can demonstrate the presence of an incomplete palmar arch. Occlusive pressure is applied over the radial and ulnar arteries. The patient is asked to open and close the fist several times to create palmar pallor. The examiner then releases one pulse. Normal skin color should return within seconds. The other artery is tested in the same manner. Slowly resolving or persistent pallor indicates occlusion of the vessel distal to the pulse.

Thoracic Outlet Maneuvers: A positive Adson's test is seen in presence of cervical rib or the scalenus anticus syndrome due to compression of the subclavian artery. The patient sits on a stool. He is instructed to take a deep breath and turn face to affected side with neck extended. The radial pulse gets obliterated or feeble due to pressure on the subclavian artery. However, general application of these maneuvers is not warranted because they may be positive in up to 50% of the population.

JAYPEE BROTHERS

Critical Ischemia: It refers to arterial disease that endangers the whole or part of leg. The following objective criteria define critical ischemia: persistent, recurrent rest pain (requiring regular analgesics for more than 2 weeks), and/or ulceration or gangrene of the foot or toes, with an ankle systolic pressure of less than 50 mm Hg.

THE VENOUS SYSTEM

In contrast to the stark symptoms and signs of arterial insufficiency, venous disease demonstrates fewer signs and therefore requires a more subtle physical examination. In a patient with varicose veins, common complaints include pruritus, burning, aching, swelling and heaviness. These are absent in the morning and become evident and aggravate during the day. The symptoms are usually relieved by leg elevation. Swelling of the extremity is the most common symptom of chronic venous insufficiency. There is hyperpigmentation of the skin due to hemosiderin deposition. This results from lysis of red cells and occurs preferentially around the malleoli and pretibial regions. If chronic venous insufficiency is left untreated, it results in brawny edema, stasis dermatitis and ulceration. Venous ulcers are shallow, large with irregular borders, erythematous and moist and are usually near the medial or lateral malleolus ("gaiter" area). The base is granulating and the surrounding skin is hyperpigmented and may be shiny (cutaneous atrophy).

The commonest cause of chronic venous insufficiency is deep vein thrombosis. An acutely thrombosed superficial vein feels like a cord. It is tender and may be surrounded by erythema, warmth swelling and induration. Even thrombosis of deep vein if associated with inflammatory reaction may result in tenderness along its course. If deep calf veins are thrombosed, there may be pain on dorsiflexion (*Homan's sign*), tenderness on anteroposterior but not on lateral compression of the calf (*Bancroft's sign*) and pain in the calf caused by inflation of a blood pressure cuff around it to a pressure of 80 mm Hg (*Lowenberg's sign*). Unfortunately, these signs are present in less than a third of patients with acute deep vein thrombosis (DVT).

Tests for Varicose Veins

The Brodie-Trendelenberg test– It is done to test the competence of the saphenofemoral junction and the perforators. The patient lies on a

JAYPEE BROTHERS

couch and the limb is elevated to empty the veins. The saphenofemoral junction (1½ inches below and lateral to pubic tubercle) is occluded by a tourniquet. The patient is asked to stand up. If the veins fill rapidly from below despite the applied tourniquet, it indicates incompetent perforating veins. Rapid filling of the veins from above downwards on releasing the tourniquet indicates incompetence of the saphenofemoral junction. The exact site of incompetent perforators can be further ascertained by placing multiple tourniquets around the thigh and calf and observing which venous segment fills on sequentially releasing the tourniquets.

The cough impulse test– The fingers are placed over the saphenous opening. A palpable fluid thrill, on asking the patient to cough, indicates an incompetent saphenofemoral junction.

The percussion or tap sign– The fingers of the left hand are placed over the saphenous opening. The main bunch (most prominent part) of the varicosities is percussed or tapped by the fingers of the right hand. A thrill is felt by the fingers at the saphenous opening thereby indicating that the valves are incompetent.

Identifying perforator sites (Fegan's method)– Mark the varicosities with the patient standing. After making the patient lie down and elevating the legs, palpation along the line of varicose veins reveals the gaps in the deep fascia through which the perforators pass. These are felt as circular openings with sharp edges.

Test for patency of deep veins (Perthe's test)– If the patient complains of bursting pain on standing, the test for deep vein patency is carried out. With the patient standing, a tourniquet is tied around the thigh and the patient is asked to walk for 5 minutes. If the pain is brought on or if the varicosities become more prominent, it indicates that the deep veins are occluded. These tests have lost their clinical importance with the advent and widespread use of color Doppler imaging which is a very useful non-invasive modality not only for the diagnosis of deep vein thrombosis but also for incompetent perforators.

The most common physical findings of deep vein thrombosis include unilateral leg swelling, warmth and erythema. *Phlegmasia cerulea dolens (blue leg)* is due to massive iliofemoral thrombosis. Tingling and numbness accompanied by severe painful cramp in

JAYPEE BROTHERS

calf or thigh are early features. The limb soon becomes deeply cyanotic with marked swelling which feels tense. *Phlegmasia alba dolens (white leg)* results from impedance of arteriolar and capillary flow causing pallor. The leg will however be edematous, turgid and improved with elevation unlike a limb with arterial occlusive disease.

LYMPHATIC DISEASE

Lymphedema: May result from lymphatic absence, underdevelopment or obstruction. In the initial stages lymphedema resembles the edema seen in chronic venous insufficiency however it has a diffuse distribution and is greatest distally. It is mildly relieved by elevation of the limb. In the early stage, it is pitting and soft. The "square toe" sign helps in differentiating lymphedema from venous edema. Lymphedema in lower limbs tends to extend to the boundary of the toes in contrast to venous edema. With time the extremity starts becoming wooden with progressive induration and fibrosis of affected tissues. The skin becomes thickened and lichenified. Recurrent attacks of lymphangitis in the form of fever with chills and red streaks in the affected part contribute to the swelling. Usually there is induration of the regional nodes.

In conclusion, good vascular diagnosis is based on a careful interrogation and thorough physical examination. The location and extent of the vascular disease and the degree of circulatory impairment can be objectively demonstrated by noninvasive diagnostic methods. Angiographic confirmation should be sought only if needed for major therapeutic decisions including the need for reconstructive vascular surgery or angioplasty.

JAYPEE BROTHERS