TOPICS IN COLORECTAL SURGERY



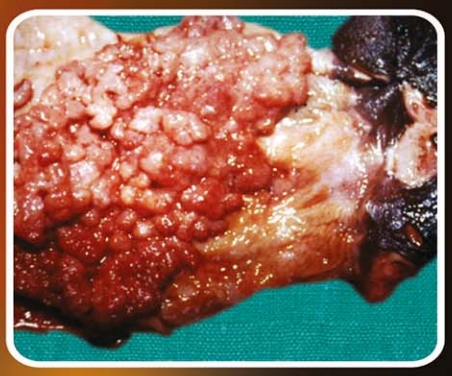

P Sivalingam

JAYPEE

Contents

1. History of Colorectal Surgery ---------- 1
2. Setting up Colorectal Clinic and Examination for Anorectal Lesions ---------- 5
3. Pelvic Floor Musculature—Levator Ani ---------- 13
4. Anorectal Physiology ---------- 18
5. Constipation ---------- 29
6. Congenital Anorectal Anomalies ---------- 38
7. Hirschsprung's Disease ---------- 46
8. Anorectal Suppuration ---------- 54
9. Fistula in Ano ---------- 64
10. Fissure in Ano ---------- 74
11. Hemorrhoids ---------- 84
12. Pilonidal Sinus ---------- 101
13. Anal Stenosis ---------- 106
14. Pruritus Ani ---------- 111
15. Fecal Incontinence ---------- 116
16. Adynamic Intestinal Obstruction ---------- 125
17. Colonic Pseudo-obstruction ---------- 133
18. Colonic Volvulus ---------- 138
19. Necrotizing Fasciitis ---------- 145
20. Irritable Bowel Syndrome (IBS) ---------- 150
21. Pre- and Probiotics ---------- 158
22. Lower GI Bleeding ---------- 166
23. Bowel Preparation ---------- 174
24. Colorectal Endoscopy ---------- 181
25. Crohn's Disease ---------- 191

26. Ulcerative Colitis ---------- 202
27. Colostomy Care ---------- 215
28. Complications of Colostomy ---------- 224
29. Colon and Rectal Anastomosis and Prevention of Leak ---------- 232
30. Management of Fecal Fistula ---------- 238
31. Rectal Prolapse ---------- 246
32. Polyps of Colon and Rectum ---------- 265
33. Predisposing Factors for Colon and Rectal Malignancy ---------- 274
34. Carcinoma of Colon ---------- 279
35. Carcinoid Tumors of Intestine ---------- 288
36. Carcinoma of Rectum ---------- 296
37. Recurrent Rectal Cancer ---------- 307
38. Carcinoma of the Anal Region ---------- 315

Index ----------323

Chapter

2 Setting up Colorectal Clinic and Examination for Anorectal Lesions

HISTORY OF COLORECTAL SURGERY

Though the surgery in colon and rectum and anal canal has been known and practiced since the dawn of civilization, it is only in recent times that the importance and seriousness of colon and rectal diseases have been realized.

In 1835 Frederick Salmon established St Mark's hospital in London. Later St Mark's became the Mecca of treatment of colon and rectal diseases and was and continues to be visited by many surgeons throughout the world. An American Physician Joseph W Mathew got training in St Mark's Hospital and started colorectal practice in America in 1878.

The History Taking

The diagnosis of anorectal diseases depend on a careful assessment of information derived from medical history, rectal examination, Proctoscopy, Sigmoidoscopy, abdominal and general examination, colonoscopy and other investigations. The use of these investigations varies from patient to patient. With some complaints the diagnosis is virtually evident from the history alone or on very simple physical examination. Rarely even with all latest investigations it may not be possible to arrive at the conclusion. Under these circumstances, re-examination when the symptoms are maximal or after an interval of some time may prove helpful.

JP Lockhart Mummery in his classical book on Diseases of the rectum and colon stated that in the diagnosis of rectal disease, the history is of little significance and every thing depends upon the physical examination. The reason is it is the great difficulty, which the average patients experience in describing the rectal complaints with delicacy and precision. It may be true for rectal conditions. But for sigmoid and other parts of the colonic conditions history taking is essential. To cut short the time, it is advisable to break one of the first rules of medical history taking and to ask the patient quite deliberately a series of leading questions about specific symptoms and their duration. A comprehensive history, paying particular attention to the patients over description of symptoms, is essential. Many problems can be diagnosed solely on the basis of the history. In other cases it can help to narrow down the differential diagnosis.

JAYPEE BROTHERS

Examination

A good light is essential for preliminary inspection of the anal region and illumination focusing down to proctoscope. For this purpose the angle poise examination lamp is excellent. The bulb should be at least 100 watts. Halogen light can be used for good illumination. Good ventilation with exhaust provision is essential.

Examination Couch

For full rectal examination the patient should ideally be on proper examination couch top which must be at least 80 cm from the ground other wise the surgeon will have to stoop unduly. Disposable gloves must be used for rectal examination. Petroleum jelly should not be used, as it is difficult to clean from the instrument and from the patient's skin. Water soluble lubricant with lignocaine is much more convenient from this point of view.

Proctoscope

Many different patterns of proctoscopes are available. The variations affect the length, caliber and shape. The larger the bore of the instrument that can be passed the better will be the view obtained. Normally 7 cm long and with a diameter of 22 mm at the tip and 32 mm at the base is useful. For patients with painful lesions or with some degree of anal spasm or stenosis, a narrower instrument is necessary. The length of the anal canal varies in patients according to physique. In some heavily built people the proctoscope cannot be inserted beyond the anal canal. For therapeutic, proctoscope with an oblique distal end, is useful because it enables more direct visualization of piles for injection or rubber band. Disposable proctoscope and self illuminating for diagnosis and therapy are also available.

Long alligator forceps are used for holding swabs and for Biopsy. The forceps of this pattern 35 cm with small serrated blades for gripping cotton wool to swab out the lumen of the bowel are the integral part of the sigmoidscopy. The biopsy forceps with sharp cupped blades for rectal lumen or other lesions also be available during sigmoidoscopy. Long suction tube may be useful when the feces are very liquid and profuse as in ulcerative colitis.

Dressing Trolley

A dressing trolley of 80 × 65 × 45 cm with underneath self and cupboards is useful to keep all instruments used during the colorectal clinical examination. A number of kidney treys and a bucket for receiving the dirty swabs are necessary. Provision must be made to hold the sigmoidoscope and long alligator forceps which is attached to the trolley in the form of long holder.

Equipments for minor surgical procedures like incision and drainage of abscess, Biopsy forceps for the anal region, injection therapy for piles

JAYPEE BROTHERS

and cauterizing agents like copper sulphate sticks and anal dilatators for stricture anal canal, Rubber band ligator, etc. must be available in the colorectal out patient department for immediate use when required.

Position of Patient

Views differ about the best position for the anorectal assessment. Left lateral position (Fig. 2.1A) is the simplest and more satisfactory for all ordinary purpose. The patient's buttocks must project a little beyond the edge of the surgeon's side of the couch. A small sand bag may be placed under the buttocks. The trunk must lie obliquely across couch top so that the head lies near the opposite edge. The position of the trunk is arranged in such a way that the hip is flexed to about 100° and the legs parallel and close to the opposite edge of the couch. The right shoulder is placed little downward direction, so that there will be a prone inclination for the trunk of the body. It is important that this inclination of the body should be maintained throughout the examination.

Knee chest position (Fig. 2.1B) is awkward and undignified for the patient. The patients who are examined in this position may be susceptible to syncope after the examination. Inverted or Jack Knife (Fig. 2.1C) position is popular in US and is extremely efficient position for sigmoidoscopy.

Conduction of Examination

General Consideration

Rectal examination is very embracing experience for the patient. If the patient had pain in the anal region, pain during and after defection, the patient will be very apprehensive and he will have tight anal sphincter and spasm of buttock muscles. This does not make for easy examination, if the surgeon proceeds regardless of it, the spasm increase, so-the rectal examination become extremely difficult. The surgeon first duty is to ally any anxiety and to encourage the patient to relax his musculature and keep it relaxed throughout the examination. Utmost gentleness at every stage of examination is essential. If there is sphincter spasm the finger or the instrument must not proceed at ordinary tempo, but must delay till the muscle relaxes. Any attempt to overcome the spasm with undue force usually hurt the patient and increase the tension of the muscles. An essential feature of gentleness in examination is the avoidance of instruments that are badly designed. Unpleasantness of rectal examination can be minimized by warning the patient in advance about the nature of the examination and explain any sensation or discomfort that may occur. The patient must be warned about the sensation or feeling of passing wind or urgency for stool when rectal examination is being done.

Inspection

This is one of the most neglected parts of the clinical examination of the patients with rectal conditions. Lesions like anal fissure or hematoma,

JAYPEE BROTHERS

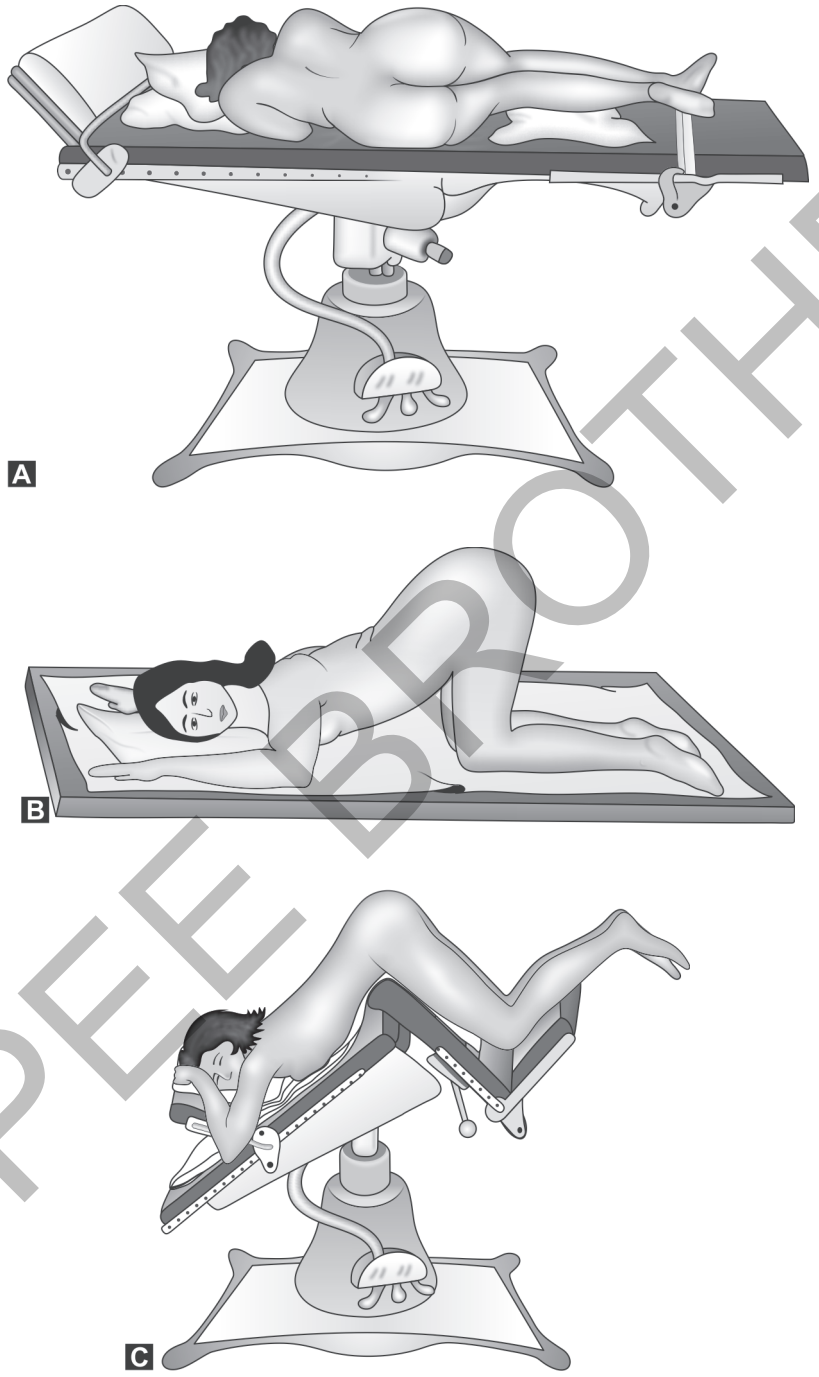

Figs 2.1A to C: Different positions for examination (A) Left lateral position, (B) Knee chest position, (C) Jack knife position

JAYPEE BROTHERS

anal warts or pruritus, can be diagnosed on inspection itself. With the left hand lift the upper most buttocks to expose the anus and perineal region to have clear view of the pathological conditions like anal hematoma, prolapsed internal piles, skin tag, lower edge of carcinoma, the external opening of an anal fistula or perianal infection and abscess. The state of tone of the anal sphincters can be judged. In suspected rectal prolapse it may be necessary to examine the patient during straining on a toilet.

Rectal Examination

To achieve a satisfactory and reasonably comfortable examination, it is essential to inform the patient about what is going to the done and what is to the expected and what is happening. Rectal examination may be unsuccessful if proper explanation is not provided. The gloved index finger is lubricated with water soluble lubricant and the pulp of the finger should be placed gently over the anal orifice and pressure is exerted until the sphincter relaxes allowing the finger to enter. Surrounding structure should then be examined in an organized manner. By rectal examination not only the interior of the anal canal and rectum are palpable but also the walls and the structures outside the walls are palpated. The finger will reach tumors up to 7 cm from anal margin. By pushing on the perineum an extra 2-3 cm can be reached. After reaching the upper palpable limits, the finger is withdrawn slowly feel the whole circumference of the wall of rectum and anal canal and the anterior, posterior and lateral structures in relation to the rectum.

Anorectal ring is situated at the junction of the surgical anal canal and the rectum, is a composite fibro muscular band composed of the upper part of the internal sphincter muscle, the longitudinal muscle, the puborectalis muscle and the deeper part of external sphincter muscle. The posterior and lateral part of the ring is easily palpable. The tip of the finger is in level with it when the proximal inter phalange joint is at the anal verge. When the finger is inserted a little further the distal inter-phalange joint can be flexed over the upper surface of the muscular ring. The coccyx can be felt behind the rectum. Running forwards from the coccyx on either side is the sacrospinous ligament. In men the prostate and seminal vesicles should be palpated for abnormal firmness, hypertrophy or nodularity. Internal hemorrhoids are normally not palpable but very long standing hemorrhoids associated with much fibrosis may be felt as longitudinal ridges or folds. Indurations following injection treatment may remain palpable just above the anorectal ring for several weeks. When a tumor is palpated, its position, size and its character in relation to polyphoid, sessile or ulcerated and the depth of bowel wall involvement, mobility, fixity and its involvement in relation to the circumference of the bowel and distant from anal margin.

In female the cervix of the uterus should not be mistaken for a tumor, which is more commonly occurs when the cervix is irregular. By-digital examination of the anal canal and perianal structures is essential to find out the course of fistula tract.

JAYPEE BROTHERS



Fig. 2.2: Proctoscopic examination

Proctoscopy (Fig. 2.2)

Many types of proctoscopes are available, range from disposable, re-useable with self lighted versions in both types No special preparation is required. Select the size of the proctoscope for the individual case depending upon the digital examination findings. The proctoscope is smeared with water soluble lubricant. It is held in the right hand with the thumb over the obturator handle and is gently introduced into the anal canal and gently pushed in the direction of umbilicus until the point enters the lower third of rectum.

This is appreciated by diminished resistance to the passage of the proctoscope. After the full length of the proctoscope is introduced, the obturator is removed and the tip of the obturator is looked for the blood, pus or feces. The lumen is examined for the presence of faces, blood or mucus. The mucus membrane is next observed for any evidence of inflammation, ulcer, etc. The proctoscope is slowly withdrawn and look for piles and hypertrophied anal papilla. It is necessary to re introduce the proctoscope for further assessment of piles as the patient strains. For this the proctoscope is withdrawn completely and is introduced after fitting the obturator.

Sigmoidoscope (Fig. 2.3)

Rigid Sigmoidoscope of different diameter and length are available, normally the scope of 16 mm diameter and 30 cm length scope is used.

Pre-examination enema is usually not necessary and the enema actually has draw back in two ways.

1. The contents in the enema may irritant to the rectal mucosa and may cause mucus discharge, which may give rise to confusion in diagnosis.

JAYPEE BROTHERS

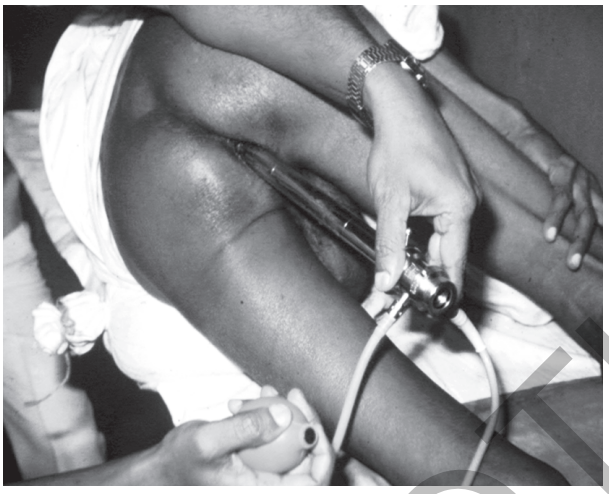

Fig. 2.3: Sigmoidoscopic examination

2. If there is no complete return of enema fluid, the rectum and sigmoid will be full of liquid feces. The fluid faces is much more difficult for sigmoidoscopy examination than loaded semisolid feces. In other words inefficient preparation is much worse than no preparation at all.

No anesthesia is needed even when painful lesions are present. The operators left forearm should rest on the patient's right buttock to give control over the movements of the instrument and to be a safe guard in case when the scope moves suddenly. The scope after well lubrication first passed towards the umbilicus and later towards the sacrum.

The low rectum and mid rectum are essentially mid line structures. The upper rectum bends slightly to the left. The recto sigmoid Junction usually turns sharply to the right and ventrally. Passing the scope around the recto sigmoid turn may be quite uncomfortable for the patient or even impossible. The first valve of Houston is seen at the 7 cm on the left side and the middle value at 9-11 am on the right side which corresponds with the reflection of peritoneum of the middle third of rectum. It is important to pullback the instrument from time to time "Stand off' the bowel wall and reassess the direction of the lumen ahead. Prolonged 'Slide by' is contraindicated. At about 15 cm particularly on the left side, pulsation of common iliac artery is visible. At this level the sigmoidoscope is pointing towards the umbilicus once again. Whilst it is desirable to pass the sigmoidoscope to its full limit, indication for this would be assessed in the light of the patient's symptom and the degree of discomfort.

It is on withdrawal that most attention is given to the location of pathology. Excessive insufflations with air should be avoided. The instrument is withdrawn in 'Ziz-Zag' fashion so that the lumen is kept in view always. Biopsy of the any suspected lesion should be done. But biopsy would be the last step in the sigmoidoscopy as it might cause a certain amount of bleeding, which obscures subsequent views. Before removing the scope, the air in the rectum must be released.

JAYPEE BROTHERS

General Examination

General physical examination must be done in all colorectal symptoms. Examination of the neck may reveal thyroid enlargement possibly related to diarrhea, enlarged lymph nodes in abdominal lymphoma, circumoral pigmentation in Peutz-Jegher syndrome oral ulcer and gum changes in Crohn's disease. The findings on inspection, palpation, and Proctoscopy and sigmoidoscopy should be clearly recorded. When the first rectal examination is done and a growth is made out, a complete description of the lesion must be recorded. The nature of the lesion either ulcerative, proliferative, or ulceroproliferative, involvement of the rectal wall in relation to clock position, consistency, lower limit in relation to dentate line, upper limit could be reached or not, involvement of the muscle layer and extra rectal plane. Biopsy must be done in the first examination itself. They are valuable to decide the type and scope of operation and other forms of treatment.

JAYPEE BROTHERS



Topics in Colorectal Surgery

Salient Features

- A ready reference text
- Covers rapid development in pathophysiology, modern investigation and treatment protocol in the field of colorectal surgery
- Includes chapters like history of colorectal surgery and predisposing factors for colorectal malignancy
- Helps surgeons to handle effectively the most complicated cases encountered in colorectal surgery like fistulas, piles, inflammatory bowel diseases, rectal carcinomas, etc.
- Useful for practising colorectal surgeons, postgraduate students as well as trainees and teachers, PG entrance examination aspirants, etc.

Available at all medical book stores
or buy directly from Jaypee Brothers through online shopping
at www.jaypeebrothers.com

or call + 91-11-32558559

JAYPEE BROTHERS
Medical Publishers (P) Ltd.
www.jaypeebrothers.com

ISBN 978-81-8448-930-9