Instructive Case Studies in PEDIATRICS

Suraj Gupte

5th Edition

Foreword WE Peterson

JAYPEE

Contents

1. Congenital hypothyroidism (cretinism) 1
2. Nephrotic syndrome 3
3. Nutritional dwarfing… celiac disease 5
4. Pericardial effusion 8
5. Down syndrome… celiac disease 11
6. Infantile tremor syndrome 13
7. Meningococcemia 15
8. Carbamazepine-induced CNS episode... tetralogy of Fallot (TOF) 18
9. Obesity… Laurence-Moon-Biedl syndrome… Pickwickian syndrome 21
10. Morquio's syndrome 23
11. Turner's syndrome 26
12. Cystic fibrosis… rectal prolapse 28
13. Pertussis 30
14. Herpes zoster 32
15. Acrodermatitis enteropathica… Hib vaccination 34
16. Acute lymphoblastic leukemia 36
17. Protein-energy malnutrition… nutritional rehabilitation… pseudotumor cerebri… nutritional recovery syndrome… Kahn syndrome… albendazole 39
18. Congenital rubella syndrome… PDA 42
19. Cavernous hemangioma 45
20. Systemic lupus erythematosus 47
21. Nutritional anemia… Wellcome classification of PEM… ancylostomiasis… primary complex 50
22. Miliary tuberculosis… marasmus… rickets… intestinal parasitosis 53
23. Food poisoning...phenothiazine toxicity 56
24. Breath-holding spells… H. nana infestation... bronchiolitis… Sturge-Weber disease 59
25. Wilms' tumor… septicemia (neonatal) 62
26. Bleeding disorder… von Willebrand's disease 65

27. Henoch-Schönlein purpura… Hess test technique 68
28. Necrotizing enterocolitis 70
29. Transposition of great arteries… CCF… fetal-alcohol syndrome… LBW… SFD 73
30. Enterobiasis… PEM… ambiguous genitalia 75
31. Precocious puberty 78
32. Infantile tremor syndrome… rickets 80
33. Jacksonian epilepsy… Todd's postictal paralysis… cysticercosis 83
34. Chronic persistent hepatitis… drug-induced hepatitis… dental caries 86
35. Recurrent abdominal pain… tapeworm infestation… Crouzon's syndrome 89
36. Cystic fibrosis… cellophane tape technique for enterobiasis 92
37. Osteogenesis imperfecta 95
38. Laurence-Moon-Biedl syndrome… exogenous/ endogenous obesity… physiologic obesity… familial obesity… slipped femoral epiphysis… Prader-Willi syndrome 97
39. Intussusception… Henoch-Schönlein purpura 99
40. Neonatal hepatitis… natal teeth… oculomandibulofacial dyscephaly 102
41. Hemolytic anemia… G-6-PD deficiency… xerophthalmia… renal dialysis 105
42. Phlyctenular conjunctivitis… BCG diagnostic test… Craniofacial dysostosis (Crouzon's syndrome)… Apert's syndrome… Carpenter syndrome… hypertelorism 108
43. Urinary tract infection (UTI)… Addison's disease 111
44. Urticaria… hypervitaminosis A… portal hypertension… gastrointestinal hemorrhage 114
45. Rheumatic heart disease… phenothiazine toxicity… typhoid vaccine 117
46. Down's syndrome… Stevens Johnson syndrome… pectus excavatum 119
47. Duchenne muscular dystrophy… DDT poisoning 122
48. Kerosene oil poisoning… dextrocardia… black tongue 125
49. Skin tuberculosis… scrofuloderma… rickets… nutritional marasmus 127

50. Diabetes mellitus… viral hepatitis… giardiasis 130
51. Chickenpox… poliomyelitis 132
52. Bronchial asthma 134
53. Ichthyosis… Refsum's syndrome 137
54. Enteric fever… MDRS and therapy 139
55. Leukemia… meningeal leukemia… chloroma… measles… black (hemorrhagic) measles 142
56. Diphtheria… ATT… CAN 145
57. Filariasis… chronic ITP… antioxidants 148
58. Coarctation of aorta… growing pains 150
59. Aortic stenosis 152
60. Acute epiglottitis… abnormal tallness… Marfan syndrome… hemocystinosis 154
61. Congenital pyloric stenosis 157
62. Collodion baby 161
63. Stevens Johnson syndrome 163
64. Hypoxic-ischemic encephalopathy (HIE) 165
65. Scalded skin syndrome (SSS) 168
66. Cranial encephalocele 169
67. Pyogenic meningitis hydrocephalus 172
68. Infant of the diabetic mother 173
69. Pericardial effusion paracentesis… cardiac temponade 175
70. Subarachnoid hemorrhage… leptomeningeal cyst… ascariasis… ascaris encephalopathy 177
71. Neonatal hypoglycemia… epicanthal fold as a normal variant 179
72. Delayed speech… failure to thrive… emotional deprivation… ascariasis… measles vaccine 180
73. Cow's milk allergy… D-xylose test… umbilical hernia… mongolion spots 183
74. Rheumatoid arthritis… passive protection against measles… geographical tongue 186
75. Indian childhood cirrhosis 189
76. Cushing's syndrome… pityriasis… Apert syndrome… paraphimosis 191
77. Thalassemia major… hepatitis B… vaccine 193
78. Transposition of great arteries… CCF… intertrigo… diaper rash… hypospadias 196

79. Mumps… periodic syndrome 198
80. Snakebite… congenital pulmonary stenosis 201
81. Malaria… cerebral malaria… BCG-adenitis 203
82. Phenylketonuria… chronic lead poisoning… loose motions in a neonate 206
83. Duchenne muscular dystrophy 208
84. Phenobarbital poisoning… Laurence-Moon-Biedl syndrome… arthrogryposis multiplex congenita 211
85. Rheumatic fever… rheumatic pericarditis… CCF… blue sclera 212
86. Marfan's syndrome… homocystinuria snakebite… DIC 215
87. Fallot's tetralogy… dehydration scoring… deficit therapy… HIV-positive mother and breastfeeding 218
88. Hurler's syndrome… ORS… dehydration scoring 221
89. Idiopathic thrombocytopenic purpura… amebiasis 223
90. Acute bronchiolitis… CCF… sternomastoid tumor 225
91. Autism… VSD… pertussis prophylaxis 228
92. Infective endocarditis… Fallot's tetralogy… hypercyanotic spells… dwarf tapeworm infestation 231
93. Rheumatic fever.. carditis 234
94. Miliary tuberculosis… BCG diagnostic test 236
95. Thalassemia major… desferrioxamine… Prader-Willi syndrome 239
96. Vitamin D deficiency rickets… costochondral beading 241
97. Pseudotumor cerebri… mannitol roseola infantum 242
98. Kwashiorkor… nutritional rehabilitation… various ferrous salts with elemental iron content 245
99. Idiopathic respiratory distress syndrome 246
100. Enuresis… desmopressin… Simian crease as a normal variant 249
101. Ventricular septal defect… infective endocarditis… Treacher Collins syndrome 251
102. Werdnig-Hoffmann disease… benign congenital hypotonia… empyema 253
103. Achondroplasia… acrodermatitis enteropathica… calcification in X-ray of skull… rectal bleeding 256
104. Down's syndrome… Hirschsprung's disease 258
105. Measles… pertussis 260

106. Cerebral palsy… gluten-induced enteropathy 262
107. Meningitis (tuberculous) 263
108. Generalized tuberculosis… middle-lobe consolidation… FNAC 266
109. Hodgkin's disease 269
110. Scurvy 271
111. Rheumatic chorea 273
112. Infantile tremor syndrome… threadworm infestation 276
113. Wilms' tumor… follicular hyperkeratosis… PEM grading 279
114. Kinky hair syndrome… cerebellar ataxia 282
115. Congenital hydrocephalus 284
116. Neonatal jaundice… Rh incompatibility 288
117. Scabies… cretinism 290
118. Neuroblastoma 293
119. Cystic fibrosis 295
120. Albinism… organic phosphate poisoning 298
121. Arthrogryposis multiplex congenita… staphylococcal pneumonia 300
122. Pierre Robin syndrome… oral thrush 302
123. Nutritional recovery syndrome… primary complex… amebiasis 304
124. Congenital hypertrophic pyloric stenosis… prickly heat 306
125. Malaria… Wilson's disease 309
126. Tropical eosinophilia 310
127. Galactosemia… hemorrhagic chickenpox 313
128. Neonatal septicemia… meningitis… assessment of gestational age 315
129. Reye's syndrome 317
130. Niemann-Pick disease… rotavirus diarrhea 319
131. Pulmonary agenesis… esophageal atresia… protection against hepatitis B 321
132. Fetal-alcohol syndrome… Vogt-Koyanagi-Harada syndrome 323
133. Kala-azar 326
134. McCune-Albright syndrome 327
135. Nonbilious vomiting (projectile)… hypochloremic acidosis… hypertrophic pyloric stenosis 330

136. Congenital hydrocephalus… Dandy-Walker malformation 332
137. CNS tuberculosis… tuberculoma… tuberculous abscess… brain herniation syndromes 333
138. Craniopharyngioma 336
139. Brain abscess 339
140. Meduloblastoma 340
141. Disseminated cysticercosis 343
142. Helicobacter pylori infection 344
143. Sturge-Weber syndrome 347
144. Pott's disease… free radicals… methionine as an antioxidant in fever 349
145. Extremely low birth weight infant… cold stress… meconium aspiration/leaks… feeding problems… supplements… protection of HbsAg positive mother's neonate 351
146. Chronic myeloid leukemia 354
147. Dengue hemorrhagic fever 355
148. Xerophthalmia… iron-deficiency anemia… hepatitis A and B vaccination 357
149. Infant of the diabetic mother 360
150. Pierre Robin syndrome 361
151. Intramedullary cervical glioma (astrocytoma/ependymoma) 363
152. Arnold-Chiari malformation syringomyelia 365
153. Diffuse cerebral calcification… Fahr syndrome… dystonia 367
154. Abnormal tallness… Marfan syndrome 370
155. Measles encephalitis 372
156. Lymphatic filariasis 374
157. Long QT syndrome 375
158. Glanzmann's thrombasthenia 378
159. Acute flaccid paralysis (AFP)… Guillain-Barre syndrome(GBS) 379
160. Leptospirosis 381
161. Chikungunya fever 383
162. Pleural effusion 386
163. Galactosemia… early-onset cataract 388
164. Tetany… hypoparathyroidism 390

165. Neonatal cholestasis syndrome (NCS)… extrahepatic biliary atresia… choledochal cyst 392
166. Respiratory distress syndrome (RDS) 393
167. Hemorrhagic disease of the newborn 395
168. Autism 397
169. Obesity… Goodpasture's syndrome 399
170. HIV… Pneumocystis carinii pneumonia 401
171. Wilson's disease 403
172. Neonatal seizures 405
173. Short stature 407
174. Patent ductus arteriosus… CCF 409
175. Infective endocarditis 412
176. Sickle-cell disease… bronchopneumonia 414
177. Reactive arthritis 416
178. Kala-azar 418
179. Acute seizures 420
180. Achondroplasia 423
181. Inflammatory bowel disease (IBD)… ulcerative colitis .. 424
182. Gastroesophageal reflux disease 426
183. Acute exacerbation of asthma 428
184. Acute viral hepatitis with encephalopathy 430
185. Ambiguous genitalia… congenital adrenal hyperplasia (CAH) 432
186. Intracranial space-occupying lesion (ICSOL)… craniopharyngioma (astrocytoma) 434
187. Precocious puberty… McCune-Albright syndrome… cafe-au-lait spots 437
188. Munchausen syndrome by proxy 438
189. Acute leukemia 441
190. Celiac disease 444
191. Ataxia telangiectasia 447
192. Pituitary dwarfism 448
193. PANDAS 451
194. Status epilepticus 453
195. Acute abdomen… testicular torsion 455
196. Bartter's syndrome 457
197. Phenylketonuria (PKU) 459
198. Kawasaki disease 462

199. Tuberous sclerosis 465
200. Pyloric stenosis 466
201. Diabetic ketoacidosis 469
202. Infective endocarditis 473
203. Antibiotic-associated diarrhea (AAD)… pseudomembranous colitis 477
Appendix 1 ..... *479*
Appendix 2 ..... *480*
Appendix 3 ..... *509*
Recommended Reading *539*
Index *541*

Case 80

A stocky boy, Gaurav, aged 6 years, was bitten by a snake. He was fully conscious and showed no evidence of neurological or hematological involvement. Bleeding and clotting times were within normal limits. Locally, however, there was a tender inflammatory swelling about the fang marks at the right ankle.

The house-physician, who was rather very fresh, immediately gave a local incision and sucked the poison from the site of the bite. At least that is what he intended to do. He also gave the child tetanus toxoid and put him on an oral tetracycline to combat local infection.

Besides, he started administering him 60 ml of AVS through an intravenous infusion. Unfortunately, within minutes of starting the drip, the boy suffered from severe anaphylactic reaction which could be controlled with great difficulty.

The senior consultant who was requested to see the case soon after the anaphylactic reaction, was furious that there had been negligence in managing the case. To quote him "we could have lost this child just because the attending doctor had been overtreating him".

On detailed examination of the patient the senior consultant was struck by the unusual facial configuration (with full checks and square outline) of the boy. Precordial examination revealed a diffuse apical impulse and pulsation in the left parasternal area. There was no cardiomegaly. A systolic thrill was palpable over the left upper parasternal area. P_2 was single, soft and late. A long loud harsh systolic murmur was heard best at the second and third left interspace. It was conducted toward the left clavicle and the posterior chest wall.

1. **What blunder had the house-physician made?**
2. **What in your opinion, was the diagnosis of the incidentally-detected cardiac findings?**
3. **What manifestations do you expect if the patient is an infant?**

JAYPEE BROTHERS

4. **Describe the X-ray and ECG findings.**
5. **Mention the features that may suggest severe cardiac disease in such a patient.**

Key to Case 80

1. Once it was clear that there were no bleeding or neurologic complication as also BT and CT were normal, there was no justification for giving AVS. Moreover, AVS should never be given without sensitivity test. What the house-physician did was indeed an invitation to a problem which did not deserve to be taken risk of.
   Also, there was no need to give incision and drainage at the local site.
2. Congenital pulmonary stenosis.
3. Breathlessness, cyanosis, and even CCF.
4. X-ray chest shows a degree of oligemia depending on severity of stenosis. Heart is not enlarged but right ventricular hypertrophy is there. In valvular stenosis, there will be a localized convexity representing the poststenotic dilatation of the main pulmonary artery. In infundibular stenosis, the pulmonary segment of the left border is concave. Vigorous pulsations are observed in the region of the main pulmonary artery and its branches on screening in only valvular stenosis.
   ECG shows incomplete bundle branch block, RVH and tall pointed P waves of right atrial hypertrophy in lead II.
5. Severe pulmonary stenosis is indicated by the following:
   - Presence of symptoms and such findings as cyanosis, cardiomegaly, and oligemic lungs.
   - Close proximity of pulmonary ejection click to the first sound.
   - Widely split P_2.
   - Long murmur.
   - P-pulmonale in ECG.

JAYPEE BROTHERS

Case 81

A 9-month-old infant suddenly had high fever with chills and rigors. It responded to baby aspirin tablet only to return again after some hours. This went on and on for 3 days. During these 3 days the child lost his appetite and became very irritable and pale.

The past history revealed that at the age of 5 months he had BCG vaccination. This was followed by large swelling in the left axilla. The swelling persisted and after about two months burst. A pediatrician was consulted. He got an X-ray chest done and then started the child on INH for 6 months. The axillary swelling slowly disappeared only a month back. The child was, however, continuing to take INH.

The child was third among the 4 siblings one of whom was a known case of Down's syndrome.

His milestones were normally attained and feeding history revealed nothing commentable.

On physical examination, it was found that the child was well-nourished and well-built. He was running a temperature of 38°C. Liver was palpable by about 2 cm. Spleen was palpable by more than 5 cm. Moderate pallor was present.

Investigations: Hb 8.2%, microcytic-hypochromic erythropoiesis. MP seen. TLC and DLC within normal limits. Urine NAD. Stools NAD.

As the child was being investigated, he developed generalized convulsions. After the convulsions were controlled, he was found to be semiconscious with positive meningeal signs. Immediate LP showed raised pressure but biochemistry and microscopy were essentially normal. Fundus showed no abnormality.

1. **What was the most likely diagnosis of child's high fever and later convulsions and meningeal signs? Describe the treatment.**
2. **What was the cause of child's persistent axillary swelling after BCG? Discuss the treatment.**

JAYPEE BROTHERS

3. Name the situations in which only INH prophylaxis may be recommended.

Key to Case 81

1. Malaria which was suggested by the clinical picture and corroborated by the demonstration of malarial parasite in the blood film.

   Since CSF picture was normal, except for raised pressure, and yet the child had convulsions and meningeal signs and positive malarial parasite in the peripheral blood smear, it is quite reasonable to think that this may well be a case of cerebral malaria.

   Quinine infusion (10mg/kg of quinine dissolved in 200 ml of saline), given slowly in 2-4 hours and then repeated 12 hourly until 6-8 doses are administered, is better than chloroquine (IV).

   The best agent for cerebral malaria currently is artemethor (Paluther). Total dose is 9.6 mg/kg(IM) - 3.2 mg/kg on first day and 1.6 mg/kg/day on subsequent 4 days. Alternative schedule is 3.2 mg/kg/day on 3 successive days.

   No primaquine is to be given to a child under 1 year.
2. BCGosis or simply BCG adenitis.

   Every child with this complication of BCG vaccination should have at least an X-ray chest. If it shows any evidence of tuberculosis, a full antituberculous therapy is justified. If it turns out to be normal, the child should receive only INH, 5-10 mg/kg/day, for 6 to 12 months.

   Some workers believe that, left as such, the adenitis subsides in due course of time. Many surgeons, however, recommend excision of the glandular swelling.
3. • Persistent lymphadenitis, with or without suppuration and abscess formation, following BCG vaccination, provided that there is no other evidence of active disease.
   • Positive Mantoux/BCG test in a child under 5 years of age and who had not received BCG in the past.

JAYPEE BROTHERS

- A recent conversion of Mantoux test from negative to positive, provided that BCG had not been administered a few months back.
- Exposure of unprotected child to an open case of tuberculosis.

JAYPEE BROTHERS

Case 82

A 3-year-old child was referred to a pediatric center by a block medical officer for evaluation of mental retardation and hyperactive personality of the child.

When the parents were interrogated, they said that child had gross delay in achieving his developmental milestones. At 3 years he could just walk and speak a few words. He did not have any bowel or bladder control.

There was a history of recurrent generalized convulsions for which he had already been receiving regularly phenobarbital and diphenyl hydantoin sodium ever since the age of 6 months with not so encouraging results. The child often vomited, had excessive sweating and suffered from chronic eczema. He was also suffering from pica.

The birth history was noncontributory.

A younger sibling, aged 1 month, was said to be suffering from loose motion, 10 to 15 times per day, ever since birth. She was on mother's milk only. Various medications had done her no good, except that her general condition was not adversely affected. Parents were, however, quite concerned.

Physical examination revealed a blond child with strikingly blue eyes. His weight was 12.5 kg and height 85.5 cm. He resisted approach from the examining doctor. Even on a chilly day he was sweating profusely which gave a peculiar odor.

His assessed mental age turned out to be just 1¼ year.

The resident was unable to make the diagnosis and passed on the case to his Registrar. The Registrar had no difficulty in reaching the correct diagnosis. In addition, he noticed that the child had moderate anemia and a peculiar line along his gums. The previous record showed that the child had received all sorts of hematinics for anemia which, however, showed no response.

1. **What was the major diagnosis which the resident failed to think of?**
2. **How does one confirm this diagnosis?**

JAYPEE BROTHERS

3. **Mention the basic principle of treatment of this disorder.**
4. **What was the cause of resistant anemia?**
5. **How does one confirm the diagnosis?**
6. **Comment on parents' anxiety about younger sibling's motions.**

Key to Case 82

1. Phenylketonuria
   This was a classical case of this heredofamilial disorder. The resident was, perhaps not familiar with the clinical profile of this condition. That is why it did not cross his mind.
2. The diagnosis is confirmed by demonstrating serum phenylalanine level exceeding 1.5 mg% and by ferric chloride test or Phenistix paper strips showing excess of phenylalanine and its metabolites in urine.
3. A low phenylalanine diet must begin before the baby is 2 weeks old, maintaining the serum phenylalanine at about 8 mg% if mental retardation is to be prevented.
4. Resistant anemia in this case appeared to be due to chronic lead poisoning. The fact that the child suffered from pica and showed a peculiar line along the surface of the gums provide an excellent lead to this diagnosis.
5. Urine lead level of more than 80 mcg/d/24 hours is diagnostic of lead poisoning.

   Blood lead level in symptomatic cases usually exceeds 80 mcg/dL.

   Urinary coproporphyrins or red cell aminolevulinic acid dehydrose levels are also good screening test.

   Peripheral blood film shows normocytic hypochromic anemia with reticulocytosis and basophilic stippling of RBC.

   X-rays may reveal opaque flakes in GIT. Screening of the bony skeleton may show a lead line at the metaphyseal areas.

   CSF pressure, proteins, and cells are moderately high.

JAYPEE BROTHERS

6. Parents' anxiety about younger sibling's motions was not well founded. It is perfectly normal for a breastfed infant to pass loose and frequent motions, up to 24 per day during the first 6 weeks or so. The motions may well be explosive, of bright green color and contain yellow soap plaques and mucus. No treatment is required.

JAYPEE BROTHERS

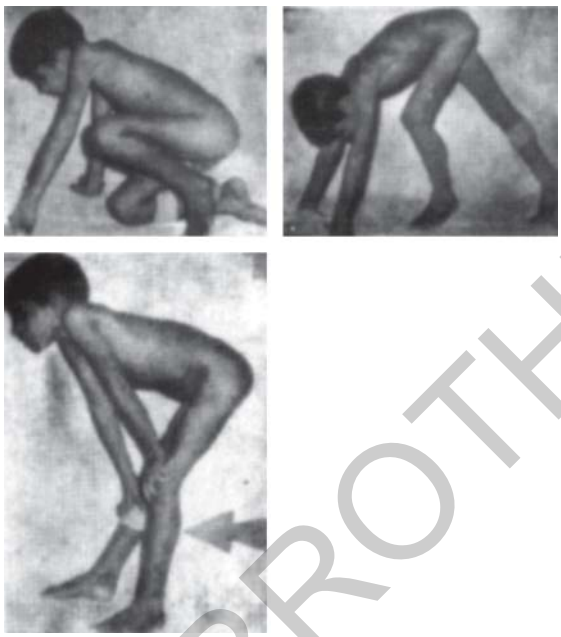

Case 83

Watch the calf muscle girth in contrast to the musculature of rest of the body and the characteristic manner in which the child is arising from the floor.

1. **What is your diagnosis?**
2. **Describe the salient features of the disease briefly.**
3. **Mention the salient differences between this disease and polymyositis.**

Key to Case 83

1. Duchenne muscular dystrophy, also called pseudohypertophic muscular dystrophy (PHMD).
2. The disease is the most common form of progressive muscular dystrophies. It is transmitted in a X-linked

JAYPEE BROTHERS

manner and manifests before the fifth birthday. Death usually occurs in the second decade.

The earliest clinical manifestation may be difficult in standing or walking, climbing stairs, arising from the floor or in other activities involving the participation of the muscles of the pelvis. A wadding gait may be noticed. Patient may find it difficult to comb his hair or lift his hands above the head.

A classical case shows a characteristic manner of arising from the bed or the floor to an upright position as is demonstrated in the pictures. This succession of movements is aptly described as "climbing up one's own thighs" (Gower's sign). Lordosis and forwardly-thrust tummy are outstanding when the child stands upright. Pseudohypertrophy, especially of the calf muscles, is striking. Tendon reflexes are sluggish or absent. Ankle jek is an exception. Cardiac enlargement, persistent tachycardia, and cardiac failure occur in 50 to 80% of the cases sometime during the course of the disease. About 33% have mental deficiency.

No effective treatment is available.

3. First, unlike polymyositis, PHMD is a familial disease. Secondly, its onset is slow and the course progressive Thirdly, distal muscle involvement is dominant, Fourthly, there is a generalized muscle atrophy though calf muscles, may be hypertrophied. In polymyositis, it is more of muscle weakness than atrophy. Moreover, hypertrophy is rare. Fifthly, steroid therapy makes no difference as far as the course of PHMD is concerned.

JAYPEE BROTHERS

Case 84

A toddler aged 2 years was said to have swallowed several tablets of phenobarbital at a time following which he became extremely drowsy. When aroused, he showed much restlessness. He had not passed urine since then. He had vomiting once.

It was revealed by the father that the child was a known case of Jacksonian seizures. He was put on phenobarbital, after due investigations in a teaching hospital, exactly a year back. They were told that they would have to continue the treatment for at least four years since the last attack of seizures. There had not been any recurrence of seizures since this treatment was initiated.

His elder brother, aged 3 years, was a known case of arthrogryposis multiplex congenita.

Physical examination revealed the child was in coma. His breathing was quite noisy. There was evidence of peripheral circulatory failure. Deep cyanosis was present.

The child's weight was 11.6 kg and height 84 cm. Head appeared to be large and box-like with a circumference of 46 cm. Anterior fontanel admitted the tip of a finger. Wrists were widened. Legs showed bowing.

A detailed body survey showed that the child had polydactyly of right hand and left foot. There was widespread scaling of the skin of dorsal surface of limbs and abdomen in the shape of geometrical figures separated by fissures. The parents said the skin problem was worse in winter. The lesions were first noticed when the child was just a newborn.

1. **Describe the main features of management in this child with phenobarbital poisoning.**
2. **Could there be any relationship between the long-term phenobarbital therapy that the child was receiving and the development of signs of rickets?**
3. **What is your diagnosis of the skin lesions?**
4. **Name the well-known syndrome in which polydactyly occurs in association with obesity. What are the other features of this syndrome?**

JAYPEE BROTHERS

5. What are the salient features of the diseases which afflicted the patient's elder brother?

Key to Case 84

1. This child needs an immediate gastric levage and oxygen inhalation, intravenous fluids and, if possible, peritoneal dialysis.

   Respiratory stimulants like bemegride are no longer recommended in the management of phenobarbital poisoning.
2. Long-term phenobarbital is known to cause vitamin D deficiency rickets. That is why many authorities feel it is advisable to give such children a periodical dose of vitamin D as also supplement their intake with extra calcium.
3. The skin lesions are typical of ichthyosis vulgaris, a congenital disorder in which there is hyperkeratinization (excessive cornification) of skin which becomes dry, thick, and scaly. The lesions are most prominent over the arms and legs and become worse during winter months.

   There is no specific treatment. The recommendations include lubrication of skin with mineral oil and/or topical vitamin A and large doses of vitamin A in winter.
4. Laurence-Moon-Biedl syndrome.

Short stature, hypogenitalism, and retinitis pigmentosa are its other cardinal features.

5. Arthrogryposis multiplex congenital is characterized by fixed deformities (usually in flexion) of one or more joints. The associated findings may include wasted hypotonic muscles, absent reflexes, thickened skin with loss of normal creases, fractures, dislocations, talipes, arachnodactyly, craniostenosis, scoliosis, cleft palate, genitourinary malformations and congenital heart disease. Mentality is usually normal. Treatment is aimed at preventing increasing contractures and handicap as the child grows. The major components of management are passive stretching as early as possible, corrections, physiotherapy, and occupational therapy.

JAYPEE BROTHERS

Instructive Case Studies in PEDIATRICS

Salient Features

- A fully revised, expanded, and updated text
- Written in straight-forward, clear, lucid and easy-to-grasp style
- Presents as many as 200 case studies to assist in refining skills in handling clinical problems and in applying remedial measures for overcoming the deficiencies methodically, efficiently and effectively
- Provides more than one case for major complaints to sharpen skills in differential diagnosis and management
- Each case presentation follows a list of questions that probe facts warranting special attention
- Covers the whole gamut of clinical pediatrics
- Serves as an ideal study tool for undergraduate and postgraduate students and teachers of pediatrics, interns, house-physicians, residents, junior pediatricians and practising physicians dealing with children and adolescents.

Suraj Gupte



A proud alumnus of the prestigious Postgraduate Institute of Medical Education and Research, Chandigarh, India, Dr Suraj Gupte is currently Professor and Head, Postgraduate Department of Pediatrics, Narayana Medical College and Narayana General and Superspeciality Hospitals, Nellore, Andhra Pradesh, India.

An occupant of a pride of place as a distinguished educationist, researcher, innovator and author at national and international levels, he has represented India at several international conferences, workshops, symposia, seminars, etc. worldwide as Guest Speaker, Chairperson-Rapporteur, Visiting Fellow/Professor, etc.

He is a winner of several national and international fellowships e.g. Indian Academy of Pediatrics, Scandinavian Academy of Medical Sciences, Royal Society of Tropical Medicine and Hygiene, etc.) and awards ("Wodehouse Award", "Young Achiever Award", "Lifetime Achievement Award", "International Peace Prize", "Man of the Year", "Medical Author of the Decade", "Hall of Fame", etc.).

He has been on several academic task forces/working groups.

He has been on editorial boards of several periodicals, both national and international.

He has published/presented at national and international conferences over 165 papers, authored/edited several books, including the ongoing international series, "Recent Advances in Pediatrics" which is now heading for its 20th annual volume and 22nd and 23rd special volumes and "The Short Textbook of Pediatrics" which is heading for its 12th edition.

In the Indian Academy of Pediatrics and its Subspeciality Chapters, Dr Gupte has held several important positions, including Founder and Vice-President of the Nutrition Chapter and Founder and Secretary of the Child Neurology Chapter. He was Advisor, 8th International Congress of Tropical Pediatrics and Executive Member, 8th Asian Congress of Pediatrics.

He is an undergraduate and postgraduate examiner to a multitude of universities/apex institutes, including National Board of Examinations (DNB), IGNOU (New Delhi), AIIMS (New Delhi), PGIMER (Chandigarh) and SKIMS (Srinagar).

Dr Suraj Gupte figures in most of the national and international "Who's Who" volumes.

Available at all medical book stores
or buy directly from Jaypee Brothers through online shopping at www.jaypeebrothers.com

or call + 91-11-32558559

JAYPEE BROTHERS
Medical Publishers (P) Ltd.
www.jaypeebrothers.com

ISBN 978-81-8448-997-2