rgery books, visit our website www.ejaypee.com, for detailed information on oncology surgery books, visit our website www.ejaypee.com, for detailed information on oncology surgery books

PRINCIPLES OF CANCER SURGERY

EVIDENCE-BASED ALGORITHMS FOR SURGICAL DECISION MAKING

VOLUME 1

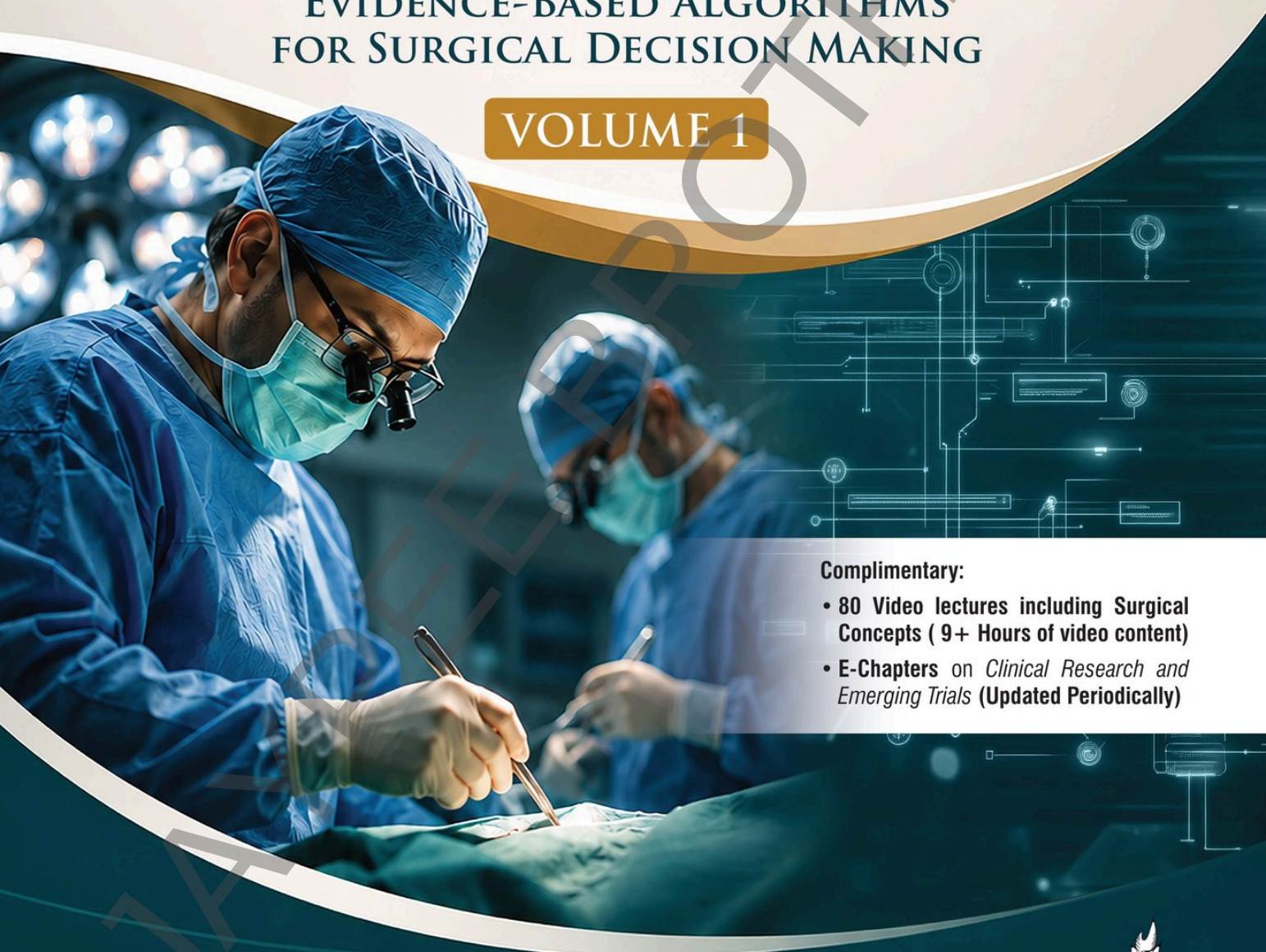

Complimentary:

- **80 Video lectures including Surgical Concepts (9+ Hours of video content)**
- **E-Chapters** on *Clinical Research and Emerging Trials* **(Updated Periodically)**

Shouptik Basu

Forewords
Chia Shulyn Claramae
Rishikesh Parmeshwar

JAYPEE

JAYPEE BROTHERS

Contents

VOLUME 1

SECTION 1: Head and Neck Oncology

Chapter 1: Risk Factors, Malignant Lesions and Prevention of Oral Cavity Cancers 3

Chapter 2: Principles of Management of Oral Cavity Cancers 21

Chapter 3: Management of the Neck in Oral Cavity Cancers 42

Chapter 4: Surgical Management of Oral Cavity Cancers: Subsite-based Approach 62

Chapter 5: Laryngeal and Hypopharyngeal Cancers 99

Chapter 6: Salivary Gland Neoplasms 120

SECTION 2: Breast Oncology

Chapter 7: Breast Cancer: Risk, Prevention, and Diagnostics 141

Chapter 8: Breast Carcinoma In Situ 168

Chapter 9: Early Breast Cancer: Oncoplastic Breast Surgery 174

Chapter 10: Locally Advanced Breast Carcinoma (LABC): Downstaging with Systemic Therapy 199

Chapter 11: Management of the Axilla: A Paradigm Shift of Surgical De-escalation 216

Chapter 12: Mastectomy and Reconstruction of Postmastectomy Defects 232

Chapter 13: Adjuvant Therapies in Breast Cancer 246

Chapter 14: Special Clinical Situations and Recent Updates in Breast Cancer 261

Chapter 15: Phyllodes Tumor of the Breast 276

SECTION 3: Thoracic Oncology

Chapter 16: Non-small Cell Carcinoma of the Lung 289

Chapter 17: Principles of Lung Cancer Surgery 315

Chapter 18: Small Cell Lung Cancer 347

Chapter 19: Chest-wall Tumors and Reconstruction of Chest Wall Defects 353

Chapter 20: Thymic and Mediastinal Neoplasms 363

Chapter 21: Tracheal Neoplasm and Carcinoids 381

Chapter 22: Malignant Pleural Mesothelioma 393

Chapter 23: Superior Vena Cava Obstruction Syndrome 401

Chapter 24: Metastatic Cancer to the Lung and Malignant Pleural Effusion 409

SECTION 4: Gastrointestinal Oncology

Chapter 25: Carcinoma Esophagus 419

Chapter 26: Carcinoma Stomach 450

Chapter 27: Gastroesophageal (GE) Junction 480

Chapter 28: Gastrointestinal Stromal Tumors (GISTs): A Paradigm Shift to Contemporary Management 487

Chapter 29: Small Bowel Malignancies 494

Chapter 30: Molecular Pathogenesis of Hereditary Colorectal Cancer and Polyposis Syndromes 505

Chapter 31: Carcinoma Colon 524

Chapter 32: Carcinoma Rectum: Evolution of the Paradigm Shift in the Management 554

JAYPEE BROTHERS

Chapter 33: Appendiceal Neoplasms: Contemporary Principles of Surgical Management 587
Chapter 34: Anal Canal Cancer 597

SECTION 5: Hepato Pancreato Biliary Oncology

Chapter 35: Hepatocellular Carcinoma 609
Chapter 36: Gallbladder Cancers: A Paradigm Shift to Multimodality Therapy 635
Chapter 37: Cholangiocarcinoma 644
Chapter 38: Cystic Neoplasms of Pancreas 659
Chapter 39: Pancreatic Neuroendocrine Tumors 671
Chapter 40: Pancreatic Ductal Adenocarinoma 682

VOLUME 2

SECTION 6: Uro-Oncology

Chapter 41: Renal Cell Carcinoma and Upper Tract Urothelial Cancer 725
Chapter 42: Bladder Cancer 758
Chapter 43: Prostate Cancer 793
Chapter 44: Penile Cancer 818
Chapter 45: Testicular and Paratesticular Malignancies 832

SECTION 7: Endocrine Oncology

Chapter 46: Current Perspectives in Differentiated and Anaplastic Thyroid Carcinoma 861
Chapter 47: Sporadic Medullary Thyroid Carcinoma 904
Chapter 48: Multiple Endocrine Neoplasia (MEN) Syndromes 913
Chapter 49: Parathyroid Tumors 927
Chapter 50: Adrenal Tumors 941

SECTION 8: Gynecological Oncology

Chapter 51: Premalignant Lesions of the Cervix 961
Chapter 52: Cervical Cancer 976
Chapter 53: Endometrial Carcinoma: Current Principles of Management 1003
Chapter 54: Uterine Sarcomas 1026
Chapter 55: Epithelial Ovarian Cancer 1035
Chapter 56: Nonepithelial Ovarian Cancer 1068
Chapter 57: Vulval Malignancies 1080
Chapter 58: Carcinoma Vagina 1094
Chapter 59: Gestational Trophoblastic Diseases 1100

SECTION 9: Skin Malignancies

Chapter 60: Melanoma 1109
Chapter 61: Basal Cell Carcinoma and Miscellaneous Skin Tumors 1128
Chapter 62: Squamous Cell Carcinoma 1139

SECTION 10: Musculoskeletal Oncology

Chapter 63: Soft Tissue Sarcoma: Evidence-based Contemporary Management 1155
Chapter 64: Retroperitoneal Sarcoma 1185
Chapter 65: Overview of Malignant Bone Tumors 1203
Chapter 66: Limb Salvage in Musculoskeletal Oncology 1232

SECTION 11: Peritoneal Surface Oncology

Chapter 67: Diagnosis and Evaluation of Peritoneal Surface Oncology 1255

JAYPEE BROTHERS

Chapter 68: Cytoreductive Surgery: A Practical Approach 1270
Chapter 69: Current Strategies in Intraperitoneal Chemotherapy 1289
Chapter 70: Contemporary Evidence-based Approaches to Peritoneal Metastases 1311

SECTION 12: Miscellaneous

Chapter 71: Carcinoma Unkonwn Primary 1337
Chapter 72: Vascular Access: Totally Implantable Venous Access Device (TIVAD) 1351

SECTION 13: Recent Advances in Surgical Oncology

Chapter 73: Practical Overview of Robotic Surgical Systems 1361
Chapter 74: Fluorescence-guided Surgery (Role of Indocyanine Green in Surgical Oncology) 1375
Chapter 75: Isolated Limb Perfusion (Including Recent Guidelines) 1382

SECTION 14: Molecular Biology and Cancer Therapeutics

Chapter 76: Hallmarks of Cancer: Translating Tumor Biology into Clinical Practice 1391
Chapter 77: Essentials of Radiation Oncology for Cancer Surgeons 1404
Chapter 78: Contemporary Medical Oncology for Cancer Surgeons 1419
Chapter 79: Preventive Oncology for Cancer Surgeons 1448
Chapter 80: Palliative Care and Hospice 1460
Index *1471*

JAYPEE BROTHERS

CHAPTER 9

Early Breast Cancer: Oncoplastic Breast Surgery

INTRODUCTION

Early breast cancer is a potentially curable disease in which treatment planning requires a multidisciplinary and individualized approach. Following clinical diagnosis, appropriate breast and axillary imaging and histopathological confirmation, these patients are staged to rule out metastatic disease. Most patients are with cT1-2, N0-1, M0 disease and do not require extensive staging for treatment planning.

Breast-conserving surgery (BCS) with or without oncoplastic reconstruction has become the preferred treatment option for patients who are eligible and desire breast preservation, offering oncological safety comparable to mastectomy with superior cosmetic and psychological outcomes. Patients with larger tumors or an unfavorable breast-to-tumor ratio who are initially unsuitable for BCS may become candidates following neoadjuvant chemotherapy (NACT), thereby increasing rates of breast preservation. However, patients with multicentric disease, persistently large tumors, inadequate breast volume, contraindications to radiotherapy, or those unwilling for BCS may require mastectomy with or without whole-breast reconstruction.



Fig. 1: Breast lump in the right breast with adequate ptosis, ideal for oncoplastic breast surgery.

Advances in oncoplastic breast surgery, neoadjuvant systemic therapy, and reconstructive techniques have significantly expanded the indications for breast conservation while maintaining oncological principles and improving esthetic outcomes. Adjuvant systemic therapy, radiotherapy, endocrine therapy, and targeted therapy are subsequently tailored according to tumor biology and stage to optimize local control and survival outcomes. **(Fig. 1, Box 1, Algorithm 1, and Video 9.1)**.

BOX 1: Need for radiation after breast conservation.

- If the patient is eligible for breast-conserving surgery (BCS), oncoplastic techniques should be considered to optimize cosmetic outcomes.
- BCS is a combined modality treatment that includes surgery followed by radiotherapy; lumpectomy alone is inadequate.
- If the patient is not initially eligible for BCS but desires breast conservation, neoadjuvant chemotherapy (NACT) should be administered; with a good response, oncoplastic BCS can be performed.
- If the patient is not eligible for BCS or declines BCS/radiotherapy, mastectomy with reconstruction is offered, along with postmastectomy radiotherapy (PMRT) when indicated.

HISTORY OF ONCOPLASTIC BREAST SURGERY

Modern oncoplastic breast surgery has evolved significantly with contributions from key pioneers in the field. Werner Audretsch is regarded as the father of modern oncoplasty, having laid the foundation for integrating oncological resection with plastic surgical principles. Subsequently, Krishna B. Clough proposed a widely accepted classification system for oncoplastic techniques, which aids in structured surgical planning and selection of appropriate reconstructive approaches.

JAYPEE BROTHERS

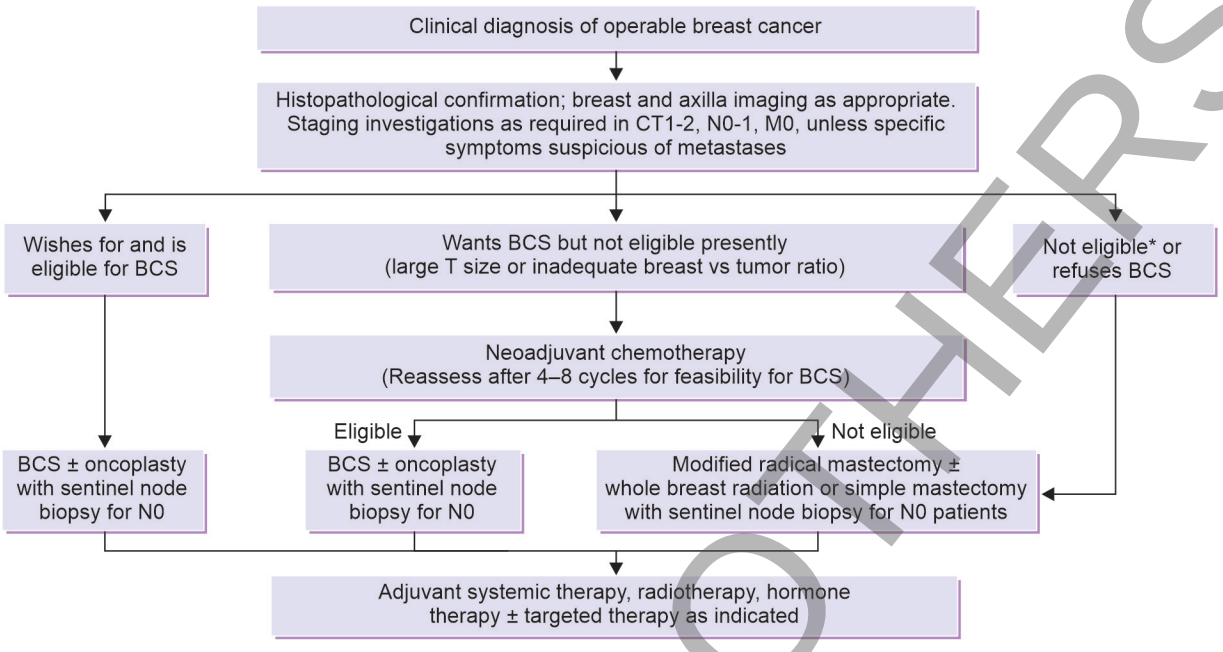

Algorithm 1: Management of operable breast cancer.
**Not eligible:* Large tumor size, multicentric disease not amenable to BCS, inadequate breast size, pregnancy (relative), connective tissue disorders (relative), etc.
(BCS: breast-conserving surgery)

Landmark Trials Comparing Breast Conservation to Mastectomy

Landmark randomized trials have established the principles of modern breast cancer management. The NSABP B-04 trial demonstrated no survival advantage of radical mastectomy over less extensive surgery, while NSABP B-06 confirmed that breast-conserving therapy (BCT; lumpectomy with radiotherapy) provides survival outcomes equivalent to mastectomy. In DCIS, NSABP B-17 and B-24 showed that radiotherapy and tamoxifen further reduce ipsilateral recurrence without affecting overall survival. The EBCTCG meta-analysis reinforced the role of radiotherapy after BCS by significantly lowering recurrence and modestly improving breast cancer–specific mortality. This is summarized in **Table 1**.

Is Breast-conserving Surgery Equivalent to Modified Radical Mastectomy?

Multiple landmark trials have consistently demonstrated the equivalence of BCT and mastectomy in early breast cancer. The NSABP B-06 trial showed similar survival across total mastectomy and lumpectomy arms, with radiotherapy significantly reducing ipsilateral breast tumor recurrence (IBTR). The Milan Cancer Institute trial reported comparable long-term overall survival, though slightly higher IBTR with BCS. Studies from the National Cancer Institute (NCI) and EORTC-10801 also confirmed similar overall survival between mastectomy and BCS, despite variations in disease-free survival and local recurrence rates. Data from Institute Gustave Roussy (IGR) and the Danish Breast Cancer Cooperative Group (DBCG) further reinforced that, when combined with appropriate radiotherapy, BCS achieves outcomes comparable to mastectomy in terms of survival and recurrence, establishing BCT as a standard of care in early breast cancer. This is summarized in **Table 2**.

Recurrence in Breast Cancer after Lumpectomy

Recurrence occurring within the previously treated breast region following lumpectomy and radiotherapy is termed a true recurrence, indicating tumor regrowth at the original site. In contrast, areas at the periphery of the radiation field, where the radiation dose gradually diminishes—referred to as the penumbra—may receive suboptimal treatment, leading to a "marginal miss," and thereby increasing the risk of recurrence in these inadequately irradiated zones.

JAYPEE BROTHERS

TABLE 1: Landmark trials comparing breast conservation to mastectomy.

Trial	*Population*	*Arms compared*	*Key results*
NSABP B-04 (1971–1974)	Clinically node-negative and node-positive	• Radical mastectomy • Total mastectomy ± RT • Mastectomy + PMRT	• No difference in DFS, RFS, distant DFS; or OS • Radical mastectomy gave no survival advantage
NSABP B-06 (1976–1984)	Stage I/II, tumor <4 cm	• Total mastectomy • Lumpectomy • Lumpectomy + WBRT	• OS, DFS, and distant DFS similar. RT after lumpectomy ↓ local recurrence • Established BCT as standard
NSABP B-17 (1985–1990) for DCIS	DCIS, *N* = 818	• Lumpectomy • Lumpectomy + RT	OS similar (94–95%). RT ↓ ipsilateral invasive and noninvasive recurrence
NSABP B-24 (1991–1994) for DCIS	DCIS, *N* = 1799	• Lumpectomy + RT + Placebo • Lumpectomy + RT + Tamoxifen	Addition of tamoxifen ↓ ipsilateral recurrence further
EBCTCG meta-analysis (2011)	Pooled 17 RCTs, >10,000 women	RT vs. no RT after BCS	RT ↓ recurrence (35% → 19%) and modestly ↓ breast cancer death (15-year average relapse ≈ 3.8%)

(BCS: breast-conserving surgery; BCT: breast-conserving therapy; DCIS: ductal carcinoma in situ; DFS: disease-free survival; N: number of patients (sample size); OS: overall survival; PMRT: postmastectomy radiotherapy; RCTs: randomized controlled trials; RFS: relapse-free survival; RT: radiotherapy; WBRT: whole-breast radiotherapy)

TABLE 2: Landmark trials confirming the status of breast conservation.

Trial/institute	*Eligibility/tumor size*	*Arms compared*	*Results*
NSABP-B06	T1–T2, ≤4 cm	• Total mastectomy • Lumpectomy alone • Lumpectomy + WBRT	Survival same across arms. IBTR: Lumpectomy alone ↑, lumpectomy + WBRT ↓
Milan Cancer Institute	≤2 cm	• RM • BCS + WBRT + AND	*20-year F/U:* OS same. IBTR: RM = 2.3%, BCS = 8.8%
National Cancer Institute (NCI)	T1, T2 ≤5 cm	• MRM • Lumpectomy + AND + WBRT	8-year OS: MRM 75%, BCS 77%. DFS: MRM 73%, BCS 57%
Institute Gustave Roussy (IGR)	≤2 cm	• MRM • Lumpectomy + AND ± RT (RNI vs. no RNI)	*After 15 years:* LR: MRM 14%, BCS 9% DM: MRM 20%, BCS 16%
Danish Breast Cancer Cooperative Group (DBCG)	Early breast cancer	• BCS + AND + RT • Mastectomy + AND + RT	10-year recurrence-free survival similar
EORTC-10801	≤5 cm	• MRM • Lumpectomy + AND + RT	OS similar. Local recurrence: MRM 12%, BCS 10%

(AND: axillary node dissection; BCS: breast-conserving surgery; DFS: disease-free survival; DM: distant metastasis; F/U: follow-up; IBTR: ipsilateral breast tumor recurrence; LR: local recurrence; MRM: modified radical mastectomy; OS: overall survival; RM: radical mastectomy; RNI: regional nodal irradiation; RT: radiotherapy; T1: tumor stage 1; T2: tumor stage 2; WBRT: whole-breast radiotherapy)

BASIS OF ONCOPLASTY: UNDERSTAND THE BRASSIERE (VIDEO 9.2)

The basis of oncoplastic surgery includes an understanding of brassiere sizing, which helps in planning breast reshaping and achieving symmetry. Bra size is determined by the difference between the bust (maximum breast circumference) and the underbust (chest circumference beneath the breast). This difference corresponds to cup size: a 1-inch difference is A, 2 inches is B, 3 inches is C, and 4 inches is D. For example, if the underbust measurement is 32 inches and the bust measurement is 35 inches, the difference is 3 inches, corresponding to a C cup, and the bra size is 32C **(Fig. 2A)**.

JAYPEE BROTHERS

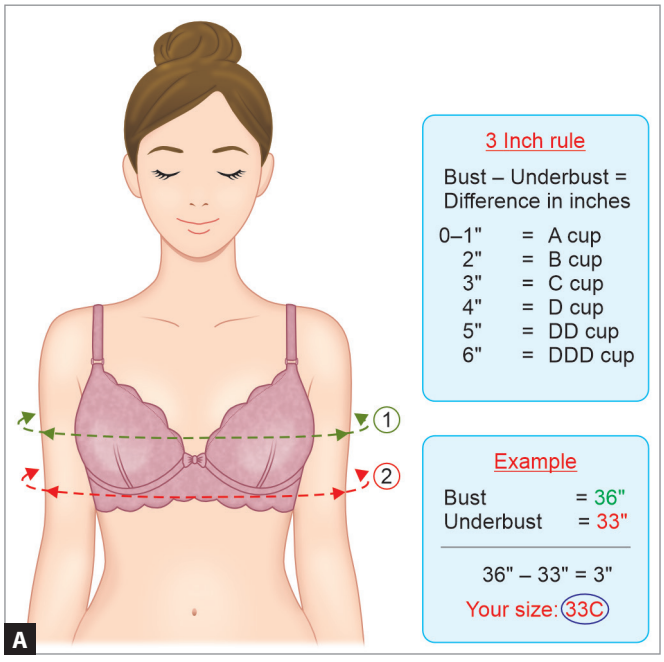

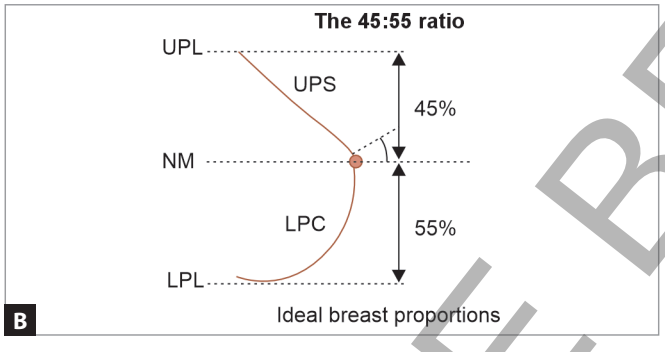

Figs. 2A and B: (A) Measurements of the breast and (B) The ideal breast (Mallucci et al.). (LPC: lower pole curve; LPL: lower pole line; NM: nipple meridian; UPL: upper pole line; UPS: upper ploe slope)

Ideal Breast

Mild breast asymmetry is common and may be seen in up to 20% of individuals. From an aesthetic perspective, an ideal breast is often described as having a C cup size, although this is individualized. The "rule of thirds" is an important guiding principle in oncoplastic planning: The areolar width should be approximately one-third of the breast base, and the nipple should measure about one-third of the areolar diameter, ensuring proportional harmony **(Fig. 2B)**.

In terms of contour and positioning, the upper pole of the breast should have a straight or slightly concave slope, while the lower pole should demonstrate a well-defined convexity with adequate tightness. The nipple–areola complex (NAC) should be oriented slightly upward, at an angle of approximately 20°, with a subtle lateral direction. Ideally, the nipple is positioned 7–8 cm above the inframammary fold (IMF), and the areola typically measures around 40 mm in diameter, contributing to an esthetically balanced breast.

Ptosis

Breast ptosis is classified as true ptosis—Grade I (nipple at the level of the inframammary fold), Grade II (nipple below the fold but above the gland contour), and Grade III (nipple below both the fold and gland contour)—along with partial ptosis (nipple above the fold with breast tissue hanging below) and pseudoptosis (nipple above the fold with a hypoplastic, dependent breast) **(Fig. 3 and Table 3)**.

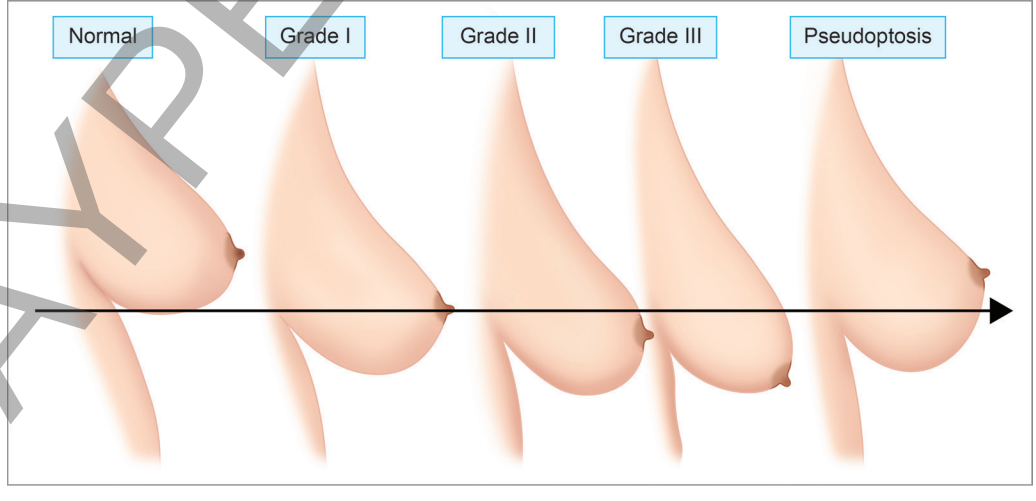

Fig. 3: Regnault's grade of ptosis.

JAYPEE BROTHERS

TABLE 3: Regnault's grade of ptosis.

Type	*Grade*	*Description*
True ptosis	Grade I	Nipple at the level of inframammary fold and above the contour of the gland
	Grade II	Nipple below the inframammary fold and above the contour of the gland
	Grade III	Nipple below the inframammary fold and below the contour of the gland
Partial ptosis	–	Nipple above the inframammary fold, but breast hangs below the fold
Pseudoptosis	–	Nipple above the inframammary fold, breast is hypoplastic and hangs below the fold

ONCOPLASTIC BREAST SURGERY

Krishna Clough Bi-level Classification

The Krishna Clough Bi-level classification categorizes oncoplastic techniques based on the extent of breast tissue excision, requirement for skin resection, and the need for mammoplasty to achieve optimal reconstruction. This is summarized in **Table 4** and **Flowchart 1**.

TABLE 4: Krishna Clough Bi-level classification of oncoplastic techniques.

Criteria	*Level I*	*Level II*
Maximum excision volume ratio	20%	20–50%
Requirement of skin excision for reshaping	No	Yes
Mammoplasty	No	Yes
Glandular characteristics	Dense	Dense or fatty

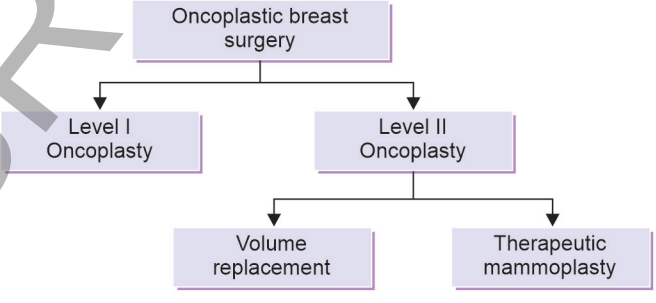

Flowchart 1: Classification of oncoplastic breast surgery.

Aims of Oncoplasty

The aims of oncoplasty are as follows:

- Complete oncological excision of the tumor
- Achievement of clear surgical margins
- Optimal cosmetic and esthetic outcomes
- Single-stage definitive surgical procedure

Indications for Oncoplasty

The indications of oncoplasty are as follows:

- Early breast carcinoma with patient willingness for adjuvant radiotherapy
- Favorable tumor-to-breast size ratio
- Good response to NACT
- Ability to achieve clear surgical margins

Contraindications

The contraindications for breast conservation are summarized as absolute and relative and are given in **Tables 5 to 7**.

PREOPERATIVE PLANNING

The selection and planning of oncoplastic breast surgery depend on a comprehensive assessment of patient, tumor, and surgical factors. They are as follows:

- *Patient factors:*
  - Age
  - Comorbidities
  - Body habitus and BMI
  - Breast size, shape, and degree of ptosis
  - Informed consent and patient preference
- Donor site factors
- Local flap considerations
- Surgical expertise
- *Tumor factors:*
  - Number and location of lesions
  - Tumor size
  - Pattern of tumor spread within the breast
  - Tumor-to-breast volume ratio
  - Anticipated volume loss
  - Need for contralateral symmetrization.

FACTORS DETERMINING THE TYPE OF SURGERY

Preoperative planning in oncoplastic surgery requires a detailed assessment of breast volume, tumor

JAYPEE BROTHERS

TABLE 5: Absolute contraindications to breast-conserving therapy (BCT).

Category	*Condition*	*Reason*
At presentation	Pregnancy (1st trimester)	Requires mastectomy; 2nd/3rd trimester may undergo BCT with postpartum RT
Past history	Prior chest wall irradiation	Previous RT is an absolute contraindication.
Clinical examination	Multicentric disease	If multiple lumps cannot be resected with good cosmesis.
Investigations	Diffuse malignant microcalcifications	Seen on mammogram; suggests widespread disease.
Intra/postoperative findings	Persistent positive margin	Positive margin after re-resection (frozen or paraffin sections)

TABLE 6: Relative contraindications to breast-conserving therapy (BCT).

Category	*Condition*	*Reason*
Connective tissue diseases	Scleroderma	Higher radiation complication rate due to skin fragility
	Sjögren's syndrome	Similar increased risk of RT-related toxicity
	SLE and rheumatoid arthritis	May have increased skin toxicity; though no fatal events noted
Tumor-breast ratio	Large tumor in small breast	May result in poor cosmesis; oncoplasty or neoadjuvant chemotherapy (NACT) can help enable BCT.
Pendulous breast	Previously a concern	Now manageable with improved RT techniques for dose homogeneity

TABLE 7: Factors no longer a contraindication.

Factor	*Reason*
Age	Older patients have lower recurrence rates and can safely undergo BCT.
Tumor location	Medial tumors can now be managed with oncoplastic reconstruction.
Invasive lobular carcinoma	Negative margins acceptable; LCIS at margin not clinically significant
Extensive intraductal component (EIC)	If margins are negative, recurrence risk is not increased.
Family history of breast cancer	Not a contraindication, but patients must be informed of second primary risk.
Lymph node positivity	Node-positive status impacts prognosis but not eligibility for BCT.

(BCT: breast-conserving surgery; LCIS: lobular carcinoma in situ)

characteristics, and imaging parameters to guide the choice of technique **(Fig. 4)**.

- Breast volume assessment using cup size, supplemented by high-resolution ultrasound based volumetric evaluation
- Estimation of resection volume as a percentage; although clinical assessment is subjective, HRUSG aids in more accurate planning
- Use of 3D reconstruction techniques in selected centers for surgical planning

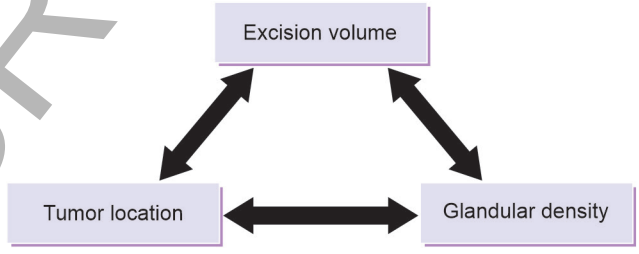

Fig. 4: Principles of oncoplastic surgery: It is based on the tumor location, the density of the breast to reshape the excised volume.

- Distance of the tumor from the nipple–areola complex (NAC), influencing the choice of oncoplastic approach
- Quadrant location of the tumor, guiding incision placement
- Tumor depth, defined as the distance from the overlying skin
- Breast density, with denser breasts generally associated with better cosmetic outcomes
- Mammographic classification of breast density into fatty, scattered fibroglandular, heterogeneously dense, and extremely dense types **(Box 2)**.

BOX 2: ACR breast density and oncoplasty.

- Dense glandular breast (ACR 3/4) can easily be mobilized by dual-plane undermining without risk of necrosis.
- Low-density breast tissue with a major fatty composition (ACR 1/2) has a higher risk of fat necrosis after extensive undermining.

JAYPEE BROTHERS

Level I Oncoplasty

Level I oncoplastic techniques are suitable for small-volume resections (<20% of breast volume) and focus on simple glandular reshaping without the need for complex reconstruction **(Figs. 5A to C)**.

- *Skin incision:* It provides adequate access for tumor excision.
- *Skin undermining:* It facilitates wide local excision and dermoglandular mobilization (dual plane mobilization; **Video 9.3**).

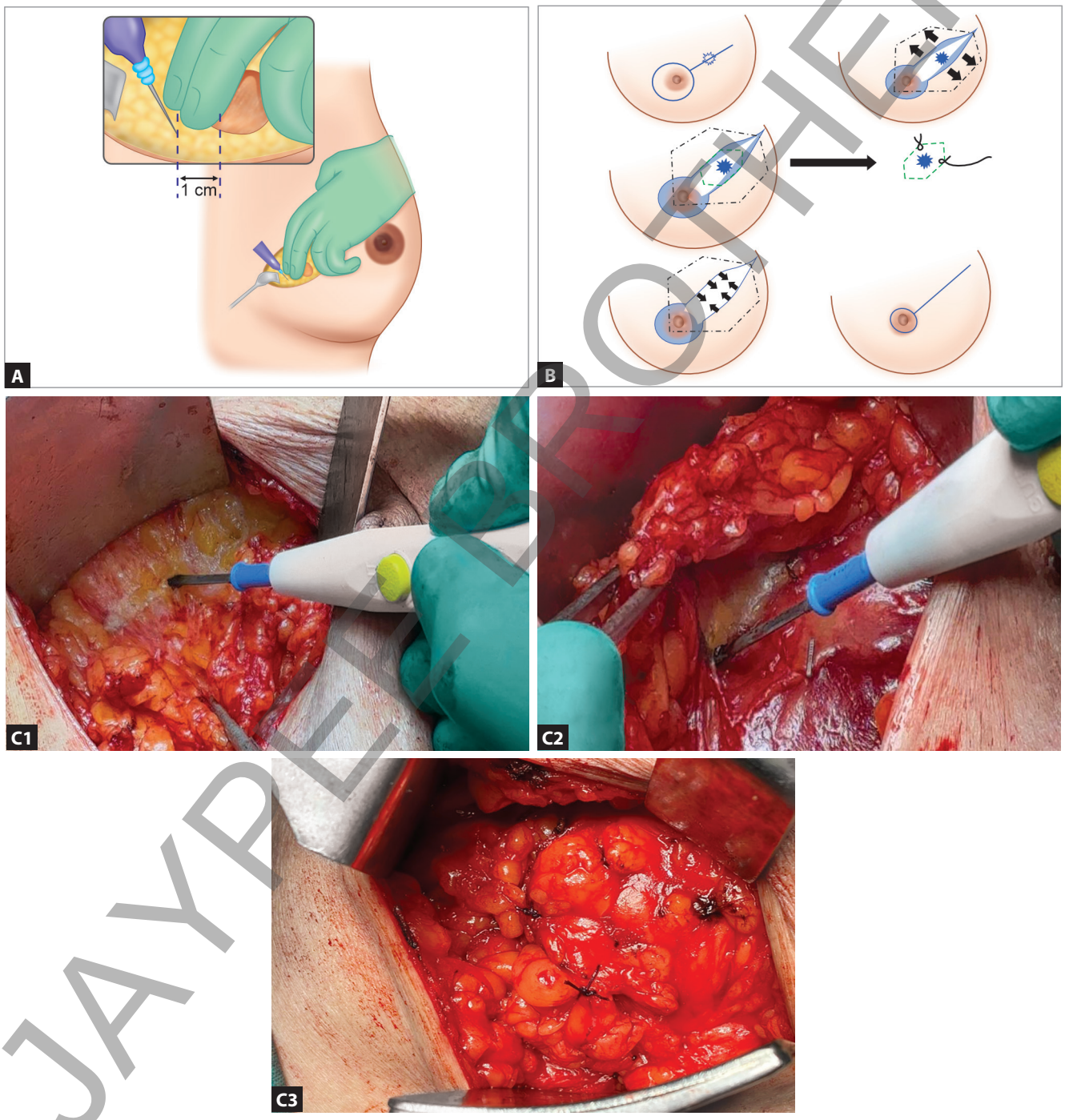

Figs. 5A to C: (A) Margin assessment with finger (conceptual guide to 1 cm margin); (B) Schematic diagram of dual plane mobilization in type 1 oncoplasty; (C1) Dual plane mobilization (superior); (C2) Dual plane mobilization (inferior); and (C3) Dual plane mobilized breasts are sutured together to fill the cavity.

JAYPEE BROTHERS

- *Nipple areolar complex undermining:* It prevents displacement of the nipple–areola complex toward the defect.
- *Full-thickness excision:* It ensures oncologically safe (R0) resection.
- *Glandular reapproximation:* It minimizes postexcision deformity.
- *De-epithelialization and nipple areolar complex repositioning:* It helps in recentring the nipple–areola complex.

Lateral/Racquet Mammaplasty

Lateral (racquet) mammaplasty is a level I oncoplastic technique primarily used for tumors located in the outer quadrants of the breast **(Box 3)**. The procedure involves planning a racquet-shaped incision, combining a periareolar component with a lateral extension toward the tumor. Wide local excision is performed through the lateral limb with adequate oncological margins (R0 resection). This is followed by skin undermining and mobilization of adjacent glandular tissue, allowing the defect to be filled by glandular advancement and reapproximation. The nipple–areola complex is preserved and may be subtly repositioned to maintain symmetry, and the skin is redraped and closed to achieve an optimal cosmetic result **(Figs. 6A to D, Video 9.4)**.

BOX 3: Quadrants and the outcomes of breast conservation surgery.

- Tumors located in the upper outer quadrant (UOQ) are considered the most favorable for breast conservation and oncoplastic surgery because they usually provide the best cosmetic outcomes.
- Tumors situated in the upper inner quadrant (UIQ) and lower pole of the breast are relatively less favorable, as surgery in these areas is associated with a greater risk of contour deformity and poor cosmesis.
- Bird-beak deformity is a postoperative contour abnormality in which scar contracture and inadequate redistribution of breast tissue produce a pointed, angular appearance, most commonly following lower pole tumor resection without oncoplastic reconstruction.



Figs. 6A to D: Lateral mammaplasty (note the incision marked with the ICG dye instilled), the nipple areolar complex may need reconstruction to prevent deviation.

JAYPEE BROTHERS

Crescent Mastopexy

Crescent mastopexy is a volume displacement oncoplastic technique commonly used for small tumors located close to the nipple–areola complex, particularly in the upper pole of the breast. The procedure involves excision of a crescent-shaped segment of skin above the areola along with glandular reshaping and advancement, allowing adequate tumor excision while maintaining breast contour, symmetry, and nipple position with a cosmetically favorable scar **(Figs. 7A to C and Video 9.5)**.

Level II Oncoplasty

Oncoplastic techniques are broadly classified into volume displacement and volume replacement procedures, based on how the postexcision defect is managed. While volume displacement utilizes rearrangement of remaining breast tissue, volume replacement employs local or regional flaps to restore breast volume and contour. This is summarized in **Table 8**.

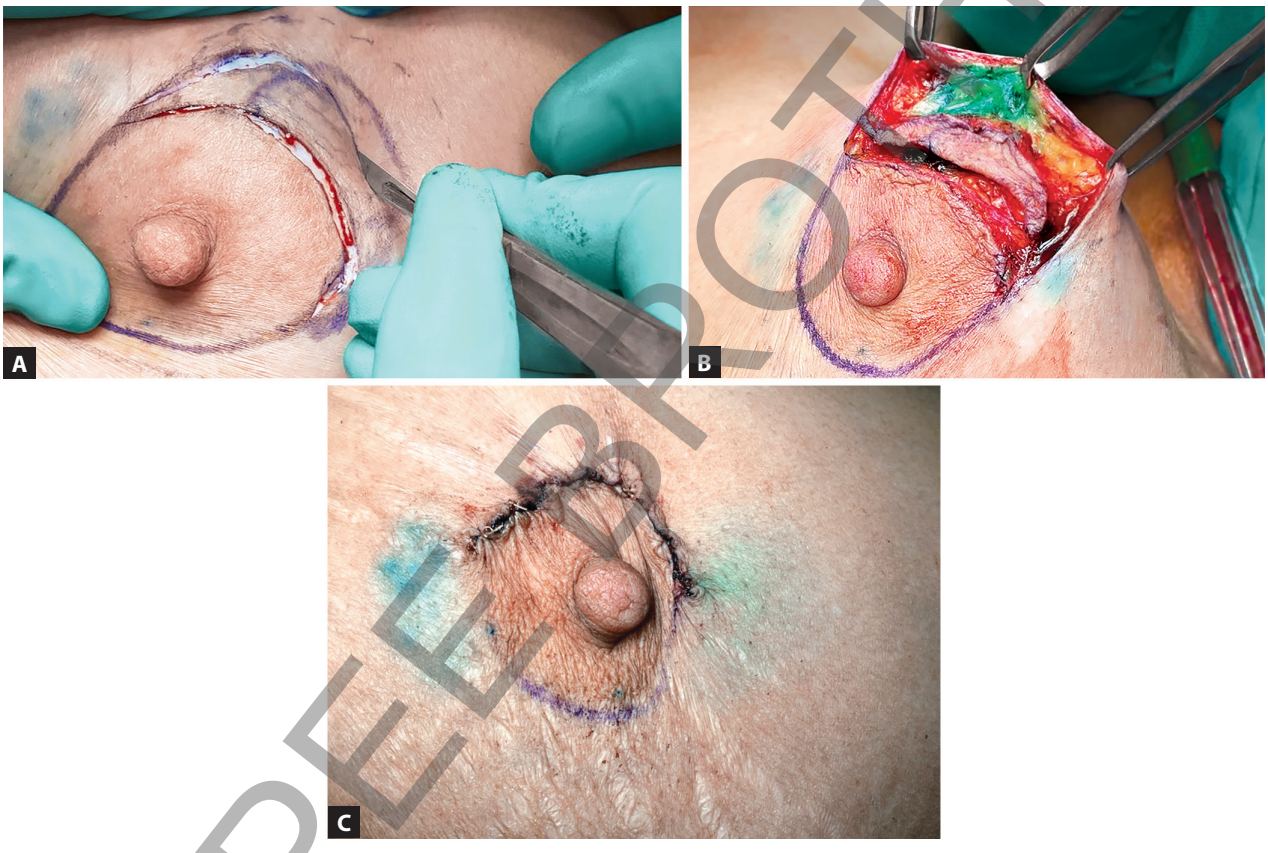

Figs. 7A to C: Cresent mammaplasty.

TABLE 8: Type II oncoplasty.

Volume replacement	*Volume displacement*
Lateral thoracodorsal flap	Glandular reshaping
Thoracoepigastric flap	Parallelogram mastopexy lumpectomy
AICAP/LICAP	Purse-string suture
TDAP flap	Round-block technique
LD myocutaneous flap	Batwing mastopexy
	Tennis racket method
	Rotation flap

(AICAP: anterior intercostal artery perforator; LD: latissimus dorsi; LICAP: lateral intercostal artery perforator; TDAP: thoracodorsal artery perforator)

JAYPEE BROTHERS

Matrix Rotation Mammaplasty

Matrix rotation mammaplasty is an oncoplastic technique used for breast conservation in medium-to-large breasts, particularly for tumors located in the upper and central quadrants. The technique involves rotational rearrangement of breast parenchyma to fill the postexcisional defect, thereby maintaining breast contour and improving cosmetic outcomes **(Figs. 8A to D)**.

Round Block Oncoplasty (Video 9.6)

The round block technique is a level I oncoplastic procedure with specific eligibility criteria based on breast characteristics and tumor location **(Figs. 9A and B)**.

- *Eligibility:*
  - Suitable for small- to medium-sized breasts.
  - Best avoided in large, ptotic, and fatty breasts.
- *Mammographic density considerations:*
  - ACR categories C and D are ideal.
  - Can be used selectively in ACR category B.
- *Tumor location:*
  - Upper quadrant tumors are preferred.
  - Can be applied to all quadrants, particularly for periareolar tumors.

Complications of round block technique: The round block technique, although cosmetically advantageous, is associated with certain procedure-specific complications that should be anticipated during planning and execution.

- Excessive undermining beneath the nipple–areola complex may lead to partial nipple necrosis.
- Seroma formation and occasional hematoma can occur.
- Fat necrosis and fibrosis, which may worsen after radiotherapy, especially in older patients with fatty breasts and compromised vascularity.
- Areolar widening leading to suboptimal esthetic outcome.

Batwing Mastopexy

Batwing mastopexy lumpectomy is a useful oncoplastic technique for tumors located deep or adjacent to the

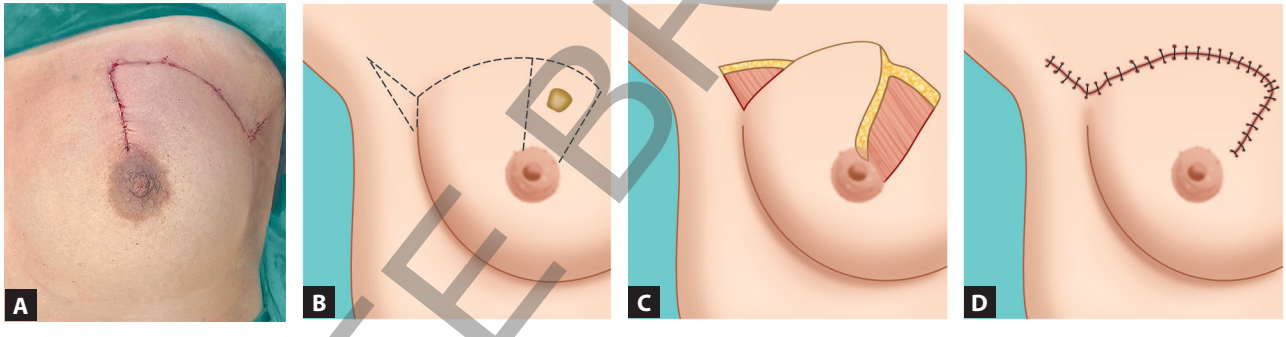

Figs. 8A to D: (A) Completed matrix rotation mammaplasty and (B to D) Schematic description of matrix rotation flap.



Figs. 9A and B: (A) Incision of the round block technique and (B) Circumferential de-epithelization of the nipple areolar complex.

JAYPEE BROTHERS

nipple–areola complex (NAC) without direct involvement. It involves excision of two crescent-shaped segments of skin and underlying parenchyma superior to the NAC, along with adjacent triangular extensions on either side, allowing adequate exposure and resection. This approach is particularly suitable for lesions in the upper hemisphere of the breast, typically between the 9 o'clock and 3 o'clock positions. It permits generous tumor excision—often up to 200 g or more depending on breast volume—while enabling effective reshaping to achieve a favorable cosmetic outcome **(Figs. 10A and B)**.

Hemi-batwing Mastopexy

The hemi-batwing technique is a modification of the batwing mastopexy, designed for more localized lesions. As the name suggests, it involves resection of only one crescent-shaped segment along with a single adjacent triangular portion of skin and underlying parenchyma, allowing targeted excision while preserving more breast tissue and maintaining cosmesis **(Fig. 11)**.

Grisotti Mastopexy (Video 9.7)

The Grisotti mastopexy is an excellent approach to oncoplasty for a centrally located tumor, especially when the NAC resection is required in a woman with adequate breast volume and moderate breast ptosis. The Grisotti flap is also known as B-flap resection because of the "B" shaped incision.

Patient selection: This incision is suitable for lesions that are located in the central quadrant and involve the NAC **(Figs. 12A to D)**.

Chest Wall Perforator Flaps

Chest wall perforator flaps (CWPF) have significantly expanded the scope of BCS, allowing selected patients—who might otherwise require mastectomy—to undergo conservation with good cosmetic outcomes. These flaps are particularly useful in patients with adequate lateral chest wall and upper abdominal fasciocutaneous tissue, enabling replacement of excised breast volume (up to 40%) with like-for-like tissue without sacrificing underlying muscle. First described by Hamdi, CWPFs are versatile and well-suited for tumors located in the outer and lower halves of the breast, especially in cases with a high tumor-to-breast ratio. They are ideal for small- to moderate-sized breasts with minimal or no ptosis, utilizing redundant lateral chest wall or upper abdominal tissue. Their proximity to the breast allows reliable transfer without compromising future reconstructive options, and the procedure can be performed in both immediate and delayed settings.

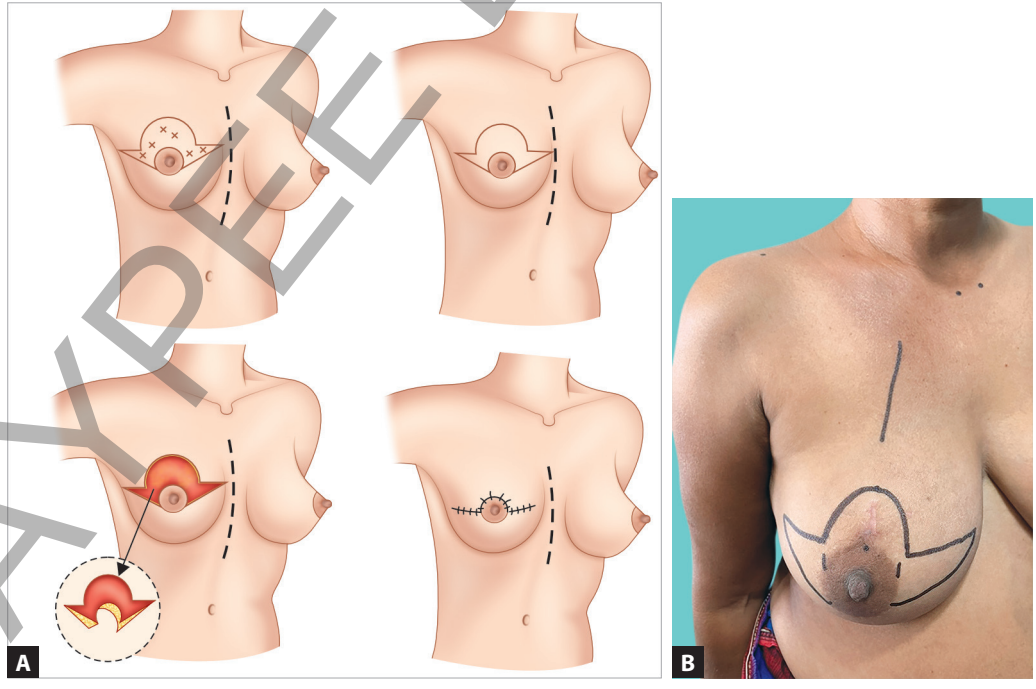

Figs. 10A and B: (A) Schematic diagram of batwing mastopexy and (B) Planning incisions in batwing mastopexy (Note the breast meridian being drawn, this also covers an unsightly scar from a previous incomplete lumpectomy).

JAYPEE BROTHERS

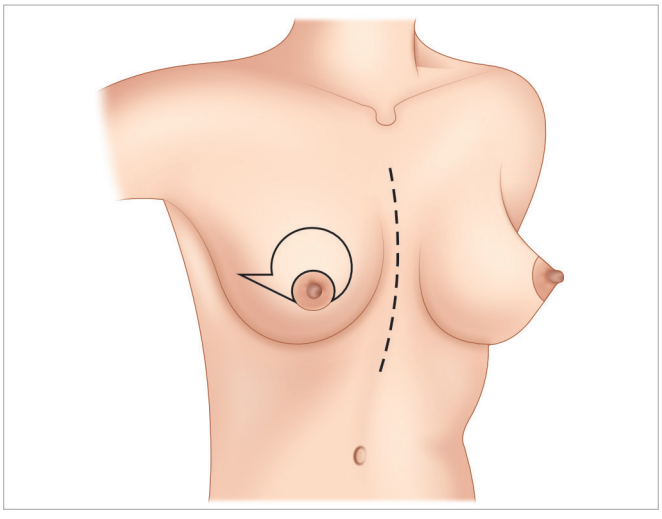

Fig. 11: Hemi batwing mastopexy.

However, specific complications include flap necrosis and fat necrosis. **Algorithm 2** demonstrates the Nottingham approach to chest wall perforator flaps in clinical decision making **(Figs. 13A and B)**.

Lateral Intercostal Artery Perforator Flap (Video 9.8)

The lateral intercostal artery perforator (LICAP) flap is a pedicled chest wall perforator flap based on the LICAPs and is particularly useful for reconstruction of defects in the outer quadrants of the breast following BCS **(Box 4)**. It provides a muscle-sparing option with minimal donor-site morbidity while maintaining good color and texture match to the breast. The flap can be designed as a propeller, turnover, or transposition flap depending on the location

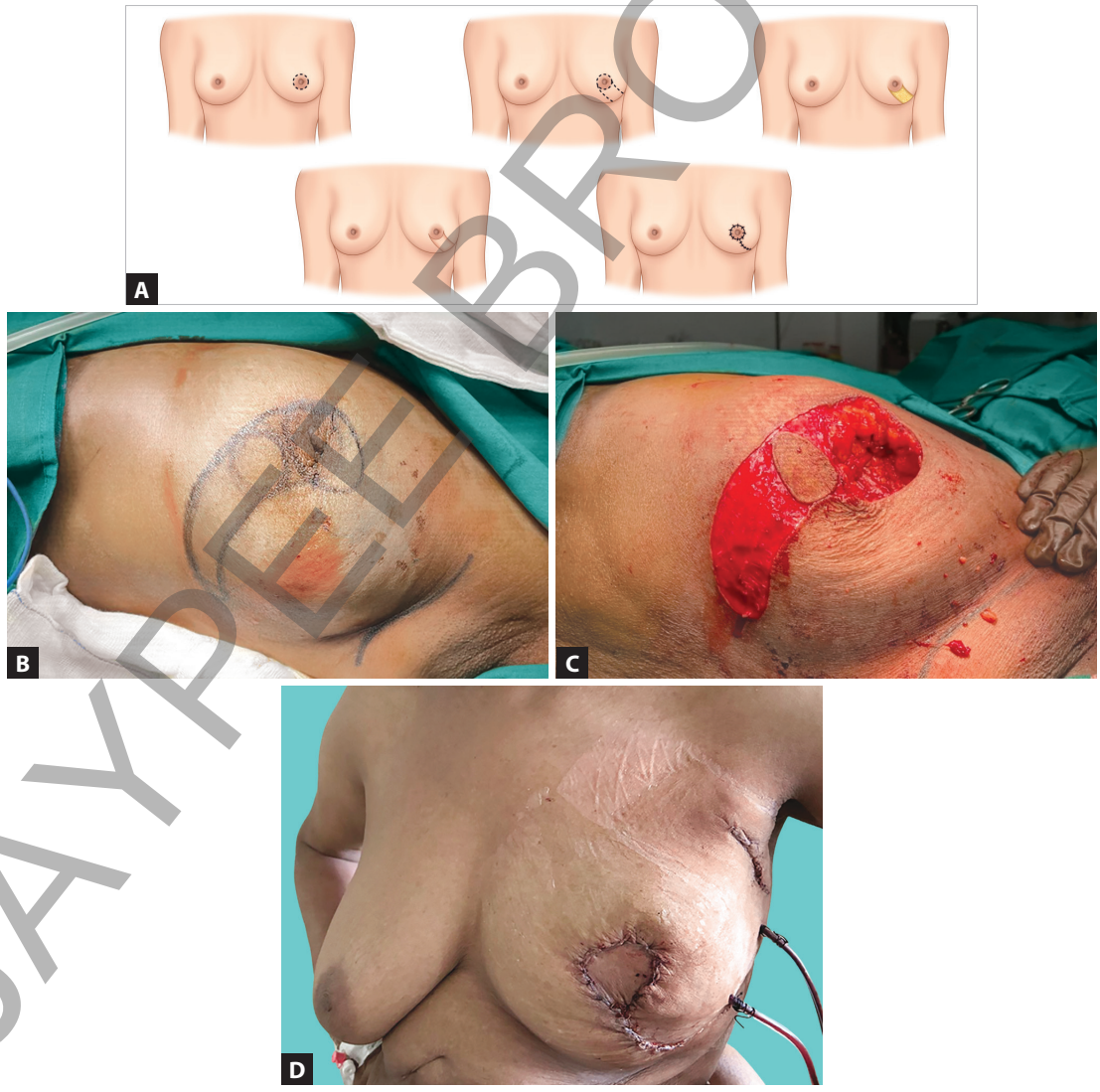

Figs. 12A to D: Grisotii mastopexy for central defects (Note the cosmesis with the flap).

JAYPEE BROTHERS

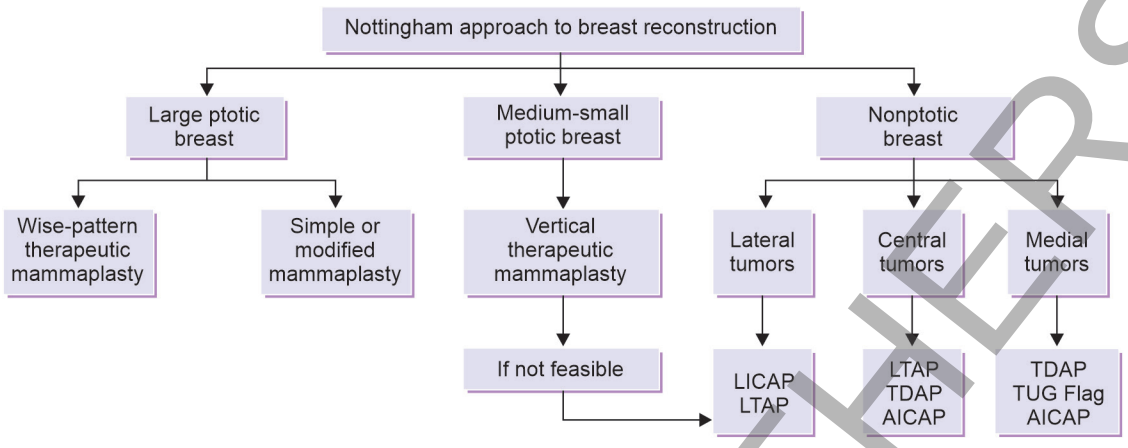

Algorithm 2: Nottingham approach to breast reconstruction. (AICAP: anterior intercostal artery perforator; LICAP: lateral intercostal artery perforator; LTAP: lateral thoracic artery perforator; TDAP: thoracodorsal artery perforator; TUG: transverse upper gracilis flap)

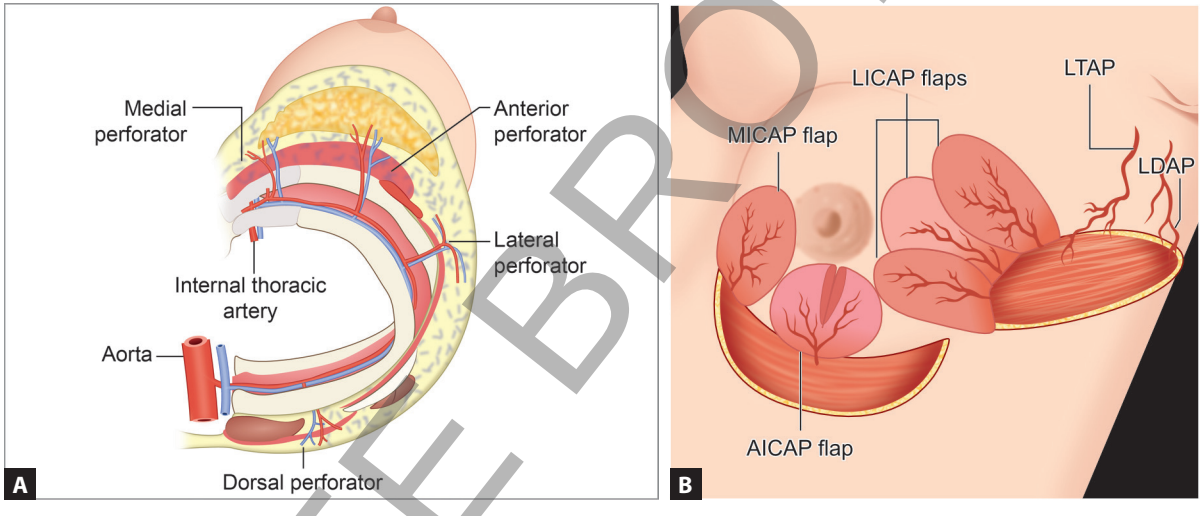

Figs. 13A and B: (A) Various perforators in the chest wall; and (B) Flaps derived from these perforator vessels. (AICAP: anterior intercostal artery perforator; LICAP: lateral intercostal artery perforator; LTAP: lateral thoracic artery perforator; MICAP: medial intercostal artery perforator; TDAP: thoracodorsal artery perforator)

and size of the defect, and its reliable vascular anatomy allows effective volume replacement with favorable cosmetic outcomes **(Figs. 14A to D)**.

BOX 4: Subcostal artery perforator (SCAP) flap: Newer chest wall perforator flap.

This is a newly explored chest wall perforator flap and is used for covering local defects of the breast, especially in the lower pole of the breast.

Anterior Intercostal Artery Perforator Flap (Video 9.9)

The anterior intercostal artery perforator (AICAP) flap is designed along the inframammary fold and is based on the anterior intercostal artery perforators emerging near the parasternal region. The superior boundary is usually the inframammary fold, while the inferior boundary extends over the upper abdominal skin and subcutaneous tissue. Medially, the flap lies close to the sternal border, and laterally it may extend toward the anterior axillary line depending on the volume required. The flap is planned as an elliptical or crescent-shaped skin paddle to allow adequate reach to lower pole and medial breast defects while maintaining a concealed donor scar within the inframammary crease **(Figs. 15A to D)**.

Lateral Thoracic Artery Perforator Flap

The lateral thoracic artery perforator (LTAP) flap is a pedicled chest wall perforator flap based on perforators from the lateral thoracic artery and is mainly used

JAYPEE BROTHERS

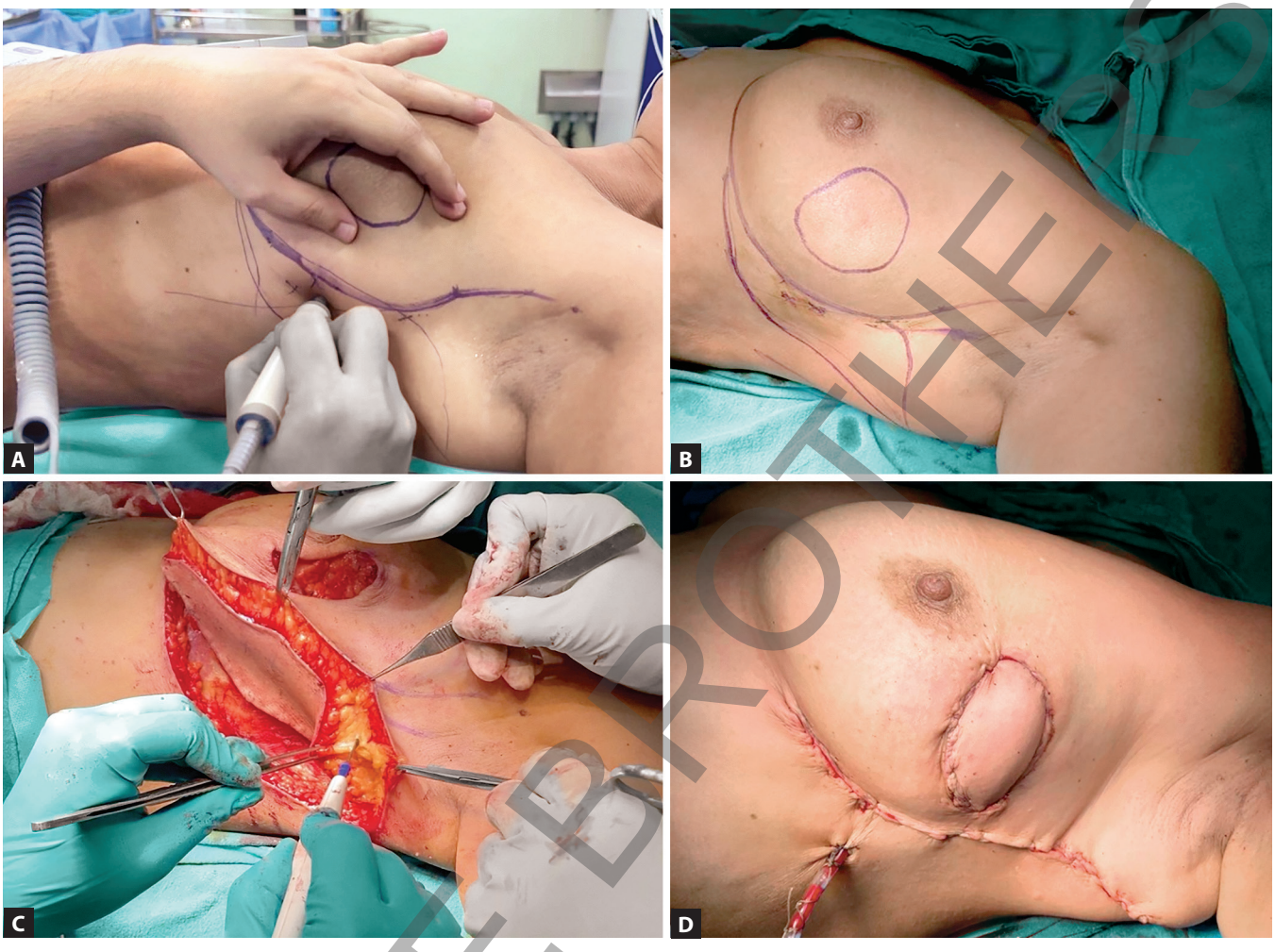

Figs. 14A to D: Planning the lateral intercostal artery perforator (LICAP) with a Doppler and marking the flap. The flap is inset into the lumpectomy cavity.

for reconstruction of lateral and superolateral breast defects following BCS. It provides thin, pliable, and well-vascularized tissue with excellent color and texture match while preserving the underlying muscles and thereby reducing donor-site morbidity. The flap can be harvested with relative ease and offers a good arc of rotation, making it useful for partial breast reconstruction with favorable cosmetic outcomes and a concealed scar along the lateral chest wall or bra line **(Figs. 16A and B)**.

Thoracodorsal Artery Perforator Flap

The thoracodorsal artery perforator (TDAP) flap is one of the most versatile pedicled perforator flaps used in partial breast reconstruction. It is based on perforators arising from the descending branch of the thoracodorsal artery and provides adequate soft tissue volume for reconstruction of lateral, central, and upper breast defects. The major advantage of the TDAP flap is preservation of the latissimus dorsi muscle, which significantly reduces postoperative pain, shoulder dysfunction, and donor-site morbidity compared with the traditional latissimus dorsi flap. The flap has a long vascular pedicle, reliable anatomy, and wide arc of rotation, allowing effective volume replacement with excellent cosmetic outcomes **(Table 9)**.

Latissimus Dorsi Mini-flap

The latissimus dorsi (LD) flap is one of the most commonly used, reliable, and versatile options in oncoplastic breast surgery, particularly for volume replacement. However, it is associated with certain drawbacks, including seroma formation, donor-site scarring, and potential wound

JAYPEE BROTHERS



Figs. 15A to D: Planning the anterior intercostal artery perforator (AICAP) with a Doppler and marking the flap. The flap is inset into the lumpectomy cavity, note the cosmesis. The perforators are demonstrated in **Figure C**. This flap is best suited for lower inner quadrants of the breast.

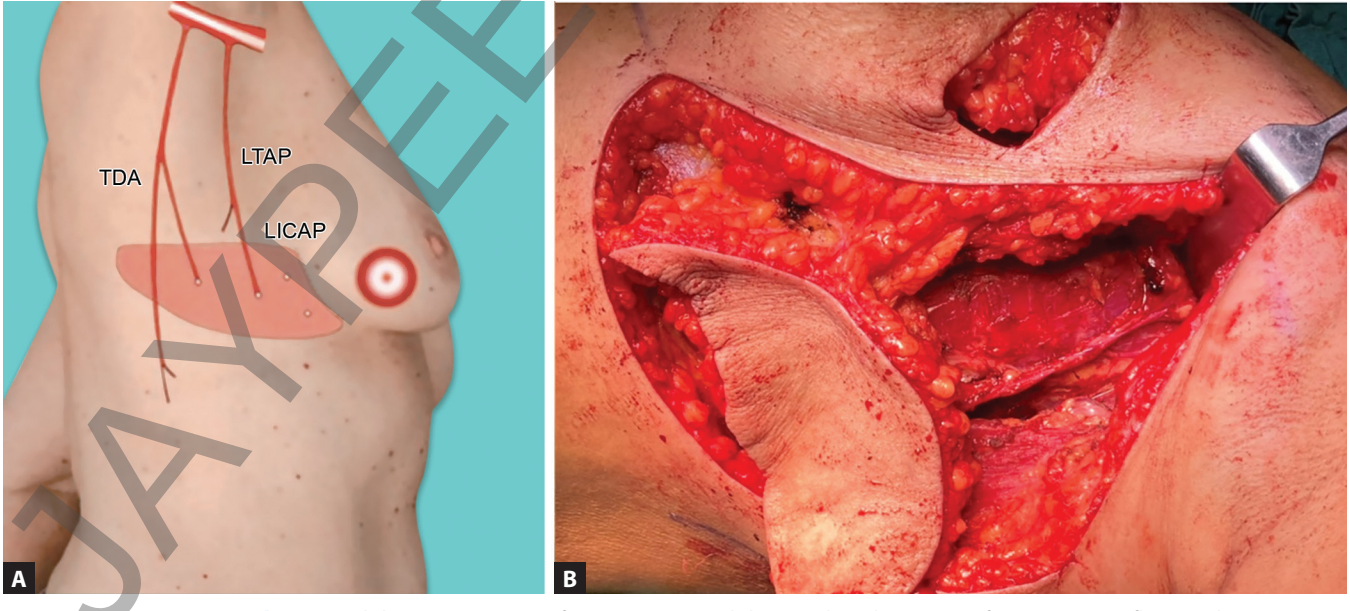

Figs. 16A and B: Lateral thoracic artery perforator (LTAP) and thoracodorsal artery perforator (TDAP) flaps and (B) Note the LTAP vessel as the supply for the flap. (LTAP: lateral thoracic artery perforator flap)

JAYPEE BROTHERS

TABLE 9: Common flaps in oncoplastic surgery and their clinical applications.

Flap (source vessel)	*Reach*	*Advantages*	*Limitations*
TDAP (Thoracodorsal artery)	All quadrants	Covers large defects; preserves LD muscle; fewer donor-site complications; good color match	Difficult perforator dissection; variable anatomy
LTAP (Lateral thoracic artery)	Lateral	Preserves TDAP/LD; scar hidden in bra strap; good reach and perfusion	Variable/absent anatomy; difficult during axillary clearance
LICAP (Lateral intercostal artery)	Lateral	Preserves TDAP/LD; easy vessel identification; concealed scar	Short perforators; variable position; risk of fat necrosis
AICAP (Anterior intercostal artery)	Inferior	No intraoperative repositioning; scar along IMF	Limited tissue volume; RT may affect vascularity
MICAP (Medial intercostal artery)	Medial	No repositioning; scar along IMF	Similar limitations as AICAP
Thoracoepigastric flap	Inferior central/ superomedial	Good arc of rotation; longer pedicle	Similar limitations as AICAP

(LD: latissimus dorsi)

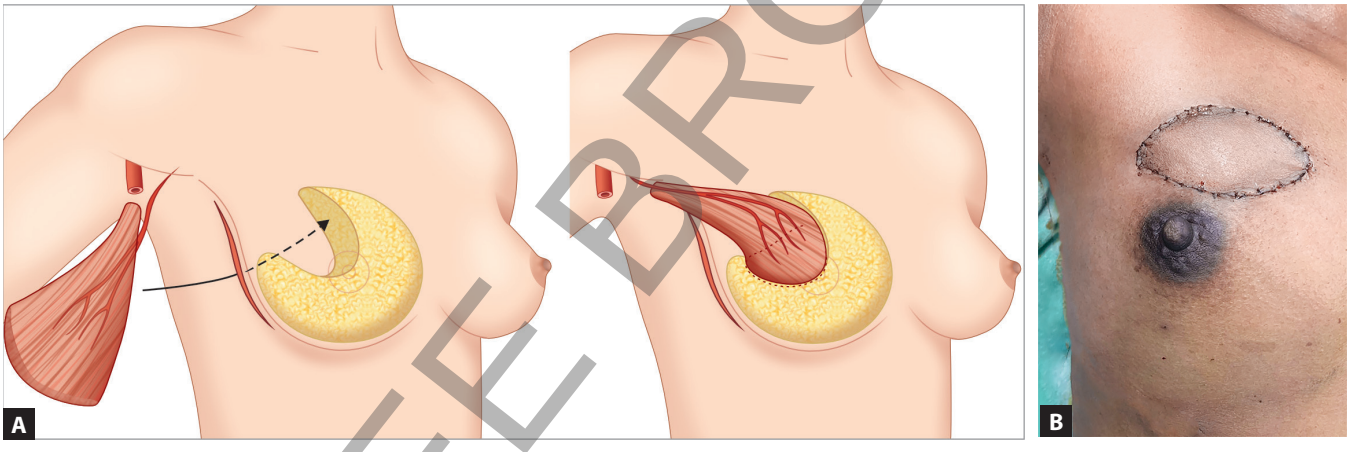

Figs. 17A and B: (A) Schematic diagram of the Latissimus dorsi minilap and (B) Mini-Latissimus dorsi flap for reconstruction of the superior breast.

healing issues, especially when large volumes are harvested. The latissimus dorsi mini-flap (LDMF) serves as a valuable alternative in cases requiring moderate volume replacement (30–40%), particularly in patients with skin loss or unsatisfactory outcomes following prior BCS **(Figs. 17A and B)**.

- *Indications/patient selection:*
  - Volume loss >30%.
  - Tumors located in the outer or central quadrants.
  - Large primary tumor with poor tumor-to-breast ratio.
  - Small- to medium-sized breasts.
  - Presence of skin loss.
  - Patient not keen on contralateral symmetrization.
  - Reluctance for implant-based reconstruction.
  - When volume displacement techniques are not feasible.
  - Secondary reconstruction for poor cosmesis after prior breast conservation.
- *Contraindications:*
  - Suspected damage to the vascular pedicle due to prior surgeries (e.g., thoracotomy or extensive axillary dissection).
  - Congenital absence of the latissimus dorsi muscle.
  - Very large defects or patients with a thin/insufficient LD muscle **(Box 5)**.

JAYPEE BROTHERS

BOX 5: Complications related to oncoplasty and reconstruction **(Figs. 18A to C)**.

- *Early postoperative complications:*
  - Hematoma
  - Wound infection
  - Seroma
  - Partial or complete flap loss
  - Wound breakdown
- *Late complications:*
  - Breast animation/twitching
  - Atrophy of the flap

THERAPEUTIC MAMMOPLASTY SURGICAL TECHNIQUES

Therapeutic mammoplasty is a key oncoplastic technique that combines tumor excision with breast reduction and reshaping, aiming to achieve both oncological safety and optimal cosmesis. It is based on three fundamental components **(Fig. 19)**:

1. Resection of excess breast tissue, including the tumor-bearing area.
2. Excision of redundant skin to allow appropriate reshaping.
3. Preservation of vascularity with maintenance and repositioning of the nipple–areola complex (NAC).

Planning a Therapeutic Wise pattern Mammaplasty is illustrated in **Video 9.10** and the incision marks are described in **Figure 20**.

Types of Therapeutic Mammoplasty

Therapeutic mammoplasty techniques are broadly classified based on the skin incision pattern into Wise

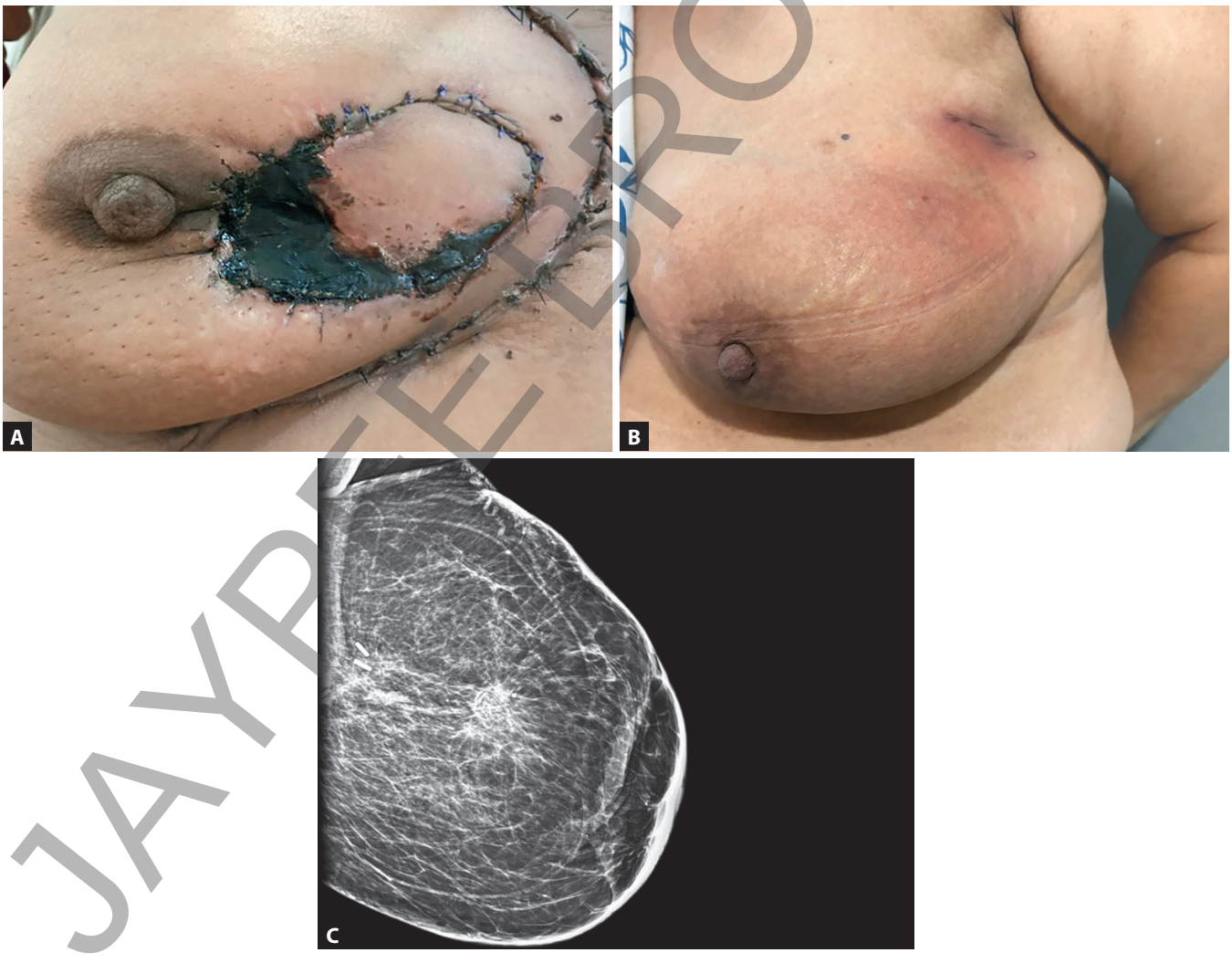

Figs. 18A to C: (A) Necrosis of a chest wall perforator flap; (B) Induration below the skin of the breast due to fat necrosis; and (C) Fat necrosis in the breast due to glandular mobilization, note the clipped region in the base, it is mistaken as a recurrence.

JAYPEE BROTHERS

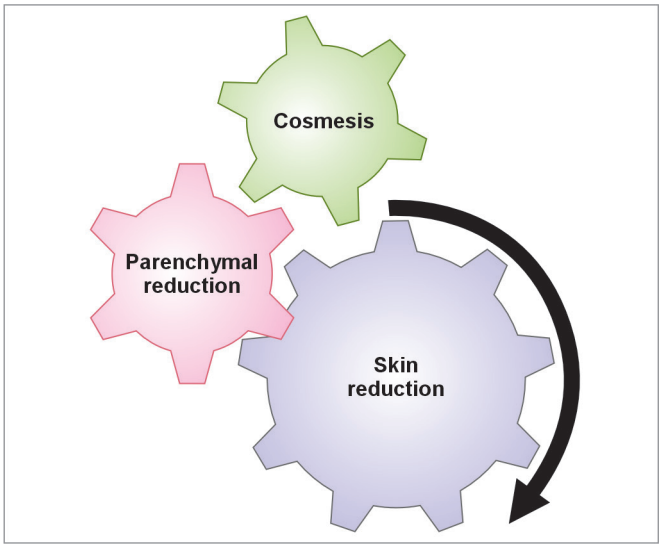

Fig. 19: Concept of therapeutic mammaplasty.

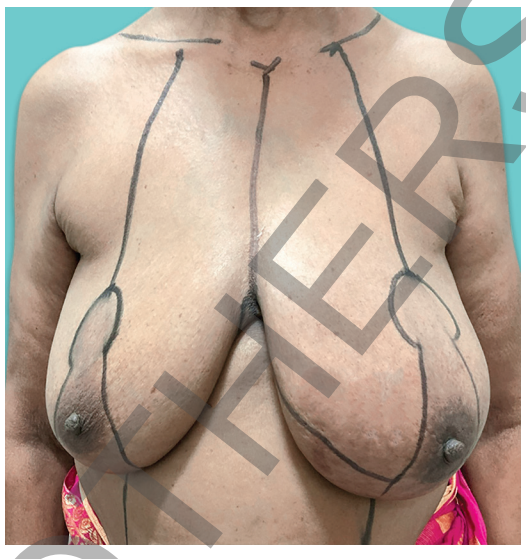

Fig. 20: Wise pattern therapeutic mammaplasty incision.

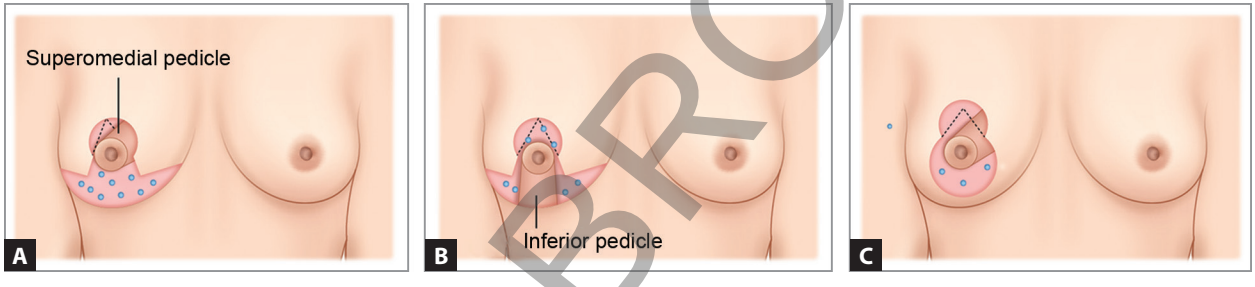

Figs. 21A to C: (A) Wise pattern incision superomedial pedicle; (B) Wise pattern incision inferior pedicle; and (C) Vertical mammoplasty (superomedial pedicle).

(inverted T; **Fig. 20 and Box 6**) and non-wise pattern approaches, each incorporating different pedicle designs and reduction strategies **(Figs. 21A to C)**.

- *Wise (inverted T) pattern:*
  - McKissock technique
  - Pitanguy technique
  - Inferior pedicle technique
  - Central mound technique
  - Free nipple graft
- *Non-wise pattern:*
  - Liposuction-assisted reduction
  - Vertical mammoplasty.

BOX 6: Pedicles for therapeutic mammaplasty.

- Pedicle selection is primarily based on tumor location: Superior/superomedial pedicles for inferior lesions, inferior pedicles for superior lesions, and superomedial/inferomedial or lateral pedicles for lateral or medial tumors, respectively.
- The choice also depends on breast size, degree of ptosis, vascular reliability of the nipple–areola complex, and the required extent of oncological excision.
- Secondary or extended pedicles may be used for complex defects to achieve adequate tumor clearance while maintaining breast shape and nipple–areola viability. Write in point form for consistency **(Fig. 23)**.

Choice of Technique

Planning of therapeutic mammoplasty (TM) commonly involves two clinical scenarios based on tumor location.

- In Scenario A, the tumor lies within the routine reduction mammoplasty excision zone, most classically in the inferior pole, and can be addressed using standard Wise or vertical pattern reductions, typically with a superior pedicle for the NAC. This approach can be adapted for other tumor locations by selecting appropriate pedicles, such as an inferior pedicle for tumors located above the nipple or medial/lateral pedicles depending on tumor position **(Figs. 22A and B)**.
- In Scenario B, the tumor lies outside the standard mammoplasty excision pattern, such as in very superior,

JAYPEE BROTHERS

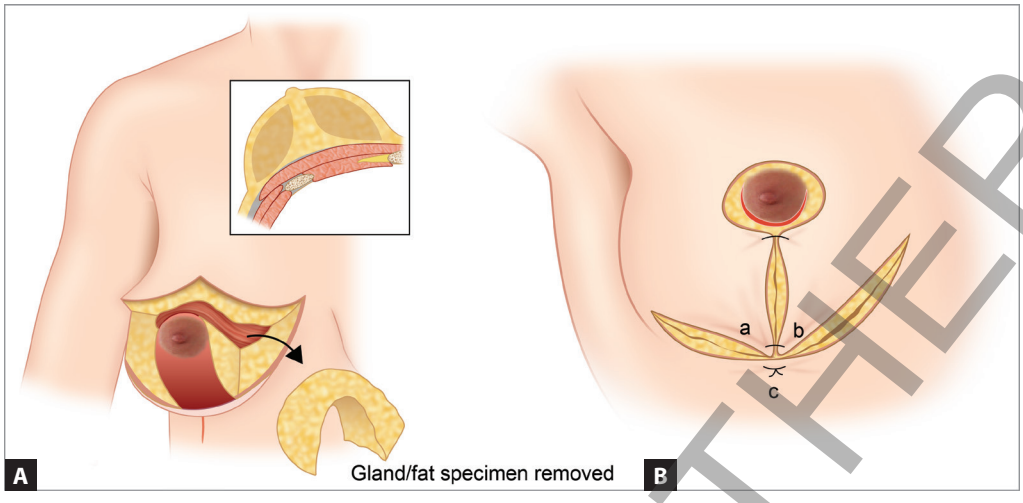

Figs. 22A and B: Wise pattern therapeutic mammaplasty technique.

medial, or lateral locations, or within regions that form the mammoplasty pillars. In these cases, modifications of the conventional mammoplasty technique are required to ensure adequate oncological resection while maintaining breast shape and symmetry.

- *Complications:*
  - *Hematoma:* <1%
  - *Seroma:* 1–5%

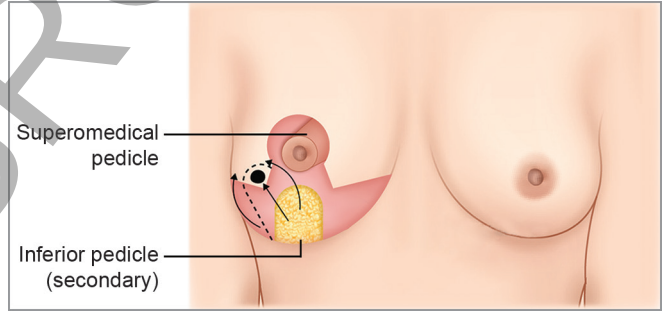

Fig. 23: Secondary pedicle for therapeutic mammaplasty.

Complications of Therapeutic Mammoplasty

Therapeutic mammoplasty is associated with a spectrum of early and late complications, alongside important considerations related to reduction and symmetrization. A clear understanding of these factors is essential for appropriate patient selection, counseling, and optimization of surgical outcomes **(Figs. 24A and B)**.

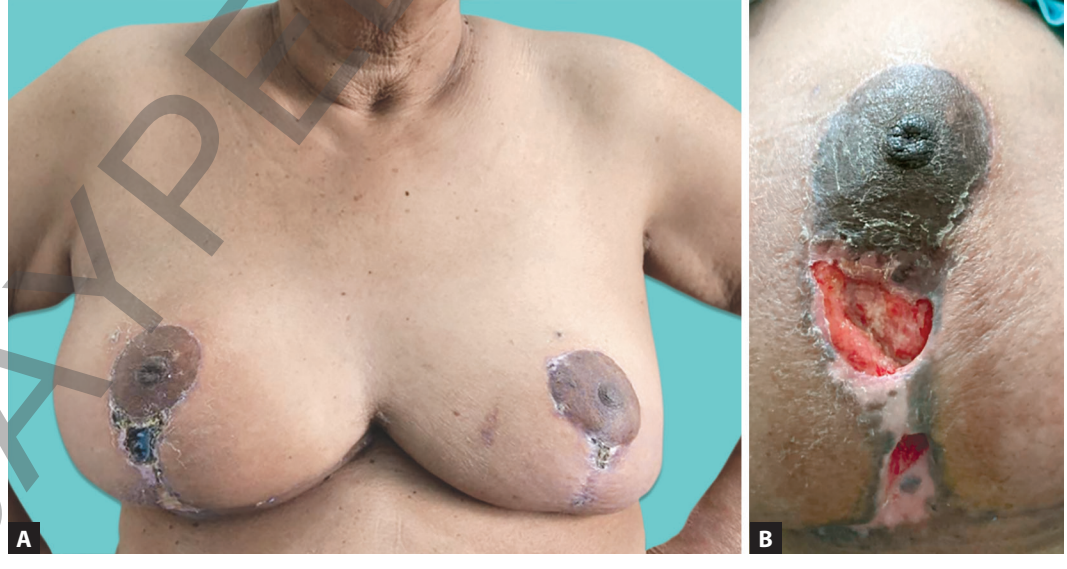

Figs. 24A and B: Complication of skin infection and loss after therapeutic mammaplasty.

JAYPEE BROTHERS

- *Infection:* Cellulitis or abscess
- Skin necrosis
- Fat necrosis
- Nipple loss
- Nipple numbness
- Hypertrophic scars

- *Asymmetry:*
  - Inadequate reduction or over reduction.
  - Boxy breast deformity
  - Recurrent enlargement
  - Inability to breastfeed
  - Dog ears
  - Inadequate mastopexy result.

Contralateral Symmetrization Procedure

Decision-making in breast reconstruction is multifactorial and requires careful consideration of patient characteristics, oncological factors, and surgical options to achieve optimal outcomes. The following factors play a crucial role in guiding the choice of reconstruction **(Figs. 25A and B and Algorithm 3)**:

- *Patient factors:*
  - Age
  - Comorbid status
- *Surgical factors:*
  - Type of mastectomy (skin-sparing vs. non-skin-sparing)
  - Type of reconstruction (autologous vs. prosthetic)
  - Timing of reconstruction (immediate vs. delayed)
- *Oncological considerations:*
  - Tumor biology and oncological risk factors
  - Need for adjuvant therapy
- *Additional considerations:* Presence of pathology in the contralateral breast.

TYPES OF REDUCTION MAMMOPLASTY

Breast reconstruction techniques may involve either transplantation or transposition approaches, depending on the clinical scenario and reconstructive goals.

- *Transplantation technique:*
  - It involves amputation of the breast with free transplantation of the NAC.
  - It is used in very ptotic breast where a long pedicle may jeopardize the blood supply to the reconstructed nipple areolar complex.
- *Transposition technique:*
  - It involves removal of excess dermoglandular tissue.
  - It preserves the NAC on a vascularized pedicle, allowing safe repositioning and improved esthetic outcomes.

Surgical Margins in Breast Conservation

The surgical margin in BCS is assessed by applying ink to the surface of the lumpectomy specimen and determining the microscopic distance between the inked surface and tumor cells.



Figs. 25A and B: Comparison of an anterior intercostal artery perforator (AICAP) flap (A) and lateral intercostal artery perforator (LICAP) flap (B) which has a significant difference in their symmetry.

JAYPEE BROTHERS

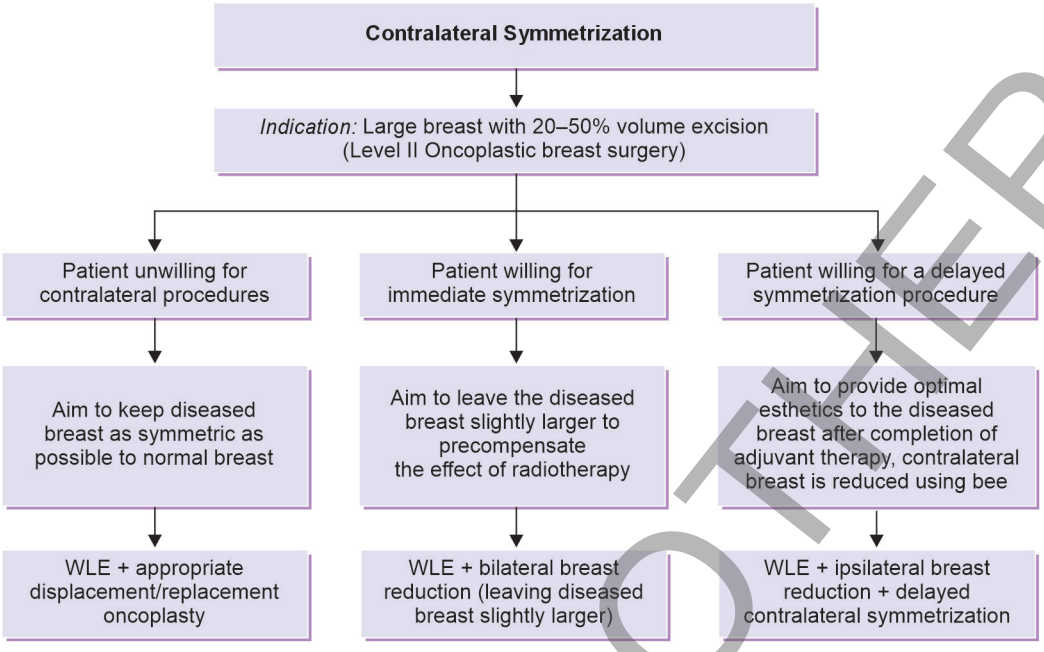

Algorithm 3: Contralateral symmetrization procedures. (WLE: wide local excision)

The 2013 Society of Surgical Oncology–American Society for Radiation Oncology (SSO–ASTRO) consensus guideline for invasive breast cancer defined a negative margin as *"no ink on tumor."* A positive margin is defined as the presence of invasive carcinoma or ductal carcinoma in situ (DCIS) at the inked margin and is associated with an increased risk of ipsilateral breast tumor recurrence.

For pure DCIS treated with BCS and whole-breast radiotherapy, a *2-mm margin* is considered the standard for an adequate negative margin. Margins wider than 2 mm have not shown additional benefit. DCIS with microinvasion (focus >1 mm) should be managed according to DCIS margin recommendations **(Table 10)**.

Re-excision is generally indicated for tumor cells on the inked margin and for DCIS margins <2 mm. However, re-excision is not required for LCIS present at the margin, as LCIS is considered a risk factor rather than a direct precursor lesion **(Figs. 26A to E and Algorithm 4)**.

TABLE 10: NCCN definition of margin positivity.

Condition	*No ink on tumor*	*2-mm margin*	*No margin necessary*
Invasive breast cancer	✓		
Invasive breast cancer + ductal carcinoma in situ (DCIS)	✓		
Invasive breast cancer + extensive DCIS	✓		
Invasive breast cancer [treated with neoadjuvant chemotherapy followed by breast-conserving surgery (BCT)]	✓		
Pure DCIS		✓	
DCIS with microinvasion		✓	
Classic lobular carcinoma in situ (LCIS) at surgical margin			✓
Atypia at surgical margin			✓

PREDICTORS OF POSITIVE MARGINS IN BREAST-CONSERVING SURGERY

Several clinicopathological factors are associated with an increased likelihood of positive margins after lumpectomy. These include:

- Extensive intraductal component.
- Multifocal disease.
- Presence of mammographic microcalcifications.
- Nonductal histology.
- Pathological nodal positivity.
- HER2-enriched subtype.
- Larger tumor size.
- Presence of associated DCIS.
- Caudal location of the lesion.

Ductal carcinoma in situ has been shown to have a higher rate of positive margins following lumpectomy compared with invasive breast cancer.

JAYPEE BROTHERS



Figs. 26A to E: (A to C) Inking of the specimen to evaluate the margins; (D) Note the margins are being put inside the cassettes; and (E) Histopathological evaluation of the inked surface (*Note:* The black ink).

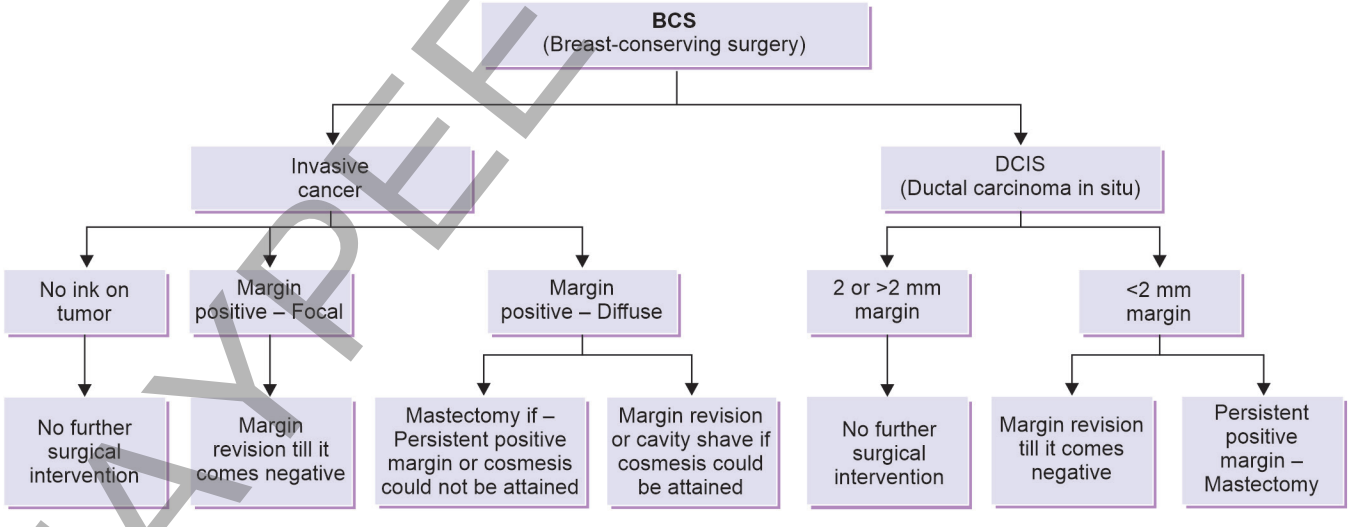

Algorithm 4: Margin in breast conservation.

JAYPEE BROTHERS

ASSESSMENT OF MARGINS IN BREAST-CONSERVING SURGERY

Preoperative Assessment

Preoperative imaging is essential for evaluating disease extent and planning surgery to achieve adequate margins.

- *Bilateral mammography* is the most commonly used imaging modality. It helps assess:
  - Tumor extent
  - Microcalcifications
  - Multifocality
  - Multicentricity
  - Contralateral breast lesions
- *Ultrasonography* is particularly useful to evaluate young women with dense breasts and mammographically detected masses at all ages.
- *MRI breast* is reserved for selected situations and problem solving. Although highly sensitive, MRI may increase biopsies and mastectomy rates without clear evidence of reducing re-excision rates or improving survival. They are also used for evaluating mammographically occult tumors and lobular cancers undergoing breast conservation.

Intraoperative Margin Assessment Techniques (Algorithm 5)

Specimen Radiography

Specimen mammography is one of the most widely used intraoperative techniques, especially for nonpalpable lesions. It confirms removal of the lesion and radiopaque markers with grossly clear margins. Proper orientation with orthogonal markers is important **(Figs. 27A and B)**.

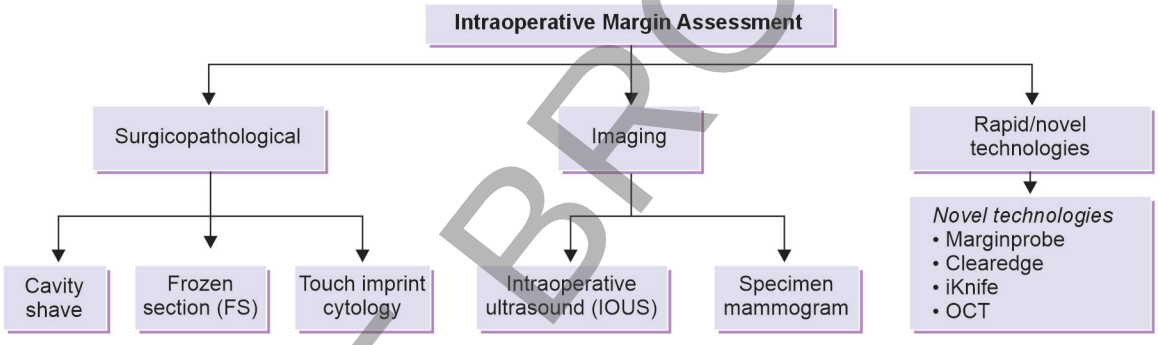

Algorithm 5: Assessment of margins in breast cancer during lumpectomy.

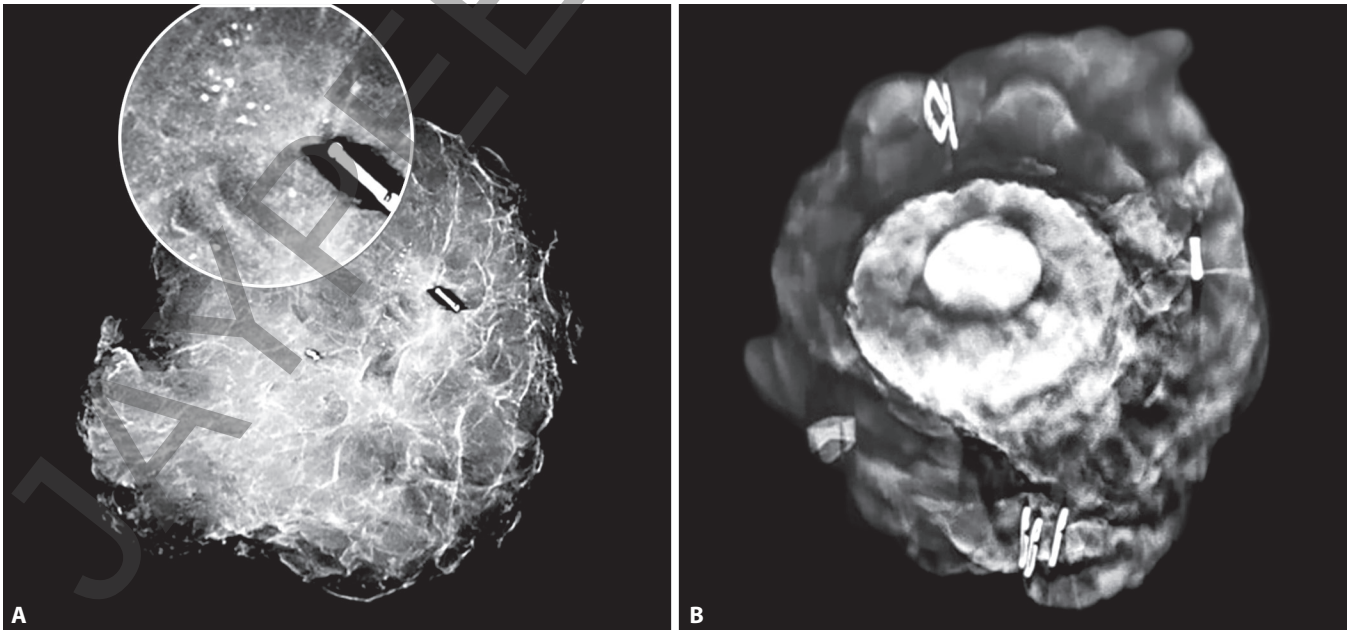

Figs. 27A and B: Specimen mammogram to evaluate the margins after lumpectomy.

JAYPEE BROTHERS

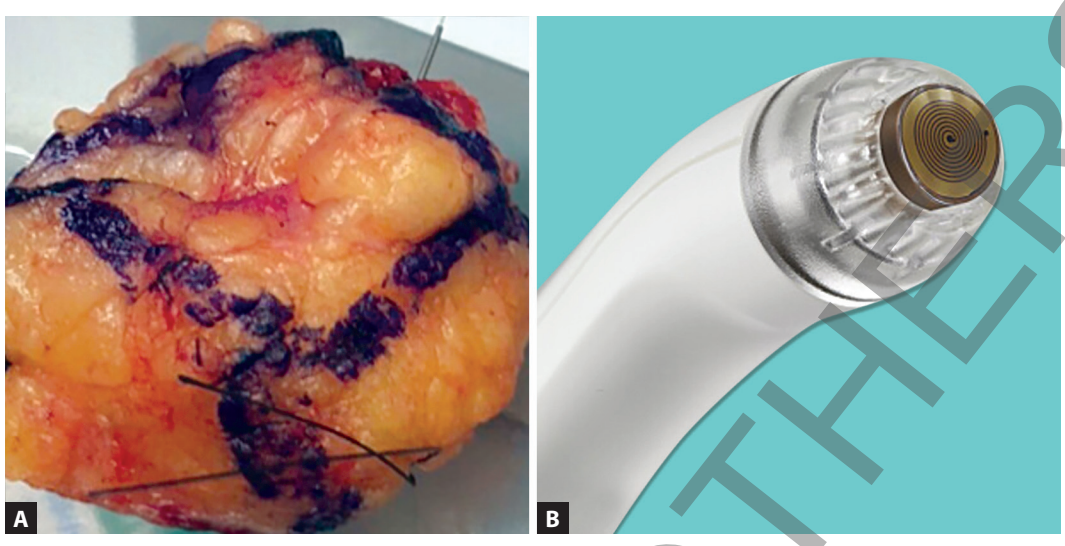

Figs. 28A and B: Margin probe. (A) Lumpectomy is divided into zones depending on the margin and (B) Tip of the probe.

Tomosynthesis

Digital breast tomosynthesis provides a three-dimensional assessment and may improve intraoperative margin evaluation compared with conventional specimen radiography.

Frozen Section Analysis and Imprint Cytology

Frozen section and imprint cytology allow intraoperative pathological evaluation of margins and facilitate immediate re-excision when necessary. However, assessment may be limited by fatty breast tissue and sampling errors.

Cavity Shave

Routine circumferential cavity shave excision significantly reduces positive margin and re-excision rates without major adverse cosmetic outcomes. This is especially useful in resource-constrained settings where frozen section facilities are unavailable. Orienting cavity shaves for the pathologist: It is important to mark the outer end of the cavity to orient them for the pathologist to avoid erroneous results.

Novel Technologies

Emerging techniques for intraoperative margin assessment include:

- MarginProbe **(Figs. 28A and B)**
- Lumicell fluorescence imaging
- Micro-CT
- Optical coherence tomography (OCT)
- Nonlinear microscopy
- Raman spectroscopy
- Intelligent knife (iKnife)
- Augmented imaging systems.

These technologies aim to improve real-time detection of residual tumor at the surgical margin.

VIDEO CONTENTS

Video 9.1: Algorithm for Early Breast Cancer.
Video 9.2: Basics of Oncoplasty.
Video 9.3: Level I Oncoplasty: Dual Plane Mobilization.
Video 9.4: Lateral/Racquet Mammaplasty.
Video 9.5: Crescent Mastopexy.
Video 9.6: Round Block Oncoplasty.
Video 9.7: Grissotti Mastopexy.
Video 9.8: Lateral Intercostal Artery Perforator Flap (LICAP).
Video 9.9: Anterior Intercostal Artery Perforator Flap (AICAP).
Video 9.10: Planning a Therapeutic Mammaplasty.

SUGGESTED READING

1. Audisio RA, Benson JR (Eds). ESSO Core Curriculum in Breast Surgery. Cham: Springer; 2021.
2. Audretsch W. Reconstruction of the partial mastectomy defect: classification and method. In: Spear SL (Ed). Surgery

JAYPEE BROTHERS

of the Breast: Principles and Art. Philadelphia: Lippincott-Raven; 1998. pp. 155-96.
3. Clough KB, Kaufman GJ, Nos C, Buccimazza I, Sarfati IM. Improving breast cancer surgery. Ann Surg Oncol. 2010;17(5):1375-91.
4. Clough KB, Kaufman GJ, Nos C, Buccimazza I, Sarfati IM. Oncoplastic surgery: pushing the limits of breast-conserving surgery. Breast J. 2015;21(2):140-6.
5. Clough KB, Lewis JS, Couturaud B, Fitoussi A, Nos C, Falcou MC. Oncoplastic techniques allow extensive resections for breast-conserving therapy. Ann Surg. 2003;237(1):26-34.
6. Deo SVS (Ed). Breast Oncoplasty and Reconstruction. Singapore: Springer Nature Singapore; 2023.
7. DeVita VT Jr, Lawrence TS, Rosenberg SA (Eds). DeVita, Hellman, and Rosenberg's Cancer: Principles and Practice of Oncology, 12th edition. Philadelphia: Wolters Kluwer; 2023.
8. Fisher B, Anderson S, Bryant J, Margolese RG, Deutsch M, Fisher ER, et al. Twenty-year follow-up of a randomized trial comparing total mastectomy, lumpectomy, and lumpectomy plus irradiation. N Engl J Med. 2002;347(16):1233-41.
9. Fisher B, Dignam J, Wolmark N, Mamounas E, Costantino J, Poller W, et al. Lumpectomy and radiation therapy for intraductal breast cancer. J Clin Oncol. 1998;16(2):441-52.
10. Fitoussi AD, Berry MG, Fama F, Falcou MC, Curnier A, Couturaud B, et al. Oncoplastic breast surgery for cancer: analysis of 540 consecutive cases. Plast Reconstr Surg. 2010;125(2):454-62.
11. Hamdi M (Ed). Pedicled Perforator Flaps in Breast Reconstruction. Cham: Springer; 2017.
12. Hamdi M, Van Landuyt K, de Frene B, Roche N, Blondeel P, Monstrey S. The versatility of the intercostal artery perforator flap in partial breast reconstruction. Br J Plast Surg. 2004;57(2):114-20.
13. Jacobson JA, Danforth DN, Cowan KH, d'Angelo T, Steinberg SM, Pierce L, et al. Ten-year results of a comparison of conservation with mastectomy. N Engl J Med. 1995;332(14):907-11.
14. Losken A, Dugal CS, Styblo TM, Carlson GW. A meta-analysis comparing breast conservation therapy alone. Ann Plast Surg. 2014;72(2):145-9.
15. McCulley SJ, Macmillan RD. Therapeutic mammaplasty—analysis of 50 consecutive cases. Br J Plast Surg. 2005;58(7):902-7.
16. Urban C, Rietjens M (Eds). Oncoplastic and Reconstructive Surgery of the Breast. Milan: Springer; 2013.
17. Veronesi U, Cascinelli N, Mariani L, Greco M, Saccozzi R, Luini A, et al. Twenty-year follow-up of a randomized study comparing breast-conserving surgery with radical mastectomy. N Engl J Med. 2002;347(16):1227-32.

JAYPEE BROTHERS

CHAPTER 32

Carcinoma Rectum: Evolution of the Paradigm Shift in the Management

INTRODUCTION

Colorectal cancer is the third most common cancer worldwide and the second leading cause of cancer-related mortality. Although India has traditionally had a lower incidence, the burden is steadily increasing, driven by Westernized dietary patterns, obesity, sedentary lifestyles, and other environmental factors. Notably, there is a paradigm shift toward younger age at presentation, with an increasing proportion of patients being diagnosed before 45 years of age; however, the underlying reasons for this trend remain unclear.

SURGICAL ANATOMY OF THE RECTUM

The rectum is the distal-most portion of the hindgut, extending from the sigmoid colon to the anal canal. The rectosigmoid junction is marked by splaying of the taeniae coli and absence of epiploic appendages at approximately S3, while the anorectal ring marks the distal transition. The anal canal measures 2–4 cm; the lower rectum 3–6 cm, mid rectum 5–6 to 8–10 cm, and upper rectum 8–10 to 12–15 cm from the anal verge. The dentate line, approximately 2 cm above the anal verge, is an important lymphatic landmark; tumors below it may drain to the inguinal and external iliac nodes. The rectum is predominantly extraperitoneal, with the upper third covered by visceral peritoneum. The peritoneal reflection, readily identified on MRI, is an important surgical landmark.

Mesorectum

The mesorectum is a cone-shaped, mesentery-like envelope of perirectal fat, lymphatics, lymph nodes, blood vessels, and autonomic nerves, enclosed by the visceral endopelvic fascia (fascia propria). It is separated from the parietal pelvic fascia by loose areolar tissue, creating a relatively avascular plane described by Heald as the "Holy Plane," which forms the fundamental plane of dissection during total mesorectal excision (TME). Posteriorly, the parietal pelvic fascia overlying the presacral veins, hypogastric nerves, and sacrum forms the presacral fascia; at S3–S4, it gives rise to the retrosacral (Waldeyer) fascia, which fuses with the fascia propria approximately 3–5 cm above the anorectal junction. Anteriorly, Denonvilliers fascia separates the rectum from the genitourinary organs, extending from the perineal body to the inferior aspect of the peritoneal reflection; in men, it overlies the seminal vesicles and prostate, while in women, it contributes to the rectovaginal septum. The cavernous nerves course along its anterolateral aspect and must be preserved during nerve-sparing surgery. Laterally, the rectum is attached to the pelvic sidewall by lateral stalks, which may contain the middle rectal vessels and branches of the inferior hypogastric plexus and are therefore important during TME and lateral pelvic dissection **(Figs. 1A to D)**.

Vascular Supply

The principal arterial supply of the rectum is through the superior rectal artery (SRA), the terminal continuation of the inferior mesenteric artery (IMA). The distal rectum receives additional supply from the middle rectal arteries, small branches of the internal iliac arteries, and the inferior rectal arteries, branches of the internal pudendal arteries. The middle rectal artery is highly variable, being identified in approximately 28–57% of individuals and is frequently unilateral. This anatomical variability is important during TME and lateral pelvic dissection, where the middle rectal vessels may be encountered within the lateral attachments of the mesorectum. The inferior rectal artery arises from the internal pudendal artery; the term "pudendal" refers to the perineal region, reflecting the distribution of this vascular territory. The superior rectal veins drain into the inferior mesenteric vein (IMV) and then the portal circulation, while the middle and inferior rectal veins drain into the internal iliac veins and the systemic circulation. This dual venous drainage explains the differing patterns of hematogenous spread from proximal and distal rectal tumors **(Fig. 2A)**.

JAYPEE BROTHERS

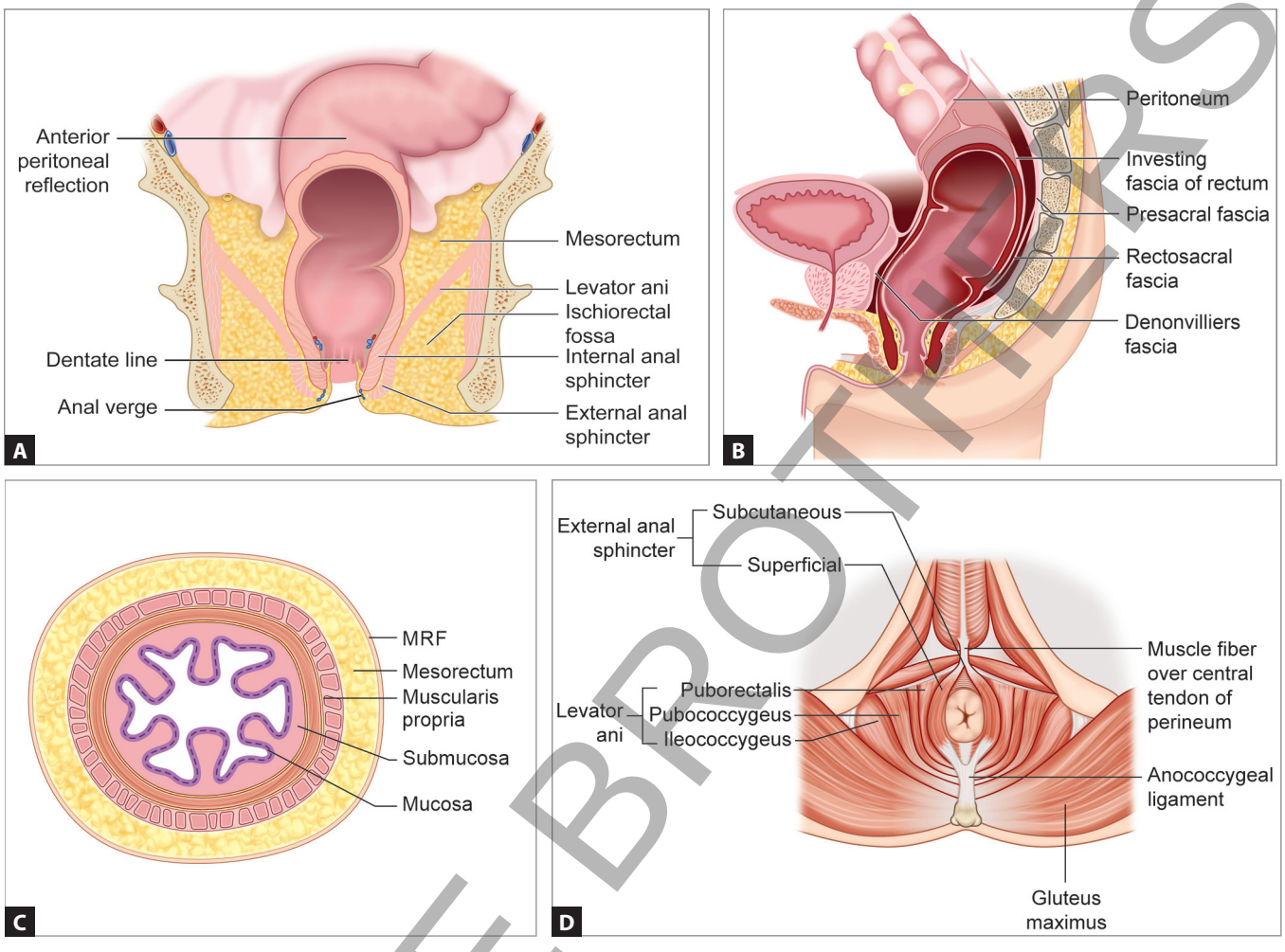

Figs. 1A to D: (A) Surgical anatomy of the rectum; (B) Fascial relations of the rectum; (C) Mesorectum; and (D) Anatomy of the pelvic floor muscles. (MRF: mesorectal fascia)

Lymphatic Drainage

The lymphatic drainage of the rectum follows two pathways, longitudinal and lateral pathways.

- The proximal two-thirds drain predominantly along the superior rectal vessels toward the superior rectal and inferior mesenteric lymph nodes, with subsequent drainage toward the para-aortic nodal chain.
- The distal third retains drainage superiorly toward the superior rectal nodes but also has an important lateral lymphatic pathway toward the internal iliac and pelvic sidewall nodes.

This dual drainage pattern has major implications for the management of low rectal cancer, particularly in patients with suspected lateral pelvic lymph node (LPLN) involvement **(Figs. 2B and C)**.

Autonomic Innervation

The autonomic innervation of the rectum consists of sympathetic and parasympathetic components and is critical for preserving urinary and sexual function during rectal surgery.

- Sympathetic fibers arise from the superior hypogastric plexus, continue as the hypogastric nerves, and join the inferior hypogastric plexus before supplying the rectum and pelvic organs. They are particularly vulnerable during dissection around the IMA and posterior rectal plane; injury may cause ejaculatory dysfunction, urinary frequency, incontinence, and postmicturition dribbling.
- The parasympathetic supply arises from the S2–S4 pelvic splanchnic nerves (nervi erigentes) and reaches

JAYPEE BROTHERS

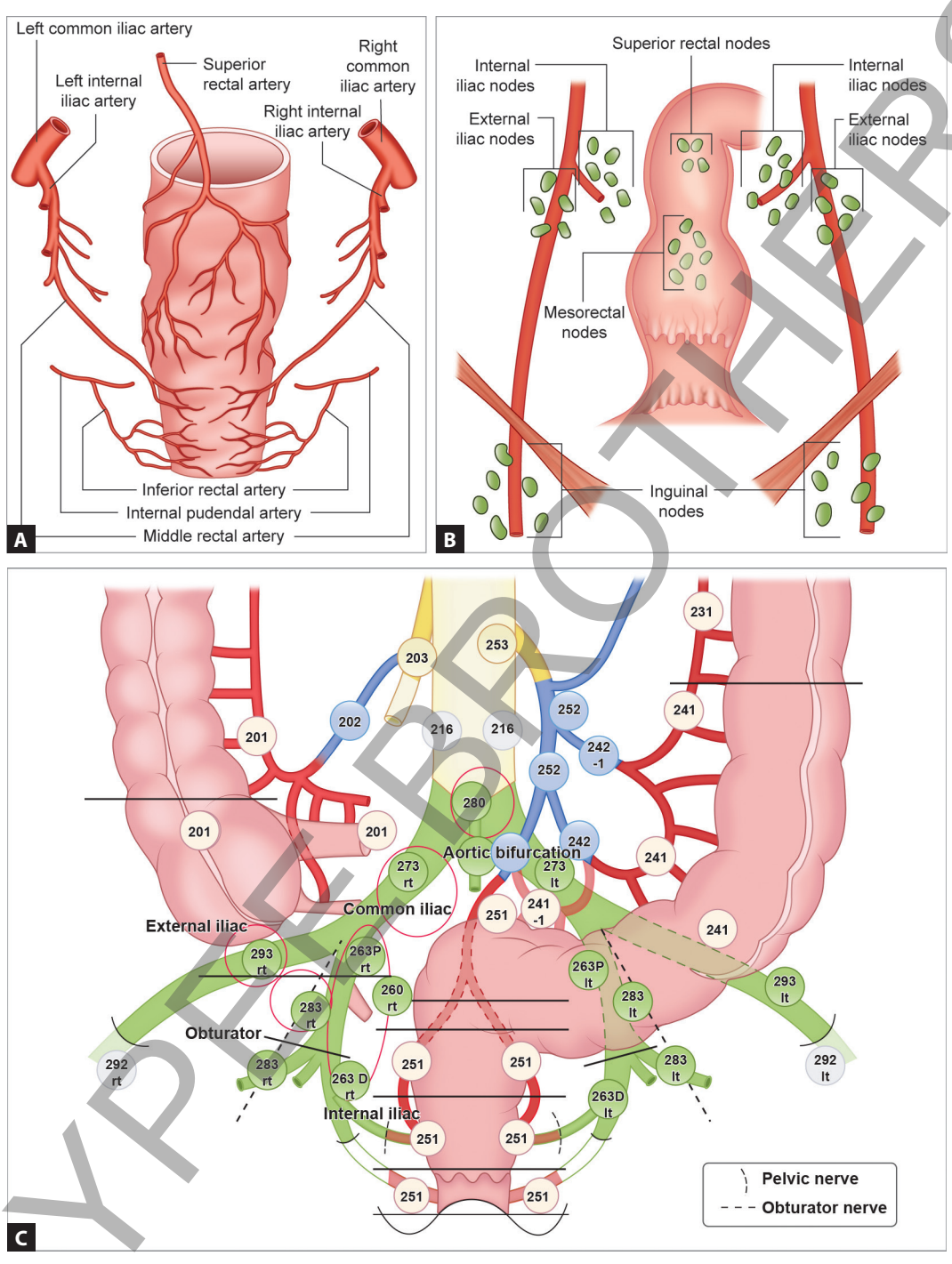

Figs. 2A to C: (A) Arterial supply of the rectum; (B) Lymphatic drainage of the rectum and the anal canal; and (C) Japanese classification of lymph node stations for rectal cancer.

JAYPEE BROTHERS

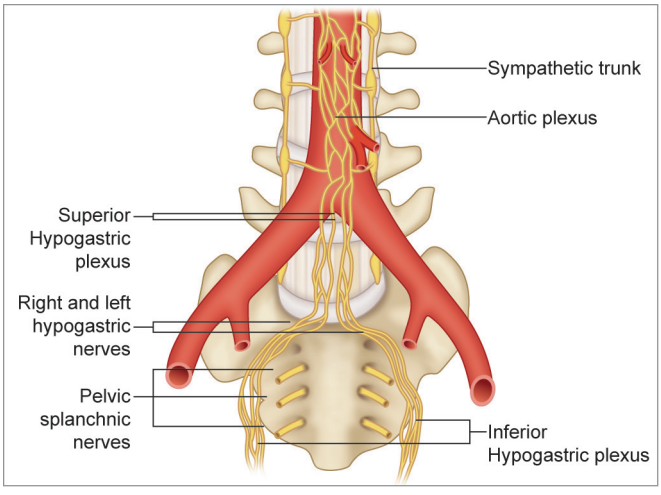

Fig. 3: Autonomic innervation of the rectum.

TABLE 1: Differences between rectal and anal cancer (anatomical and therapeutical).

	Rectal cancer	*Anal cancer*
Location	Above the dentate line	Below the dentate line
Histology	Adenocarcinoma	Squamous cell carcinoma
Feeding vessel	Inferior mesenteric vessels	Pudendal vessels
Lymphatic spread	Internal mesenteric nodes	Inguinal nodes
Primary treatment Modality	Neoadjuvant chemoradiation + surgery	Definitive chemoradiation

the rectum through the inferior hypogastric plexus. These nerves are particularly at risk during dissection around the lateral stalks and seminal vesicles; injury may result in urinary retention and erectile dysfunction, while in women it may cause reduced vaginal lubrication **(Fig. 3 and Table 1)**.

CLINICAL PRESENTATION

Rectal cancer may mimic benign anorectal conditions such as hemorrhoids, resulting in delayed diagnosis. Bleeding per rectum is the most common presentation and is usually painless. Upper rectal tumors commonly present with bleeding, altered bowel habits, constipation, and features of partial obstruction, whereas low rectal tumors more often cause urgency, tenesmus, incomplete evacuation, painful defecation, and fecal incontinence due to sphincter involvement. Tenesmus is characterized by a persistent urge to defecate despite inability to pass stool and is particularly common with low rectal tumors. Large or circumferential tumors may cause partial or complete obstruction, presenting with abdominal colicky pain, bloating, constipation, and distension. Weight loss, weakness, fatigue, and iron-deficiency anemia are important constitutional or alarm features. Locally advanced tumors involving the pelvic sidewall or nerves may produce pelvic or lower back pain, urinary dysfunction, erectile dysfunction, or retrograde ejaculation. Advanced disease may rarely present with jaundice from liver metastases, ascites, or peritonitis following tumor perforation.

EVALUATION

- *History:* A detailed personal and family history should be obtained, with particular attention to a history suggestive of hereditary colorectal cancer syndromes such as familial adenomatous polyposis (FAP) and hereditary nonpolyposis colorectal cancer (HNPCC/Lynch syndrome). A significant family history should prompt genetic counseling and appropriate germline testing.
- *Digital rectal examination:* It is an essential component of the initial evaluation and provides information regarding the presence, location, mobility, circumferential involvement, and relationship of the tumor to the anal sphincter. High rectal and rectosigmoid tumors may not be palpable. Rigid proctoscopy or sigmoidoscopy allows accurate assessment of the lower rectum, usually up to approximately 15 cm, and precise measurement of the tumor from the anal verge, which is important for surgical planning and assessment of sphincter preservation **(Algorithm 1)**.
- *Biopsy:* Histological confirmation should be obtained by endoscopic biopsy. Low rectal lesions can be biopsied during proctoscopy or rigid sigmoidoscopy, whereas upper rectal lesions are generally sampled during colonoscopy. Any additional suspicious lesion elsewhere in the colon should also be biopsied.
- *Blood investigations:* Baseline investigations should include complete blood count, renal function tests, liver function tests, and serum tumor markers, particularly carcinoembryonic antigen (CEA). Tumor-marker

JAYPEE BROTHERS

levels should ideally be obtained before treatment and during postoperative surveillance. A subsequent rise in a previously normalized CEA level may suggest disease recurrence, while markedly elevated levels may be associated with advanced or metastatic disease.

- *Colonoscopy:* Complete full-length colonoscopy is recommended to identify synchronous colorectal neoplasms and adenomatous polyps. Synchronous malignancies occur in approximately 2–6% of patients, while synchronous adenomatous polyps are more common. If colonoscopy is incomplete because of tumor-related obstruction, it should be completed after treatment, typically within 6 months after surgery, to exclude occult synchronous lesions **(Figs. 4A and B, Video 32.1)**.
- *Radiological evaluation:* The essential imaging investigations for rectal cancer include a high-resolution pelvic MRI for local staging and contrast-enhanced CT (CECT) of the chest, abdomen, and pelvis. Endoscopic ultrasound may be used when MRI is not possible or to evaluate early rectal cancer. CT is primarily used for assessment of distant metastatic disease. CT of the chest is preferred over chest radiography because of its superior sensitivity for detecting pulmonary metastases. Fluorodeoxyglucose positron emission tomography–computed tomography (FDG PET-CT) is not routinely required for initial staging but may be useful in known metastatic disease, particularly when potentially resectable or oligometastatic disease is being considered, to identify occult metastatic sites and aid treatment planning.

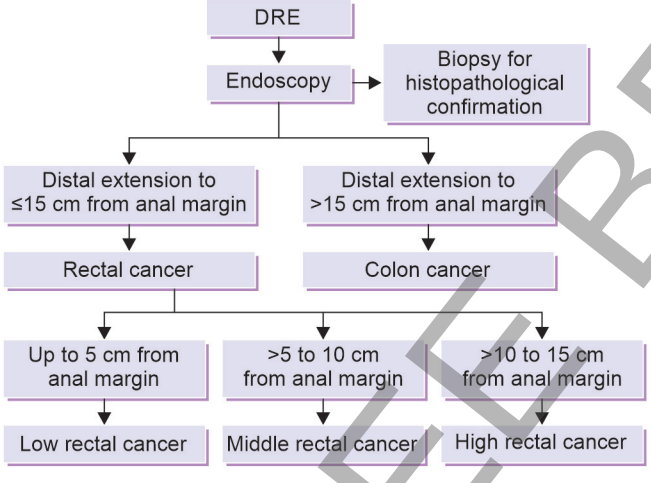

Algorithm 1: Definition of rectal cancer.

MRI PELVIS FOR RECTAL CANCER

High-resolution pelvic MRI is the investigation of choice for local staging of rectal cancer because of its superior soft-tissue contrast and ability to accurately assess tumor depth, mesorectal fascia (MRF), extramural vascular invasion, and regional lymph nodes. The MERCURY study demonstrated that MRI could predict the extent of local tumor spread with an accuracy of approximately 0.5 mm, with 92% specificity for predicting a clear circumferential resection margin (CRM). The MRI-based T stage is designated by the prefix "mr" (e.g., mrT3), while after neoadjuvant therapy, the prefix "ymr" is used to denote the posttreatment MRI stage (e.g., ymrT3; **Video 32.2**).

Planning for MRI Pelvis

- *Patient preparation:* Rectal gel and spasmolytics are not routinely required; spasmolytics may reduce motion artefacts.

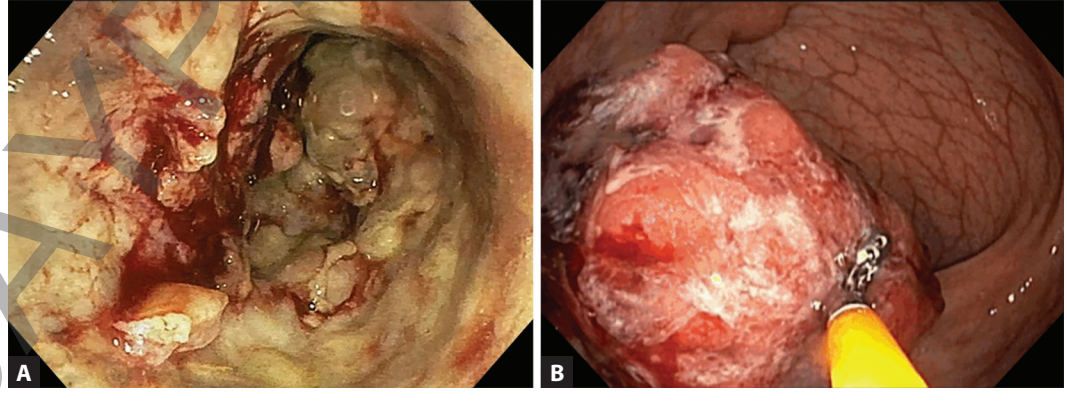

Figs. 4A and B: Colonoscopic image of the rectum. (A) Ulceroproliferattive lesion of the rectum and (B) Colonoscopic biopsy being taken from the lesion.

JAYPEE BROTHERS

- Perform T2-weighted, non-contrast MRI on a 1.5-T or 3-T scanner using an external surface coil, an endorectal coil is not routinely required.
- Obtain axial images perpendicular to the long axis of the rectum to assess extramural tumor spread and MRF involvement.
- High-resolution 2D T2-weighted imaging is the key sequence for T staging and assessment of pathological lymph nodes, with a 1–3 mm slice thickness (≤4 mm acceptable). Axial, sagittal, and coronal planes should be obtained to assess tumor extent and its relationship to surrounding structures, with axial/coronal images angulated perpendicular and parallel to the tumor axis for mid and upper rectal tumors, and along the anal canal axis for low rectal tumors.
- T1-weighted imaging without contrast, diffusion-weighted imaging (DWI), and contrast-enhanced T1-weighted imaging are not routinely required for primary staging; however, T1-weighted imaging may help assess other pelvic pathology, while DWI is useful for evaluating treatment response and yT staging after neoadjuvant therapy.

MRI Assessment in Rectal Cancer (Table 2)

Preneoadjuvant MRI

Baseline pelvic MRI should systematically document the distance from the anal verge or anorectal junction to the lower tumor margin, tumor length, mrT and mrN stage, tumor deposits, and mesorectal fascia status. MRF assessment should include the minimum tumor-to-MRF distance in millimeters and the site of closest approach. The report should also identify suspicious extramesorectal lymph nodes, extramural venous invasion (EMVI), circumferential tumor location, and the depth of extramural invasion in T3 tumors.

Postneoadjuvant MRI

Restaging MRI assesses tumor response and residual disease and should document the distance from the anal verge or anorectal junction to the residual tumor, residual tumor length, and ymrT and ymrN stage. The report should distinguish viable tumor, typically showing intermediate-to-high T2 signal, from fibrosis, which demonstrates low T2 signal. It should document residual mesorectal tumor deposits, suspicious lymph nodes, extramesorectal nodes, persistent or regressed MRF involvement, and the minimum residual tumor-to-MRF distance. The report may additionally describe circumferential tumor location, depth of extramural extension in yT3 disease, residual tumor morphology, and EMVI.

TABLE 2: Rectal cancer—structured MRI reporting template **(Figs. 5A to C)**.

Parameter	*MRI assessment*
Location	• *Lower tumor border:* Distance from the anorectal junction or anal verge. • Relation to the lower border of the pelvic floor • Relation to the anterior peritoneal reflection
Size	Tumor length
cT-category	• *cT1–cT2:* Confined to the rectal wall • *cT3:* Extending beyond the rectal wall to the mesorectal fat (T3a: <1 mm, T3b: 1–5 mm, T3c: 5–15 mm, T3d: >15 mm) • *cT4a:* Invasion of the peritoneum or peritoneal reflection • *cT4b:* Invasion of adjacent organs or structures
Extramural venous invasion (EMVI)	*EMVI–:* No involved vessels in the vicinity of the tumor *EMVI+:* Tumor signal extending into or disrupting a vessel
Sphincter invasion	Document involvement of the *internal sphincter, intersphincteric space, and external sphincter*, including the *side and location/ clockface position* of involvement
Mesorectal fascia (MRF)	*No:* >1 mm margin *Yes:* ≤1 mm margin from the primary tumor, EMVI, irregular lymph node, and tumor deposit
cN-category	Assess regional lymph nodes and tumor deposits in the mesorectum, obturator region, and internal iliac region • *cN0:* No suspicious lymph nodes or tumor deposits • *cN1:* ≤1 suspicious lymph node or tumor deposit <5 mm nodes are generally not positive unless they are 3 or more in number. 5–9 mm nodes must be 2 or more in number. A single node > 9 mm is considered positive.
Pelvic metastases (cM)	• Presence of any nonregional suspicious lymph nodes, such as inguinal nodes • Presence of distant metastases within the pelvis, e.g., bone or peritoneal metastases

JAYPEE BROTHERS

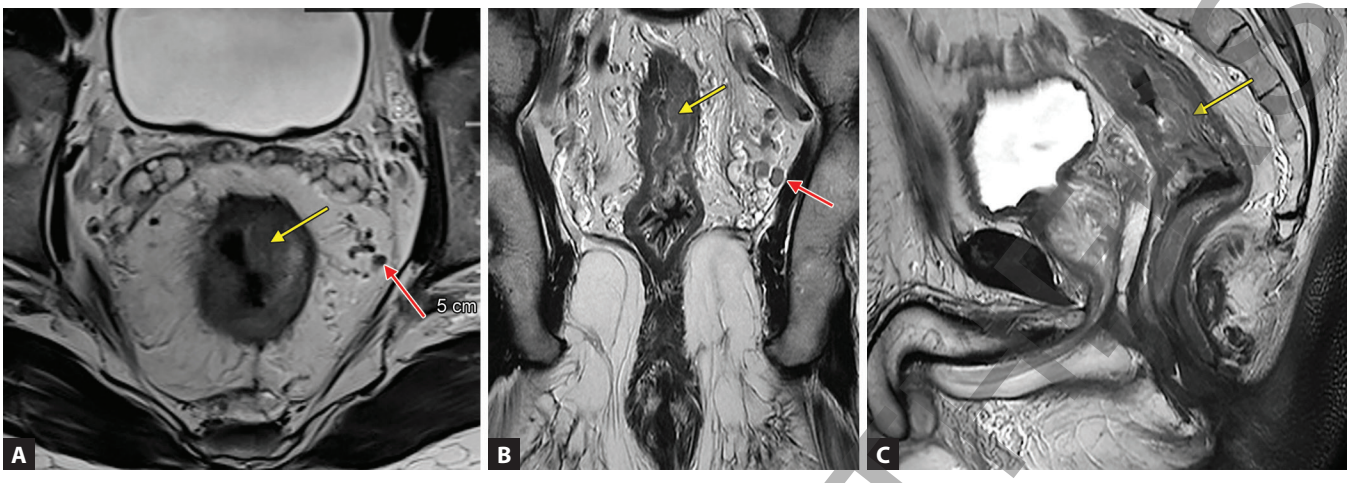

Figs. 5A to C: Rectal MRI (T2WI sequences). (A) Axial, note the seminal vesicles anteriorly and a rectal mass at 2 o'clock; (B) Coronal showing the rectal mass, note the sphincters and the levator muscle; and (C) Sagittal cuts showing a large tumor occluding the lumen (tumor: yellow arrow; nodes: red arrow).

Role in Surgical Planning

MRI findings directly influence the surgical strategy, particularly assessment of the MRF, pelvic sidewall, anal sphincter, intersphincteric plane, and adjacent pelvic organs. These findings help determine suitability for sphincter-preserving surgery. The landmark trials of MRI in rectal cancer have been summarized in **Table 3**.

TABLE 3: MERCURY trials in relation to MRI and rectal cancer.

Trial	*Conclusions*
MERCURY trial	MERCURY established that high-resolution pelvic MRI accurately predicts the circumferential resection margin (CRM), thus supporting a risk-based stratification for neoadjuvant therapy and surgical planning. • MRI-clear CRM (>1 mm from the mesorectal fascia) identifies low-risk patients with better outcomes (5-year OS 62.2% vs. 42.2%) • Threatened/involved CRM (≤1 mm) indicates high-risk disease.
Low rectal cancer study (MERCURY II)	The primary aims of the low rectal cancer study (MERCURY II) are to assess the rate of CRM positivity rate in low rectal cancer and to assess the difference in quality of life at 2 years postsurgery in patients according to plane of surgery with or without sphincter preservation.

ENDORECTAL ULTRASOUND

Endorectal ultrasound (EUS) provides high-resolution assessment of the rectal wall, which demonstrates alternating echogenic and hypoechoic layers: Mucosa (echogenic), muscularis mucosae (hypoechoic), submucosa (echogenic), muscularis propria (hypoechoic), and serosa/perirectal fat (echogenic). The prefix "u" is used to denote ultrasound-based staging (e.g., uT3). Conventional probes operate at 7–10 MHz, while high-resolution probes use 10–23 MHz; contrast microbubbles may further enhance image quality. EUS also permits assessment of mesorectal lymph nodes, with the possibility of fine-needle aspiration cytology (FNAC) when indicated.

The major limitations of EUS are operator dependence, variable training and expertise, and limited assessment of structures beyond the immediate tumor vicinity. In particular, the MRF and pelvic sidewalls, which are crucial for surgical planning, are often inadequately visualized. A 2004 meta-analysis demonstrated broadly comparable sensitivity and specificity of EUS and MRI for lymph-node staging; however, EUS has limitations in bulky tumors and large lymph nodes and is not sufficiently comprehensive for complete local staging. Therefore, MRI remains the preferred modality for rectal cancer staging, with EUS generally reserved for selected cases, particularly when MRI is contraindicated or when detailed assessment of early T-stage disease is required **(Fig. 6 and Box 1)**.

JAYPEE BROTHERS

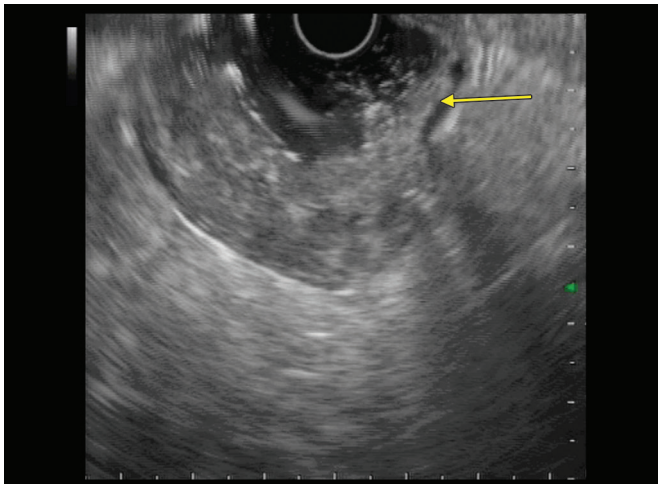

Fig. 6: Endorectal ultrasound evaluating a rectal mass and its depth (T stage).

BOX 1: Controversies and consensus (MRI versus EUS).

- MRI cannot differentiate between T1 and T2 cancers, and EUS is used to confirm T1N0 disease).
- *MRI:* Preferred modality for rectal cancer staging, particularly for T stage, circumferential resection margin (CRM), mesorectal fascia, extramural spread, and tumor deposits; sensitivity and specificity for lymph-node involvement are 66% and 76%, respectively.
- *EUS:* Mainly useful for superficial/early lesions or when MRI is contraindicated/inconclusive; sensitivity and specificity for lymph-node involvement are 67% and 78%, respectively, but it is operator-dependent and limited in bulky or advanced tumors.

STAGING

The AJCC 8th edition staging for rectal cancer is similar to colon cancer and can be found in the previous chapter.

MANAGEMENT OF RECTAL CANCER

Management begins with CEA, colonoscopy with biopsy, and microsatellite instability (MSI) assessment, followed by pelvic MRI/ERUS and CT of the thorax and abdomen for staging. Early rectal cancer is managed according to stage and risk: Selected T1N0 lesions may undergo transanal surgery, with completion transabdominal resection if the excision is incomplete; T1–T2N0 and selected low-risk T3N0 upper rectal cancers undergo transabdominal surgery, followed by observation in the absence of high-risk features or 6 months of adjuvant therapy when high-risk features are present. Locally advanced rectal cancer (LARC; T2–T4, N+, EMVI-positive, or MRF-positive) is treated with neoadjuvant therapy, preferably neoadjuvant chemoradiotherapy, followed by restaging, definitive

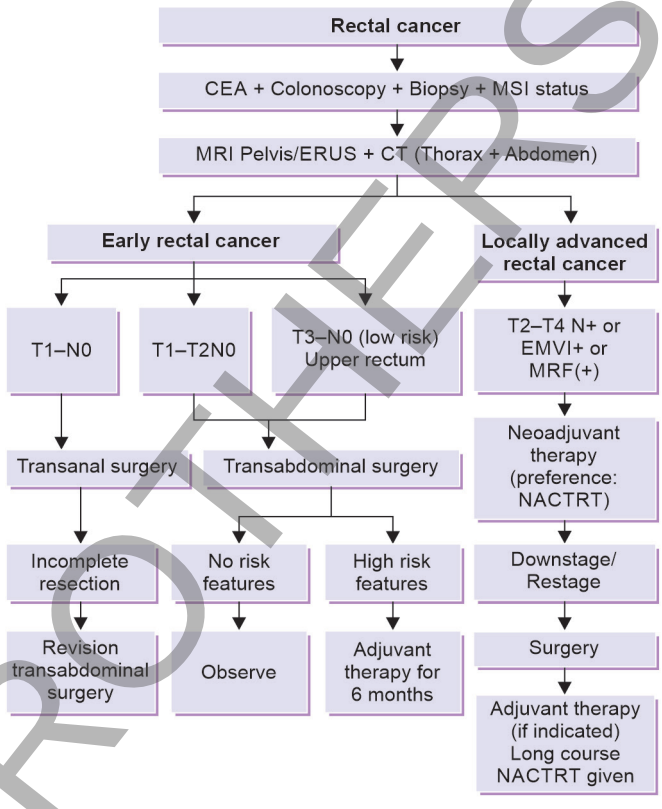

Algorithm 2: Management of rectal cancer.

surgery, and adjuvant therapy when indicated; patients receiving long-course neoadjuvant chemoradiotherapy may not require additional postoperative chemoradiation **(Algorithm 2)**.

EARLY RECTAL CANCER

Transanal Excision

Transanal excision encompasses conventional transanal local excision (TLE), transanal endoscopic microsurgery (TEM), transanal minimally invasive surgery (TAMIS), and transanal single-port robotic excision. It is primarily used for carefully selected precancerous lesions and low-risk early rectal cancers, particularly cT1N0 lesions, as well as for obtaining definitive pathology when clinical and pathological findings are discordant. Patients with clinical evidence of lymph-node metastasis are not suitable for local excision because the procedure does not include intentional lymphadenectomy. The fundamental principle is full-thickness excision of the tumor with clear margins, extending to the perirectal fat without further dissection **(Figs. 7A to E)**.

- Conventional transanal excision is best suited to distal rectal lesions, as exposure of mid- and proximal-rectal

JAYPEE BROTHERS

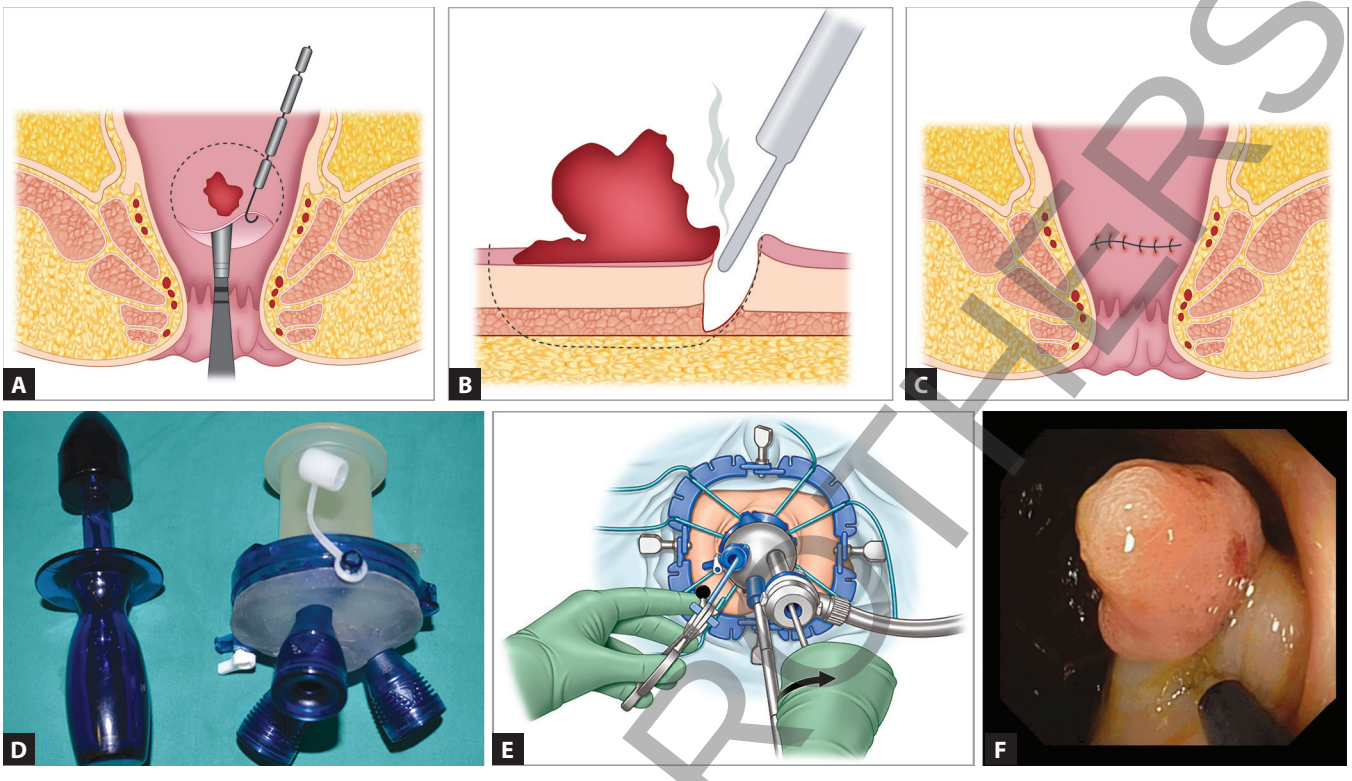

Figs. 7A to F: Transanal excision. (A to C) Conceptual image of transanal resection with circumferential resection along the tumor and transversely closing the defect; (D) Gel port for TAMIS; (E) Conceptual image of transanal excision of rectal tumor for early rectal tumor; and (F) Advanced endoscopic resection of a polypoid rectal tumor.

lesions is technically difficult. After digital examination and rectal irrigation, the anal canal is dilated and the lesion exposed using retraction sutures or rectoscopes. For mucosal lesions, submucosal injection may facilitate excision. The tumor is removed with at least a 0.5-cm macroscopic margin, the specimen is pinned and oriented for pathological assessment, and the full-thickness defect is generally closed transversely.

- TEM was developed to overcome the limited visualization and reach of TLE. It uses a dedicated approximately 4-cm rigid rectoscope with CO_2 pneumorectum and specialized laparoscopic instruments, providing magnified visualization and enabling precise excision of more proximal rectal lesions. Full-thickness proximal lesions require particular care because of the risk of peritoneal entry, while very distal lesions may be technically difficult because TEM requires adequate insufflation.
- TAMIS follows the principles of TEM but uses a single-use transanal access platform rather than a dedicated rigid rectoscope, allowing laparoscopic instruments to be introduced through the port. It provides greater flexibility and four-quadrant access. Transanal single-port robotic excision further adapts this approach using a robotic platform, providing enhanced visualization and instrument articulation for endoluminal rectal surgery **(Box 2)**.

BOX 2: Selection criteria for local excision.

Local excision may be considered in carefully selected early rectal cancers, particularly T1 lesions, when all favorable criteria are fulfilled:

- Tumor should be well differentiated and preferably small, typically <3 cm in size.
- Tumor should involve <30% of the rectal circumference and be located within 8 cm of the anal verge.
- A clear margin of >3 mm should be achievable.
- The lesion should be limited to T1 disease, with no lymphovascular invasion (LVI) or perineural invasion (PNI).
- There should be no radiological evidence of regional lymph-node metastasis.
- The practical "rule of 3s" is: <3 cm tumor, <30% circumference involvement, and >3 mm resection margin.

JAYPEE BROTHERS

Advanced Endoscopy

Advanced endoscopic techniques include endoscopic mucosal resection (EMR), endoscopic submucosal dissection (ESD), and hybrid ESD. EMR involves submucosal lifting followed by snare resection, whereas ESD enables precise submucosal dissection and en-bloc removal, hybrid ESD combines peripheral ESD with snare resection of the remaining lesion. These techniques are primarily used for mucosal and superficial submucosal lesions while preserving the rectal wall **(Fig. 7F)**.

LOCALLY ADVANCED RECTAL CANCER: A PARADIGM SHIFT TO TOTAL NEOADJUVANT THERAPY

The standard approach for LARCs has traditionally been neoadjuvant chemoradiotherapy (NACTRT) followed by surgery and systemic chemotherapy. Upper rectal cancers or rectosigmoid junction cancer are treated with upfront surgery and adjuvant therapy as required. Preoperative chemoradiotherapy provides significant tumor downstaging and improved local control, although a clear overall survival benefit has not been demonstrated. However, selected T3a/T3b tumors with a clear CRM and lymph nodes not threatening the CRM may be considered for upfront surgery because of their relatively low risk of local recurrence, although this approach remains controversial. Short-course radiotherapy (SCRT) may be preferred in selected patients. The introduction of TME, with meticulous dissection along the MRF and complete removal of the mesorectum, has substantially reduced local recurrence rates. The conventional sequence for LARC is NACTRT followed by an 8–12-week interval and then surgery. In patients with persistent CRM involvement on post-NACTRT MRI, additional systemic chemotherapy with FOLFOX or CAPOX for 12–16 weeks may be administered before surgery, followed by postoperative adjuvant chemotherapy where indicated. Nevertheless, distant metastasis remained a major cause of treatment failure, and patients who developed postoperative complications frequently experienced delays in or failed to receive adjuvant chemotherapy. These limitations led to a major paradigm shift toward total neoadjuvant therapy (TNT), in which both systemic chemotherapy and radiotherapy are delivered entirely in the preoperative period. TNT improves chemotherapy compliance, disease-free survival, pathological complete response (pCR), and clinical complete response (cCR).

TABLE 4: Differences between high- and low-risk rectal cancer.

Low-risk features	*High-risk features* **(Figs. 8A to C)**
≤cT3	>cT3
cN0–2 without lateral nodal involvement	cN+ and/or lateral node involvement
CRM–	CRM+ or threatened CRM
EMVI–	EMVI+

Furthermore, this approach has created an opportunity for organ preservation through watch-and-wait management in appropriately selected patients **(Table 4)**.

NEOADJUVANT RADIATION IN RECTAL CANCER

Preoperative radiotherapy is generally considered for cT3+ or cN-positive rectal cancers, particularly when there is an increased risk of local recurrence or a threatened CRM.

Rationale of preoperative radiotherapy: The primary objective is to reduce local recurrence and improve local control. It may also sterilize or downstage involved lymph nodes, improve tumor resectability, increase the likelihood of a negative radial margin (CRM), and reduce treatment-related morbidity compared with postoperative radiotherapy. However, in the setting of high-quality TME surgery, preoperative radiotherapy does not consistently confer an overall survival advantage. Landmark evidence for long course radiation (preoperative versus postoperative) is summarized here:

German Rectal Cancer Trial (CAO/ARO/AIO-94): In this study, patients with cT3–4 or cN-positive rectal cancer, with the tumor extending up to 16 cm from the anal verge, were randomized to preoperative chemoradiotherapy (50.4 Gy) or postoperative chemoradiotherapy (55.8 Gy), with concurrent 5-FU and adjuvant bolus 5-FU. All patients underwent TME surgery. Preoperative treatment resulted in similar 10-year overall survival (60% vs. 60%) and distant metastasis rates (30% vs. 30%) but significantly improved local control (7% vs. 10%), sphincter preservation (40% vs. 20%), and treatment tolerability.

Advantages of preoperative treatment: Although the Swedish Trial for short course radiation confirms that radiation would compensate for a poor surgery in the pre-TME era, TME has standardized surgical treatment for rectal cancers. Radiation therapy to the pelvis after surgery would have negative implications, thus over the years,

JAYPEE BROTHERS

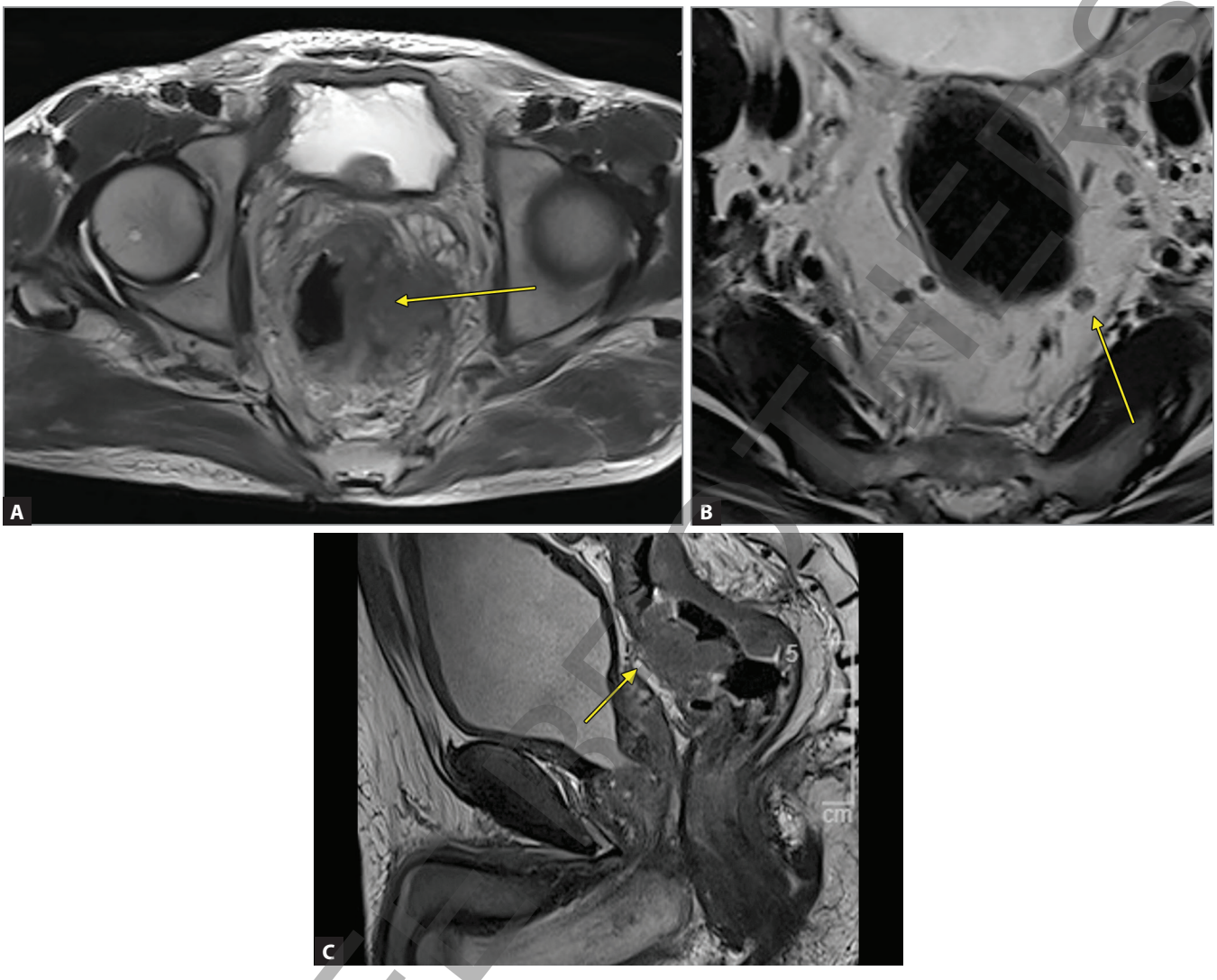

Figs. 8A to C: High-risk features on MRI. (A) Involvement of the mesorectal fascia and involving the seminal vesicle; (B) Nodes present in the mesorectum with EMVI; and (C) Threatened mesorectal fascia anteriorly in a nearly lumen occluding lesion (yellow).

evidence has shifted in favor of postoperative radiation. Preoperative chemoradiotherapy in the German Trial was associated with substantially lower acute toxicity (27% vs. 40%), late toxicity (14% vs. 24%), and better treatment compliance, with 90% completing radiotherapy compared with only 55% in the postoperative group. These findings established preoperative chemoradiotherapy as preferable to postoperative radiotherapy because the tumor is irradiated in a more favorable anatomical setting, with less small-bowel exposure, better treatment completion, improved local control, and greater potential for sphincter preservation, without compromising overall survival **(Box 3)**.

BOX 3: Optimal interval between preoperative radiotherapy and surgery.

- *Traditional recommendation after long course radiotherapy (LCRT):* Surgery is generally performed after 6–8 weeks, allowing tumor regression, downsizing, and potentially improved resectability and pathological response.
- *Delay beyond 6–8 weeks:* Delaying surgery beyond 6–8 weeks may increase tumor regression and pCR; however, retrospective data from Tata Memorial Centre suggest that delaying surgery beyond 12 weeks does not provide additional benefit in pCR or survival.
- *GRECCAR-6 Trial:* This randomized trial compared surgery at 7 versus 11 weeks after chemoradiotherapy and found no significant difference in pCR or oncological outcomes, suggesting that prolonging the interval to 11 weeks does not provide a clear advantage.

JAYPEE BROTHERS

SHORT-COURSE RADIOTHERAPY

Short course radiotherapy (SCRT) consists of 5 Gy per fraction for 5 consecutive days, delivering a total dose of 25 Gy. This is followed by a 7–10-day waiting period, after which the patient proceeds to immediate surgery **(Box 4)**. The landmark trials of short-course radiation are as follows:

- *Swedish Rectal Cancer Trial:* Compared surgery alone with preoperative SCRT (25 Gy in 5 fractions). At 13 years, overall survival was significantly improved with radiotherapy (38% vs. 30%), with a substantial reduction in local recurrence (9% vs. 26%). The trial predated widespread adoption of TME, and the high local recurrence rate with surgery alone was therefore higher than that seen in modern TME series. Interestingly, even with non-TME surgery, local recurrence remained ≤10% in Dukes A disease compared with higher rates in Dukes B and C, suggesting that radiotherapy can partly compensate for inadequate surgical technique.
- *Dutch TME Trial:* Compared TME alone with preoperative SCRT (25 Gy in 5 fractions) followed by TME; postoperative radiotherapy was recommended in the surgery-alone group when the CRM was ≤1 mm. There was no significant difference in overall survival, but preoperative radiotherapy significantly reduced 10-year local recurrence from 11 to 5%, demonstrating that SCRT provides additional local control even when high-quality TME is performed.

BOX 4: Timing of surgery after short-course radiotherapy.

- Historically, surgery was performed within 1 week of completing short-course radiotherapy (SCRT). But a delay of 4–8 weeks after SCRT produces acceptable complication profile and pathological complete response.
- The Stockholm III trial was a randomized phase III study comparing SCRT (5d × 5 Gy) with immediate surgery, SCRT with delayed surgery after 4–8 weeks, and long-course radiotherapy with delayed surgery. Local recurrence rates were similar across the three groups, establishing noninferiority of delayed surgery after SCRT. Delaying surgery after SCRT was associated with a significantly lower postoperative complication rate compared with immediate surgery (41% vs. 53%), although acute radiation toxicity was somewhat higher. pCR was achieved in 0.3%, 10.4%, and 2.2% patients in the SCRT, SCRT-delay, and long-course radiotherapy-delay groups, respectively.

Advantages:

- It offers greater patient convenience by simplifying the overall treatment course.
- It is associated with a lower overall treatment cost.
- It results in reduced treatment-related toxicity.
- It allows earlier initiation of effective adjuvant systemic chemotherapy.

Side Effects of Short-course Radiotherapy

- Acute toxicity is predominantly gastrointestinal, with proctitis, tenesmus, diarrhea, rectal pressure, and crampy abdominal pain, occurring particularly during the 1st week after treatment.
  - *Gastrointestinal toxicity:* Proctitis, tenesmus, diarrhea, rectal pressure, and crampy abdominal pain are the most common acute toxicities, particularly during the 1st week after SCRT.
  - *Near-obstructing tumors:* Treatment-related edema and inflammation may worsen obstructive symptoms; therefore, SCRT should be used cautiously in patients with near-complete obstruction.
  - *Urinary toxicity:* Dysuria and increased urinary frequency may occur but are generally less common.
  - *Skin toxicity:* Significant radiation dermatitis is uncommon; however, perianal irritation or fissuring may develop secondary to diarrhea, particularly in patients subsequently undergoing abdominoperineal resection (APR).
  - *Neurological toxicity:* An occasional flare of preexisting sciatica may occur.
- *Late toxicity:* Late effects are generally mild and may include chronic changes in bowel habit, increased urinary frequency, and vaginal stenosis.

As a surgical team in a multidisciplinary tumor board, a decision is often required for choosing between the type of radiation required. This has been highlighted in **(Table 5, Boxes 5 and 6)**.

BOX 5: Evidence for choosing between short-course and long-course radiation.

Trans-Tasman (TROG) Trial: This randomized trial compared neoadjuvant short-course radiotherapy (SCRT) with neoadjuvant long-course chemoradiotherapy, followed by surgery after an interval of approximately 4–6 weeks.

There was no significant difference in 5-year overall survival (74% vs. 70%), late toxicity, or locoregional failure (7.5% vs. 4.4%). These findings established SCRT as an effective alternative to long-course chemoradiotherapy in appropriately selected patients with locally advanced rectal cancer.

JAYPEE BROTHERS

BOX 6: Present use of short-course radiation.

- It is mostly required for resectable intermediate disease without any high-risk features like mesorectal nodes, EMVI, and no threatened MRF for added local control and sterilizing the surgical field.
- Frail patients not fit for concurrent chemotherapy

TABLE 5: Differences between long-course and short-course radiation.

	Short course	*Long course*
Eligible clinical stage	cT1-2/N0	cT3-4 and/or N+
Treatment schedule	Only RT-5 Gy/fraction x 5 days (25 Gy)	RT 1.8 Gy/fraction over 5–6 weeks (45–50.4 Gy) with concurrent 5-FU based chemotherapy
Interval between RT and surgery	5 days	4–8 weeks
Concurrent chemotherapy	No	Yes
Improved local control	Yes	Yes
Sphincter preservation	No	Yes

Why was Short-course Radiotherapy Historically Less Favored?

- *Timing of surgery:* Historically, SCRT was followed by immediate surgery within 1 week, whereas LC-CRT was followed by a 4–8-week interval, allowing more time for tumor regression.
- *Tumor response:* The longer interval after LC-CRT resulted in greater tumor regression and downstaging, with higher pCR rates. In EORTC 22921, pCR was approximately 14% with LC-CRT vs. 5% without concurrent chemotherapy.
- *Surgical advantages:* Greater tumor regression could facilitate technical resection, particularly in bulky or low rectal tumors, and was associated with more favorable pathological features.

Total Neoadjuvant Therapy

Total neoadjuvant therapy refers to the delivery of the entire planned course of systemic chemotherapy in combination with neoadjuvant radiotherapy, thereby completing both systemic and radiation treatment in the preoperative period before definitive rectal surgery.

Rationale for Total Neoadjuvant Therapy

The interval of approximately 8–10 weeks between neoadjuvant radiotherapy and surgery allows recovery from toxicity and tumor response but provides limited systemic control of micrometastatic disease, while pelvic cCR/pCR rates remain only 10–20%. Importantly, recurrence is predominantly systemic; in EORTC 22921, extrapelvic recurrence was more than twice as frequent as pelvic recurrence. Furthermore, postoperative chemotherapy is difficult to deliver reliably, with only 50–75% of patients in clinical trials actually initiating and completing adjuvant chemotherapy as planned. These limitations provide a strong rationale for moving systemic chemotherapy earlier in the treatment course, forming the basis of TNT.

Benefits of Total Neoadjuvant Therapy

They are as follows:

- A complete course of systemic chemotherapy is administered before proctectomy, along with neoadjuvant short- or long-course radiotherapy.
- TNT provides early systemic treatment of micrometastatic disease and may increase the pCR rate.
- Delivering chemotherapy before surgery may improve treatment tolerance and completion rates.
- TNT may increase tumor resectability and facilitate optimal surgical outcomes.
- It may also reduce the duration of temporary ileostomy.

Comparing TNT with Conventional Treatment

The evidence comparing TNT with conventional treatment in LARC has evolved from establishing the feasibility of delivering chemotherapy before surgery to demonstrating improvements in tumor response, systemic disease control, and long-term survival **(Table 6)**.

BOX 7: Timing of therapy in the major TNT trials.

- *RAPIDO:* Patients received short-course radiotherapy for 5 days, followed by an 11–18-day interval, then CAPOX/FOLFOX for 18 weeks, followed by a 2–4-week interval before surgery (TME).
- *PRODIGE 23:* Patients received mFOLFIRINOX for 3 months, followed by long-course chemoradiotherapy for 5.5 weeks, with a 7-week interval before surgery (TME), followed by 8 weeks of adjuvant chemotherapy.

Influence of Treatment Sequencing

The sequence of chemotherapy and chemoradiotherapy within TNT appears to influence tumor response and the

JAYPEE BROTHERS

TABLE 6: Major trials evaluating total neoadjuvant therapy in locally advanced rectal cancer **(Box 8)**.

Trial	*Comparator groups*	*Outcomes*	*Clinical significance*
WAIT	NACTRT → 3 cycles fluorouracil-based chemotherapy → surgery vs. NACTRT → surgery	*pCR:* 16% vs. 25%; not statistically significant	Demonstrated the feasibility and safety of chemotherapy during the interval between NACTRT and surgery
Polish II	SCRT → 3 cycles FOLFOX → surgery vs. long-course NACTRT → surgery	*pCR:* 16% vs. 12%; R0 resection: 77% vs. 71%. Lower acute toxicity with TNT	Demonstrated feasibility of TNT, but no sustained long-term survival benefit
RAPIDO	SCRT → 6 cycles CAPOX/9 cycles FOLFOX → surgery vs. long-course NACTRT → surgery → adjuvant chemotherapy	pCR: 28% vs. 14%; reduced 3-year disease-related treatment failure and distant metastases. Later follow-up showed higher local recurrence with TNT.	Established TNT as an effective strategy for high-risk LARC, particularly for reducing systemic failure.
PRODIGE-23	FOLFIRINOX → NACTRT → surgery → adjuvant FOLFOX vs. NACTRT → surgery → adjuvant FOLFOX	pCR: 28% vs. 12%; improved long-term DFS and OS	• Provided strong evidence for survival benefit with TNT, supporting intensified chemotherapy in fit, high-risk patients • 92% patients completed induction with FOLFIRINOX thus supporting triplet chemotherapy
STELLAR	SCRT → 4 cycles CAPOX → surgery → 2 cycles CAPOX vs. long-course NACTRT → surgery → 6 cycles CAPOX	Complete response: 23% vs. 13%; improved 3-year OS	Supports TNT for improving tumor response and overall survival, although distant and locoregional controls were not significantly different

potential for organ preservation. Induction TNT administers systemic chemotherapy before chemoradiotherapy, whereas consolidation TNT delivers chemotherapy after chemoradiotherapy and before surgery. Although longer intervals after neoadjuvant therapy may allow greater tumor regression, current evidence suggests that consolidation TNT may be particularly advantageous when tumor response and organ preservation are the primary goals, as it prolongs the interval between completion of radiotherapy and surgery while maintaining systemic therapy during this period **(Table 7, Figs. 9A to D, Box 8)**.

BOX 8: Response assessment after initial therapy.

- *Response assessment after neoadjuvant treatment:* Restaging should be performed to detect distant metastases that may alter treatment, reassess the surgical approach, and determine whether additional therapy or resection can be avoided. The recommended assessment includes pelvic MRI for local restaging along with chest CT and abdominal CT/MRI for distant disease.
- PET-CT is not used in rectal cancer for response assessment.

De-escalation of Therapy

A major concern with TNT is potential overtreatment and treatment related toxicities, particularly in patients with biologically favorable or lower-risk disease. De-escalation strategies therefore aim to maintain oncological outcomes while reducing treatment-related toxicity, especially the long-term functional consequences of pelvic radiotherapy. Current approaches include selective omission of radiotherapy, omission of systemic chemotherapy, and tailoring treatment according to tumor location and baseline risk **(Box 9)**.

BOX 9: De-escalation strategies in rectal cancer.

- *Upper/proximal rectal cancer:* Tumors above the anterior peritoneal reflection often behave more like left-sided colon cancers, with local recurrence rates comparable to colon cancer and lower than distal rectal cancer. In selected node-negative proximal locally advanced rectal cancers (LARC), upfront resection is reasonable when the mesorectal fascia is clear and there are no high-risk features; neoadjuvant therapy should be considered for T4 disease, MRF involvement, EMVI positivity, significant nodal disease, or other features predicting poor local or systemic control.
- *Lower-risk low rectal cancer:* Selected node-negative low rectal cancers, particularly those in the APR territory in patients not pursuing organ preservation, may be considered for de-escalation with neoadjuvant CRT followed by surgery without routine TNT. However, this strategy risks undertreatment because of clinical understaging. Thus, omission of systemic therapy based solely on apparently early-stage disease should be approached cautiously.

JAYPEE BROTHERS

TABLE 7: Induction versus consolidation total neoadjuvant therapy.

Trial	*Comparator groups*	*Outcomes*	*Clinical significance*
CAO/ARO/AIO-12	*Induction TNT:* 3 cycles FOLFOX → NACTRT → surgery vs. *Consolidation TNT:* NACTRT → 3 cycles FOLFOX → surgery	*pCR: 17% vs. 25%*, favoring consolidation TNT. No significant difference in 3-year DFS, local recurrence, or OS.	*Consolidation TNT improves tumor response* but does not provide a demonstrated survival advantage.
OPRA	*Induction TNT:* Chemotherapy → NACTRT vs. *Consolidation TNT:* NACTRT → chemotherapy, with *watch-and-wait* for complete or near-complete clinical responders	*3-year TME-free survival: 41% vs. 53%*, favoring consolidation TNT. DFS and OS were similar.	*Consolidation TNT increases the likelihood of organ preservation* without compromising oncological outcomes.

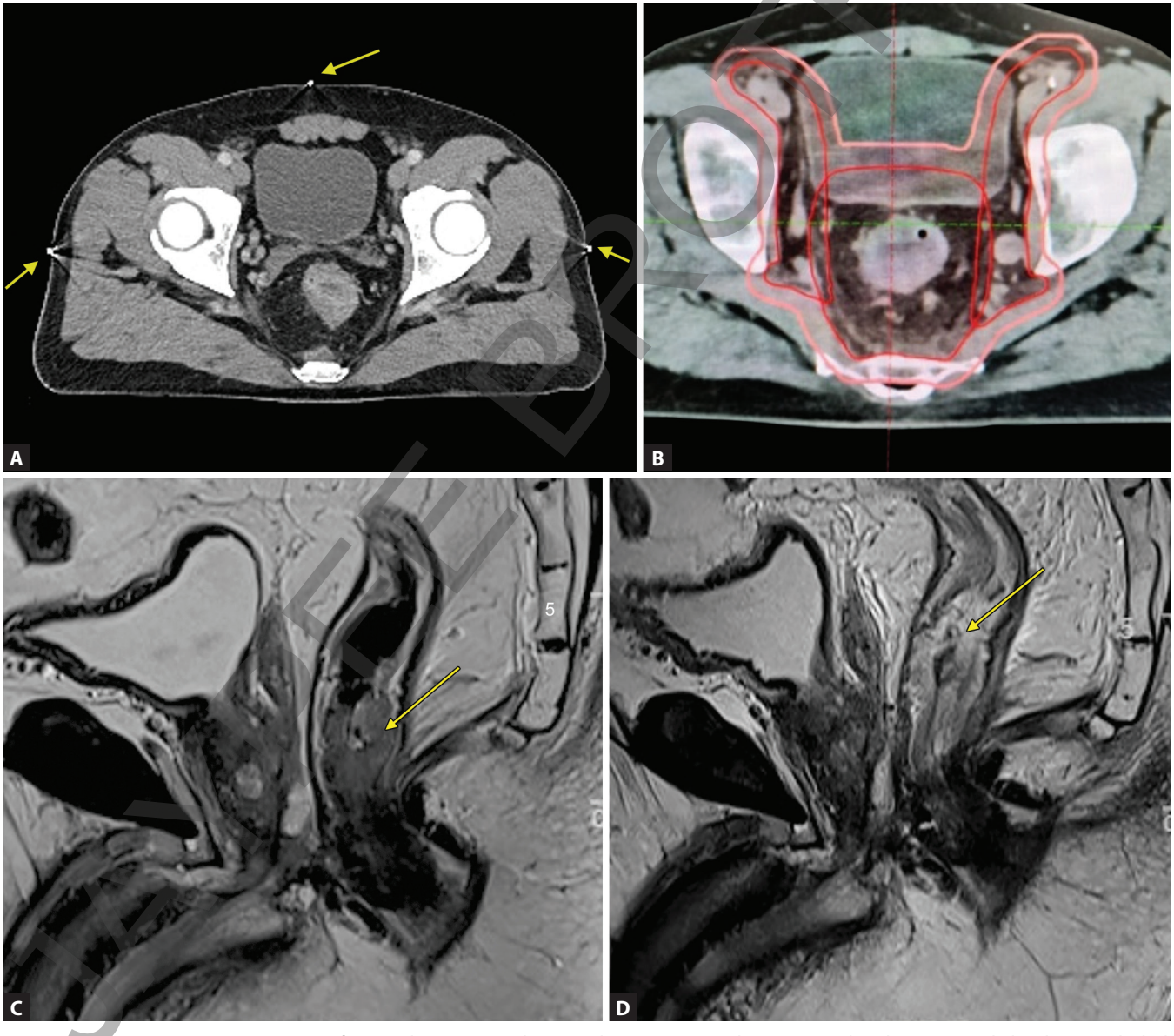

Figs. 9A to D: (A) Contouring CT scans for rectal cancer; (B) Planning the treatment volumes, note the obturator node has been included in the treatment field of the rectum and the pelvic nodes; and (C and D) Pre- and postneoadjuvant LCRT, respectively (yellow arrow).

JAYPEE PROOFHELPS

Omission of Radiotherapy

This concept was evaluated in the following trials **(Box 10)**:

BOX 10: Current status of selective omission of radiotherapy.

- The tumor is located in the proximal or mid-rectum.
- The tumor is non-T4.
- There is limited nodal disease, typically N1.
- The mesorectal fascia (MRF) is clear.

Patients with T4 disease, threatened/involved MRF, extensive nodal disease, or other high-risk features should generally continue to receive an appropriate neoadjuvant radiation-containing strategy.

- *GRECCAR4 and FOWARC trials:* Both trials evaluated strategies incorporating induction chemotherapy without mandatory CRT and suggested that, in carefully selected patients, omission of radiotherapy may not compromise oncological outcomes.
- *PROSPECT trial:* This phase III noninferiority trial compared neoadjuvant FOLFOX with selective chemoradiation versus conventional neoadjuvant CRT in patients with LARC undergoing surgery. FOLFOX was noninferior for 5-year DFS, with comparable 5-year OS and local recurrence rates. Importantly, the study excluded patients at high risk of incomplete resection, including T4 tumors, low rectal tumors, tumors within 3 mm of the radial margin, and patients with ≥4 enlarged pelvic nodes. Thus, its findings are most applicable to intermediate-risk LARC rather than high-risk disease.
- *CONVERT trial:* This phase III noninferiority trial compared neoadjuvant CAPOX alone with conventional CRT. There was no significant difference in pCR or downstaging, while chemotherapy alone was associated with lower rates of perioperative distant metastases and diverting ileostomy. However, only patients with a clear CRM were included, again emphasizing the importance of careful patient selection.

Immunotherapy and Biologic Agents in Neoadjuvant Treatment

- *Immunotherapy in mismatch repair-deficient (dMMR)/MSI-high rectal cancer:* The integration of immunotherapy into neoadjuvant treatment represents an important emerging paradigm, with the strongest evidence currently available in dMMR/MSI-high rectal cancer. In a prospective phase II study, neoadjuvant dostarlimab, an anti-PD-1 antibody, produced cCR. These findings have generated considerable interest in nonoperative management and organ preservation for selected dMMR rectal cancers, although longer-term follow-up is essential before this approach can be considered broadly established.
- *Biologic and immune combinations in LARC:* Several trials have evaluated the addition of targeted or immune therapies to conventional neoadjuvant treatment. EXPERT-C and GEMCAD 1402 demonstrated improvements in selected response measures with cetuximab or aflibercept, but without a consistent survival benefit. Similarly, NRG-GI002 showed limited improvement in pathological or clinical response with pembrolizumab, although subsequent follow-up suggested a possible overall-survival advantage. More recent studies such as TORCH and the phase III UNION trial have reported encouraging response and pCR rates with immunotherapy-containing regimens, including in selected pMMR/MSS disease.

A summary of the neoadjuvant decision-making process has been highlighted in **Algorithm 3**.

SURGERY FOR RECTAL CANCER

Principles of Rectal Cancer Surgery

Principle 1: Proximal Ligation of the Inferior Mesenteric Artery

The optimal level of IMA ligation remains controversial. High tie, involving ligation of the IMA at its origin from the aorta, has been advocated for potential removal of para-aortic nodal disease and for increasing proximal colonic mobility to facilitate a tension-free anastomosis. However, high ligation may compromise proximal colonic perfusion and carries a theoretical risk of injury to the para-aortic autonomic nerve plexus. Importantly, there is no convincing evidence that high ligation provides a survival or oncological advantage **(Figs. 10A to D)**.

Principle 2: Total Mesorectal Excision

The fundamental principle of rectal cancer surgery is dissection along embryologically defined planes. In the rectum, this corresponds to the "holy plane" between the MRF and the surrounding pelvic fascia. The mesorectum is the fatty and lymphovascular envelope surrounding the posterior and lateral aspects of the rectum, which acts as a

JAYPEE BROTHERS

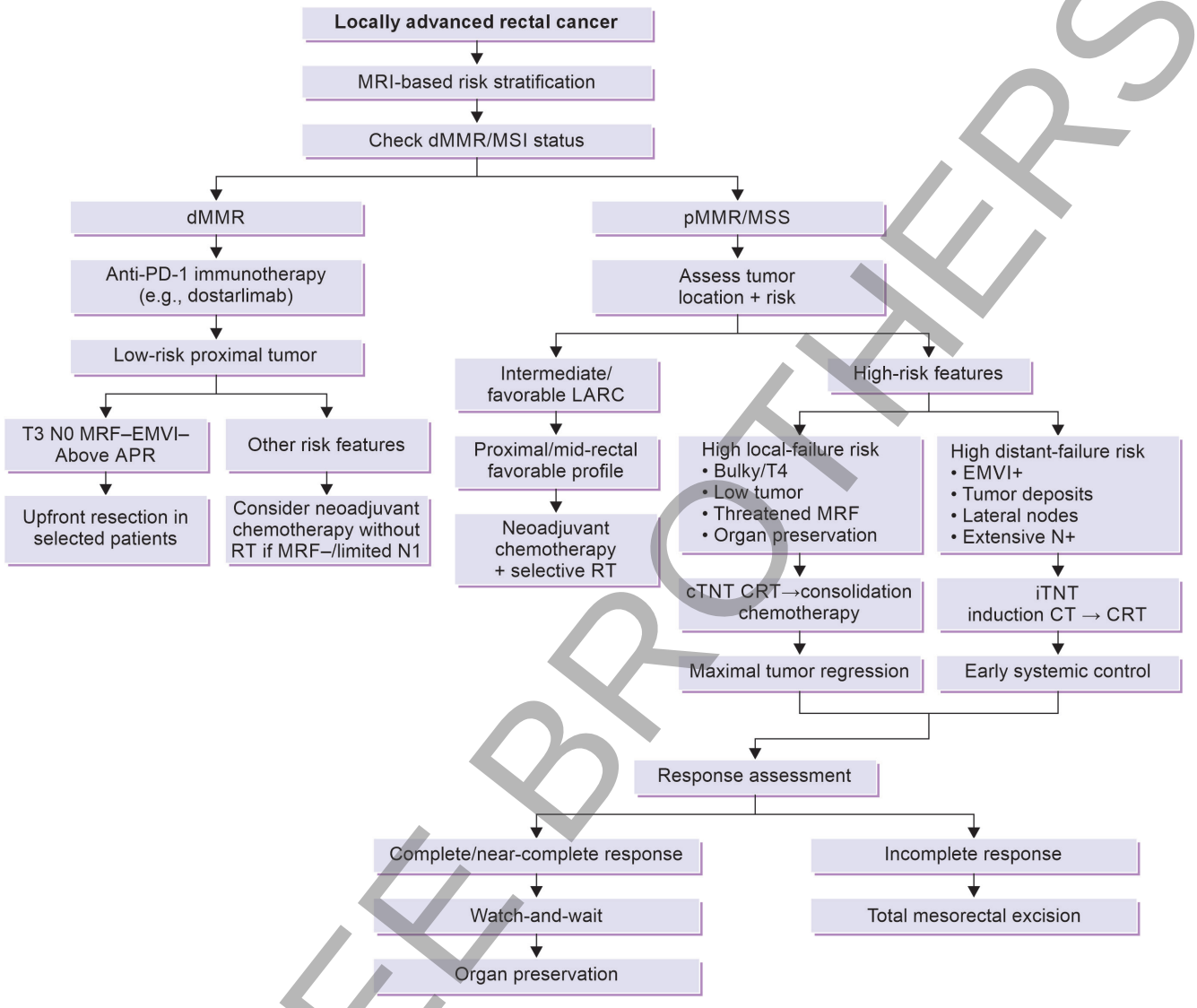

Algorithm 3: Neoadjuvant therapy for rectal cancer.

barrier to lateral tumor spread. Complete excision of this mesorectal envelope with the tumor therefore improves local control and reduces the risk of local recurrence. The plane is also relatively avascular, allowing precise sharp dissection with minimal blood loss. TME is the standard surgical approach for middle- and lower-rectal cancers. For upper rectal cancers, a partial mesorectal excision is performed, with the mesorectum divided approximately 5 cm distal to the tumor **(Figs. 11A to C)**.

Principle 3: Distal Resection Margin of the Rectum

Before the advent of TME, a distal resection margin of 5 cm was considered necessary to minimize local recurrence. However, subsequent studies demonstrated that distal intramural spread is uncommon, occurring in only about 10% of rectal cancers, with only 2–3% of stage I–III tumors extending more than 1 cm beyond the primary lesion. Such distal spread is more often associated with adverse histologic features, such as poor differentiation, and its independent impact on local recurrence and overall survival remains uncertain.

In contrast, mesorectal spread is more clinically important and may extend up to 3–4 cm beyond the primary tumor, providing the rationale for TME. For distal rectal cancers undergoing TME, a 2-cm distal margin is considered ideal; however, in the absence of unfavorable

JAYPEE BROTHERS

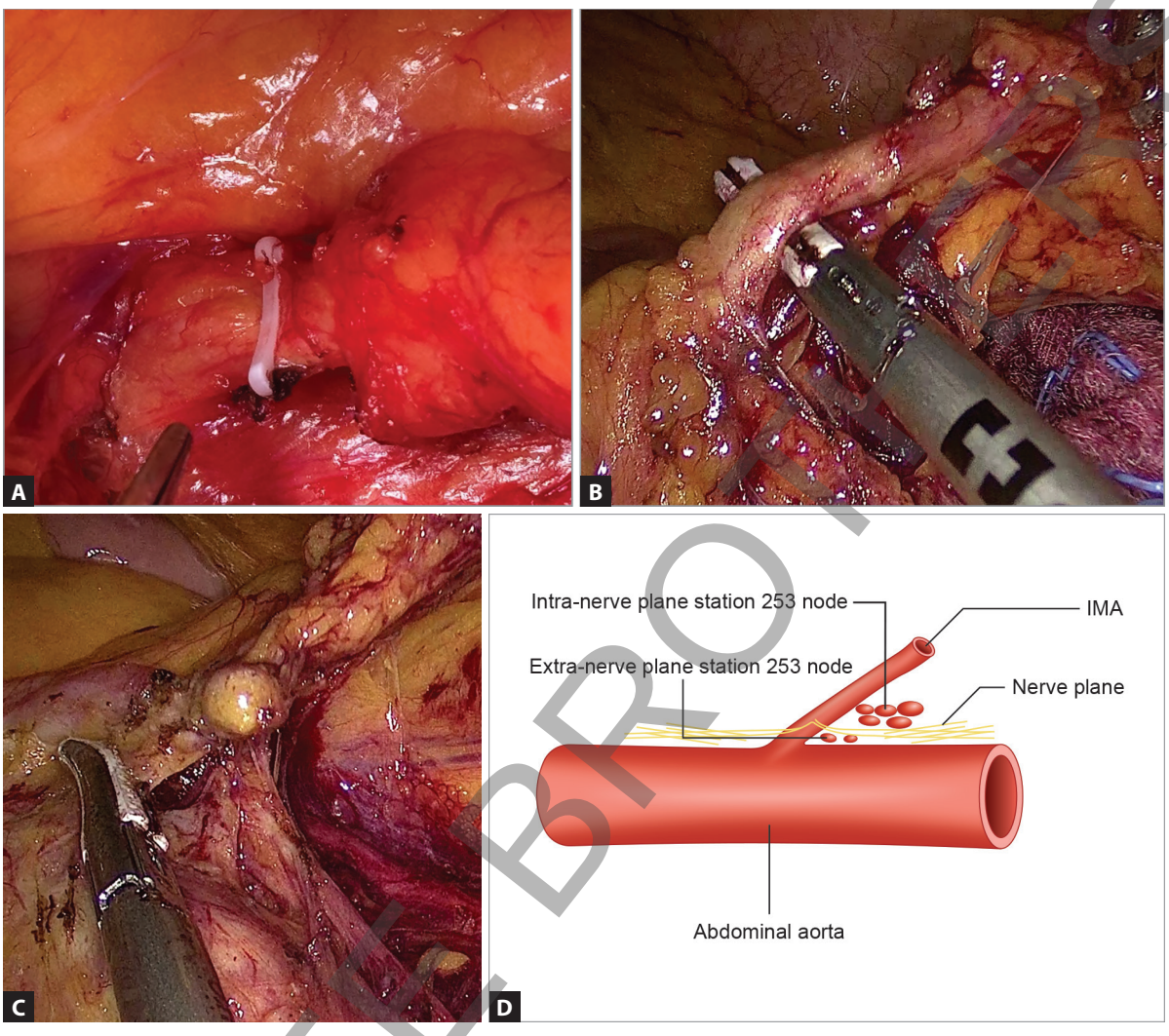

Figs. 10A to D: High ligation of the inferior mesenteric artery. (A) Open surgery; (B) Laparoscopic surgery; and (C and D) The station 253 node is harvested in this technique.

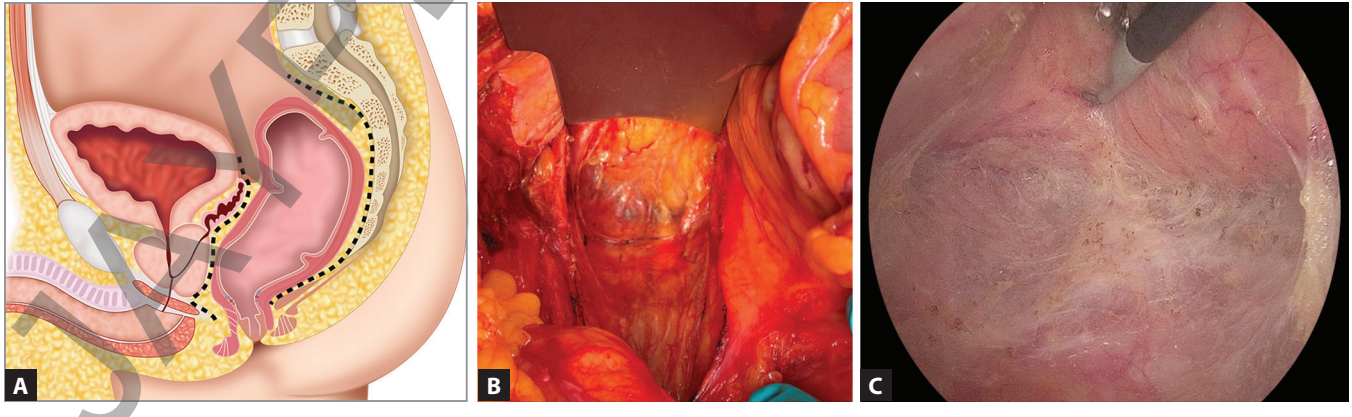

Figs. 11A to C: Total mesorectal excision (Holy plane of Heald). (A) Concept of TME; (B) Total mesorectal excision (open surgery); and (C) TME in laparoscopic surgery, note the bloodless dissection field on sharp dissection.

JAYPEE BROTHERS

tumor characteristics, a shorter but negative margin may be acceptable, particularly when sphincter preservation is an important objective **(Figs. 12A to F)**. A classification system was introduced by Rullier and colleagues which classified low rectal tumors into 4 types, thus categorizing them into various resection types **(Fig. 13)**.

Principle 4: Circumferential Resection Margin

The circumferential resection margin is a major determinant of local control in rectal cancer. Quirke demonstrated that microscopic CRM involvement was strongly associated with local recurrence, establishing CRM positivity as an important predictor of local recurrence and poor disease-free survival. A 1-mm negative CRM is now generally considered acceptable, with studies showing no clear difference in recurrence compared with 2 mm. Preoperative MRI accurately predicts CRM involvement and is therefore essential for identifying patients at high risk. Tumors threatening or involving the MRF may still be resectable but often require multimodality therapy and, when necessary, multivisceral resection to achieve an R0 resection **(Fig. 14 and Box 11)**.

BOX 11: Extended TME (e-TME).

An extended TME (e-TME) is defined as a surgical procedure which requires en-bloc resection of adjacent organs or structures adhering to the primary rectal cancer.

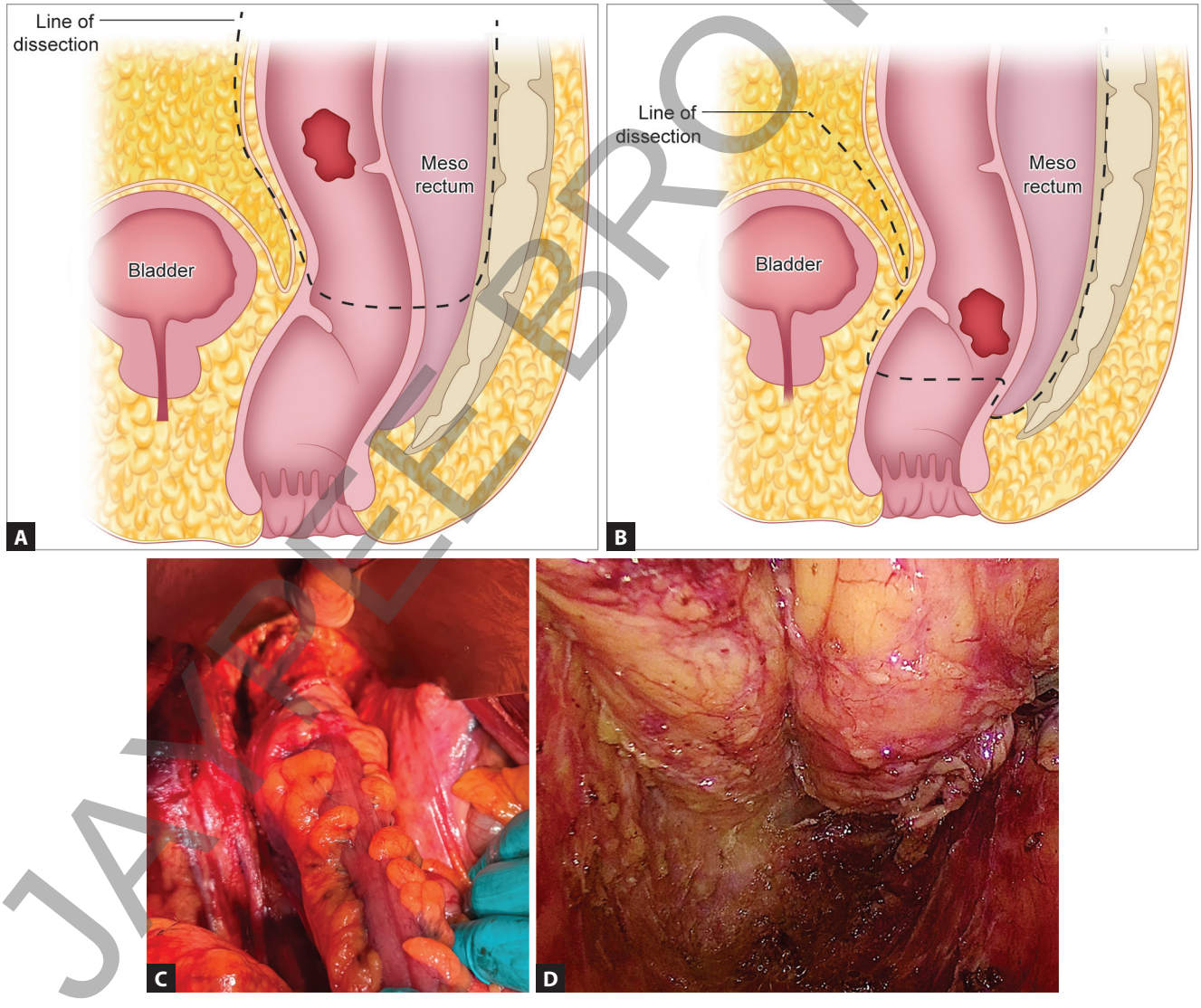

Figs. 12A to D

JAYPEE BROTHERS

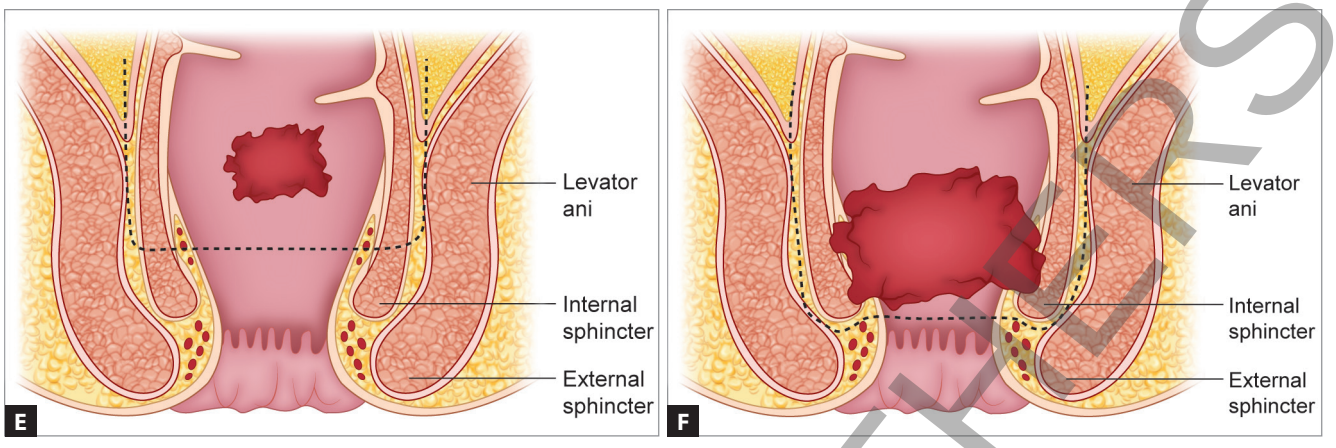

Figs. 12E and F

Figs. 12A to F: Distal resection margin. Concept of (A) Partial TME for upper rectal tumors; (B) Complete TME; (C) Distal margin after mobilizing the entire rectum; (D) Pelvic floor on laparoscopy for ultra-low anterior resection; (E) Partial intersphincteric resection; and (F) Total intersphincteric resection.

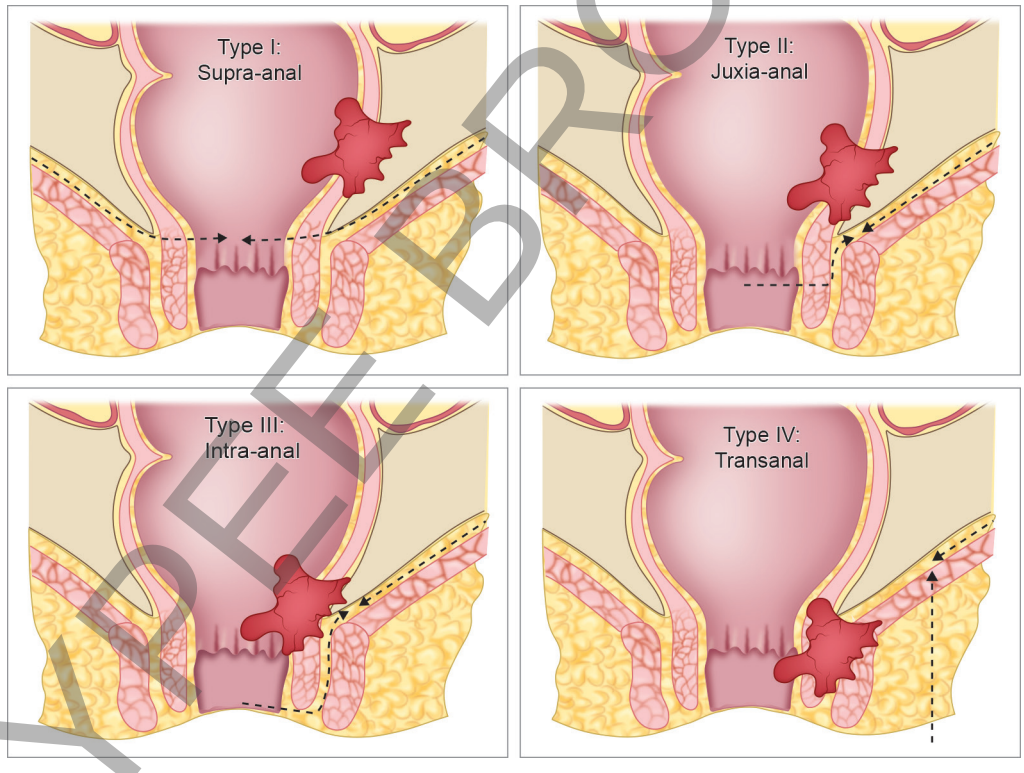

Fig. 13: Rullier classification for low rectal cancers.

Operative Management of Rectal Cancer

Rectal cancer surgery is more or less straightforward with no difference in open or minimal access outcomes. The recent introduction of the robotic platform has helped perform minimal access surgery in a very narrow pelvis. Fluorescence-guided surgery with indocyanine green helps assess the perfusion of the colonic conduit prior to anastomosis. The general steps involved are as follows **(Table 8, Box 12, Videos 32.3 and 32.4)**:

- *Colonic mobilization:* The sigmoid and descending colon may be mobilized by medial-to-lateral or lateral-to-medial dissection, with early identification of the

JAYPEE BROTHERS

left ureter and appropriate vascular control. The splenic flexure is mobilized when additional length is required.

- *Pelvic entry and holy plane:* Pelvic dissection enters the "holy plane" between the mesorectal and presacral fascia. Maintaining this plane avoids presacral bleeding, autonomic nerve injury, and incomplete mesorectal excision.
- *Posterior dissection:* Sharp dissection proceeds caudally in the correct TME plane with preservation of the MRF.
- *Lateral dissection:* Dissection proceeds toward the lateral stalks while avoiding the pelvic autonomic plexus and nervi erigentes, thereby reducing the risk of urinary and sexual dysfunction.



Fig. 14: Specimen of a rectal cancer after surgery. Note the mesorectum as a cylindrical structure.

BOX 12: Colorectal Reconstruction

- *End-to-end anastomosis:* The anvil is placed into the distal colon after clearing the bowel edge of appendices epiploicae, and the circular stapler is introduced transanally into the rectum. The pin is brought out just anterior or posterior to the staple line, the anvil is connected, and the stapler is fired after ensuring proper bowel alignment.
- *Colonic J-pouch:* A 6–8 cm J-pouch is constructed from the descending colon using a single longitudinal firing of a linear cutting stapler to improve stool frequency. A 6 cm pouch provides better early bowel function than a straight anastomosis, with approximately 3 versus 6 bowel movements/day at 1 year, although this advantage is lost by about 2 years.
- *Transverse coloplasty pouch:* A transverse coloplasty pouch is designed to interrupt antegrade colonic peristalsis and is a less bulky alternative to a J-pouch in patients with a narrow pelvis. A 7–8 cm longitudinal incision is made on the antimesenteric side of the descending colon and closed transversely with seromuscular absorbable sutures, after which the pouch is hand-sewn or stapled to the anorectal stump **(Fig. 15C)**.

TABLE 8: Pragmatic approach to terminologies in rectal cancer surgery **(Algorithm 4 and Figs. 15A to D)**.

Location	*Relation to the anatomical landmarks*	*Terminology of the resection*	*Anastomosis*	*Diversion Ileostomy by convention*
Upper rectal cancer/ rectosigmoid junction cancer	Anastomosis above the peritoneal reflection	Anterior resection	Circular stapler/hand-sewn (technically difficult)	±
Upper to mid rectal tumor	Anastomosis below the peritoneal reflection	Low anterior resection	Circular stapler **(Fig. 15B and Video 32.5)**	+
Mid-to-low rectal tumors	Anastomosis at the pelvic floor	Ultra-low anterior resection	Circular stapler	+
Low rectal tumor (Rullier 1)	Supra-anal tumor >1 cm from the anorectal ring	Ultra-low anterior resection	Circular stapler	+
Low rectal tumor (Rullier 2)	Juxta-anal tumor <1 cm from the anorectal ring	Partial intersphincteric resection	Hand-sewn coloanal anastomosis	+
Low rectal tumor (Rullier 3)	*Intra-anal tumor:* Invading the internal anal sphincter	Total intersphincteric resection/intersphinteric APE	Hand-sewn coloanal anastomosis **(Fig. 15C and Video 32.6)**	+
Low rectal tumor (Rullier 4)	*Transanal tumor:* Invading the external anal sphincter	Abdominoperineal resection/ELAPE **(Figs. 16A to C)**	No anastomosis	Permanent colostomy

JAYPEE BROTHERS

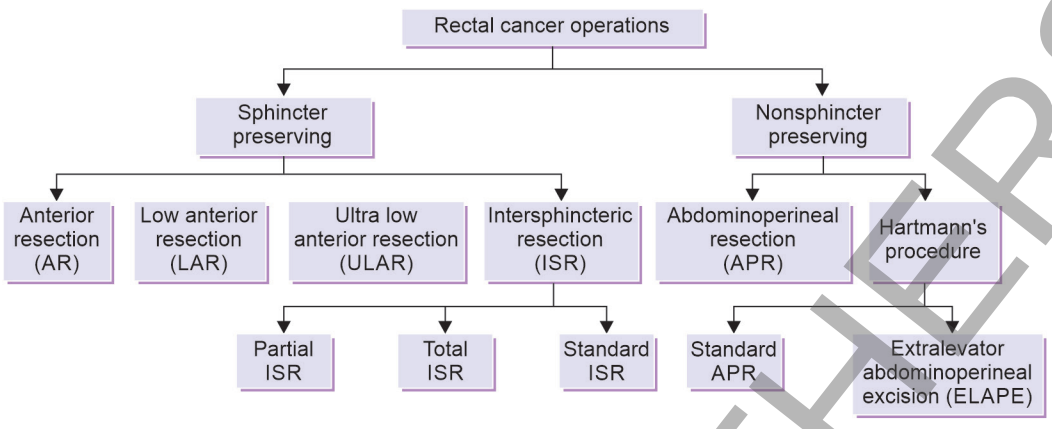

Algorithm 4: Classification of rectal cancer operations.

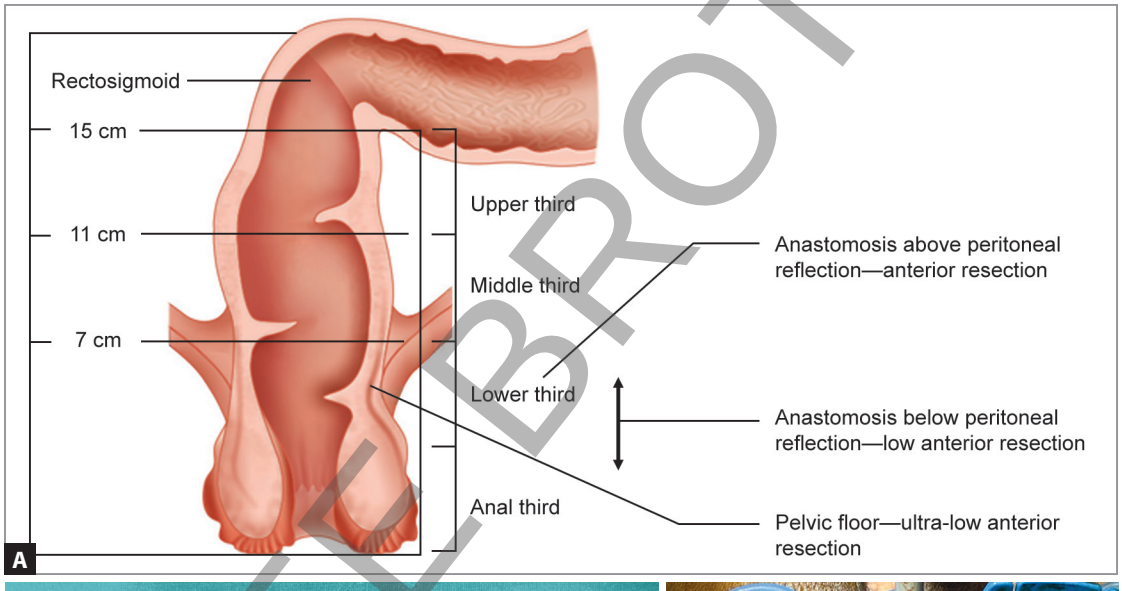



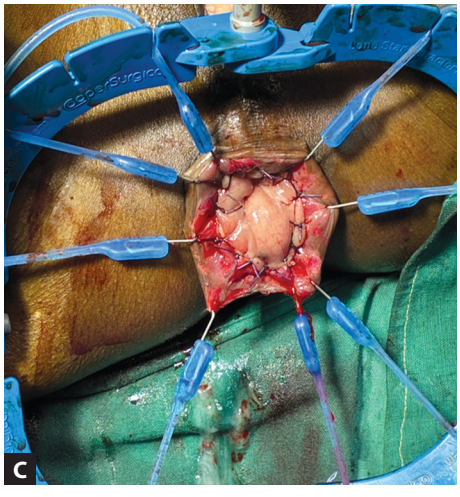

Figs. 15A to C

JAYPEE BROTHERS

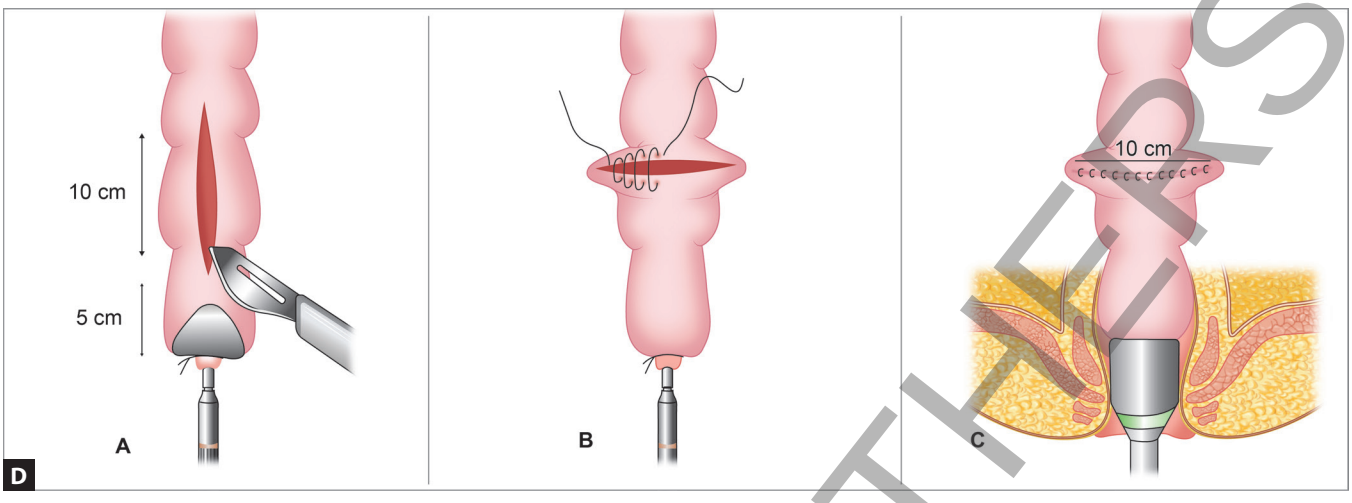

Fig. 15D

Figs. 15A to D: (A) Classification of rectal cancer surgery, techniques of anastomosis; (B) Circular stapler; (C) Hand-sewn coloanal anastomosis after intersphinteric resection; and (D) Transverse coloplasty.

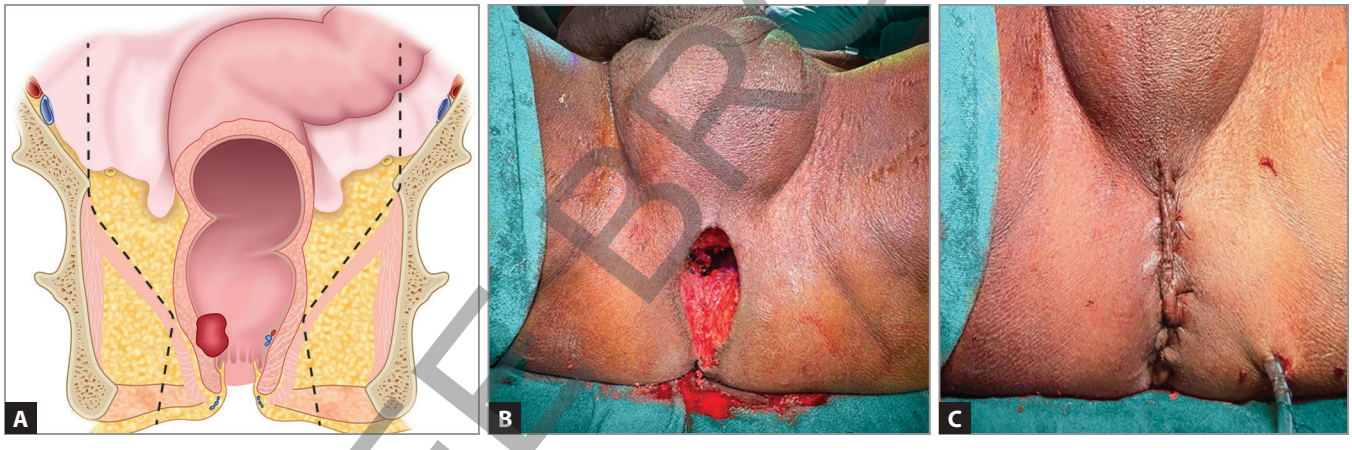

Figs. 16A to C: Abdominoperineal resection (Miles Procedure). (A) Conceptual image of APR (note the waist, at the convergence of the perineal and abdominal phases; (B and C) Perineal part of the operation.

- *Anterior dissection:* After opening the peritoneal reflection, dissection proceeds behind Denonvilliers fascia, which is preserved unless the tumor threatens the anterior margin.
- *Completion of TME:* Circumferential dissection is continued to the pelvic floor while avoiding "coning", which can compromise the mesorectal envelope and CRM. For partial mesorectal excision, the mesorectum is divided perpendicular to the bowel at the planned distal margin.
- *Distal resection:* Sphincter-preserving surgery, including very low anterior resection (LAR) and coloanal anastomosis, is appropriate in selected patients. Extralevator abdominoperineal excision (ELAPE)/APR is performed when sphincter preservation is not oncologically or functionally feasible, and this is done from the perineal approach.
- *Proximal resection and perfusion:* The proximal margin is determined by the vascular anatomy and level of IMA ligation. ICG fluorescence may be used to assess conduit perfusion before anastomosis.
- *Anastomosis:* Colorectal anastomosis is usually performed with a circular stapler, while very low resections may require a hand-sewn coloanal anastomosis.
- *Anastomotic assessment:* The anastomosis should be assessed with flexible sigmoidoscopy and an air-leak test; an identified defect may require revision or proximal diversion.

JAYPEE BROTHERS

MINIMAL ACCESS SURGERY IN RECTAL CANCER

Minimal access rectal cancer surgery has now become a popular choice among surgeons. Especially with the advent of the robotic systems, working into the depth of the pelvis is now performed with better magnification. The landmark trials of minimal access rectal cancer surgery are summarized in **Table 9 and Figures 17A and B**.

TABLE 9: Major randomized trials in minimally invasive rectal cancer surgery.

Trial	*Intervention arms*	*Outcomes*	*Oncological results*
MRC CLASICC	Laparoscopic vs. open colorectal/rectal resection	Laparoscopy had longer operative time but faster recovery and shorter hospital stay. Conversion rate was 34%. Positive CRM after low anterior resection was 12% vs. 6%.	Long-term follow-up showed no increase in local recurrence or poorer survival despite the initial CRM concern.
COLOR II	Laparoscopic vs. open surgery for rectal cancer	Similar TME quality, lymph-node yield and CRM positivity (10% vs. 10%); laparoscopy resulted in less blood loss, earlier bowel recovery, and shorter hospital stay.	*3-year local recurrence:* 5% vs. 5%; OS 86.7% vs. 83.6% and DFS 74.8% vs. 70.8% for laparoscopic vs. open surgery. Supported laparoscopic TME in experienced centers.
COREAN	Laparoscopic vs. open surgery after neoadjuvant chemoradiotherapy for mid/low rectal cancer	Laparoscopy provided faster gastrointestinal recovery, shorter incision and better early quality of life, with similar CRM, TME quality, and lymph-node yield.	At long-term follow-up, 3-year DFS, OS, and local recurrence were not significantly different, supporting oncological safety in experienced hands.
ACOSOG Z6051	Laparoscopic vs. open resection for stage II–III rectal cancer	Composite pathological endpoint included complete/nearly complete TME, negative CRM, and negative distal margin. Laparoscopy failed to meet the predefined noninferiority criteria.	At 2 years, DFS and recurrence were similar, but the study was not powered to establish long-term differences in local recurrence.
ALaCaRT	Laparoscopic vs. open resection for T1–3 rectal cancer	Similar clinical outcomes, but laparoscopic surgery failed to demonstrate pathological noninferiority for the composite endpoint of TME completeness, CRM and, distal margin.	At 2 years, no significant difference in DFS or recurrence, although long-term oncological equivalence could not be definitively established.
ROLARR	Robotic vs. laparoscopic rectal resection	Robotic surgery did not significantly reduce conversion to open surgery (8.1% vs. 1.22%). CRM positivity, TME completeness, and genitourinary dysfunction were also similar.	No demonstrated oncological or clinical superiority of robotic surgery over laparoscopy.

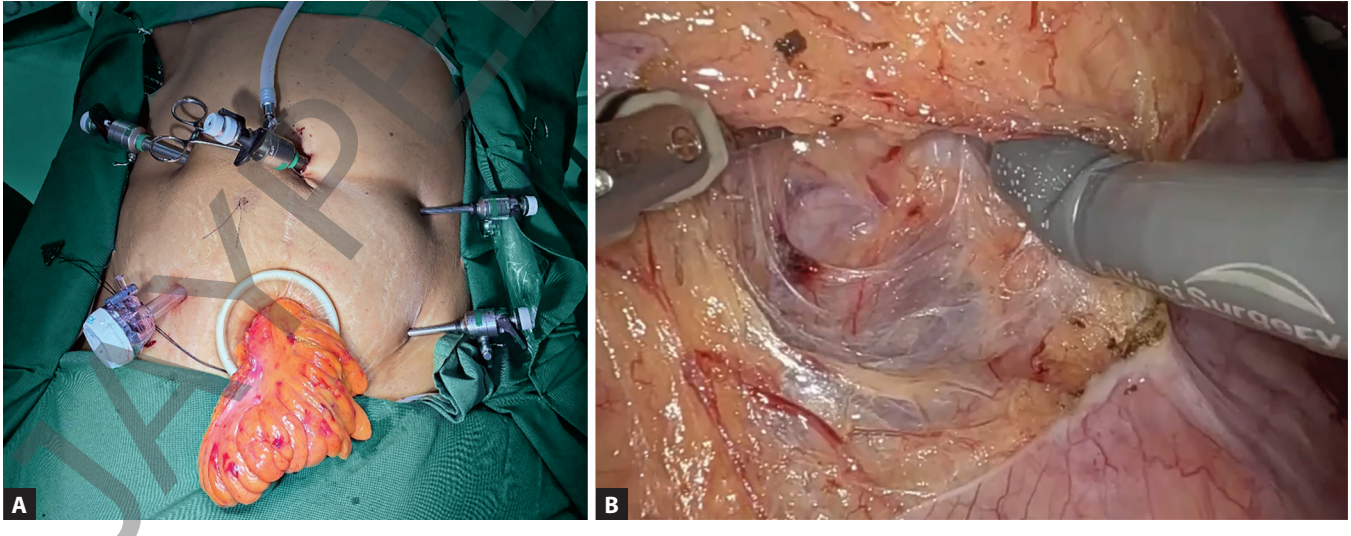

Figs. 17A and B: Minimal access rectal surgery. (A) Laparoscopic, note the port positions and the stoma site marked. Specimen is delivered through an Alexis retractor, and the anvil of the circular stapler is being placed; and (B) Robotic low anterior resection for a Da Vinci Si system.

JAYPEE BROTHERS

Protective Diversion after Rectal Surgery

Routine diversion with a loop ileostomy is recommended for patients undergoing LAR. It is generally not recommended following standard anterior resection. However, protective diversion should be considered in the following situations:

- Patients who have received neoadjuvant radiation
- Incomplete doughnut
- Unsatisfactory anastomosis or a positive intraoperative leak test
- Poor general condition of the patient.

Reversal of the loop ileostomy is generally done after the rectal stump has healed. A distal cologram is often necessary to evaluate the same. Many surgeons prefer to reverse the stoma after neoadjuvant therapy but with the advent of TNT reversal may be planned earlier. With the recent evidence, ileostomy reversal as early as 2 weeks may be done. Ileostomy may be revered with stapled or hand-sewn anastomosis.

BOX 13: Enterostomal therapist and planning stomas.

- A nurse specializing in stoma care is known as an enterostomal therapist (ET). Patients undergoing elective surgery in which a temporary or permanent stoma is planned should receive preoperative counseling from both the surgeon and an ET, including appropriate stoma education. Dedicated care by a specialized ET is associated with improved quality of life in patients with newly created stomas. Emotional and social support services may also be required during the preoperative or postoperative period.
- The stoma should ideally be located in the outer third of the rectus abdominis muscle. Physical characteristics of the torso, including a protuberant abdomen or large pannus, abdominal folds, previous scars, the position of the costal margin and iliac crest, pendulous breasts, and the presence of hernias, should be considered. Patient-related factors such as mobility, wheelchair dependence, posture including kyphosis, manual dexterity, and vision should also be assessed. The patient's preference regarding stoma location should be considered, particularly in relation to the beltline and other individual factors. Surgical considerations, including whether a loop or end stoma is planned and which segment of the intestine will be used, should also guide the selection of the stoma site **(Fig. 18)**.



Fig. 18: Planning a permanent colostomy for an APR/ELAPE. Note that the stoma has been marked by the enterostomal therapist.

CONTEMPORARY MODIFICATIONS IN RECTAL CANCER SURGERY

Transanal Total Mesorectal Excision

Distal rectal cancer surgery is technically challenging, with higher rates of positive CRM, local recurrence, anastomotic leakage, and permanent stomas, particularly in patients with a narrow pelvis, obesity, bulky tumors, or postradiotherapy fibrosis, fringe stapling devices in the distal rectum is often very difficult. Transanal total mesorectal excision (TaTME) combines the transabdominal approach with transanal dissection of the distal rectum and mesorectum, providing direct visualization of the distal tumor margin, TME plane, and ventral neurovascular structures. This may improve CRM clearance and TME completeness, while facilitating a double-purse-string anastomosis that avoids dog-ears and intersecting staple lines, with direct anastomotic assessment and leak testing; potential benefits include improved distal margin control, TME quality, and reduced stoma rates. The evidence in relation to TaTME is as follows:

- Deijen et al. reported that TaTME was associated with a lower rate of CRM positivity compared with laparoscopic TME (3.2% vs. 7.6%) and a higher rate of complete TME specimens (82.8% vs. 75.2%). Functional outcomes were broadly comparable, with similar bowel and urinary function and some evidence suggesting better sexual function after TaTME. TaTME has also been associated with a lower requirement for diverting stomas and potential improvements in quality of life.
- A Norwegian national series of 157 patients reported higher local recurrence (11.6% vs. 2.4%) and anastomotic leakage (8.4% vs. 4.5%), leading to suspension of TaTME in Norway.

JAYPEE BROTHERS

- *COLOR III trial:* This international, multicenter, phase III randomized noninferiority trial compared TaTME with LapTME for mid and low rectal cancer. TaTME significantly reduced conversion to open surgery (1% vs. 17%), while 90-day postoperative morbidity (20% vs. 18%) and anastomotic leakage (10% vs. 8%) were comparable. Macroscopically complete resection was achieved in 84% vs. 86%, with very low and comparable rates of positive CRM (1% vs. <1%) and positive DRM (1% vs. <1%). These short-term findings support TaTME as a safe alternative to LapTME.

Extralevator Abdominoperineal Excision

Standard abdominoperineal excision (APE) for low rectal cancer may produce a characteristic "waist" at the level of the puborectalis, resulting in reduced tissue around the distal tumor and increasing the risk of CRM involvement and intraoperative perforation. ELAPE was developed to overcome this limitation by removing a wider cylindrical specimen around the tumor. In ELAPE, the abdominal dissection is stopped before the mesorectum is dissected away from the levator ani. The levator ani muscles are divided under direct vision from the perineal side, as laterally as possible and close to the obturator internus muscles. This allows removal of the rectum, anus, external sphincter, and additional levator muscle as a single specimen, avoiding the characteristic waist of conventional APE. The perineal dissection is commonly performed in the prone jack-knife position, which provides better exposure of the pelvic planes and allows the rectum to be prolapsed through the pelvic opening. This facilitates visualization of the plane between the rectum and the prostate or vagina and may aid preservation of important nerves and vessels.

The wider cylindrical excision provides greater tissue around the distal rectum and increases the distance between the tumor and CRM. In the multicenter European study, ELAPE reduced CRM involvement from 49.6% to 20.3% and intraoperative perforation from 28.2% to 8.2% compared with standard APE. These advantages persisted even in patients who had received preoperative long-course chemoradiotherapy **(Figs. 19 to 21, Box 14)**.

Perineal Reconstruction

Extralevator abdominoperineal excision creates a larger perineal defect and is associated with a higher incidence of perineal wound complications and hernia, reported as approximately 38% compared with 20% after standard APE. Myocutaneous flap reconstruction, including gluteus maximus, rectus abdominis, or gracilis flaps, may be used to obliterate the dead space, particularly following neoadjuvant therapy.

BOX 14: Important points for ELAPE.

The anterior aspect is particularly vulnerable to CRM involvement and tumor perforation. When the anterior margin remains threatened despite preoperative treatment, en-bloc resection of the posterior vaginal wall or prostate may be required to achieve an adequate oncological margin.

Lateral Pelvic Lymph Node Dissection

The management of LPLNs in rectal cancer remains controversial, with Eastern (Japanese) practice traditionally considering them locoregional disease and routinely performing TME with lateral pelvic lymph node dissection (LPLND), whereas Western practice generally uses neoadjuvant chemoradiotherapy followed by TME, reserving LPLND for selected patients.

A large Japanese nationwide study by Akiyoshi et al. supported the concept that LPLN metastases, particularly internal iliac nodal disease, behave more like regional rather than distant disease. The JCOG0212 trial showed similar 5-year relapse-free survival with TME alone and TME with LPLND (73.3% vs. 73.4%), although local recurrence was higher with TME alone (13% vs. 7%), supporting a potential local-control benefit from LPLND without significant differences in urinary or sexual dysfunction.

Current evidence favors selective LPLND based on MRI. The MRI size criteria used for a lateral node is ≥7 mm on initial MRI. Persistent nodal enlargement after neoadjuvant therapy is particularly important, with a posttreatment node ≥5 mm proposed as an indication for LPLND during surgery.

Posterior Exenteration in Females

The Peking classification of posterior pelvic exenteration (PPE) was developed by the China PelvEx Collaborative, based on preoperative MRI findings and the specific site of invasion of the female internal reproductive organs

JAYPEE BROTHERS

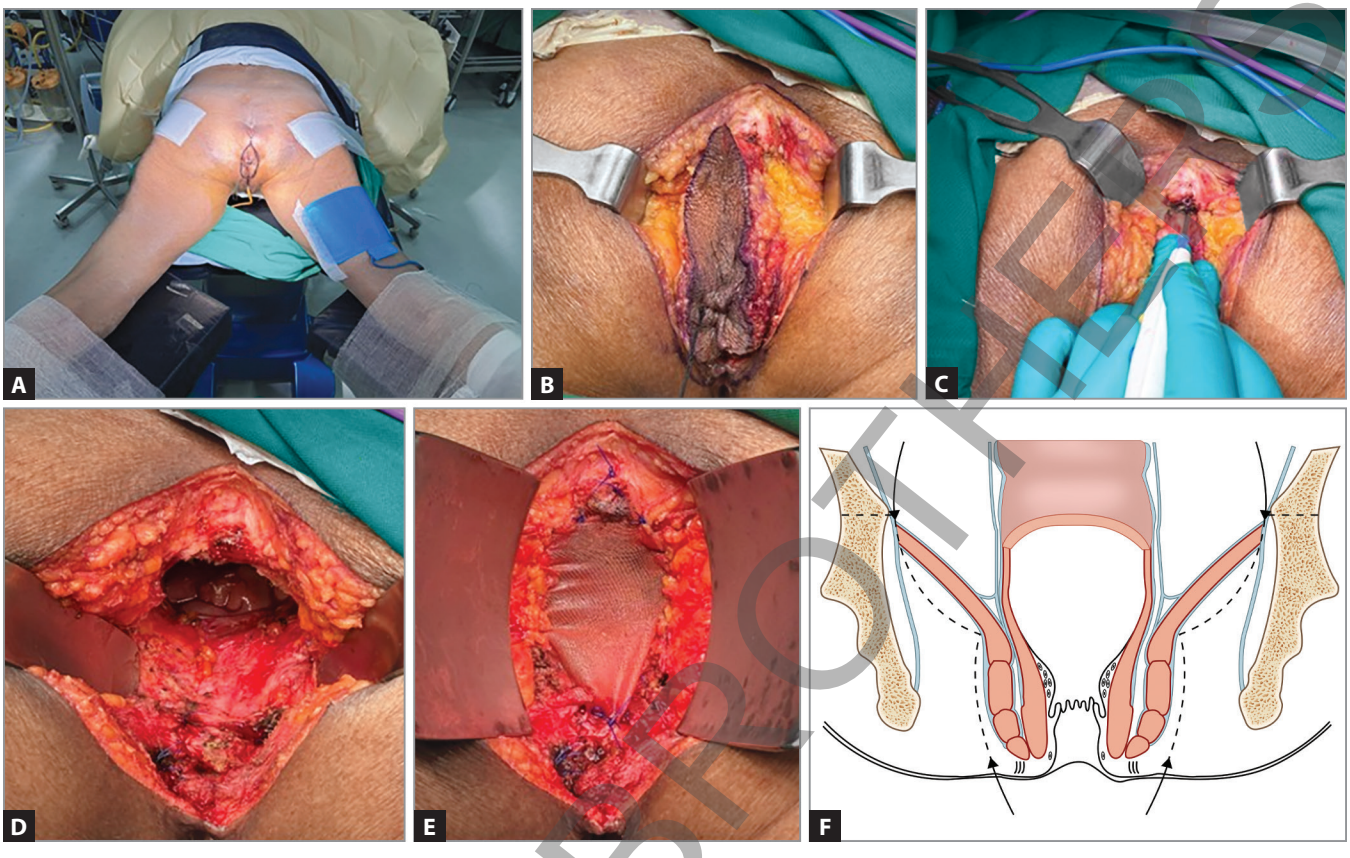

Figs. 19A to F: ELAPE: (A) Prone Jackknife position with a teardrop incision; (B) Incision to reach the gluteal muscles; (C) Transection of the coccyx to enter into the pelvis and resect along the levator muscles; (D) Completed ELAPE, note the prostate and the urethra; (E) Reconstruction with a Vicryl mesh; and (F) Conceptual specimen of ELAPE (cylindrical).

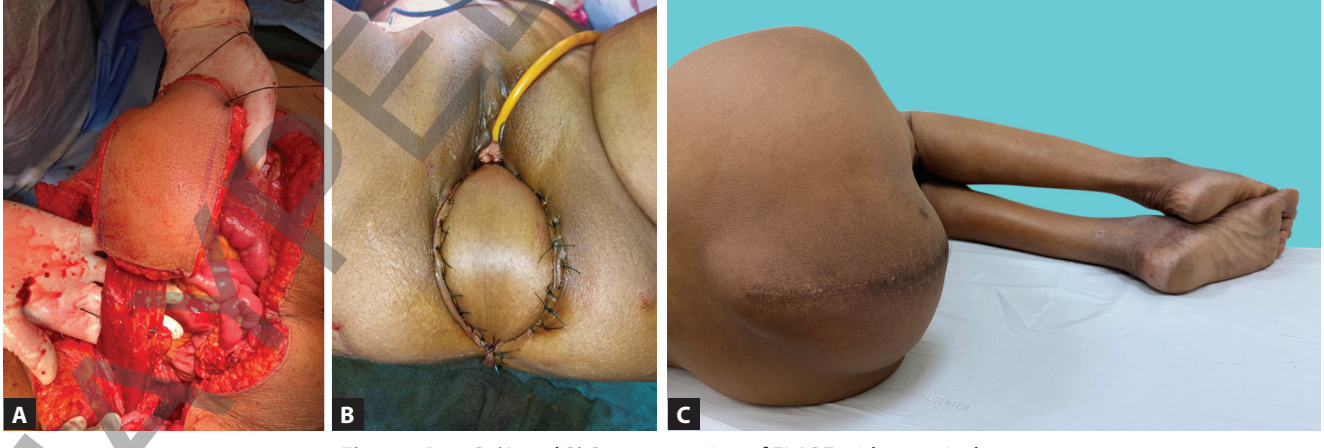

Figs. 20A to C: (A and B) Reconstruction of ELAPE with a vertical rectus abdominis myocutaneous (VRAM) flap and (C) Perineal hernia after ELAPE.

JAYPEE BROTHERS

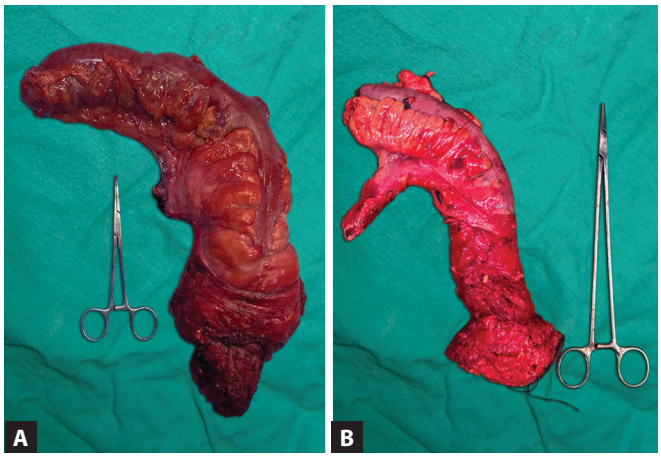

Figs. 21A and B: Comparison of the specimens of APR (A) and ELAPE (B), note the waist on the APR specimen and a cylindrical specimen on the ELAPE.

in locally advanced rectal cancer. Higher classification grades were associated with progressively poorer survival outcomes **(Table 10, Figs. 22A and B)**.

COMPLICATIONS OF RECTAL CANCER SURGERY

The major complications of rectal cancer surgery are:

- Anastomotic leak **(Box 15)**
- Low anterior resection syndrome **(Box 16)**
- Bleeding and hematoma formation
- Ileus
- Urinary and sexual dysfunction
- Intestinal obstruction
- Deep vein thrombosis

BOX 15: Anastomotic leak.

Anastomotic leak can occur in up to 20% of the patients. Symptoms include fever, tachycardia, tachypnea, enterocutaneous fistula, or frank peritonitis. Management includes adequate supportive measures and diversion stoma in patients who do not respond to conservative measures.

BOX 16: Low anterior resection syndrome (LARS).

- Low anterior resection syndrome is a common functional consequence of sphincter-preserving rectal surgery, with up to 80% of patients undergoing low or very low anterior resection, experiencing a combination of fecal urgency, increased stool frequency, clustering, fragmentation, difficulty with evacuation, fecal incontinence, and increased gas. Although many patients improve within 6–12 months.
- The pathophysiology is multifactorial, involving loss of the rectal reservoir, altered neorectal motility, colonic dysmotility, anal sphincter injury, and pelvic autonomic nerve dysfunction; total rather than partial mesorectal excision and neoadjuvant pelvic radiotherapy are associated with a higher risk of major LARS.
- The LARS score, a validated five-item questionnaire assessing incontinence for flatus and liquid stool, frequency, clustering, and urgency, is useful for identifying and grading postoperative bowel dysfunction.
- Management should be multimodal and stepwise, beginning with dietary modification, bowel-regulating agents such as loperamide when appropriate, pelvic floor muscle training and biofeedback, followed by transanal irrigation for persistent frequency and incontinence. Selected patients may benefit from 5-HT3 antagonists, bile-acid sequestrants, or treatment directed at specific symptoms such as bloating or diarrhea, although evidence for several pharmacological interventions remains limited. Sacral nerve stimulation may be considered in patients with persistent severe symptoms despite conservative and rehabilitative measures, while a permanent stoma remains an option for highly selected patients with refractory LARS and severely impaired quality of life **(Algorithm 5)**.

ADJUVANT CHEMOTHERAPY

Adjuvant chemotherapy remains a standard component of treatment for most fit patients with stage II/III rectal cancer following neoadjuvant chemoradiotherapy and surgery, although its benefit is less well defined than in colon cancer.

In the EORTC 22921 trial, the addition of adjuvant 5-fluorouracil (5-FU)-based chemotherapy after

TABLE 10: Peking classification of pelvic exenteration.

Classification	*Pattern of tumor invasion*	*Surgical procedure*	*Vaginal reconstruction*
PPE-I	Uterine invasion	Anterior resection + *hysterectomy*	Vagina preserved; primary closure
PPE-II	Upper vaginal or cervical invasion	Low anterior resection + *hysterectomy* + *upper vaginectomy*	Partial vaginal preservation and primary closure
PPE-III	Lower vaginal invasion	*Abdominoperineal resection (APR)* + posterior vaginal wall wedge resection	Primary closure
PPE-IV	Major/extensive vaginal invasion	APR with *complete posterior vaginal wall resection*	*V-Y plasty or gluteal fold flap* reconstruction

JAYPEE BROTHERS

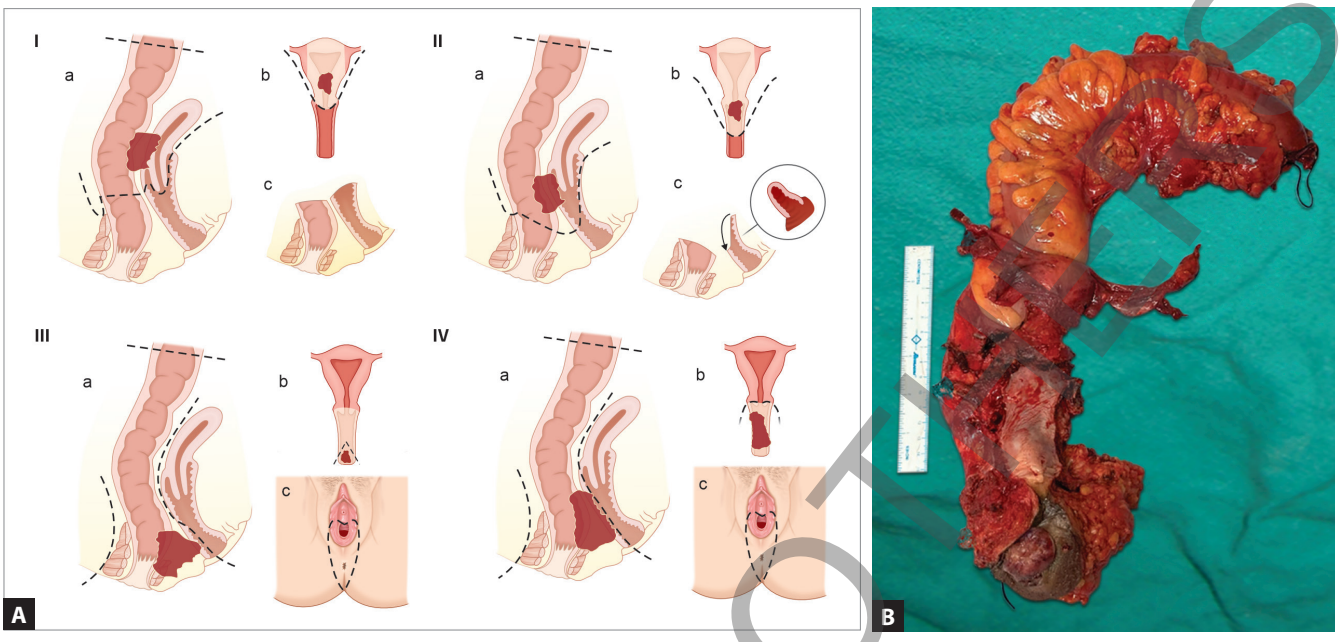

Figs. 22A and B: (A) Peking classification of pelvic exenteration and (B) Posterior exenteration with ELAPE (Note the tumor and the uterus with posterior wall of the vagina).

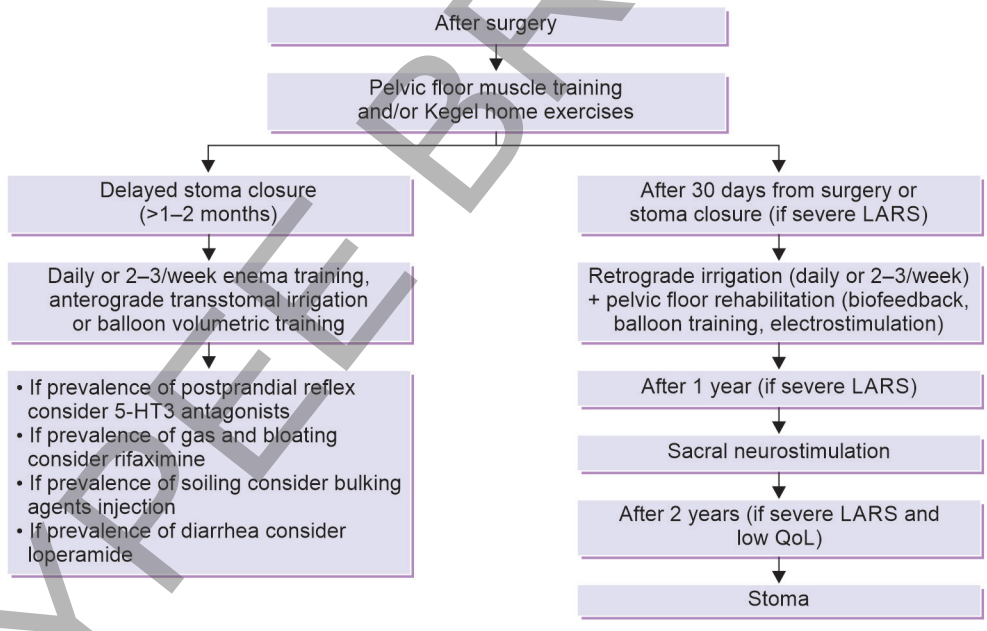

Algorithm 5: Management of LAR syndrome.

preoperative radiotherapy/chemoradiotherapy did not demonstrate a significant long-term overall-survival benefit, although a disease-free survival benefit was observed in some analyses. The ECOG E3201 trial demonstrated the feasibility of incorporating oxaliplatin into postoperative therapy, while the CAO/ARO/AIO-04 trial and the ADORE phase II trial further supported the use of oxaliplatin-containing regimens such as FOLFOX in the adjuvant setting.

However, evidence remains conflicting: A meta-analysis of four randomized trials involving 1,196 patients found that adjuvant fluoropyrimidine-based chemotherapy with 5-FU/leucovorin, capecitabine, or CAPOX after preoperative therapy and surgery did

JAYPEE BROTHERS

not significantly improve overall survival, disease-free survival, or distant recurrence, whereas meta-analyses by Peterson et al. and Petrelli et al. reported potential benefits of adjuvant 5-FU-based chemotherapy, including improved disease-free and overall survival; these findings were limited by substantial bias from nonrandomized studies. Carvalho et al. similarly found no robust evidence supporting a definite survival benefit from adjuvant chemotherapy.

Despite these conflicting data, adjuvant chemotherapy is generally recommended, with FOLFOX or CAPOX preferred and 5-FU/leucovorin or capecitabine considered alternatives in selected patients. Chemotherapy should be initiated as soon as the patient has adequately recovered from surgery, preferably within 4 weeks, as a meta-analysis of more than 15,000 patients demonstrated a reduction in overall survival when initiation was delayed beyond 4 weeks. The conventional duration of perioperative systemic therapy is approximately 6 months, although in the contemporary era of TNT, the need for additional postoperative chemotherapy should be individualized according to the amount and type of systemic chemotherapy already delivered preoperatively.

WATCH-AND-WAIT STRATEGY

The watch-and-wait strategy is an organ-preservation approach for selected patients with rectal cancer who achieve a cCR after neoadjuvant treatment. It was proposed by a Brazilian colorectal surgeon Angelita Habr-Gama. The objective is to avoid potentially unnecessary TME and its associated morbidity, permanent stoma, and urinary, sexual, and anorectal dysfunction. The essential prerequisite for watch-and-wait is a strictly defined cCR, established through clinical, endoscopic, and radiological assessment.

Assessment of complete clinical response: Tumor response is time-dependent, with most patients achieving the criteria for cCR by approximately 16 weeks after radiotherapy, while very few require more than 6 months. Clinically, there should be no palpable tumor, ulceration, irregularity, or stenosis, with only minimal scar induration; endoscopy typically shows a flat white scar without ulceration, with minor telangiectasia or hyperemia. MRI is the preferred imaging modality, with low-signal fibrosis on T2-weighted images and mrTRG 1–2 suggesting complete or near-complete response; diffusion-weighted imaging provides additional information. Routine biopsy is not required because it may produce misleading results. A recently published study, STAR-TREC, demonstrated that in selected early rectal cancers, long-course chemoradiation gave better chances of avoiding major rectal surgery than SCRT.

Surveillance: Patients undergoing watch-and-wait require intensive surveillance, particularly during the first 3 years, using digital rectal examination, proctoscopy, and high-resolution MRI, along with routine systemic surveillance. Assessment is typically performed every 8–12 weeks for the first 3 years, followed by 6-monthly surveillance until 5 years and then annually; after a sustained cCR for 3 years, the risk of local regrowth falls to <5% **(Figs. 23A and B)**.

Local regrowth occurs in approximately 25–35% of patients within 3 years after achieving a cCR, with the risk increasing from approximately 20% in cT2, 30% in cT3,

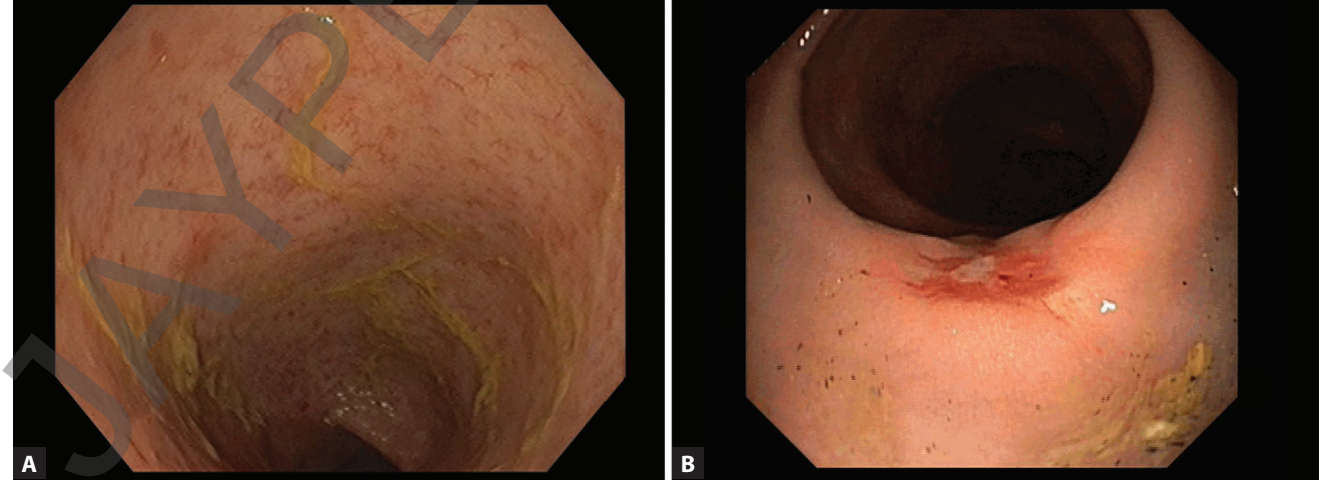

Figs. 23A and B: (A) Colonoscopic view of complete response after TNT. The patient was subsequently placed for watch and wait and (B) Colonoscopic view of near complete response (Note the minimal ulcer present).

JAYPEE BROTHERS

and nearly 40% in cT4 tumors; most regrowths have an endoluminal component and can therefore be detected clinically or endoscopically. Salvage surgery is feasible in >90% of patients and frequently achieves an R0 resection with excellent local control, although previous transanal excision may make subsequent TME more difficult. Patients with cCR managed by watch-and-wait have a low risk of distant metastases, comparable to those achieving pCR after surgery, but this risk increases to approximately 30% in patients who develop local regrowth.

LIMITED UNRESECTABLE RECTAL CANCER

Neoadjuvant chemotherapy is the preferred approach for initially unresectable metastatic disease, as resectability is subjective and depends partly on the aggressiveness of the surgical approach. Downstaging occurs in approximately 10–15% of patients, with objective responses leading to an R0 resection in about 12–33%. Radiological response should be reassessed, and surgery should be performed as soon as the metastases become technically resectable. When the primary rectal tumor is resectable, SCRT is preferred before surgery.

Surgical Treatment of Locally Recurrent Rectal Cancer

Pelvic exenteration is the principal radical surgical procedure for selected patients with locally recurrent rectal cancer and may be classified as follows **(Fig. 24 and Box 17)**:

- *Supralevator pelvic exenteration:* Resection is confined to the pelvic viscera above the levator ani muscles, with preservation of the pelvic floor and perineum.
- *Anterior pelvic exenteration:* Resection involves the anterior pelvic organs, principally the bladder and adjacent reproductive organs, while the rectum is preserved.
- *Posterior pelvic exenteration:* Resection involves the posterior pelvic organs, including the rectum and adjacent reproductive organs, while the urinary bladder is preserved.
- *Anterior supralevator exenteration:* An anterior compartment resection performed above the levator ani, with preservation of the pelvic floor.
- *Posterior supralevator exenteration:* A posterior compartment resection performed above the levator ani, with preservation of the pelvic floor.
- *Total pelvic exenteration:* En-bloc resection of both anterior and posterior pelvic compartments, including the bladder, rectum, and involved reproductive organs.

BOX 17: Composite pelvic exenteration.

This involves pelvic exenteration combined with en-bloc bony resection, which may include portions of the pubic symphysis, sacrum and coccyx, ischium, or ischiopubic rami. Sacral resection can be performed using either a combined abdominal–trans-sacral approach, as described by Wanebo and Marcove, or an anterior osteotome approach, as described by Temple and Ketcham, after completion of pelvic dissection and identification of the pelvic nerves.

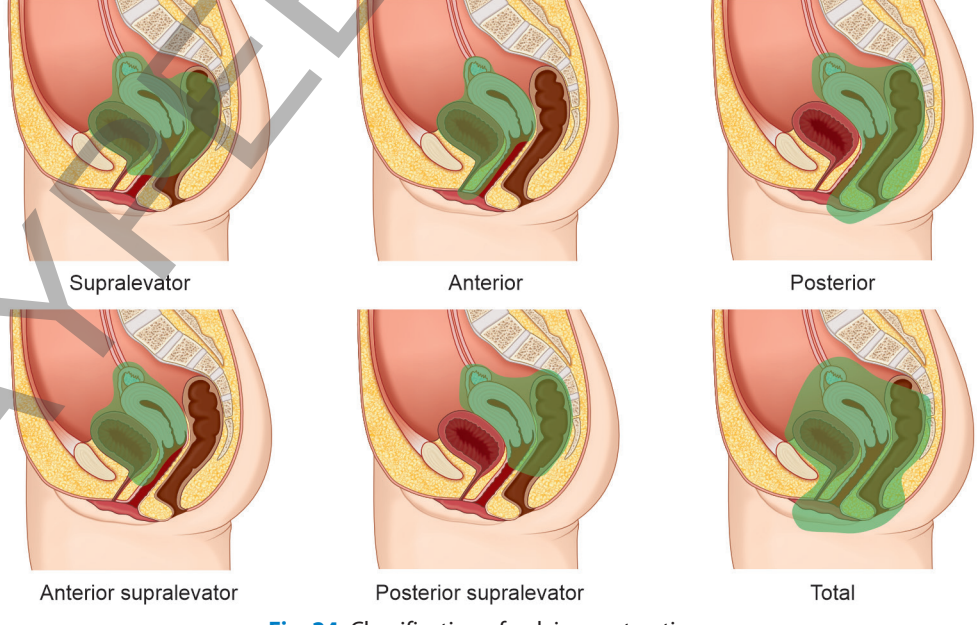

Fig. 24: Classification of pelvic exenteration.

JAYPEE BROTHERS

Reconstruction and Complications

Reconstruction is a critical phase of pelvic exenteration because it largely determines long-term morbidity.

- Urinary diversion is most commonly achieved using an isolated ileal conduit, although continent options may be used.
- Reconstruction of the pelvic floor is essential to obliterate the pelvic dead space and reduce abscess, wound complications, fistula, and bowel obstruction, using absorbable mesh, omentum, or well-vascularized myocutaneous flaps such as rectus abdominis, gracilis, or gluteus maximus flaps.
- Vaginal reconstruction, either immediate or delayed, may be performed using skin grafts or myocutaneous flaps for psychological, functional, and wound-healing benefits.

Pelvic exenteration remains associated with substantial morbidity, including pelvic abscess, bowel obstruction, fistula, wound breakdown, flap necrosis, urinary complications, venous thrombosis, and psychological morbidity; gastrointestinal and urinary complications are particularly influenced by previous radiotherapy.

LOCAL RECURRENCE

Local recurrence after rectal cancer resection has decreased substantially over the past two decades; however, 5–15% of patients with locally advanced disease may still develop recurrence after local resection. Nearly half of these patients present with unresectable systemic metastases, for whom treatment is primarily palliative with chemotherapy and/or radiotherapy. In carefully selected patients with potentially resectable isolated recurrence, aggressive surgical management—including abdominoperineal excision, pelvic exenteration, or sacrectomy—may be considered. When an R0 resection is achieved, long-term outcomes can be favorable, with reported 5-year survival exceeding 35%.

METASTATIC RECTAL CANCER

Rectal Cancer with Liver or Lung Metastasis

For patients with synchronous resectable liver or lung metastases, perioperative systemic chemotherapy is generally recommended to treat micrometastatic disease, with TNT being a preferred strategy for synchronous metastases **(Fig. 25)**. Preoperative therapy allows early treatment of micrometastases, assessment of chemotherapy response, and avoidance of local therapy in patients with early progression but may cause progression, make resection planning difficult after complete response, and produce oxaliplatin-related sinusoidal injury or irinotecan-related steatohepatitis. Neoadjuvant treatment is generally limited to 2–3 months to minimize hepatotoxicity, and treatment sequencing should be individualized through a multidisciplinary approach.



Fig. 25: Carcinoma rectum with extensive liver metastasis.

Widespread Metastatic Rectal Cancer

Treatment of widespread metastatic rectal cancer follows principles similar to those used for metastatic colon cancer, with systemic therapy and appropriate targeted or biological treatment forming the mainstay of management. Detailed management is discussed in the Chapter 31.

VIDEO CONTENTS

Video 32.1: Evaluation of Rectal Cancer on Colonoscopy.
Video 32.2: Interpretation of MRI Pelvis for Rectal Cancer.
Video 32.3: Laparoscopic Low Anterior Resection.
Video 32.4: Robotic Low Anterior Resection.
Video 32.5: Basics of Circular Stapler and Colorectal Anastomosis.
Video 32.6: Hand-sewn Colo-anal Anastomosis.

JAYPEE BROTHERS

SUGGESTED READING

1. Bunjo Z, Sammour T. The Landmark Series: Neoadjuvant Therapy for Locally Advanced Rectal Cancer. Ann Surg Oncol. 2025;32:4935-44.
2. DeVita VT Jr, Lawrence TS, Rosenberg SA (Eds). DeVita, Hellman, and Rosenberg's Cancer: Principles and Practice of Oncology, 12th edition. Philadelphia: Lippincott Williams & Wilkins; 2023.
3. Heald RJ, Ryall RDH. Recurrence and survival after total mesorectal excision for rectal cancer. Lancet. 1986;1(8496):1479-82.
4. National Comprehensive Cancer Network. NCCN Guidelines. Rectal Cancer. Version 2.2026. Plymouth Meeting, PA: National Comprehensive Cancer Network; 2026.
5. Yeo CJ, DeMeester SR, McFadden DW, Matthews JB, Fleshman JW (Eds). Shackelford's Surgery of the Alimentary Tract, 8th edition. Philadelphia: Elsevier; 2019.

JAYPEE BROTHERS

CHAPTER 69

Current Strategies in Intraperitoneal Chemotherapy

JAYPEE BROTHERS

INTRODUCTION

Peritoneal surface malignancies were once considered a terminal manifestation of advanced cancer and were managed primarily with palliative systemic chemotherapy. However, advances in the understanding of the unique pharmacokinetic properties of the peritoneal cavity have transformed the management of these diseases. The peritoneal–plasma barrier enables the delivery of high concentration of chemotherapeutic agents directly to the peritoneal cavity while minimizing systemic toxicity, providing the biological rationale for regional intraperitoneal chemotherapy (IPC). Over the past three decades, intraperitoneal treatment strategies have evolved from conventional liquid chemotherapy to sophisticated regional therapies such as hyperthermic intraperitoneal chemotherapy (HIPEC), early postoperative intraperitoneal chemotherapy (EPIC), normothermic intraperitoneal chemotherapy (NIPEC), and pressurized intraperitoneal aerosol chemotherapy (PIPAC).

PHARMACOLOGY RELATED TO DELIVERY OF INTRAPERITONEAL CHEMOTHERAPY

Pharmacokinetics describes how the body absorbs, distributes, metabolizes, and eliminates a chemotherapeutic agent, whereas pharmacodynamics refers to the biological effects of the drug on tissues and tumor cells. Understanding these principles is essential because the technique is more complex and associated with higher morbidity than systemic administration. Therefore, the use of intraperitoneal chemotherapy is justified only when it provides a clear pharmacokinetic advantage, achieving higher local drug concentrations within the peritoneal cavity while limiting systemic exposure and toxicity. Various pharmacological factors determine the outcome of dissemination of drugs through the peritoneal cavity. They are given in **Table 1**.

TABLE 1: Pharmacokinetic and pharmacodynamic variables affecting intraperitoneal dissemination of chemotherapeutic agents.

Pharmacokinetic variables	*Pharmacodynamic variables*
Dose	Tumor nodule size
Volume	Tumor density
Duration of exposure	Tumor vascularity
Carrier solution	Interstitial fluid pressure
Intra-abdominal pressure	Drug-binding characteristics
Molecular weight of drug	Temperature

PERITONEAL–PLASMA BARRIER

The peritoneum is a large serosal organ composed of a single layer of mesothelial cells overlying a basement membrane and a connective tissue matrix containing collagen, proteoglycans, interstitial cells, and blood vessels. It lines the abdominal cavity, covers the visceral organs, and forms the peritoneal cavity. Besides providing lubrication and facilitating organ movement, the peritoneum contributes to immune defense through lymphoid aggregates (milky spots) and serves as the first line of defense against peritoneal metastasis. The peritoneal membrane acts as a plasma–peritoneal barrier, creating the pharmacokinetic basis for intraperitoneal chemotherapy by allowing high local drug concentrations with limited systemic exposure. Experimental and clinical studies have shown that removal of the mesothelial lining during peritonectomy does not significantly alter drug transport, as the principal barrier is formed by the subperitoneal vasculature and interstitial matrix rather than the mesothelium itself. Solutes are cleared from the peritoneal cavity through diffusion into blood vessels and absorption via peritoneal lymphatics, particularly on the diaphragmatic surface **(Fig. 1)**.

Dedrick Diffusion Model

The pharmacokinetic rationale is based on the plasma–peritoneal barrier, which allows high local drug concentrations within the peritoneal cavity while limiting systemic exposure. Dedrick and colleagues demonstrated that hydrophilic chemotherapeutic agents are cleared

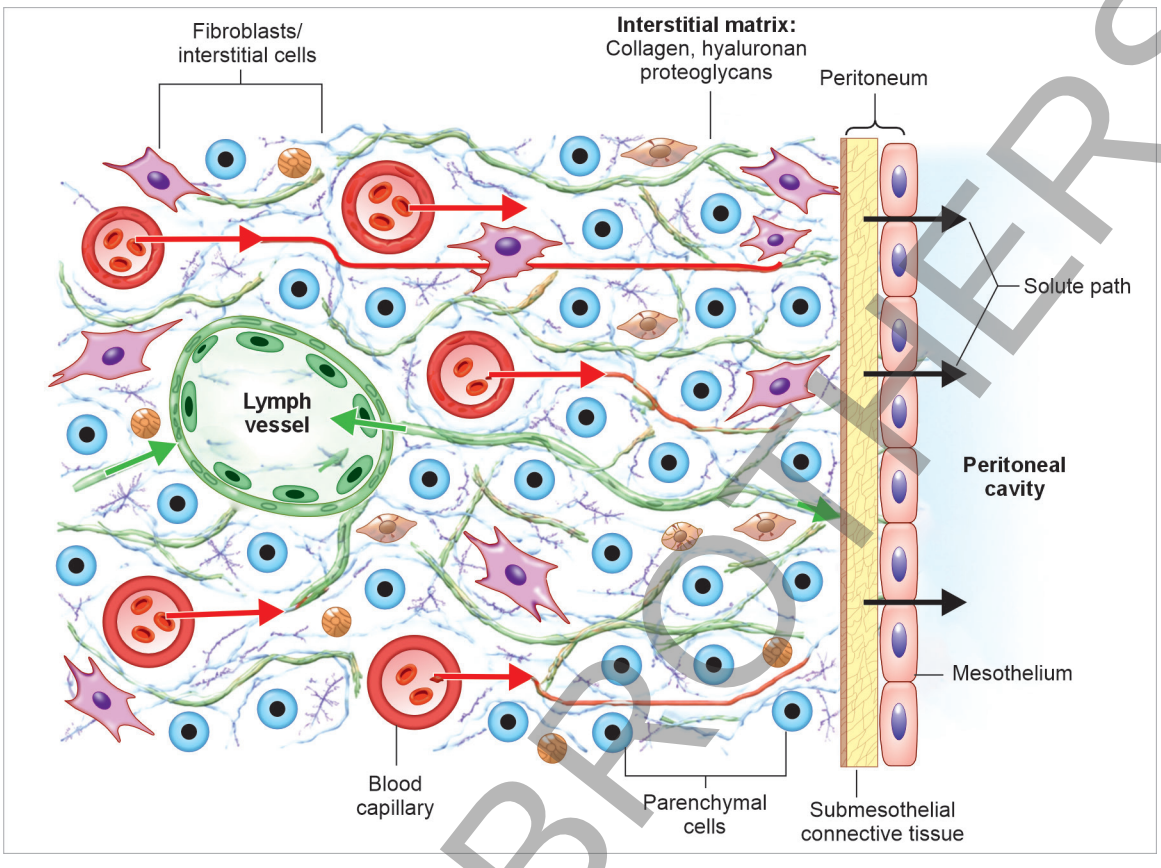

Fig. 1: Plasma–peritoneal barrier.

slowly from the peritoneal cavity but more rapidly from the systemic circulation, resulting in a substantial concentration gradient favoring the peritoneal compartment. Peritoneal drug clearance is inversely related to molecular weight, enabling prolonged retention of larger molecules and producing higher intraperitoneal-to-plasma exposure, commonly expressed as the area under the concentration–time curve ratio. Drug transfer across the peritoneal membrane depends on the permeability-area product and the concentration gradient between the peritoneal cavity and blood. However, increased intraperitoneal drug concentrations do not necessarily translate into greater tumor uptake, as penetration into tumor nodules remains limited. Therefore, the ideal intraperitoneal chemotherapeutic agent should combine prolonged peritoneal retention with effective tissue penetration and tumor accumulation. Rapid systemic metabolism of absorbed drug helps maintain the concentration gradient, thereby enhancing locoregional efficacy while minimizing systemic toxicity **(Fig. 2A)**. This allows for the concept of high intraperitoneal drug concentrations commonly employed in bidirectional chemotherapy **(Fig. 2B)**.

TIMING OF CANCER CHEMOTHERAPY IN RELATION TO TIMING OF SURGICAL INTERVENTION

- *Neoadjuvant intraperitoneal and systemic chemotherapy (NIPS):* NIPS is administered before cytoreductive surgery (CRS) in patients with extensive peritoneal metastases to reduce tumor burden, improve resectability, and increase the likelihood of complete cytoreduction. Its effectiveness may be limited by intraperitoneal adhesions, incomplete drug distribution, treatment-induced fibrosis, and increased operative difficulty during subsequent surgery. It is commonly used in gastric cancers.
- *HIPEC:* HIPEC is the most widely used modality and is delivered intraoperatively immediately after CRS. It combines maximal tumor debulking with heated, high-concentration regional chemotherapy to eradicate

JAYPEE BROTHERS

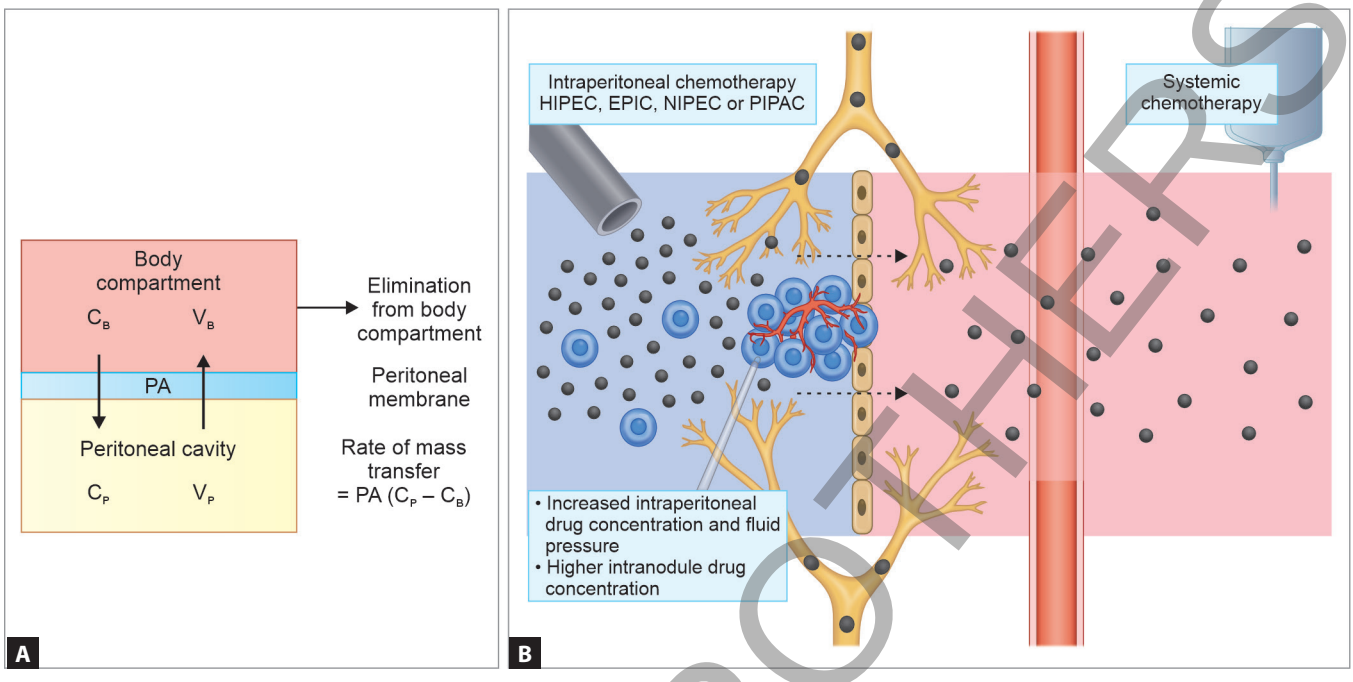

Figs. 2A and B: (A) Dendrick diffusion model: The traditional two-compartment model of peritoneal transport; transfer of a drug from the peritoneal cavity to the blood occurs across the "peritoneal membrane." The permeability-area product (PA) governs this transfer. PA is calculated by measuring the rate of drug disappearance from the cavity, which is divided by the overall concentration difference between the peritoneal cavity and the blood (or plasma). C_B = the free drug concentration in the blood (or plasma); C_P = the free drug concentration in the peritoneal fluid; HIPEC V_B = volume of distribution of the drug in the body; V_P = volume of the peritoneal cavity and (B) Concept of bidirectional chemotherapy drug delivery. (EPIC: early postoperative intraperitoneal chemotherapy; HIPEC: hyperthermic intraperitoneal chemotherapy; NIPEC: normothermic intraperitoneal chemotherapy; PIPAC: pressurized intraperitoneal aerosol chemotherapy)

residual microscopic disease while minimizing systemic toxicity.

- *EPIC:* EPIC is administered through intraperitoneal drains during the first 3–5 postoperative days before adhesions develop, allowing uniform distribution of chemotherapy throughout the peritoneal cavity. Cell cycle-specific agents such as 5-fluorouracil (5-FU) and taxanes are commonly used to target residual microscopic tumor deposits.
- *Sequential postoperative intraperitoneal chemotherapy (SPIC):* SPIC consists of repeated cycles of postoperative IPC combined with systemic chemotherapy and is primarily used as adjuvant treatment in ovarian cancer or as a bridging strategy following incomplete cytoreduction before definitive surgery.

HYPERTHERMIC INTRAPERITONEAL CHEMOTHERAPY

Hyperthermic intraperitoneal chemotherapy is administered immediately after CRS to eradicate residual microscopic peritoneal disease. Heated chemotherapy is circulated throughout the abdominal cavity, allowing direct exposure of tumor cells to high concentrations of chemotherapeutic agents while minimizing systemic toxicity. Compared with historical treatment, CRS combined with HIPEC has improved survival in selected patients with peritoneal surface malignancies. HIPEC was first introduced and performed by Dr John S Spratt at the University of Louisville in 1979–1980, when he treated a patient with pseudomyxoma peritonei **(Figs. 3A to D)**.

Rationale of Hyperthermic Intraperitoneal Chemotherapy

The hypotheses offered to explain the better outcomes are:

- The procedure is based on the preferred timing of regional therapy immediately after tumor debulking and prior to the formation of postoperative adhesions that hinder drug distribution and efficacy.
- The peritoneal route of chemotherapy is based on the plasma peritoneal barrier concept that allows high

JAYPEE BROTHERS

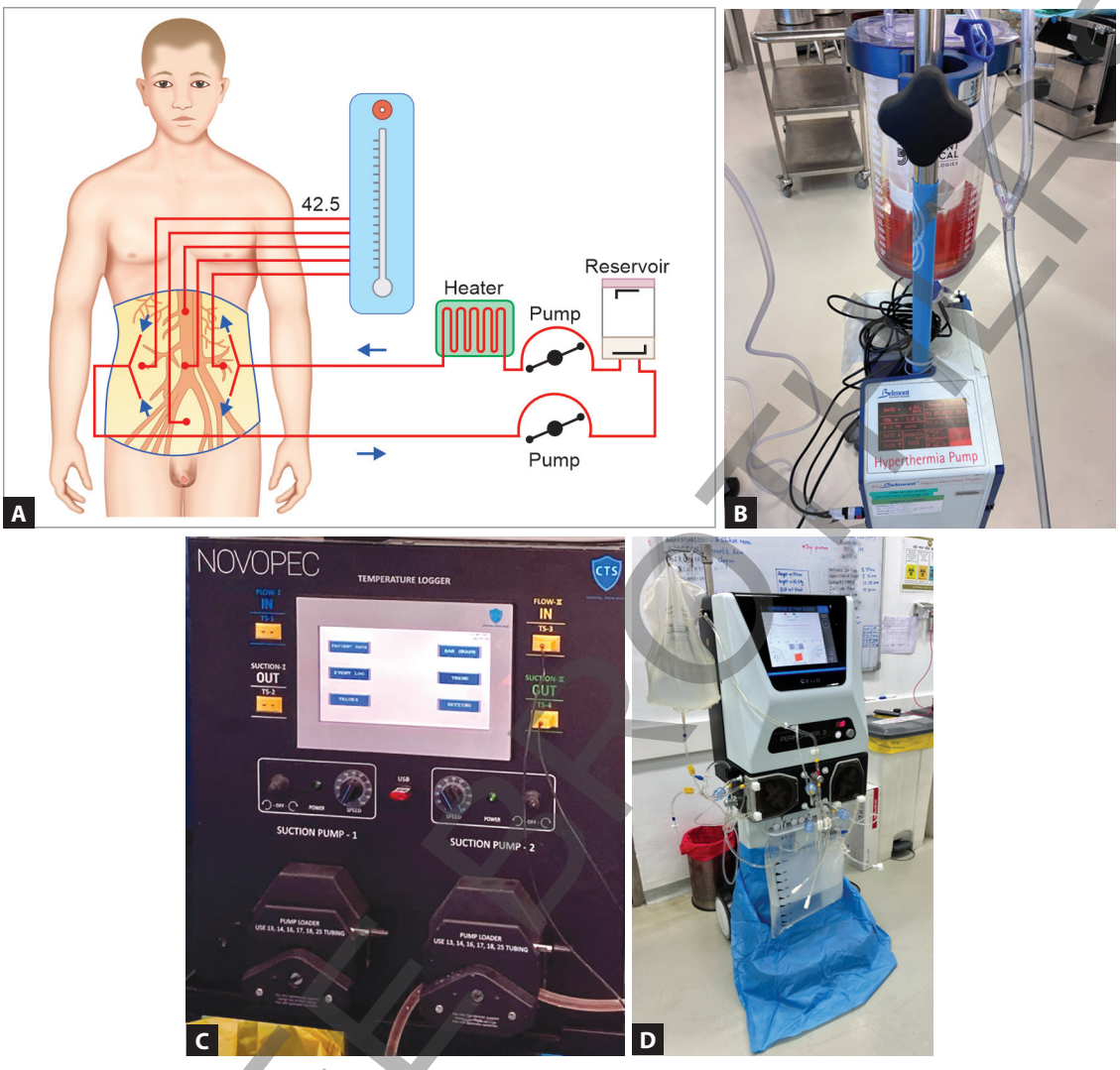

Figs. 3A to D: HIPEC: (A) Concept of HIPEC, a reservoir containing the carrier solution and chemotherapy is perfused into the abdominal cavity with increased temperature with roller pumps connected to the inflow catheter, the same is delivered back to the machine via an outflow; (B) Belmont hyperthermia pump; (C) Indian NOVOPEC HIPEC device (Curotherm Solutions); and (D) RAND Performer 3 machine.

concentration of the chemotherapy to be in direct contact with cancerous cells with minimal systemic absorption and side effects.

- There is a synergistic antitumor effect of chemotherapy combined with hyperthermia. Hyperthermic temperatures around 42°C immediately following maximal CRS enhance the antitumor effects of drugs by augmenting cytotoxicity secondary to the loss of DNA repair activities.
- Hyperthermia reverses platinum resistance.
- Hyperthermia enhances the penetration of drugs into tumor deposits.
- Moderate hyperthermia (41–43°C) is optimal and selectively induces cytotoxicity of malignant cells due to:
  - Impaired DNA repair
  - Protein denaturation
  - Inhibition of oxidative metabolism in the microenvironment of malignant cells, leading to:
    - Increased acidity
    - Lysosomal activation
    - Increased apoptotic cell death and inhibition of angiogenesis.

Factors Influencing Hyperthermic Intraperitoneal Chemotherapy

The HIPEC procedure is defined by six major parameters:

1. Choice of chemotherapeutic drug
2. Drug dosage

JAYPEE BROTHERS

3. Carrier solution and perfusate volume
4. Duration of perfusion
5. Perfusion temperature
6. Perfusion technique (open or closed).

Choice of Drugs for Hyperthermic Intraperitoneal Chemotherapy

The ideal chemotherapeutic agent for HIPEC should be cell cycle nonspecific and remain stable and active at high temperatures, exhibit minimal local toxicity, possess activity against the target malignancy, not require systemic metabolic activation, and demonstrate synergistic cytotoxicity with heat. The efficacy depends largely on the intraperitoneal-to-plasma area under the curve ratio, with agents such as mitomycin-C, cisplatin, oxaliplatin, 5-FU, taxanes, irinotecan, and doxorubicin exhibiting favorable pharmacokinetic profiles. Since the maximum tissue penetration is only 3–5 mm, complete cytoreduction is essential, and residual tumor deposits should ideally measure ≤2.5 mm **(Box 1 and Table 2)**.

BOX 1: Characteristics of an ideal hyperthermic intraperitoneal chemotherapy (HIPEC) drug.

An ideal chemotherapeutic agent for HIPEC should possess the following characteristics:
- Effective against the target tumor histology.
- High molecular weight to enhance peritoneal retention and minimize systemic absorption
- Water-soluble and chemically stable in the carrier solution.
- Stable under mild hyperthermic conditions (41–43°C).
- Demonstrates synergistic cytotoxicity with hyperthermia.
- Has an acceptable toxicity profile with limited systemic adverse effects
- Safe to handle, with minimal occupational risk to healthcare workers.

Body Surface Area-based versus Concentration-based Intraperitoneal Chemotherapy

The optimal dosing strategy remains uncertain. Body surface area (BSA)-based dosing, the conventional method, is simple and widely used but correlates poorly with the actual peritoneal surface area, and larger perfusate volumes may reduce intraperitoneal drug concentration. In contrast, concentration-based dosing maintains a constant intraperitoneal drug concentration, potentially improving tumor penetration but with a greater risk of systemic toxicity **(Box 2)**.

BOX 2: COBOX trial.

This study randomized patients to receive HIPEC using either body surface area-based dosing or concentration-based dosing. Concentration-based chemotherapy provided a more standardized intraperitoneal drug concentration, resulting in higher drug penetration and increased intratumoral drug levels without increasing treatment-related morbidity.

Carrier Solution

The carrier solution plays a pivotal role in determining the pharmacokinetics and efficacy during HIPEC. It influences drug clearance from the peritoneal cavity, drug distribution, tissue penetration, and the duration of drug exposure. An ideal carrier solution should maximize peritoneal surface contact, maintains an adequate intraperitoneal volume, prolong drug retention by slowing peritoneal clearance, and produce minimal toxicity to the peritoneal membrane. Isotonic high-molecular-weight dextrose-based solutions are preferred because they provide sustained intraperitoneal exposure and favorable pharmacokinetic characteristics. Although hypotonic solutions may theoretically enhance drug uptake, clinical studies have not demonstrated superior outcomes and

TABLE 2: Common drugs used in hyperthermic intraperitoneal chemotherapy (HIPEC) and their carrier solution and side effects.

Drug	*Maximum dose*	*Split dosing*	*Target intra-abdominal temperature*	*Duration of perfusion*	*Carrier solution*	*Recommended drug combinations*	*Prevention of side effects*
Cisplatin	100 mg/m^2	Recommended	41–42°C	90 minutes	Normal saline (0.9% NaCl)	Mitomycin-C, doxorubicin	Sodium thiosulfate
Mitomycin-C	35 mg/m^2	Recommended	41–42°C	90 minutes	Not specified	None	None
Oxaliplatin	200 mg/m^2	Not recommended	41–42°C	90 minutes	5% Dextrose	5-Fluorouracil (5-FU)	None
Paclitaxel	175 mg/m^2	Not recommended	41–42°C	90 minutes	Normal saline (0.9% NaCl)	Cisplatin, mitomycin-C	None

JAYPEE BROTHERS

have reported an increased risk of postoperative bleeding and thrombocytopenia.

The most commonly used carrier solution is 1.5% dextrose peritoneal dialysis solution, while normal saline and 5% dextrose are used selectively depending on the chemotherapeutic agent. The perfusate volume is generally 1.5–2 L/m^2 and is individualized according to the patient's BSA and the HIPEC technique employed (open or closed), ensuring adequate distribution of the chemotherapeutic agent throughout the peritoneal cavity.

Duration of Perfusion

The duration of HIPEC perfusion is a critical determinant of therapeutic efficacy and is influenced by the pharmacokinetic properties, intraperitoneal half-life, and systemic toxicity profile of the chemotherapeutic agent used. Since most intraperitoneal chemotherapeutic drugs have a half-life of 90 minutes or less, prolonged perfusion beyond this period offers limited additional benefit while increasing the risk of systemic toxicity. Consequently, the duration of perfusion should be individualized according to the drug characteristics and the patient's tolerance.

The most commonly employed HIPEC protocols include perfusion at 41°C for 90 minutes or 43°C for 30–40 minutes, balancing optimal cytotoxicity with acceptable toxicity. Selection of the perfusion duration should aim to maximize local antitumor effects while minimizing systemic exposure and bone marrow toxicity.

The duration is an important determinant of treatment efficacy, as adequate exposure time is required to maximize tumor cell kill. However, prolonged perfusion may increase systemic drug absorption and toxicity.

Temperature

Hyperthermia enhances the efficacy through direct tumor cell injury and synergistic interaction with chemotherapeutic agents by increasing drug penetration, impairing DNA repair, and promoting apoptosis. Most HIPEC protocols use temperatures of 41–43°C, which enhance the activity of agents such as mitomycin-C, cisplatin, doxorubicin, oxaliplatin, gemcitabine, and melphalan. While hyperthermia offers important pharmacological advantages, its additional clinical benefit over normothermic intraperitoneal chemotherapy continues to be evaluated in ongoing studies.

Modes of Perfusion

There are three main modes of perfusion of chemotherapy during HIPEC. They are summarized below and in **(Table 3 and Figs. 4A to C)**:

1. *Open abdomen (coliseum) technique:* In the open technique, the abdominal wall is elevated using traction sutures, allowing direct visualization, manual stirring, and uniform distribution of heated chemotherapy throughout the peritoneal cavity. Although it provides excellent drug distribution, appropriate protective measures are required to minimize occupational exposure.
2. *Closed abdomen technique:* In the closed technique, the abdomen is temporarily closed before perfusion, allowing rapid achievement of hyperthermia, reduced chemotherapy leakage, and improved operating room safety. However, drug distribution may be less uniform, although clinical outcomes are generally comparable to the open technique.

TABLE 3: Various modes of perfusion for HIPEC and their advantages and disadvantages.

Feature	*Closed technique*	*Open (coliseum) technique*	*Semi-open technique*
Abdominal cavity	Closed	Open	Partially covered
Heat retention	Excellent	Poor	Moderate
Drug distribution	Less uniform	Excellent	Good
Intra-abdominal pressure	High	Normal	Intermediate
Staff exposure	Minimal	Highest	Moderate
Drug leakage	Minimal	Higher	Low
Main advantage	Better heat retention, increased tissue penetration, least exposure	Uniform drug distribution and temperature	Combines advantages of open and closed techniques
Main disadvantage	Uneven distribution, higher ileus/ fistula risk	Heat loss and greater chemotherapy exposure	Moderate heat loss and staff exposure

JAYPEE BROTHERS

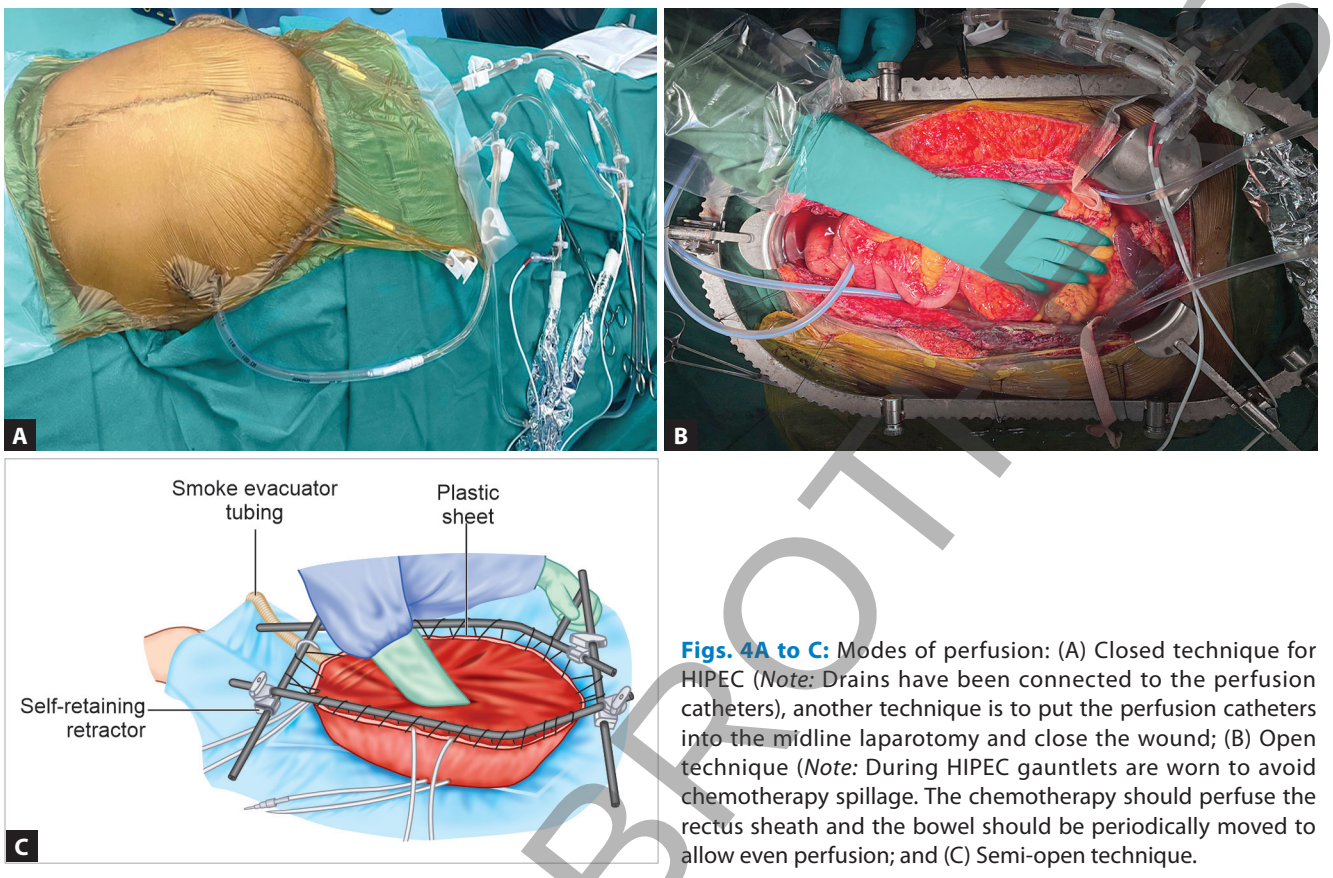

Figs. 4A to C: Modes of perfusion: (A) Closed technique for HIPEC (*Note:* Drains have been connected to the perfusion catheters), another technique is to put the perfusion catheters into the midline laparotomy and close the wound; (B) Open technique (*Note:* During HIPEC gauntlets are worn to avoid chemotherapy spillage. The chemotherapy should perfuse the rectus sheath and the bowel should be periodically moved to allow even perfusion; and (C) Semi-open technique.

3. *Semi-open/semiclosed techniques:* Hybrid techniques, such as the peritoneal cavity expander and abdominal cavity expander methods, combine the advantages of open and closed HIPEC by improving drug distribution while minimizing chemotherapy exposure to operating room personnel.

Peritoneal Surface Oncology Group International Recommendations for Hyperthermic Intraperitoneal Chemotherapy

The term hyperthermic intraperitoneal chemotherapy was standardized at the 4th International Workshop on Peritoneal Surface Malignancies held in Madrid, Spain, in 2004. It replaced several previously used terms, establishing a uniform nomenclature for this treatment modality. Since then, the Peritoneal Surface Oncology Group International (PSOGI) has become the leading organization in developing evidence-based consensus statements and clinical practice recommendations for HIPEC. The key PSOGI recommendations are summarized in **Box 3 and Tables 4 and 5**.

BOX 3: PSOGI consensus guidelines for HIPEC.

- Drug dose may be calculated using the body surface area (mg/m^2)-based dosing method.
- The target intra-abdominal temperature during HIPEC should be maintained between 41°C and 42°C.
- The recommended perfusate volume is 2 L/m^2 of body surface area.
- Four inflow catheters are recommended to ensure uniform distribution of the perfusate within the peritoneal cavity.
- Three intra-abdominal temperature probes should be used for continuous monitoring of perfusate temperature at different locations.
- Post-HIPEC abdominal drains are recommended as part of routine postoperative care.
- Bowel anastomoses should ideally be performed before HIPEC whenever feasible.
- The closed HIPEC technique is preferred over the open technique.

(PSOGI: Peritoneal Surface Oncology Group International)

JAYPEE BROTHERS

Tables 4 and 5 provide HIPEC regimes for various peritoneal malignancies.

Intraoperative Procedure to Deliver Hyperthermic Intraperitoneal Chemotherapy

The technique to deliver HIPEC has been demonstrated in **Video 69.1**.

1. Prime the extracorporeal perfusion circuit with the appropriate carrier solution before initiating perfusion.
2. Warm the perfusate using a heat exchanger until the target temperature of 41–42°C is achieved.
3. Position inflow catheters to ensure uniform distribution of the perfusate.
4. Place outflow catheters in the dependent portions of the abdominal cavity to facilitate continuous drainage.
5. Use a perfusate volume of approximately 2 L/m^2 of BSA.
6. Establish continuous circulation using a roller or centrifugal pump adjusting the flow rates, according to patient size and circuit pressures **(Figs. 5A to D)**.
7. Administer the chemotherapeutic agent only after the target intraperitoneal temperature has been reached.
8. Maintain a stable intra-abdominal temperature between 41°C and 42°C throughout the perfusion period.
9. Continue perfusion for 60–90 minutes, depending on the chemotherapeutic agent and institutional protocol.
10. Monitor temperatures continuously using temperature probes placed at the inflow and outflow **(Figs. 6A to D)**.
11. Periodically redistribute the bowel manually during the open technique or gently rock the operating table during the closed technique to promote homogeneous drug distribution.
12. Ensure unobstructed inflow and outflow by preventing catheter kinking and maintaining a leak-free circuit.

TABLE 4: HIPEC regimes for primary peritoneal and gastrointestinal cancers.

Primary site	*Preferred HIPEC regimen (first preference)*
Colorectal cancer	MMC 35 mg/m^2 (high-dose regimen) irrespective of whether systemic chemotherapy was administered within the preceding 6 months
PMP	Cisplatin 25 mg/m^2/L + MMC 3.3 mg/m^2/L
Peritoneal mesothelioma	Cisplatin 50 mg/m^2 + doxorubicin 15 mg/m^2 for 90 minutes following complete cytoreductive surgery
Gastric cancer	Cisplatin + MMC for both prophylactic HIPEC in locally advanced gastric cancer and curative HIPEC after CRS for gastric peritoneal metastases

(CRS: cytoreductive surgery; MMC: mitomycin-C; PMP: pseudomyxoma peritonei)

TABLE 5: Epithelial ovarian cancer: Recommended HIPEC regimens.

Clinical setting	*First preference*	*Second preference*	*Third preference*
Advanced epithelial ovarian cancer (in addition to interval cytoreductive surgery)	*OVHIPEC-1 regimen:* Cisplatin 100 mg/m^2 for 90 minutes with triple dosing and intravenous sodium thiosulfate	*CHIPASTIN regimen:* Cisplatin 75 mg/m^2 for 60 minutes	Cisplatin 50 mg/m^2 + doxorubicin 15 mg/m^2 for 90 minutes
Recurrent epithelial ovarian cancer (in the setting of a clinical trial)	*OVHIPEC-1 regimen:* Cisplatin 100 mg/m^2 for 90 minutes with triple dosing and intravenous sodium thiosulfate	*CHIPASTIN regimen:* Cisplatin 75 mg/m^2 for 60 minutes	Cisplatin 50 mg/m^2 + doxorubicin 15 mg/m^2 for 90 minutes
Mucinous epithelial ovarian cancer	Any cisplatin (single-agent)-based regimen	Any cisplatin + doxorubicin combination	Low-dose or high-dose MMC regimen
Evaluation in clinical trials	*OVHIPEC-1 regimen:* Cisplatin 100 mg/m^2 for 90 minutes with triple dosing and intravenous sodium thiosulfate	*CHIPASTIN regimen:* Cisplatin 75 mg/m^2 for 60 minutes	*HIPEC ROC-1 regimen:* Cisplatin 100 mg/m^2 for 90 minutes

(MMC: mitomycin-C)

JAYPEE BROTHERS

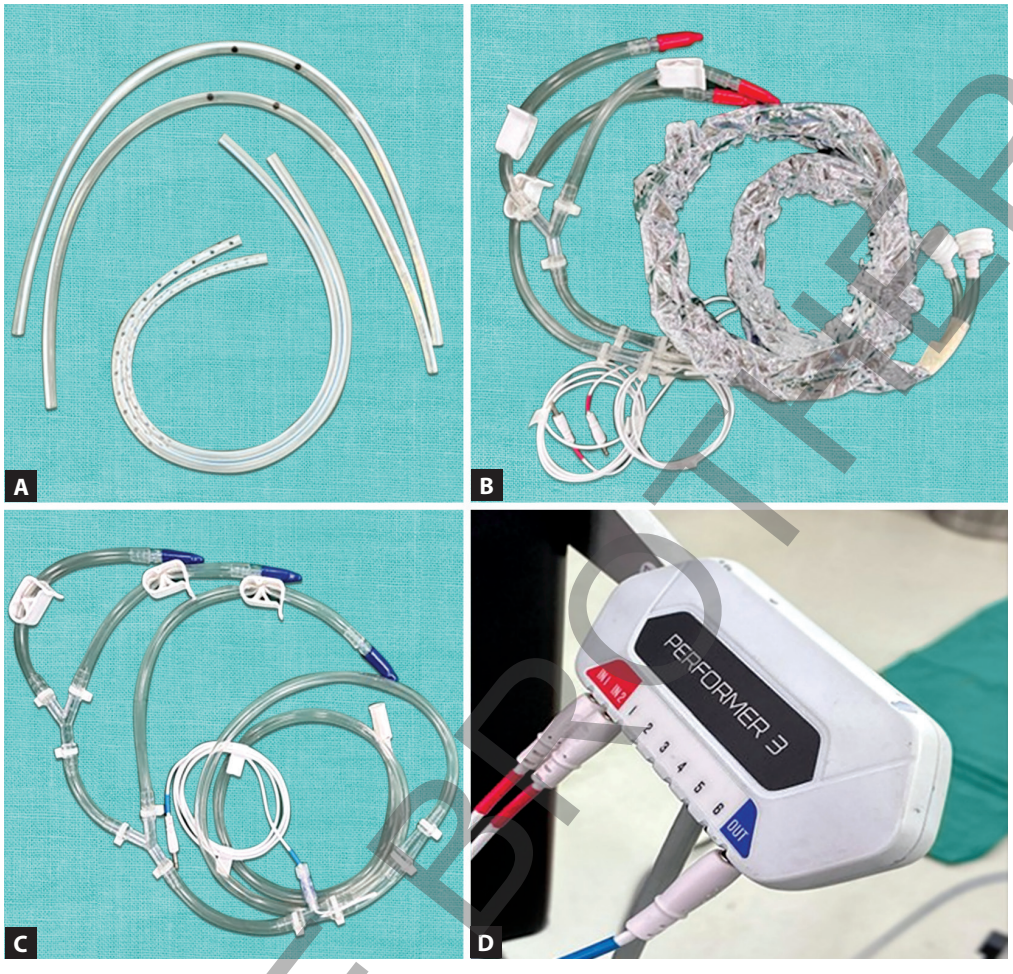

Figs. 5A to D: Setting up the HIPEC kits: (A) Inflow and outflow catheters (*Note:* The black marks should always be inside the abdomen. The outflow catheters are designs to decrease the suction effect to avoid injury to the bowel); (B) Inflow catheter (*Note:* It is covered with insulated material to prevent heat dissipation; (C) Outflow catheters; and (D) Temperature probes being connected to the machine (*Note:* Each inflow and outflow catheter has temperature probes).

13. Monitor perfusion flow, circuit pressure, core body temperature, urine output, and hemodynamic parameters throughout the procedure **(Figs. 6 and 7)**.
14. At the completion of HIPEC, completely drain the chemotherapy solution from the abdominal cavity.
15. Irrigate the peritoneal cavity with warm saline if required by the institutional protocol.
16. Place abdominal drains as indicated and proceed with definitive abdominal closure after restoration of intestinal continuity.

Bidirectional Chemotherapy

Bidirectional chemotherapy combines simultaneous intravenous and intraperitoneal chemotherapy during HIPEC, creating a bidirectional concentration gradient that exposes tumor nodules from both the vascular and peritoneal surfaces. This approach enhances drug penetration and locoregional cytotoxicity. Intravenous chemotherapy is administered immediately before or during HIPEC, either as a bolus or continuous infusion. Commonly used regimens include intravenous 5-FU with intraperitoneal oxaliplatin for colorectal cancer and intravenous ifosfamide with intraperitoneal cisplatin and doxorubicin for ovarian cancer, gastric cancer, peritoneal sarcomatosis, and malignant mesothelioma. Although early pharmacokinetic and clinical studies have shown promising results, further research is needed to define the optimal drug combinations and treatment protocols.

JAYPEE BROTHERS



Figs. 6A to D: Setting up the HIPEC machine. (A) Temperature of the carrier solution is confirmed as the set point is reached; (B) As the circulation starts, the graphs are visible on the machine along with the inflow and outflow temperatures; (C) Roller pumps on the machine pump the carrier solution into the abdomen; and (D) Chemotherapy (mitomycin-C) is being injected into the circuit.

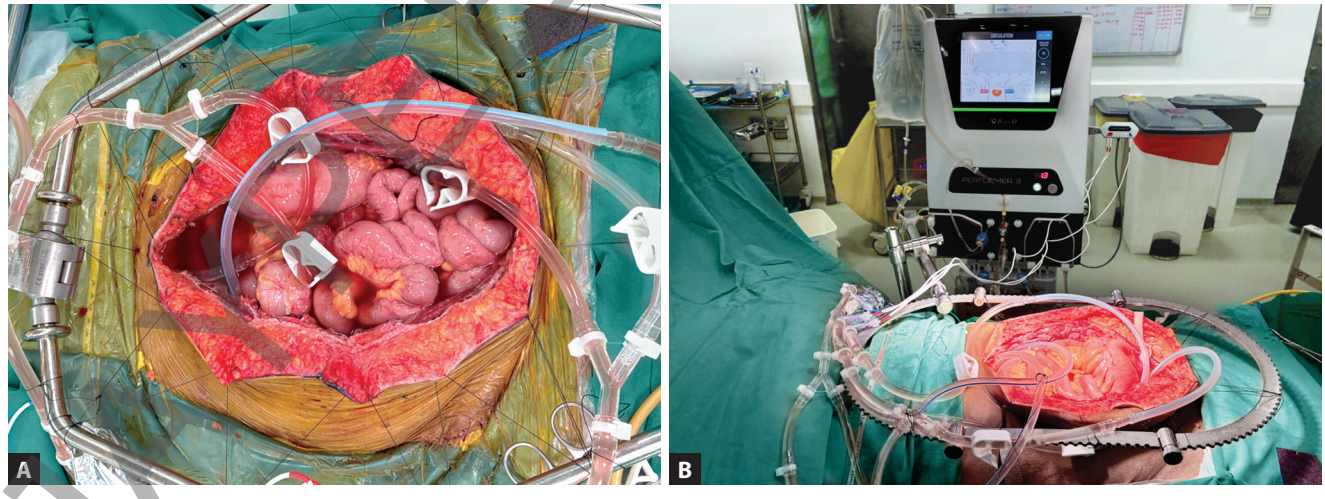

Figs. 7A and B: HIPEC with open technique: (A) Note the placement of the inflow and outflow catheters and the process has been initiated and (B) HIPEC in progress.

JAYPEE BROTHERS

EARLY POSTOPERATIVE INTRAPERITONEAL CHEMOTHERAPY

Early postoperative intraperitoneal chemotherapy is a form of normothermic intraperitoneal chemotherapy administered through intraperitoneal catheters placed during CRS, usually from postoperative day 1 to day 4 or 5. It is delivered before postoperative adhesions develop, allowing uniform distribution of chemotherapy and prolonged exposure of residual microscopic disease to cell cycle-specific agents while achieving high local drug concentrations with minimal systemic toxicity. Each chemotherapy instillation remains within the peritoneal cavity for approximately 23 hours, followed by 1 hour of drainage before the next cycle. EPIC may be used alone or in combination with CRS and HIPEC but should be reserved for carefully selected patients because of its association with increased postoperative morbidity. EPIC was developed by Dr Paul H Sugarbaker in the late 1980s and formally introduced around 1990 as part of his perioperative treatment strategy following CRS for peritoneal surface malignancies.

Technique of Early Postoperative Intraperitoneal Chemotherapy

The technique includes the following steps:

1. *Catheter placement:* Intraperitoneal inflow catheters (commonly a Tenckhoff catheter) and abdominal drains are placed at the completion of CRS.
2. *Initiation of therapy:* EPIC is usually commenced within 24 hours of surgery (postoperative day 1) and continued daily for 4–5 days.
3. *Chemotherapy instillation:* Before each cycle, residual intraperitoneal fluid is completely drained, following which the chemotherapy solution is rapidly infused through the intraperitoneal catheter.
4. *Drug dwell time:* The chemotherapy solution is retained within the peritoneal cavity for approximately 23 hours, after which the drains are opened for 1 hour to allow complete drainage before the next instillation.
5. Optimization of drug distribution: Large-volume carrier solutions, patient repositioning (alternating right and left lateral positions every 30 minutes during the first 6 hours), abdominal massage, and Trendelenburg positioning help achieve uniform intraperitoneal drug distribution.
6. *Monitoring and completion:* Patients are monitored clinically, including pulse oximetry during the early postinstillation period, and the abdominal drains remain open after the final treatment cycle until catheter removal **(Figs. 8A and B)**.

Drugs Used in Early Postoperative Intraperitoneal Chemotherapy

The drugs are as follows:

- 5-FU is the most commonly used drug for EPIC in colorectal, appendiceal, and gastric peritoneal

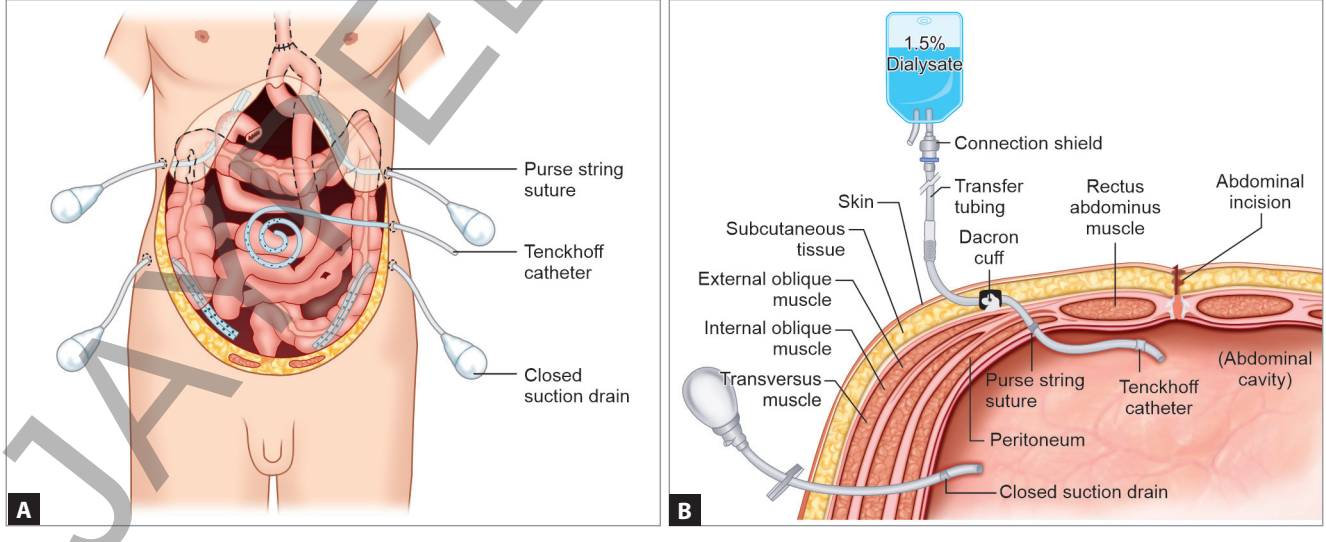

Figs. 8A and B: Early postoperative intraperitoneal chemotherapy (EPIC): (A) Placement of catheters for EPIC and (B) Delivery of chemotherapy into the abdomen and closed suction drainage system to evacuate the chemotherapy.

JAYPEE BROTHERS

metastases. It is a cell cycle-specific antimetabolite that inhibits thymidylate synthase, thereby impairing DNA synthesis. Despite its low molecular weight, it demonstrates an excellent intraperitoneal pharmacokinetic profile.

- Paclitaxel (PTX) is a high-molecular-weight taxane that stabilizes microtubules, causing mitotic arrest and apoptosis. It achieves prolonged intraperitoneal retention resulting in sustained local drug concentrations and minimal systemic toxicity. It is widely used for EPIC in ovarian cancer and diffuse malignant peritoneal mesothelioma.
- Docetaxel has a mechanism of action similar to PTX and also demonstrates excellent intraperitoneal pharmacokinetics. Its prolonged peritoneal exposure, low systemic absorption, and cell cycle-specific activity make it suitable for EPIC.

Morbidity and Clinical Considerations

Mortality following CRS with EPIC ranges from 0% to 9%, while overall morbidity ranges from 15% to 57%, with most complications attributable to CRS rather than chemotherapy. Common complications include anastomotic leak, gastrointestinal fistula, abdominal sepsis, bleeding, prolonged ileus, pleural effusion, and intra-abdominal collections, whereas hematological toxicity is uncommon. EPIC may provide additional benefit when combined with CRS and HIPEC in carefully selected patients achieving complete cytoreduction (CCR-0).

Current Role of Early Postoperative Intraperitoneal Chemotherapy

Early postoperative intraperitoneal chemotherapy remains an attractive strategy for prolonged postoperative exposure of microscopic residual disease to chemotherapy. While CRS and HIPEC remain the cornerstone of treatment for peritoneal metastases, EPIC may serve as an adjunctive therapy in selected patients, particularly those with favorable tumor biology, complete cytoreduction, and minimal prior treatment.

NEOADJUVANT INTRAPERITONEAL AND SYSTEMIC CHEMOTHERAPY

Neoadjuvant intraperitoneal and systemic chemotherapy is a bidirectional treatment strategy that combines intraperitoneal and systemic intravenous chemotherapy before CRS to maximize drug delivery to peritoneal metastases. By simultaneously targeting tumor deposits from the peritoneal cavity and the systemic circulation, NIPS reduces peritoneal tumor burden, facilitates complete cytoreduction, eradicates occult systemic disease, and provides an opportunity to assess tumor chemosensitivity and biological behavior. Although initially developed as a neoadjuvant approach, NIPS is now also used as normothermic intraperitoneal and systemic chemotherapy in selected patients with unresectable peritoneal metastases. NIPS was developed in Japan in the early 2000s by Dr Yonemura and colleagues, with subsequent refinement by Dr Hironori Ishigami, as a bidirectional treatment strategy using an implanted intraperitoneal access port for patients with peritoneal metastases.

Catheter-based Intraperitoneal Chemotherapy

NIPS is delivered using catheter in which a surgically implanted subcutaneous port and intraperitoneal catheter permit repeated administration of normothermic chemotherapy. Compared with HIPEC and PIPAC, it is minimally invasive, does not require repeated general anesthesia, enables prolonged weekly treatment, and allows serial peritoneal fluid sampling for cytological and biomarker assessment, making it well suited for long-term regional therapy.

Physiological Basis and Rationale of Normothermic Intraperitoneal and Systemic Chemotherapy

The effectiveness of NIPS is based on the unique physiology of the peritoneal cavity. Despite its large surface area, the peritoneum receives only 1–2% of the cardiac output, limiting the effectiveness of intravenously administered chemotherapy. The peritoneal–plasma barrier, restricts systemic absorption while maintaining prolonged intraperitoneal drug exposure. As a result, it achieves high local drug concentrations with relatively low systemic toxicity. Drug transport across this barrier is influenced by molecular size, charge, lipid solubility, and extracellular matrix composition, all of which are altered by inflammation, fibrosis, angiogenesis, and tumor infiltration.

However, the same peritoneal–plasma barrier also limits drug penetration into tumor nodules. Dense fibrosis, desmoplasia, and elevated interstitial fluid pressure further restrict diffusion of chemotherapy

JAYPEE BROTHERS

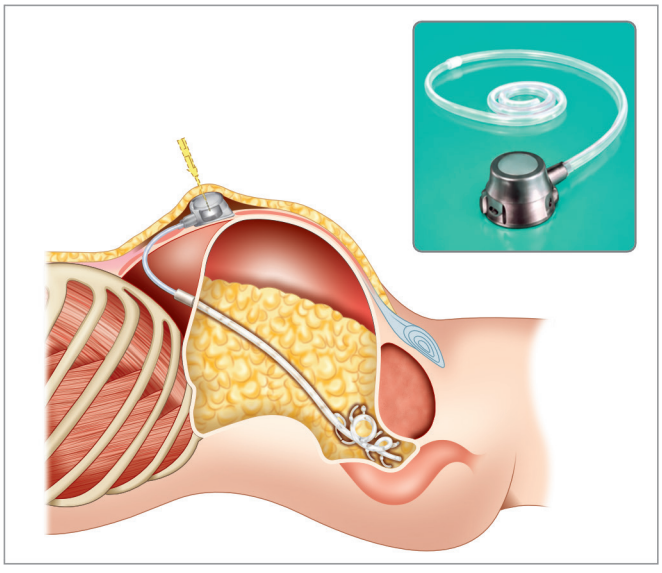

Fig. 9: Conceptual image of NIPS (neoadjuvant intraperitoneal and systemic chemotherapy). Note the *intraperitoneal chemoport*.

from both the bloodstream and the peritoneal cavity. Consequently, the principal challenge is not simply achieving high intraperitoneal drug concentrations but ensuring adequate penetration into metastatic deposits. Although intraperitoneally administered drug remains in the peritoneal cavity for prolonged periods and directly penetrates tumor nodules, its depth of penetration is generally limited to <100 µm to a few hundred micrometers. Therefore, it is most effective against free-floating tumor cells and superficial peritoneal implants, while bulky tumors remain relatively resistant. In addition, postoperative adhesions may impair uniform distribution of chemotherapy throughout the peritoneal cavity **(Fig. 9)**.

Paclitaxel for NIPS

Paclitaxel is the cornerstone chemotherapeutic agent used in NIPS because of its highly favorable pharmacokinetic properties. Its high molecular weight and lipophilic nature result in prolonged retention within the peritoneal cavity, maintaining therapeutic intraperitoneal drug concentrations for >72 hours while minimizing systemic absorption and toxicity.

Paclitaxel is particularly effective against free-floating tumor cells and microscopic peritoneal metastases, making it an ideal agent for regional neoadjuvant therapy. It also induces minimal peritoneal adhesion formation, allowing safe repeated administration through an implanted intraperitoneal port. However, its limited tissue penetration (<1 mm) reduces its efficacy against bulky or deeply invasive tumor nodules.

Commonly Used Neoadjuvant Intraperitoneal and Systemic Chemotherapy Regimens with Taxanes

- *Yonemura regimen:* Oral S-1 is administered for 14 days followed by a 7-day rest; intraperitoneal docetaxel (30 mg/m^2) and cisplatin (30 mg/m^2) are given on day 1, followed by the same agents intravenously on day 8, maximizing bidirectional chemotherapy exposure in gastric cancer with peritoneal metastases.
- *Ishigami regimen:* S-1 is given for 14 days with a 7-day rest, while intravenous PTX (50 mg/m^2) and intraperitoneal PTX (20 mg/m^2) are administered on days 1 and 8 every 3 weeks, combining high locoregional PTX concentrations with systemic disease control.
- *Fujiwara regimen:* Oral S-1 is combined with intraperitoneal docetaxel (40–60 mg/m^2 in 1 L normal saline) every 3 weeks, providing prolonged regional taxane exposure while maintaining concurrent systemic chemotherapy.
- *Sugarbaker regimen:* Intraperitoneal PTX (20 mg/m^2) is administered through an intraperitoneal port for 5 consecutive days, with intravenous oxaliplatin (100–150 mg/m^2) infused on day 3, integrating sustained intraperitoneal taxane therapy with systemic platinum-based chemotherapy for enhanced bidirectional cytotoxicity.

Advantages of Neoadjuvant Intraperitoneal and Systemic Chemotherapy

- It provides sustained high locoregional chemotherapy exposure within the peritoneal cavity.
- It simultaneously treats systemic and peritoneal disease through a bidirectional approach.
- Repeatable treatment cycles can be administered via intraperitoneal port systems.
- It has lower systemic toxicity compared with high-dose intravenous chemotherapy alone.
- It may downstage disease and facilitate conversion surgery in selected responders.
- Response assessment with second-look laparoscopy helps determine resectability and further treatment planning.

JAYPEE BROTHERS

Disadvantages of Neoadjuvant Intraperitoneal and Systemic Chemotherapy

- There is limited drug penetration into large or bulky peritoneal deposits.
- It requires intraperitoneal port placement and repeated treatment sessions.
- There may be risk of catheter-related complications, infection, or port malfunction.
- Evidence is still largely based on selected institutional experiences and Asian data.
- Not all patients achieve sufficient response for conversion surgery.

Box 4 provides important points of NIPS.

BOX 4: Important points related to NIPS.

- *Sequential administration:* NIPS requires sequential administration of chemotherapy, withintraperitoneal and intravenous
- chemotherapy typically delivered on the same day.
- *Response assessment:* Evaluation of treatment response often requires repeat staging laparoscopy, as imaging alone may not accurately assess peritoneal disease.
- *Uncertain drug distribution:* Uniform distribution of intraperitoneal chemotherapy cannot always be ensured, particularly in the presence of adhesions or bulky disease.
- *Port-related complications:* Repeated intraperitoneal therapy may be associated with port-site complications, including infection, catheter blockage, leakage, malfunction, and, rarely, port-site metastasis.

PRESSURIZED INTRAPERITONEAL AEROSOL CHEMOTHERAPY

Pressurized intraperitoneal aerosol chemotherapy was developed by Marc A Reymond and colleagues and was first introduced into clinical practice in 2011 as a novel laparoscopic technique for the treatment of peritoneal metastases. Subsequently, the International Society for the Study of Pleura and Peritoneum (ISSPP) has played a pivotal role in standardizing PIPAC through international consensus statements, clinical recommendations, and educational initiatives.

Rationale for Pressurized Intraperitoneal Aerosol Chemotherapy

Peritoneal metastases are characterized by poor vascularity, elevated interstitial fluid pressure, and the presence of the peritoneal–plasma barrier, all of which limit the effectiveness of systemic chemotherapy. Conventional liquid intraperitoneal chemotherapy is limited by nonuniform distribution within the peritoneal cavity and restricted tissue penetration, reducing its efficacy against peritoneal tumor nodules.

Pressurized intraperitoneal aerosol chemotherapy was developed to overcome these limitations by delivering normothermic chemotherapy as a pressurized aerosol during laparoscopy. Aerosolization ensures a more homogeneous distribution of chemotherapy over the peritoneal surfaces, while the capnoperitoneum maintained at approximately 12 mm Hg creates an artificial pressure gradient that counteracts the elevated interstitial fluid pressure within tumor nodules. This results in improved tissue uptake, greater depth of drug penetration, and higher local drug concentrations while minimizing systemic drug absorption and toxicity. Consequently, PIPAC provides an effective, minimally invasive, and repeatable locoregional treatment option for selected patients with unresectable peritoneal metastases **(Fig. 10)**.

Indications of Pressurized Intraperitoneal Aerosol Chemotherapy in Gastrointestinal Malignancies

Pressurized intraperitoneal aerosol chemotherapy is primarily indicated in patients with unresectable or recurrent peritoneal metastases who are unsuitable for CRS with HIPEC or have progressed despite standard treatment. It serves as a minimally invasive locoregional therapy that can be administered repeatedly and may be combined with systemic chemotherapy.

Pressurized Intraperitoneal Aerosol Chemotherapy with Cisplatin and Doxorubicin

Potential indications include:

- Second-line or later treatment for gastric cancer with isolated peritoneal metastases.
- Second-line or later treatment for hepatobiliary and pancreatic malignancies with peritoneal dissemination.
- Recurrence of malignant peritoneal mesothelioma, particularly when repeat cytoreduction is not feasible.
- Patients with intolerance or significant toxicity from systemic chemotherapy.
- Control of refractory malignant ascites, especially in platinum-resistant disease.

JAYPEE BROTHERS

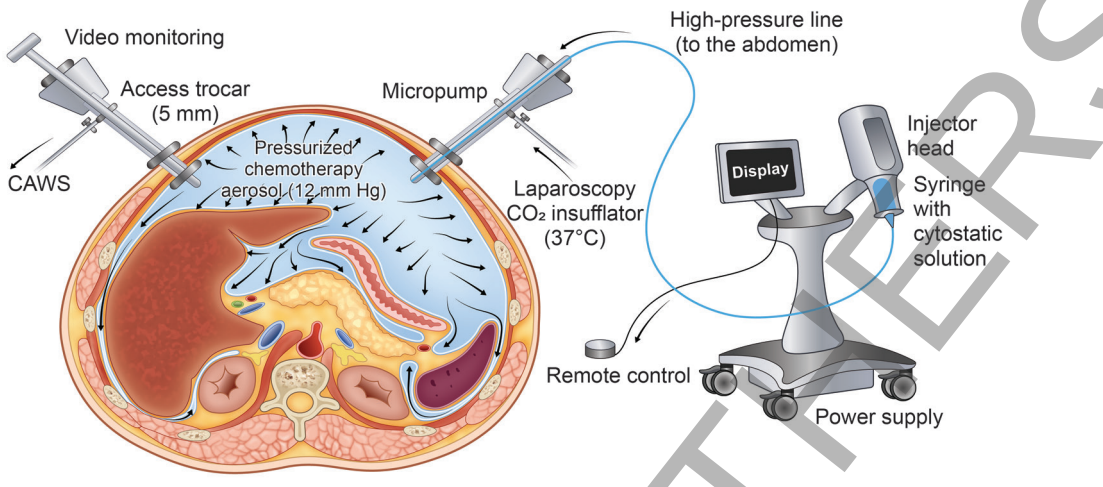

Fig. 10: Concept of pressurized intraperitoneal aerosol chemotherapy (PIPAC). (CAWS: closed aerosol waste system)

Pressurized Intraperitoneal Aerosol Chemotherapy with Oxaliplatin

Potential indications include:

- Salvage therapy for colorectal cancer with unresectable peritoneal metastases after failure of standard systemic chemotherapy.
- Other selected peritoneal surface malignancies where oxaliplatin-based intraperitoneal therapy is considered appropriate.

Contraindications to Pressurized Intraperitoneal Aerosol Chemotherapy

Absolute contraindications:

- Life expectancy <3 months.
- Bowel obstruction, dependence on total parenteral nutrition (TPN), or requirement for continuous gastric decompression.
- Decompensated or uncontrolled malignant ascites.

Relative contraindications:

- Extraperitoneal metastases, except isolated malignant pleural effusion in selected patients.
- Poor performance status.
- Planned simultaneous intestinal anastomosis during the surgery.
- Portal vein thrombosis.
- Previous CRS and HIPEC, particularly when extensive peritonectomy may limit laparoscopic access (although access is often feasible if no peritonectomy has been performed).
- Previous severe hypersensitivity or anaphylactic reaction to the intended chemotherapeutic agent (alternative agents should be considered where possible).
- Severe renal or hepatic dysfunction.
- Significant myelosuppression.
- Severe cardiac disease, including myocardial insufficiency, recent myocardial infarction, or uncontrolled cardiac arrhythmias.

Steps of the Pressurized Intraperitoneal Aerosol Chemotherapy Procedure

1. *Patient preparation and positioning:* The patient is placed in the supine or French position under general anesthesia, standard laparoscopic monitoring is established, and the operating room is prepared with the high-pressure injector, CapnoPen®, closed aerosol evacuation system, and appropriate chemotherapy safety measures.
2. *Abdominal access:* Pneumoperitoneum is established using an open (Hasson) or Veress needle technique, followed by insertion of two airtight balloon trocars under direct vision to minimize chemotherapy leakage.
3. *Staging laparoscopy:* A systematic exploration of all 13 abdominopelvic regions is performed, the Peritoneal Cancer Index (PCI) is calculated, ascites is documented, and the feasibility of proceeding with PIPAC is assessed.
4. *Ascites aspiration and peritoneal biopsies:* Ascitic fluid is collected for cytological examination, and

JAYPEE BROTHERS

representative peritoneal biopsies are obtained from standardized sites to establish baseline histopathology and assess treatment response during subsequent procedures.

5. *Chemotherapy preparation:* The chemotherapy solution, commonly low-dose cisplatin with doxorubicin or oxaliplatin depending on tumor type, is prepared according to institutional protocols and connected to the high-pressure injector and nebulizer.
6. *Safety verification:* A standardized safety checklist is completed to confirm correct trocar sealing, injector connections, operating room evacuation, remote monitoring, and proper functioning of the closed aerosol waste system (CAWS) before chemotherapy administration.
7. *Remote aerosol chemotherapy administration:* After all personnel leave the operating room, chemotherapy is delivered remotely through the CapnoPen® micropump, generating a pressurized aerosol within a 12 mm Hg capnoperitoneum to achieve uniform drug distribution and enhanced tissue penetration.
8. *Therapeutic exposure:* The aerosolized chemotherapy is maintained within the abdominal cavity for approximately 30 minutes under stable pressure, allowing optimal tissue penetration while the patient is continuously monitored remotely.
9. *Controlled aerosol evacuation:* At the end of the exposure period, residual chemotherapy aerosol is evacuated through a CAWS incorporating HEPA filtration before desufflation and trocar removal, thereby preventing environmental contamination.
10. *Procedure completion:* The trocars are removed, port sites are closed in the standard fashion, equipment is decontaminated or discarded according to cytotoxic waste protocols, and the patient is transferred for routine postoperative recovery. Peritoneal Regression Grading Scores (PRGS) are to be evaluated with each cycle **(Figs. 11 to 14 and Box 5)**.

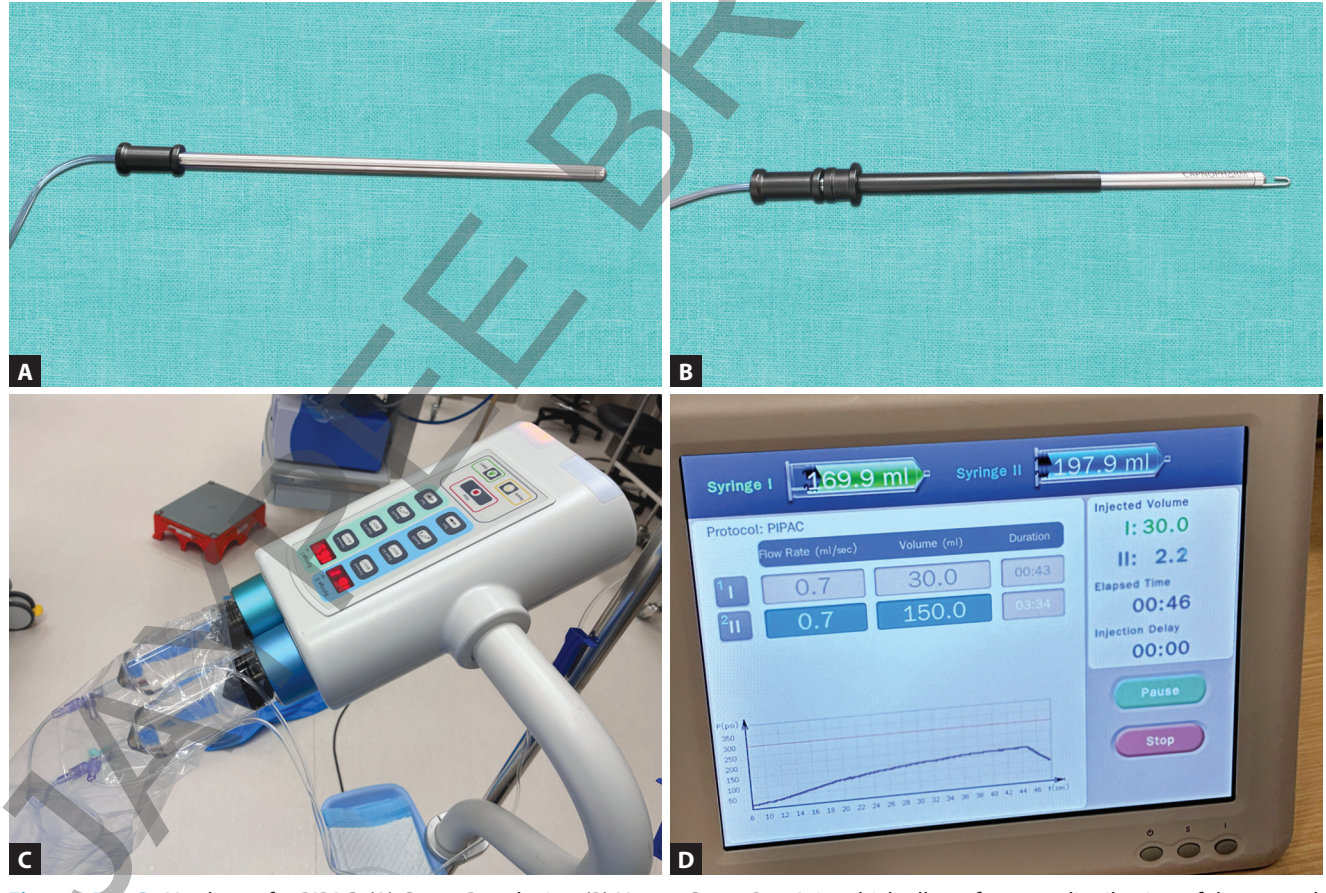

Figs. 11A to D: Hardware for PIPAC: (A) CapnoPen device; (B) Newer CapnoPen J tip which allows for even distribution of the aerosol; (C) Pressure injector system; and (D) Remote controlled delivery of the drug canisters.

JAYPEE BROTHERS

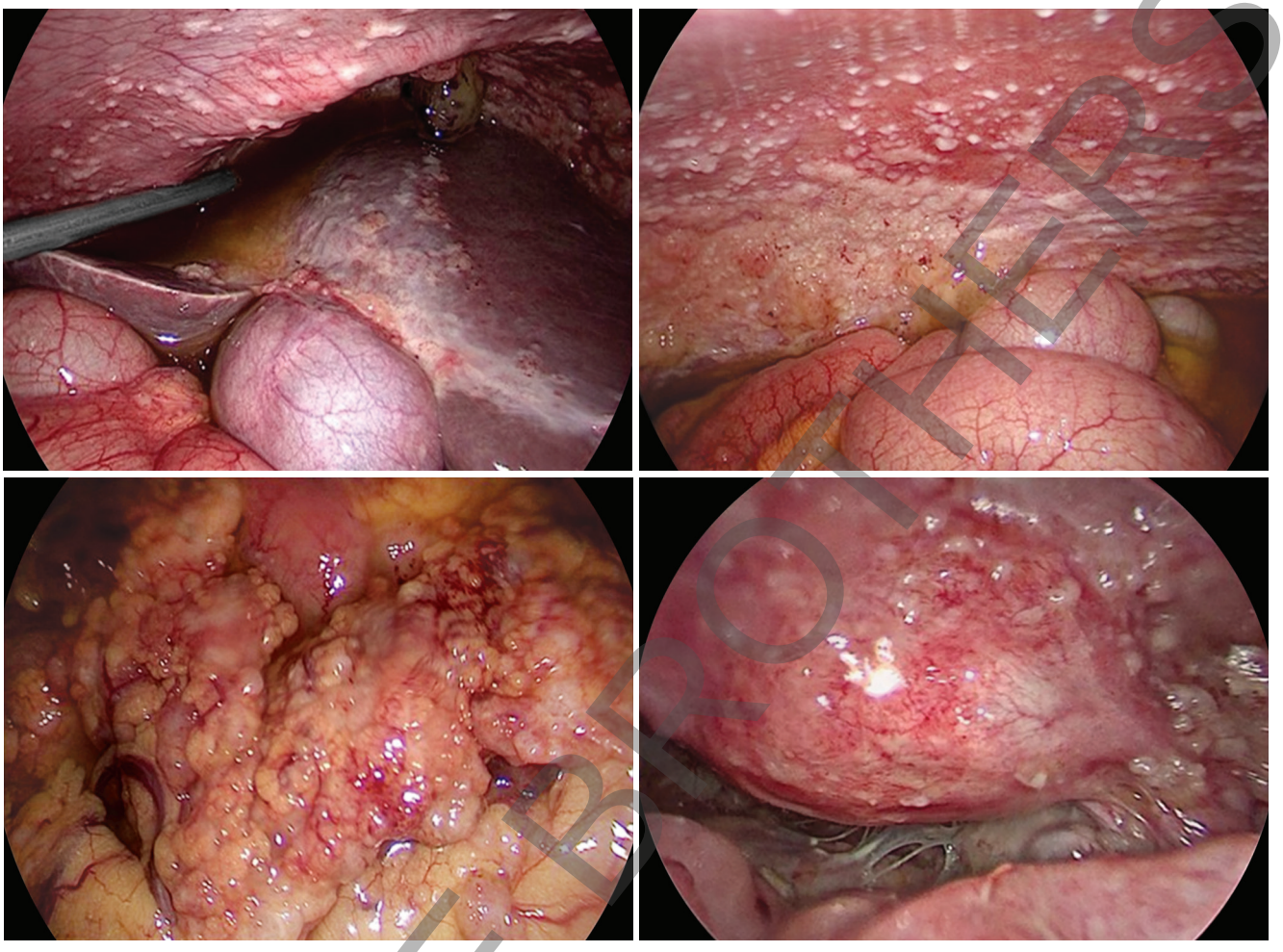

Fig. 12: Diagnostic laparoscopy and Peritoneal Cancer Index (PCI) assessment prior to PIPAC.

BOX 5: Response assessment after pressurized intraperitoneal aerosol chemotherapy (PIPAC).

- *Limitation of PCI in assessing response to PIPAC:* PCI is suboptimal for evaluation of response to PIPAC because it is difficult to differentiate true macroscopic disease progression from treatment-induced fibrosis.
- Response assessment after PIPAC should be evaluated using the PRGS scoring system **(Figs. 15A and B)**.

(PCI: Peritoneal Cancer Index; PRGS: Peritoneal Regression Grading Score)

Minimizing Occupational Risk During Pressurized Intraperitoneal Aerosol Chemotherapy

This includes the following steps **(Figs. 16A and B)**:

1. *Institutional safety protocols:* Every PIPAC program should follow standardized institutional safety protocols to protect healthcare workers from occupational exposure to aerosolized chemotherapy.
2. *Structured risk management:* A comprehensive risk management program should include hazard identification, protocol development, staff training, simulation, environmental monitoring, incident reporting, and biological surveillance.
3. *Protection against liquid exposure:* Skin contamination should be prevented by using impermeable gowns, double chemotherapy-resistant gloves, and protective eye shields during drug preparation and handling.
4. *Reduction of inhalation risk:* Inhalational exposure is minimized by maintaining a sealed pneumoperitoneum, using HEPA-filtered operating room ventilation, and evacuating aerosol through a CAWS.

JAYPEE BROTHERS

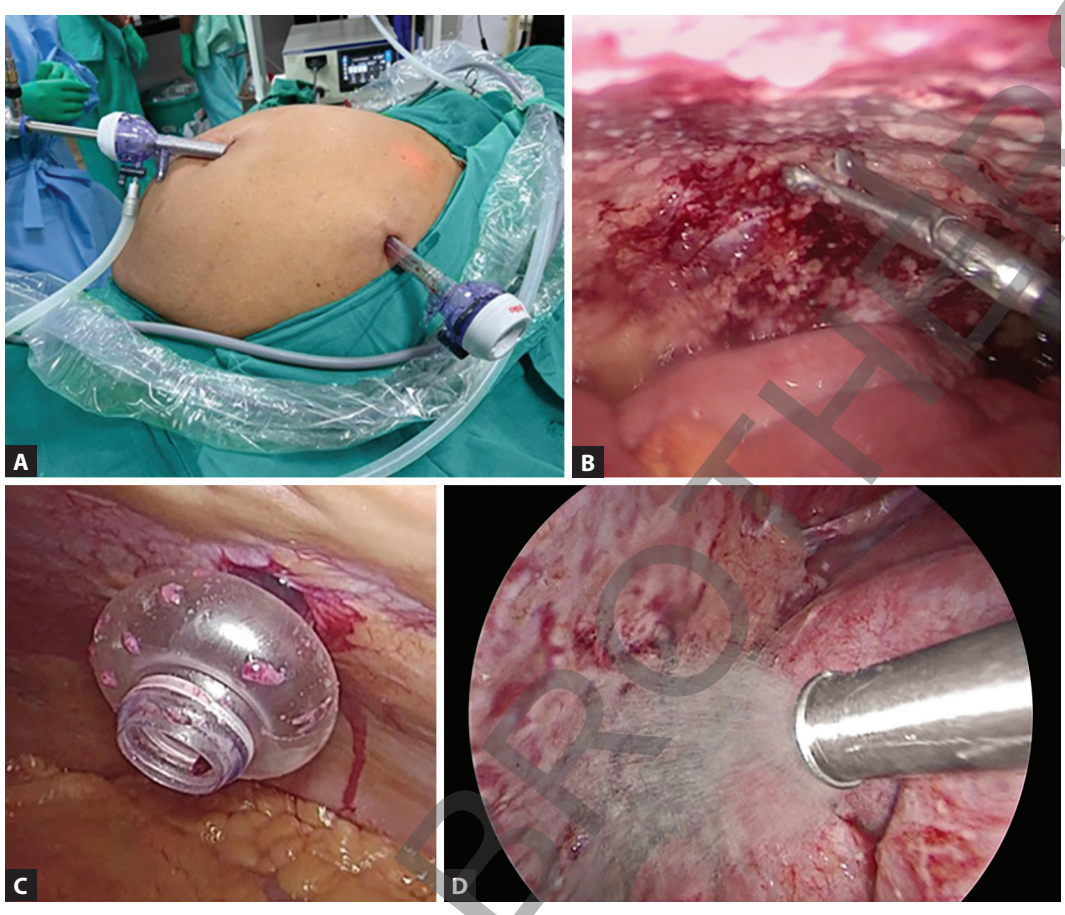

Figs. 13A to D: PIPAC procedure: (A) Note two ports—camera port and working port; (B) Biopsy taken from the peritoneum; (C) Balloon trocars to avoid leak of aerosol from the port site; and (D) PIPAC delivery through the CapnoPen.



Fig. 14: Operating room set up with PIPAC under progress (*Note:* These drapes are to be discarded after the procedure).

5. *Triple protection strategy:* Occupational safety is achieved through a closed abdominal cavity, HEPA-filtered ventilation, and remote chemotherapy administration with no personnel inside the operating room.
6. *CAWS:* CAWS safely removes residual aerosolized chemotherapy before trocar removal, preventing contamination of the operating room.
7. *Environmental workplace monitoring:* Regular environmental monitoring confirms minimal chemotherapy contamination at critical operating room locations when safety protocols are followed.
8. *Training and quality assurance:* Regular staff training, strict protocol adherence, validated cleaning procedures, and continuous environmental surveillance are essential for maintaining occupational safety.

JAYPEE BROTHERS

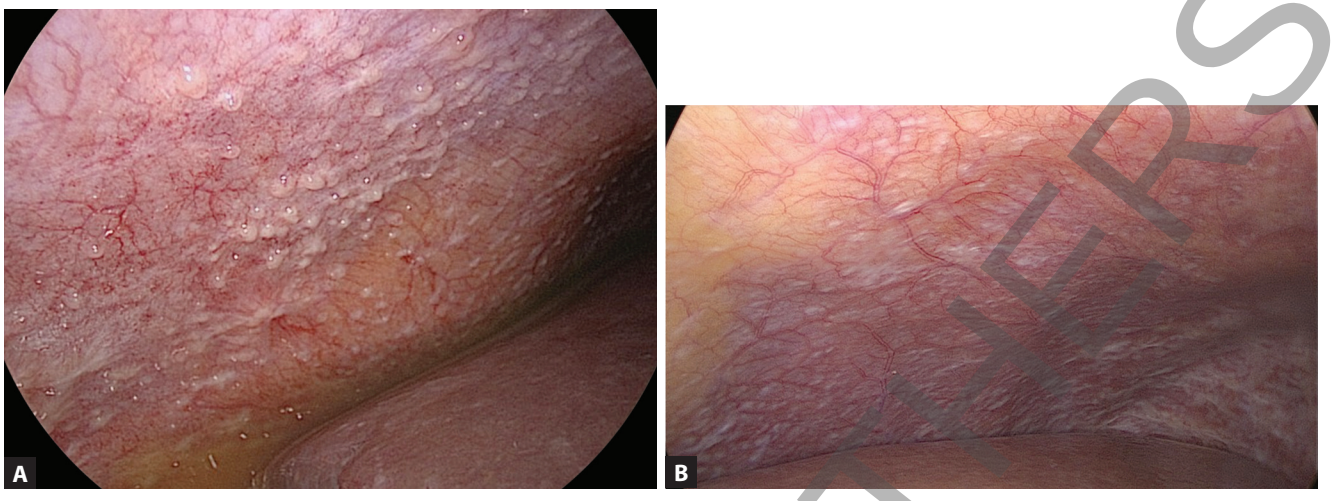

Figs. 15A and B: Response assessment after the third cycle of PIPAC: (A) Before PIPAC procedure and (B) After third PIPAC procedure.



Figs. 16A and B: Safety for PIPAC: (A) Surgical team is outside the operating room with N95 masks to avoid dissemination and (B) Operating room with restricted entry due to biohazard [*Note:* PIPAC under process through the operation theater (OT) window].

Complications of Pressurized Intraperitoneal Aerosol Chemotherapy

Pressurized intraperitoneal aerosol chemotherapy has a low overall morbidity when performed in experienced centers. Complications may be related to anesthesia, surgery, local chemotherapy effects, or systemic toxicity.

- *Anesthesia-related:* Rare; includes allergic reactions, anaphylaxis, and aspiration, particularly in patients with massive ascites.
- *Access injuries:* Small bowel injury (0.3–0.8%) and bleeding (1–2%) are uncommon and usually related to trocar insertion or biopsy.
- *Diaphragmatic perforation:* Rare complication during diaphragmatic biopsy that may result in pneumothorax or pleural contamination.
- *Subcutaneous toxic emphysema:* Uncommon, usually self-limiting, and more frequent after open abdominal access.
- *Abdominal pain:* Usually mild; more severe pain is seen with oxaliplatin-based PIPAC than with cisplatin–doxorubicin.
- *Local toxicity:* Oxaliplatin is associated with higher local toxicity, including nausea, ileus, neurotoxicity, abscess, and hypersensitivity reactions.
- *Prolonged postoperative ileus:* Occurs in approximately 4–8% of patients, particularly in those with advanced bowel involvement.
- *Severe peritoneal sclerosis:* Rare complication reported mainly after repeated oxaliplatin-based PIPAC.
- *Delayed bowel perforation:* Increased risk in patients with colonic stents or receiving anti-angiogenic agents (e.g., bevacizumab, ramucirumab).

JAYPEE BROTHERS

- *Systemic toxicity:* Generally minimal because of limited systemic drug absorption; hypersensitivity reactions to platinum compounds remain the most important systemic adverse event.

Current Evidence of Pressurized Intraperitoneal Aerosol Chemotherapy and its Practice

The clinical role of PIPAC continues to evolve. Several prospective studies and the first randomized clinical trials evaluating PIPAC with cisplatin and doxorubicin for isolated peritoneal metastases have been initiated to assess its impact on tumor response, symptom control, and survival. While early results are encouraging, PIPAC is currently considered an adjunctive or investigational treatment in many gastrointestinal malignancies and should ideally be offered within experienced centers or clinical trials. Early clinical studies have consistently demonstrated the feasibility, safety, and tolerability of PIPAC, with encouraging evidence of improved local bioavailability, pathological tumor regression, symptom control, and quality of life. Consequently, PIPAC has emerged as a promising palliative treatment for selected patients with isolated unresectable peritoneal metastases, particularly when standard evidence-based treatment options are limited or have failed. Ongoing randomized clinical trials are expected to further define its role in the multidisciplinary management of peritoneal surface malignancies.

- *Phase I dose-escalation studies:* Early phase I dose-escalation studies demonstrated excellent tolerability of escalating doses of cisplatin, doxorubicin, and oxaliplatin administered via PIPAC. The maximum tolerated dose was not reached, and no dose-limiting toxicities were observed, establishing the safety of repeated aerosolized intraperitoneal chemotherapy and providing the foundation for subsequent efficacy studies.
- *Phase I dose-finding studies of oxaliplatin:* Phase I trials further refined the optimal oxaliplatin dose for PIPAC. Dumont et al. identified 90 mg/m^2 as the recommended Phase II dose after observing dose-limiting toxicities at higher doses, whereas Kim et al. demonstrated that doses up to 120 mg/m^2 could be administered safely without significant systemic toxicity. These studies confirmed the feasibility of combining oxaliplatin-based PIPAC with systemic chemotherapy.
- *Latest evidence—10 years of PIPAC:* A 2023 systematic review and meta-analysis summarized a decade of clinical experience with PIPAC, including 53 published studies. Most available evidence comprised prospective and retrospective cohort studies, with relatively few phase I and II trials and no completed phase III randomized studies, highlighting the need for further high-quality evidence despite encouraging clinical outcomes.
- *Conversion to curative surgery:* One of the emerging applications of PIPAC is conversion therapy for patients with initially unresectable peritoneal metastases. Repeated PIPAC treatments may downstage disease sufficiently to permit CRS with or without HIPEC in carefully selected patients, and although conversion rates remain modest, encouraging long-term survival has been reported, particularly in gastric and colorectal malignancies. This may be seen in 5.1–14.4% of patients.
- *Effect on quality of life (QoL):* Systematic reviews have consistently shown that PIPAC is well tolerated and does not significantly impair overall QoL despite repeated treatment cycles in patients with advanced peritoneal malignancies. However, interpretation of these findings is limited by the heterogeneity of patient populations, tumor types, and treatment protocols across published studies.
- *ISSPP consensus guidelines for PIPAC:* ISSPP has established consensus guidelines standardizing patient selection, operative technique, safety protocols, chemotherapy administration, and quality assurance for PIPAC worldwide **(Box 6)**.

BOX 6: Simultaneous cytoreductive surgery (CRS) and PIPAC.

Current evidence does not support performing cytoreductive surgery and PIPAC during the same operation. Simultaneous treatment is associated with a significantly increased risk of postoperative complications, particularly anastomotic leakage, which is difficult to manage and contributes to high postoperative mortality. Consequently, CRS and PIPAC are generally recommended as staged procedures.

Advantages of Pressurized Intraperitoneal Aerosol Chemotherapy

- It can be used as an adjunct to systemic chemotherapy or as an alternative locoregional treatment in selected patients with isolated peritoneal disease.
- It is a minimally invasive laparoscopic procedure associated with low morbidity and rapid postoperative recovery.

JAYPEE BROTHERS

- It is repeatable at intervals of 6–12 weeks, allowing multiple treatment cycles and sustained locoregional therapy.
- It facilitates serial assessment of treatment response through repeat laparoscopy, peritoneal biopsies, and response assessment.
- It provides homogeneous distribution of aerosolized chemotherapy over exposed peritoneal surfaces with improved tissue penetration and minimal systemic toxicity.

Quality of Life after Pressurized Intraperitoneal Aerosol Chemotherapy

Patients with peritoneal metastases commonly present with ascites, abdominal pain, abdominal distension, malnutrition, nausea, vomiting, and intestinal obstruction, resulting in significant symptom burden and substantial impairment of quality of life. As the disease progresses, quality of life continues to decline because of worsening physical symptoms, nutritional deterioration, and functional impairment, often until the end of life.

Therefore, there is a compelling unmet clinical need for more effective therapeutic strategies that not only prolong survival but also preserve or improve quality of life. An ideal treatment should provide durable disease control while minimizing both disease-related symptoms and treatment-associated toxicity, thereby reducing morbidity and maintaining functional well-being.

Future of Pressurized Intraperitoneal Aerosol Chemotherapy

- *Hyperthermic PIPAC (hPIPAC):* It combines pressurized aerosol chemotherapy with hyperthermia (41–43°C) to enhance drug penetration, tissue uptake, and cytotoxicity through the synergistic effects of pressure, aerosolization, and heat.
- *Electrostatic PIPAC (ePIPAC):* It uses electrically charged aerosol particles to improve tissue deposition and drug uptake, potentially enabling lower chemotherapy doses and shorter treatment times.
- *Nanomedicine-based PIPAC:* It incorporates nanoparticle drug delivery systems to enhance drug stability, targeted intraperitoneal delivery, and tissue penetration while reducing systemic toxicity. However, these modifications remain investigational, and ongoing clinical trials continue to define their role in both palliative and neoadjuvant settings.

TABLE 6: Comparison of various methods of intraperitoneal drug delivery.

Feature	*HIPEC*	*NIPS*	*PIPAC*
Phase	Liquid	Liquid	Aerosol
General anesthesia	Yes	No	Yes
Temperature	Hyperthermic	Normothermic	Normothermic
Occurrences	Single	Multiple	Multiple
Combination with CRS	Yes	+/–	No

[NIPS: neoadjuvant intraperitoneal and systemic chemotherapy (for gastric cancer); PIPAC: pressurized intraperitoneal aerosol chemotherapy]

SUMMARY OF VARIOUS INTRAPERITONEAL CHEMOTHERAPY DELIVERY SYSTEMS

Table 6 provides a summary of various intraperitoneal delivery systems.

FUTURE PROSPECTS OF MULTIPLE-DOSE INTRAPERITONEAL DRUG DELIVERY

Continued advances in drug delivery systems and regional chemotherapy are expanding the role of intraperitoneal therapy beyond conventional HIPEC. Several emerging strategies aim to improve drug distribution, prolong intraperitoneal drug exposure, enhance tumor penetration, and optimize locoregional disease control while minimizing systemic toxicity.

- *Alternative lavage techniques:* Extensive intraperitoneal lavage, hydrogen peroxide, and povidone-iodine lavage to eliminate free intraperitoneal tumor cells.
- *Bidirectional chemotherapy:* Combined systemic and intraperitoneal chemotherapy to improve tumor drug penetration.
- *Repeated HIPEC:* Multidose HIPEC leverages the peritoneal–plasma barrier, repeated hyperthermia, and fractionated chemotherapy to maintain high intraperitoneal drug concentrations, eradicate cell cycle—heterogeneous tumor cells, enhance chemosensitivity, and reduce systemic toxicity.
- *PIPAC:* Repeatable aerosolized for unresectable, palliative, and neoadjuvant treatment.
- *Novel drug delivery systems:* Nanoparticles, hydrogels, fibrin carriers, and sustained-release formulations to prolong intraperitoneal drug exposure.

JAYPEE BROTHERS

- *Combined regional and systemic therapy:* Integration of neoadjuvant and adjuvant IPC with systemic treatment to improve disease control.
- *Intraperitoneal radionuclide therapy:* Targeted radiopharmaceuticals for the treatment of microscopic residual peritoneal disease.
- *Intraperitoneal immunotherapy:* Immunotherapy, including immune checkpoint inhibitors, chimeric antigen receptor (CAR)-T cells, dendritic cell therapies, and cancer vaccines, alone or in combination, represents a promising strategy for improving outcomes in patients with peritoneal carcinomatosis.

VIDEO CONTENTS



Video 69.1: Administration of Hyperthermic Intraperitoneal Chemotherapy (HIPEC) (Open Technique)

SUGGESTED READING

1. Alyami M, Hübner M, Grass F, Bakrin N, Villeneuve L, Laplace N, et al. Pressurized intraperitoneal aerosol chemotherapy: Rationale, evidence, and consensus recommendations from the International Society for the Study of Pleura and Peritoneum. Pleura Peritoneum. 2019.
2. Bhatt A, Van Der Speeten K, Hubner M, Kusamura S, Glehen O. ASO Author Reflections: Standardizing HIPEC methodology and regimens: A prelude to the PSOGI expert consensus. Ann Surg Oncol. 2021;28:9114-5.
3. Bhatt A. Management of Peritoneal Metastases: Cytoreductive Surgery, HIPEC and Beyond. Singapore: Springer; 2018.
4. Kusamura S, Bhatt A, van Der Speeten K, Kepenekian V, Hübner M, Eveno C, et al. Review of 2022 PSOGI/RENAPE Consensus on HIPEC. J Surg Oncol. 2024;130(6):1290-8.
5. Lemoine L, Thijssen E, Carleer R, Geboers K, Sugarbaker PH, van der Speeten K. Body surface area-based vs concentration-based perioperative intraperitoneal chemotherapy after optimal cytoreductive surgery in colorectal peritoneal surface malignancy treatment: COBOX trial. J Surg Oncol. 2019;119(7):999-1010.
6. Nowacki M, Alyami M, Villeneuve L, Mercier F, Hubner M, Willaert W, et al. International expert consensus on pressurized intraperitoneal aerosol chemotherapy (PIPAC): Recommendations from the International Society for the Study of Pleura and Peritoneum (ISSPP). Ann Surg Oncol. 2022.
7. Sugarbaker PH. Cytoreductive Surgery & Perioperative Intraperitoneal Chemotherapy for Peritoneal Surface Malignancy: Textbook and Video Atlas. Woodbury: CineMed Publishing; 2012.
8. Yonemura Y, Ishibashi H, Hirano M, Mizumoto A, Takeshita K, Noguchi K, et al. Neoadjuvant intraperitoneal and systemic chemotherapy (NIPS) in the treatment of gastric cancer with peritoneal metastasis. Eur J Surg Oncol. 2012;38(10):913-9.

JAYPEE BROTHERS

for detailed information on oncology surgery books, visit our website www.ejaypee.com, for detailed information on oncology surgery books, visit our website www.ejaypee.com, for detailed

PRINCIPLES OF CANCER SURGERY

Evidence-Based Algorithms for Surgical Decision Making

Principles of Cancer Surgery: Evidence-based Algorithms for Surgical Decision Making is a concise, structured, and clinically focused guide to contemporary practice in surgical oncology. Designed for rapid learning and efficient revision, it simplifies complex oncological concepts into clear algorithms, flowcharts, and high-yield summaries. Bridging the gap between exhaustive reference texts and real-world clinical practice, the book emphasizes evidence-based decision-making, highlights landmark trials, and integrates the practical application of current clinical guidelines across organ systems.

Salient Features

- Image and algorithm-driven approach to simplify learning and surgical decision-making
- High-yield content tailored for MS/DNB (Surgery), MCh/DrNB (Surgical Oncology) trainees and candidates preparing for entrance examinations (INI-SS) and Surgical Oncology Fellowships for their residency programmes or fellowship board examinations in India and abroad
- Integration of landmark evidences with current clinical consensus guidelines
- Structured flowcharts, tables, and revision boxes for rapid revision
- Clinically relevant insights for day-to-day surgical oncology practice
- QR-linked video lectures and operative surgical videos for practical understanding
- Ideal for surgical trainees and young surgical oncologists, this book serves as a reliable companion for both examination preparation and day- to-day surgical oncology practice.



Shouptik Basu MBBS (Hons, Gold Medalist) MS (Gold Medalist) DNB (Gold Medalist) MCh (Surg Onco, AIIMS) MRCS (Edin) MRCS (Glasg) MNAMS FMAS FAIS FSSO Fellowship (Robotic Surgery) is a Consultant and Surgical Oncologist based in Kolkata, West Bengal, India, with multiple academic distinctions, including the prestigious Dr B Ramamurthy National Gold Medal in DNB. He completed his MCh (Surgical Oncology) from the All India Institute of Medical Sciences and also holds MRCS qualifications from the Royal College of Surgeons of Edinburgh and the Royal College of Physicians and Surgeons of Glasgow. He is currently serving as Consultant, Tata Medical Centre, Kolkata, West Bengal, India. His clinical interests include gastrointestinal, thoracic, and peritoneal surface malignancies, with a focus on advanced oncological procedures and multidisciplinary cancer care. He has authored several book chapters and peer-reviewed scientific publications. He also serves on the editorial boards of reputed journals in surgical oncology. He is actively involved in surgical education and academic initiatives, including the development of structured e-learning modules in surgical oncology.

Shelving recommendation
ONCOLOGY AND SURGERY

ISBN 978-93-0952-456-1

9 789309 524561

Buy from ejaypee

JAYPEE BROTHERS

JAYPEE BROTHERS