ee.com, for detailed information on gastroenterology books, visit our website www.ejaypee.com, for detailed information on gastroenterology books

ERCP

Simplified

S Easwaramoorthy

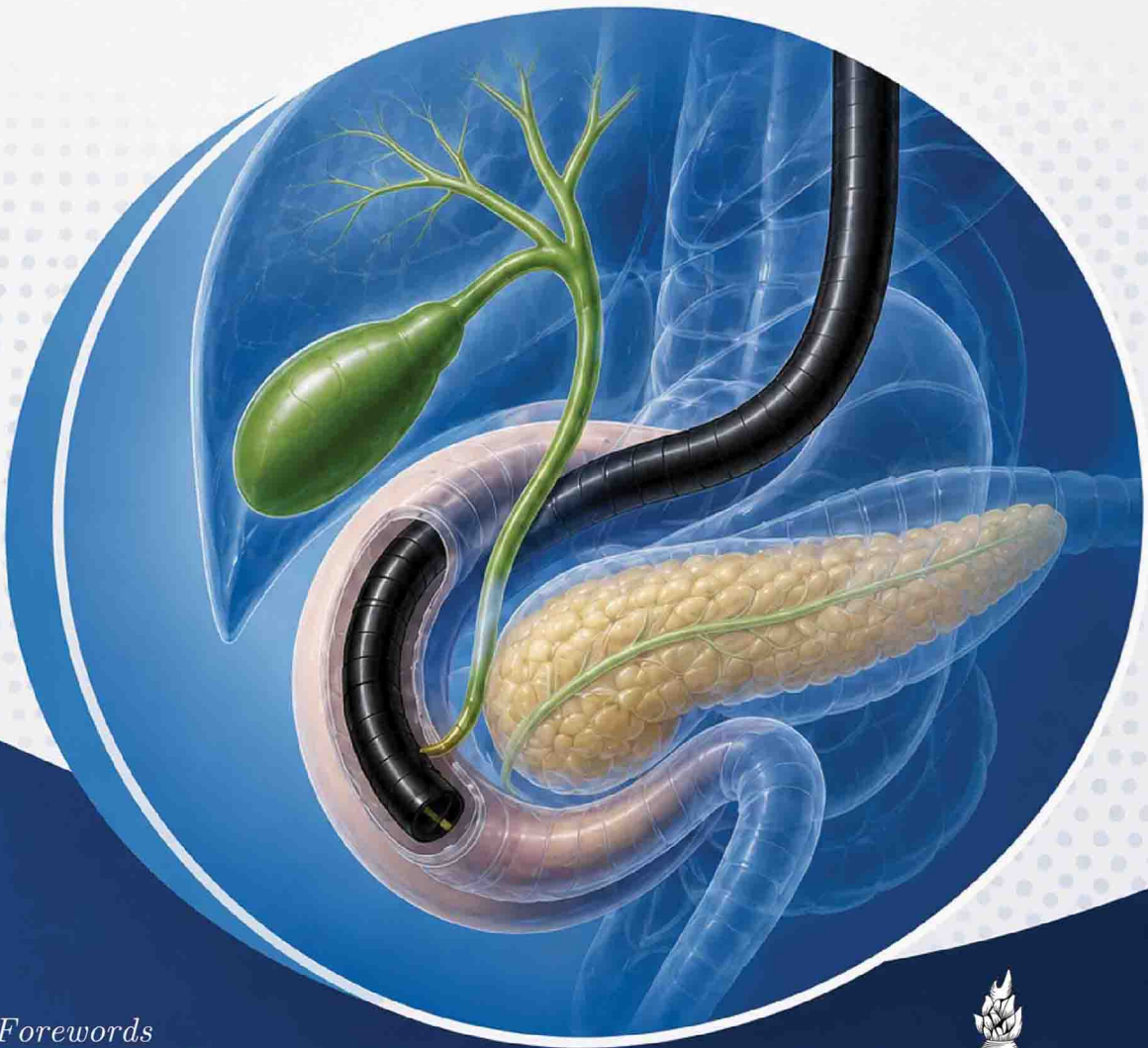

Forewords
B Krishna Rau
Eric M Pauli

JAYPEE

Contents

1. **60 Years of ERCP** 1
2. **Essential Anatomy for ERCP** 6
3. **Indications, Contraindications, Risk Stratification, and Consent for ERCP** 14
4. **ERCP Suite and Team Dynamics** 20
5. **Anesthesia for ERCP** 28
6. **Fluoroscopy for ERCP** 32
7. **ERCP Step by Step** 44
8. **Overview of ERCP Accessories** 68
9. **Selective Biliary and Pancreatic Cannulation: Tricks of the Trade** 83
10. **Precut Sphincterotomy** 95
11. **Role of ERCP in Biliary Disorders** 100
12. **The Role of ERCP in Pancreatic Disorders** 120
13. **ERCP Adjuncts** 129
14. **Complications of ERCP** 143
15. **Training in ERCP** 154

Appendices 163

Appendix 1: *ERCP Simplified: Post-test Questionnaire* 163

Appendix 2: *ERCP for Surgeons: Tips and Tricks* 168

Index *181*

CHAPTER 3

Indications, Contraindications, Risk Stratification, and Consent for ERCP

CHAPTER OUTLINE

- Indications for ERCP
- Contraindications for ERCP
- Risk Stratification before ERCP
- Model Informed Consent form for ERCP

INTRODUCTION

The fundamental principle of endoscopic retrograde cholangiopancreatography (ERCP) is that it should be performed only with a therapeutic intent. With the universal availability of high-resolution magnetic resonance cholangiopancreatography (MRCP) and endoscopic ultrasound (EUS), ERCP is no longer considered a diagnostic tool.

INDICATIONS FOR ERCP

Indications are categorized by the intent to treat or palliate specific biliary and pancreatic pathologies.

Biliary Indications

- *Choledocholithiasis:* Removal of bile duct stones using balloon or basket extraction, often following a biliary sphincterotomy
- *Obstructive jaundice:* Management of jaundice caused by biliary obstruction, whether benign (e.g., stones) or malignant (e.g., tumors).
- *Acute cholangitis:* Urgent decompression is indicated to treat ascending infections caused by biliary obstruction.
- *Gallstone pancreatitis:* Specifically indicated when there is concomitant cholangitis or persistent biliary obstruction
- *Biliary strictures:* Diagnosis (via brush cytology) and management (via stenting or dilation) of benign or malignant narrowing of the bile ducts
- *Postsurgical complications:* Management of postcholecystectomy bile leaks and strictures
- *Ampullary lesions:* Resection (ampullectomy) of adenomas or small tumors of the major papilla

Pancreatic Indications

- *Chronic pancreatitis:* Management of symptomatic pancreatic duct stones or strictures

JAYPEE BROTHERS

- *Pancreatic pseudocysts:* While EUS-guided drainage is now the primary method, ERCP remains indicated for transpapillary drainage if a cyst communicates with the pancreatic duct.
- *Pancreas divisum:* Minor papilla sphincterotomy may be required in selected symptomatic patients.
- *Pancreatic tumors:* For relief of jaundice preoperatively or with palliative intent

CONTRAINDICATIONS FOR ERCP

Contraindications are divided into absolute (where the risk of death or severe injury is high) and relative (where the procedure should proceed with extreme caution or consider alternative techniques).

Absolute Contraindications

- *Unstable cardiopulmonary status:* Patients with severe heart failure, uncontrolled arrhythmias, or respiratory compromise who cannot safely undergo sedation or general anesthesia.
- *Bowel perforation:* Existing gastrointestinal perforation makes further instrumentation potentially fatal.
- *Pharyngeal or esophageal obstruction:* Structural barriers that prevent the passage of the side-viewing duodenoscope.

Relative Contraindications

- *Uncorrected coagulopathy:* Risk of significant bleeding is high during sphincterotomy if the international normalized ratio (INR) is >1.5 or platelets <50,000/μL. Consider fresh frozen plasma transfusion before ERCP in a critically ill septic patient. Additionally, consider a temporary stent (e.g., a nasobiliary drain) without sphincterotomy to manage cholangitis initially.
- *Acute pancreatitis (nongallstone):* Except for gallstone-induced obstruction, performing ERCP during an active inflammatory phase can worsen the clinical course.
- *Contrast allergy:* Minimal systemic absorption occurs in the ducts, and for severe anaphylaxis, gadolinium-based contrast can be used as an alternative.

RISK STRATIFICATION BEFORE ERCP

Endoscopic retrograde cholangiopancreatography risk stratification is the process of identifying patients at high risk for complications, such as post-ERCP pancreatitis (PEP), hemorrhage, perforation, and sedation-related events, before the scope is even passed. Effective stratification allows for the implementation of prophylactic measures [such as rectal nonsteroidal anti-inflammatory drugs (NSAIDs) or pancreatic stents] and ensures informed consent is truly "informed."

JAYPEE BROTHERS

Patient-related Risk Factors

- *High-risk phenotype for PEP:*
  - Young age <50 years
  - Female gender
  - Prior history of PEP or recurrent pancreatitis
  - Known case of sphincter of Oddi dysfunction
- *Comorbidity [American Society of Anesthesiologists (ASA) status]:*
  - ASA III and IV with severe systemic disease such as chronic obstructive pulmonary disease (COPD), ischemic heart disease (IHD) or end-stage renal disease with high risk for any cardiopulmonary bad events
  - Child–Pugh class B or C type of chronic liver disease with risk of bleeding or infection
- *Drugs:*
  - Clopidogrel and other P_2Y_{12} inhibitors must be withheld for 5 days.
  - Direct oral anticoagulants (DOACs) such as apixaban are withheld for 48 hours.
  - Low-dose aspirin is generally continued.

Procedure-related Risk Factors

- *Difficult cannulation:* More than five attempts or >5 minutes at biliary cannulation increases the risk of PEP.
- Inadvertent entry into pancreatic duct (PD) contrast opacification
- Balloon sphincteroplasty in a younger patient
- Ampullectomy, wherein the risks of PEP, bleeding, and perforation are more

Endoscopist-related Risk Factors

- *Low-volume center:* Centers with fewer than 150 ERCPs per year
- Early in the learning curve of an endoscopist

Risk Management

Incidence or severity of PEP can be minimized by following the treatment strategy, namely:

- Aggressive hydration
- Rectal indomethacin suppository
- PD stent insertion

Risk reduction strategies include:

- Adequate training of the endoscopist
- Appropriate selection of the cases
- Proper optimization of the patients
- Excellent teamwork
- Availability of an array of accessories

JAYPEE BROTHERS

CONCLUSION

The decision to perform an ERCP is a multidisciplinary one. The endoscopist must weigh the therapeutic benefit against a significant risk profile, ensuring that less-invasive diagnostic modalities have been exhausted first. Risk assessment and risk-reduction strategy are key to minimizing the incidence of PEP and bleeding. The endoscopist should be vigilant before and during ERCP to reduce the incidence and severity of post-ERCP complications.

SUGGESTED READING

1. Adler DG, Baron TH, Davila RE, Egan J, Hirota WK, Leighton JA, et al. ASGE guideline: The role of ERCP in diseases of the biliary tract and the pancreas. Gastrointest Endosc. 2005;62(1):1-8.
2. Cohen S, Bacon BR, Berlin JA, Fleischer D, Hecht GA, Loehrer PJ Sr, et al. National Institutes of Health State-of-the-Science Conference Statement: ERCP for diagnosis and therapy. Gastrointest Endosc. 2002;56(6):803-9.
3. Cotton PB, Garrow DA, Gallagher J, Romagnuolo J. Risk factors for complications after ERCP: A multivariate analysis of 11,497 procedures over 12 years. Gastrointest Endosc. 2009;70(1):80-8.
4. Cotton PB. Analysis of 59 ERCP lawsuits, mainly about indications. Gastrointest Endosc. 2006;63(3):378-82. quiz 464.
5. Freeman ML, Guda NM. Prevention of post-ERCP pancreatitis: A comprehensive review. Gastrointest Endosc. 2004;59:845-64.
6. Haidar H, Manasa E, Yassin K, Suissa A, Kluger Y, Khamaysi I. Endoscopic treatment of post-cholecystectomy bile leaks: A tertiary center experience. Surg Endosc. 2021;35(3):1088-92.
7. Hussain N, Alsulaiman R, Burtin P. The safety of endoscopic sphincterotomy in patients receiving antiplatelet agents: A case-control study. Aliment Pharmacol Ther. 2007; 25:579-84.
8. Kohli K, Samant H, Khan K. Risk stratification in post-ERCP pancreatitis: How do procedures, patient characteristics, and clinical indicators influence outcomes? Pathophysiology. 2021;28:76-85.
9. Masci E, Mariani A, Curioni S. Risk factors for pancreatitis following endoscopic retrograde cholangiopancreatography: A meta-analysis. Endoscopy. 2003;35:830-4.
10. Tse F, Yuan Y. Early routine endoscopic retrograde cholangiopancreatography (ERCP) strategy versus early conservative management strategy in acute gallstone pancreatitis: A Cochrane systematic review and meta-analysis. Cochrane Database Syst Rev. 2012;16:CD009779.

JAYPEE BROTHERS

MODEL INFORMED CONSENT FORM FOR ERCP

Patient Name: ..... *DOB:* ..... *MRN:* .....

Procedure Description

I authorize Dr ..... and designated assistants to perform *endoscopic retrograde cholangiopancreatography (ERCP)*. I understand this involves passing a flexible endoscope through the mouth to the small intestine to visualize the bile and pancreatic ducts using X-ray dye.

Authorized Interventions

I further authorize the following as medically necessary:

- *Sphincterotomy:* Enlarging the duct opening using electric current.
- *Stone extraction:* Removing stones from the bile or pancreatic ducts.
- *Stent placement:* Inserting plastic or metal tubes to ensure drainage.
- *Biopsy/cytology:* Collecting tissue or cell samples for testing.
- *Dilatation:* Stretching narrowed areas of the ducts.

Acknowledgment of Risks

I understand that although ERCP is generally safe, serious complications can occur, including:

- *Pancreatitis:* Inflammation of the pancreas (most common risk).
- *Bleeding:* Especially following sphincterotomy.
- *Infection:* Inflammation of the bile ducts (cholangitis).
- *Perforation:* A tear or hole in the esophagus, stomach, or bowel.
- *Sedation risks:* Allergic reactions or respiratory/cardiac issues.

Declaration by the Patient

- I have been informed of the *benefits* and *alternatives* (e.g., MRCP, surgery).
- I understand no guarantee has been made regarding the procedure's outcome.
- I have had the opportunity to ask questions, and they have been answered to my satisfaction.
- I voluntarily consent to the procedure and understand I may withdraw this consent at any time before the procedure begins.

JAYPEE BROTHERS

- I understand all the above details, being told to me in my native language before signing the consent form

Signatures

- *Patient/Guardian Signature:* ..... *Date/Time:* ....
- *Doctor Signature:* ..... *Date/Time:* .....
- *Witness Signature:* ..... *Date/Time:* .....

JAYPEE BROTHERS

or detailed information on gastroenterology books, visit our website www.ejaypee.com, for detailed information on gastroenterology books, visit our

ERCP
Simplified

Master the art of biliary and pancreatic intervention with this streamlined guide designed for all enthusiastic endoscopists. Endoscopic retrograde cholangiopancreatography (ERCP) is often intimidating, but this manual simplifies its complexity into actionable bedside practice.

Covering 15 essential topics, we start with the foundations—clinical anatomy, ERCP suite, and fluoroscopy basics—before diving into the technical nuances of both basic and difficult cannulation. Packed with hard-won tips, "how-to" tricks, and plenty of high-resolution pictures, this visual-first resource bridges the gap between surgical intuition and advanced endoscopic skill.

Whether you are navigating difficult ductal access or refining your sphincterotomy technique, this book provides the clarity you need for superior patient outcomes.

Elevate your practice with this ultimate simplified reference for mastering the Art and Science of ERCP.



S Easwaramoorthy MS FRCS (England) FRCS (Glasgow) Hon FRCS (Edinburgh) CCST (UK) FAGIE (ERCP) FALS FAES is a well-known Minimal Access Surgeon and a renowned Endoscopic Trainer for 3 decades. Currently, he serves as Professor of Surgery and Consultant Surgeon, Department of Minimal Access Surgery, Lotus Hospital and Research Centre, Erode, Tamil Nadu, India. *Manual of Endoscopy* and *Art and Science of Colonoscopy* are his other famous books in the field of flexible endoscopy.

Shelving Recommendations
GASTROENTEROLOGY & HEPATOLOGY

ISBN 978-93-0952-685-5

Buy from ejaypee

JAYPEE BROTHERS