ur website www.ejaypee.com, for detailed information on cardiology books, visit our website www.ejaypee.com

# Tips & Tricks in Interventional Cardiology

Shuvanan Ray



4th Edition

JAYPEE

# Contents


1. **Who Needs Percutaneous Coronary Intervention?.....1**
   *Soumitra Kumar, Shuvanan Ray*
   - Percutaneous Coronary Intervention in ST Elevation Myocardial Infarction *2*
   - Percutaneous Coronary Intervention in Non-STEMI and Acute Coronary Syndrome *3*
   - Percutaneous Coronary Intervention in Stable Angina *4*

2. **Cath Lab Workstation (The Unsung Heroics).....7**
   *Sabyasachi Mitra, Shuvanan Ray*
   - Components of Catheterization Laboratory Team *7*
   - Care—C: Check *8*
   - Care—A: Avoid *11*
   - Care—R: Reset *18*
   - Diabetic Patients before Percutaneous Coronary Intervention *20*
   - Care—E: Explain *22*
   - SYNTAX and Clinical SYNTAX Score *23*
   - Postprocedure Care *24*
   - Events after Percutaneous Coronary Intervention *34*
   - Postprocedure Medications *35*
   - Life after Percutaneous Coronary Intervention *37*

3. **The Gateway of Percutaneous Coronary Intervention—Access and its Management .....40**
   *Shuvanan Ray*
   - Why Radial Access? *40*
   - Femoral Access *41*
   - Radial Access *46*

4. **Hemodynamics in Catheterization Laboratory (The Guiding Star).....52**
   *Shuvanan Ray*
   - How do You Formulate a Hemodynamic Worksheet? *52*
   - Measurement of Cardiac Output *54*
   - Story of Oxygen and Hemodynamic Data *57*
   - Shock *60*
   - Pulmonary Hypertension *61*
   - Uses of Hemodynamic Calculations in Catheterization Laboratory *61*

**5. Radiographic Views for Vascular Anatomy (The Pathway).....71**
*Sabyasachi Mitra, Shuvanan Ray*

- Heart *71*
- Arterial Supply of the Heart *72*
- How to Start Coronary Visualization? *75*
- Arteries of the Head and Neck *84*
- Subclavian Arteries *86*
- Arteries on the Posterior Abdominal Wall *92*
- Selective Cannulation *97*
- Arteries of the True Pelvis *99*

**6. Guide Catheters (The Platform)..... 101**
*Shuvanan Ray*

- Guide Catheter *101*
- Depending on the Support, Classification of Guide Catheters *102*
- Basic Shapes of Guide Catheters *104*
- Cannulation of Coronary Arteries *105*

**7. Guidewires (The Lifeline) ..... 117**
*Shuvanan Ray*

- Structure of Guidewire *117*
- Newer Wires *120*
- Special Guidewires According to Tip Load *123*
- Manipulation of Guidewire *123*
- Complications of Guidewires *129*

**8. Balloon Catheters (The First Revolution)..... 130**
*Suman Karmakar, Shuvanan Ray*

- Properties of Balloon Catheter *130*
- Selection of Balloon Catheter *136*
- Drug-coated Balloons *137*

**9. Stents/Stents/Stents..... 141**
*Priyam Mukherjee, Shuvanan Ray*

- Everolimus-eluting Stents *144*
- Device-related Safety Outcomes: Insights from Mechanical and Device Integrity and Failure *145*
- Biodegradable Polymers *149*
- Polymer-free Stents *150*
- Tapered Stents *151*
- Ultrathin Strut Stents *151*
- Bioresorbable Vascular Scaffolds *152*

**10. Intravascular Imaging—A New Era ..... 155**
*Avik Karak, Basabendra Choudhury, Shuvanan Ray*

- Fractional Flow Reserve *155*
- Instantaneous Wave-free Ratio *159*

- Intravascular Imaging (IVUS, OCT) *164*
- Assessing Percutaneous Coronary Intervention *169*

**11. Drugs Used in the Catheterization Laboratory and Mechanical Circulatory Support ..... 184**
*Deepankar Paul, Arindom Mondal, Siddhartha Bandyopadhyay, Shuvanan Ray*

- Antiplatelet Agents *184*
- Cyclooxygenase Inhibitor *184*
- Adenosine Diphosphate Receptor Antagonists *185*
- Anticoagulant Therapy *188*
- No-reflow Phenomenon *190*
- Vasoactive Drugs in Catheterization Laboratory *191*
- Mechanical Circulatory Support *199*
- Cardiogenic Shock *211*

**12. PCI in Difficult Subsets and Complex Patients (Keep it Simple Stupid)!..... 217**
*Shuvanan Ray*

- Bifurcation Stenosis Percutaneous Coronary Intervention *217*
- Side Branch First: The Crush Family *226*
- Ostial Lesions *232*
- Percutaneous Coronary Intervention in a Tortuous Artery *238*
- Calcified Lesions *245*
- Steps of Rotablation *251*
- Chronic Total Occlusion (The Antegrade Way) *258*
- Predictive Factors Related to Success or Failure of PCI for Chronic Total Occlusion *260*
- Hardwares for Chronic Total Occlusion Intervention *262*
- Other Techniques *271*
- Thrombus-containing Lesions *278*
- A Few Words about Saphenous Vein Graft Angioplasty *285*
- In-stent Restenosis *289*

**13. Structural Heart Disease—A New Horizon of Catheter Intervention ..... 294**
*Pallab Kumar Bose, Shuvanan Ray*

- Mitral Balloon Valvuloplasty *294*
- Accordion Maneuver *303*
- Pulmonary Balloon Valvuloplasty *305*
- Aortic Stenosis *307*
- Postprocedure Management *323*

**14. Congenital Heart Disease Intervention in Adults: ASD/VSD/PDA ..... 325**
*Lopamudra Mishra, Shuvanan Ray*

**Atrial Septal Defect Closure 325**
- Data to Support Atrial Septal Defect Closure in Adults *325*
- What to Do—Device or Surgery? *326*
- Definition of Rims *327*
- Steps of Closure *328*

**Ventricular Septal Defect Closure 332**
- Indications for Percutaneous Closure of Ventricular Septal Defects *332*
- Criteria for Percutaneous Closure *332*
- Contraindications for Percutaneous Closure *332*
- Steps *332*

**Patent Ductus Arteriosus 333**
- Indications for Intervention in Patent Ductus Arteriosus *333*
- Steps of Device Closure *334*
- Coarctation of Aorta *335*
- Balloon Coarctoplasty *338*
- Coarctation of the Aorta Stenting Procedure *339*

**15. Complications and Cath Lab Nightmares ..... 342**
*Prithwiraj Bhattacharjee, Shuvanan Ray*

- Types of Complications *342*
- Management of Complications *343*
- Radial Access Complications *345*
- Coronary Complications *346*
- Postprocedural Complications *360*
- Coronary Aneurysm *364*
- Others *368*

*Index* ..... *375*

CHAPTER 3

# The Gateway of Percutaneous Coronary Intervention—Access and its Management

*Shuvanan Ray*

## INTRODUCTION

Percutaneous Seldinger technique changed the choice of access for percutaneous coronary intervention (PCI) to femoral artery (FA), and it became a rule. Later, radial artery (RA) and, occasionally, ulnar arteries are being used, and particularly, radial access is getting such popularity that it has become a parallel institution.

## WHY RADIAL ACCESS?

*Problems of radial access:* Radial access has some problems which can be overcome with practice.

- Radial artery is a more muscular artery that has a tendency to develop spasms, producing pain and difficulty in catheter manipulation. This can happen in spite of drugs to combat.
- Anatomical variations, severe tortuosities, or loops in RA or brachial artery (incidence is close to 5%)
- Access does not allow catheters > 7F.
- Backup support maybe under question in some complex procedures.

So, access for PCI is mostly femoral and radial, and a budding interventional cardiologist must know at least these two accesses thoroughly **(Table 3.1)**.

**TABLE 3.1:** Advantages of radial access: Less access-related complications compared to femoral.

| *Complications* | *Femoral (%)* | *Radial (%)* |
|---|---|---|
| Hematoma (>5–10 mL) | <5 | 1–3 |
| Retroperitoneal bleeding | <2 | 0 |
| Pseudoaneurysm | 1–2 | <0.1 |
| Arteriovenous fistula | 1–2 | <0.8 |
| Limb ischemia | <0.1 | Extremely rare |
| Infection | <5 | <0.1 |
| Dissection/perforation | <1 | <1 |

JAYPEE BROTHERS

## FEMORAL ACCESS

For femoral access, the following important points are to be remembered:

- Puncture should be done in the common FA.
- It must be an anterior wall puncture.

### How do You Locate the Common Femoral Artery? (Fig. 3.1)

- Skin crease and inguinal ligament by surface marking
- Radiological marker—the femoral head
- Arterial calcification, if any
- Ultrasonography (USG)-guided puncture

  Femoral access is not a very difficult procedure to learn, particularly in a young, nonobese, male subject, but it is difficult and needs attention and planning in obese, female, and elderly patients.
- *Inguinal ligament:* It is the most important surface marking for femoral access because it is the line at which the "U" shaped origin of inferior epigastric artery takes place, and any puncture at or above the site would cause damage to the artery leading to retroperitoneal hemorrhage. So, the upper limit of the puncture must be the inguinal ligament.
- *Skin crease and inguinal ligament:* It is to be stressed that inguinal skin crease does not corroborate with inguinal ligament, particularly in obese patients or patients with lax abdominal walls.
- *Radiological marker:* It is seen that the radiological marker for perfect femoral puncture is the midpoint of femoral head. The common femoral artery (CFA) extends along the length of femoral head. So, to locate the puncture site, it is better to locate femoral head in an anteroposterior (AP) view with leg externally rotated and knee extended. A metal hemostat is used as a marker to identify the best location for femoral artery cannulation. This is achieved by a skin puncture done at the lower border of femoral head with the needle entering the skin at 30–45° angle (steeper angle in more obese patients).

JAYPEE BROTHERS

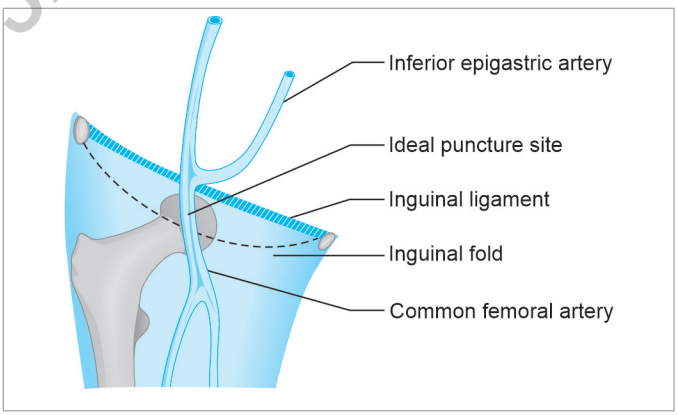


**Fig. 3.1:** Anatomy of femoral artery.

It is not advisable to puncture lower (near or below femoral head) for the fear of puncturing profunda femoris artery, which gives rise to more pseudoaneurysm formation.

- *USG-guided puncture:* The FAUST (Femoral Arterial Access with Ultrasound Trial) has demonstrated the superiority of USG-guided puncture of CFA in reduction of complications (like major bleeding, retroperitoneal hemorrhage, and pseudoaneurysm) over the fluoroscopy-guided femoral puncture. Although it may be beneficial in selected high-risk populations, particularly obese patients in high anticoagulant milieu (like in rescue PCI), USG-guided puncture in all patients cannot be recommended as mandatory.

## Ultrasound-guided Femoral Puncture

### *Retrograde Puncture (Fig. 3.2)*

- A linear array probe is normally used; this produces a rectangular image, which is displayed with the skin surface at the top, the vertical axis showing depth into the body and the horizontal axis showing position along the probe. When imaging blood vessels, the probe can be placed either along the vessel to produce a longitudinal scan or across the vessel to produce a transverse scan.
- For retrograde femoral puncture, transverse scan is sufficient. But for antegrade puncture, longitudinal scan helps in directing the wire into superficial femoral artery (SFA).

JAYPEE BROTHERS

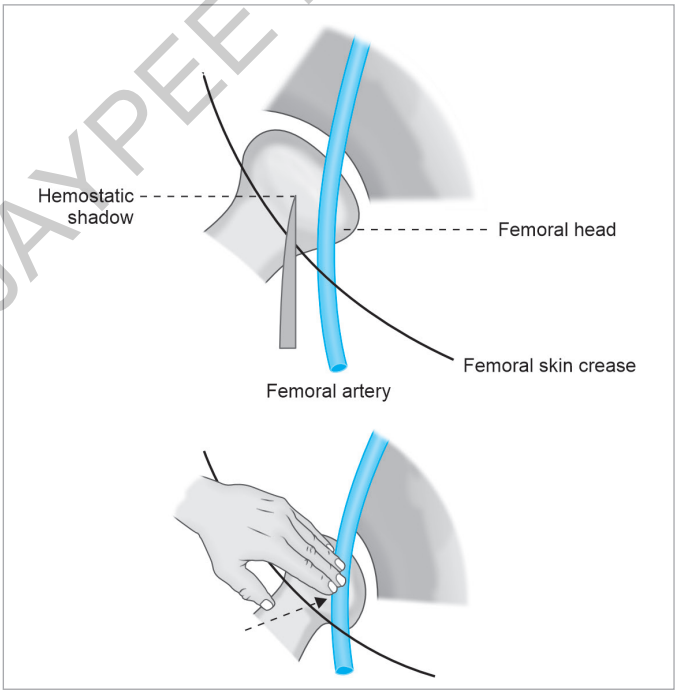


**Fig. 3.2:** Performing a proper puncture.

- Vascular probe is placed just below the inguinal crease with indicator at 9'o clock direction.
- FA is located in the middle as pulsatile round shadow; medial to it is the elliptical femoral vein which is compressible.
- Needle is inserted just behind the probe to go proximally, and it is seen above the femoral arterial shadow. If the needle is pushed, it enters the artery **(Fig. 3.3)**.

## *Antegrade Puncture (Figs. 3.4 to 3.6)*

First, locate the bifurcation of the femoral artery; once the bifurcation is identified, trace the artery proximally to identify CFA and then make a transverse scan and try to puncture.

*Popliteal access:* Femoral artery (FA) maybe punctured in probe position but we prefer supine puncture.

JAYPEE BROTHERS

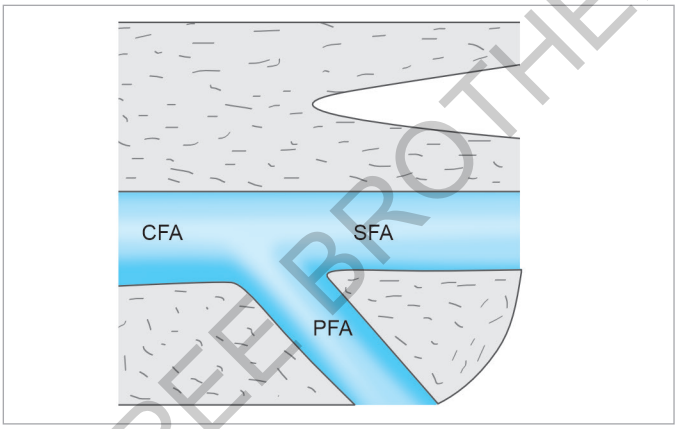


**Fig. 3.3:** Longitudinal scan of the femoral artery. CFA divides into SFA and PFA. Skin surface is at the top of the image. Arterial blood flow is from left to right.

(CFA: common femoral artery; PFA: profunda femoris artery; SFA: superficial femoral artery)

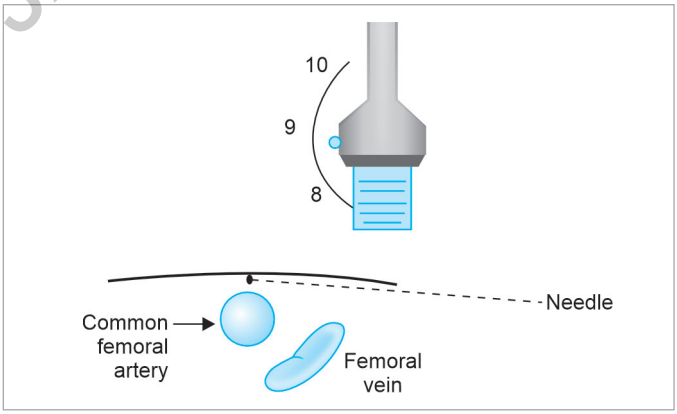


**Fig. 3.4:** Transverse scan.

The patient remains supine with the lower extremity 60° externally rotated and knee in gentle flexion. The puncture site is usually 8–10 cm below the border of the medial condyle of the femur and parallel with the posterior medial border of the tibia for 1 cm. The puncture is performed with 21-gauge needle and a 0.018-inch V-18 guidewire (Boston).

## *Puncture of Dorsalis Pedis Artery (USG-guided)(Figs. 3.7)*

Puncture of dorsalis pedis artery is shown in **Figures 3.7**.

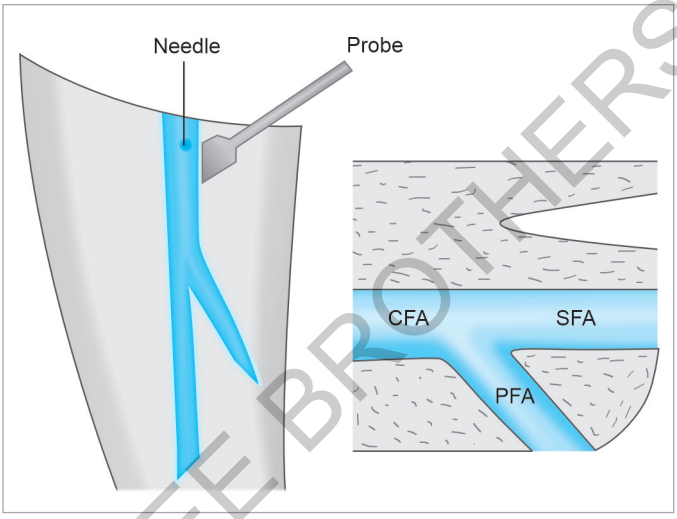


**Fig. 3.5:** Antegrade femoral puncture.

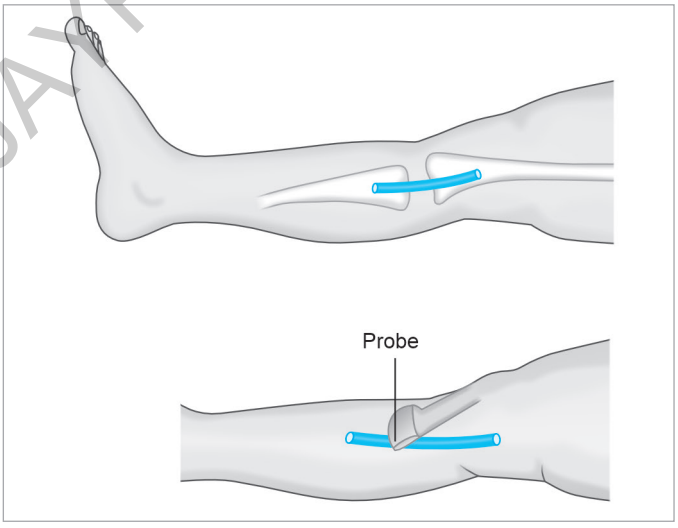


**Fig. 3.6:** *Popliteal puncture*: Place the vascular probe on popliteal artery and puncture. Leg is slightly flexed and externally rotated at hip.

JAYPEE BROTHERS

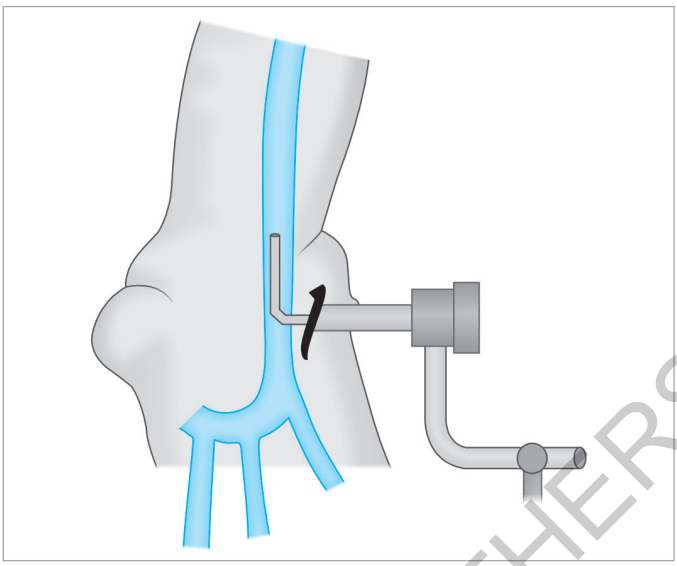

**Fig. 3.7:** 4F sheath: Dorsalis pedis puncture.

JAYPEE BROTHERS

*How to Perform a Proper Puncture?*

- Locate the puncture site.
- Surface marking of inguinal ligament and 2 cm below it, where maximum pulsation of FA is felt; correlate radiologically.
- Feel the pulse with the flat of your fingers (do not buckle).
- With a 25-gauge needle, the skin is to be infiltrated with 1% lidocaine 2–3 cm below the index finger placed over the artery.
- 10 mL lidocaine is to be given to the skin and if possible, track the needle through the subcutaneous tissue.
- Now, take a standard arterial puncture needle and place the needle at the site where local anesthetic is given and push the needle at an angle that allows the needle to reach the estimated puncture site on the artery; usually, it is 30–45%.
- When the needle reaches the artery, arterial pulsation can be felt. Push the needle a little. The blood jet will come out and the anterior puncture of FA is established.
- Put the guidewire through the needle hub. It will be easy to steer till the end.
- Come out with the needle; make a small nick around the wire with an 11-blade scalpel.

Push the sheath in:

- If the guidewire does not go easily, rotate and manipulate the needle and try to negotiate the wire; do not use force to push the wire.
- If the wire moves a certain length without any hindrance and then gets stuck, try the Wholey wire (Covidien, Mansfield, MA).
- Do not use Terumo/hydrophilic wire through needle; its Teflon coating will be stripped off.
- If it does not go after simple maneuvers, remove the needle, press for 10 minutes and then try again on either ipsilateral or contralateral side.

# RADIAL ACCESS

## Patient Selection

*Allen's test:* In most of the laboratories, modified Allen's test is used. The steps are as follows:

- Put a pulse oximeter on the index finger of the right hand, and look for a normal oximeter wave.
- Compress the RA and look for the response.
  - *Type A:* No change in pulse wave
  - *Type B:* A damped but distinct pulse wave
  - *Type C:* Loss of phasic pulse waveform

Radial puncture and cannulation can proceed with type A or type B response but not with type C response **(Fig. 3.8)**.

*Reverse Allen's test*: Recommended in previously cannulated RA. In this test, a phasic waveform is observed after compressing the ulnar artery.

## Patient Preparation

Patient is to be sedated, well hydrated, and comfortably positioned.

- Wrist to be placed next to the femoral access site.
- A roll of sterile towels is used to support and flex the wrist in a hyperextended position **(Fig. 3.9)**.
- *Puncture point:* After draping, the radial pulse is palpated. The ideal puncture site is 1–2 cm proximal to radial styloid, the bony prominence of the distal radius.
- A small amount (1 mL) of local anesthetic is infiltrated in and around the puncture point, raising a small wheal.
- Many standard radial kits are available nowadays. A standard hydrophilic sheath with Angiocath type 20G needle and 0.25" × 18" cm hydrophilic guidewire (Terumo) can be recommended to start a program.

JAYPEE BROTHERS



**Fig. 3.8:** Position of hand for radial puncture.

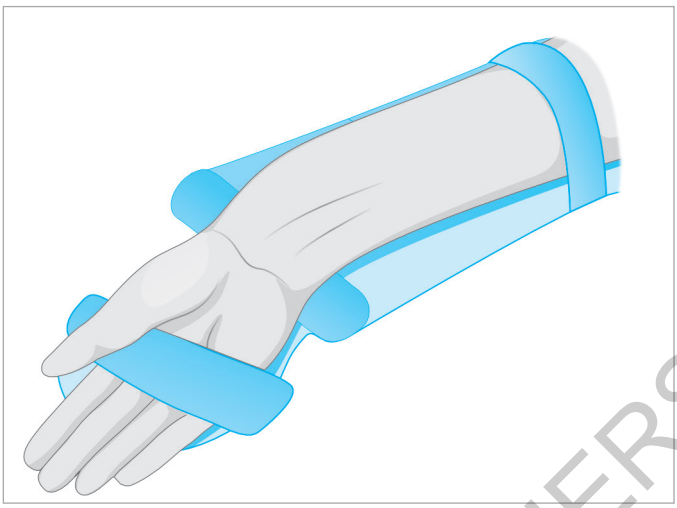

**Fig. 3.9:** Hyperextension at wrist joint.

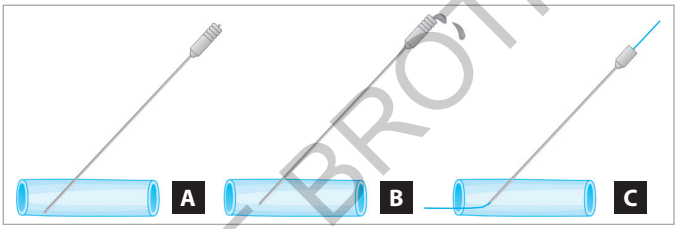


**Figs. 3.10A to C:** Radial artery cannulation.

JAYPEE BROTHERS

- The needle with plastic sheath assembly can be steered through the puncture point on the skin toward the artery to transfix the vessel. Once the artery is punctured, then there will be a faint blood stain into the needle hub **(Fig. 3.10A)**.
- Remove the needle from the cannula and withdraw the cannula very gently till the pulsatile blood comes out through it **(Fig. 3.10B)**.
- Steer the guidewire through the cannula and keeping it in place; withdraw the cannula from the artery **(Fig. 3.10C)**.
- Make a small nick on the skin around the guidewire with an 11-blade scalpel.
- Thread the sheath on the guidewire, till the end of guidewire comes out of the sheath.
- Push the sheath in and remove guidewire and dilator together from the sheath.

## Radial Access: Troubleshooting

- If the wire is stuck anywhere, do not push but take an angiogram picture.
- On the basis of angiography, anatomic variant diagnosis is made. This can be classified in three subgroups **(Table 3.2)**:

**TABLE 3.2:** Subgroups of anatomic variant diagnosis.

| *ABC: Anatomical variant* | *Prevalence* |
|---|---|
| *Group A: Radio–brachial arterial axis* | |
| Absent radial pulse | 0.3 |
| Significant (>50%) radial stenosis | 0.4 |
| Radial–brachial tortuosities (>45°) | 4.9 |
| Radial–brachial arterial loops **(Fig. 3.11)** (360° loops in arterial course not located at anastomotic sites) | 0.4 |
| Radioulnar loops (360° loops at the anastomosis with brachial–ulnar artery) | 0.7 |
| High origin of the radial artery, brachial–axillary artery | 29 |
| *Group B: Axillary–subclavian–anonymous arterial axis* | |
| Severe tortuosities (bend of >90° in the contour of the vessel) | 1.5 |
| Significant (>50%) stenosis | 0.4 |
| *Group C: Aortic arch* | |
| Retroesophageal right subclavian artery (arteria lusoria) | 0.2 |
| Aortic arch elongation | 0.1 |

JAYPEE BROTHERS

  - *Group A:* Radial–brachial arterial axis
  - *Group B:* Axillary–subclavian–anonymous axis
  - *Group C:* Aortic arch
- Commonly, a hydrophilic guidewire can overcome tortuosities and bends in group A. And in group B, a hydrophilic guidewire and deep inspiration can allow the catheter to move into the ascending aorta.
- The fact is that loops and tortuosities are invariably unilateral; so, if there is a loop on the right side, left radial can be tried.
- Few important tricks can be used before moving to another access:
  - *Trick 1:* If there is a 360° loop, try with an extra support 0.014" percutaneous transluminal coronary angioplasty (PTCA) wire to cross. Try to negotiate with Judkins right (JR) catheter; if it fails, then try trick 2.
  - *Trick 2:* Put another wire to act as a buddy wire and try the same; if it fails, then try trick 3.
  - *Trick 3:* Balloon-assisted tracking (BAT) is a technique in which an inflated balloon is placed partially into the catheter and partially outside, deployed at 3–6 atmosphere pressure. For 5F catheter 1.5 × 15 mm and for 6F catheter 2 × 15 mm balloon is used usually. Now, entire assembly can be tracked over a 0.014" PTCA wire. It can be used not only in radial loop but also in any spasm or tortuosity involving RA/brachial or subclavian artery.
  - *Trick 4:* Exchange of wire. If it is difficult to track on the PTCA wire, take a pigtail catheter and push the catheter

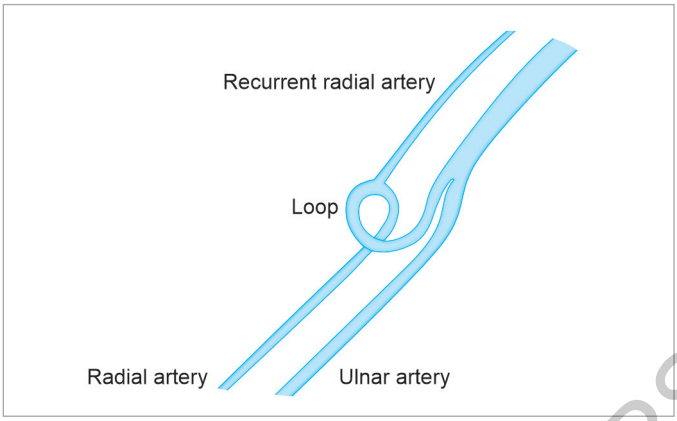


**Fig. 3.11:** Radial loop.

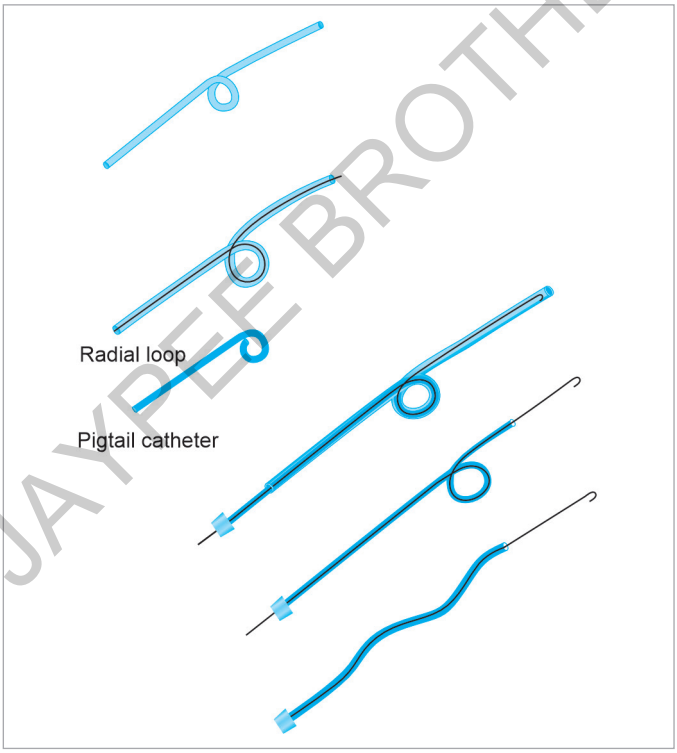


**Fig. 3.12:** Trick 4.

as far as possible; then try to exchange PTCA wire with either 0.025/0.035 wire and try to track on it. Sometimes, the wire can be exchanged with Super Stiff wire and that will straighten the loop. Remember, Super Stiff wires precipitate radial spasm **(Fig. 3.12)**.

JAYPEE BROTHERS

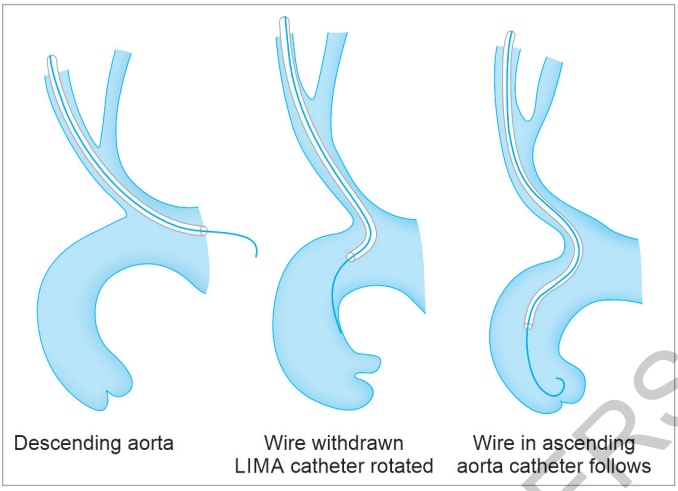


**Fig. 3.13:** Entering ascending aorta from right radial route.

- *Elongated aorta and arteria lusoria:* True arteria lusoria is rare (<1%) but elongated aorta also, sometimes, has the same effect on transradial procedure. The problems are two-fold:
  i. To enter ascending aorta
  iii. To cannulate coronary ostium
- *Entry into ascending aorta [left anterior oblique (LAO)-40 view]* **(Fig. 3.13)**: Ask the patient to take a deep breath and push the guidewire (0.35). If it enters ascending aorta, track the catheter on it.

If a right coronary or Tiger catheter fails to enter the ascending aorta, take a LIMA diagnostic catheter/Simmons catheter and come to descending aorta. Then rotate the catheter and withdraw so that it faces toward the ascending aorta in LAO view. Push the guidewire and enter the ascending aorta. Follow the wire with the catheter. Once in ascending aorta, the catheter is exchanged on an exchange-length guidewire (Patel et al.).

- Cannulation of coronary arteries:
  - *Left coronary artery (LCA):*
    - EBU, XB (0.5 size larger)
    - JL
    - Ikari L (one size higher)
  - Right coronary artery (RCA):
    - Multipurpose catheter (MAC), Amplatz left (AL), Judkins right (JR)

## Radial Cocktail and Radial Spasm

Radial spasm can make the procedure very uncomfortable for both the patient and the operator. Following are the steps to prevent radial spasm:

- *Before procedure*
  - Topical nitroglycerin (NTG) over the radial artery (optional)

JAYPEE BROTHERS

- *Sedation:* Fentanyl 25–50 μg + Ondansetron 4 mg IV
- Local anesthetic, 1% lidocaine

- *After sheath insertion:*
  - NTG 100–200 μg/Nicorandil
  - Verapamil 2.5–5 mg diluted in 10 mL saline
  - Heparin 5,000 IU for angiography and 80–100 IU/kg for PCI
- Try to puncture on first attempt.
- Do not exchange catheters frequently.
- Downsizing of catheter (e.g., 5F)

## CONCLUSION

Given the rapid pace at which the transradial approach is surpassing and displacing the transfemoral approach, one cannot help but wonder if the future of transfemoral procedures will be limited to a select few super-specialists.

## SUGGESTED READINGS

1. Burzotta F, Brancati MF, Trani C, Tommasino A, Porto I, Niccoli G, et al. Impact of radial-to-aorta vascular anatomical variants on risk of failure in trans-radial coronary procedures. Catheter Cardiovasc Interv. 2012;80(2):298-303.
2. Lim MJ, Sorajja P, Kern MJ (Eds). The Interventional Cardiac Catheterization Handbook. Amsterdam, Netherlands: Elsevier; 2013.
3. Patel T, Shah S, Pancholy S, Radadiya R, Deora S, Vyas C, et al. Working through complexities of radial and brachial vasculature during transradial approach. Catheter Cardiovasc Interv. 2013;83(7):1074-88.
4. PCR Online. (2012). Percutaneous Interventional Cardiovascular Medicine: PCR-EAPCI Textbook. [online] Available from https://textbooks.pcronline.com/the-pcr-eapci-textbook [Last accessed February, 2024].
5. Tugrul Norgaz, Gorgulu S, Dagdelen S. A randomized study comparing effectiveness of right and left radial approach of coronary angiography. Catheter Cardiovascular Intervention. 2012;80(2):260-64.

JAYPEE BROTHERS

for detailed information on cardiology books, visit our website www.ejaypee.com, for detailed information on car

Tips & Tricks in

# Interventional Cardiology

***Salient Features***

- Explains important ideas in a way that is easy to understand
- Evidence-based coverage of percutaneous coronary intervention (PCI) indications, coronary anatomy, and radiological views
- Chapters are updated with recent advances wherever required
- Updated PCI techniques for complex lesions including rotational atherectomy, Orbital atherectomy and Intravascular Lithotripsy (IVL)
- Comprehensive discussion on PCI tools, intravascular ultrasound (IVUS), optical coherence tomography (OCT), stents, and CathLab hemodynamics
- Covers structural heart interventions such as transcatheter aortic valve replacement (TAVR), left atrial appendage (LAA) closure, and MitraClip
- Handy book for fellows, operators, technicians and nurses in the CathLab.



**Shuvanan Ray** MD DM FSCAI FACC FCSI is the Director of the Department of Cardiology and Chief of Cardiac Intervention, Fortis Hospitals, Kolkata, West Bengal, India. He passed MBBS (1979) from RG Kar Medical College and Hospital, followed by MD in Medicine and DM in Cardiology from Calcutta University, Kolkata. He is Fellow of Cardiological Society of India (CSI), Fellow of Society for Cardiac Angiography and Interventions (SCAI), Fellow of American College of Cardiology (ACC), and Member of International Andreas Gruentzig Society. He regularly conducts live workshops in different national and international cardiological meetings as the Principal Operator. He has over 100 publications (national and international) to his credit.

Over the years of practice in the field of cardiac intervention, he has gathered countless experiences and immense reputation. Through this book, he ventures to share a part of his eternal knowledge for all.

Shelving Recommendation
**CARDIOLOGY**

ISBN 978-93-0952-986-3

9 789309 529863

Buy from ejaypee

JAYPEE BROTHERS