HUMAN ANATOMY

A Dissection Manual

Sujatha Kiran

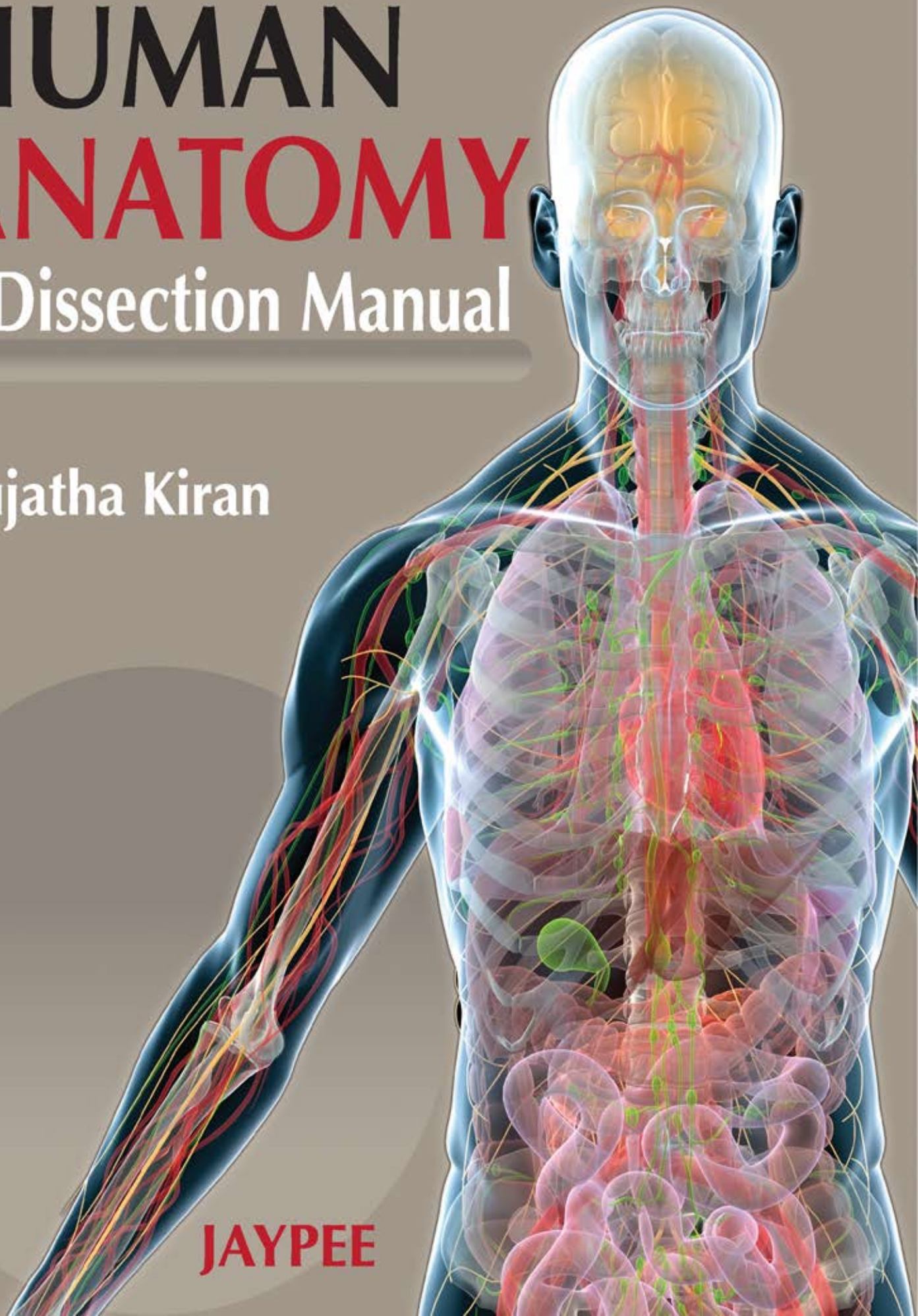

JAYPEE

Contents

1. General Introduction 1



- Anatomical Terminology 3
- Structures Encountered in Dissection 5
- Dissection 17
- Instruments and their Usage 18
- Dissection Methodology 18

2. Upper Limb 21



- Pectoral Region 24
- Axilla 31
- Sternoclavicular Joint 35
- Back 36
- Disarticulation of the Upper Limb 39
- Scapular Region 40
- Anterior Compartment of Arm and Cubital Fossa 42
- Back of the Arm 48
- Pectoral Girdle and Shoulder Joint 51
- Front of Forearm and Hand 53
- Back of the Forearm and Hand 69
- Joints of the Hand 77

3. Thorax 85

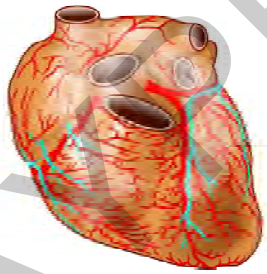

- Thoracic Wall 87
- Pleural Cavity 92
- Anterior Mediastinum 98
- Middle Mediastinum 98
- Posterior Mediastinum 112

4. Abdomen 117

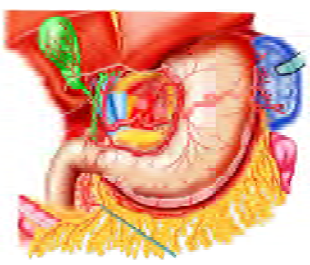

- Loin 121
- Anterolateral Abdominal Wall 124
- Inguinal Canal and Scrotum 128
- Abdominopelvic Cavity 134
- Diaphragm 137
- Lesser Sac 138
- Coeliac Trunk 139

JAYPEE BROTHERS

- Liver 140
- Gallbladder 142
- Stomach 143
- Spleen 145
- Jejunum and Ileum 146
- Large Intestine 148
- Duodenum and Pancreas 153
- Kidney, Suprarenal and Blood Vessels 158
- Autonomic Nerve Plexuses 161
- Posterior Abdominal Wall 163

5. Pelvis and Perineum 167



Pelvis 169
- Pelvic Peritoneum 170
- Male Pelvis 173
- Female Pelvis 177
- Pelvic Wall 180

Perineum 185
- Anal Triangle 185
- Urogenital Region—Male 187
- Urogenital Region—Female 191

6. Lower Limb 195



- Anteromedial Aspect of Thigh 199
- Gluteal Region 211
- Back of Thigh and Popliteal Fossa 218
- Hip Joint 224
- Back of Leg 227
- Knee Joint 231
- Anterolateral Compartment of Leg and Dorsum of Foot 236
- Ankle 243
- Joints of the Foot 253
- Tarsal Joints 255

7. Head and Neck 259

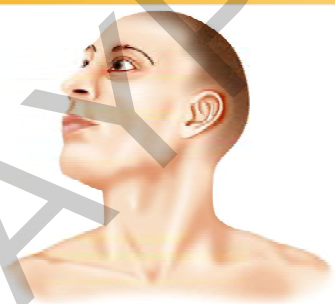

Superficial Dissection of Head 262
- Scalp 262
- Face 267

Neck 274
- Posterior Triangle 277
- Suboccipital Triangle 283
- Anterior Triangle 285
- Sternoclavicular Joint–Disarticulation 288
- Inlet of Thorax 289
- Thyroid and Parathyroid 291
- Neurovascular Bundle 292
- Digastric Triangle 300

Deep Dissection of Head 302
- Temporal and Infratemporal Region 302

JAYPEE BROTHERS

- Submandibular Region 308
- Removal of Spinal Cord 310
- Cranial Cavity 312
- Orbit 317
- Nose 323
- Mouth 331
- Pharynx 335
- Larynx 339
- Eyeball 344

8. Central Nervous System 347

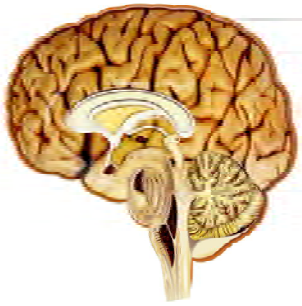

Spinal Cord 347
- Blood Supply of Spinal Cord 349
- External Features 350
- Internal Structure 352

Brain 354
- External Features 354
- Brainstem 360
- Cerebellum 363
- Fourth Ventricle 368
- Sections of Brainstem 369
- Forebrain 374
- Cerebrum 376
- Limbic System 382
- White Matter of Cerebrum 383
- Lateral Ventricle 386
- Third Ventricle 387
- Diencephalon 388
- Sections of Forebrain 389

Appendix 393

Index 395

JAYPEE BROTHERS

CHAPTER 4

ABDOMEN

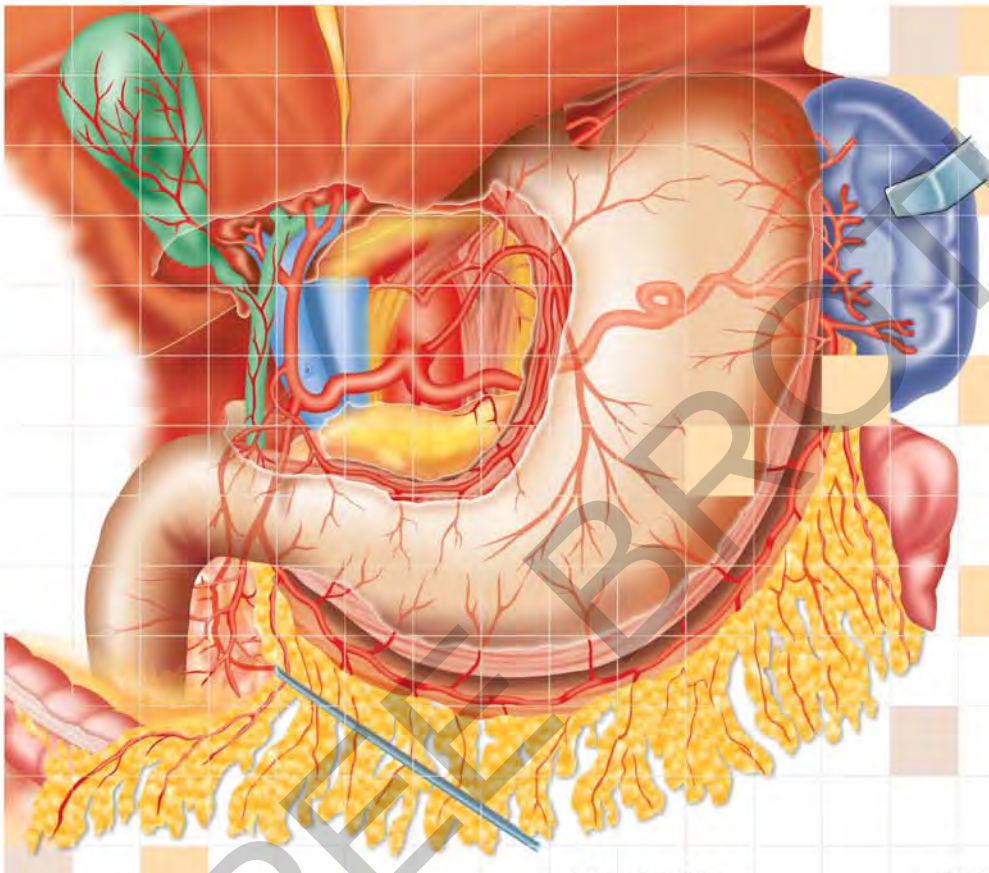

Introduction
Loin
Anterolateral Abdominal Wall
Inguinal Canal and Scrotum
Abdominopelvic Cavity
Diaphragm
Lesser Sac
Coeliac Trunk
Liver
Gallbladder
Stomach
Spleen
Jejunum and Ileum
Large Intestine
Duodenum and Pancreas
Kidney, Suprarenal and Blood Vessels
Autonomic Nerve Plexuses
Posterior Abdominal Wall

JAYPEE BROTHERS

INTRODUCTION

The abdomen is the lower, most extensive part of the trunk. It is divided into ***abdomen proper, pelvis and perineum.*** It is partly supported by bones. The lower thoracic cage protects the abdomen superiorly, the bony pelvis protects it inferiorly and lumbar vertebrae protect it posteriorly. The remaining anterolateral wall is formed by musculature. This helps in the expansion of the abdominal contents. The abdominal cavity is separated from the thoracic cavity by the dome shaped diaphragm. The abdominal cavity is continuous with the pelvic cavity at the inlet of the pelvis. The pelvic cavity is separated from the perineum by the pelvic diaphragm. The abdomen is filled with viscera. They are parts of the gastrointestinal tract, urinary system, genital system, endocrine gland suprarenal and lymphoid organ spleen, and their neurovascular bundle. As there are too many organs in the abdomen, to understand their position in the body, the abdomen is divided into regions by imaginary lines. Loin is the posterior aspect of the abdomen and is occupied by the postvertebral muscles.

SURFACE ANATOMY (Fig. 1)

Bony boundaries: Try to identify the bony boundaries on the living and on the skeleton. Superiorly feel the ***xiphisternum*** in the midline. Anterolaterally feel the ***costal margin*** (formed by costal cartilages of 7th rib to 10th rib), lower end of the costal margin is formed by 10th rib. Inferiorly feel the ***pubic symphysis*** in the midline**.** It is the secondary cartilaginous joint formed between the two pubic bones. Run your fingers along the ***pubic crest.*** It is a part of pubic bone and the ***pubic tubercle*** is the lateral end of crest. Laterally identify the ***anterior superior iliac spine,*** the most anterior projection of the iliac crest, and the ***iliac crest,*** the upper surface of the iliac bone **(Fig. 1).**

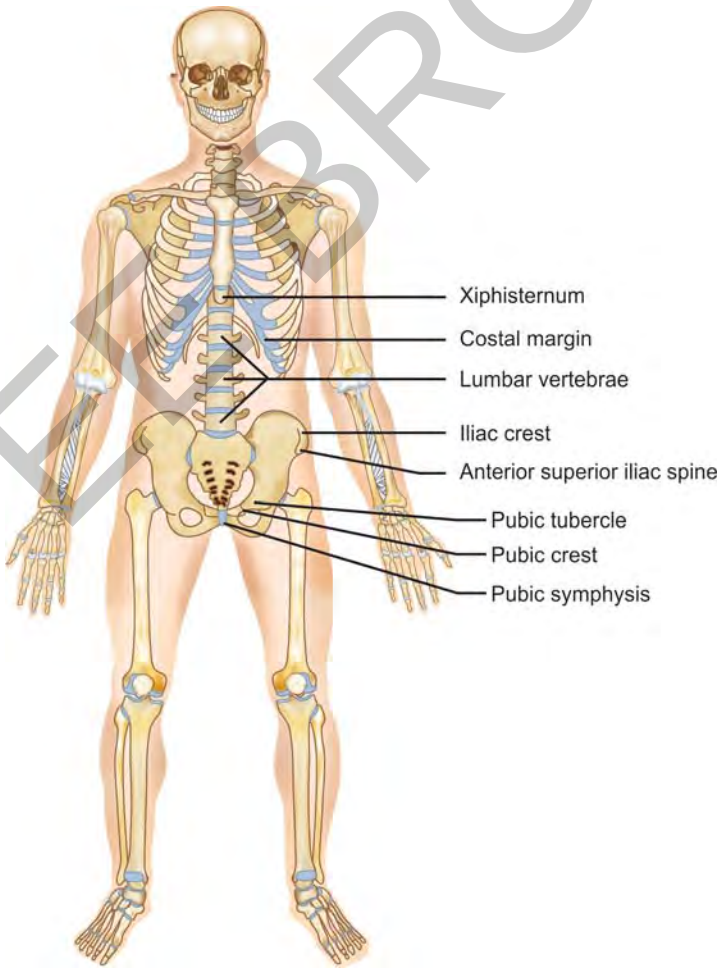

FIGURE 1 Surface anatomy

JAYPEE BROTHERS

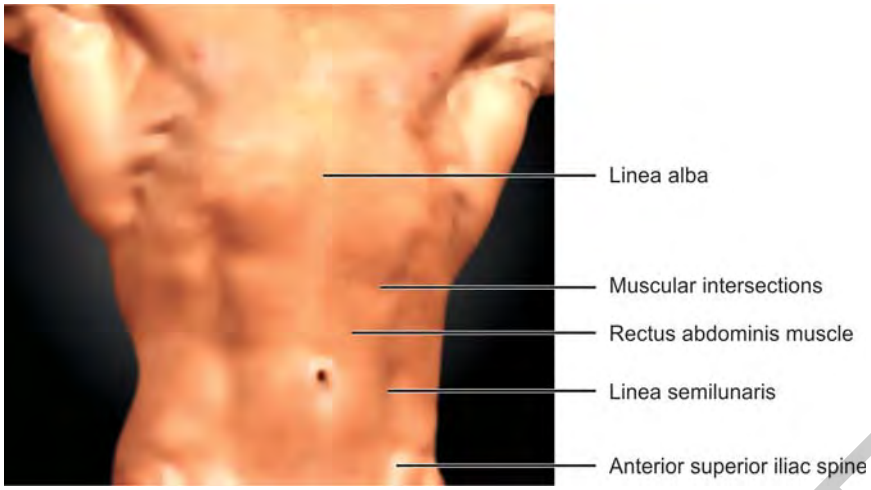

FIGURE 2 Surface anatomy—muscle elevations

Surface anatomy (Fig. 2): In a muscular person we can see a midline depression that extends from xiphisternum to pubic symphysis. This is due to a midline tendinous raphae called ***linea alba***. ***Linea semilunaris*** extends from 9th costal cartilage to the pubic tubercle. This is the depression to the side of the rectus abdominis muscle. ***Intersections*** of rectus abdominis muscle can also be visible as transverse lines.

REGIONS OF ABDOMEN (Fig. 3)

Draw the following lines on the cadaver:

Transpyloric plane: This is a horizontal line cutting across the tip of 9th costal cartilage. This will cut the first lumbar vertebra.

Subcostal plane: This line passes below the 10th rib. This would cut the upper border of third lumbar vertebra.

Transtubercular plane: It is a line connecting the two iliac tubercles. This would cut the lower border of L5.

Midinguinal or midclavicular line/vertical line: Draw this line from the middle of the clavicle to the midinguinal point (point midway between anterior superior iliac spine and pubic symphysis).

The above lines are used to divide the abdomen into nine regions.

Right and left hypochondriac regions lie under cover of the ribs.

Epigastric region lies below the xiphisternum.

Right and left lumbar regions lie below the hypochondriac regions.

Umbilical region is in the midline around the umbilicus.

Right and left inguinal regions lie in relation to iliac fossa.

Hypogastric region lies above the pubic symphysis.

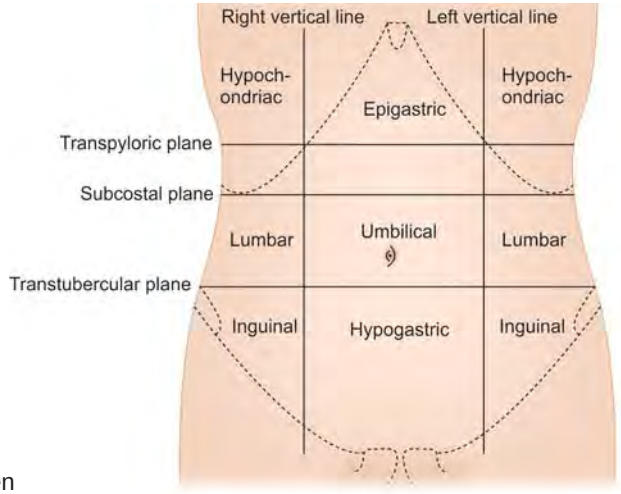

FIGURE 3 Regions of abdomen

JAYPEE BROTHERS

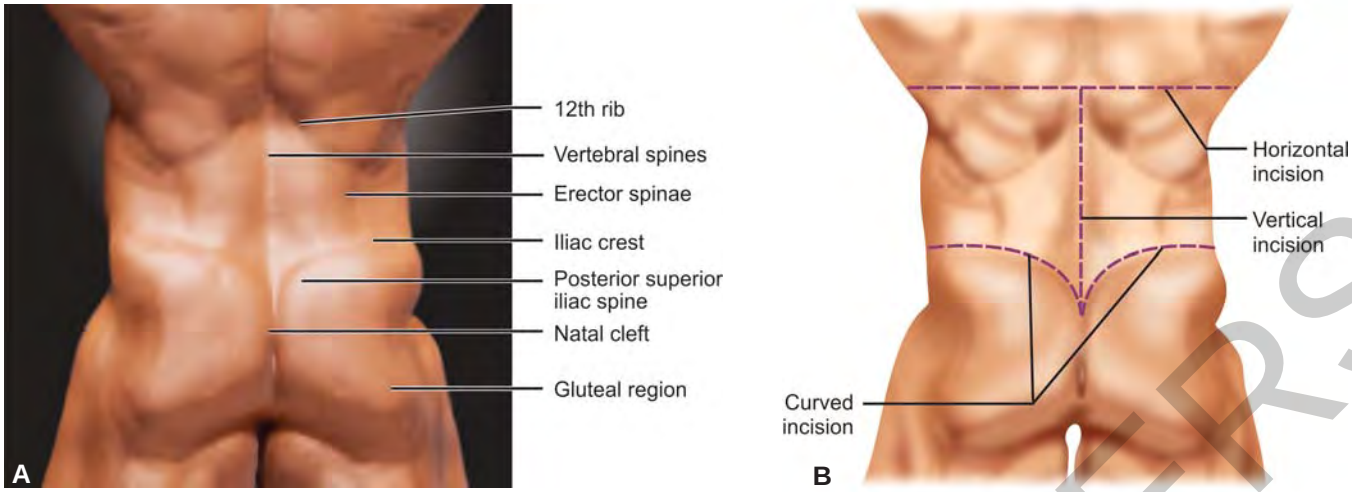

FIGURES 4A AND B (A) Surface anatomy—posterior aspects and (B) Skin incisions

LOIN

Loin is the area lateral to the lumbar vertebrae. It is occupied by three layers of muscle and the fascia separating them. The most superficial layer here is the latissimus dorsi, belonging to the upper limb. This gives a firm anchorage to the upper limb. Deep to this is the extensor muscle of the vertebral column—the erector spinae. The deepest layer is the quadratus lumborum, the lateral rotator of the lumbar region.

SURFACE ANATOMY (Fig. 4A)

Turn the body to a prone position and identify the following:

12th rib: Feel the tip of the 12th rib lateral to the erector spinae muscle.

Spines of vertebrae: Feel them from 12th thoracic to 2nd sacral in midline.

Iliac crest: Feel and trace it posteriorly.

Posterior superior iliac spine can be seen as a dimple on the posterior aspect **(Figs 4A and B)**.

Erector spinae: This is the postvertebral muscle and raises a vertical elevation.

Natal cleft: This is the depression between the two gluteal regions.

MUSCULATURE

Skin Incision (Fig. 4B)

Dissection: Make a horizontal incision at the level of 8th thoracic spine to the mid axillary line. Make a vertical incision in the midline from T8 spines to coccyx. Make a curved incision from the posterior superior iliac spine along the iliac crest to the mid axillary line. Reflect the skin laterally to the midaxillary line.

The posterior cutaneous nerves and posterior branches of the lateral cutaneous nerves supply this area. Both these branches are too tiny to be located.

JAYPEE BROTHERS

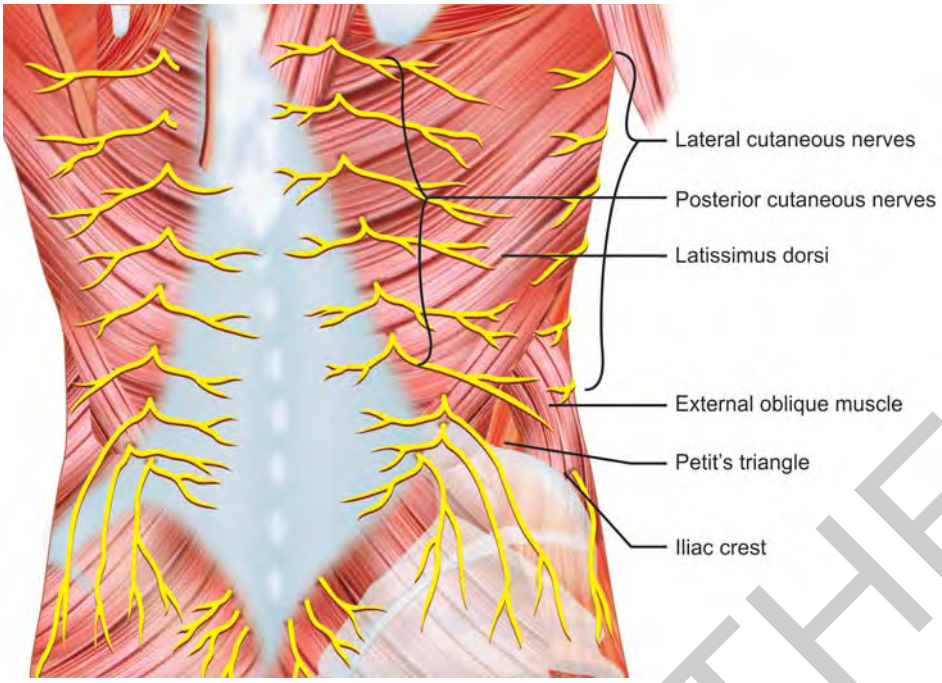

FIGURE 5 Loin—Latissimus dorsi

Latissimus dorsi (Fig. 5): Study its origin from the lower thoracic, lumbar and sacral spines, supraspinous ligaments and outer lip of posterior part of iliac crest.

Lumbar/petit's triangle: This is a muscular triangle in this region. Look for the posterior border of the external oblique muscle, this forms the anterior boundary. The inferior border is formed by the iliac crest. The medial border is formed by lateral border of latissimus dorsi.

Dissection: Cut the latissimus dorsi by the side of the spines and remove it. (It is already cut in the upper limb dissection).

JAYPEE BROTHERS

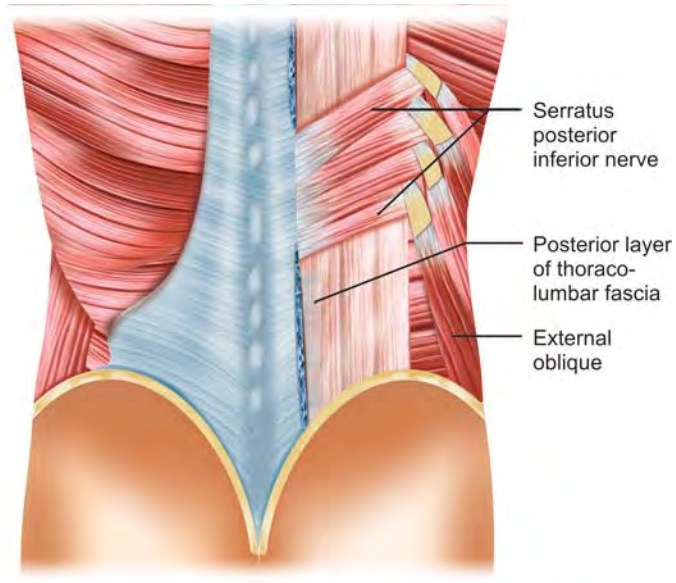

FIGURE 6 Loin—serratus posterior inferior

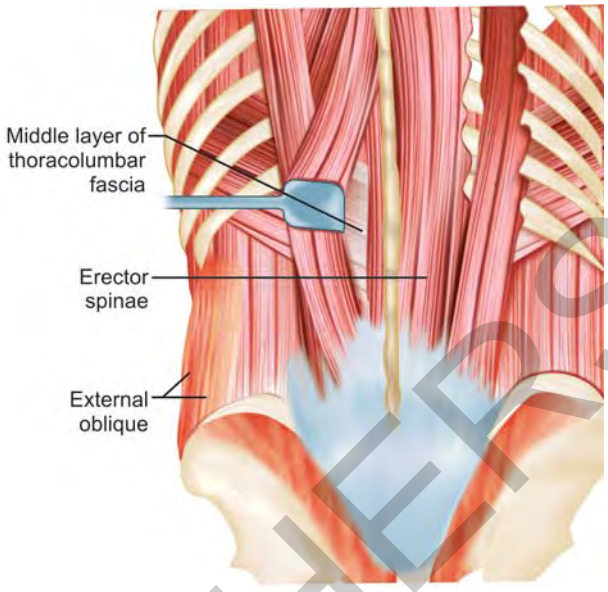

FIGURE 7 Erector spinae muscle

Serratus posterior inferior (Fig. 6): It has 4 slips. They extend from spines to the posterior angles of the lower 4 ribs. Identify them.

Dissection: Detach and remove the serratus posterior inferior.

Thoracolumbar fascia: It has three layers of fascia and envelops two muscles. The erector spinae is enclosed between the posterior and middle layer and the quadratus lumborum muscle is enclosed between the middle and anterior layer. All the three layers unite laterally and give attachment to the anterolateral musculature of the abdomen.

Posterior layer of thoracolumbar fascia: Identify this thick layer deep to the latissimus dorsi and serratus posterior inferior.

Dissection: Cut through the posterior layer of thoracolumbar fascia by a vertical incision parallel to the spines. clean the fascia and study the erector spinae muscle.

Erector spinae muscle (Fig. 7): It is the extensor muscle of the vertebral column. It extends from the sacrum to the occiput. The muscle extends between the spines and posterior angles of the ribs. It is divided into three layers horizontally and three layers superficial to deep. This muscle is best developed in the neck region. This will be studied in detail there.

Middle layer of thoracolumbar fascia: Pull the erector spinae muscle laterally and see the deeper, middle layer of thoracolumbar fascia.

The posterior and middle layer of thoracolumbar fascia unite laterally. This further unites with anterior layer of thoracolumbar facia which will be seen later.

Study the Morris parallelogram. This is the projection of the kidney posteriorly. This is very much essential to approach the kidney posteriorly for surgical procedures. Study the attachments of the fasciae and the muscles on the lumbar vertebrae.

JAYPEE BROTHERS

ANTEROLATERAL ABDOMINAL WALL

It is made up of three layers of muscles. The direction of fibres of these muscles is different. They reach the thoracolumbar fascia posteriorly, ribs superiorly, midline anteriorly and inguinal ligament inferiorly.

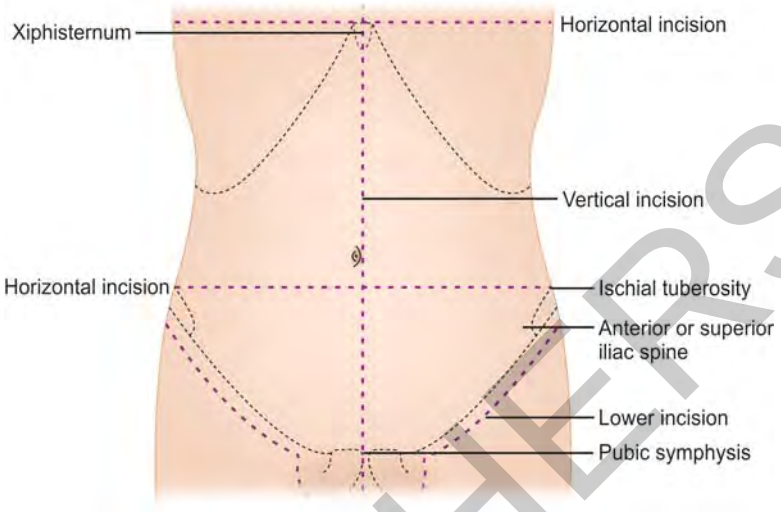

FIGURE 8 Incisions

Skin Incision (Fig. 8)

Dissection: Mak]e a vertical incision from xiphoid process to pubic symphysis. Make a lower incision from the pubic symphysis to the anterior superior iliac spine extend it upto pubic tubercle. Make a horizontal incision from one tubercle to the other. Horizontal incision above xiphisternum. Reflect and remove the skin totally in four flaps.

Superficial Fascia (Fig. 9)

It is made up of two layers—a superficial fatty layer called fascia of Camper and a deep membranous layer called, fascia of Scarpa. The amount of fat is variable in different individuals. The lower part of the abdomen is filled with more fat. Cutaneous veins are seen here.

Dissection: Cut through the superficial fatty layer and reflect it. As you reflect you will note on its undersurface there is a thick sheet of connective tissue. This is the membranous, Scarpa's fascia. Inferiorly it is attached to the deep fascia of thigh below the inguinal ligament.

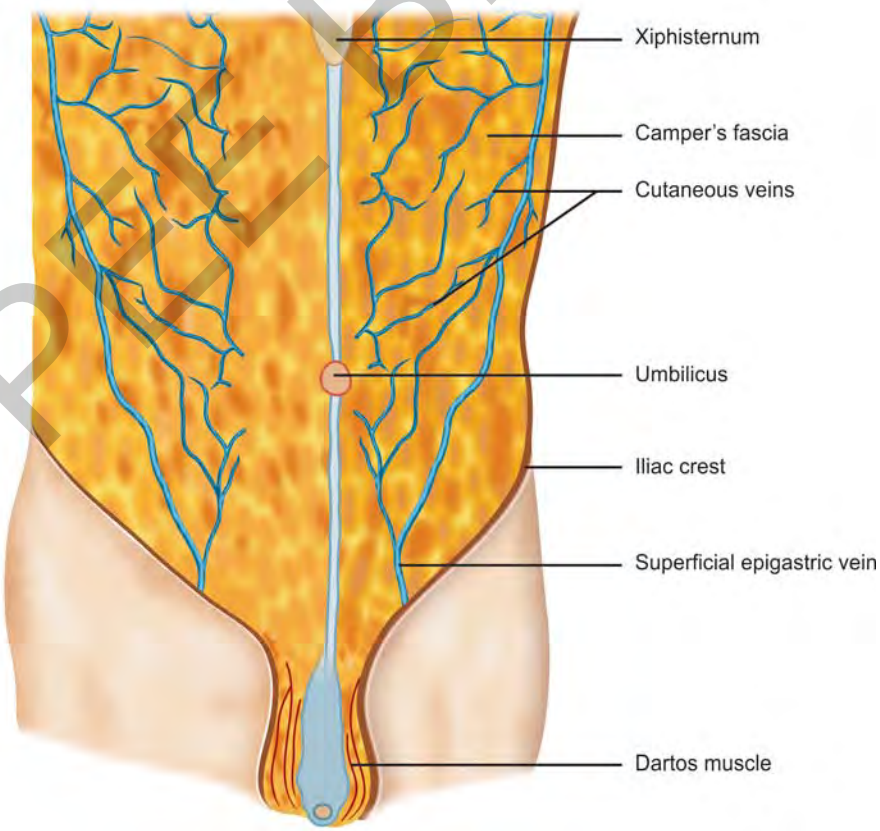

FIGURE 9 Superficial fascia–anterior abdominal wall and scrotum

JAYPEE BROTHERS

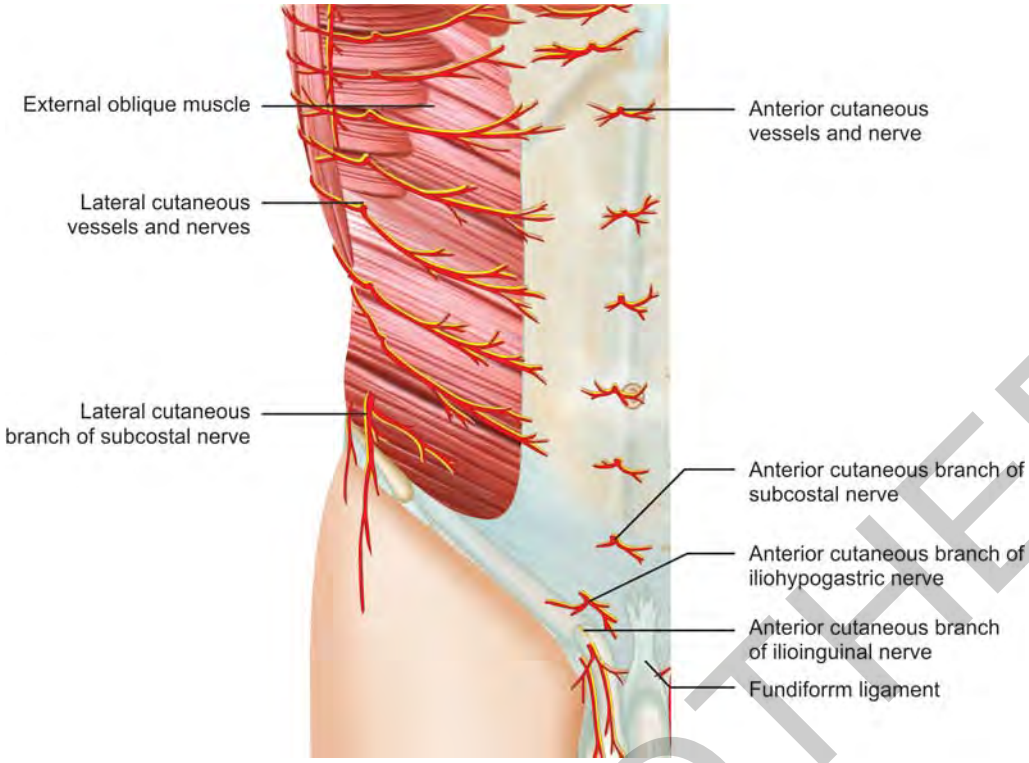

FIGURE 10 Anterior abdominal wall—cutaneous vessels and nerves

CUTANEOUS STRUCTURES (Fig. 10)

Anterior cutaneous vessels and nerves: These are small fine branches lateral to the midline. These are branches of intercostal vessels and nerves. The 12th thoracic branches reach the pubic region. Anterior cutaneous branches of iliohypogastric and ilioinguinal reach abdominal wall lateral to the linea semilunaris.

Lateral cutaneous branches of intercostals, subcostal and iliohypogastric reach the skin along the midaxillary line and supply the skin.

Fundiform ligament is the thick connective tissue sheet which connects the top of penis to the anterior abdominal wall.

Deep fascia: There is no deep fascia in the anterior abdominal wall. The function of the deep fascia is to hold the underlying structures tightly in position. In abdomen as most of the organs need to expand there cannot be a deep fascia.

JAYPEE BROTHERS

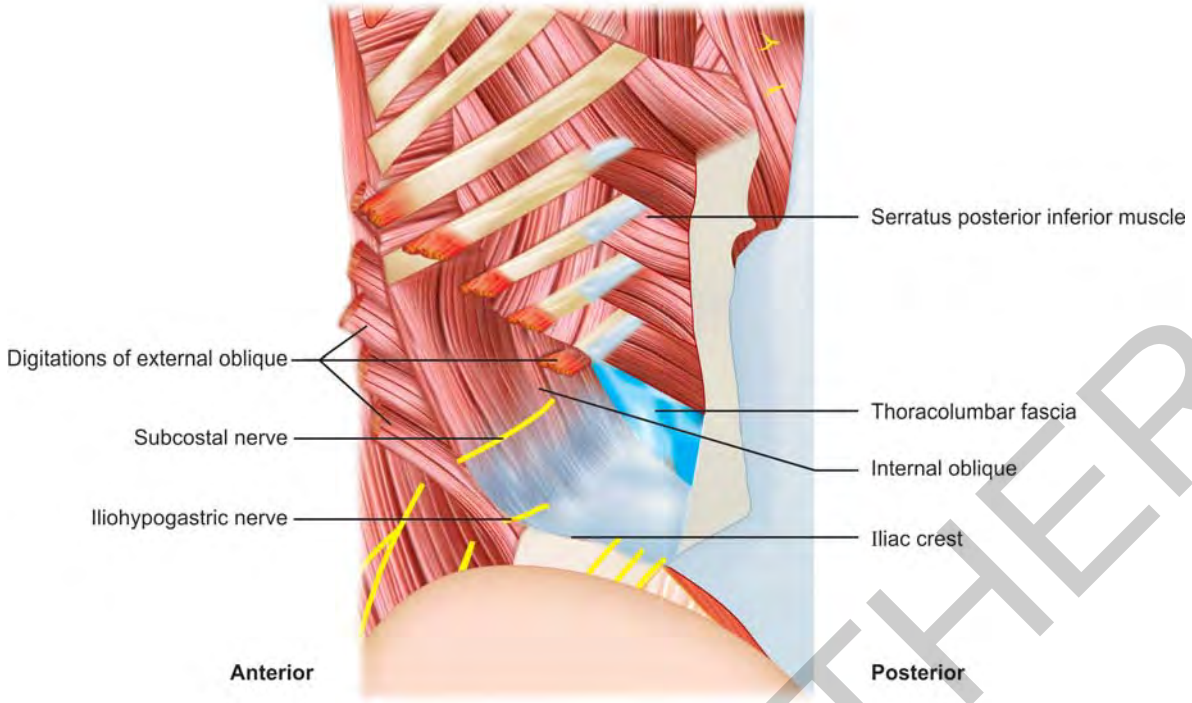

FIGURE 11 Anterior abdominal wall—reflection of external oblique muscle posterior side view

MUSCLES OF ABDOMEN

External oblique muscle: It is the most superficial of the muscle. It arises from the lower eight ribs near their anterior angles. The fibres run downward and forward to reach the linea semilunaris, where they become aponeurotic. Inferiorly the muscle is ligamentous and is called the inguinal ligament. It extends between the anterior superior iliac spine to the pubic tubercles.

Dissection (Fig. 11): Turn the body to sides and note that the fibres arising from the 11th and 12th rib run vertically downward to reach the anterior 2/3rd of the outerlip of the iliac crest. Detach the muscle from the ribs near its origin, and from the iliac crest. Cut across the muscle from the anterior superior iliac spine to the linea semilunaris and turn the muscle medially to the linea semilunaris.

Iliohypogastric nerve: Note this nerve while reflecting the external oblique. It pierces the internal oblique and passes through the external oblique to become cutaneous. Note the ***subcostal*** nerve piercing through the muscle.

Internal oblique (Fig. 12): It is the muscle seen deeper to the external oblique. Note the direction of the fibres. They run downwards and posteriorly. The muscle extends from lower borders of the lower six ribs from the thoracolumbar fascia, anterior 2/3rd of the middle lip of iliac crest and the lateral 2/3rd of the inguinal ligament.

Dissection: Turn the body to the side. Cut the internal oblique in front of the thoracolumbar fascia and detach the muscle from ribs and iliac crest. Cut the muscle across the anterior superior iliac spine to the linea semilunaris in line with the external oblique muscle. While reflecting the muscle note the neurovascular bundle which lies deep to it between internal oblique and transversus abdominis muscle.

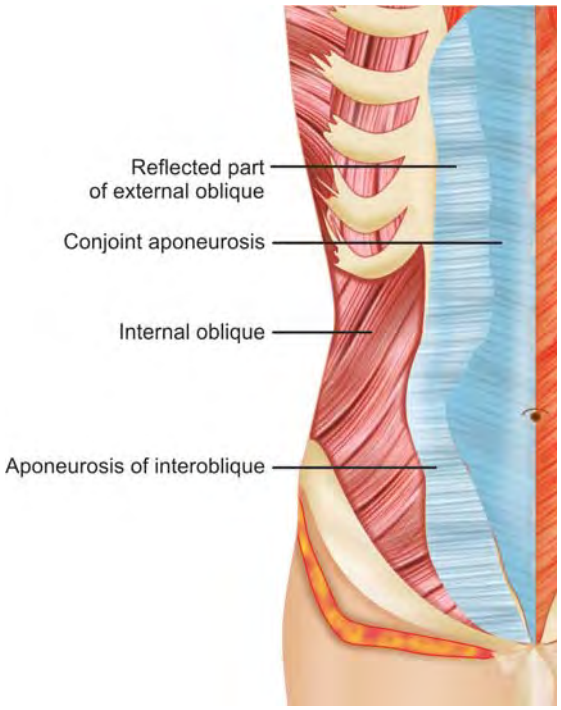

FIGURE 12 Anterior abdominal wall—Internal oblique muscle

JAYPEE BROTHERS

Transversus abdominis muscle (Fig. 13): Note the transversely running fibres of this muscle. It extends from the inner aspect of the lower six ribs, thoracolumbar fascia and anterior 2/3rd of the inner lip of the iliac crest and the lateral 1/3rd of the inguinal ligament. Trace these fibres medially to the linea semilunaris.

RECTUS SHEATH

Rectus abdominis muscle is present between the linea semilunaris and linea alba and is enclosed in the rectus sheath.

Linea semilunaris is the curved lateral margin of rectus sheath. Note all the three muscles, the external oblique, internal oblique and transversus abdominis have united here and the neurovascular bundle passes through it.

Linea alba is the midline white glistening structure extending from the xiphisternum to the pubic symphysis. This is a raphae of six muscles—the anterolateral muscles of both right and left side.

Anterior layer of rectus sheath is formed by aponeurosis of external oblique and anterior layer of internal oblique muscle.

Dissection: Cut vertically through the rectus sheath next to linea alba. Separate the rectus muscle from its anterior wall. Note that the rectus abdominis is adherent to the anterior wall by three intersections between xiphisternum and umbilicus. Cut through them.
Push your fingers to the laterally towards the lineal semilunaris and note that the internal oblique has split into two layers—one merging anteriorly with the external oblique muscle and the deeper layer going posteriorly and merging with the transversus abdominis.

Rectus abdominis muscle (Fig. 14): It arises by two slips from the pubic symphysis and pubic crest, ascends up, to be inserted into 5th, 6th and 7th costal cartilages along a horizontal line. Not that this muscle shows three tendinous intersections between the umbilicus and xiphisternum, denoting the segmental origin.

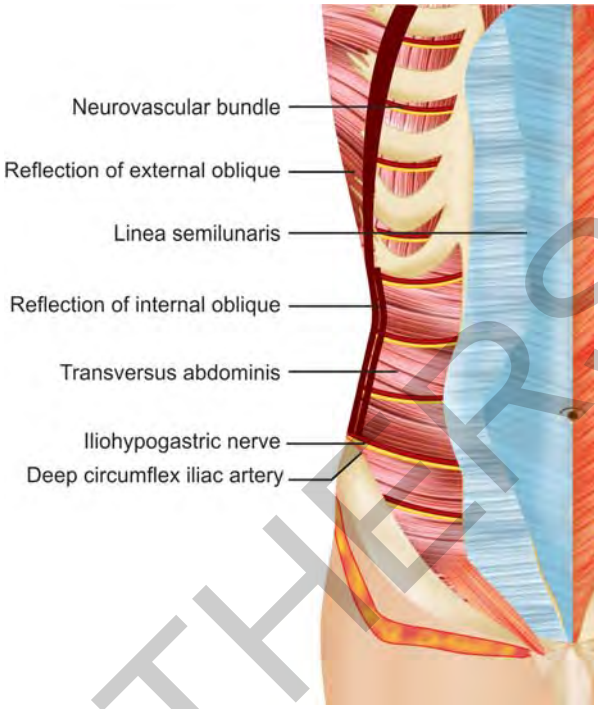

FIGURE 13 Anterior abdominal wall—transversus abdominis

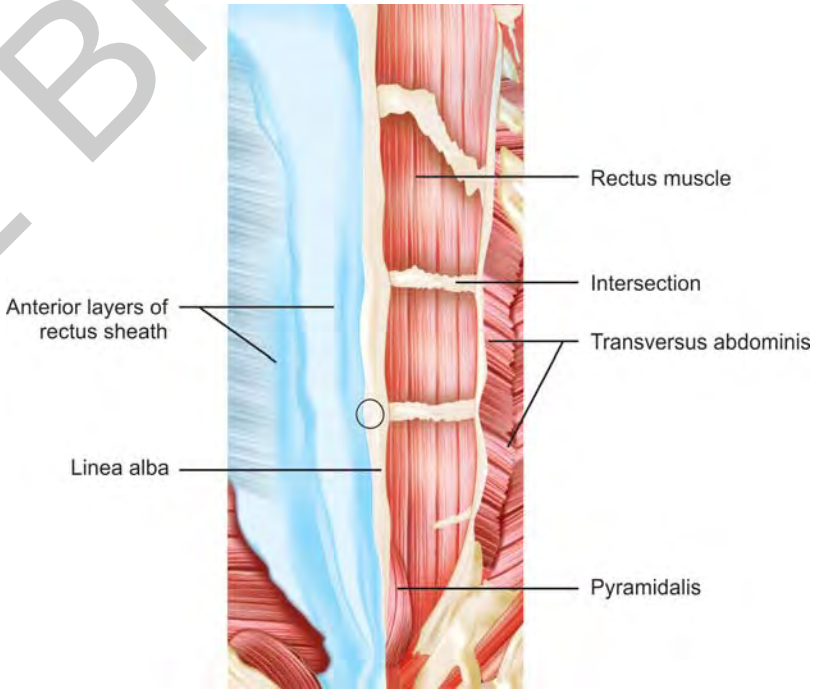

FIGURE 14 Anterior abdominal wall—rectus muscle

JAYPEE BROTHERS

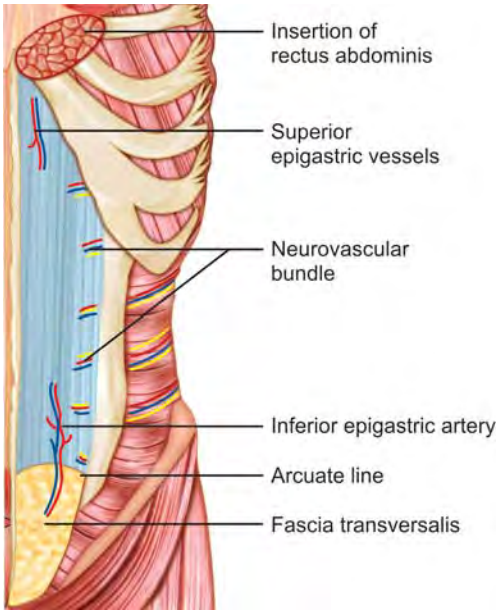

FIGURE 15 Anterior abdominal wall—rectus sheath

Pyramidalis: It is a small muscle present in the lower part, superficial to rectus muscle. It arises from the pubic crest and is inserted into the linea alba.

Dissection: Cut through the rectus muscle transversely near the umbilicus. Lift it superiorly and inferiorly and identify the structures deep to the muscle **(Fig. 15).**

Superior epigastric artery: This runs down from the space lateral to the xiphisternum. It is one of the terminal branches of the internal thoracic artery.

Inferior epigastric artery: This is branch of the external iliac and enters the rectus sheath from below.

Intercostals vessels and nerves: They enter the rectus sheath along the linea semilunaris.

Arcuate line: Note the sharp semilunar margin within the posterior wall between the umbilicus and pubic symphysis. At this level all the three muscles turn anterior to the rectus muscle thus leaving a sharp posterior margin.

Fascia transversalis: Note this thin fascia below the arcuate line. This is similar to the endothoracic fascia of thorax. It lines the inner aspect of the anterior abdominal wall.

INGUINAL CANAL AND SCROTUM

Inguinal region is the area where the anterior and posterior walls of the abdomen meet. The testis which develops anterior to the posterior abdominal wall on either side of the vertebral column migrates downwards and anteriorly to reach the ***scrotum*** located in front of the pubic bones, below the anterior abdominal wall. While doing so it passes through the anterior abdominal wall musculature and superficial fascia, thus getting covered by them. The passage through which the testis passes is called ***inguinal canal***. In the adult anatomy the male gonad, the ***testis*** and the ***epididymis*** lies in the scrotum. The ***ductus deference*** continues from the epididymis and passes through the inguinal canal with its neurovascular bundle. It is called ***spermatic cord***.

JAYPEE BROTHERS

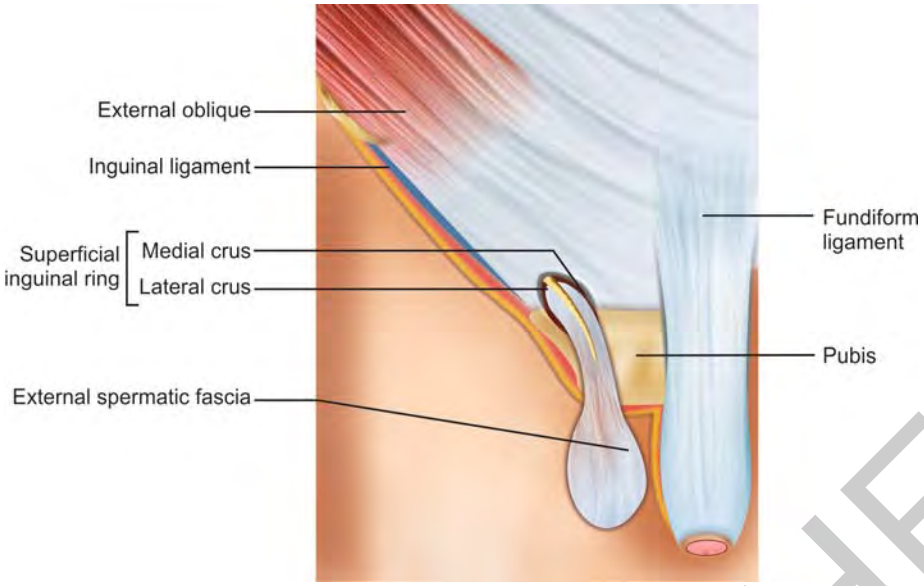

FIGURE 16 Inguinal canal and scrotum—external oblique muscle

SCROTUM

Dissection: Feel the scrotum. Put a midline incision on each half of the scrotal sac. Reflect the skin to either side. The skin here is very thin and should be reflected carefully. Deep to the skin the fatty layer of the superficial fascia is replaced here by dartos muscle. The muscle fibres can be identified because of the coloration. Clean and identify the scrotal vessels and nerves, the cutaneous nerves of this region.

Dartos muscle: It is the subcutaneous muscle present within the superficial fascia. It is attached to the skin and causes the wrinkles of the scrotal skin. It helps in controlling the temperature for the testis.

Scrotal vessels and nerves: The two parallel vessels and nerves can be easily identified on the anterior aspect within the superficial fascia. These are branches of the pudendal nerve and vessels.

Membranous layer of superficial fascia: lies deep to the dartos muscle and is a thick fascia.

External oblique (Fig. 16): *Locate the lower unreflected part of the external oblique muscle. Push your fingers downward deep to the external oblique muscle toward the superficial inguinal ring and feel the thick sheet covering your fingers. This is the* ***external spermatic fascia****. It is a continuation of the external oblique aponeurosis into the scrotum.*

Superficial inguinal ring: It is the thick margin within the external oblique aponeurosis from where the external spermatic fascia continues. It shows two thick margins—the lateral and medial walls called crura. The lateral crus is attached to the pubic tubercle and the medial crus to the pubic symphysis.

Intercrural fibres are aponeurotic fibres crossing across the superficial inguinal ring, can be seen clearly against light.

JAYPEE BROTHERS

HUMAN ANATOMY
A Dissection Manual

To expose the wonderful composition of the human body is not easy. The seed of this book was brewing in the author's mind for many years.

This book navigates through the human body by dissection. Every single dissection is explained in a picture with only the necessary details.

This book is aimed at imparting information to the extent that the student should get a thorough knowledge of the accurate location of the structures in the body. The book is primarily for undergraduate students. A quick run, through the diagrams, should give a postgraduate a revision of human body.

Sujatha Kiran PhD is born in Chennai on 3rd December 1946 to a famous Telugu music director Sri Pendyala Nageswara Rao. She did her MSc and PhD from Madras Medical College, Chennai. She has put in more than 40 years of service in various medical colleges, TNMC Bombay, GMC Surat, Muhimbili Medical Centre, Dar-es-Salaam (Tanzania) SRMCRI Chennai and KIMS Narketpally and presently at MNRMC Sangareddy, Andhra Pradesh.

She is a life member of Anatomical Society of India and its Tamil Nadu and Andhra Pradesh Chapters and also a member of American Association of Anatomists. She organized state level conferences at SRMCRI Chennai, KIMS Narketpally and MNRMC Sangareddy. She was President (1991-1992) and Vice President (1989 and 1990) for the Tamil Nadu Chapter of ASI. She is presently holding the post of President of Andhra Pradesh Society of Anatomy.

She received Dr PC Bansal Memorial Gold Medal for the best paper on Histochemistry/Histology in 1996, Dr HJ Mehta Memorial Gold Medal for the best paper published in JASI, Dr Liza Chaco Memorial Award for best paper on Neuroanatomy, Dr Motilal Pan Memorial Award for best research paper in Embryology and Dr PC Bansal Memorial Gold Medal for best paper in Histochemistry/Histology in 2006 for the paper titled "Histogenesis of Neurons in Human Sympathetic Ganglia: A Quantitative Study" published in Vol 53(2) ASI Journal in the year 2004.

She has delivered the prestigious Dr Sukhbir Prasad Jain Oration in 54th National Conference of ASI Cochin, Kerala on "Development of Sympathetic Chain in Humans" in the year 2006 and "Use of ICT in Anatomy and Physiology Teaching Production and Practices" in the Seminar on "Information and Communication Technology in Medical Education" organized by MNR Medical College, Sangareddy as a part of MCI Platinum Jubilee Celebrations.

Presently, she holds the post of HOD of Anatomy and Academic Vice Principal at MNR Medical College, Sangareddy, Andhra Pradesh, India.

Available at all medical book stores
or buy directly from Jaypee Brothers through online shopping at www.jaypeebrothers.com

or call + 91-11-32558559

JAYPEE BROTHERS
Medical Publishers (P) Ltd.
www.jaypeebrothers.com

ISBN 978-93-5025-015-0
9 789350 250150