Forensic Radiology Made Easy®



With Photo CD-ROM

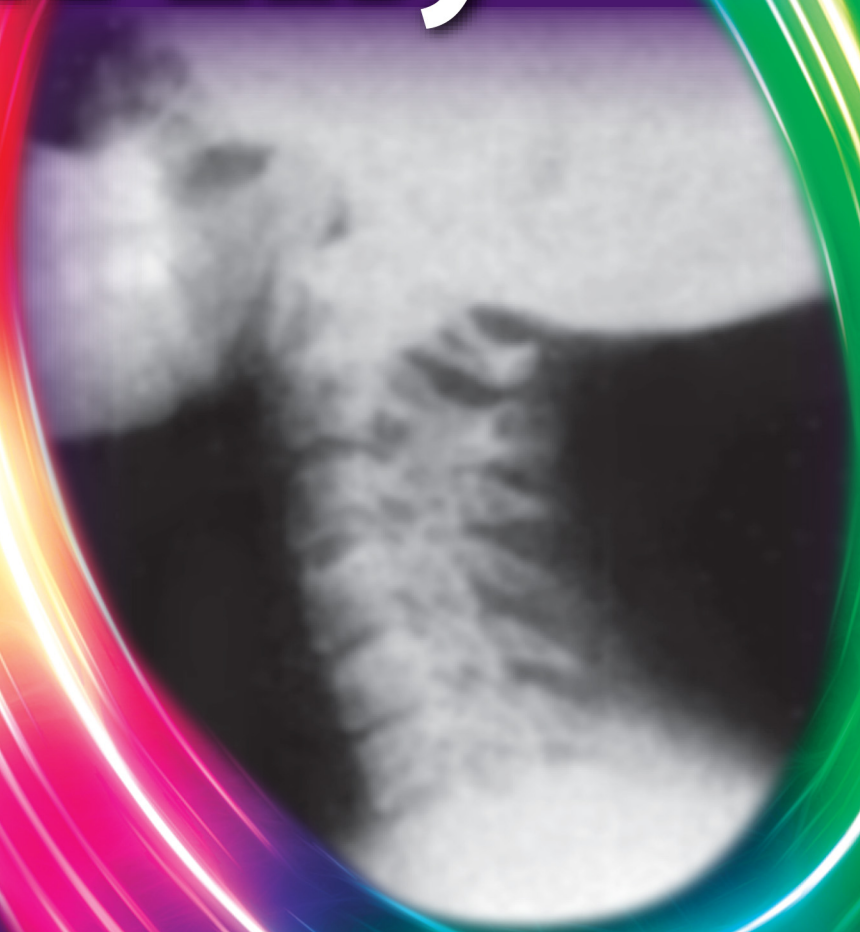

D Govindiah

JAYPEE

Contents

SECTION 1: MEDICOLEGAL RADIOLOGICAL AGE DETERMINATION

1. Skeletal Anatomy **1**

- The Skeleton 3
- The Skull 7
  - Cranial Vault 7
  - Eruption of temporary teeth 15
  - Eruption of permanent teeth 15
- The Vertebral Column 16
  - Intervertebral disk 16
  - Sacrum and coccyx 18
  - Sternum 19
  - Ribs 22
  - Costal Cartilages 22
  - Clavicles 22
  - Scapula 23
  - Humerus 24
  - Elbow joint 26
  - Radius 27
  - Ulna 27
- The Wrist Joint and the Hand 27
  - Wrist joint 27
  - Metacarpal bones 28
  - Phalanges of hand and fingers 29
  - Pelvis 29

– Hip bones 29
– Hip joint 31
– Femur 31
– Knee joint 33
– Patella 33
– Tibia 34
– Fibula 35
– Ankle and foot 35
– Ankle joint 36
– Metatarsal bones 36
• Phalanges 37

2. Lower Jaw for Development of the Third Molar Tooth 39

3. Shoulder Joint 47
• Collar Bone and Shoulder Joint 47
– Collar bone 47
– Shoulder joint 48
• Scapula 48
– Primary ossification center for body of scapula 48
– Secondary ossification centers 48

4. Elbow Joint 57
• Humerus 57
– Primary ossification center 57
– Secondary ossification center at distal end 57
• Radius 58
– Primary ossification center 58
– Secondary ossification centers at distal end 58

- Ulna 58
  - Primary ossification center 58
  - Secondary ossification centers in proximal end 59
  - Secondary ossification centers at distal end 59

5. Wrist Joint and Hand 70
- Distal Ends of Radius and Ulna 70
  - Secondary ossification centers 70
- Carpal Bones 71
  - Primary ossification centers 71
- Metacarpal Bones 71
  - Primary center 71
  - Secondary center 71
- Phalanges 71
  - Primary center 71
  - Secondary center 72

6. Hip Joint and Pelvis 86
- Pelvis/Hip Joints 86
  - Primary ossification center 86
  - Secondary ossification center 86
- Proximinal end of femur (secondary center) 87

7. Knee Joint 94
- Distal End of Femur 94
  - Primary center 94
  - Secondary center 94

8. Ankle Joint and Foot 97
- Ankle Joint 97
  - Secondary center 97

- Foot Bones 98
  - Tarsal bones 98
  - Metatarsal bones 100
  - Phalanges 100

9. Skull Vault and Suture Closure 101
- Vault of the Skull and Closure of the Sutures 101

10. Mixed Dentition 104

11. Collar Bone 105

12. Hyoid Bone 106

13. Sternum 112

SECTION 2: TRAUMATIC BONE FRACTURE AND DISLOCATION INJURIES IN MEDICOLEGAL CASES

14. Traumatic Bone Fracture and Dislocation Injuries in Medicolegal Cases 117
- Injuries of the Facial Skeleton 119
  - Fracture of the nasal bones 119
  - Fractures of the maxillary bones 119
  - Fractures of the mandible 119
- Injuries to the Front of the Neck 119
  - Hyoid bone fractures 119
- Laryngeal Skeleton Fractures 121
- Fracture of Clavicle 121
- Common Traumatic Injuries Around the Shoulder Joint 123
  - Dislocation or subluxation of sternoclavicular joint 123
  - Dislocation of acromioclavicular joint 124
- Trauma to the shoulder joint 124
- Dislocation of the shoulder joint 124

– The anterior dislocation of the shoulder joint 124
– Posterior dislocation of the shoulder joint 125
• Fracture of Neck of the Humerus 125
• Fractures of the Shaft of the Humerus 125
• Injuries of the Elbow 125
– Dislocation of the elbow 127
– Fractures of the distal end of the humerus 127
• Dislocation and Subluxation of the Head of Radius 128
• Fractures of the Proximal 128
• End of the Radius 128
• Fracture of the Proximal End of Ulna 128
• Fracture of the Middle Third of Shaft of Ulna 129
• Fracture Dislocations of the Distal End of the radius 130
• Dislocation and Fractures of Carpal Bones 130
• Fracture Dislocation of Metacarpal Bones of the Hand 132
– Fracture dislocation at the base of first metacarpal bone 132
– Fractures of the shafts of metacarpal bones 132
– Fractures of phalanges 132
– Dislocation of metacarpophalangeal Joints and interphalangeal joints 133
• Dislocations and Fractures of Cervical Vertebrae 133
• Fractures of the Spinous Processes, Transverse Processes, Laminae and Pedicles 135
• Dislocation and Fractures of Thoracic and Lumbar Vertebrae 135

- Thorax and Abdomen 135
- Images of Soft Tissue Shadows Showing Abnormal Findings 138
- Plain X-ray of Abdomen 138
  - Bony pelvis 138
  - Lower-thoracic vertebrae and lower ribs 138
  - Lumbar vertebra 139
  - Other parts of the pelvis 139
- Common Traumatic Injuries of the Bony Pelvis and its Joints 140
  - The pubic ramii 141
  - The symphysis pubis 141
  - The sacroiliac joints 141
- Dislocation of the Hip Joint 141
  - Posterior dislocation 141
  - Anterior dislocation 142
  - Central dislocation 142
- Fracture of the Neck of Femur 142
- Fractures of the Shaft of the Femur 143
- Common Traumatic Injuries of the Knee 143
  - Fracture of the patella 144
  - Fractures of distal end of femur and the proximal end of tibia 144
  - Fracture of the tibia and fibula 145
- Common Traumatic Injuries about the Ankle Joint 145
  - Abduction Fractures 145
  - Adduction Fractures 147
  - External Rotation Fractures 147
- Fractures of the Calcaneum 148

- Fractures of the Talus 148
- Injuries of the Metatarsals and Phalanges of the Foot 148

SECTION 3: OTHER CASES OF MEDICOLEGAL IMPORTANCE

15. Other Cases of Medicolegal Importance 153
- – Findings in a typical case of TB lungs 155
- – X-Ray Examination 155
- Choking 155

SECTION 4: EXERCISES FOR AGE ESTIMATION AND RADIOLOGICAL EXAMINATIONS FOR SEX DIFFERENCES AND PRIMARY OSSIFICATION CENTERS OF IUL

16. Exercises for Age Estimation and Radiological Examinations for Sex Differences and Primary Ossification Centers of IUL 159
- Exercises for Age Estimation 159
  - – Line drawing from x-ray film 159
- Radiological Examination for Sex Differences in Skull and Pelvis of Male and Female (Adult) 170
- Radiological Examination for Primary Ossification Centers of Intrauterine Life (IUL) 174
  - – Primary ossification centers appear in skull in 7th or 8th prenatal week 177

Section 5: Radiographic Positioning, Identification and Radiology in Bone Injuries

17. Radiographic Positioning, Identification and Radiology in Bone Injuries **183**
- Radiographic Positioning 183
  - Important considerations 184
  - Positioning of the part 184
  - Skull: Anteroposterior (AP)–Supine 186
  - Chest 186
  - Knee 186
- Identification from Radiological Examinations 187
- Radiology in Bony Injuries 193
  - Child abuse 195
  - Battering of wife (spousal abuse) 200
  - Abuse on old and elderly persons 201

Section 6: Radiology and Firearm Injuries

18. Firearm Injuries **203**
- Foreign bodies seen in X-ray 214
- Other Foreign Bodies Visualized in Radiographs 214

Index *215*

Chapter 3

Shoulder Joint

COLLAR BONE AND SHOULDER JOINT (FIG. 3.1)

COLLAR BONE

Ossification centers {appearance (A) and fusion (F)}:

1. Primary center
   Shaft: 4-5 weeks (A) IUL
2. Secondary center
   Inner end: 15-19 years (A), 20-22 years (F)

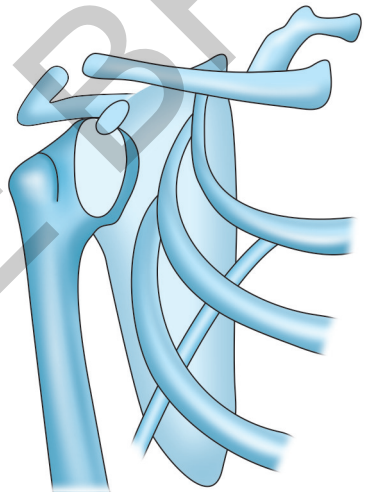

Figure 3.1: Right collar bone and right shoulder joint

JAYPEE BROTHERS

SHOULDER JOINT

1. **Primary ossification center:** For shaft of humerus, 8 weeks IUL.
2. **Secondary ossification centers:** For proximal end of humerus
   - Head: 1 year (A)
   - Greater tuberosity: 3 years (A)
   - Lesser tuberosity: 5 years (A)
     Head of humerus and tuberosities 5-6 years (F) and form a conjoint epiphysis, and the conjoint epiphysis unites with the shaft at 18-19 years (F).

SCAPULA

PRIMARY OSSIFICATION CENTER FOR BODY OF SCAPULA

8 weeks IUL

SECONDARY OSSIFICATION CENTERS

- Glenoid cavity : 14-15 years (A), 17 years (F).
- Acromion process : 14-15 years (A), 17-18 years (F).
- Coracoid process (tip) : 10-11 years (A), 16 years (F)

Radiograph of left shoulder joint AP view shows (Figs 3.2 and 3.3)

- Epiphysis of proximal end of humerus: Fused and shows epiphyseal line.
- Epiphysis of acromion process: Fused.

Opinion: As per the radiological examination of left shoulder.

The age of the individual is about 21 years.

JAYPEE BROTHERS

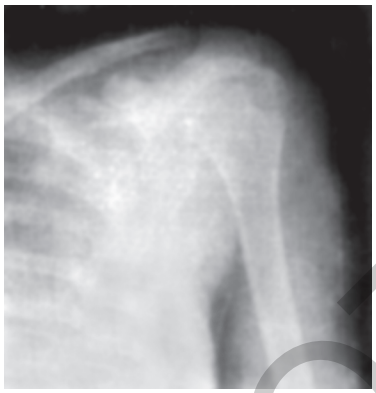

Figure 3.2: Anteroposterior view of left shoulder joint (showing scapula)

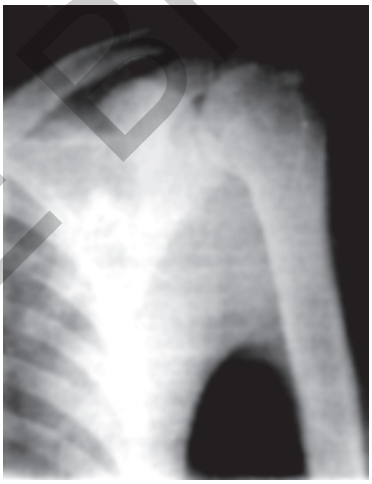

Figure 3.3A: X-ray of left shoulder joint AP view

JAYPEE BROTHERS

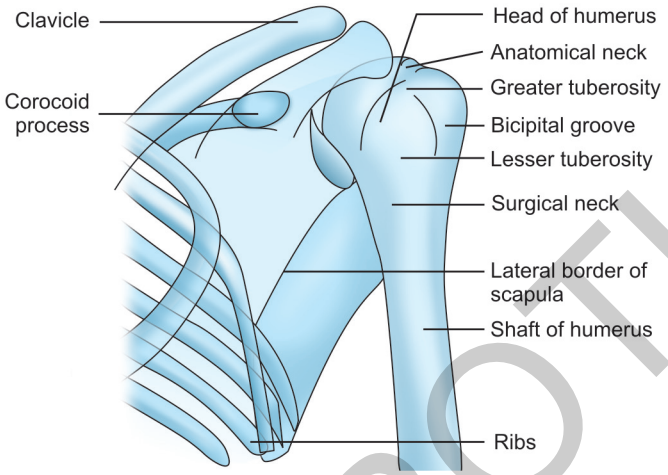

Figure 3.3B: Outline of radiograph anteroposterior view of left shoulder

OTHER IMPORTANT POINTS

- The process of fusion in the proximal end of humerus is nearly complete but the epiphyseal line can be distinguished.
- Epiphyseal line does not indicate recent union.
- Bicipital groove is the intertubercular groove present between the greater and lesser tubercle of humerus.
- Acromion process is seen forming a sort of hood above the shoulder joint.
- The proximal end of the humerus is cartilaginous at birth. In childhood, three separate secondary centers are developed in the cartilaginous end.
- When all the epiphyses of bones of the skeleton are united. It is possible to estimate the age of the individual as above 25 years.

JAYPEE BROTHERS

Radiograph of right shoulder shows (Figs 3.4A and B)

- Epiphysis of head of humerus and greater tuberosity: Fused.
- Epiphysis of proximal end of humerus not fused with the shaft.

Opinion: As per the radiological examination, the age of the individual is above 6 years and below 18 years.

OTHER IMPORTANT POINTS

- Epiphyseal plate is the binding cartilage between the epiphysis and the diaphysis, which is radiolucent in radiograph.
- Secondary ossification centers of head, greater tuberosity and lesser tuberosity fuse together and form a single epiphysis, which later fuses to the diaphysis.

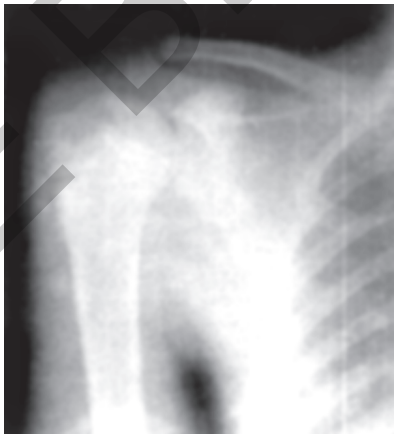

Figure 3.4A: X-ray of right shoulder—AP view

JAYPEE BROTHERS

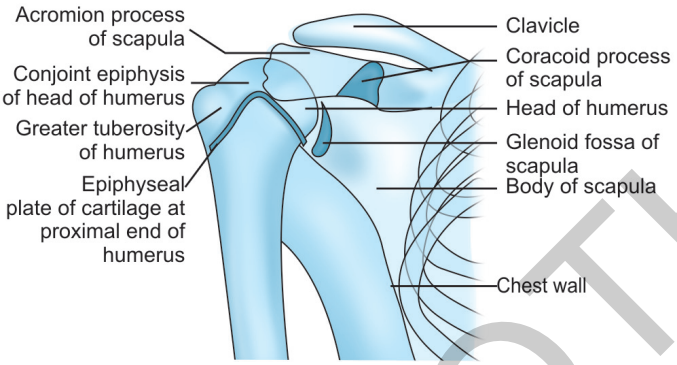

Figure 3.4B: Outline of AP radiograph of right shoulder

Radiograph of right shoulder AP view shows: Epiphysis of acromion process appeared and not fused (Figs 3.5A and B).

Opinion: As per the radiological examination, the age is above 14 years and below 18 years.

OTHER IMPORTANT POINT

Conjoint epiphysis of head of humerus is formed by union of epiphysis of head and greater tuberosity at the age of 6 years.

AP radiograph of left shoulder shows: Conjoint epiphysis of proximal and of humerus not formed. Epiphyses of acromion process not appeared (Figs 3.6A and B).

Opinion: The age of the individual as per the radiological examination is above 5 years and below 6 years (epiphysis of head of humerus and epiphysis of greater tuberosity not united).

JAYPEE BROTHERS

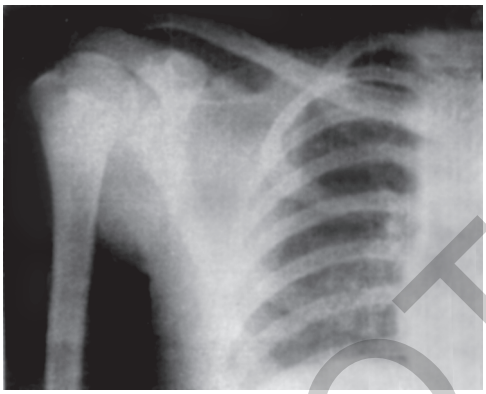

Figure 3.5A: X-ray of right shoulder—AP view

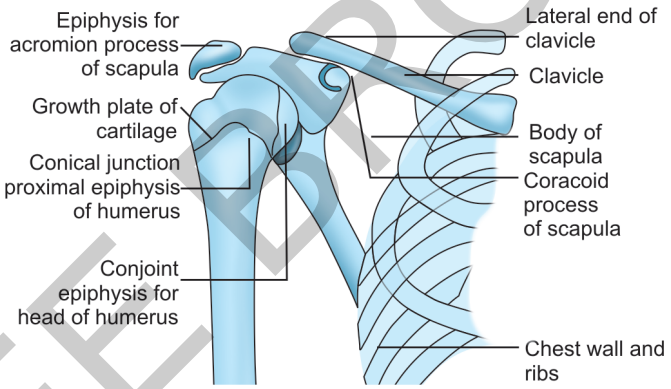

Figure 3.5B: Outline of AP view radiograph of right shoulder

OTHER IMPORTANT POINTS

- The proximal end of humerus shows "no union" of epiphysis with the shaft.
- Epiphysis of head of humerus and greater tuberosity unites at about 6 years and forms conjoint epiphysis.

JAYPEE BROTHERS

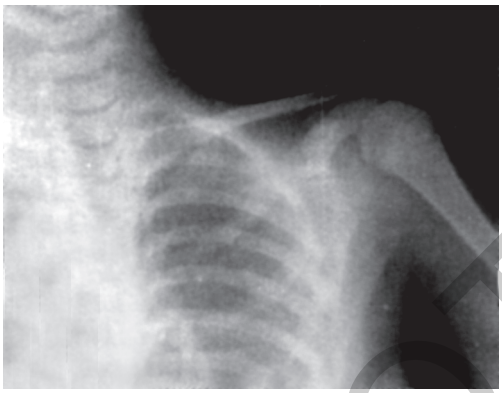

Figure 3.6A: X-ray of left shoulder—AP view

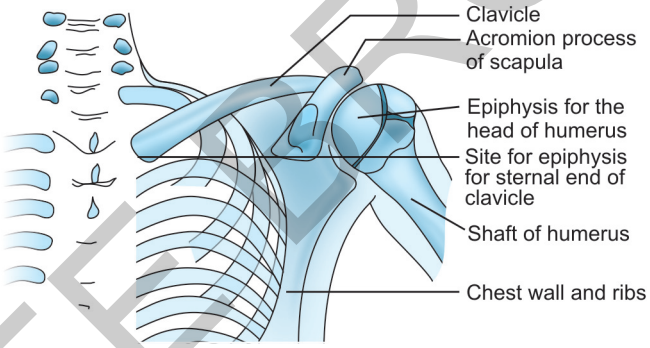

Figure 3.6B: Outline of AP view radiograph of left shoulder

AP radiograph of left shoulder shows: Epiphysis of head of humerus; greater tuberosity and lesser tuberosity not united to form conjoint epiphysis of proximal end of humerus. Epiphyses of proximal end are not united to the shaft (Figs 3.7A and B).

JAYPEE BROTHERS



Figure 3.7A: X-ray of left shoulder—AP view

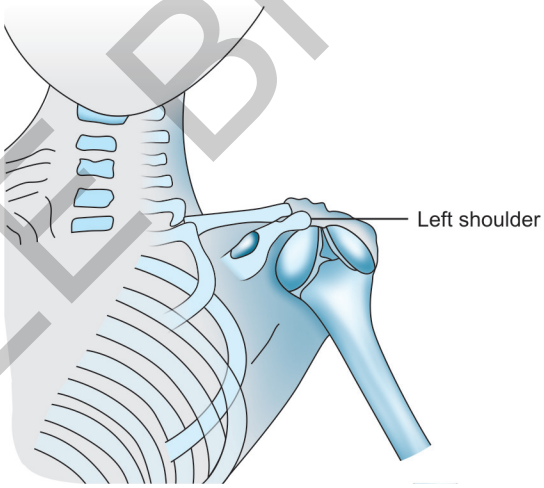

Figure 3.7B: Outline of AP radiograph of left shoulder

JAYPEE BROTHERS

Opinion: The age of individual as per the radiological examination is above 3 years and below 5 years (epiphysis of greater tuberosity appeared and lesser tuberosity did not appear).

OTHER IMPORTANT POINTS

- Primary ossification centers appear in eight week IUL.
- At the proximal end of humerus ossification centers of head; greater tuberosity and lesser tuberosity join at about sixth year and form a large epiphysis.

JAYPEE BROTHERS

Forensic Radiology
Made Easy®

Salient Features

- A thoroughly revised and updated text
- Focuses on the roles of radiology in dealing with various forensic situations, especially in the determination of ages of individuals
- Provides a number of medicolegal cases and their thorough examinations to solve numerous legal problems in the court of law
- Adds entirely new chapters, viz. Exercises for Age Estimation, Radiographic Positioning, and Radiology and Firearm Injuries
- Includes many new illustrations and drawings to have a clear and easy understanding of the concepts to the readers
- Serves as a useful tool to the Practicing Doctors, Law-forming and Law-enforcing Authorities, Undergraduate and Postgraduate Medical Students with special interest in Forensic Medicine and Toxicology and Radiology.



D Govindiah is a forensic specialist and medicologal expert. He is a retired Professor and Head, Department of Forensic Medicine, Osmania Medical College, Hyderabad (AP), India. He has an experience of over 25 years in the field of forensic medicine. He held a number of high posts during his active life of service in the field. He is a specialist in Torture Medicine and a counselor for Torture Survivors. He is also expert in the field of human rights. He is an Ex-Army Officer, EC/AMC and Ex-Director, Department of Forensic Science (AP). He is also an Ex-Selection Committee Member in UPSC for forensic experts. He is also the Ex-Chairman for approval of PG courses in Venkateswara University Medical College, Hyderabad (AP), and the Ex-Examiner of National Board of Forensic Medicine and various universities of India.

He has deep and intensive knowledge and experience in the Forensic Medicine and has ability to recognize and interpret correctly any forensic cases.

Available at all medical book stores
or buy directly from Jaypee Brothers through online shopping at www.jaypeebrothers.com

or call + 91-11-32558559

JAYPEE BROTHERS
Medical Publishers (P) Ltd.
www.jaypeebrothers.com

ISBN 978-93-5025-036-5