Dissection

With Photo CD-ROM

Manual, Living and Cross-sectional Anatomy

Sibani Mazumdar
Ardhendu Mazumdar

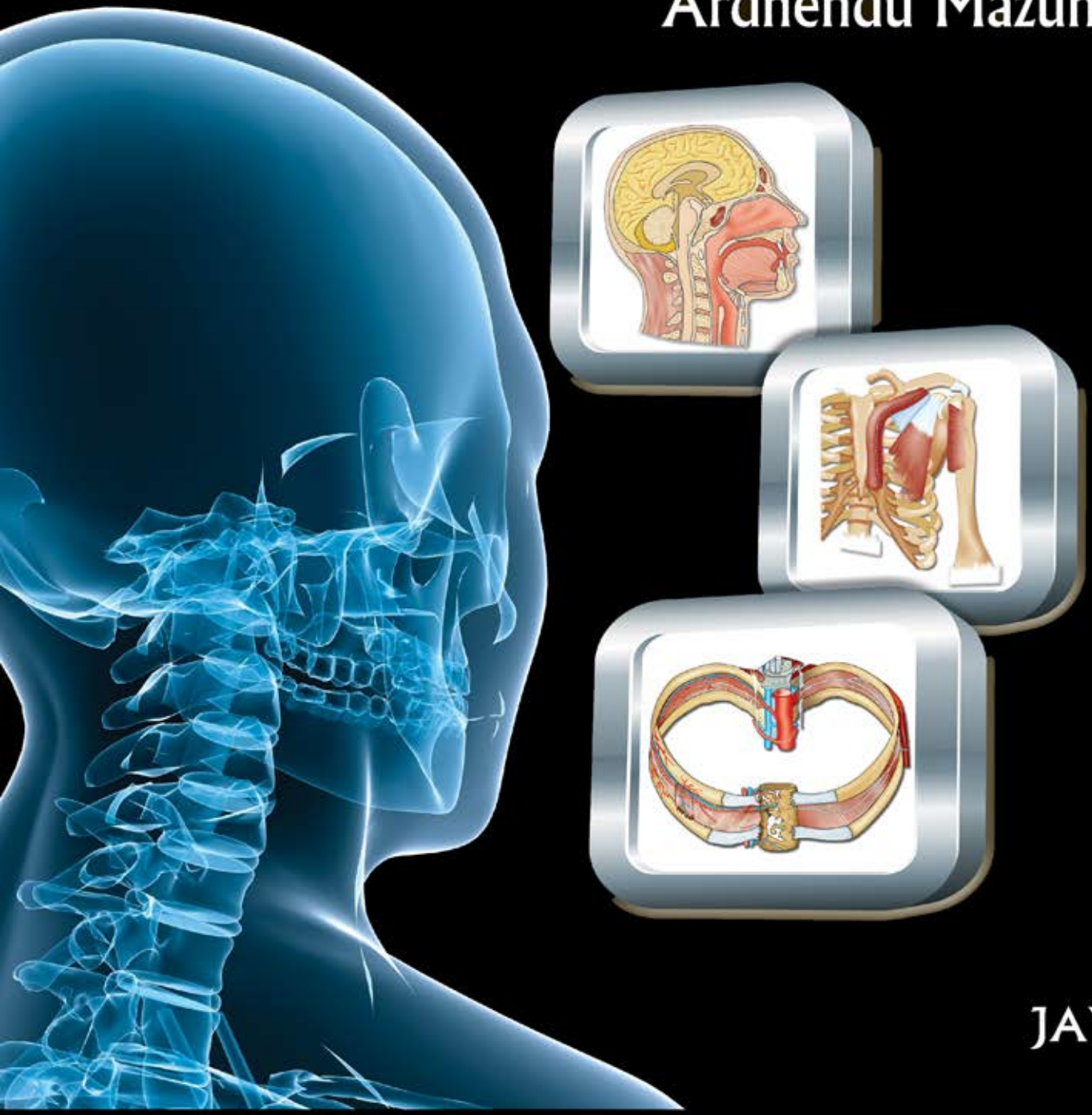

JAYPEE

CONTENTS

1 INTRODUCTION

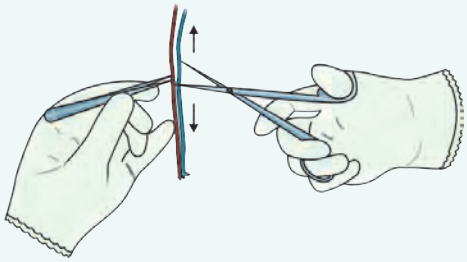

Instruments used during dissection 1; Methods of embalming of dead body 3; Tricks for meticulous dissection 3; Difference between window dissection and identification 5; Positioning of body and terminology of body regions 5; Positioning (body posture) 5; Anatomical terms 5; Regional terms for specific body areas 6.

2 THE UPPER LIMB SUBDIVISIONS

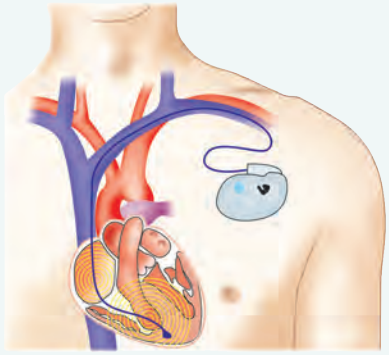

Front of upper limb 8; Clavipectoral fascia 8; Incision 8; Steps of dissection 9; Applied anatomy 10; Axilla 11; Position of body during dissection—supine with upper limb at right angle with the body 12; Dissection procedure and contents of axilla 12; Muscles in this region 14; Applied anatomy (clinical anatomy) 14; Cubital fossa 16; Position of body during dissection 16; Incision 17; Steps of dissection 17; Applied 18; Palm 18; Position of body 19; Incision 19; Clinical anatomy 21; Midpalmar space and thenar space 21; Infection of the pulp space of the finger 22; Carpal tunnel syndrome 22; Front of arm 22; Incision 23; Dissection procedure and contents of arm 23; Bone of this region—humerus 24; Front of forearm 25; Steps of dissection and contents 25; Bones of forearm are radius (on lateral side) and ulna (on medial side) 28; Muscles of forearm 28; Triangular and quadrangular space (scapular region) 28; Clinical anatomy 32; Back of upper limb 32; Posterior compartment of arm 32; Position of body 32; Incision 32; Steps of dissection and identification of structure 32; Back of forearm with dorsum of hand 34; Contents 34; Muscles 34; Position of the body 35; Incision 35; Steps of dissection and identification of structures 35; Bones of the region 37; Shoulder joint (glenohumeral joint) 39; Bones concerned 40; Steps of dissection and identification of structures 40; Movements of the joint 40; Clinicial anatomy 42; Viscera (upper limb) and thorax 43; Breast 43.

JAYPEE BROTHERS

3 THE LOWER LIMB SUBDIVISIONS

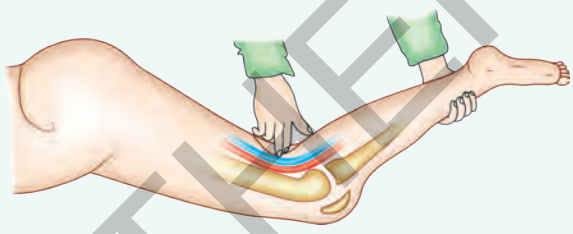

Inferior extremity (front) 47; Femoral triangle 47; Position of body 47; Steps of dissection 47; Applied (clinical) anatomy 51; Name of the dissection—adductor canal and front of thigh 51; Position of the body—supine, with thigh slightly abducted and rotated laterally 51; Steps of dissection and identification of structures 52; Incisions 52; Clinical anatomy 53; Dissection of leg (anterolateral compartment) 53; Position of body 53; Incisions 54; Bones of this region 55; Tibia and fibula 55; Muscles of this region 56; Muscles of anterior compartment of leg 56; Applied (clinical) anatomy 56; Name of the dissection— dorsum of foot 57; Position of body—supine with slight plantar flexion of foot 57; Incisions 57; Steps of dissection and structures identified in this region 58; Bones of this region are articulated skeleton of foot (dorsal aspect) 59; Applied anatomy 59; Inferior extremity (back) 61; Name of the dissection—gluteal region 61; Incisions 61; Steps of dissection and identification of structures 63; Bones of gluteal region 64; Hip bone, sacrum, coccyx and femur 64; Main muscles of the gluteal region 65; Applied anatomy 65; Popliteal fossa 67; Position of body—prone with extended knee 67; Incisions 67; Steps of dissection and identification of structures 67; Applied anatomy 68; Name of dissection—back of thigh 69; Position of the body—prone with extended thigh and knee 69; Steps of dissection and identification of structures 70; Incisions 70; Applied anatomy 71; Back of leg 72; Position of body—prone with extended knee 72; Steps of dissection and identification of structures 73; Incisions 73; Bones of the back of leg are posterior surface of tibia and fibula 74; Applied (clinical) anatomy 75; Sole 76; Steps of dissection and identification of structures 76; Incisions 76; Bones of this region are articulated skeleton of foot 77; Applied (clinical) anatomy 77; Hip joint 78; Movements of the joint, muscle involved, and nerve supply 80; Applied anatomy 81; Knee joint 82; Steps of dissection and identification of structures 82; Applied anatomy 85; Questions on faced during window dissection and identification 86; Lower limb 86; Adductor canal and front of thigh 87; Anterolateral crural region 87; Gluteal region 88; Back of thigh 88; Popliteal fossa 88; Back of leg 89; Sole 89; Dorsum of foot 89.

JAYPEE BROTHERS

4 ABDOMEN

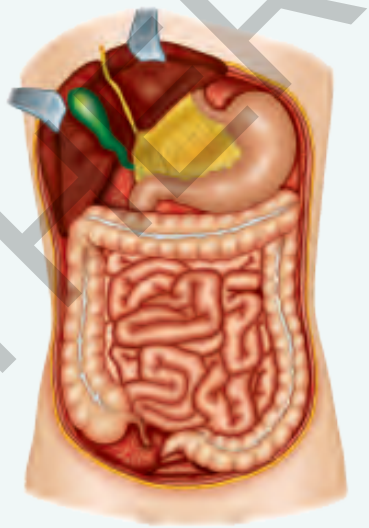

Name of the dissection—inguinal canal 90; Steps of dissection and identification of structures 90; Incisions 90; Rectus sheath 92; Position of body—supine with thigh extended 92; Formation of rectus sheath 94; Opening up of abdominal cavity 94; Position of body—supine 94; 1st day 94; Study of peritoneum and its cavity 95; Peritoneal folds 96; Peritoneal compartments 98; Peritoneal gutters 99; Applied anatomy 99; 4th day 99; 5th day 100; 6th day 103; 7th day 104; Lumbar plexus and its branches 105; Branches come out from the medial border of psoas major 105; Dissection of pelvis 106; Internal iliac artery (right and left) and its branches 106; Sacral plexus and its branches 108; Perineum (window dissection) 108; Boundary 108; Urogenital triangle 110; Anal triangle 112; Duodenum, jejunum and ileum 114; Large intestine 116; Important features (cardinal features) 116; Genitourinary system 120; Female reproductive system 123; Male reproductive system 124; Abdomen 125; Rectus sheath 126; Peritoneal cavity 126; Superior mesenteric artery 126; Celiac trunk and portal vein 126; Inferior mesenteric artery and abdominal aorta 126; Structures of posterior abdominal wall 127; Internal and external iliac arteries and interior of pelvis 127.

5 THORAX

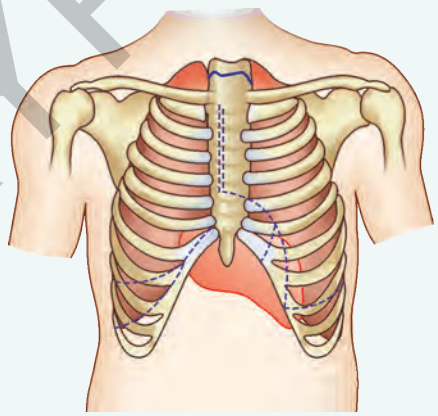

Intercostal space 128; Branches 129; Deep muscles of thorax 129; Opening of cavity of thorax 131; Pleural cavities 132; Visceral pleura 133; Nerve supply 133; Recesses of pleura 133; Applied (clinical) anatomy 133; Right side of thoracic wall 133; Sympathetic trunk 133; Left side of thoracic wall 134; Mediastinum 134; Pericardial cavity 135; Lungs 137; Applied anatomy 140; Important notes 140; Heart 140; Introduction 140; Artery supply of heart (coronary circulation) 143; The diaphragm 144; Thorax 145; Intercostal space and internal thoracic artery 145; Thoracic cavity (right side) 145

JAYPEE BROTHERS

6 HEAD AND NECK

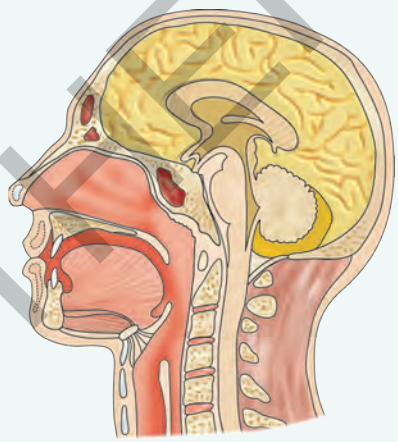

Name of the dissection—face 146; Position of body (supine) 146; Identification 146; Steps of dissection and identification of structures 147; Incisions 147; Bones of this region are: frontal, maxilla, zygomatic, nasal, ethmoid, mandible and parietal 148; Removal of skull cap and study of dural venous sinuses and roots of cranial nerves 148; Dural venous sinuses 151; Study the cranial nerves and base of the skull 152; Name of dissection—anterior triangle 158; Position of body (supine with neck extended) 158; Identify the following structures in this region 158; Steps of dissection and identification of contents 158; Incisions 158; Find out the floor 160; Name of dissection—posterior triangle 161; Position of body (supine with neck turned towards opposite side) 161; Steps of dissection and identification of structures 162; Incisions 162; Infratemporal fossa 163; Steps of dissection and identification of structures 164; Muscles of this region 164; Muscles of mastication 167; Viscera of head and neck 168; Brain 174; White matter of cerebral hemisphere 179; Questions from identifications and window dissection from head, neck and face 184; Anterior triangle of neck 184; Posterior triangle of neck 184; The cranial cavity 185; Infratemporal fossa 185.

7 SECTIONAL ANATOMY

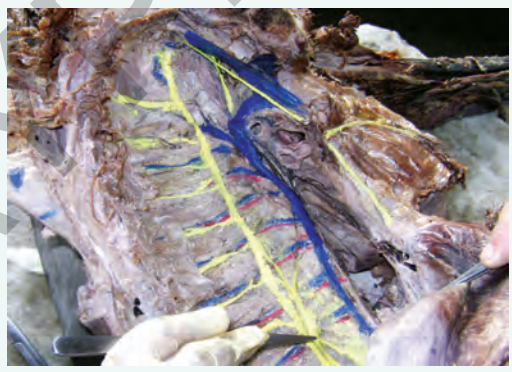

The importance of sectional anatomy 186; How to preserve cadavers for sectional anatomy 186; Middle 1/3rd section of arm or forearm thigh or leg means we see the section at the region of upper 1/3rd and lower 2/3rd part 187; Cross-section of left leg at the level of upper 2/3rd and lower 1/3rd junction—as the same section is turned upside down—so the orientation of tibia and fibula has changed 191.

INDEX 207

JAYPEE BROTHERS

Chapter 4

Abdomen

NAME OF THE DISSECTION—INGUINAL CANAL (FIGS 4.1 TO 4.4)

It is an oblique canal (4 cm long) situated in the lower part of anterior abdominal wall, above the medial part of inguinal ligament. It extends from deep inguinal ring (mouth of protrusion of fascia transversalis) to superficial ring (Y-shape; present in external oblique aponeurosis).

Anterior wall (Figs 4.1A and B):

- Throughout its whole extent formed by external oblique aponeurosis.
- Anterolaterally the wall is re-inforced by internal oblique and transversus abdominis muscles.

Posterior wall: Throughout its whole extent it is formed by fascia transversalis. Medial part of this wall is reinforced by conjoint tendon (union of medial arched fibers of internal oblique and that of transversus abdominis).

Roof: Formed by arched fibers of internal oblique and transversus abdominis.

Floor: Inguinal ligament.

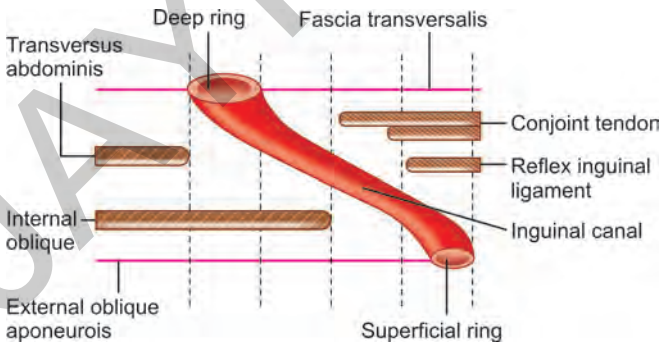

Fig. 4.1A: Inguinal canal: Schematic representation of structures forming the anterior and posterior walls

Contents of this canal is spermatic cord in male; round ligament of uterus in female and ilioinguinal nerve (partial content).

Position of body: Supine with extended thigh.

STEPS OF DISSECTION AND IDENTIFICATION OF STRUCTURES

Incisions (Fig. 4.2)

- Transverse incision from anterosuperior iliac spine (ASIS) up to midline.
- Vertical incision from the middle up to pubic tubercle. Reflect the skin downwards and laterally.
- Superficial fascia is exposed. It is divided here into superficial fatty Camper and deep membranous Scarpa's fascia. Both layers are identified if you put

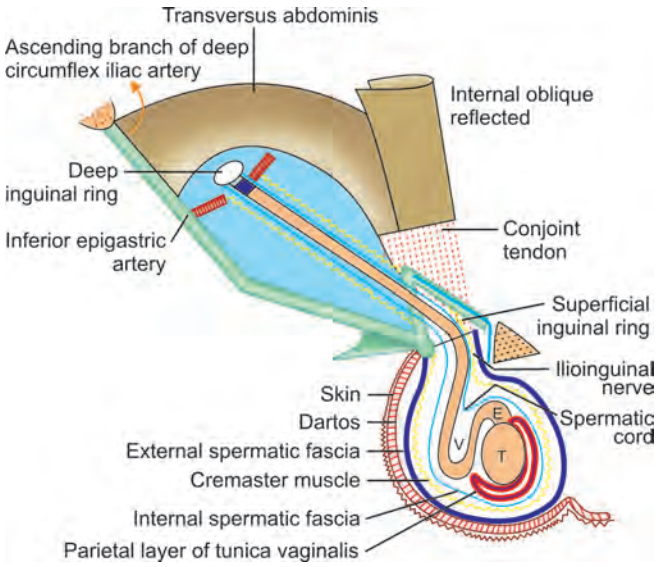

Fig. 4.1B: Boundaries of the inguinal canal: T—testis; V—vas deferens; E—epididymis

JAYPEE BROTHERS

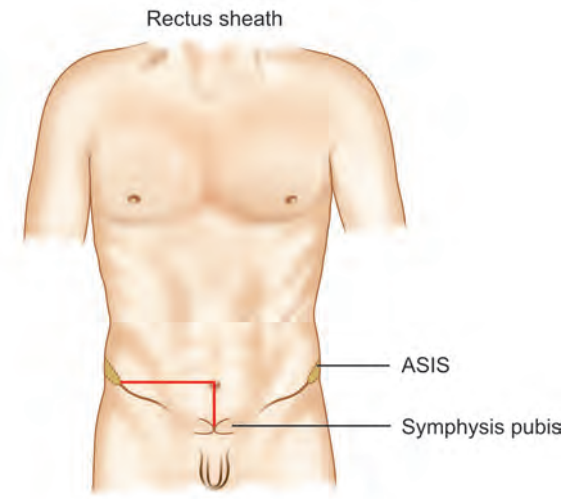

Fig. 4.2: Incisions

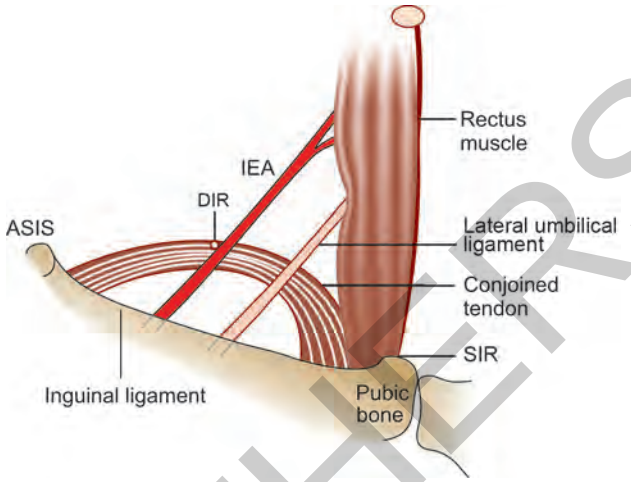

Fig 4.4: Direct hernia arises through Hesselbach's triangle; IL—inguinal ligament, SIR—superficial inguinal ring, DIR—deep inguinal ring, ASIS—anterosuperior iliac spine, IEA—inferior epigastric artery

wet cotton over the region after removal of skin. Water in the cotton swells up the two layers and they are easily separated. Reflect the superficial fascia by similar incision like skin (Fig. 4.3).

- External oblique aponeurosis is exposed. There is no deep fascia in abdomen. Note near the medial end and towards pubic tubercle a triangular gap is seen after removal of external spermatic fascia. This is superficial inguinal ring. It is guarded by 2 crura and they are connected by intercrural fibers. The lateral or inferior crus is strong and attached to pubic tubercle. The medial or superior crus is thin and attached to the front of symphysis pubis and blends with the fibers of medial crus of opposite side. Its dimension is 2.5 /1.5 cm. In male this opening is larger. So inguinal hernia is more common in male. You will notice thick spermatic cord descends through this ring to scrotum in male (Figs 4.1B and 4.3).
- Cut by transverse incision external oblique muscle and aponeurosis is such a way that it extends on the lateral aspect of rectus abdominis and then to symphysis pubis.
- Arched fibers of internal oblique is visible and part of inguinal canal with its contents is seen.
- The fibers of internal oblique are cut from inguinal ligament and reflected medially towards conjoint tendon (Fig. 4.1B).
- The whole length of inguinal canal is exposed and ilioinguinal nerve is present on the medial aspect of cord. This nerve does not pass through deep ring.
- The spermatic cord or round ligament of uterus is retracted downwards. The fascia transversalis and deep

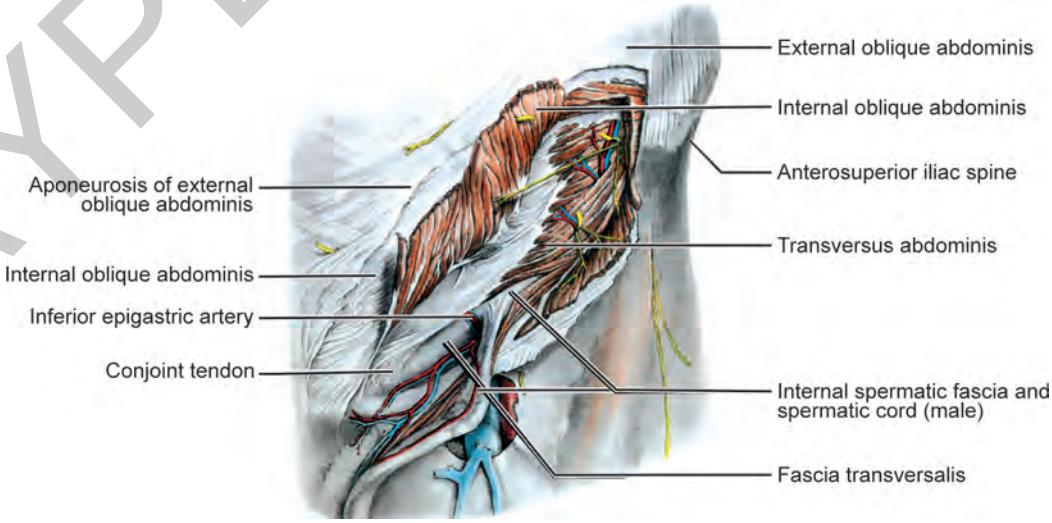

Fig. 4.3: Inguinal canal

JAYPEE BROTHERS

inguinal ring is exposed. Note that inferior epigastric vessels lies medial to deep inguinal ring and this artery acts as a guide to determine the deep ring. The inferior epigastric artery is a branch of external iliac artery.

Applied (Clinical) Anatomy (Figs 4.5A to D)

Inguinal hernia: When a part of intestines or peritoneal fold passes through the inguinal canal it is known as inguinal hernia. There are two types of inguinal hernia—direct and indirect. The indirect one comes through the deep ring and transverses the canal through and through. It is more common in young. It lies within the coverings of spermatic cord. A direct inguinal hernia occur by invagination of posterior wall in old age when muscles are weak and there is chronic strains like constipation, cough, etc. Inguinal hernia is more common in male as the canal is bigger.

RECTUS SHEATH

Position of Body—Supine with Thigh Extended

It is an aponeurotic sheath that is present almost wholly around the rectus abdominis muscle. Lower 1/3rd, it is deficient behind, where curved arcuate line is formed. Middle 2/3rd, it is aponeurotic and complete. After removing the anterior wall of sheath we can see the transverse intersections within rectus abdominis muscle.

Contents of the sheath are:

- Rectus abdominis muscle
- Pyramidalis, if present
- Lower 7th to 12th thoracic nerve and iliohypogastric and ilioinguinal nerve, which enter the muscle towards its lateral aspect (Fig. 4.6)
- Anastomosis of superior and inferior epigastric artery within the substance of muscle (Fig. 4.6).

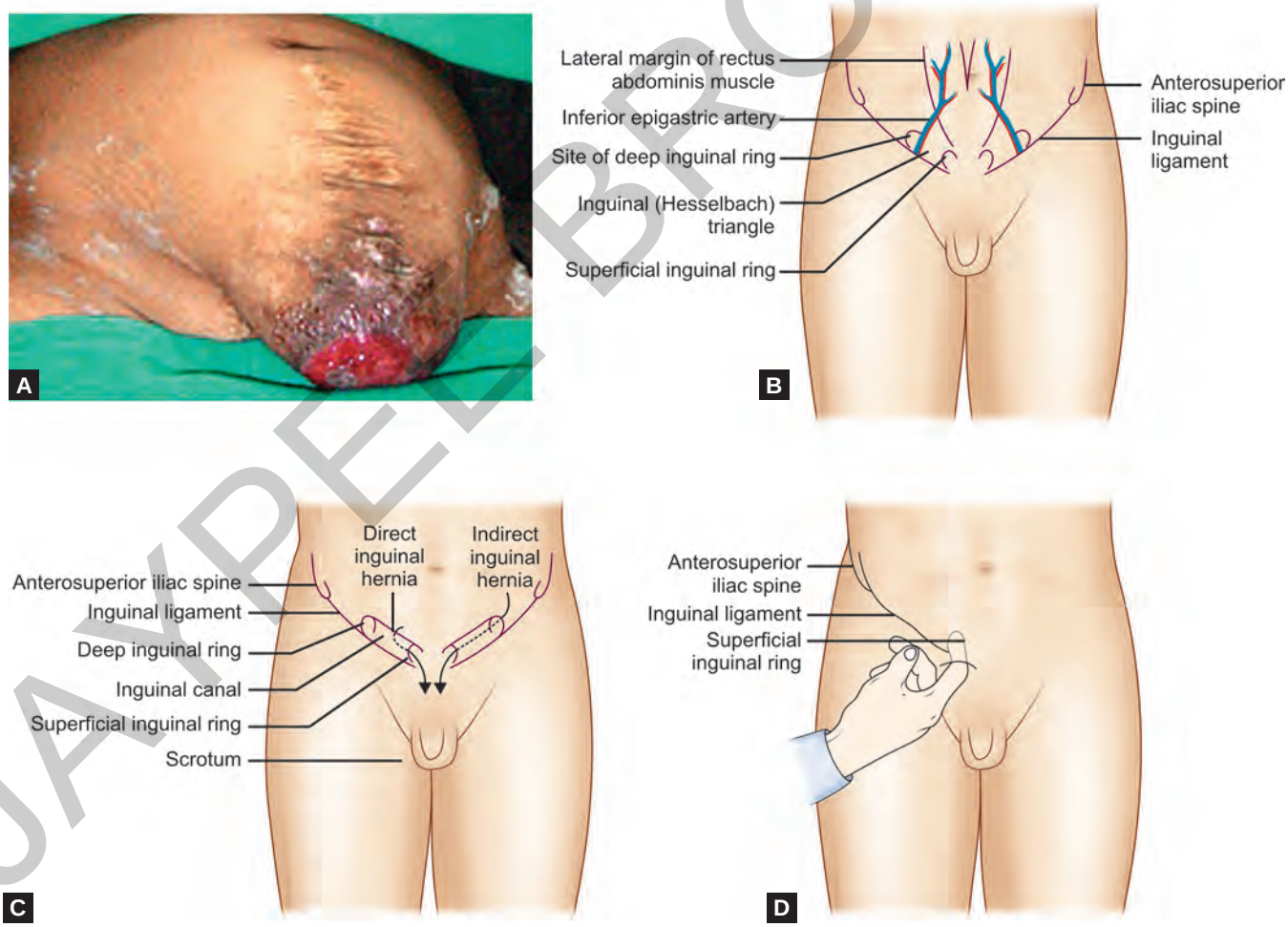

Figs 4.5A to D: A. Left sided complete inguinal hernia in a patient with benign prostatic hyperplasia (BPH) who is on Foley's catheter. He needs transurethral resection of prostate (TURP) with hernioplasty, B. Anterior view of lower part of abdomen showing the positions of superficial and deep ring, C. Direction of direct and indirect inguinal hernia, D. Palpation of superficial ring

JAYPEE BROTHERS

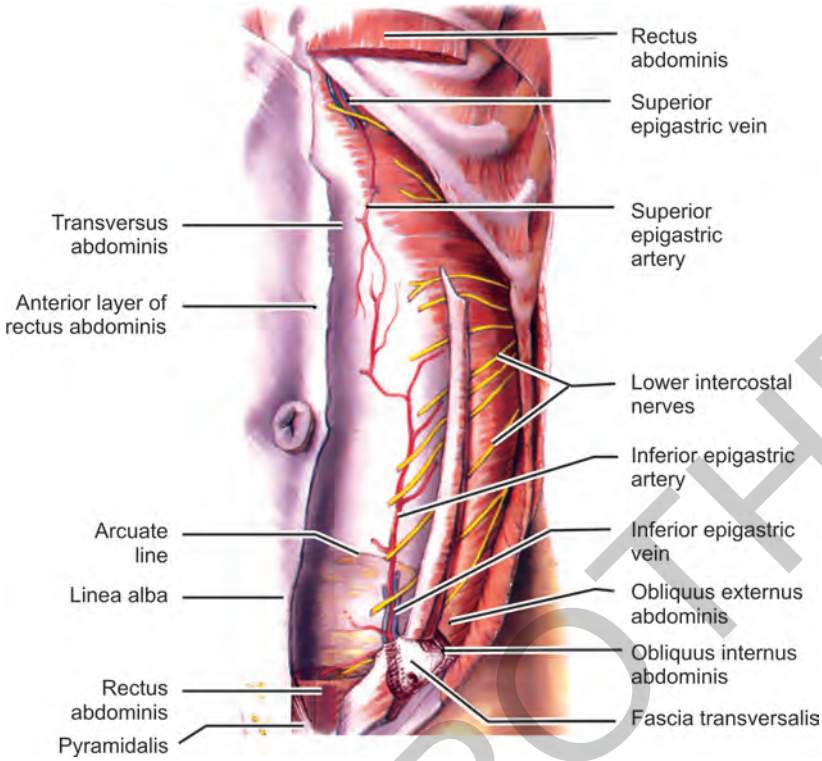

Fig. 4.6: Rectus sheath (posterior aspect)

Steps of Dissection and Identification of Structures (Fig. 4.7)

Incisions

- Transverse incision from xiphoid process up to 4½" (10 cm) laterally.
- Another oblique incision from anterosuperior iliac spine up to pubic tubercle.
- Midline vertical incision extending from the xiphoid process to symphysis pubis encircling the umbilicus.
- Skin along with superficial fascia is exposed and reflected sideways. Anterior layer of rectus sheath is exposed.
- Note that it is present through and through (Fig. 4.8).
- Cut the anterior layer of sheath. First lift a part of the sheath by means of toothed forceps; make a nick, introduce your finger and make the sheath free from surrounding muscle. In this way, you cut the sheath and proceed it upwards and downwards. You will notice in certain areas from umbilicus to xiphoid process. The sheath is attached to the anterior part of rectus abdominis muscle (Fig. 4.8). These are called tendinous intersections. It keeps the muscle is position during contraction. Cut the tendinous attachment from anterior layer of the sheath and reflect is laterally like skin.
- Identify the rectus abdominis muscle. Its lower attachment is narrow.
- Retract the medial border of rectus and note the posterior part of the sheath.
- Try to retract the lateral border of rectus medially; you will notice a number of intercostal nerves (T7 to T12), goes to supply the muscle. As the nerves enter through lateral aspect, during opening of abdomen in surgery

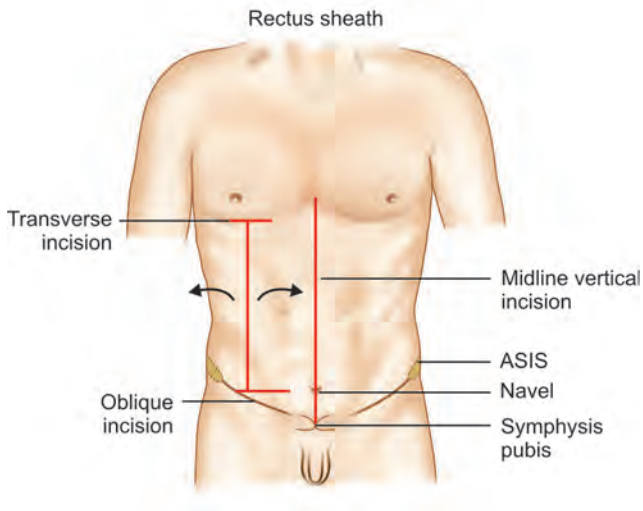

Fig. 4.7: Incision (rectus sheath): ASIS—Anterosuperior iliac spine

JAYPEE BROTHERS

rectus is reflected laterally and paramedian incision is given.

- Note the anastomosis of superior epigastric branch of internal thoracic artery and inferior epigastric branch of external iliac artery (see Fig. 4.6).
- You will notice in the lower part, posterior wall of the sheath is absent and form arcuate line (arc like). The arcuate line is formed by all the aponeurosis and muscle comes in front of rectus (see Fig. 4.6).

Formation of Rectus Sheath (Fig. 4.8)

Anterior wall: Throughout the whole length the external oblique muscle. From lower margin of thorax to a level midway between umbilicus and symphysis pubis, the sheath is formed by fused external oblique, anterior layer of internal oblique and anterior layer of transversus abdominis. At this level the posterior wall is formed by fusion of posterior layer of internal oblique and transversus abdominis. In the upper most part the rectus lies directly on costal cartilages and inferiorly, it directly lies on fascia transversalis below the arcuate line.

Applied (Clinical) Anatomy

- *Rectus sheath hematoma:* Most of the cases, it is due to bleeding from inferior epigastric artery in lower abdomen. Common in female due to trauma, typhoid fever, severe straining and exercise.
- *Incisional hernia:* It is the herniation through weak abdominal scar (scar of previous surgery). It is common in old age and fatty person.

OPENING UP OF ABDOMINAL CAVITY

Position of Body—Supine

1st Day

- After dissection of anterior abdominal wall open the abdominal cavity by lid like incision.
- Boundaries of abdomen above—The diaphragm by which it is separated from thoracic cavity. Below by pelvic diaphragm (formed by levator ani and coccygeus muscles) by which it is separated from perineum. Posterior wall is formed by 5th lumbar vertebrae in the midline and by psoas major and quadratus lumborum laterally. Anterolateral wall by three oblique and one rectus abdominis muscles.
- Incision goes along the costal margin, by the side of flank (waist) up to iliac crest; from iliac crest up to 1 inch medial to anterosuperior iliac spine. Reflect the lid of anterior abdominal wall downwards. During its reflection you will notice peritoneum. In the upper part, a falx like falciform ligament (see Fig. 4.11A) from umbilicus to liver obstruct the process. Cut this ligament and reflect the lid downwards.
- You note the shiny membrane covering the posterior aspect of anterior abdominal wall (Fig. 4.9). This is the parietal peritoneum. You will notice 2 paired folds and 1 unpaired fold in parietal peritoneum behind the lid. Unpaired one—median umbilical ligament, formed by urachus (embryological remnant) coming from the apex of the urinary bladder up to umbilicus. Two medial umbilical fold formed due to elevation of

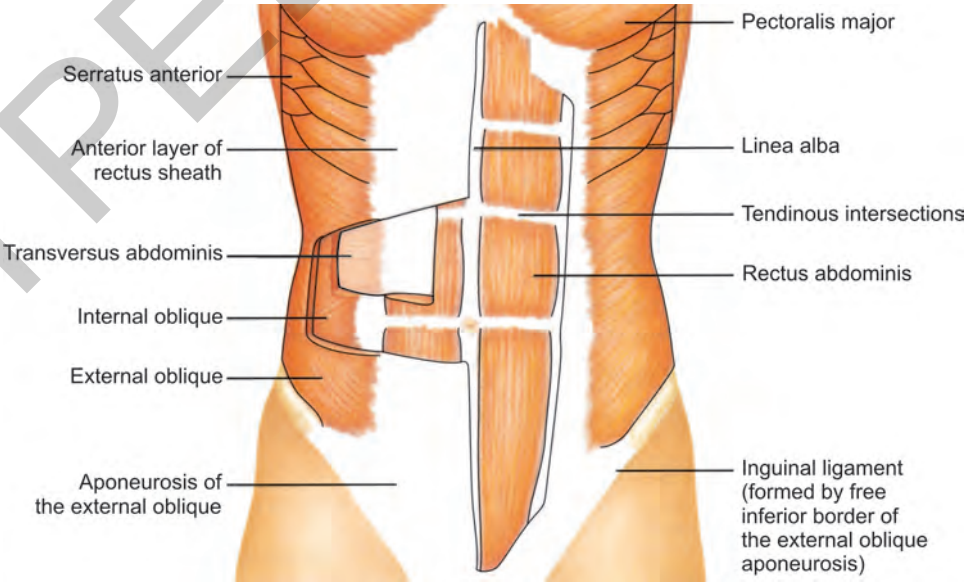

Fig. 4.8: Exposure of rectus sheath

JAYPEE BROTHERS

Muscles of anterior abdominal wall are (Fig. 4.8):

Muscle	*Origin*	*Insertion*	*Description*	*Nerve supply*	*Action*
External oblique (outer layer)	By fleshy slips from outer surface of lower eight ribs	Most fibers inserted in linea alba (white line) some into pubic crest, tubercle and iliac crest	It is most superficial muscle. Fibers run downwards and medially end in aponeurosis, which folds upon inferiorly and forms inguinal ligament	By T7 to T12 intercostal nerve	It compresses abdominal wall and increases the intra-abdominal pressure (which helps in micturition, defaecation, sneezing, etc.) along with the muscles of back, it helps in trunk rotation and lateral flexion
Internal oblique (middle layer)	Arises from a thoracolumbar fascia, iliac crest, inguinal ligament	Inserted in linea alba, pubic crest and last three ribs	Fibers run upwards and forward at right angle to those of external oblique.	T7-T12 intercostal and L1 nerves	Same as external oblique
Transversus abdominis (innermost layer)	Arises from thoracolumbar fascia, inguinal ligament, cartilage of last six ribs, iliac crest	In linea alba and in pubic crest	Fibers run horizontally and its deep surfaces lined by transversalis fascia	T7-T12 intercostal nerve and L1 spinal nerve	Compresses abdominal contents
Rectus abdominis	Arises as tendon from pubic crest and symphysis pubis	Inserted in xiphoid process (anterior surface) and 5-7 ribs (as fleshy fiber)	It is vertically placed straight muscle of abdomen situated on either side of midline intersected by tendinous intersection	T7-T12 intercostal nerves	Flex and rotate the lumbar region of vertebral column

obliterated umbilical artery. Two lateral umblical fold is formed by inferior epigastric vessels (Fig. 4.9).

- Teachers will show you the positions and relations of viscera. Note that the sacculated large gut occupies the periphery and the small gut lies in the center. Aggregated longitudinal muscle fiber from the base of appendix starts (known as tinea) and present all over large gut except rectum and anal canal. The small gut is covered by a thin apron, sometimes it is laden with heavy fat in obese (fatty) person; this is greater omentum which hangs from greater curvature (superficially placed) of stomach. Sometimes greater omentum is puckered when there is an infection. It localizes infection and so it is called policeman of abdomen. For conveyance of study as well as for clinical examination abdomen is divided into nine regions by two vertical (mid-clavicular) and two transverse line (transpyloric and transtubercular plane). Position of abdominal viscera in relation to regions of abdomen are tabulated below (Fig. 4.10):

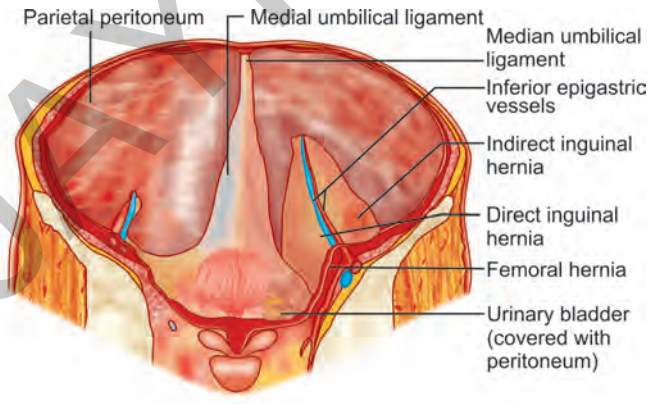

Fig. 4.9: View of anterior abdominal wall from behind

Viscera	*Quadrants of abdomen*
Liver	Right and left hypochondrium and epigastrium.
Stomach	Epigastrium, left hypochondrium and umbilical region
Duodenum	First part extends into epigastrium; rest of the part extends to posterior abdominal wall.
Pancreas	It is retroperitoneal and is situated in the epigastrium and left hypochondrium
Spleen	Left hypochondrium and against the 9th, 10th and 11th rib.
Cecum with appendix	Right iliac fossa.
Transverse colon	Right lumbar, umbilical and may extends up to hypogastrium, lumbar, left hypochondrium.
Rectum and anal canal	Pelvic cavity

STUDY OF PERITONEUM AND ITS CAVITY

In body, three serous cavities are present. Plural cavity, one on either side of chest; pericardial cavity, within the pericardium and peritoneal cavity, within abdomen. It is the largest of all the body cavity. All these cavities are potential cavities which is clearly understood during accumulation of fluid. All the serous cavities contain slippery serous membrane.

The peritoneum is a thin translucent, serous membranes which lines the abdominal wall and reflected over viscera. So it has two layers—parietal layer (lines the body wall)

JAYPEE BROTHERS

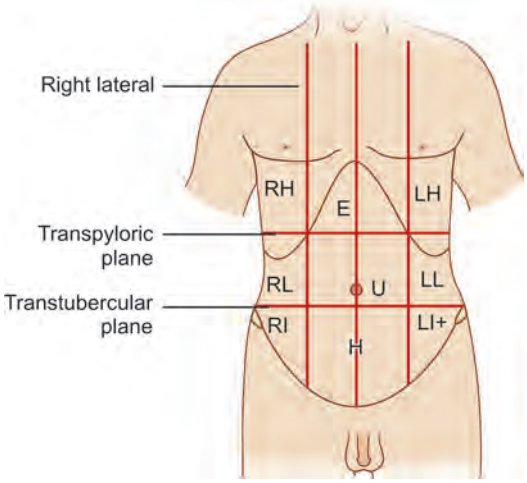

Fig. 4.10: Regions of abdomen

RH—Right hypochondrium, E—Epigastrium, LH—Left hypocondrium, RL—Right lumbar, U—Umbilical, LL—Left lumbar, RI—Right iliac, H—Hypogastrium, LI—Left iliac

and visceral layers (intimately covers the viscera) known as visceral peritoneum. It is potential space containing serous fluid, which decreases friction during organ movement. In male it is a closed serous sac but in female the sac is open as uterine tube into the peritoneal cavity. The parietal and visceral layers of peritoneum is continuous with one another via several extensions known as folds.

They are the mesentery, lesser and greater omenta (Figs 4.11A to C), falciform ligament transverse and sigmoid mesocolon, broad ligament, etc. The peritoneal cavity is divided into a major part known as greater sac and small protrusion of it, behind the stomach and anterior two layers of greater omentum is the lesser sac. The two sacs communicate by a narrow opening known as epiploic foramen (see Fig. 4.13A). It is vertical slit about 2.5 cm in size, bounded anteriorly—lesser omentum containing hepatic ducts, hepatic arteries and two division of portal vein (posteriorly by inferior vena cava and below by first part of decodenum).

Main parts of the small and large intestines are suspended by folds peritoneum some organs like kidneys, ureters and pancreas are plastered onto posterior abdominal wall by parietal peritoneum. They are known as retroperitoneal organs.

Peritoneal Folds

On the posterior surface of anterior abdominal wall there are six folds of peritoneum; out of which one fold extends from umbilicus to liver, the falciform ligament. It contains the ligamentum teres hepatis (obliterated remains of left umbilical vein) (Figs 4.12 and 4.13). The other four folds lies below umbilicus. One is a central fold and with a pair on either side. The central fold is known as median umbilical fold (extends up to umbilicus) (see Fig. 4.9).

Peritoneal folds that connects the small and large intestine.

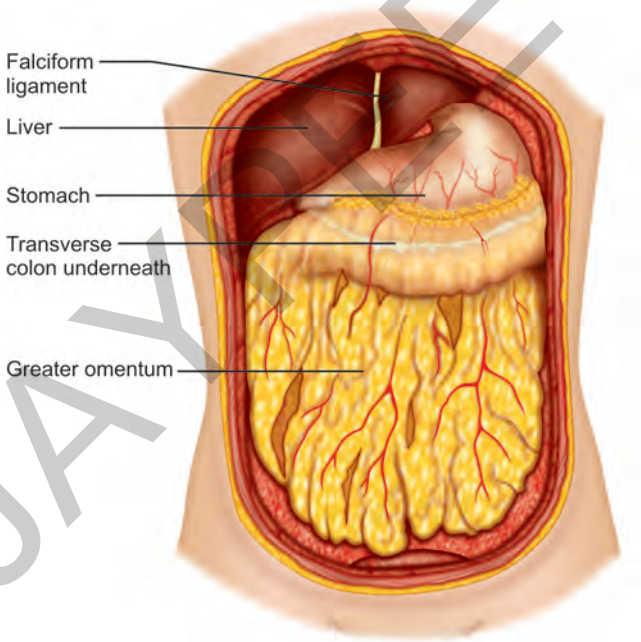

Fig. 4.11A: Abdominal cavity containing greater omentum (almost cover the whole abdomen)

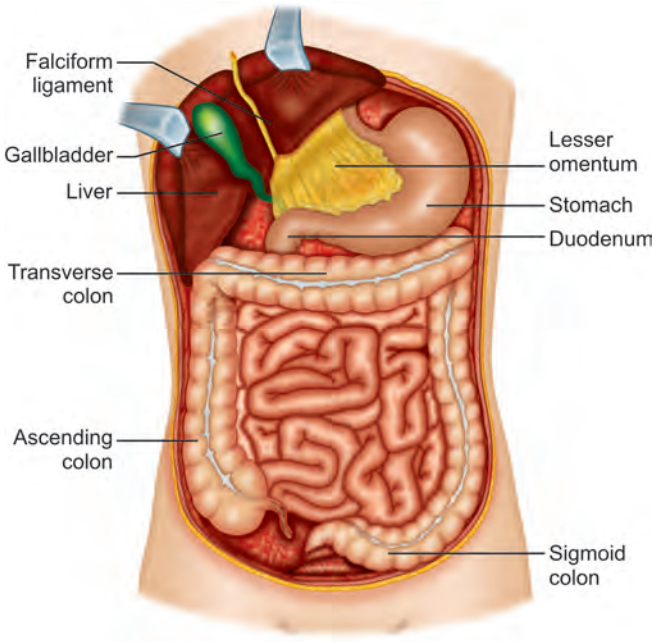

Fig. 4.11B: Visualization of lesser omentum after cutting of greater omentum

JAYPEE BROTHERS

1. At the stomach (Figs 4.11A, B and 4.12)
   a. Along the lesser curvature—lesser omentum is attached. It has two parts—hepatogastric (limited within stomach) and hepatoduodenal (that extends up to 1st one inch of 1st part of duodenum). Its right free margin containing hepatic duct, hepatic artery and portal vein forms the anterior boundary of epiploic foramen.

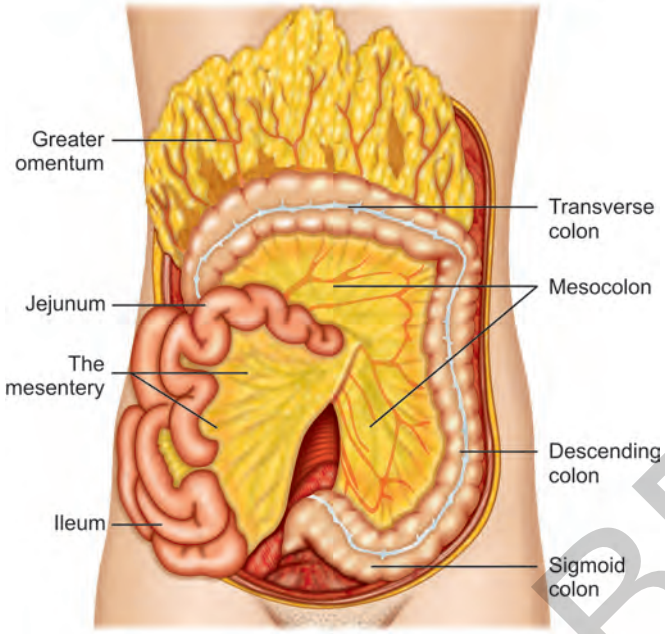

Fig. 4.11C: Visualization of the mesentery after reflecting the greater omentum

   b. Along the greater curvature—from above down wards lies gastrophrenic ligament gastrosplenic ligament and anterior two layers of greater omentum (Fig. 4.11A).

Greater omentum is a double fold of peritoneum, folded on itself and forms four layers. Anterior two layers descends like an apron over the coils of intestine. The 1st layer from the 3rd layer and 2nd layer form the 4th layer and ascends infront of the transverse colon and form transverse mesocolon. It goes up to anterior border of body of pancreas. The mesocolon in thin and contains fat, right, and left gastroepiploic vessels. It acts as a protector against spread of infection; so it is name as policeman of abdomen.

2. Along the coils of jejunum and ileum, which are suspended from dorsal body wall by the mesentery. It is fan shaped (Fig. 4.11C), its intestinal border is 6 meters whereas vertebral border is 15 cm. Breadth is 20 cm at the maximum point. It goes obliquely from the left part of L2 vertebra up to right sacroiliac joint. This border crosses the following structures from left to right.
   a. Third part of duodenum
   b. Abdominal aorta
   c. Inferior vena cava
   d. Right psoas major and minor
   e. Right gonadal vessels
   f. Right ureter at right sacroiliac joint.

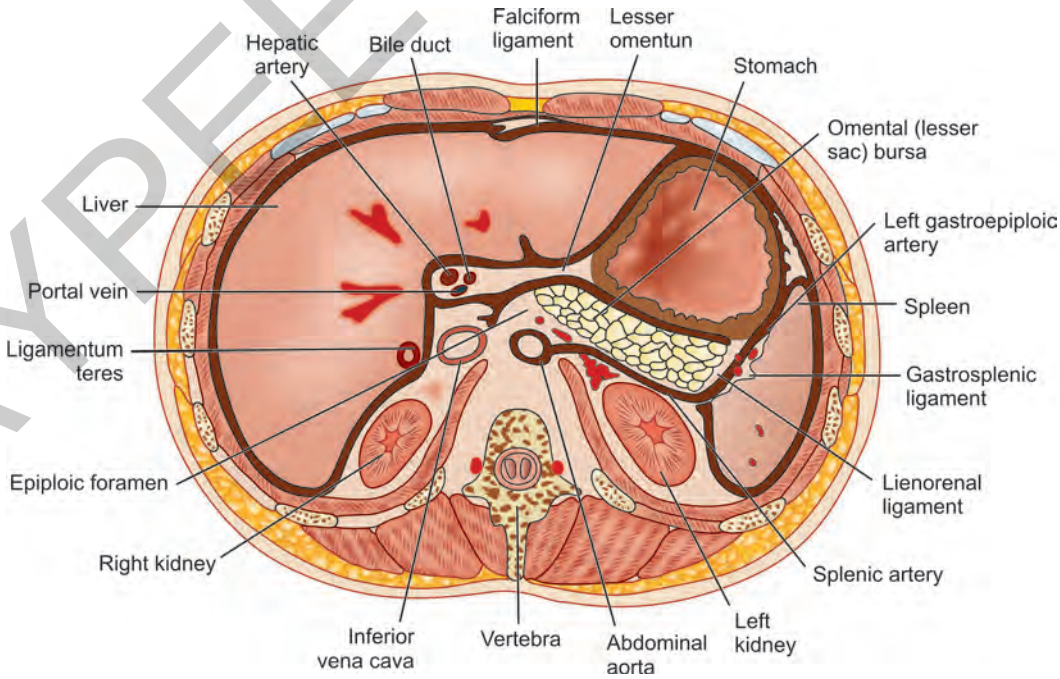

Fig. 4.12: Horizontal section of peritoneal cavity (viewed from below)

JAYPEE BROTHERS

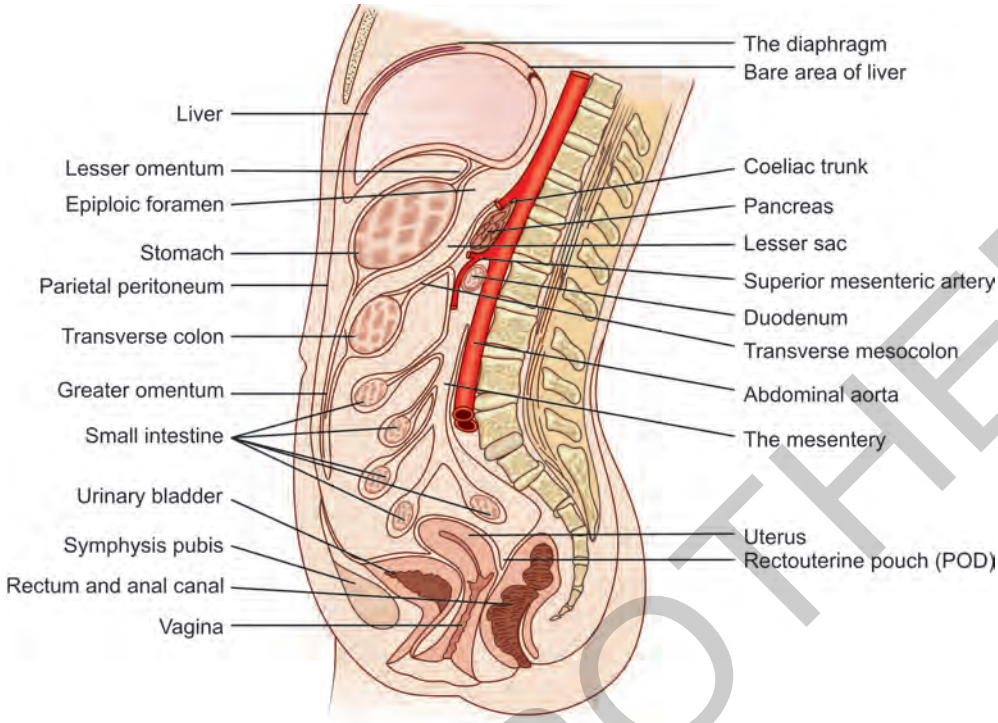

Fig. 4.13: Sagittal section of abdomen showing peritoneal cavity and the folds of peritoneum

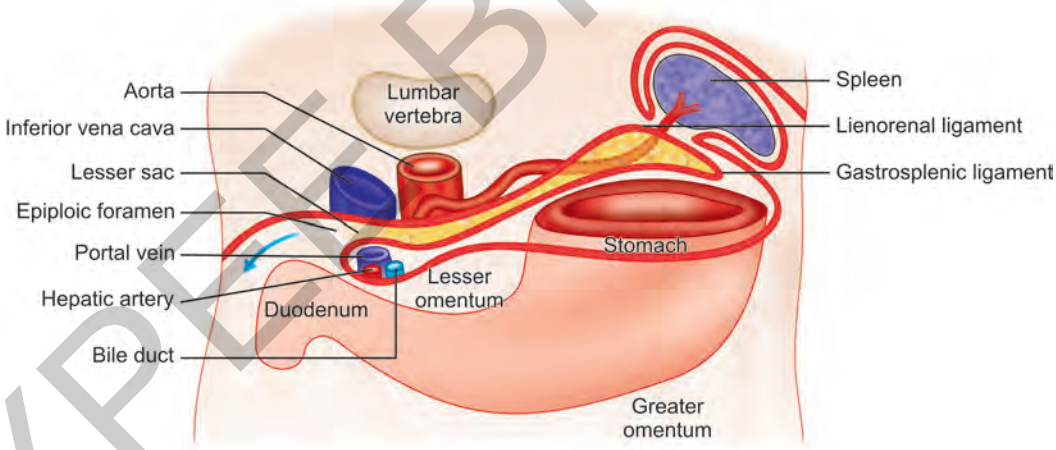

Fig. 4.14A: Lesser and greater sacs. The lesser sac (omental bursa) lies posterior to the stomach and communicate into the grater sac through epiploic foramen

Contents of the Mesentery

1. Jejunum and ileum
2. Jejunal and ileal vessels
3. Sympathetic plexus, lymph nodes (about 200) and fat.

Peritoneal Compartments (Figs 4.14A and B)

The peritoneal cavity is divided into compartment, called supracolic, infracolic and pelvic compartment. The dividing line between supracolic and infracolic compartment is the attachment of transverse mesocolon to the posterior abdominal wall and also at the middle of the 2nd part of duodenum. The transfer colon and its mesocolon are adherent along the posterior surface of greater omentum. When greater omentum is lifted over the costal margin, the stomach transverse mesocolon is lifted upwards and posterior surface of mesocolon is seen. The attachment of liver to diaphragm and falciform ligament to anterior

JAYPEE BROTHERS

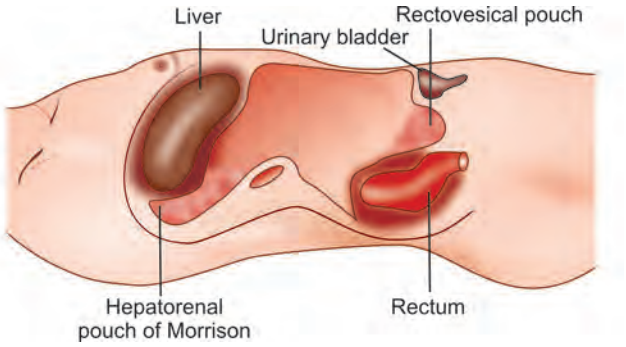

Fig. 4.14B: Commonest site of collection of fluid or pus in peritoneal cavity

abdominal wall divided supracolic space into right and left subdiaphragmatic (subphrenic space) spaces. Behind the right lobe of the liver and in front of the right kidney lies hepatorenal pouch of Morrison. It is the most dependant part in lying position another dependens space is rectovesical space in case of male, or rectouterine space in case of female. When fluid accumulates, it accumulate either on hepatorenal pouch or rectovesical pouch the right recess is the common site for abscess formation. Pathological material may transported from one recess to another.

PERITONEAL GUTTERS (FIG. 4.15)

The mesentery of the small intestine, ascending colon and descending colon are attached to the posterior abdominal wall by a special pattern. As a result of that 4 gutters are formed on either side of ascending and descending colon. They can efficiently convey materials (inflammatory material, ascitic fluid, blood, bile, etc.) from one point two another through these paracolic gutters.

Applied Anatomy

- Inflammation of peritoneum is known as peritonitis which affect parietal peritoneum and there is card board like rigidity of anterior abdominal wall.
- Ascites—accumulation of fluid within the peritoneum is known as ascites.
- The paracolic gutter provied pathway for flow of ascitic fluid (see Fig. 4.4).

Applied (Clinical) Anatomy

- *Appendicitis:* Inflammation of appendix; which causes vague pain around umbilicus at first, due to same segmental [T10] supply. Next severe pain in McBurney's point where maximum tenderness is felt.
- *Peptic ulcer:* Breach is the mucous membrane of stomach or 1st part of duodenum is known as peptic ulcer (gastric ulcer—when stomach is affected and duodenal ulcer—when duodenum is affected).

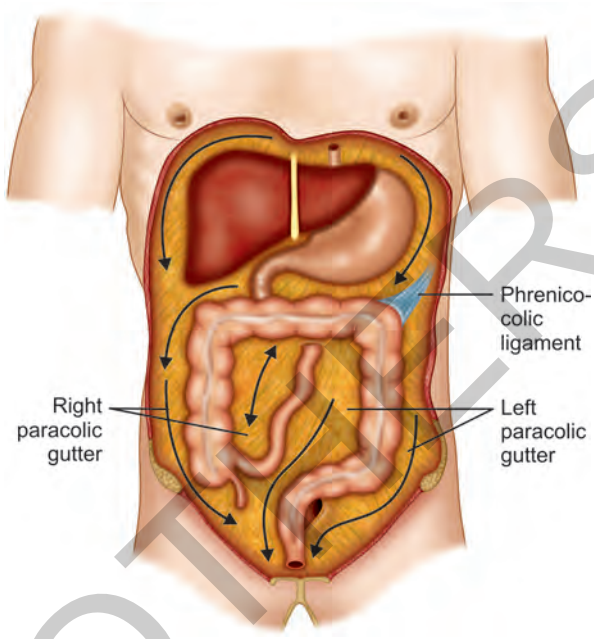

Fig. 4.15: The four gutters in the peritoneal cavity

4th Day

Superior Mesenteric Artery (Fig. 4.16)

Identify the pylorus of stomach; then gradually trace the duodenum and head of pancreas. Lift up the coils of small intestine retract it and feel the root of superior mesenteric artery or you can see the vessels of the intestine. Trace the vessels at the root of the mesentery and ascend upwards. You can get the roots of superior mesenteric vessels. Superior mesenteric artery is cleaned. Identify its vessels that arise from concave border—they are: (1) middle colic, (2) right colic and (3) ileocolic arteries. From convex border 12-16 jejunal and ileal branches arise. Superior mesenteric artery is the 2nd ventral branch of abdominal aorta and it supplies the midgut [i.e. from 2nd part of duodenum (major duodenal papilla) to the junction of right 2/3rd and left 1/3rd of transverse colon]. The jejunal and ileal arteries divides within the mesentery and form arterial arcades (Fig. 4.16).

- Identify the middle colic just below the body of pancreas. It enters the transverse mesocolon at once and divides into right and left branches. Secondary and tertiary branches from it form arterial arcade.
- Identify the inferior pancreaticoduodenal artery below the right end between head of pancreas and 2nd part of duodenum.

JAYPEE BROTHERS

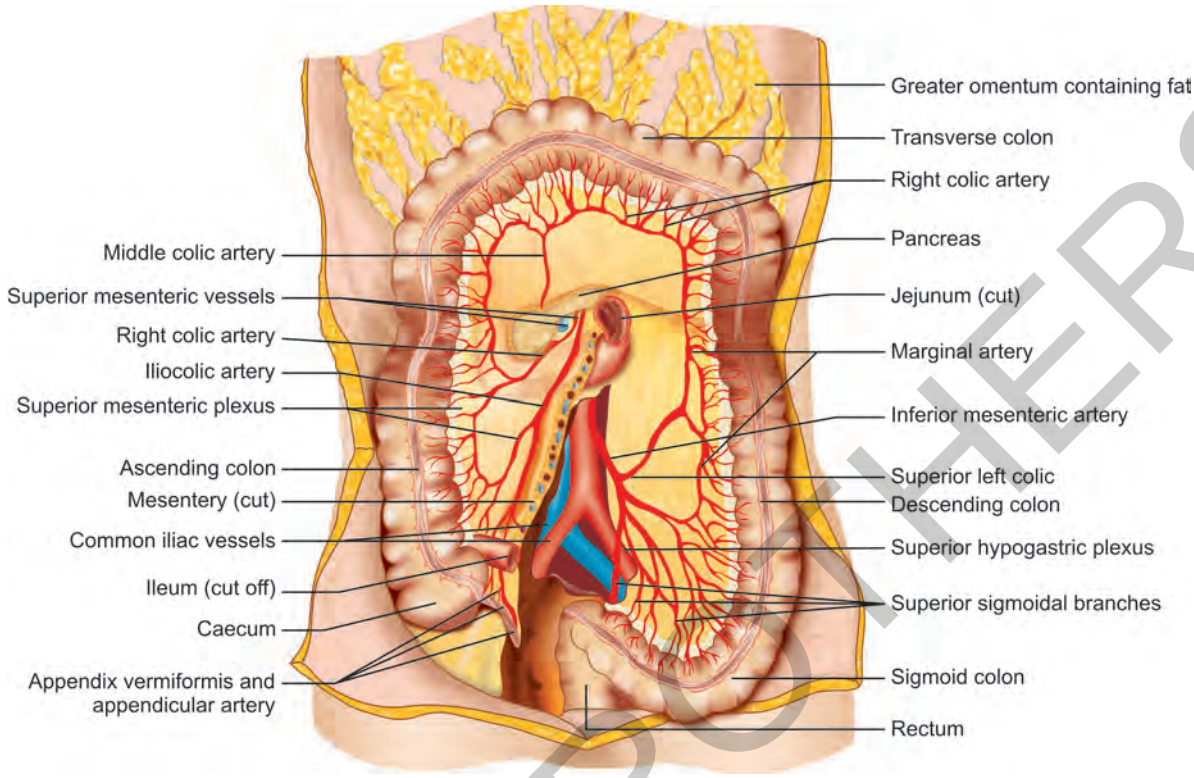

Fig. 4.16: Vessels and nerves of large intestine

- Look for right colic artery (Fig. 4.16). It runs towards right across 3rd part of duodenum, inferior vena cava, right psoas major, gonadal vessels and iliacus. It ends by dividing into ascending and descending branches.
- Ileocolic artery (Fig. 4.16) arises slightly lower down from right colic or may arise as a common trunk. It also ends by dividing into ascending and descending branches. The descending branch gives anterior caecal, posterior caecal and appendicular artery. After identifying the branches of superior mesenteric artery remove the midgut (small intestine except duodenum and large gut up to right colic flexure and make a specimen of the mesentry). How will you remove the small and part of large intestine. Tie two pieces of string 2 to 3 cm apart tight by along the duodenojejunal flexure and another two pieces of string below right colic flexure. Use scalpel to out through gut between the adjacent pain of ties.

5th Day

Celiac Trunk (Figs 4.17 and 4.18)

Though this is the first ventral branch that arises at the level of intervertebral disk between T12 and L1, yet you should do it after superior mesenteric artery. It will be easier in your dissection procedure.

- Pull the stomach downwards. You will notice the lesser curvature of stomach at a deeper plane. Note the abdominal aorta through lesser omentum (slightly left to midline). Make a nick in the lesser omentum near the lower part of body of stomach.
- Remove the anterior layer of lesser omentum.
- Identify the left gastric artery near the esophageal end of stomach. In this region you also get anterior gastric nerve (left vagus) in front of esophagus. Trace the right gastric artery along the lesser curvature and its continuation to parent trunk; common hepatic artery. Trace the right gastric vein. Note that it drains into portal vein.
- Next clean the hepatic artery up to porta hepatis. First, you will get gastroduodenal branch from the lower part of the artery. Clean all the structures of porta hepatis. There are two branches of hepatic artery (right and left), two branches of hepatic duct (comes out from liver) and portal vein (it lies behind all the above mentioned structures).
- Identify the gallbladder, its neck and then cystic duct. Cystic duct and the hepatic duct unite to form the bile duct. Push aside the bile duct and hepatic artery by means of untoothed forceps and clean the portal vein up to duodenum.

JAYPEE BROTHERS

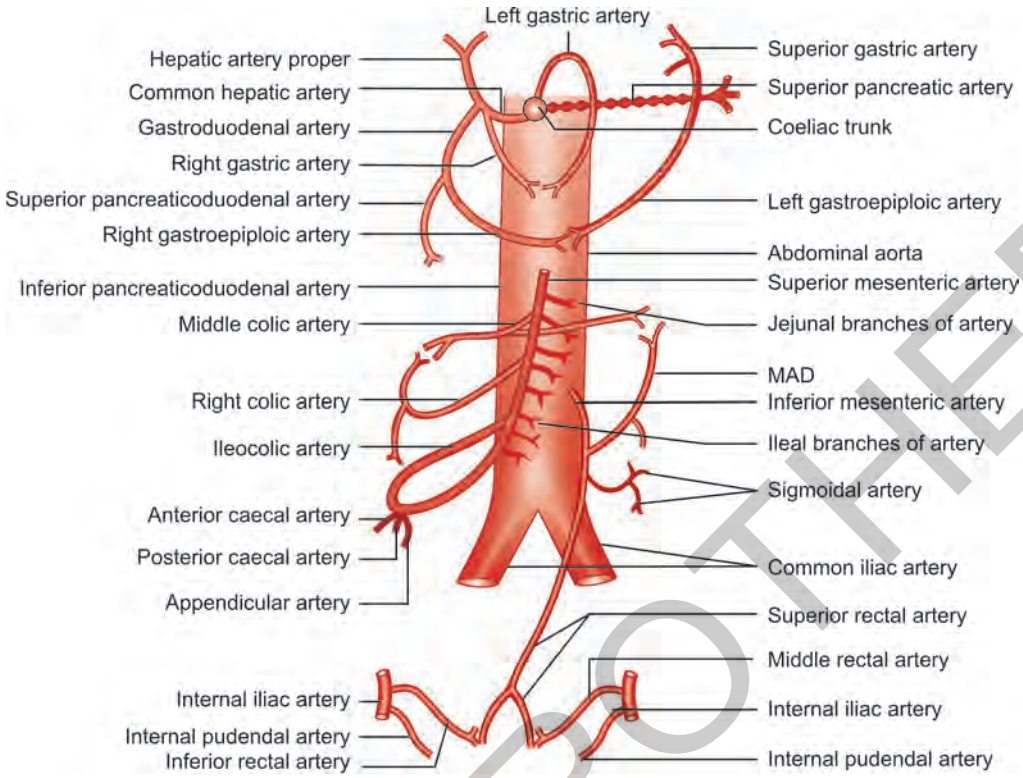

Fig. 4.17: Arterial supply of abdominal part of alimentary system (schematic)

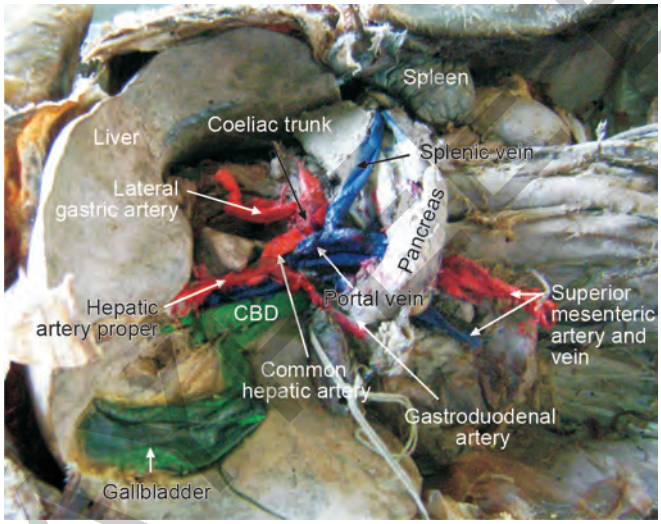

Fig. 4.18: Celiac trunk and other structures

- Next remove the posterior layer of lesser omentum and you will get tortuous splenic artery which arises from celiac trunk. It will follow the upper border of pancreas and divide into four and five branches which enter the spleen through hilum and supplies the organ.
- Note that splenic vein (straight) lies below the splenic artery. Trace it towards the right side where it will join with superior mesenteric vein to form portal vein behind the neck of pancreas.
- After visualizing the celiac trunk you will remove the stomach. Now duodenum, pancreas and spleen is clearly visible in posterior abdominal wall.

Portal Vein (Flow chart 4.1)

The hepatic portal system collect blood from digestive tract, and are valve less. They form a trunk—the portal vein, which enter into the liver and breaks up again into capillaries. Thus, the blood having passed through capillaries in the gut wall, again passes through capillaries (sinusoids) in the liver (Fig. 4.19).

Applied (Clinical) Anatomy

Portal hypertension (pressure over 40 mm Hg and normal pressure lies between 5-15 mm Hg): It is developed due to cirrhosis of liver (destruction of liver parenchyma and replaced by fibrous tissue), thrombosis of portal vein. Important portosystemic anastomosis exists at:

1. *Lower end of esophagus:* Communication of esophageal branch of left gastric (portal system) with esophageal veins of azygos system (systemic). An abnormally large amount of blood passes through these

JAYPEE BROTHERS

Dissection

Manual, Living and Cross-sectional Anatomy

Salient Features

- Highly organized practical aspects of anatomy
- Key concept presented in examination-oriented approach
- Comprehensive and concise text for quick resource and reference
- Unique two facing page spread format focusing on easy comprehension and retention
- Incision and exposure of structures as per 'Window Dissection' to enable the students to have a preview of present-day minimal invasive surgery
- Steps of dissection have been outlined to suit the availability and status of cadavers in tropical countries with minimal faculty and staff pattern
- List of actual instruments to be used and their sizes are mentioned
- Several diagnosis and pictures to illustrate living and clinical anatomy aspects
- Several charts and tables to highlight the basic facts and concepts
- Simple steps of preservation of cadavers

Sibani Mazumdar is presently working as Professor of Anatomy at Calcutta National Medical College, Kolkata, West Bengal, India. She is a renowned teacher and has been teaching anatomy to undergraduate and postgraduate students for 30 years in several medical colleges and institutes. She has been examiner of various medical colleges and universities. She has another medical book 'Anatomy at a Glance' published by Jaypee Brothers and it has been translated in Chinese language.



Ardhendu Mazumdar has been teaching in University College of Medicine for more than a decade. He has been selected 'Gem of India' at Delhi International Award. Apart from his contribution in this book, he has written several books among which 'Child and Society' has won 5 Who's Who awards.



Available at all medical book stores
or buy directly from Jaypee Brothers through online shopping
at www.jaypeebrothers.com

or call + 91-11-32558559

JAYPEE BROTHERS
Medical Publishers (P) Ltd.
www.jaypeebrothers.com

ISBN 978-93-5025-047-1