thers.com, for detailed information of otorhinolaryngology books, visit our website www.jaypeebrothers.com, for detailed information of otorhinolaryngology boo

CLINICAL ENT MADE EASY®

A Guide to Clinical Examination

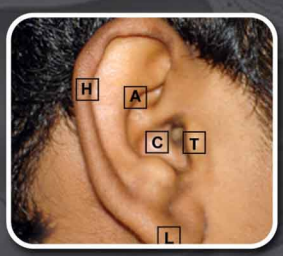



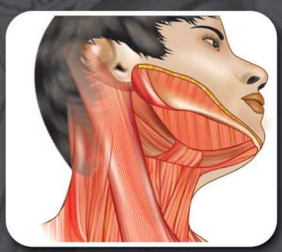

D Balakrishnan

Foreword
Ramesh C Deka

JAYPEE

Contents

1. General Introductory Topics **1**

How to Face the University Clinical Examinations? 3
Some Secret Tricks to Answer any Question, on a Medical Topic that You have not Read 6
The Anatomy of a Structured Case Sheet 11

2. Ear **19**

Basic Structure and Functions of the Ear 21
Natural History of Ear Infection 24
Taking the History in Ear Diseases 27
Physical Examination of the Ear 35
Model Case Sheet: Chronic Suppurative Otitis Media with Central Perforation Both Ears 50
FAQs in CSOM 57

3. Nose **65**

Structure and Functions of the Nose in Health and in Disease 67
Symptoms in Nasal Diseases 74
Physical Examination of the Nose 78
Investigations in Nasal Diseases 88
Brief Notes on Nasal Allergy 90
Model Case Sheet: Deflected Nasal Septum with Chronic Sinusitis 92
Model Case Sheet: Chronic Sinusitis with Ethmoidal Polyp 97
Model Case Sheet: Rhinosporidiosis 102
Model Case Sheet: Atrophic Rhinitis 107

4. Throat **113**

The Oral Cavity and Throat 115
Structure and Functions of Neck 128
Physical Examination of the Neck 143
Model Case Sheet: Chronic Adenotonsillitis 148
FAQs on Tonsillitis and Adenoiditis 155

5. Audiology **159**

FAQs in Audiology 174
Hearing Handicap 177
Conventional Hearing Aids 178

Other Assistive Devices 180
Bone Anchored Hearing Aid 181
Cochlear Implant 182

6. Instruments and Surgeries 187

Instruments Used in Office Examination 190
Some Office Procedures 195
Tonsillectomy 204
Adenoidectomy 213
Myringotomy and Ventilation Tube Insertion 217
Myringoplasty 218
Mastoidectomy 221
Instruments Used in Nasal Surgeries 231
Operations for Correcting a Deviated Nasal Septum 232
Functional Endoscopic Sinus Surgery 241
Endotracheal Tube Insertion and Emergency Laryngotomy 246
Tracheostomy 249
Rigid Endoscopy 256
Flexible Endoscopy 262
Microlaryngeal Surgery 264
Stapedectomy 265
Nasal Bone Fracture Reduction 266
Caldwel-Luc Operation 268
Lateral Rhinotomy (Moure's Operation) 269
Maxillectomy 270
Laryngectomy 270
Endoscopic Dacryocystorhinostomy 273
Lasers in Otolaryngology 273
The Use of Local Anesthetics in ENT Surgeries 276

7. Basic Radiology in ENT 279

History of Diagnostic Radiology 281
General Principles 282
Conventional Tomography 283
Computerized Tomography 283
Magnetic Resonance Imaging 284
Positron Emission Tomography 285
Single Photon Emission Computed Tomography 286
Occipitomental View of the Paranasal Sinuses (Water's View) 287
Occipitofrontal View of the Paranasal Sinuses (Caldwel's View) 291
Lateral View of the Skull and the Paranasal Sinuses 292
Submentovertical View for the Base of Skull 293

Mastoid X-ray 294
X-rays of the Neck 295
Imaging the Thyroid Gland 298
Ultrasound Examination of the Thyroid Gland 298
Nuclear Medicine Tests for Thyroid Function 298
Radioactive Iodine Uptake (RAIU) Study 299
Thyroid Scintiscan 299
Foreign Bodies in the Digestive Tract 301
Retropharyngeal Abscess 303
Foreign Bodies in the Airway 304
Contrast Films of Esophagus 307
Computerized Tomography Scans of Paranasal Sinuses 310

Index *317*

Chapter 3

Nose

The Pareto principle, or the Law of the Vital Few, is the work of an Italian economist Vilfredo Pareto (1848-1923). It is also known as the 80:20 rule. Originally developed for surveying land ownership, it gradually came to be applied to several other fields. It can be simply stated as 'a small portion of just about anything will most likely represent the majority of the total'. This principle can be applied to all aspects of life. The Pareto law also tells you how to use your time efficiently. Of all the things you do, only 20 percent really matter. This 20 percent of effort is responsible for 80 percent of your result. Identify this twenty percent and focus on that portion only. This book aims at providing you this vital fifth. Read on … …

JAYPEE BROTHERS

Chapter Outline

- Structure and Functions of the Nose in Health and in Disease 67
- Symptoms in Nasal Diseases 74
- Physical Examination of the Nose 78
- Investigations in Nasal Diseases 88
- Brief Notes on Nasal Allergy 90
- Model Case Sheet: Deflected Nasal Septum with Chronic Sinusitis 92
- Model Case Sheet: Chronic Sinusitis with Ethmoidal Polyp 97
- Model Case Sheet: Rhinosporidiosis 102
- Model Case Sheet: Atrophic Rhinitis 107

STRUCTURE AND FUNCTIONS OF THE NOSE IN HEALTH AND IN DISEASE

The external nose is also called the nasal pyramid. It is shaped like a pyramidal tent. The midline septum acts as the tent pole. The visible external part of the nasal pyramid (dorsum) is reinforced by the nasal bones. The skin in this portion is thin. The lower part of the dorsum is reinforced by the lateral nasal cartilages. The skin of this lower part is relatively thicker and has large sebaceous glands. Hence, furuncles are common in this lower part. In the elderly, these sebaceous glands may hypertrophy, resulting in a very large tip with thick skin, resembling an orange peel (peau d'orange skin). This condition is called 'rhinophyma' *(Fig. 3.1)*.



Fig. 3.1: Rhinophyma. This 85-year-old Anglo Indian resident of Madras attributed his nose swelling to his beer drinking habit. For cosmetic purposes, the mass was pared with sharp dissection and the raw area was grafted with split skin harvested from the postauricular area (Reprinted with permission from Chennai Clinical Centres)

JAYPEE BROTHERS

Sometimes, the nasal pyramid may appear bent. This is termed external nasal deviation, pyramidal deviation or dorsal nasal deviation. The cause may be an earlier trauma—a fall, a cricket ball injury or a traffic accident. Sometimes, during the birth process itself, the nasal pyramid might have got moulded. On examination of the interior of the nose, you will commonly find that the septum itself had bent and the dorsum had simply followed the tent pole.

Sometimes, you may see a collapsed nose. This is usually due to a loss of support, caused by a septal perforation. The most common cause of perforation is trauma. Safety pins, ornaments, or other foreign bodies may accidentally injure the septum and cause a perforation. 'Chrome perforation' is an occupational hazard among the chromium-platers. Habitual nasal picking may predispose to a perforation. Snuff and cocaine use may also cause such a catastrophe. It is sad to note that cocaine snorting has recently crept into India. Repeated cauterization of the Little's area in cases of epistaxis, may result in a perforation. Perforations may also occur after a submucous resection operation, due to unintended tears in the mucoperichondrium. When such tearing occurs on both sides of the septum, opposite to one another, a perforation may result. During removal of rhinosporidial or angiomatous masses also, a perforation might occur.

A perforation in the septum might also occur due to pathologic conditions like Syphilis, Hansen's disease, Tuberculosis, Lupus (low virulence tuberculosis), etc. Amongst these diseases, only syphilis produces a bony perforation as a result of perivascular cuffing and endarteritis. All the other diseases produce a perforation in the cartilage portion. Sometimes, granulations might be seen around a perforation. In lupus, such granulations appear pale. Malignancy is a sinister cause of perforation. If the perforation were to be very large, the nasal pyramid might collapse, leading to a collapsed nose.

Cutaneous leishmaniasis manifests as granulomatous ulcers, in and around the nose. In 1903, while working in Madras Medical College, Lord Charles Donovan discovered that sandfly was the vector of Leishmaniasis. In those times, in India, leishmaniasis was a lethal disease. However, now, leishmaniasis has almost totally disappeared from Madras. This author, living in Madras (Chennai) almost continuously since 1971, has not seen any case in that city. The only time he saw a patient with cutaneous leishmaniasis, was in 1997 in the Saudi Arabian desert *(Fig. 3.2)*. Within India, it is still seen sporadically in the central Indian states of Madhya Pradesh and Bihar.

The eyes are separated from the nose by a thin paper like bone, called lamina papyracea. An increase in the distance between the eye balls is called hypertelorism. Such an appearance is commonly described as a 'frog face' due to its close resemblance to our amphibian cousin. Hypertelorism may result from trauma or due to a polyp inside. Hypertelorism may also occur in some congenital conditions, e.g. Crouzon's disease. Rarely, you may come across other congenital conditions like a bifid nose, a dermoid *(Fig. 3.3)*, a midline dermal sinus, etc.

The area found immediately inside the anterior nasal openings, is called the nasal vestibule. This vestibule is lined by skin, sporting, short and thick hairs

JAYPEE BROTHERS

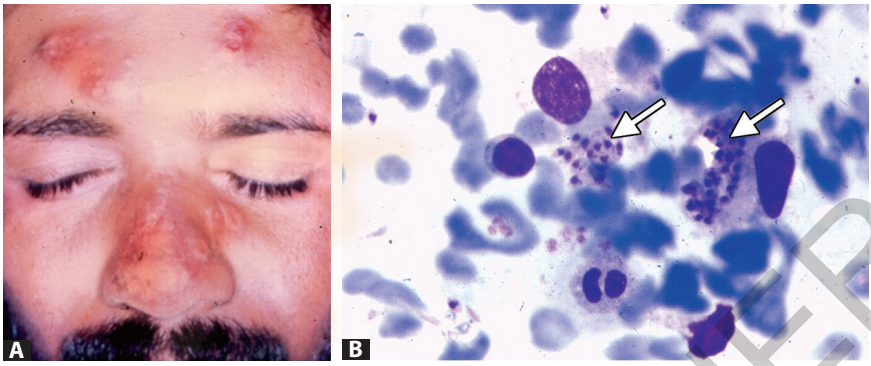

Fig. 3.2: This 28-year-old bedouin (shepherd) used to sleep in the open deserts of Arabia. (A) One year ago, erythematous macules and papules had appeared on his nose. Slowly, they had turned into ulcers. Satellite lesions are now seen around the nose. No lesion was present inside the nose. There was no splenomegaly or hepatomegaly. Serological tests ruled out any sexually transmitted disease. A smear from the lesion confirmed the diagnosis to be cutaneous leishmaniasis. (B) Photomicrograph of a nasal smear from this patient shows oval shaped amastigote forms of the Leishmania parasite within the host macrophages. They are called Leishmann Donovan bodies. Some amastigotes lie free, after rupture of the host cells. Sodium stibogluconate was given for ten days by slow intravenous infusion with ECG monitoring. The lesions started resolving right from the third day (Reprinted with permission from Chennai Clinical Centres)



Fig. 3.3: (A) Nasal dermoid in a 12-year-old boy (B) Nasal dermoid in a different child, one year old. Gentle pressure over site expresses purulent secretion (C) MRI of the same child, as in B. The arrow points to the dermoid cavity (Reprinted with permission from Chennai Clinical Centres)

called vibrissae. The follicles of these vibrissae may get inflamed and present as intensely painful swellings (folliculitis, nasal vestibulitis). The superior limit of the vestibule is a curved ridge of skin in the interior of the nasal cavity called the limen nasi. The limen nasi marks the transition of keratinising squamous epithelium into respiratory type of epithelium.

The septum separates the interior of the nose into right and left nasal cavities. The nasal septum is made up of a quadrilateral shaped septal cartilage with bony contributions from the ethmoid, palatine, vomer and the maxillary bones *(Fig. 3.4)*. The inferior (caudal) edge of the septum is called the columella. The septum is rarely straight. A gentle bend in the

JAYPEE BROTHERS

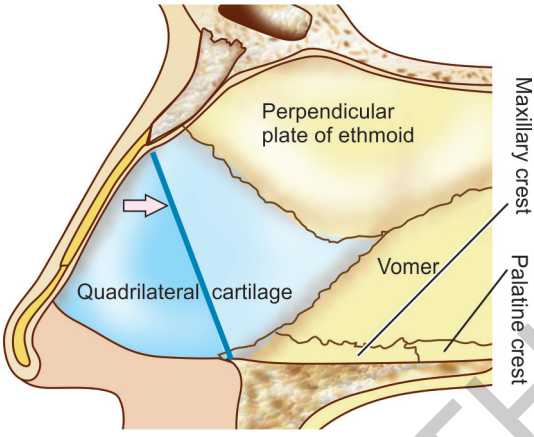

Fig. 3.4: The nasal septum. The arrow points to the Cottle's line

septum is called a deviation or deflection. The deviations may be 'C' shaped, i.e. confined to one side. Or, they may be 'S' shaped, i.e. may involve both sides. A buckling of the cartilaginous septum at its junction with the maxillary and the palatine crests is a dislocation *(Fig. 3.5)*. A sharp projection of the cartilage or the bone is appropriately termed a spur. Very frequently, the patients see their grossly deviated septum in a mirror and imagine it to be a growth. In the general population, two out of every three persons have some degree of bent septum. Only when such bends produce any symptom, do they need surgical treatment. Otherwise, they are best left alone.

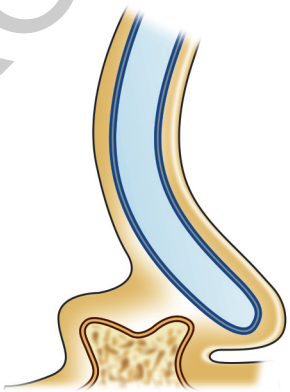

Fig. 3.5: Caudal dislocation of the nasal septum

There are three scroll like bony projections in each lateral wall. These are called turbinates. The turbinates are lined by ciliated columnar epithelium (respiratory type of mucosa). The word 'turbinate' indicates bare bone. A turbinate clothed with mucosa is called a 'concha'. Each such concha encloses a recess, beneath it, called the meatus (pleural: meati or, meatuses). There are three such meati, respectively called the superior, the middle and the inferior. The area above the superior concha is called the sphenoethmoidal recess, because of its situation. The floor of the nasal cavity is formed by the hard and the soft palates and is horizontal.

A deviation of the septum on one side, obviously results in a roominess of the opposite nasal cavity. Hence, the air conditioning efficiency will go down,

JAYPEE BROTHERS

due to reduced area of air contact with the mucosa. To prevent this from happening, the conchae of the roomy nasal cavity may undergo enlargement. This is called compensatory hypertrophy.

An imaginary vertical line can be drawn passing from the anterior nasal spine to the tip of the nasal process of the frontal bone. This line is called 'Cottle's line' *(Fig. 3.4)*. Septal deviations are classified into anterior and posterior deviations, with reference to this line. Septoplasty is necessary for correcting an anterior deviation, while a submucous resection must be employed for correcting a posterior deflection.

The nasal septum and the lateral walls are richly supplied by blood vessels and nerves. The anteroinferior part of the septum deserves special mention. This area is called the Little's area. Several branches of the external carotid system anastomose here. This anastomosis is called Kiesselbach's plexus *(Fig. 3.6)*. Because of this rich blood supply, even a minor trauma to the nose may cause profuse bleeding.

The roof of the nasal cavities is formed by the base of skull. Anteriorly, the perforated cribriform plate allows the passage of the olfactory nerve. In infants, a defect in the cribriform plate area, may lead to a herniation of the dura and the brain tissue. When only the dura herniates, the condition is called meningocele. When such a dural sac contains brain matter also, it is termed meningoencephalocele. An unsuspecting doctor may miss such a serious condition and may falsely presume it to be a nasal polyp.

The nose serves as a conduit for the respired air. The vibrissae filter the coarse particles in the inspired air. The mucus traps finer particles. The rich blood supply acts like a car radiator and effectively approximates the temperature of the inspired air to that of the body and thus protects the lungs from extremes of cold and heat. In addition, the air is humidified. Thus, the nose functions as an excellent air conditioner. And, this machine is the best in the world. It does its job within a space of four inches!

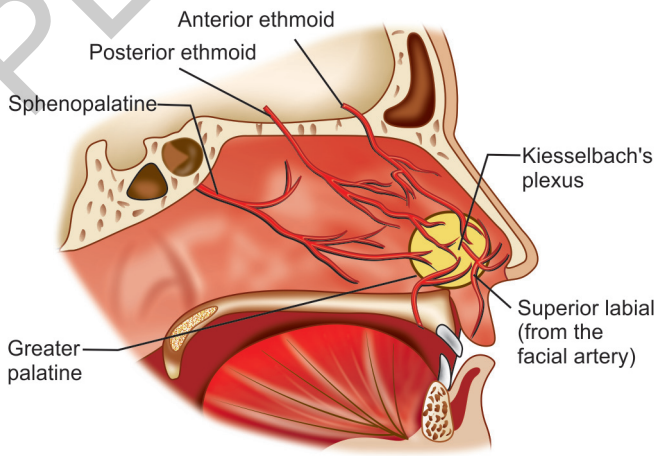

Fig. 3.6: Arteries which supply the nasal septum

JAYPEE BROTHERS

An additional job done by the nose is the sensation of smell. The relevant olfactory epithelium is situated high up on the septum and on the adjoining lateral wall. The olfactory nerve in the anterior cranial fossa connects to this special epithelium through the cribriform plate. Odorous substances in the inspired air must reach this olfactory area for effective smell sensation. Any obstruction to the airflow due to a deflected nasal septum or a polyp may result in reduced smell sensation (hyposmia). A total loss of smell (anosmia) may occur in head injuries due to disruption of the nerves. The odoriferous substances must dissolve in the mucosal discharge to elicit a proper chemical response. In dry weather conditions and in atrophic rhinitis, there is paucity of moisture within the nasal cavity. Hence, there is bound to be hyposmia or anosmia.

Around the nose, there are several air containing cavities, called the paranasal sinuses. On the cheek, inferior to the orbit, the maxillary sinuses are situated. In between the orbits, the ethmoidal sinuses are present. On the forehead, the frontal sinuses are present. Posteriorly, in continuation with the posterior group of the ethmoidal cells, the sphenoidal sinus is present. All the paranasal sinuses drain into the middle meatus. The exceptions are the posterior ethmoidal cells and the sphenoid sinus. The posterior ethmoidal cells drain into the superior meatus. The sphenoid sinus drains into the sphenoethmoidal recess or alternately may drain through the posterior ethmoidal cells.

The lacrimal glands, one on each side, are situated in the superolateral part of the orbital cavity. The lacrimal secretion (the tear fluid) lubricates the cornea and then collects in the lacrimal sac, situated in the medial part of the orbit. This lacrimal sac is separated from the nasal cavity, by the agger nasi cells. The lacrimal sac narrows down to form the lacrimal duct, which traverses inferiorly and opens into the inferior meatus of the nose.

Facial clefts deserve particular mention, because a majority of them can be corrected surgically. Examples are cleft lip and cleft palate. When you see a cleft lip, you must deliberately look for a cleft palate. A cleft palate may lead to a serous otitis media. Hence, in a case of cleft palate. You should never forget to look at the ear also.

The anterior nasal opening in the bony skull is called the pyriform aperture. The posterior nasal aperture is called the choana (pleural: choanae). Occasionally, the nasal cavities may not develop fully and the posterior nasal aperture might be atretic. This condition is called 'choanal atresia'. It can be unilateral or bilateral. A bilateral choanal atresia leads to a total airway block. The newborn simply do not know that they can open their mouth and breathe. This ignorance on their part is termed 'obligatory nasal breathing'. Hence, *bilateral* choanal atresia in a newborn presents with stridor and dyspnea. It is an emergency and the child may even die. But, when the condition is properly recognized, simple introduction of a pharyngeal airway will save the baby's life. A *unilateral* choanal atresia may not be recognized at birth, because it does not produce any respiratory difficulty. However, it may manifest later, usually by 4 or 5 years of age, as a unilateral nasal block or as a unilateral nasal discharge.

JAYPEE BROTHERS

A nasal airway block due to choanal atresia can be easily recognized by a test called 'cold spatula test'. In this test a mirror or a polished tongue depressor is held below the anterior nasal apertures. Misting indicates that the nasal airway of that side is patent *(Please see page 78)*. However, quite obviously, a partial choanal atresia will still allow some air to pass through. Hence, a partial atresia (also known as choanal stenosis) will be missed by this test.

Another ready and inexpensive method of identifying choanal atresia is passing a catheter through the nasal cavity and *looking through the mouth for its emergence behind the palate*. Liberal lubrication of the catheter with 5% xylocaine jelly helps you in this procedure. In a neonate, a catheter with a minimum size of 10 FG must be employed for this test, because catheters of less size may easily pass through a partial choanal atresia and give a false impression of patency. Detection of choanal atresia is important, because it may alert us to the possibility of certain other coexisting conditions, for example, the CHARGE association (*C*oloboma, *H*eart defects, *A*tresia of the choana, *R*etardation of growth, *G*enital and urinary abnormalities and *E*sophageal atresia). A choanal atresia can also be detected by doing a contrast X-ray or a CT scan *(see Fig. 7.30)*.

Very rarely, you may come across a newborn child with respiratory difficulty, where the nasal cavities would not allow a catheter to pass through. This will lead you to make a diagnosis of choanal atresia. However, if you were careful, you would sometimes notice that the obstruction had occurred in the *initial* few centimeters. Here, it would be the anterior bony aperture of the nose, which is stenosed. This condition is called Pyriform aperture stenosis. However it is very rare. Also, many children quickly grow out of it, and the breathing difficulty resolves before two years of age *(see Fig. 7.31)*. Recognition of this condition assumes importance, because it might be associated with serious anomalies of the brain and face. One such serious anomaly is called Holoprosencephaly. In this condition, the normally paired prosencephalon (the fore brain of the developing embryo) fails to develop into two hemispheres. This failure usually occurs by the fifth and the sixth weeks of embryonic development. This condition can be mild or severe. In most cases of holoprosencephaly, the malformations are so severe that the babies die before birth. In less severe cases, babies are born with normal or near-normal brain development and some facial deformities. Common facial deformities involve the eyes, nose, and upper lip. A surface marker of this serious condition of holoprosencephaly is a single mega incisor tooth. Hence, once you detect a pyriform aperture stenosis in an infant, you have to look for a single mega incisor in an X-ray of the skull.

Common sensation within the nose is subserved by the V cranial nerve. The autonomic nervous system plays an important role in the air conditioning. The sympathetics maintain a constant tonic vasoconstrictor state. The parasympathetics cause vasodilatation and also supply the glands. A delicate balance is maintained between the two systems, always.

The sympathetic fibers arise in the superior cervical sympathetic ganglion and pass around the internal carotid artery as the carotid plexus. Ultimately,

JAYPEE BROTHERS

this carotid plexus gives rise to the deep petrosal nerve. This deep petrosal nerve joins with the greater superficial petrosal nerve to form the vidian nerve. This vidian nerve passes through the pterygoid canal and enters the pterygopalatine fossa and then reaches the sphenopalatine ganglion. Inside this ganglion, it does not relay and is distributed directly to the entire nose. A sectioning of the cervical sympathetics causes vasodilatation and a stuffy nose.

The parasympathetics are derived from the nervus intermedius and pass through the greater superficial petrosal nerve. We have already seen that the greater superficial petrosal nerve joins with the deep petrosal nerve to form the vidian nerve and how it reaches the sphenopalatine ganglion. The difference between the sympathetic and the parasympathetic fibers is that the parasympathetic fibers relay in that ganglion.

Thus, the vidian nerve comprises of both sympathetic and parasympathetic fibers. However, the parasympathetics predominate. Hence, a section of the vidian nerve results in vasoconstriction and dimunition of nasal secretions. Hence, a few decades ago, in patients, with incapacitating nasal watering (allergic rhinitis), vidian neurectomy used to be frequently done. Nowadays, it is rarely done, because after a few years of relief, the rhinorrhea had been found to return.

Lymphatic drainage: The submandibular lymph nodes collect the lymph from the external nose and anterior part of the nasal cavity. The rest of the nasal cavity drains into the other upper deep cervical nodes, either directly or through the retropharyngeal lymph nodes. Thus, the first station in a maxillary sinus malignancy could well be the retropharyngeal nodes within the space of Gillette.

SYMPTOMS IN NASAL DISEASES

Eliciting history is an art. This art can be cultivated. As you listen to the patient, you must keep on thinking about the diseases that can produce the particular complaints. Your further questioning must be directed towards confirming a particular diagnosis. Many times, a careful history can exclude other possible diagnoses.

When a patient says that he has itching of nose, sneezing and watery nasal discharge, on exposure to dust, perfumes, incense sticks or frying fumes, you have to immediately think of inhalational allergy. And, you have to ask whether the nasal symptoms recur each time he is exposed to the same allergen. Additionally, you have to ask whether there is associated wheezing or swelling of lips and eyes. Sneezing and nasal discharge usually occur during episodes of cold. A watery nasal discharge of short duration (about three days) may indicate a viral rhinitis. In allergic rhinitis, the duration will be longer.

Bacterial rhinosinusitis might show only watery discharge, during the initial days. When infection supervenes, the watery nasal discharge turns thick and viscid. It may also turn yellowish. When the air is dry, the discharge forms crusts. In atrophic rhinitis, the crusts are usually green and have a characteristic

JAYPEE BROTHERS

bad smell. Imagine the plight of a young woman, condemned to live constantly in a foul effluvium. But, mercifully, the nasal discharge in atrophic rhinitis dries up into crusts and covers the smell receptors, leading to anosmia. Thus, the patient herself is spared the ordeal of cacosmia. Hence, this condition is aptly described as *merciful anosmia*.

When a patient complains of a nasal block, you have to first think of common cold. However, had the block been continuously present, you will have to start thinking of a mass. It might be an allergic polyp, a rhinosporidium, a juvenile nasopharyngeal angiofibroma, or even a malignancy. You must ask whether there had been any bleeding. Frank bleeding indicates malignancy, rhinosporidium, angiofibroma, trauma or systemic hypertension. Occasionally, bleeding might result from infection and ulceration. But in such cases, there will only be blood stained discharge and not frank bleeding. All these while, do not forget that nose picking is a common cause of nasal bleeding.

A nasal block, regardless of the cause, will impede streamlined air flow through the nose. Frequently, a nasal block leads to mouth breathing. When airflow is obstructed, eddy currents will form within the nasal cavity and ultimately result in snoring.

Headache is a common symptom. Veritably, no one has immunity from it. A list of conditions producing headache is quite long. Common detectable causes of headache include refractive errors, cervical spondylosis, various neuralgias and sinusitis. The site, onset, nature, duration and associated features give a clue to the cause of headache. A throbbing or a pulsatile headache will most certainly have a vascular basis, e.g. migraine. Similarly, a headache precipitated by long hours of reading or television watching indicate refractive errors. Some causes are quite sinister, namely, an extradural hemorrhage, a subdural hemorrhage or even a brain tumor. Hence, a complaint of headache must be earnestly investigated. However, be warned that you will be able to detect a cause in only ten percent of patients.

Headache due to sinusitis will usually be a dull ache. Sometimes, it may just be a heaviness of head. In frontal sinusitis, the headache will characteristically be severe in the mornings and get better as the day progresses. Several bankers, whose working day coincides with this timing, may seek your consultation for headache of this nature. Hence, it is also described as the Banker's headache. A headache of sphenoidal sinus origin might manifest in the vertex of the head or the bridge of the nose *(Fig. 3.7)*. However, much reliance cannot be placed on the site of headache.

When a patient comes to you, and, if you are not able to detect a cause, do not jump to an immediate diagnosis of neurosis or malingering. Always remember that no patient will take the trouble of consulting you unless they really feel that they have a problem. The problem might have an organic basis and you may be able to detect it. Or, it may have a non-organic basis. This non-organic group also does suffer from headache. And, these patients do require treatment, but by a different specialist! Try to probe gently for further details or better still seek the opinion of a neurologist or a psychiatrist.

JAYPEE BROTHERS

Checklist of symptoms in nasal diseases

Major symptoms

External deformity of the nose (swelling)
Nasal block (snoring)
Nasal discharge (mucoid, purulent, blood stained or frank bleeding)
Headache
Itching, sneezing, watery discharge, red eyes, watering from the eyes
Hyposmia, anosmia, cacosmia, parosmia

Minor symptoms

Ear block
Epiphora
Associated symptoms of GERD
Altered voice

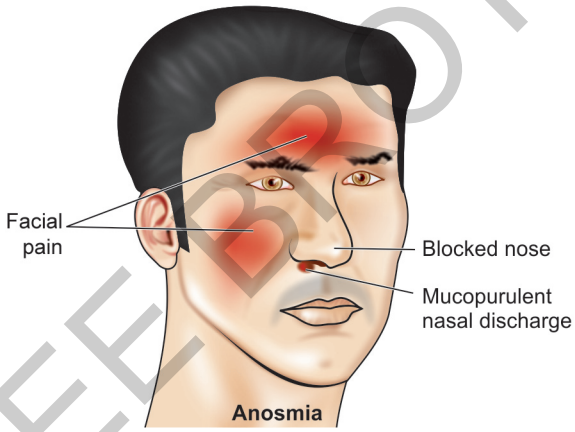

Fig. 3.7: Clinical features of acute sinusitis

Ear block is a common accompaniment of cold and it occurs due to blocking of the pharyngo- tympanic tube. It is usually transient. You must develop the habit of examining adjacent structures also, in every patient.

When we speak, the air contained within the nose and the paranasal sinuses resonates. This resonance adds additional tones, whose frequencies are arithmetic multiples of the fundamental frequency of our voice. Such an addition makes our voice 'full.' This is called 'timbre.' Whenever there is a fluid in the nasal cavity or in the sinuses, such resonance does not occur. This results in a 'flat' voice. A mass in the nose and in the nasopharynx viz a growth, a polyp or an enlarged adenoids also has the same effect. Such a voice is called rhinolalia clausa (clausa means closure). A palatal perforation, a cleft palate or a palatal paralysis may lead to an escape of air through the nose and result in a voice called rhinolalia aperta (aperture means a hole).

JAYPEE BROTHERS

Sometimes, a bony palatal cleft may be hidden from ready view, because it is clothed over by mucosa. This is called submucous cleft palate. A bifid uvula, a midline pale raphe on the soft palate and a palpable notching in the midline of the posterior margin of the hard palate will indicate a submucosal cleft. In such a child, the adenoids may enlarge in a compensatory fashion and prevent nasal regurgitation. Removal of a grossly enlarged adenoid in children with submucosal cleft may result in a temporary nasal regurgitation and in rhinolalia aperta. When these two occur after an adenoidectomy, both improve with time. However, it would be wise to withhold adenoidectomy in patients with submucous cleft palate.

A nasal block may lead to mouth breathing and snoring. When snoring is not associated with alveolar hypoventilation (as evidenced by oxygen desaturation by pulse oximetry), it is called 'primary snoring.' The harms of such primary snoring are predominantly social and not medical. It is the mildest form of sleep disorder breathing (SDB). However, snoring may not always be innocuous. When snoring is accompanied by cessation of breathing (apneic pauses), it is called obstructive sleep apnea (OSA). During the apneic periods, oxygen desaturation, hypercapnea, disturbances of cardiac rhythm, pulmonary hypertension, etc. may occur. Frequent disruption of sleep also occurs, leading to excessive daytime sleepiness. This stage is called obstructive sleep apnea syndrome—OSAS *(Fig. 3.8)*. Daytime sleepiness and the consequent cognitive impairment are serious consequences and are implicated in several automobile accidents. A common cause of OSA in adults is obesity, whereas in children, it is adenotonsillar enlargement. Several medical conditions of the lung and the heart also may cause snoring and OSA. A proper examination and treatment of a patient with OSA is a multidisciplinary task.

Nasal regurgitation: When this is present, you have to carefully examine the palate for velopharyngeal sphincter insufficiency. Some of the causes like palatal paralysis, perforation and cleft palate can be easily seen. Sometimes, a cleft of the palate may be submucosal and may not be readily apparent.

Watering from the eyes: In some patients with nasal allergy, excessive lacrimal secretion might occur. When there is obstruction to the nasolacrimal duct, due to a large mass in the nose or due to anterior nasal packing, the tears cannot

PS	UARS (in children)	OH	OSA	OSAS
Snoring not associated with daytime symptoms	Increased UAR not sufficient to cause symptoms like EDS	Increased UAR sufficient to cause increased $PaCO_2$ or decreased SaO_2	Upper airway obstruction leading to manifest apnea	Same as OSA with daytime somnolence (EDS)



Fig. 3.8: Sleep disordered breathing is a continuous spectrum. As the upper airway resistance (UAR) increases, the severity of symptoms, signs and complications also increase

JAYPEE BROTHERS

drain freely into the nose. Hence, they overflow down the checks. This is called epiphora. When you find such epiphora, your examination must focus on the inferior meatus.

Beware: Epiphora might occur in patients with facial nerve paralysis, also. In facial nerve paralysis, the punctum in the lower eye lid gets everted. Hence, the tears overflow down the cheeks.

Gastroesophageal reflux disease (GERD): In this condition, the acidic gastric contents reflux back into the esophagus and the throat, resulting in retrosternal burning, hypopharyngitis, laryngitis and sinusitis. Epigastric pain, flatulence and belching also indicate GERD.

PHYSICAL EXAMINATION OF THE NOSE

You must sequentially examine the external contour of the nose, the septum, the lateral walls and contents of the cavity. When you look at the nasal cavities from the front, it is called anterior rhinoscopy. In adults, a nasal speculum is used to visualize the interior. The Thudicuhm's speculum is ideal for this purpose. Xylometazoline or oxymetazoline nasal drops constrict the mucosa and afford better vision. Hence, they may be used occasionally. Children are apprehensive of the metallic nasal speculum. Hence, in a child, you may tilt the nasal tip with your bare thumb and get a reasonable view of the interior. This technique is useful in adults also *(Fig. 3.9)*. A meaningful examination of the nose must include the nasopharynx. This can be achieved by a postnasal mirror examination.

The External Nose

First, look at the general contour of the nose and the dorsum of the nose *(Fig. 3.10)*. In children with adenoidal hypertrophy, the nasal passage is



Fig. 3.9: Lifting the tip of the nose with the thumb. In this patient, on either side of the columella inferiorly, a caudal dislocation is seen bilaterally

JAYPEE BROTHERS

How to hold a Thudichum's nasal speculum

Here is a simple way to learn the use of Thudichum's speculum. Do you remember your childhood play—cops and robbers! Make a revolver out of your left hand, i.e. index finger pointing to the front, thumb up and the other three fingers folded back. Point this revolver towards the nose of the patient. Hang the speculum on the pointing index finger at a place just in front of the first knuckle, with the blades of the speculum pointing towards you. Flex both the knuckles of the same finger, i.e. crook it towards you. As a result, the blades will turn towards the patient. Keep your left thumb over the bend of the hanging speculum so as to steady the same. Now, let release the left middle finger and wrap it around the hanging arms of the speculum. At this stage, you will find that your middle and ring fingers straddle either side of the freely hanging springy arms of the speculum *(Fig. 3.11)*. These wrapping fingers control the springiness of the speculum and thus avoid excessive pressure and consequent discomfort to the patient.

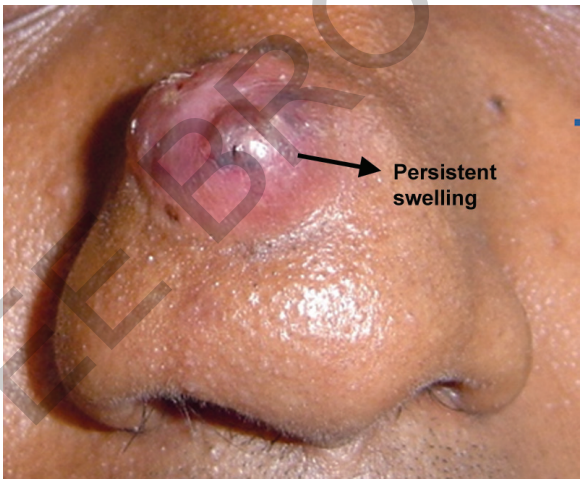

Fig. 3.10: Adenoma of the nose (Reprinted with permission from Chennai Clinical Centres)

blocked and air stream does not pass through the nose. Hence, the nose may not develop well and appear small as if someone has pinched the nose. This is described as 'pinched' nose.

The nose is a very vascular organ. Hence, even trivial injuries result in a lot of bleeding. If the injury is severe enough, it may cause a nasal bone fracture. Such fractures exhibit crepitus and sharp tenderness. The fracture fragments may or may not be displaced. When the fracture fragments get displaced, the dorsum would appear obviously crooked. But, on several occasions, subcutaneous hematoma and edema will mask the fracture. The edema may extend to the orbits also.

JAYPEE BROTHERS

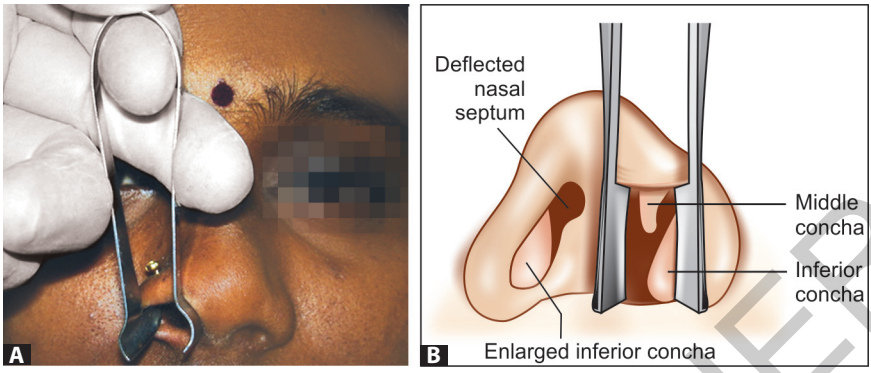

Fig. 3.11: Method of holding the Thudichum's nasal speculum and the structures seen

A fracture of the nose may result in a hematoma, in and around the nose. In a septal hematoma, the blood collects in the subperichondrial plane and can be seen as a bulge in both nasal cavities *(Fig. 3.12)*.

The smell can be tested in individual nasal cavities, by utilizing lemon, coffee and asafoetida (Asafoetida is a gum of vegetable origin, commonly used in Indian cuisine). However, smell is rarely tested clinically, because of the practical difficulty in *objectively* assessing the responses.

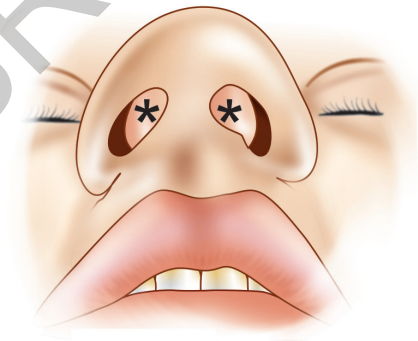

Fig. 3.12: Septal hematoma—septal abscess. Bulging is present on both sides of the septum

The Septum

The septum is rarely straight. In your case sheet, please record any deviations or spur when present. Learn to draw simple diagrams quickly *(Fig. 3.13)*.

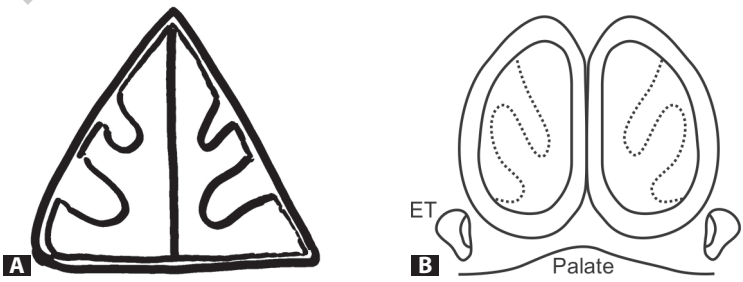

Fig. 3.13: Templates for recording the clinical findings in anterior rhinoscopy and in postnasal examination

JAYPEE BROTHERS

detailed information of otorhinolaryngology books, visit our website www.jaypeebrothers.com, for detailed information of otorhinolaryngology books, visit our we

CLINICAL ENT MADE EASY®

A Guide to Clinical Examination

During the quarter century of his teaching career, the author had been observing successive batches of students committing the same slips over and over again. This book addresses such mistakes. The language is deliberately kept simple. The diagrams are even simpler. Written mainly with the graduate students in mind, this book will prove to be of immense value to regular medical practitioners also. This book presents a structured approach and contains:

- Points to remember while taking history and examining ENT patients
- Template case sheets, common X-rays, instruments and surgeries
- Questions that the examiners usually ask and the answers to such questions
- University theory questions, multiple choice questions (MCQs) and extra information are given in the associated website
- This book contains much more than what an intelligent medical student needs to know and what a successful practitioner would ever require.

Who should read this book?

Unlike didactic textbooks, it reads like a novel. An industrious student can start and complete this book in one stretch. When read at the beginning of the course, it will serve as an introduction to this field. When the same book is read at examination time, it will help him to confidently face the examination. Much later, when the student becomes a doctor, he will find valuable tips to deliver better care to his patients. Thus, it is a single source of valuable information, rendered in a lucid style.

D Balakrishnan BSc MBBS MS DLO PhD obtained his BSc degree in 1971 from Annamalai University, Chidambaram, Tamil Nadu, India with University 1st rank. He received his entire medical education from Madras Medical College, Chennai, Tamil Nadu and got an MS in the Otolaryngology branch in 1981. Later, he became a teacher in his own alma mater. In 1998, he was a Visiting Fellow in Sophia Children's Hospital, Erasmus University, Rotterdam, Netherlands. In 2000, he was amongst the faculty of Second International Otolaryngology Congress of SAARC, Kathmandu, Nepal. He is one of the founders of the Association of Pediatric Otolaryngologists of India and is the national secretary of that association. At present, he is the Dean of Medical Research in SRM University, Chennai. His research interests include Pediatric ENT, Sleep Studies and Snoring. He also studies environmental issues such as silicosis, perchlorate contamination and water recycling.



Shelving Recommendation
OTORHINOLARYNGOLOGY

ISBN 978-93-5025-084-6

Available at all medical book stores
or buy directly from Jaypee Brothers through online shopping
at www.jaypeebrothers.com

JAYPEE BROTHERS
Medical Publishers (P) Ltd.
www.jaypeebrothers.com