Reproductive Medicine

Challenges, Solutions and Breakthroughs

Editors
Sulbha Arora
Rubina Merchant
Gautam N Allahbadia

Foreword
Hananel EG Holzer

JAYPEE

Contents

Section 1 **GYNECOLOGICAL ENDOSCOPY**

1. Philosophy of Endoscopy in Infertility **3**
Vivek Salunke, Rajesh V Darade

Ancient Indian Perspective *3*
History of Endoscopy in Infertility *4*
Endometriosis *4*
Endoscopy in Infertility *4*
Endoscopic Tubal Surgery *4*
Laparoscopic Myomectomy *5*
Endoscopy in Endometriosis *5*

2. Hysteroscopic Markers of Genital Tuberculosis **7**
Sunita Tandulwadkar, Bhavana Agarwal Mittal

The Problem of Tuberculosis *7*
Genital Tuberculosis *7*
Pathogenesis *8*
Endometrial Tuberculosis *8*
Clinical Presentation *8*
Diagnosis *8*
Findings *9*
Recent Advances *11*

3. Hysteroscopic Intratubal Sterilization **13**
Hervé Fernandez, Anne-Claire Donnadieu, Claire Basille, Xavier Deffieux, Estelle Feyereisen, Amelie Gervaise

Instrumentation and Technique *13*
Premedication *14*
Problem Solving and Troubleshooting *15*
Efficacy of Sterilization *16*
X-ray Abdomen *16*
Hysterosalpingography *17*
Transvaginal Ultrasound *17*
Combined Hysteroscopic Sterilization and Operative Hysteroscopy *18*
Overview of Technologies and Technical Characteristics *18*

4. Ovarian Drilling by Transvaginal Fertiloscopy for the Treatment of Polycystic Ovary Syndrome **22**
Hervé Fernandez, Amélie Gervaise, René Frydman

Patients *23*
The Procedure *24*

5. Laparoscopic Ovarian Cauterization: How Many Punctures are Optimal? **29**
Sandeep Talwar

Endocrine Changes following LEOS *29*
Ovarian Stromal Blood Flow Changes after LEOS in Women with PCOS *30*
Laparoscopic Ovarian Drilling *30*
Complications of LEOS *31*
Results after Surgery *31*
LEOS versus Gonadotropins *31*
Cost of LEOS versus Gonadotropins *31*
Recent Advances *31*
LASER versus Ovarian Surgery *31*

6. Laparoscopic Recanalization after Tubal Sterilization **33**
Alain Audebert

Reasons for Reversal Demand *33*
Method of Tubal Sterilization *34*
Classical Therapeutic Tools *35*

Laparoscopic Tubal Recanalization *35*
Practical Management *36*

7. Does Surgery for Endometriosis Improve the ART Outcomes? 38
Lakshmi Ravikanti, Ved Prakash Singh
How much do We Know about Endometriosis? *38*
Is the IVF Outcome affected in Endometriosis? *38*
How does Endometriosis affect the Outcome of IVF? *38*
Management Options in Endometriosis-related Infertility *39*
Does Endometrioma affect IVF? *41*
Endometrioma: Excision or Ablation *41*
Prolonged GnRH Agonist Therapy Prior to an IVF Cycle in Endometriosis Patients *41*
Fertility Outcome after Surgery for Grade III / IV Endometriosis in our Practice *41*
Additional Procedures Required and Complications *41*
Keys to a Successful Endometriosis Unit *41*

8. Radical Excision of Endometriosis Improves the Fertility Outcome 43
Nutan Jain, Shweta Goel, Anjali Gupta
Radical Excision of Grade I Endometriosis *43*
Deep Rectovaginal Endometriosis *45*
Treatment Options *47*

9. Laparoscopic Myomectomy: Is it Worth it? 56
Yuval Kaufman, Arie Lissak

10. Laparoscopic Hysterectomy in the Frozen Pelvis 63
Paul PG, Tony Thomas, Satyen Kasabwala
Causes for Frozen Pelvis *63*
Patient Evaluation *63*
Preparation for Surgery *64*
Surgical Technique *64*

11. Complications of Laparoscopic Hysterectomy 69
Edi Vaisbuch, Zion Hagay
Options of Laparoscopic Hysterectomy *69*
Complications of Laparoscopic Hysterectomy *70*
The Evolution of Laparoscopic Hysterectomy at Kaplan Medical Center *72*
Robot-assisted Laparoscopic Hysterectomy *73*

12. Making Hysteroscopic Surgery Safer 75
Abraham Golan, Shimon Ginath
History *75*
Hysteroscopic Technique *75*
Clinical Use and Recent Advances *79*
Complications of Hysteroscopy *85*

13. Resection of the Uterine Septum or *In Vitro* Fertilization: What Comes First? 89
Murat Berkkanoglu, Kemal Ozgur
Clinical Discussion *89*
Treatment *90*
Indications *90*

Section 2 **OVARIAN STIMULATION PROTOCOLS**

14. Gonadotropin Preparations in Infertility Treatment 95
Mybodi Karimzadeh, Robab Taheripanah, Sedighe Ghandi, M Eftekhar
Pituitary Gonadotropins *96*
Human Menopausal Gonadotropin (hMG) *98*
Recombinant Human FSH (rhFSH) Preparation *99*
Is There a Difference in Safety? *100*
Ovarian Induction without IVF *101*
Ovarian Stimulation for IVF *101*
Corifollitropin-alfa *101*
Efficacy *101*
Recombinant Human LH (rhLH) *102*
Human Chorionic Gonadotropin (hCG) *102*
Future Directions *103*

15. The Choice of Starting Dose in *In Vitro* Fertilization 107
Aygul Demirol, Suleyman Guven
Follicle Stimulating Hormone and Folliculogenesis *107*
Choice of Gonadotropins for Superovulation *108*
Starting Dose of FSH for COH *108*

16. Evaluation and Treatment of the Female Partner before ART 114
Manisha Takhtani, Akanksha Allahbadia, Gautam N Allahbadia
Evaluation of the Female Partner *114*
Cervical Factors *116*
Peritoneal Factors *116*

17. Aromatase Inhibitors for Ovulation Induction 119
Mandakini Parihar, Meenakshi Bharath
Rationale for the Use of Aromatase Inhibitors in Anovulatory Women *119*

18. Intrafollicular Consequences of the Use of Aromatase Inhibitors in ART 123
Maruthini D, Manisha Palep Singh
Human Aromatase Activity *123*
Aromatase Activity in the Ovaries *123*
Clinical Applications of Aromatase Inhibitors *125*
Aromatase Inhibitors in Ovulatory Infertility/Superovulation *125*

19. Addition of Luteinizing Hormone in Controlled Ovarian Stimulation Protocols using Recombinant FSH 128
Maruthini D, Manisha Palep Singh
Physiological Role of LH in Folliculogenesis *128*
Gonadotropin Preparations *128*
Use of Gonadotropins in Ovarian Stimulation *129*
LH Threshold and Ceiling Activity *129*
Controlled Ovarian Stimulation Protocols *129*
Addition of LH to rFSH *130*
COH in Polycystic Ovary Syndrome *130*

20. Gonadotropin-releasing Hormone Antagonists: An Unfulfilled Expectation? 133
Kalyani Patel, Gautam N Allahbadia, Akanksha Allahbadia
Mode of Action *133*
GnRH Antagonists for *In Vitro* Fertilization *134*
GnRH Antagonists and Pregnancy Outcomes *134*
Need for LH Supplementation *134*
GnRH Antagonists in Poor Responders *135*
Benefits of the Use of GnRH Antagonists for IVF *135*

21. Rationale for the Use of Insulin Sensitizing Drugs in Polycystic Ovary Syndrome 138
Meena Chimote, Natachandra Chimote
Insulin Sensitizers *138*
Metformin *139*
Thiazolidinediones *139*
α-Glucosidase Inhibitors (Acarbose) *140*
D-Chiro Inositol (DCI) *140*
Herbal Medicine (Hyponidd) Containing Acarbose and DCI *141*

22. Does Natural Cycle IVF or Minimal Stimulation have a Role in Clinical Practice Today? 145
Daniel Humberto Méndez Lozano, René Frydman
Proposed Approaches *146*
Natural Cycle IVF with Controlled LH Surge Ovulation *147*

23. Minimal Monitoring of Ovarian Stimulation: Is it Safe? 149
Padma Rekha Jirge
Aims of Monitoring *149*
Monofollicular Ovulation *150*
Ovarian Stimulation for Intrauterine Insemination *150*
Controlled Ovarian Hyperstimulation for IVF/ICSI *150*
Proposed Monitoring of Ovarian Stimulation *150*

Section 3 CONTEMPORARY CLINICAL MANAGEMENT

24. Do We Need HSG in the Era of 3D/4D Ultrasonography? 155
Madhusree Ghosh, Shelly Tse, Kamal Ojha

Hysterosalpingography (HSG) ***156***
Three-dimensional Ultrasonography (3D USG) ***156***
Hysterosalpingo-contrast-sonography (HyCoSy) ***156***
Three-dimensional Coded Contrast Imaging (3D CCI) During HyCoSy ***158***
Laparoscopy ***159***
Fertiloscopy ***159***

25. How to Approach Submucous Myomas in Infertile Women? 161
Sunita Tandulwadkar, Anil Chittake, Vineeta Kharb

Impact of Fibroids on Assisted Conception ***162***
Preoperative Diagnostic Assessment ***162***
Surgical Technique ***164***
Postoperative Care and Follow-up ***167***
Gynecare Versapoint ***167***

26. Alternatives to Myomectomy 171
Roy Mashiach

Medical Therapy ***172***
Myolysis ***175***

27. Diagnosis of Genital Tuberculosis: Newer Techniques for an Old Disease 181
Lakhbir Dhaliwal, Shalini Gainder

Endometrial Biopsy ***181***
Laboratory Evaluation ***182***
Direct Approach ***182***
Serological Diagnosis of Tuberculosis ***184***
Indirect Approach ***186***

28. Management of Polycystic Ovary Syndrome 188
Kamala Selvaraj, Priya Selvaraj, Deepu Rajkamal Selvaraj

Menstrual Disturbances/Disorders ***188***
Polycystic Ovary Syndrome in Adolescents ***188***
Obesity ***189***
Hirsutism ***189***
Infertility ***189***
The Impact of PCOS on ART ***190***
Surgical Management ***190***
New Trends in PCOS: *In vitro* Maturation ***191***

29. Recurrent Endometriosis: Physiopathology, Epidemiology, Prevention and Treatment 192
Céline Lefebvre Lacoeuille, Catala Laurent, Boussion F, Philippe Descamps

Physiopathology of Recurrent Endometriosis ***192***
Epidemiology of Recurrent Endometriosis ***193***
Prevention of Recurrent Endometriosis ***198***
Treatment of Recurrent Endometriosis ***201***

30. Treatment of Deep Rectovaginal Endometriosis 207
Elizabeth Ball, Charles Koh

Definition and Topography of Rectovaginal Endometriosis ***208***
Clinical Management ***212***

31. Management Practices for Endometriotic Cysts Associated with Infertility 219
Alain Audebert

Epidemiology of Ovarian Endometriomas ***220***
Ovarian Endometriomas and Infertility ***220***
Therapeutic Tools ***220***
In Vitro Fertilization ***223***
Role of Surgery, IVF and Ultrasound-guided Aspiration ***224***
Role of Abstention ***224***

32. Management of Mild to Moderate Endometriosis in the Infertile Patient 227
Surveen Ghumman

Assessment of the Disease ***227***
Prognostic Factors ***227***
Expectant Management ***228***
Surgical Treatment of Early Stage Endometriosis ***228***
Conservative Surgery ***228***

Peritoneal Implants *228*
Outcome *228*
Ovarian Suppression *228*
Management of Endometriotic Cysts Associated with Infertility *229*
Treatment *229*
Rectovaginal Endometriosis in an Infertile Patient *230*
Frozen Pelvis with Extensive Endometriosis *231*
Recurrence—Repeat Surgery vs IVF *231*
ART in Endometriosis *231*

33. Hydrosalpinx and ART: Options and Rationale for Treatment 235
Daniel B Williams
Non-surgical Evaluation of the Fallopian Tubes *235*
Hydrosalpinx and Fertility *236*
Surgical Management of Hydrosalpinges *237*
Alternative Management of Hydrosalpinges *237*
Laparoscopic Management of Tubal Pathology *237*
Distal Tubal Disease *238*

34. In Women with Unexplained Infertility, should IVF be the First or Last Treatment Option? 240
Surveen Ghumman
Diagnosis *240*
Controversies in Diagnosis *241*
Evaluation of Fertilizing Capacity of Sperm *241*
Tests for Ovarian Reserve *241*
Uterine Receptivity *241*
Management *241*
Counseling *242*
COH and IUI versus IVF *243*
IVF versus ICSI *244*

35. Management of the Obese Infertile Patient 248
Kulvinder Kochar Kaur, Gautam N Allahbadia, Mandeep Singh
Mechanisms by which Obesity may Affect Fertility in Women *249*
Obesity as a Condition of Sex Hormone Imbalance in Women *249*
The Obesity-PCOS Link: Pathophysiological Aspects *250*
Management *252*
Treatment *252*
Case Report *254*
Potential Role of Endocannabinoid System *254*
Role of Other Adipokines *255*
Role of Topiramate *255*

Section 4 **THE ENDOMETRIUM**

36. What can Clinicians do to Improve Implantation? 261
Arpita Ray, Amit Shah, Anil Gudi
Preconceptual Care *261*
Adjuvant Pharmaceutical Therapies *261*

37. Endometrial Receptivity in Infertility 268
Sujata Kar
The Implantation Window *268*
The Receptive Endometrium *269*
Markers of Endometrial Receptivity *269*
Growth Factors *270*
Clinical Applications *270*
Clinical Strategies to Assess Endometrial Receptivity *271*
Evaluation of Biochemical Markers *272*
β-3 Integrins *272*
Cyclin E and P_{27} *272*
The Future *273*

38. Management of a Persistently Thin Endometrium 274
Murat Berkkanoglu, Kemal Ozgur
Diagnosis *275*
Treatment *276*

Section 5 **ASSISTED REPRODUCTIVE TECHNIQUES**

39. Luteal Phase Support in Ovarian Stimulation Cycles **283**
Robab Taheripanah, Mybodi Karimzadeh

Definition ***283***
Physiology ***284***
Luteal Support Regimens ***285***
Progesterone ***285***
Human Chorionic Gonadotropin ***286***
Estrogen ***287***
GnRH Agonist (GnRH-a) ***289***
GnRH Antagonist Stimulated Cycles and the Luteal Phase ***289***
Duration of Luteal Phase Support ***290***

40. Should We Encourage Patients to Try Complementary Therapies as a Means of Improving Well-being and Fertility Success? **294**
Sandra de la Garza, Carmen Martinez Jover

The Stress of Infertility: Lack of Control ***294***
Addressing Stress and Infertility ***294***
Accompanying Program ***295***

41. Age and ART Success: Where do We Draw the Line? **297**
Neri Laufer, Avi Tsafrir

ART Success in Patients Aged 40 and Older ***298***
Predictive Factors for ART Success in AMA Patients ***299***
How Many Cycles? ***299***
When is there no Chance at All? ***299***
Where do we Draw the Line? ***299***

42. Is There an Ideal Luteal Phase Support Protocol in ART? **301**
Shevach Friedler

Methods of Luteal Phase Support ***301***
hCG Supplementation ***302***
Progesterone Supplementation ***302***
Mid-luteal Addition of Estradiol ***304***
Mid-luteal Addition of hCG in Cycles with Progesterone Supplementation ***305***
GnRH Agonist as Luteal Phase Support ***305***

43. Intracytoplasmic Sperm Injection for All? **310**
Timur Gurgan, Suleyman Guven, Aygul Demirol

ICSI versus IVF for Unexplained Total Fertilization Failure after Conventional IVF ***311***
ICSI versus IVF for Unexplained Infertility after Failed Insemination ***311***
ICSI versus IVF for Male Factor Infertility ***312***
ICSI versus IVF for Tubal Factor Infertility ***312***
ICSI versus IVF for Poor Responders ***313***
ICSI versus IVF in Patients with PCOS ***313***
ICSI versus IVF for Patients with Increased Oocyte Immaturity ***313***
ICSI for Other Indications ***313***
The Effect ICSI versus IVF on Embryo Quality ***313***
The Effect ICSI versus IVF on the Obstetric Outcome ***314***

44. Selection Criteria for Oocyte and Sperm Donors in IVF Programs **316**
Geetha Haripriya

Oocyte Donation ***316***
Sourcing Oocyte Donors ***316***
Counseling ***317***
Ideal Oocyte Donors ***317***
Screening of Donors ***317***
Consent ***318***
Compensation to Donors ***318***
Donor Anonymity ***318***
Selection Criteria for Donor Sperms ***318***

45. Did We Really Stop Performing Tubal Procedures? **320**
Kamala Selvaraj, Priya Selvaraj, Deepu Rajkamal Selvaraj

Tubal Procedure ***320***
Gamete Intrafallopian Transfer ***320***
Embryo Transfer ***321***

In Vitro Fertilization-Embryo Transfer *321*
Contrast between Tubal (GIFT) and ET (IVF-ET) Procedures *321*
Dual Procedure (Applying Tubal and ET Procedures in Combination) *321*
Results of a Retrospective Study *321*

46. Procreation Options in Human Immunodeficiency Virus-infected Patients 323
Marialuisa Partisani, Jeanine Ohl, Catherine Rongières

47. Management of Poor Ovarian Response in ART: Myths and Facts 326
Kaberi Banerjee

48. Nuances of Ultrasound-guided Embryo Transfers 332
Durga Rao
Factors Influencing Embryo Transfer Outcome *332*
Different Modes of Embryo Transfer *333*
Evidence Regarding UGET *333*
Role of Mock (Trial) Embryo Transfer *334*
Procedure of Ultrasound-guided ET *334*
Vaginal Ultrasound and ET *335*
Three-dimensional Ultrasound and ET *335*

49. Follicular Fluid Environment and ART Outcome 338
Ernesto Bosch
Synthesis of Follicular Fluid *338*
Composition of Follicular Fluid *338*
Follicular Fluid in the Natural Cycle *339*
Follicular Fluid in Ovarian Stimulation Cycles *340*
Follicular Fluid Hormonal Variations: Impact on Oocyte Quality *341*

Section 6 **THE ART LABORATORY**

50. Improving Implantation: Choosing the Right Embryo 349
Padma Rekha Jirge
Assessment of Embryo Quality: Non-invasive Methods *349*
Omics *351*
Time-lapse Imaging of Embryos (EmbryoScope) *351*
Doppler Studies *351*
Invasive Methods *351*
Predicting the Embryo Quality *351*

51. Oocyte Cryopreservation 357
Andrea Borini, Cristina Lagalla, Verinica Bianchis
Freezing Procedures *358*
Possible Damage to the Oocyte due to Cryopreservation *359*
Results with Slow Cooling *360*
Results with Vitrification *361*

52. Comparison of Two Freezing Techniques for Human Embryos: Slow Freezing and Vitrification 364
Ramadevi Papolu, Charulata Chatterjee, Adusumilli Rajyalakshmi, Jagarlamudi Vijaylakshmi
Materials and Methods *365*
Blastocyst Grading *365*
Transfer of Blastocysts and Assessment of Pregnancy *366*
Vitrification of Blastocysts *366*
Blastocyst Warming and Assessment of Survival *366*

53. The Role of Co-culture in Implantation 369
Natachandra Chimote, Meena Chimote, Nirmalendu Nath, Amiya Mukherjee
Types of Co-culture *370*
Endometrial Co-culture *370*
Blastocyst Transfer after Co-culture with Human Endometrial Epithelial Cells *371*
Blastocyst Culture after Intracytoplasmic Sperm Injection *371*
Cumulus Co-culture *372*
Experience at Our Center *372*
Establishment of Co-culture System *372*

54. Oocyte and Embryo Wastage in ART: It is in the Seed, not the Soil 377
Sujata Kar
Natural Human Reproduction *377*
Present Success of ART *378*

Enormous Biological Loss: Both in Nature and Assisted Reproduction *378*
Embryo and Oocyte Wastage *378*
Chromosomal Abnormalities in Preimplantation Embryos *379*
Programmed Cell Death and Embryo Wastage *379*
Programmed Cell Death and Massive Oocyte Loss in the Human Ovarian Germ Cell Line *380*
Implications for ART *380*
What is a Good Embryo (The Seed)? *380*
Role of Preimplantation Genetic Screening in Embryo Selection *381*
Role of Metabolic Profiling of the Embryo *381*

Section 7 **PREIMPLANTATION GENETIC DIAGNOSIS**

55. Preimplantation Genetic Diagnosis: Expansion of Indications and Technical Advances 385
Sanjeev Khot, Manisha Joshi
Indications and Conditions for PGD *386*
Late Onset Diseases *388*
Cancer Predisposition Syndromes *388*
PGD for Sex Selection *388*
PGD for Non-medical Traits *388*
Technical Aspects of PGD *388*
Evaluation of Embryos *389*
Biopsy Procedures *389*
Genetic Analysis Testing *390*
Fluorescent *in situ* Hybridization *390*
Polymerase Chain Reaction *390*
Diagnosis and Misdiagnosis of PGD Applications Categorized by FISH and PCR *390*
Preimplantation Genetic Haplotyping *390*
PGH versus Previous PGD Techniques *390*
Embryo Transfer and Cryopreservation of Surplus Embryos *390*
Ethical Issues *391*
Regulatory Authority *391*

56. Preimplantation Genetic Diagnosis for Single Gene Disorders 393
KK Gopinathan
Genetic Counseling *393*
Treatment-Related Counseling *393*
Patient Selection *394*
Intracytoplasmic Sperm Injection *394*
Embryo Biopsy *394*
Diagnostic Methods *394*
Allele Specific Drop-out: A Problem *397*
Primed *in situ* Labeling *397*
Whole Genome Amplification (WGA) *399*
Embryo Transfer *399*

57. Preimplantation Genetic Diagnosis for Selecting HLA Compatible Embryos 401
Semra Kahraman, Cagri Beyazyurek
Patients and Methods *403*
Preclinical Work-up *404*
PGD Study *404*
IVF and Embryo Biopsy Procedure *404*

58. Preimplantation Genetic Diagnosis: Clinical Applications 410
Mirudhubashini Govindarajan
Preimplantation Studies: The Techniques *411*
Analyzing Methodologies *411*
Preimplantation Genetic Diagnosis (PGD) *412*
Main Indications for PGD *412*
Preimplantation Genetic Screening (PGS) *413*
Indications for PGS *413*
Technical Problems and Limitations *413*

59. Preimplantation Genetic Diagnosis: The Current State of the Art 415
Sulochana Gunasheela
Preimplantation Genetic Diagnosis (PGD) *415*
PGD for Group 1 Diseases (Aneuploidy) *416*
PGD for Group 2 Diseases *417*

The Technique of PCR in PGD *417*
Amplification Failure *417*
Allele Drop-out *417*
Contamination *417*
Common Diseases Referred for PCR (Group 2) *418*
Results of PGD Conducted by ESHRE Consortium Steering Committee *418*
Multiplex PCR *418*
Fluorescent PCR *419*
PCR for Embryo Selection in IVF *419*

Section 8 **ART OUTCOME AND BEYOND**

60. Can We Improve the IVF Outcome? 423
Mohinder Kochhar
Factors Responsible for Success *423*
Improving Embryo Quality *423*
Assisted Hatching *424*
The Role of the Endometrium *424*

61. Does Seasonal Variability Affect ART Outcome? 425
Lata Kamble, Anil Gudi, Amit Shah
Seasonality in Human Reproduction *425*
Mediators of the Seasonal Effect on Reproduction *426*
Seasonality in Assisted Reproduction *427*

62. Natural Killer Cells as Predictors of Successful Implantation 432
Stefan Kostadinov, Surendra Sharma
Peri-implantation Events and Placentation *432*
Immune Cells of Decidua *433*

63. Medical Treatment with Misoprostol for Early Failure of Pregnancies Conceived Following ART 438
Daniel S Seidman, Micha Baum, David Stockheim, Ronit Machtinger
Medical Treatment *438*

64. Management of Recurrent Miscarriages 443
Yadava Bapurao Jeve
Etiology *443*
Recurrent Miscarriages and Infertility *446*
Investigations *446*
Special Investigations for Assisted Reproductive Techniques (ART) *447*
Management *448*
Tender Loving Care *448*
Management of Specific Disorders *449*
ART as a Treatment for Recurrent Miscarriages *450*

65. Current Concepts in Multifetal Pregnancy Reduction and Selective Termination 453
Alon Shrim, Rivka Peltz, Shlomo Lipitz
Technique *453*
Timing *454*
Results *454*
Special Cases *454*
Selective Termination *455*
Selective Termination in Dichorionic Diamniotic Twins *455*
Selective Termination in Monochorionic Diamniotic Twins *455*

66. The Association Between Congenital Malformations and Infertility, Infertility Treatment and ART 457
Jacob Farhi, Benjamin Fisch
The Association Between Congenital Malformations and IVF Treatment *457*
The Association Between Various Elements of IVF Treatment and the Risk of Congenital Malformations *458*
Intracytoplasmic Sperm Injection (ICSI) and Congenital Malformations *458*
Imprinting Disorders and IVF *459*
The Association Between Diagnosis of Infertility and the Risk of Congenital Malformations in Non-IVF Conceptions *459*

67. Preservation of Ovarian Tissue: Pioneers Close to a New Border? 462
René Frydman, Antoine Torre

Iatrogenic Female Infertility and the Failure of Conventional Treatments ***462***
Young Women and Anticancer Treatment: Surviving but Sterile ***462***
Other Situations and their Fertility Risk ***464***
Conventional Solutions for Safeguarding Female Fertility ***464***
Newer Methods ***464***
Cryopreservation of Ovarian Tissues ***464***
The Autograft of Ovarian Strips ***464***
Autograft of Whole Ovary ***465***
The Cryopreservation of Primordial Follicles ***466***
Control of the Metastasis Risk ***466***

68. Is Aspirin Useful in ART Protocols? 469
Kaberi Banerjee

Antithrombotic Effect ***469***
Aspirin and IVF ***469***
Meta-analysis of the Role of Aspirin in Patients Undergoing IVF-ICSI ***470***

69. Cytokines and Embryo Implantation 472
Gérard Chaouat, Fabrice Petit, Mona Rahmati, Marie Petitbarat, Sylvie Dubanchet, Nathalie Ledée

Implantation Steps ***473***
Embryo Signals ***473***
Inflammation and Implantation ***474***
The Th1/Th2 Cytokine Balance ***475***
A Cardinal Role for Uterine Natural Killer (NK) Cells ***475***
Angiogenic Cytokines ***476***
Other Regulations of Importance ***476***
Complement ***476***
Microarrays ***477***

70. Endometrial Cancer and Wish of Pregnancy: Is Conservative Treatment Possible? 482
Priya Selvaraj, Kamala Selvaraj

Risk Factors ***482***
Other Risk Factors ***483***
Symptomatology ***483***
Nutrition and Cancer Risk ***483***
Screening Procedures ***483***
Staging ***484***
Prognostic Factors ***484***
Fertility Options ***485***
Conservative Management ***485***
Unresolved Issues ***487***
Recent Research ***487***

Section 9 **CURRENT CONCEPTS IN THE TREATMENT OF MALE INFERTILITY**

71. Managing Azoospermia 493
Rajeev Kumar

Etiologic Causes ***494***
Delivery Abnormalities ***494***
Evaluation ***496***
Therapy ***499***

72. The Effect of Smoking on Semen Quality in Infertile Men 503
Mete Isikoglu, Murat Seleker, Kemal Ozgur

Case Studies ***504***

73. Is there an Ideal Sperm Retrieval Technique? 508
Rupin Shah, Hemant Bhanudas Nemade, Devendra Patil

Indications for Sperm Retrieval ***508***
Requirements of an Ideal Technique ***508***
Sperm Retrieval Techniques ***509***
Epididymal Sperm Retrieval—Percutaneous Methods ***509***
Ideal Technique ***511***

74. Why are We Still Ligating Varicoceles? 513
Kishore Nadkarni, Dharmesh Kapadia, Purnima Nadkarni

History ***513***

Pathophysiology ***513***

Diagnosis ***513***

Why do We Need to Ligate a Varicocele in the Era of Assisted Reproduction? ***514***

Indications for Surgical Treatment of Varicocele ***515***

Surgical Procedures ***515***

Technique of Microsurgical Varicocelectomy ***516***

Complications of Varicocele Surgery ***517***

Results and Cost-effectiveness ***517***

Controversial and Debatable Areas ***518***

75. Is Cryopreserved Retrieved Sperm the Gold Standard for ART? 520
Luís Arturo Ruvalcaba Castellón, Martha Isolina García Amador, Jorge Eduardo Montoya Sarmiento, Humberto Aguirre Famanía, Henry Mateo Sanez, Marco Antonio Flores Miranda, Sandra Cubillos Gracía, Silvio Cuneo Pareto

Case Studies ***522***

Methodology of Sperm Cryopreservation ***523***

Cryodamage ***524***

Section 10 **ULTRASONOGRAPHY IN INFERTILITY**

76. 3D Ultrasound and Infertility: Evaluating the Uterus of the Infertile Patient 529
L Gindes, Yaron Zalel

Ultrasound Acquisition of Data ***530***

3DUS in Gynecologic Pelvic Examination ***530***

Intrauterine Device ***536***

Endometrial Receptivity ***537***

Adenomyosis ***538***

Intrauterine Adhesions ***539***

77. Color Doppler and Prediction of Success in ART 541
Anoop Kumar Gupta

What is Color Doppler Ultrasound? ***541***

Ovarian Follicular Dynamics: From Basic Science to Clinical Practice ***542***

Ultrasonography as a Predictor of Embryo Implantation after In Vitro Fertilization ***542***

Relationship Between Uterine Blood Flow and Endometrial and Subendometrial Blood Flows During Stimulated and Natural Cycles ***542***

Endometrial and Subendometrial Perfusion are Impaired in Women with Unexplained Subfertility ***542***

The Role of Endometrial and Subendometrial Blood Flows, Measured by Three-Dimensional Power Doppler Ultrasound, in the Prediction of Pregnancy during Ivf Treatment ***542***

The Role of Ultrasonography in the Evaluation of Endometrial Receptivity Following Assisted Reproductive Treatments: A Critical Review ***543***

Endometrial Evaluation in Superovulation Programs: Relationship with Successful Outcome ***543***

Doppler Evaluation of the Uterine and Spiral Arteries from Different Sampling Sites and Phases of the Menstrual Cycle during Controlled Ovarian Hyperstimulation ***543***

Transvaginal Color Flow Doppler in the Assessment of Ovarian and Uterine Blood Flow in Infertile Women ***543***

Endometrial Receptivity in the Light of Modern Assisted Reproductive Techniques ***543***

Endometrial Thickness, Morphology, Vascular Penetration and Velocimetry in Predicting Implantation in an *In Vitro* Fertilization Program ***543***

78. Uterine Contractility and Ultrasound 545
Jude Jose, Anil Gudi, Amit Shah

Physiology of Uterine Contractions in the Non-pregnant Uterus ***545***

Uterine Contractility and Conception ***546***

Uterine Contractions and Sperm Transport ***546***

Uterine Contractility on the Day of Blastocyst Transfer *546*
Role of Hormones in Uterine Contractility *547*
Assessment of Uterine Contractility *547*

Section 11 **BATCH IVF**

79. Does Batch IVF Compromise the IVF Laboratory? 555
Jayant G Mehta
Infection Control and Protective Measures *556*
Consumables *556*
Records and Protocols *557*
Maintenance Calibration and Equipments Monitoring *558*
Staffing Requirements *560*
Air Conditioning System *561*

Section 12 **MARKETING AND ADVERTISING IN IVF**

80. Web Marketing for IVF Clinics 567
Aniruddha Malpani
Why You Need a Website? *567*
How Your Website Helps You? *567*
Promoting Your Website—An Ongoing Effort *568*

81. Role of Mass Media in Marketing Your IVF Center 570
Jayant G Mehta
Types and Functions of Mass Media *570*
Types of Media that can be Employed in Marketing your IVF Clinic *571*
Composing Effective Messages for Specific Channels *573*
Understanding How to Interact with Media *574*
The Relationship of Mass Media to Other Forms of Communication *574*

82. Cross-border Reproductive Care: A Worldwide Phenomenon 576
Daniel S Seidman, Guy Israel Seidman
The Increase in Reproductive Tourism *577*
Reasons for International Travel for IVF Treatment *577*
Is IVF Tourism a Good or a Bad Phenomenon? *580*

Section 13 **ART REGULATION**

83. Is there a Worldwide Need for ART Regulatory Guidelines? 585
Jyothi Pillai, Kamini A Rao
Ethical Issues *585*
Legal Status of Embryo *586*
Presence of National Guidelines *586*
Absence of Guidelines *586*

84. Ethical Issues in Gamete Donation and Surrogacy 587
RS Sharma
Surrogacy *589*
Possible Misuse of ART—Sale of Embryos and Stem Cells *590*
Rights of a Child Born Through Various ART Techniques *590*

85. Accreditation and Supervision of ART Clinics: Worldwide Trends 592
Kulvinder Kochhar Kaur, Gautam N Allahbadia
Initial History of IVF *592*
Accreditation *593*
Accreditation in India and the Subcontinent *593*
In USA *594*
Professional Accomplishments that have
Enhanced Oversight of ART *594*
Professional Society Guidelines and Practice *594*
Professional Society Ethical Guidelines *594*
In Canada *596*
Monitoring Reproductive Health in Europe *596*
Role of ESHRE *596*
In UK *597*
In Sweden *597*
In Australia *598*
Egg Sharing (PROS and CONS) *598*

86. The Uterus in Third Party Reproduction: Medicolegal Status and Ethical Concerns **601**
Nikhil D Datar

What is Surrogacy? ***601***

Is Surrogacy Recognized in India? ***601***

Is Commercial Surrogacy Unethical? ***602***

Does the Surrogacy Contract Infringe upon the Right to Life and Liberty? ***602***

Right to Abort ***602***

Does the Child have the Right to Find his/her Genetic Parents? ***603***

Custody of the Child ***603***

Unresolved Issues ***603***

Complicating Issues Further ***604***

Section 14 **THE FUTURE OF ART**

87. Anti-Müllerian Hormone: Insights into a Novel Biomarker of the Ovarian Follicular Status **607**
Michael Grynberg, Estelle Feyereisen, C Ferretti, René Frydman, Renato Fanchin

Serum Amh Concentration is a Marker of the Ovarian Follicular Status ***608***

Serum AMH: A Reproductive Intercycle Measurement ***608***

Dynamics of Serum AMH Concentrations During the Menstrual Cycle and the Final Follicle Maturation and Luteinization ***609***

88. *In Vitro* Maturation of Oocyte: Will it Ever Replace the Traditional IVF Program? **613**
Sulochana Gunasheela

What are the Strategies Available to Prevent OHSS Today? ***615***

89. Stem Cell Therapeutic Potential: Miles to go Before We Sleep **619**
Jayant G Mehta

Cell Therapy and Regenerative Medicine ***619***

Screening of Donor Sources ***620***

Setting Standards for Cultured Human Stem Cell Lines ***620***

Culturing without a Feeder Layer of Animal Cells Improve Safety ***621***

Importance of Detailed Characterization of Human Stem Cell Populations ***621***

Assessment of Human Stem Cell Safety in Animal Models of Human Diseases ***622***

Index *625*

CHAPTER

24

Do We Need HSG in the Era of 3D/4D Ultrasonography?

Madhusree Ghosh, Shelly Tse, Kamal Ojha

OVERVIEW

Subfertility affects one in ten couples worldwide with global prevalence rates varying from approximately 5 percent in developed countries to 30 percent in certain developing countries. Tubal assessment forms an integral part of the subfertility work-up. Historically, hysterosalpingography (HSG) has been advocated as the first line of investigation to diagnose tubal pathology. However, HSG is associated with risks of radiation and exposure to iodine. Laparoscopy and dye test is the gold standard for diagnosing tubal pathology. Laparoscopy however, involves cost issues and it is not free of complications. With recent developments in ultrasonography and with the introduction of three-dimensional ultrasonography, various ultrasonographic techniques, which involve visualization of the uterine cavity with the use of a contrast agent, have now been devised. Any ultrasound technique that uses fluid as a contrast agent in the evaluation of tubal patency is called hysterosalpingo-contrast-sonography (HyCoSy). The most commonly used dye for HyCoSy is an agent called Sono Vue. HyCoSy is an outpatient procedure. The patient has a transvaginal scan (TVS), and the contrast dye, which is inserted through the cervix, should be observed filling the uterine cavity and spilling out of the tubes through the fimbrial end. Coded contrast imaging (CCI) is a new software that optimizes the use of the ultrasound contrast media and enhances the visualization of the Fallopian tube. CCI can emit an ultrasound beam at a selected frequency, thereby preventing overlap of tissue and contrast responses. Some authors feel that HSG is an outdated investigation and has no place in current day evidence-based medicine. However, in developing countries, it is still the investigation of choice in evaluating women with subfertility and suspected tubal pathology. Expertise and funds are required to perform three-dimensional ultrasonographic procedures.

INTRODUCTION

The appropriateness of many investigations for subfertility continues to be a debate amongst many clinicians. For the concerned couple, an ideal test should be diagnostically accurate, involve the least amount of delay, be minimally invasive and most reliable. Tubal assessment is an integral part of female fertility evaluation and accounts for up to 30 percent of female subfertility.[1] Further investigations should be carried out to screen for and diagnose tubal pathology. Hysterosalpingography (HSG) has been advocated as the first line investigation historically. HSG is a radiographic examination of the uterine cavity and Fallopian tube that involves the use of a radiographic contrast medium. It has been suggested that HSG has a therapeutic role in enhancing subfertility.[2] Laparoscopy and dye test remains the gold standard in diagnosing tubal patency. However, it is an invasive and expensive procedure requiring general anesthesia with a 0.13 percent risk of surgical complications.[3] With advances in diagnostics, more tests, such as those with the use of ultrasound, have been advocated. Various ultrasonographic contrast media have been developed for tubal visualization and have been used in the diagnosis of tubal patency or blockage.[4] Any ultrasound-based technique that uses fluid as a contrast agent in the evaluation of tubal patency is called hysterosalpingo-contrast-sonography (HyCoSy). In an attempt to overcome the limitations with conventional HyCoSy, a newer software called coded contrast imaging (CCI) technology during HyCoSy, with the help of 3-dimensional (3D) ultrasonography (USG), has been studied. The aim of this chapter is to look into the advantages and disadvantages of HSG and 3D USG in the investigation of

JAYPEE BROTHERS

a subfertile couple, with a brief mention of laparoscopy and fertiloscopy as a part of the same investigative work-up.

CLINICAL DISCUSSION

Hysterosalpingography (HSG)

Hysterosalpingography is an X-ray examination of the uterine cavity and Fallopian tubes that involves the use of a radiographic contrast medium.

Procedure

Hysterosalpingography is performed in the Radiology Department. It is performed between days 7 to 10 of the menstrual cycle to avoid interfering with a possible pregnancy. Table 24.1 presents the indications to perform a hysterosalpingography. The patient is counseled about the actual process and may receive anti-inflammatory agents prior to the procedure as it may involve some pelvic discomfort and pain. The patient is placed in the dorsal position and the posterior vaginal wall is retracted with a Sim's speculum. The cervix may be held with a tenaculum. A hysterosalpingographic cannula is fitted with a syringe containing radio-opaque dye, Urograffin (water soluble iodine). The cannula is passed through the cervix and 5 to 10 mL of dye is slowly introduced. An immediate X-ray plate in the anteroposterior view is taken under fluoroscopic control and another plate is taken 10 to 15 mins later. Tubal patency is assessed by peritoneal spillage, visualized on the X-ray plate (Figs 24.1A and B).

Antibiotic prophylaxis is given with Doxycycline (100 mg twice daily for 5 days) after the procedure. For those allergic to Doxycycline, Azithromycin or Erythromycin may be prescribed. Table 24.2 presents the advantages and disadvantages of HSG.

Table 24.1: Indications for hysterosalpingography

- To assess tubal patency
- To identify tubal blockage and dilatation (hydrosalpinx)
- To detect uterine malformations, like uterine septa, in recurrent miscarriages
- To identify translocated intrauterine contraceptive device
- May indicate endometrial polyps, submucous fibroids
- To diagnose uterine synechiae

Three-dimensional Ultrasonography (3D USG)

To overcome the limitations of HSG, newer modalities for testing tubal patency and infertility investigations have been studied. With the advent of high resolution vaginal probes, transvaginal sonography (TVS) has assumed an important role in assessing the myometrium and the endometrial echo complex. The diagnostic value of 3D ultrasound in the detection of intrauterine lesions is superior to 2 dimensional (2D) ultrasound.[9]

Hysterosalpingo-contrast-sonography (HyCoSy)

Recently, various ultrasonographic contrast media have been developed for tubal visualization and have been used in the diagnosis of tubal patency or blockage.[10] Any ultrasound-based technique that uses fluid as a contrast agent in the

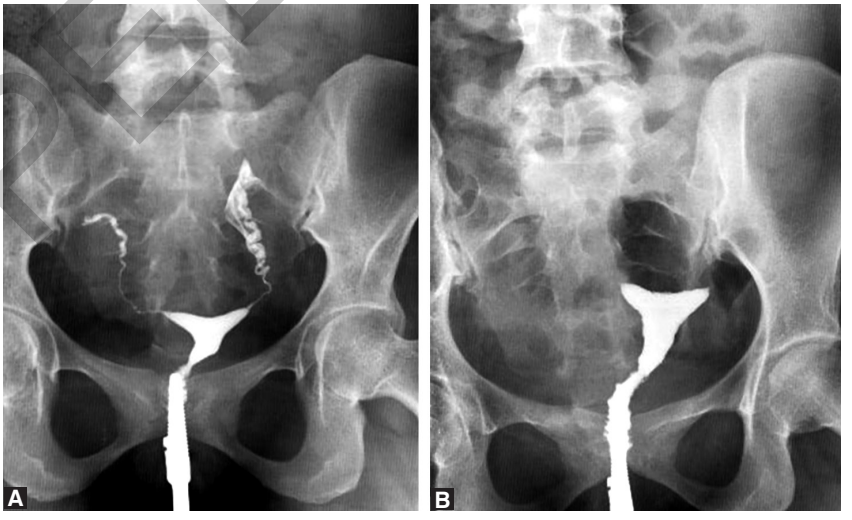

Figs 24.1A and B: (A) A radiograph showing a normal hysterosalpingogram (HSG), with free flow of radio-opaque dye into the abdominal cavity indicating bilateral patency of the Fallopian tubes; (B) Another radiograph showing the outline of the uterus without spillage of dye, indicating bilateral tubal obstruction

JAYPEE BROTHERS

Table 24.2: Advantages and disadvantages of hysterosalpingography

Advantages	*Disadvantages*
• Identifies uterine cavity abnormalities	• Sixty-five percent sensitivity and 83 percent specificity for diagnosing tubal obstruction[5]
• Does not require much expertise	• Pelvic pain and discomfort
• Can be therapeutic-forcing dye through the tube may unblock a blocked tube	• Oil-soluble contrast media may be associated with oil embolism and granulomatous inflammation in blocked or inflamed Fallopian tubes[6]
• Can be performed in low resource settings	• Water-soluble contrast media (more commonly used) have been linked with increased frequency and duration of bleeding post-HSG and higher post-HSG miscarriage rates[7]
	• Overall, 10 percent risk of post-HSG complications
	• Exposure to radiation—the mean dose area product (DAP) for a complete HSG examination is 2.05 Gy cm^2 compared to 0.09 Gy cm^2 for a single posterior anterior chest X-ray examination[8]
	• Involvement of the Radiology department is required

evaluation of tubal patency is called hysterosalpingo-contrast-sonography (HyCoSy). This technique was introduced in the 1990's.

Procedure

It is performed as an outpatient procedure. A speculum is inserted into the vagina to visualize the cervix and a fine tube with a balloon is inserted into the cervix. The speculum is then removed and a TVS probe is inserted. This procedure is traditionally performed using ultrasound contrast media, which is injected through the cervix. The dye should be observed filling the uterine cavity, passing through the tubes and spilling out at the fimbrial end. Figure 24.2 depicts a 3D HyCoSy image of the uterine cavity in a patient with a uterine septum.

Similar to HSG, prophylactic antibiotics need to be prescribed for the HyCoSy procedure.

Different dyes used for HyCoSy

1. Echovist is a suspension of galactose microparticles in aqueous galactose solution and is an echogenic contrast medium. This is no longer available as the manufacturer has withdrawn the dye due to lack of availability of ingredients for the dye. The dye was well-established and quoted in publications.
2. Currently, we are using Sono-Vue, which is a dye for cardiac Doppler. Sono-Vue is a second-generation agent, which provides a substantial harmonic response at low acoustic pressures. It was recently introduced for sonographic tubal patency evaluation.
3. Recently, ExEm gel—hydroxyethylcellulose; glycerol has shown to be very useful for HyCoSy.
4. In places where dye is not available, water can be used for HyCoSy. Rapid movement of water between syringes with a three-way cannula can help to create a bubbling effect and obtain good quality image during HyCoSy examination.

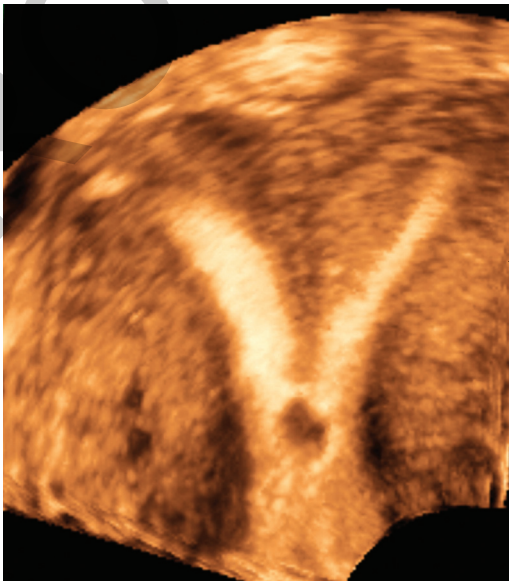

Fig. 24.2: 3D-image of the uterine cavity. The lower-third of the cavity shows the inflated HyCoSy catheter used to insert Echovist dye to outline the uterine cavity and the right Fallopian tube. This is a case of uterine septum with dye on either side of the uterine septum

A number of difficulties are encountered with the standard 2D gray-scale HyCoSy technique. Firstly, the Fallopian tube cannot be visualized completely in any scanning plane. Secondly, spill of echo-positive medium from the fimbrial end of the tube is difficult to distinguish from the bowel

JAYPEE BROTHERS

Table 24.3: Advantages and disadvantages of Hysterosalpingo-Contrast-Sonography (HyCoSy)

Advantages	*Disadvantages*
• As accurate as HSG in terms of establishing tubal patency[11] • Additional advantage of ultrasound assessment of the pelvis at the same time • Superior in detection of intrauterine abnormalities such as endometrial polyps, submucus fibroids, synechiae, hydrosalpinx and abnormal ovaries Does not require the use of iodine • No exposure to radiation • Input from other specialties are not required • Although the costs of HSG and HyCoSy are similar, costs of HyCoSy can be further reduced by using air/saline as a medium • Less painful and better tolerated than HSG • Combined with the initial sonographic examination, it is believed to reduce the necessity for laparoscopy, and accelerates the whole investigation process Complication rate (fever, pelvic inflammatory disease) is 4 percent	• Physician learning curve is longer • Spill of dye from the distal end of the tube may be difficult to visualize because of similar echogenecity with the surrounding bowel • Exact site of blockage may be difficult to ascertain

Table 24.4: Advantages and disadvantages of 3-Dimensional Power Doppler Imaging (3D PDI)[4]

Advantages	*Disadvantages*
• Ultrasound assessment of the pelvic organs can be done in the same sitting • 3D volumes, which include that of the Fallopian tube, can be stored and analyzed later, reducing the examination time of the patient • Less contrast agent is required • 3D ultrasound helps in diagnosing uterine malformations like bicornuate uterus and uterine septum	Resulting image obtained is not always clear enough to draw a conclusion about tubal patency

surrounding the tube, which is of similar echogenecity. Thirdly, the procedure needs expertise and training. Table 24.3 presents the advantages and disadvantages of HyCoSy. This procedure has been modified and the feasibility of 3D power Doppler imaging (3D-PDI) in the assessment of tubal patency during HyCoSy has been studied. Table 24.4 presents the advantages and disadvantages of 3D power Doppler imaging.

Three-dimensional Coded Contrast Imaging (3D CCI) During HyCoSy

Coded contrast imaging (CCI) is a new software that optimizes the use of ultrasound contrast medium by means of low acoustic pressure and enhances the visualization of the Fallopian tubes. The image displayed is therefore based on harmonic signals produced by the contrast medium microspheres and broadband ultrasound signals from the surrounding tissue are completely filtered out. In principle, the bubbles reflect ultrasound waves to give the bright image observed during ultrasound examination. CCI is able to emit an ultrasound beam at a selected frequency, thereby preventing overlap of tissue and contrast responses.[12] Table 24.5 presents the advantages and disadvantages of 3D coded contrast imaging.

Table 24.5: Advantages of 3D CCI[12]

- 3D volume acquisition of the entire Fallopian tube easily shows the course of the tube
- Allows distinction of contrast medium in the tubes and ovaries from surrounding tissues and organs due to clearly detectable differences between the harmonic response of the contrast medium micro-bubbles and the broadband ultrasonic signals from surrounding tissue
- 3D volume acquisition is static, therefore less dependent on the experience and skill of the operator
- 3D volumes of the uterus and tubes can be stored and analyzed later, thereby reducing examination time for patients

JAYPEE BROTHERS

Procedure

Coded contrast imaging technology during HyCoSy involves the intrauterine injection of ultrasound contrast medium, which in a completely anechoic pelvis is visualized as hyperechoic fluid. This fluid is first seen in the uterus, in the tube proximally if patent, and finally spills into the abdominal cavity if the distal end of the tube is patent. As the contrast medium is hyperechoic, its course along the uterus and tubes can be studied for several minutes and 3D volume acquisitions can be done. The dye used for this is Sono-Vue solution, which contains sulfur hexafluoride bubbles.

Laparoscopy

Laparoscopy and dye test is the gold standard method to check the Fallopian tubes, particularly in high-risk patients (women with a past history of pelvic infection or abdominal surgery). Laparoscopy allows direct visualization of the internal organs of the abdomen and pelvis and excludes other pathologies such as endometriosis, fibroids, ovarian cysts and adhesions. Most infertile couples require a diagnostic laparoscopy for complete evaluation of their infertility. Among women whose tubes were found to be unobstructed using HSG, 18 percent were found to have tubal obstruction or peritubal adhesions using laparoscopy and a further 34 percent were found to have endometriosis or fibroids.

The laparoscopy procedure is usually done as a day care surgery under general anesthesia. It takes about 15 to 30 minutes.

When performing the laparoscopy procedure, a fine Verres needle is inserted into the abdomen and gas (carbon dioxide) is pumped into the abdomen to push the intestines away. A second incision might also be made so that a probe can be inserted in order to move pelvic organs, such as the ovaries, into clear view. A colored dye (methylene blue) is then injected through the cervix. If the tubes are not blocked the dye should pass along them and spill into the abdomen. If an abnormality is found during laparoscopy, this may be dealt with at the same time, thus avoiding another operation. Diagnostic laparoscopy is associated with approximately 3 percent risk of minor complications, such as nausea and shoulder tip pain. The risk of major complications, such as bowel injury and injury to blood vessels, is about 0.6 to 2/1000.[3]

Fertiloscopy

Fertiloscopy is a new minimally invasive method for the exploration of the posterior cul-de-sacm which allows a complete work-up of the mechanical factors of female infertility.

When the indications are correct, fertiloscopy can be considered as a valid alternative to diagnostic laparoscopy. In fact, it uses the vaginal approach and requires relatively simple equipment. Moreover, it can be performed under local anesthesia or under sedation.

Fertiloscopy currently, is mostly a diagnostic procedure with restricted operative possibilities limited to biopsies, minimal adhesiolysis and ovarian drilling; nevertheless, operative fertiloscopy is an emerging technique, which will probably develop in the near future.

Fertiloscopy is the combination of different procedures, which include the following:

- Transvaginal hydrolaparoscopy
- Dye test
- Salpingoscopy
- Microsalpingoscopy
- Hysteroscopy.

CONCLUSION

Tubal damage can be due to various reasons, including pelvic infection, endometriosis and fibroids. A detailed history and physical examination of the patient at the initial visit should be carried out. The main organism causing pelvic inflammatory disease is Chlamydia trachomatis. Microimmunofluorescence (MIF) is widely used for Chlamydia antibody titer (CAT) testing. Although CAT testing does not provide any detail on the anatomy of the uterus and tubes, it should be able to identify women who need further tubal or pelvic evaluation. Historically, HSG has remained the first line of investigation in the diagnosis of tubal patency. However, HSG is associated with risks of exposure to iodine and radiation. With advances in technology, 3D ultrasonography and HyCoSy procedures have gained popularity in the investigation of such patients. 3D ultrasonography gives us the additional advantage of an initial sonographic assessment of the pelvic organs during the same sitting. Complete visualization of the uterine cavity to the fimbrial end of the tube is now possible with the 3D CCI technology during HyCoSy. However, laparoscopy remains the gold standard in diagnosing tubal pathology. Many author's question—whether HSG should be performed as a part of modern fertility investigations? Proponents of HSG would argue that HSG can be performed in low resource settings and does not need the availability of an ultrasound. However, X-ray, fluoroscopic equipment and liason with the Radiology department are required as a bare minimum. Studies have shown that HyCoSy and HSG procedures bear the same cost and accuracy. With the use of 3D USG we can also avoid radiation exposure. Most fertility clinics in the developed world have access to ultrasound as a part of their very basic infertility work-up. Some authors feel that HSG is out of date and has no place in modern evidence-based fertility investigations,[6] however, in developing parts of the world, it is still the investigation of choice, especially because greater training, expertise and funds are required to perform 3D USG procedures.

JAYPEE BROTHERS

REFERENCES

1. Cates W, Wasserheit JN. Genital chlamydial infections: epidemiology and reproductive sequelae. Am J Obstet Gynaecol 1991;164:1771-81.
2. Yaegashi N, Kuramoto M, Nakayama C, Nakano M, Hoshai H. Pregnancy rates after hysterosalpingography comparing water soluble contrast medium with oily contrast medium. Nippon Sanka Fujinka Gakkai Zasshi 1987;39:1812-4.
3. Chapron C, Querleu D, Bruhat MA, Madelenat P, Fernandez H, Pierre F, Dubuisson JB. Surgical complications of diagnostic and operative gynaecological laparoscopy: a series of 29,966 cases. Hum Reprod 1998;13:867-72.
4. Sladkevicius P, Ojha K, Campbell S, Nargund G. Three-dimensional power Doppler imaging in the assessment of fallopian tube patency. Ultrasound Obstet Gynecol 2000;16:644-7.
5. Swart P Mol, BWJ van der Veen F, van Beurden M, Redekop WK, Bossuyt PM. The accuracy of hysterosalpingography and the diagnosis of tubal pathology : a meta-analysis. Fertil Steril 1995;64:486-91.
6. Lim CP, Hasafa Z, Bhattacharya S, Maheswari A. Should a hysterosalpingogram be a first-line investigation to diagnose female tubal subfertility in the modern subfertility work-up? Hum Reprod 2011;26:967-71.
7. Spring DB, Barkhan HE, Pruyn SC. Potential effects of contrast materials in hysterosalpingography: a prospective randomized clinical trial. Kaiser Permanente Infertility Work Group. Radiology 200;214:53-7.
8. Hart D, Hillier MC, Wall BF. HPA-RPD-029 – doses to patients from radiographic and fluoroscopic X-ray imaging procedures in the UK-2005. Review 2009;2010:95.
9. El – Shirbiny W, Nasr AS. Value of 3- dimensional sonohysterography in infertility work-up. J Minim Invasive Gynaecol 2011; 18:54-8.
10. Deishert U, Schlief R, Van de Sandt M, Juhnke I. Transvaginal hysterosalpingo-contrast-sonography (HyCoSy) compared with conventional tubal diagnosis. Human Reprod 1989;4:418-24.
11. Heikkinen H, Tekay A, Volpi E, Martikainen H, Jouppila P. Transvaginal salpingosonography for the assessment of tubal patency in infertile women: methodological and clinical experiences. Fertil Steril 1995;64:293-8.
12. Exacoustos C, Di Giovanni A, Szabolcs B,Binder-Reisinger H, Gabardi C, Arduini D. Automated sonographic tubal patency evaluation with three-dimensional coded contrast imaging (CCI) during hysterosalpigo-contrast sonography (HyCoSy). Ultrasound Obstet Gynecol 2009;34:609-12.

JAYPEE BROTHERS

CHAPTER

25

How to Approach Submucous Myomas in Infertile Women?

Sunita Tandulwadkar, Anil Chittake, Vineeta Kharb

JAYPEE BROTHERS

OVERVIEW

Submucous myomas have a causal relationship with infertility. Submucous myomas are classified on the basis of intramural extension. Preoperatively, transvaginal sonography (TVS) is used to assess size, number, location, the extent of the intramural extension, and the free margin.

Type 0 myomas are systematically shaved off with a resectoscope loop until the pedicle is reached. Dislodging the myoma from the base may pose problem in resecting further.

For Type 1 and 2 myomas, minimal pressure is applied to prevent pushing the fibroid deep in the wall and intravasation of fluid. Following removal of the portion protruding in the cavity, the part vested deep in the myometrium is removed by either controlled endocavitary pressure variation or the cold knife technique. It is recommended that large Type 2 myomas (> 4 cm) be removed laparoscopically.

Intraoperative fluid balance is to be maintained and the duration of the surgery plays a major role. The Versapoint bipolar resectoscope causes a reduced risk of hyponatremia as normal saline is used as the distension media. It causes vaporization and desiccation of tissues so the specimen is not available for histopathological examination (HPE).

INTRODUCTION

Leiomyomas of the uterus are the commonest solid pelvic tumors in women, present in 20 to 25 percent of women aged more than 35 years. Leiomyomas are associated with infertility, the causal relationship in this regard appearing to be more evident for submucosal myomas. Of all the myomata, 5 percent are submucosal,[1] although in selected groups, this may be as high as 18 percent.[2]

Several hypotheses have been suggested to explain how submucosal myomas cause infertility or repeated abortions, but none are definitive. Submucous or intramural myomata may cause dysfunctional uterine contractility, which may interfere with sperm migration, ovum transport or nidation.[3-5] In addition, uterine myomata may be associated with preconceptional (implantation) failure or gestational discontinuation due to focal endometrial vascular disturbance as well as endometrial inflammation, secretion of vasoactive substances, or an enhanced endometrial androgen environment.[4,6] In another study that examined the ultrastructure of the host myometrium of fibromyomatas uteri,[7] the sacrolemmal dense bands of host myometrial myocytes were found to be of significantly greater length than that of normal myometria with a corresponding decrease in the number of caveolae, making the host myometria structurally abnormal. This specific abnormality may affect calcium metabolism in these tissues, which in turn, may cause abnormal contractions leading to reproductive wastage or infertility.

CLASSIFICATION OF SUBMUCOSAL FIBROIDS (TABLE 25.1)

The European Society of Hysteroscopy has agreed on a classification for submucous fibroids.[8]

A submucous fibroid is the one that distorts the uterine cavity. It is further divided into three subtypes:

Type 0: Pedunculated fibroid without intramural extension.

Type 1: Sessile with intramural extension of fibroid of <50 percent.

Type 2: Sessile with intramural extension of fibroid of >50 percent.

Table 25.1: Classification of intrauterine myomas by the European Society of Hysteroscopy

Grade 0 (G0)	Myoma with development limited to the uterine cavity, pedunculated or with limited implant base	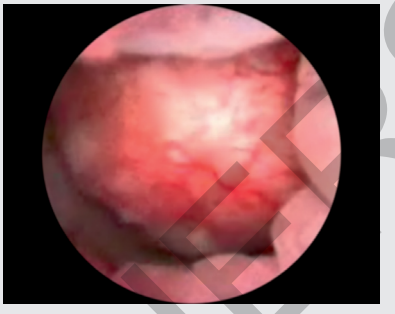
Grade 1 (G1)	Myoma with partial intramural development, intramural component < 50 percent. Angle of protrusion between the myoma and the uterine wall <90°	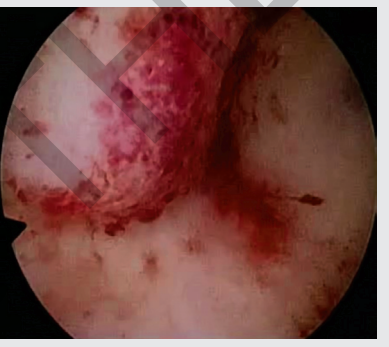
Grade 2 (G2)	Myoma with predominantly intramural development. Intramural component >50 percent. Angle of protrusion between the myoma and the uterine wall >90°	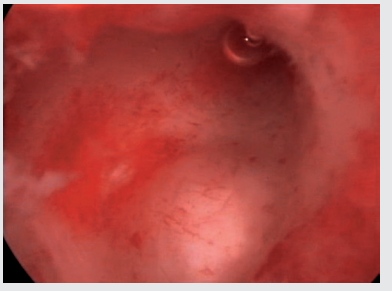

The degree of intramural extension can be assessed by transvaginal ultrasonography or by hysteroscopy by observing the angle between the fibroid and the endometrium at the attachment to the uterine wall.

CLINICAL DISCUSSION

Impact of Fibroids on Assisted Conception (Table 25.2)

A few retrospective cohort studies have examined the impact of fibroids on the results of assisted conception. Results for each type of fibroid are separately analyzed in Table 25.2. The pregnancy rate per embryo transfer in submucous, intramural and subserosal fibroids were 9, 16 and 37 percent respectively, compared with an average of 30 percent in control subjects. The miscarriage rates in various types of fibroids were: submucous 40 percent, intramural 33 percent and subserosal 33 percent compared with the total of 16.4 percent among all the control subjects.

From the data in Table 25.2, it appears that patients should be advised to have submucous and possibly intramural fibroids removed prior to *in vitro* fertilization (IVF).

Preoperative Diagnostic Assessment

Preoperative diagnostic assessment consists of transvaginal ultrasound (TVS). TVS is useful to confirm the diagnosis and to assess the number, size and location of myomas. Ultrasonography must indicate the extent of myomal intramural extension and particularly, the free margin. Three-dimensional (3D) and four-dimensional (4D) USG has almost replaced the need for preoperative magnetic resonance imaging (MRI).

JAYPEE BROTHERS

Table 25.2: Outcome of assisted conception treatment in women with fibroids[9-16]

Author	*Total cases*	*ET*	*PR*	*IR*	*FR*	*LB*	*On going PR*	*MR*	*Control subjects (n)*	*ET*	*PR*	*LB*	*MR*	*IR*	*FR*	*On going PR*
Subjects with submucosal fibroids																
Farhi et al. (1995)	18	55	5\55 (9)	-	-	3/5 (60)	-	2/5 (40)	50	127	32\127 (25)	24/32 (75)	8/32 (25)	-	-	-
Eldar Geva et al. (1998)	9	10	1\10 (10)	-	-	NS	-	NS	249	318	98/318 (30)	78/h98 (80)	20/98 (20)	-	-	-
Subjects with subserosal fibroids																
Eldar Geva et al. (1998)	46	55	9\55* (16)	-	-	6/9 (67)	-	3/9 (33)	249	318	98/31 (30)	78/98 (80)	20/98 (20)	-	-	-
Flavio Garcia Oliveria et al. 2004	117	-	45/110	-	-	78/245 (32)	-	28/110	110	-	78	77/245 (31.5)	39	-	-	-
Subjects with intramural fibroids																
Seoud et al. (1992)	11	24	10/24 (42)	-	-	5/10 (50)	-	5/10 (50)	1357	2018	586/2018 (29)	484/586 (83)	102/586 (17)	-	-	-
Eldar Geva et al. (1998)	33	41	14/41 (34)	-	-	11/14 (79)	-	3/14 (21)	249	318	98/318 (30)	78/98 (80)	20/98 (20)	-	-	-
R Hart and Yanoub (2001)	106	-	23.3	11.9	-	-	15.1	-	-	-	34.1	-	-	20.9	-	28.3
Z Rafael Tel Aviv	94	-	21.2	-	57.8	-	-	9.09	184	-	22.8	-	8.69	-	58.3	-
Subjects with intramural subserosal fibroids																
Ramzy et al. (1998)	39	39	15/39 (39)	-	-	9/15 (60)	-	6/15 (40)	367	367	123/367 (34)	104/123 (85)	19/123 (15)	-	-	-
Stovali et al. (1998)	91	91	34/91 (37)	-	-	30/34 (88)	-	4/34 (12)	91	91	48/91 (53)	44/48 (92)	4/91 (4.4)	-	-	-
Farhi et al. (1995)	28	86	25/86 (29)	-	-	15/25 (60)	-	10/25 (40)	50	127	32/127 (25)	24/32 (75)	8/32 `(25)	-	-	-

Abbreviations: ET: embryo transfer; PR: pregnancy rate; IR: implantation rate; LB: live births; MR: miscarriage rate

Role of Preoperative GnRH Agonist

There are several publications to support preoperative gonadotropin-releasing hormone (GnRH) treatment.[17-20] Owing to their transient effect, analogs can be used as a preoperative treatment. This therapy results in substantial reduction in the tumor size and control of symptoms, such as menorrhagia and abnormal uterine bleeding. The reduction in volume significantly promotes the hysteroscopic management of larger or multiple myomas. It also controls intravascular intravasation of distension media. It also gives us time to correct anemia. Gonadotropin-releasing hormone (GnRH) analogs can also be used when an initial hysteroscopic attempt fails to completely remove the myoma. Shrinking of a persistent tumor, which is partially intramural, combined with the contractile activity of uterine fibers, provokes protrusion in the uterine cavity. This helps the surgeon to remove the remaining segment in a second hysteroscopic intervention.

Preparation of the patient

It is preferable to do the procedure in the immediate postmenstrual period as this does not require any particular preparation of the patient. It is advisable to take a detailed case history and perform an in depth gynecological work-up. In addition, it is always wise to perform hysteroscopic myomectomy in a fully equipped operating room, where any complications can be dealt with and where simultaneous laparoscopy can be performed in the most complicated cases or when intraoperative complications have occurred.

As regards to the hysteroscopic operability of myoma dimensions and site, the classification proposed by the European Society of Hysteroscopy is currently the best guide

JAYPEE BROTHERS

for identifying the type of leiomyoma by the degree of intramural development.

Obviously, while even an inexperienced surgeon can handle myomas of Grade 0, myomas of Grade 2 require a great deal of experience in hysteroscopic surgery. It is interesting to note that this classification makes no mention of myoma dimensions, which plays an important role in decision-making regarding the operability. The dimensions of the myoma have a marked effect on the angle. Indeed, despite an open angle of protrusion, small myomas can be easily removed because of their smaller intramural mass; the opposite holds true for large myomas with relatively acute angles and even those reaching the myometrial serous membrane because of their very large size. However, the operability also depends on the intra-mural component of the myoma itself and, in particular, the free margin, i.e. the thickness of the myometrium remaining between the deep edge of the myoma and serous peritoneum of the uterus. Various authors set this safety margin at 0.5 to 1.0 cm.

Anesthesia

Operative hysteroscopy can be performed both, with local anesthesia, administered by a paracervical block, or under general anesthesia. We routinely operate Grade 0 myomas with size less than 2 cm with an office hysteroscope and Versapoint and without any anesthesia.

Surgical Technique

Myomas with a submucosal localization can be treated exclusively using an operative hysteroscope, the standard surgical approach. Neuwirth and Amin[21] first suggested that hysteroscopic myomectomy may be the procedure of choice for treating submucosal myomas.[21] Several retrospective studies of small case series were published during the 1990s,[14,22-25] demonstrating successful reproductive outcomes after hysteroscopic removal of submucosal myomas in infertile women.

The size and number of fibroids to be removed depends upon the individual surgical skill and experience. It is advisable not to remove big anterior and posterior fibroids in the same sitting to avoid intrauterine adhesions or synechiae formation. It is very important to know ahead of time if we are dealing with a type 0, type I or type II, not only because the type II myomas may require more than one sitting, but there is also a slightly different technique when a type 0, type I and type II is resected.

For leiomyoma resection, a 26 Fr resectoscope is normally used with 30 degree telescope. A smaller resectoscope (22 Fr) is used if the uterine cavity and/or cervical canal is narrow. After cervical dilatation upto 10 mm, the resectoscope with the electrosurgical working element for control of the 900 cutting loop is introduced. Distension of the uterine cavity is obtained with glycine or a sorbitol/mannitol solution. Irrigation is controlled with an electronic suction and an irrigation pump, which automatically controls both intrauterine pressure and the flow rate. The system also ensures constant suction.

The following settings are generally used: Flow rate of approximately 250 mL/min, pressure of 80 to 100 mm Hg, monopolar electricity generator at 60 to 100 Watts and suction pressure of 0.25 Bar. The fluid balance is recorded by measuring the infused and drained fluid from the continuous flow resectoscope.

Basic

1. Hold the camera in your left hand (if you are right-handed)
2. Hold the scope with your right hand
3. Know which is the inflow and outflow.

Main Techniques of Resection

Resection is performed by placing the electrical loop behind the myoma to be resected and retracting it towards the distal lens of the hysteroscope (Fig. 25.1).

Type 0: It is systematically shaved off with the resectoscope loop until the pedicle is reached (Figs 25.2A to D). Type 0 myoma should never be dislodged at the base first, which is the most tempting thing to do. One should avoid this as removal of floating myoma from uterine cavity creates a great problem. Once it is separated, resection and slicing down to smaller pieces is not possible.

Type 1 and Type 2: If the myoma is smaller in size, one can give a semicircular incision on the inferior margin at the angle between the myoma and uterine wall. The myoma can be enucleated in toto from its capsule by giving simple mechanical pressure with the loop at the lower edge. One should not attempt this technique for larger myomas, as again, removal of the enucleated myoma will be a great problem.

While resecting Type 1 and Type 2 myomas, particular care should be taken with regard to the intrauterine pressure.

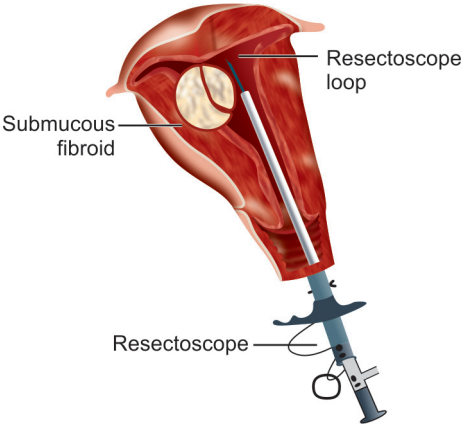

Fig. 25.1: Electrical loop behind the myoma

JAYPEE BROTHERS

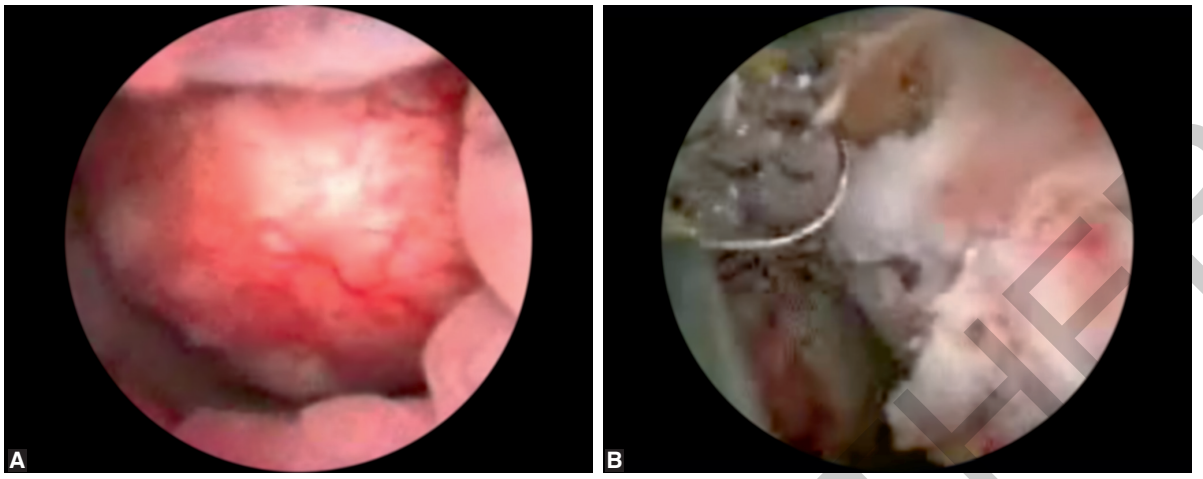

Figs 25.2A and B: (A) Type 0 myoma; (B) Resection of myoma

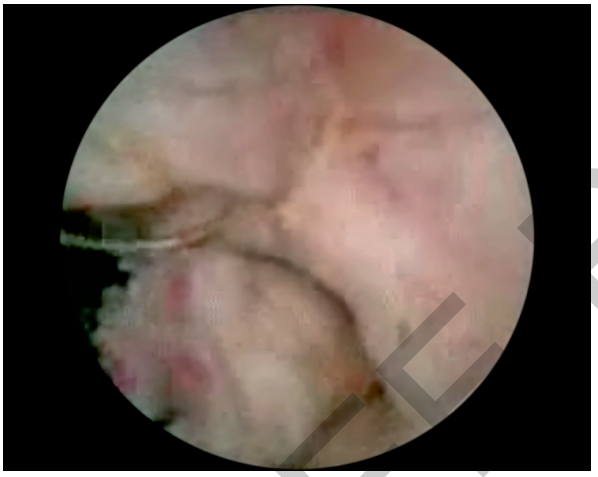

Fig. 25.2C: Resection till pedicle base

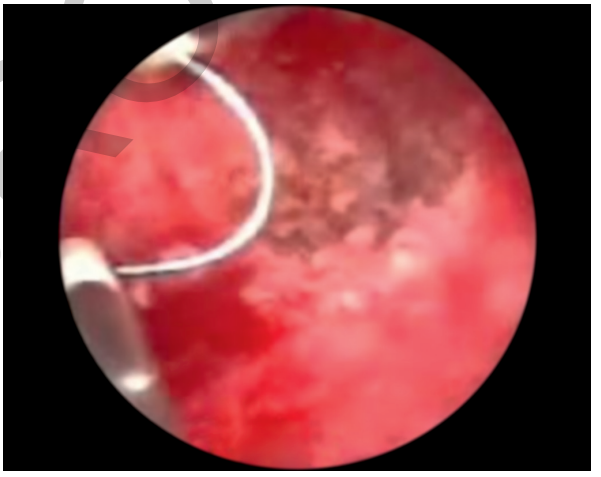

Fig. 25.2D: End result

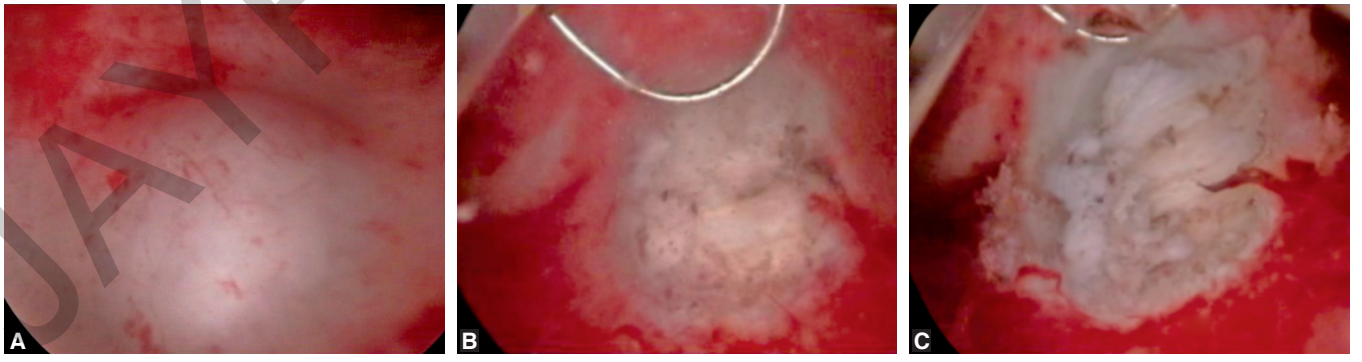

Figs 25.3A to C: (A) Type 2 myoma; (B) Resection with loop; (C) Resection till myoma becomes flat

JAYPEE BROTHERS

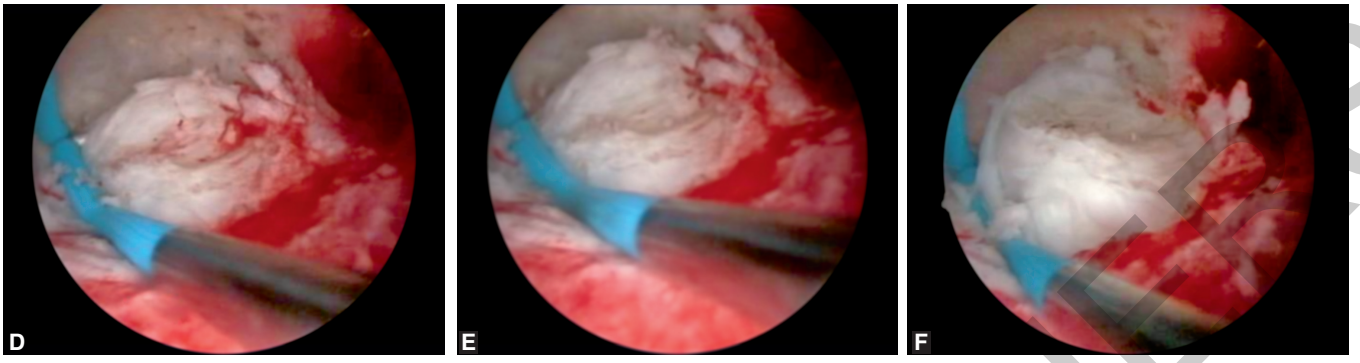

Figs 25.3D to F: (D) Grade II myoma nested deep; (E) Cold knife enucleation; (F) Cold knife enucleation



Figs 25.3G to I: (G) Enucleation; (H) Completely enucleated; (I) Completely enucleated with crater in the background

If the pressure is very high, fibroids will be pushed deep into the wall making resection difficult and also, it may increase the intravasation of fluid. To prevent this, the minimal pressure that gives adequate distension and clear vision is used. Resection is done by placing the loop behind the myoma and retracting it towards the scope. The myoma is shaved down with a slicing technique, with the cutting loop to the level of myometrium till the myoma becomes flat (Figs 25.3A to C). After having dissected the portion of myoma protruding into the cavity, an attempt is made to remove the part nested deep in the myometrial wall.

This can be achieved by two techniques:

1. By giving hydromassage by controlled variation of the endocavitary pressure (opening and closing the endo-uterine aspiration system)
2. Cold knife technique, which consists of simple, mechanical passage of the resectoscope loop or Colin's knife along the capsule lining of the myoma, detaching it from the fibrous bridges that anchors it to the uterine wall, without any electrocoagulation (Figs 25.3D to I).

The operation can be considered complete when only the myometrium can be seen throughout the entire surgical area. Utmost care should be taken to prevent damaging the smooth muscle fiber bundles. If it is impossible to totally remove the intramural fibroid in one sitting, despite the above techniques, if it is too deep or because of technical difficulties, the remaining myoma can be coagulated until dry. This effect is achieved by placing the loop in direct contact with the remaining wall of the myoma and applying a high coagulation current for approximately 30 seconds. The fibroid can then be treated at a later date (2–3 months later) as over this period, the intramural component of myoma migrates into the uterine cavity.

When the surgery is complete, very rarely is it necessary to perform selective coagulation of any bleeding myometrial vessels. In the vast majority of the cases, myometrial contractions are sufficient to stop bleeding.

Complications, such as uterine perforation or bleeding, are related more to the surgeon's skills than to the technique used. Intrauterine pressure and duration of surgery are the main factors that can affect the safety of hysteroscopic surgery.

The following intraoperative precautions are recommended:

1. Meticulous attention to intraoperative fluid balance is imperative if a fluid deficit more than 1 to 1.5 liters is detected. Serum sodium is measured and hyponatremia, if present, should be treated. For every liter of electrolyte-free fluid that is absorbed the sodium level will decrease

JAYPEE BROTHERS

by approximately 10 mEq/L. This helps the surgeon to determine when to stop a case. If the deficit is approximately 1500 cc, it is advisable to put in a Foley's catheter and give a diuretic.
2. Continuous suction, using a multichannel hysteroscope with wide outflow, is recommended to avoid increased intrauterine pressure above safe levels (70–100 mm Hg). This also facilitates clear field of vision.
3. For surgeons with less experience it is advisable to avoid prolonged operative time and excess fluid use for irrigation in cases of large or multiple myomas. In fact, they should avoid operating grade 2 myomas.
4. Less absorption should occur if resection takes place when the endometrium is relatively avascular in the mid-proliferative phase of menstrual cycle.
5. It is important to diagnose patients who are at great risk of absorbing excessive volumes of fluids: those who have patent Fallopian tubes, no endometrial preparation, large uterine fibroids and poor cardiovascular reserve.
6. Absorption of large volumes of electrolyte-free, low viscosity fluid, especially with large myomas, triggers some systemic changes during the operation. Myomectomy of large myomas is liable to hyponatremia, hypo-osmolality, increased cardiovascular pressure (CVP), increased prothrombin time (PT) and partial thromboplastin time (PTT) and increases most of the cardiodynamic parameters.[26-29] These changes demand that the procedure be performed by an experienced hysteroscopic surgeon using a quick technique with the least possible glycine volume and minimal intrauterine pressure to achieve the goal of a safe minimal access surgery.

Postoperative Care and Follow-up

1. Intraoperative antibiotics are administered to all patients. Most of the time, the patient is discharged on the day of surgery.
2. Routine transvaginal sonography is sufficient to know the optimum results of surgery. Follow-up diagnostic hysteroscopy is generally performed only if multiple myomas are removed in one sitting.

Gynecare Versapoint

Versapoint is a bipolar electrosurgical unit (Figs 25.4A and B). It consists of:
1. Dedicated generators
2. Three 5 Fr electrodes
3. Bipolar resectoscope.



Figs 25.4A and B: (A) Generators; (B) 5 Fr electrodes

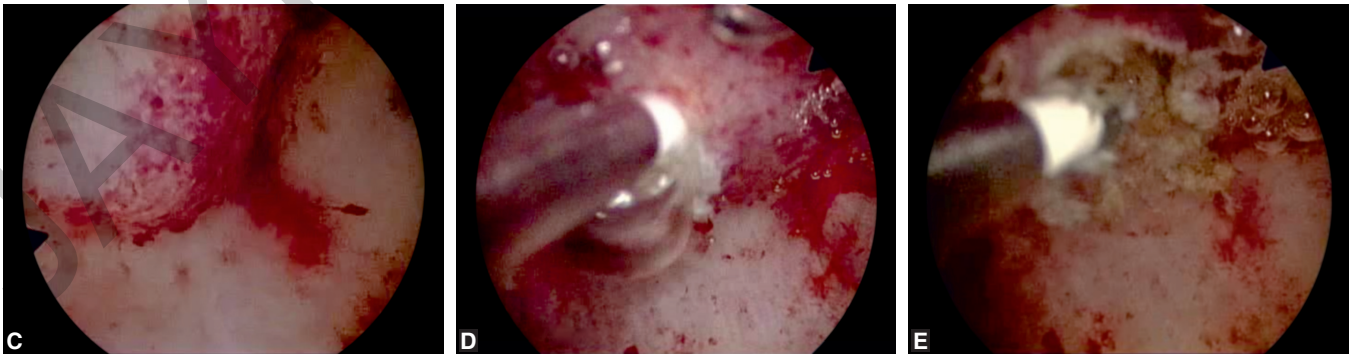

Figs 25.4C to E: (C) Myoma; (D) Versapoint electrode in action; (E) Vaporization of myoma with Versapoint

JAYPEE BROTHERS

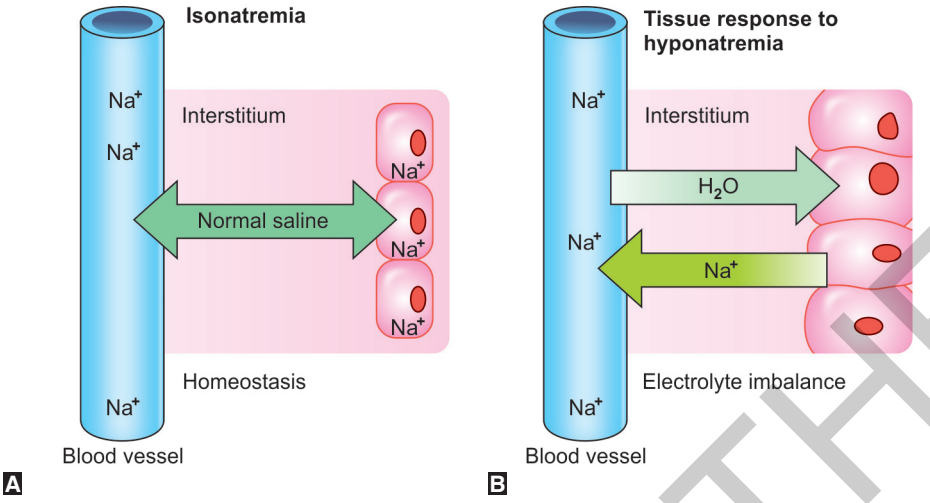

Figs 25.5A and B: Tissue response to hyponatremia

The Versapoint electrode can be passed through the operative channel of therapeutic sheath of the hysteroscope and small myomas (<2 cm) can be dealt with (Figs 25.4C to E).

The advantage of bipolar electrosurgery:

1. It can be used in saline as distention media.
2. Allows for a larger volume of fluid infusion with minimum risk of fluid overload.
3. Reduced risk of hyponatremia compared to non-physiologic solutions.[30-31] Intravascular absorption of non-physiologic solutions may cause hyponatremia, which can result in cerebral and pulmonary edema or cardiac arrhythmia. Normal saline contains physiologic levels of sodium and, therefore, does not disrupt homeostasis (Figs 25.5A and B).
4. Controlled predictable tissue effects.
5. No stray current through patient's body.

Mechanism of Versapoint (Fig. 25.6)

The bipolar system of Gynecare Versapoint functions as follows:

Saline acts as a "safety valve", pulling the electrosurgical current through the path of least resistance and back in the return electrode to the generator.

Vaporization creates a vapor pocket or steam bubble that causes instantaneous cellular rupture upon contact with tissue.

Desiccation dehydrates the cells and leads to hemostasis. Energy returns through the return electrode to prevent over treatment or carbonization.

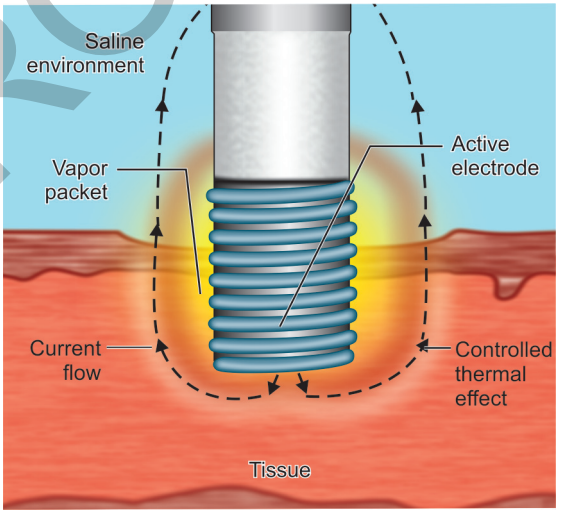

Fig. 25.6: Mechanism of Versapoint

Limitatons with Versapoint

1. Electrodes cannot be used for large myomas but with the bipolar resectoscope, large myomas can be dealt with.
2. Cost of equipment and disposables is the major concern.
3. Since it works with the principle of vaporization, the specimen is not available for histopathological examination.

Complications with Versapoint

Complications as such, only with Versapoint, are rare but air embolism can be a possibility.

JAYPEE BROTHERS

Reproductive Medicine

Challenges, Solutions and Breakthroughs

Reproductive medicine and the field of assisted reproduction has never seemed more promising, yet more challenging. In the strife to give and get the best, the gush of advances in endoscopy, molecular biology, drug technology, and assisted reproduction techniques have resulted in the emergence of new concepts, taking clinical and laboratory practice to undaunted heights. Third party reproduction, promoted by cross-border reproductive tourism and the boon of new cryopreservation techniques, is celebrated now like never before, regardless of traditional societal obligations or the pressure of age or time, to satisfy the unanimous motive for a child.

The first global cooperation between Indian and French doctors was the Indo-French Congress on Gynecologic Endoscopy, Ultrasound and Infertility, organized by Rotunda— The Center for Human Reproduction, Mumbai, Maharashtra, India. The mystic city of Varanasi, Uttar Pradesh, India, played the perfect host to the exploration of the feminine mystique and medical possibilities. This was the first global cooperation between Indian and French doctors in the field and was a milestone in related academia on the Indian subcontinent. The idea of compiling a textbook with Indian and French authors, contributing their experience, was initiated by Dr Gautam N Allahbadia and Professor René Frydman. They also invited experts from other French-speaking countries to contribute chapters as well.

This book is a meticulously designed volume and a detailed insight into how the most complex clinical and laboratory situations can be tackled to realize success. The book is divided into 14 distinct sections, with 89 methodically listed chapters enriched with the knowledge and evidence-based clinical and research experience of world authorities in the field, the book leaves no stone unturned. From gynecological endoscopy, ultrasonography, ovarian stimulation protocols, contemporary clinical management, ART outcomes, regulations, laboratory management and its future to preimplantation genetic diagnosis and beyond, the book has it all, being well-equipped to reach out to practicing clinicians, technicians, researchers, students in training or just the anxious patient grouping for the right knowledge in this vast field. By bringing experts to this common forum of expression, the editors aim to disseminate clinically useful knowledge in reproductive medicine with tailored solutions to problems that should pave the way for conceptually clear, judgmentally conscientious and long-term safe solutions punctuating the seemingly endless quest for a healthy child.



Sulbha Arora is a Consultant Fertility Specialist at the Rotunda Blue Fertility Clinic and Keyhole Surgery Center. She joined the medical team of Rotunda (2004) as a Clinical Associate, and set-up India's first budget IVF Center, the Rotunda Blue Fertility Clinic and Keyhole Surgery Center, Dadar, Maharashtra, India, as its Scientific Director (2008). She was awarded the Mumbai Obstetric and Gynaecological Society (MOGS) Dr Shantabai Gulabchand Traveling Fellowship (2009), which enabled her to complete her Fellowship in Basic and Advanced Reproductive Techniques from the Chaim Sheba Medical Center, Israel. She is on the Editorial Board of IVF Lite (Journal of Minimal Stimulation IVF) and has been a peer reviewer for the journals—Fertility and Sterility and the Journal of Obstetrics and Gynecology of India (JOGI).



Rubina Merchant joined the assisted reproduction team at Rotunda—The Center for Human Reproduction, Bandra, Mumbai, Maharashtra, India, as an Embryologist (2001). She is a Doctorate in Genetics and a Masters in core Life Sciences. After working with the basic assisted reproductive techniques and contributing to the motive of the infertile patients for an initial period, in league with the brilliance and vision of Dr Gautam N Allahbadia, she dedicated her efforts towards the collation and dissemination of invaluable scientific knowledge and expertise of world authorities in the field to assist clinicians, embryologists, andrologists, researchers, scientists, students and patients alike crack answers to dilemmas that confound infertility management, and to make success more tangible within the ethical, moral and legal confines. She has numerous publications in landmark scientific journals and has edited several stimulating volumes in the areas of assisted reproduction, obstetrics, gynecological endoscopy and infertility, infertility management, polycystic ovary syndrome, third party reproduction and minimal stimulation IVF that go a long way to inspire, upgrade and transform clinical practice into a result-oriented and satisfying experience.



Gautam N Allahbadia is the Medical Director of Rotunda—The Center for Human Reproduction, the world-renowned infertility clinic at Bandra, Mumbai, Maharashtra, India, including three other group-clinics in Mumbai at Shivaji Park, Lokhandwala-Andheri and Navi-Mumbai. He is currently, also a visiting IVF consultant and Medical Director at the New Hope Gynecology and Fertility Hospital, Sharjah, UAE, and directs two Franchisee satellite Rotunda IVF units in Varanasi, Uttar Pradesh, India, and Kumasi, Ghana. The development of a highly successful egg donation program at Rotunda has made it possible to achieve pregnancies in women, who have premature ovarian failure.

He and his world-class team of reproductive endocrinologists, embryologists, andrologists and infertility specialists have helped hundreds of couples to have babies through assisted reproduction. He is a noted world authority on the ultrasound-guided embryo transfers and one of the pioneers in third party reproduction in South-East Asia, with India's first transethnic surrogate pregnancy involving a Chinese couple's baby delivered by an unrelated Indian surrogate mother, and India's first same-sex couple pregnancy and delivery of twins to his credit. Having completed his training in an IVF/ICSI at the University of Gottingen, Bielefeld IVF Center and the University of Munich, Germany, he has been instrumental in developing new fertility-enhancing protocols and propagating the use of ultrasound in embryo transfer procedures. He cherishes 125 peer-reviewed publications, over 125 scientific papers, 114 book chapters and 18 textbooks, the latest being a comprehensive textbook, entitled Minimal Stimulation IVF, and is on the Editorial Board of several international journals. He has also been instrumental in setting up 17 private IVF Centers in India in 2000-2012, and 8 Rotunda IVF Franchisee units in 2000-2011 as an IVF Consultant. He is the recipient of over 25 prizes and fellowships, the Canadian Young Scientist Fellowship Award (1994), the national prize Dr Kumud P Tamaskar Award and FOGSI-CORION National Research for original research work in infertility in the years 1991 and 1998, respectively, and the prestigious Deutscher Akademischer Austauschdienst Fellowship (1996) to train in assisted reproductive techniques in Germany. He is the recipient of six research grants from the International College of Surgeons and the Medical Research Centre of Bombay Hospital Trust. He has been an invited guest speaker or faculty member at over 200 Congresses, Workshops and Scientific Meetings and has organized several international conferences in the field. He has recently been elected as the Vice President of the World Association of Reproductive Medicine (WARM), headquartered in Rome.

Shelving Recommendation
OBSTETRICS & GYNECOLOGY

ISBN 978-93-5025-778-4
9 789350 257784

Available at all medical book stores or buy directly from Jaypee Brothers through online shopping at www.jaypeebrothers.com

JAYPEE

JAYPEE BROTHERS
Medical Publishers (P) Ltd.
www.jaypeebrothers.com