Textbook of
DENTAL ANATOMY
and
ORAL PHYSIOLOGY
Including Occlusion and Forensic Odontology





Manjunatha BS

Forewords
C Bhasker Rao
GS Kumar
R Gowramma

JAYPEE

Contents

1. Introduction **1**

Manjunatha BS, Dharam Hinduja

- Functions of Teeth 2
- Aims of Dental Anatomy 2
- Objectives of Dental Anatomy 2
- Scope of Dental Anatomy 2
- Evolution of Teeth 3
- Definitions 3
- The Deciduous Dentition 3
- The Permanent Dentition 4
- Dental Formula 4

2. Definitions and Meaning of Terms Used in Dental Anatomy **5**

Manjunatha BS, Dharam Hinduja

- Terms 5
- Parts of a Tooth 6
- Structures (Tissues) of a Tooth 7
- Surfaces of a Tooth 8
- Terms Used in the Description of Morphology of a Tooth 10
- Tooth Form and Function 20
- Division of Tooth in Different Directions 21
- Line and Point Angles of Different Teeth 22

3. Tooth Numbering Systems **24**

Manjunatha BS

- Zsigmondy/Palmer System 24
- Universal System 26
- FDI/Two Digit System 27

4. Development of Occlusion **30**

Manjunatha BS, Narayan Kulkarni, Rajashekhara BS

- Predentate Period 30
- Deciduous Dentition 33
- Mixed Dentition 38
- Permanent Dentition 47

5. Permanent Incisors **49**

Manjunatha BS

- Functions of Incisors 49
- Maxillary Incisors 50
- Maxillary Central Incisor 50
- Maxillary Lateral Incisor 57
- Mandibular Incisors 62
- Mandibular Central Incisor 62
- Mandibular Lateral Incisor 66

6. Permanent Cuspids **70**
Manjunatha BS
- Functions of Canines 70
- Class Traits [General Characters] of Canines 71
- Maxillary Canines 72
- Chronology of Permanent Maxillary Canine 73
- Mandibular Cuspids 77
- Chronology of Permanent Mandibular Canine 78

7. Premolars **81**
Manjunatha BS
- Functions of Premolars 81
- Class Traits [General Characters] of Premolars 81
- Maxillary First Premolar 82
- Chronology of Permanent Maxillary First Premolar 83
- Maxillary Second Premolar 87
- Chronology of Permanent Maxillary Second Premolar 87
- Permanent Mandibular Premolars 91
- Permanent Mandibular First Premolar 91
- Chronology of Mandibular First Premolar 92
- Mandibular Second Premolar 96
- Chronology of Mandibular Second Premolar 97

8. Permanent Molars **103**
Manjunatha BS
- Functions of Molars 103
- Permanent Maxillary Molars 104
- Permanent Maxillary First Molar 105
- Chronology of Permanent Maxillary First Molar 106
- Permanent Maxillary Second Molar 113
- Chronology of Permanent Maxillary Second Molar 113
- The Permanent Mandibular Molars 116
- Permanent Mandibular First Molar 116
- Chronology of Permanent Mandibular First Molar 116
- Permanent Mandibular Second Molar 124
- Chronology of Permanent Mandibular Second Molar 124

9. Deciduous Dentition **128**
Manjunatha BS, Rajashekhara BS, Mallikarjuna M Rachappa
- Maxillary Central Incisor 129
- Maxillary Lateral Incisor 130
- Maxillary Canine 131
- Maxillary First Molar 132
- Maxillary Second Molar 134
- Mandibular Central Incisor 135
- Mandibular Lateral Incisor 137
- Mandibular Canine 137
- Mandibular First Molar 138
- Mandibular Second Molar 140
- Differences Between Deciduous and Permanent Dentition 142

10. Occlusion **146**
Manjunatha BS, Narayan Kulkarni, Ramesh Naykar
- Other Factors Associated with Occlusion 149
- Dynamic Occlusion 154
- Keys to Occlusion 155
- Factors Affecting the Occlusion 158
- Age Changes in Occlusion 159
- Balanced Occlusion 159

11. Vascularity and Innervation of Maxilla and Mandible **161**
Nagarajappa Das
- Venous Drainage of Maxilla and Mandible 161
- Nerve Supply to the Maxilla and Maxillary Teeth 161
- Nerve Supply to the Mandible and Mandibular Teeth 165

12. Tooth Anatomy and Forensic Odontology **167**
Ashith B Acharya
- Definition of Metric Dental Traits 167
- Definition of Non-metric Dental Traits 168
- Sex Identification from Tooth Size 173
- Race Identification from the Dentition 175

13. Carving Steps of Different Teeth **181**
Gururaj B Patil
- Carving of a Rectangle from Wax Block 181
- Carving of a Cylinder from Wax Block 181
- Carving of a Basic Model 182
- Carving of Central Incisor 182
- Carving Steps in Canine 186
- Carving of Premolar 189
- Carving of Molars 192
- Carving of Mandibular Molar 195

14. Trait Features of Teeth **198**
Manjunatha BS

15. Calcium and Phosphorus Metabolism **204**
Manjunatha BS
- Physiological Functions of Calcium 204
- Distribution in the Body 205
- Dietary Sources of Calcium 205
- Calcium Absorption 206
- Recommended Dietary Allowance 206
- Calcium Balance 207
- Calcium Homeostasis 207
- Parathyroid Hormone 208
- Calcitonin 210
- Vitamin D 211
- Effects of Other Hormones on Calcium Metabolism 212
- Applied Physiology 212
- Phosphate Metabolism 213

16. Functions of Teeth **216**
Manjunatha BS

17. Pain **218**
Nagarajappa Das, Manjunatha BS
- History 218
- Components of Pain 218
- Types of Pain 219
- Theories of Pain 220
- Distribution of Pain Receptors 222
- Pathway of Pain in Orofacial Region 222
- Dentinal Sensitivity and Pulpal Pain 222
- Control of Pain 225

18. Saliva **226**
Manjunatha BS
- Composition of Saliva 226
- Saliva Components 227
- Properties of Saliva 228
- Factors Influencing Salivary Flow and Composition 229
- Functions of Saliva 230
- Lubrication and Protection 230
- Buffering Action 231
- Antimicrobial Activity 231
- Mechanical Cleansing Action 232
- Taste 232
- Digestion 232
- Bolus Formation for Swallowing 233
- Maintenance of Tooth Integrity 233
- Miscellaneous Functions 234
- The Diagnostic Applications of Saliva 234
- Disadvantages/Limitations of Saliva 237

Index *239*

CHAPTER 2

Definitions and Meaning of Terms Used in Dental Anatomy

Manjunatha BS, Dharam Hinduja

Eyes can't see what mind doesn't know

It is very much essential to be familiar with the basic knowledge of the subject when someone enters a new field of study. Without adequate knowledge in the field, one cannot understand or learn the subject properly. So it is very important to know definitions, meaning and explanations of many terminologies used in description of tooth morphology. Thus, the basic foundation of the subject of dental anatomy, one should become familiar with these terms, which are in use throughout the professional life.

TERMS

- **Dentition:** It is defined as the arrangement of natural teeth (single or multiple sets) or artificial dentures in the mouth of an individual. Human beings have two sets of dentition, which has already been discussed in the previous chapter
- **Dental arch:** It is that part of the jaw which gives attachment to the root portion of teeth and is held in position to each other. The teeth are arranged in the upper and lower jaws in the form of two dental arches
- **Maxillary:** It refers to entities which are related to the upper jaw or the maxilla
- **Mandibular:** It refers to entities which are related to the lower jaw or the mandible
- **Quadrant:** It represents one side of a jaw either maxilla or mandible which are normally bilaterally symmetrical (Fig. 2.1)

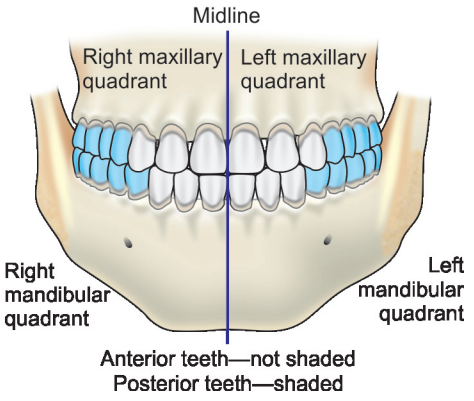

Fig. 2.1: Quadrants in maxilla and mandible

JAYPEE BROTHERS

- **Alveolus:** That part of the bony jaw which surrounds the roots of teeth and gives attachment to periodontal ligament, thus supporting the tooth.

Teeth are of different groups namely incisors, canines, premolars and molars, depending on their shape, size and functions. They are bounded by the lips, cheeks and tongue on either side.

The term '**Anterior**' refers to the direction towards front side close to lips and '**Posterior**' refers to the direction towards the back side, next to the cheek of an individual's head/face respectively.

Anterior teeth are the six upper and six lower front teeth that consists of incisors and canines. Incisors are used to cut the food. Cuspids are meant for the function of gripping and tearing food. Other than these prime functions, anterior teeth have significance in proper phonation and aesthetics of an individual. Mastication or chewing is the major function of posterior teeth.

PARTS OF A TOOTH

Each tooth consists of a crown and a root joined at a slightly thinner part, called the neck. The tissue that surrounds the neck of a tooth and covers the jawbone is called the gum or gingiva.

- **Crown:** The portion of a tooth, above the gum line which is visible in the mouth (outside)
- **Root:** The part of a tooth embedded inside the jaw and holds the tooth in place within the bone.

Anatomical Crown

It is that part of the crown of a tooth which is covered by enamel surface.

Clinical Crown

It is that part of the tooth that is visible or exposed to outside in the oral cavity. This may be larger or smaller than the anatomic crown. The clinical crown is larger, when some part of the anatomic root is exposed due to recession or reduction in the size of gingiva.

Anatomical Root

It is that part of the root of a tooth which is covered by cementum surface.

Clinical Root

Part of the tooth present within the gingiva and is not exposed to oral cavity.

Cervical Line

It is a thin line, which separates the anatomic crown and the anatomic root. It is also termed as cemento-enamel junction.

JAYPEE BROTHERS

Root Trunk

It is that part of the root which starts from the cervical line to the furcation area of multirooted teeth.

Furcation

It is the junction of roots in multirooted teeth mainly in posterior teeth.
Bifurcation and trifurcation: It is the junction of two and three roots in multirooted posterior teeth.

Apex

It is the tapered end of the root tip of a tooth.
Apical foramina: It is the communicating channel or opening between the periodontal membrane and the pulp. It is usually present at the apex of the root. (pleural of foramen—'foramina')

Pulp Cavity

It is a collective or general term used to designate the central part of a tooth which has housed the 'pulp' tissue of both crown and the root which is continuous in nature.
Pulp chamber: The part of the pulp cavity seen only in the crown of a tooth.
Pulp canal: The part of the pulp cavity seen in the root canal(s) of a tooth.
Pulp horn: It is the highest point or peak of the pulp chamber, which corresponds to the cusp or incisal tips located in the crown of a tooth.

STRUCTURES (TISSUES) OF A TOOTH

Structurally, teeth are composed of four different tissues (Fig. 2.2), which are as follows:

- **Enamel:** The outer most part of crown of the tooth and is the hardest tissue in the body. It is an avascular and acelluar tissue, so not considered as living tissue
- **Dentin:** Present below the enamel and cementum, and it is the second hardest tissue that makes up the bulk of the tooth. In contrast, it is a living tissue and is less hard than enamel. It also surrounds the pulp all around both in crown and root of a tooth
- **Cementum:** Covers the root part of a tooth that is embedded in the bone
- **Pulp:** Present in the center of the tooth and is made of loose connective tissue. It contains nerves and blood vessels, which enter the tooth through the apical foramen at the tip of the root.

Enamel, dentin and cementum are hard tissues of the tooth. The pulp is the 'only' soft tissue of the tooth. The crown and the root join at the cemento-enamel junction and also termed as 'cervical line', which is visible as a separating line on

JAYPEE BROTHERS

a tooth specimen with the naked eye. It is advised to refer an oral histology text book for complete detailed information regarding the microscopic structure and histological features of these individual tissues of a tooth.

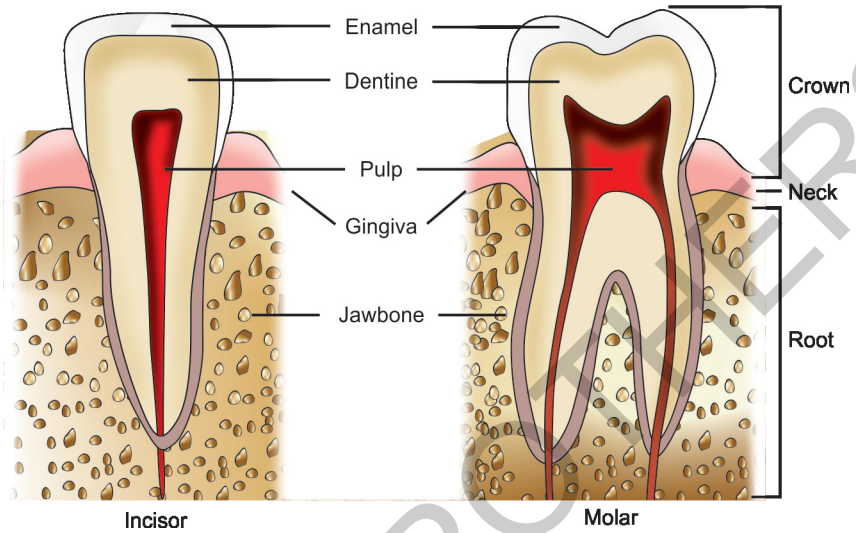

Fig. 2.2: Microscopic structure of the tooth and associated parts

SURFACES OF A TOOTH

Both anterior and posterior teeth have five surfaces, which are named according to their positions and uses (Fig. 2.3). These are named so for the convenience of the clinician in practice and record maintenance. The following terms are used for the surfaces of the teeth:

- **Labial surface:** It refers to the side of a tooth that is adjacent or towards the inner side of the lip. Technically, only anterior teeth have a close relationship with lips. The term 'labium' means lips, so the surface towards lips is termed as labial surface
- **Buccal surface:** It refers to the side of a tooth that is adjacent or towards the inner side of the cheek. Applies only to posterior teeth, where the cheeks are present instead of lips. The term buccal is derived from buccinator muscle which is chief muscle in the formation of cheek
- **Facial surface:** It refers to the surface next to the face; the outerside of a tooth that is adjacent to the cheek or lips. This term may be used to describe both the term buccal and labial in anterior and posterior teeth as well
- **Lingual surface:** It refers to the side of a tooth adjacent to or towards the tongue. Although this term is technically specific to the mandible, still it is in extensive use in reference to the maxilla as well
- **Palatal surface:** It refers to the side of a tooth adjacent or towards the palate. This term is absolutely used in the maxilla and not for mandibular teeth

JAYPEE BROTHERS

- **Mesial surface:** It refers to the direction towards the midline, in the anterior part of a dental arch in each quadrant
- **Distal surface:** It refers to the direction furthest from the midline of a dental arch in each quadrant. All teeth except the last tooth (normally third molar in permanent and second molar in decidious dentition) in each quadrant of a dental arch have a distal surface
- **Proximal surface:** It is a general term which includes both mesial and distal surfaces. when referring to the proximal surface i.e. mesial or distal surface of a tooth lying next to another tooth. Surfaces that are in close proximity to each other; the mesial surface of one tooth touches the distal surface of the adjacent tooth in the same arch
- **Incisal edge:** It refers to the biting edge of anterior teeth. It is usually not called as surface because incisors and canines have a thin cutting edge instead of a broad chewing surface, seen in case of posteriors
- **Occlusal surface:** It refers to the biting surface of posterior teeth
- **Cervical area:** It means 'neck' in Latin, refers to the narrowing of the tooth surface at or near the CEJ, where the crown meets the root
- **Gingival area:** It refers to the direction towards the gingiva.

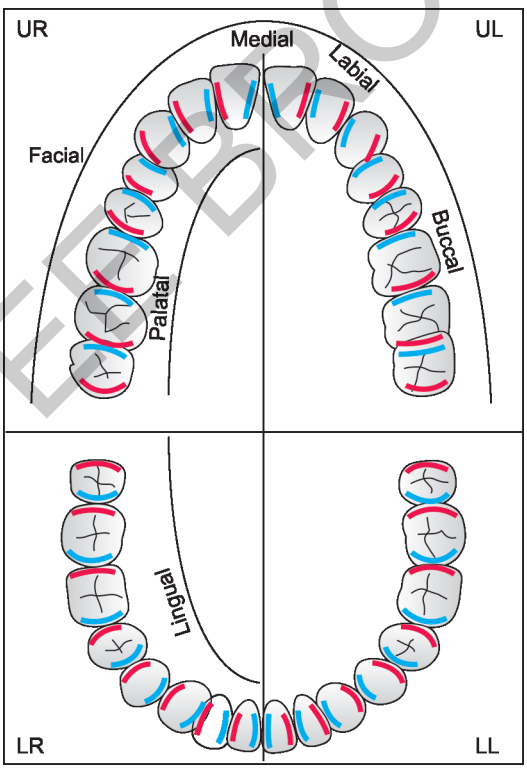

Fig. 2.3: Surfaces of a tooth

JAYPEE BROTHERS

TERMS USED IN THE DESCRIPTION OF MORPHOLOGY OF A TOOTH

Cusp

Literally, a cusp is a sharp point or a cone at the tip seen in two or three dimensional structures respectively. A number of technical terms are derived and in use for this, giving a wide range of meaning in various fields. In dentistry, cusp is a 'pointed' or 'rounded elevation' on the crown of a tooth.

It is defined as "a functional elevation or a peak present on the chewing (incisal or occlusal) surface of the crown of a tooth, which divides the respective surface into many parts". It is found on cuspids and on the chewing surfaces of bicuspids and molars. Canine has 'one' cusp and premolars have 'two' cusps, so named as 'cuspid' and 'bicuspids' respectively. Cusp has all histological components of a crown such as enamel, dentin and pulp.

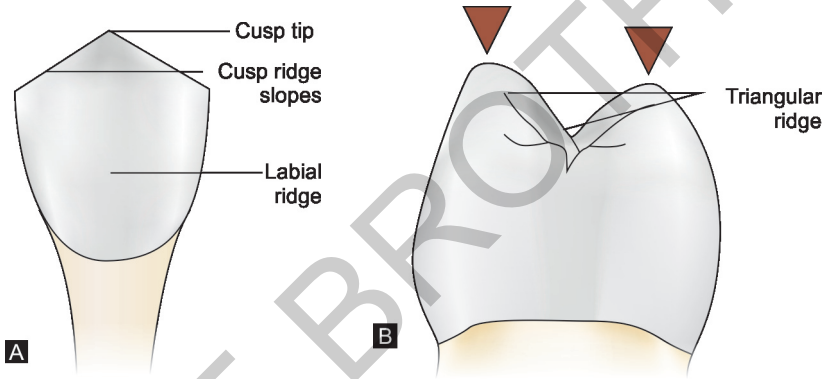

Figs 2.4A and B: Facial and proximal view of tooth showing cusps

Parts of a cusp: Basically a pyramid/cone and has the following:

- Two cusp slopes or cusp ridge slopes: These are inclined surfaces that form an angle at the tip and are named as mesial and distal cusp slopes or cusp arms (Fig. 2.4A)
- One cusp tip (Fig. 2.4A)
- Labial/buccal/lingual ridge: Anyone for the respective cusp
- Triangular ridge only in occlusal surface of posteriors (Fig. 2.4B).

Ridge

It is defined as 'a linear elevation found on the surface of the crown of a tooth' and named according to its location and/or form.

Types of ridges: Various types of ridges are seen in different teeth and are named accordingly on the surface in which they are situated.

- **Labial ridge:** It is the ridge seen on labial surface. It runs cervico-incisally almost in the center of labial surface (Fig. 2.5).

Example: Prominent labial ridge running from cusp tip to cervical area, on labial surface of canines

JAYPEE BROTHERS

- **Buccal ridge:** It is the ridge seen on buccal surface. It runs cervico-occlusally approximately in the center of buccal surface.
  Example: Prominent buccal ridge noted on the buccal surface of premolars and molars mainly in permanent dentition.
- **Lingual ridge:** The ridge present on the lingual surface, which extends from the cingulum to the cusp tip in permanent canines and posteriors.

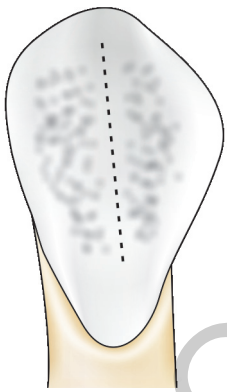

Fig. 2.5: Labial ridge in anterior tooth

- **Marginal ridge:** It is a linear, rounded border of enamel that forms the mesial and distal margins of the lingual and occlusal surfaces of anterior and posterior teeth respectively. There are two marginal ridges on each tooth seen at the mesial and distal ends respectively (Fig. 2.6). They are named as:
  - Mesial MR
  - Distal MR

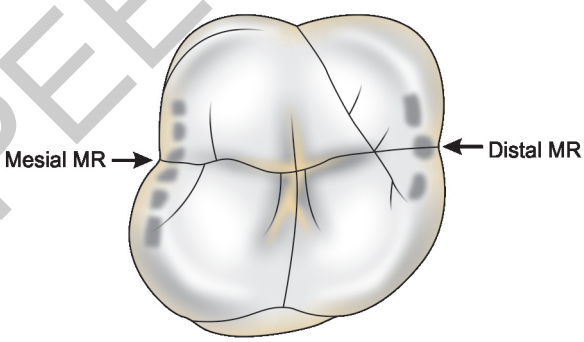

Fig. 2.6: Marginal ridge in posterior tooth

- **Triangular ridge:** Triangular ridge is present only on premolar and molars. It runs (descends/inclines) from cusp tip up to the center of the occlusal surface. It is designated so because two slopes of each side of the ridge meet to form a triangular ridge and resemble two sides of a triangle. Each triangular ridge is named according to the cusp from which it forms and located either on a facial or a lingual cusp (Fig. 2.7).

JAYPEE BROTHERS

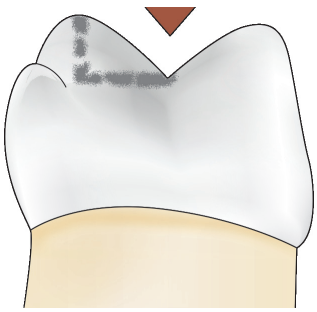

Fig. 2.7: Triangular ridge in posterior tooth

- **Transverse ridge:** This ridge is formed by union of buccal and lingual triangular ridges that crosses the surface of a posterior tooth in transverse (buccolingual) direction. These are roughly 90° to both the buccal and lingual tooth surfaces. Transverse ridges are present on the occlusal surface of premolars and permanent mandibular molars (Fig. 2.8).

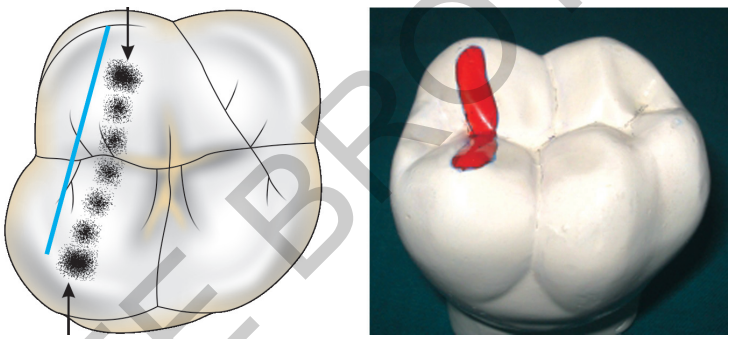

Fig. 2.8: Transverse ridge in posterior tooth

- **Oblique ridge:** It is formed by union of triangular ridges of the mesiopalatal and the distobuccal cusps, in oblique direction. Oblique ridges are present on the occlusal surface of maxillary deciduous second molar and all permanent maxillary molars (Fig. 2.9).

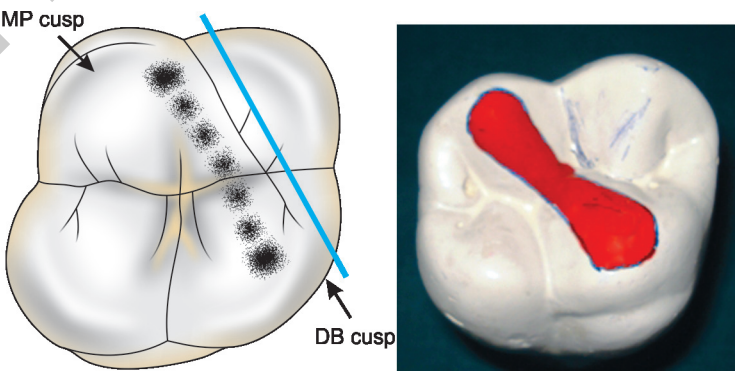

Fig. 2.9: Oblique ridge in maxillary permanent molar

JAYPEE BROTHERS

- **Cervical ridge:** It runs mesiodistally at cervical 1/3rd buccal surface of the crown, present on all deciduous teeth and only on permanent molars.

Cingulum

A cingulum is the convexity or a bulge or a lobe, found on the cervical 1/3rd of lingual aspect of anterior teeth. It is derived from a Latin word meaning 'girdle' or 'belt'.

It is defined as 'a girdle encircling the cervical 1/3rd of lingual surface of the crown of anterior teeth'. It makes up the bulk of the cervical part of the lingual surface of anteriors (Fig. 2.10).

It is prominent in permanent than in deciduous teeth and also in maxillary than mandibular teeth.

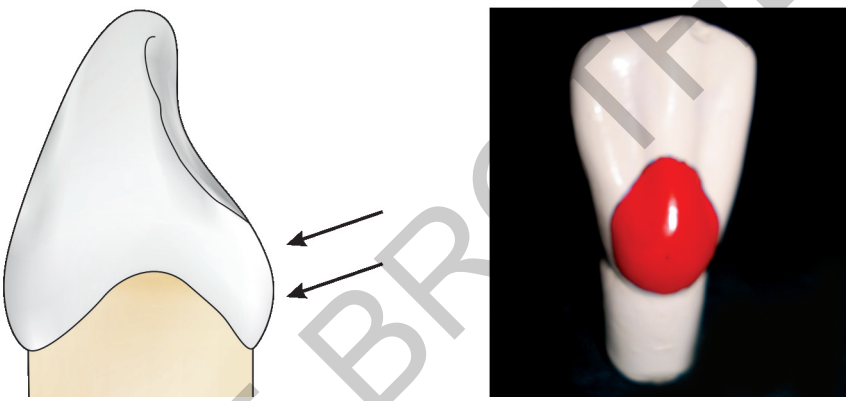

Fig. 2.10: Cingulum from proximal and lingual surfaces

Tubercle

It is a small elevation present on the crown of a tooth due to extra formation of enamel. For example, tubercle of Carabelli present on the palatal aspect of mesiopalatal cusp of permanent maxillary first molar and maxillary deciduous 2nd molar. Tubercle of Carabelli is a small additional cusp, first described in 1842 by George Carabelli.

Eminence

It is a prominence or projection of a bone or enamel on a tooth surface. Canine eminence is very prominent on the labial aspect of the root surface of permanent maxillary canine, which has a cosmetic value.

Fossa

It is defined as a rounded or an irregular depression or concavity, present on a surface of the crown of a tooth (plural of fossa—'fossae').

Types of Fossa

- **Lingual fossa:** It is an Irregular, shallow depression found on the lingual surfaces of incisors and cuspids (anterior teeth) (Fig. 2.11)

JAYPEE BROTHERS

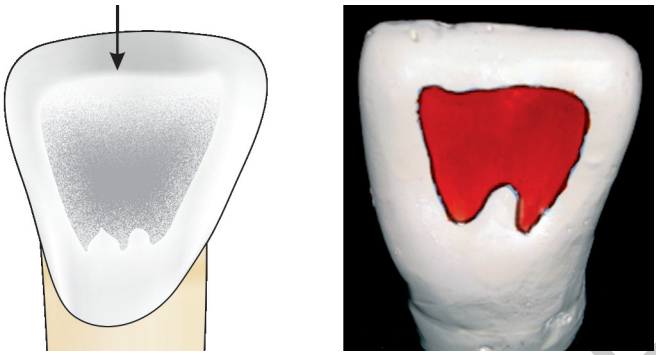

Fig. 2.11: Lingual fossa

- **Triangular fossa:** These are situated next to mesial and distal marginal ridges on the occlusal surfaces of posterior teeth. Two types of triangular fossa are mesial and distal triangular fossae (Fig. 2.12). Triangular fossae are considered as minor fossa

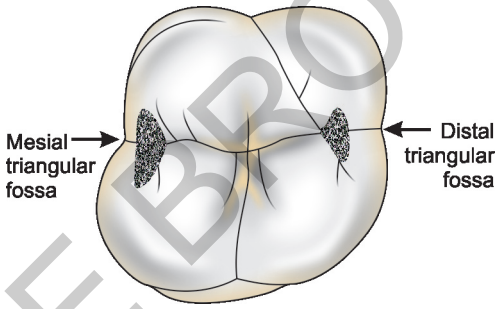

Fig. 2.12: Triangular fossa

- **Central fossa:** It is centrally located depression found on the occlusal surface of maxillary and mandibular molars. Other bicuspids have mesial and distal triangular fossa, but do not have a central fossa. Central fossa is considered as major fossa (Fig. 2.13).

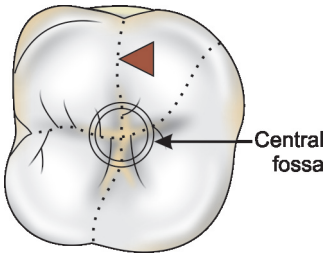

Fig. 2.13: Central fossa in posterior tooth

JAYPEE BROTHERS

Developmental Depression

It is a long, narrow, linear depression on the long axis of mesial and distal surfaces of the root of a tooth, formed during the development of the tooth.

Developmental Groove

It is a short, shallow, line or depression between primary parts of the crown or root of a tooth formed during the development. Developmental grooves usually separate lobes or major parts of a tooth (Fig. 2.14).

Example: Buccal and lingual/palatal developmental groove, mesial marginal ridge groove.

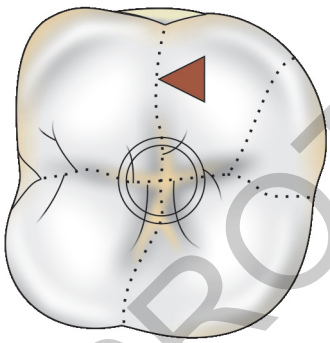

Fig. 2.14: Developmental grooves

Supplemental Groove

Supplemental grooves are numerous, less distinct, shallow, linear, depressions on the occlusal surface of teeth, which are supplemental to a developmental groove and do not represent the junction of primary parts of a tooth unlike the developmental groove. It is a minor, auxiliary groove that branches off from a prominent developmental groove and gives the occlusal surface a wrinkled appearance (Fig. 2.15).

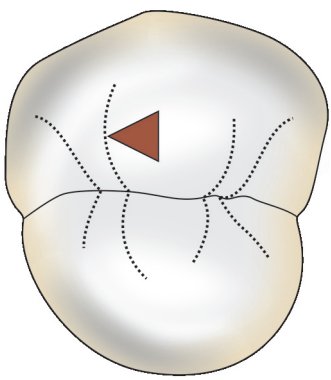

Fig. 2.15: Supplemental grooves

JAYPEE BROTHERS

Sulcus

It is a long depression/valley on the surface of a tooth seen between ridges and cusps. Sulcus slopes/inclines towards the center and meet at an angle, which is mainly noted on the occlusal surface of posteriors (Fig. 2.16).

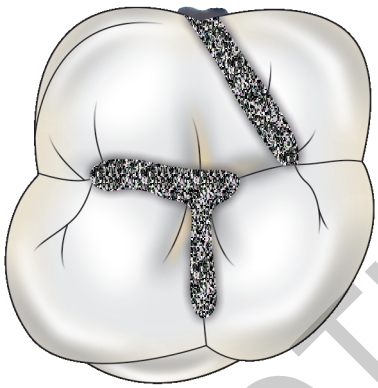

Fig. 2.16: Sulcus in molars

Pit

Pits are small, pin point depressions located at the junction or terminal part of developmental grooves. It is a small defect in the enamel of crown of the tooth, usually present at the junction of four formative lobes of a developing tooth.
Example: Buccal pit, lingual/palatal pit, central pits.

- Buccal pit is terminal part of buccal developmental groove
- Lingual pit is terminal part of lingual developmental groove.

Fissure

It is a narrow channel/cleft, located at the depth of a developmental groove formed during development of a tooth (Fig. 2.17). This may rarely extend from developmental grooves inwards into the pulp.



Fig. 2.17: Cross section of tooth showing the fissure

JAYPEE BROTHERS

Lobe

It is the center of formation in the development of the crown of a tooth. In simple words 'Lobe is one of the primary divisions of a crown' and is usually separated by developmental grooves. For development of any tooth minimum of 4 lobes are necessary.

In anterior teeth (Fig. 2.18A),

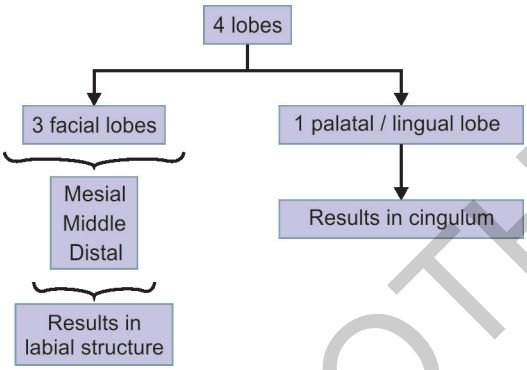

In posterior teeth, number of cusps is equal to number of lobes (Fig. 2.18B). Each lobe results in one cusp in all posterior teeth including decidious teeth.

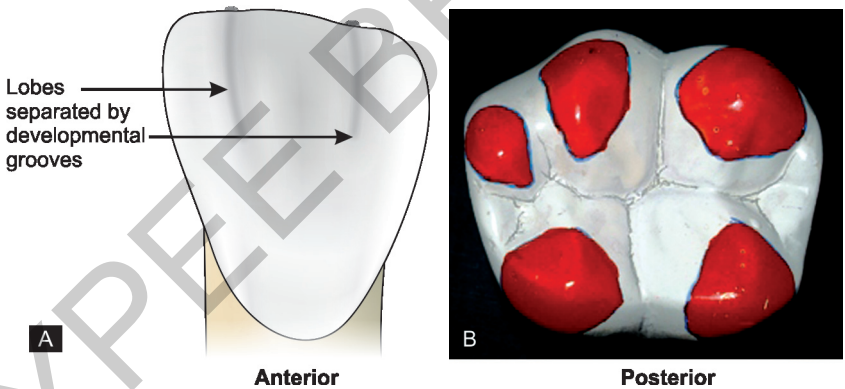

Figs 2.18A and B: Lobes in anterior and posterior teeth

Mamelons

These are small rounded protuberances/projections of enamel found on the incisal edges of newly erupted incisors (Fig. 2.19A). Mamelons are found predominantly in permanent and also in maxillary than in mandibular incisors. These projections wear away soon after eruption due to masticatory forces. They are three in number which are mesial, middle and distal named according to the lobe. Mesial is the largest and middle is the smallest (Fig. 2.19B).

JAYPEE BROTHERS

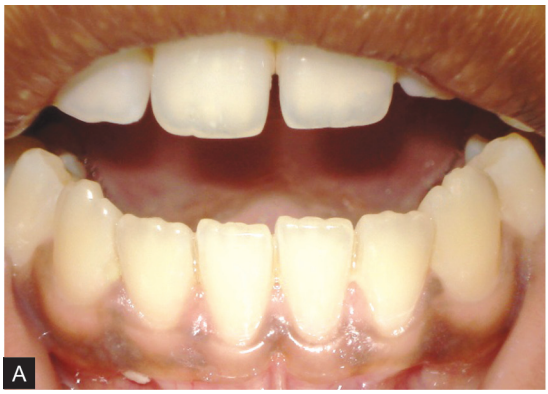

Figs 2.19A and B: Mamelons in newly erupted teeth

Crest of Curvature

It is the greatest convexity or the bulge on the surface of a tooth.

Contact Point

It is the crest of curvature on the proximal surface of the crown of a tooth where two adjacent teeth of the same arch are in contact for proper alignment in the jaw. Normally, it is pronounced as 'point' in anteriors as the contact is not wider as in case of posteriors.

Contact Area

It is the crest of curvature on the proximal surface of the crown of a tooth where two adjacent teeth of the same arch are in contact for proper alignment in the jaw. Normally, it is pronounced as 'area' as the contact is broader in case of posterior teeth unlike anteriors where contact is point or a smaller area.

Diastema

It is the space between two adjacent teeth that don't contact with each other which are supposed to be present normally.

Interproximal Space

This is the triangular space seen between two adjacent teeth, cervical to the contact area.

Embrassure

Embrassure is a potential 'V' shaped space that surrounds the contact areas and narrowed at contact area, widening towards facial, lingual and occlusal surfaces. There are different types of embrassures named according to the surfaces it is located. Embrassures are also termed as 'spillways', which help in escape of food during mastication and prevent food impaction (Fig. 2.20).

JAYPEE BROTHERS

Types of embrassures are as follows:

- Labial/buccal embrassure termed as 'facial embrassure'
- Lingual/palatal embrassure
- Occlusal/incisal
- Gingival embrassure.

Lingual/palatal embrassure is larger than others. This is because most teeth converge lingually.

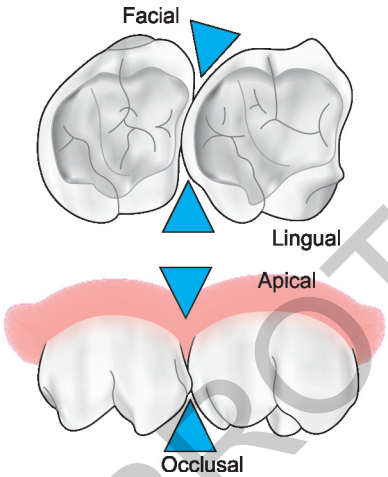

Fig. 2.20: Embrassures

Interdental Papilla

It is the triangular pad of gingival tissue filled in the interproximal space between two adjacent teeth in the same arch (Fig. 2.21).

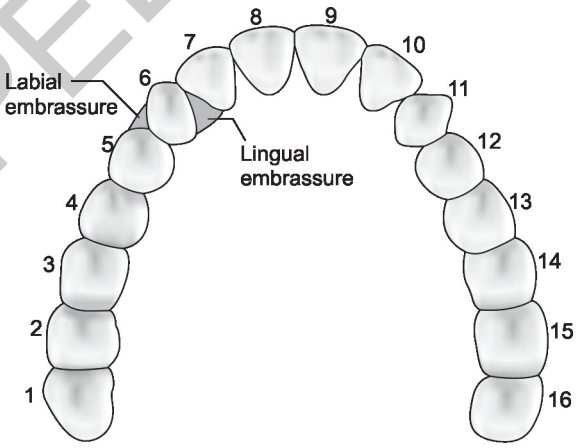

Fig. 2.21: Interdental papilla in interproximal space

JAYPEE BROTHERS

Textbook of

DENTAL ANATOMY and ORAL PHYSIOLOGY

Including Occlusion and Forensic Odontology

Textbook of Dental Anatomy and Oral Physiology Including Occlusion and Forensic Odontology covers today's need of the complex field of dental anatomy while also motivating students to venture beyond memorization to a broader understanding of the concepts. The textbook is completely updated and based on students who are new to the field. This is organized into four major sections and adds important new details, including expanded coverage of dental anatomy with occlusion, oral physiology, steps to tooth carving and forensic odontology. This is a very practical book on the application of dental anatomy and forensic odontology to oral medicine, general dentistry, orthodontics, prosthetics, implantology, endodontics including conservation of tooth and orofacial surgery.

SALIENT FEATURES

- Outstanding full-color art illustrations, images of original cases that make it easy-to-understand the subject to stimulate critical thought
- Each chapter has a brief outline and a narrative illustrating an important aspect of each tooth that will be made clear to the student
- At the end of each chapter, summaries are organized in a readable two-column format
- A thoroughly updated undergraduate textbook, engages the student with details of morphology of each tooth with color illustrations of anomalies
- Includes up-to-date knowledge of forensic odontology and oral physiology
- Provides richly-illustrated chapters with useful teaching tools written in an accessible style and simple English
- Reviewed thoroughly by experts for depth of coverage and use of terminology appropriate for undergraduates.

Manjunatha BS BDS MDS (DNB) completed his Masters in Oral and Maxillofacial Pathology from SDM College of Dental Sciences, Dharwad, Karnataka, India. In the past eight years, he has been working as Assistant Professor and Reader in the subject of Oral and Maxillofacial Pathology in many reputed colleges and universities. Currently, he is working as Associate Professor in KM Shah Dental College and Hospital, Vadodara, Gujarat, India. He has authored more than 30 scientific papers both in indexed national and international journals.



Shelving Recommendation
DENTISTRY

Available at all medical book stores
or buy directly from Jaypee Brothers through online shopping
at www.jaypeebrothers.com

JAYPEE BROTHERS
Medical Publishers (P) Ltd.
www.jaypeebrothers.com

ISBN 978-93-5025-995-5